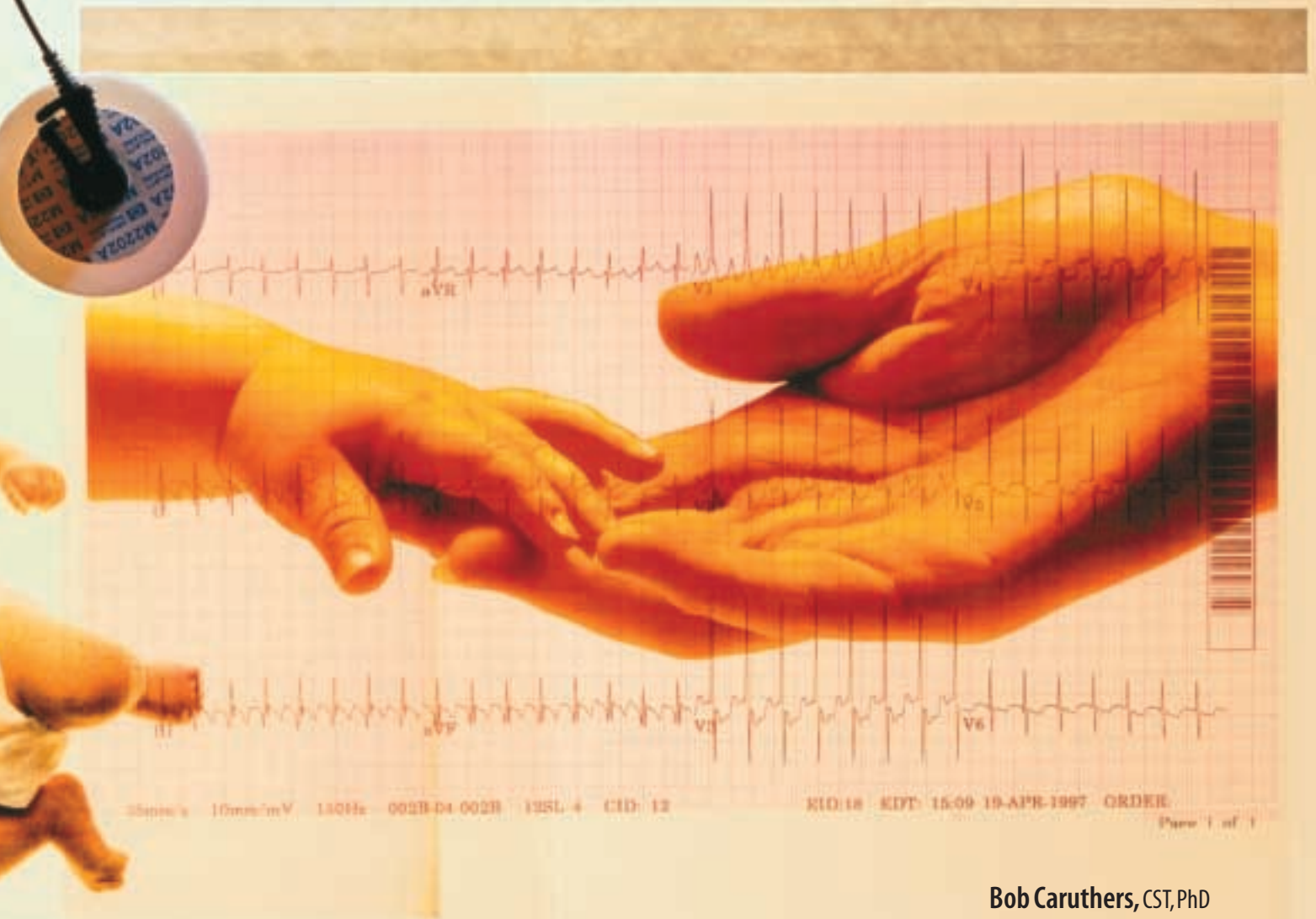




# STRUCTURAL AND MECHANICAL FACTORS ASSOCIATED WITH THE BIRTH PROCESS



**Bob Caruthers, CST, PhD**

Birth is essentially a mechanical process. Labor literally defines the process. The uterus, via the mechanism of contractions, labors to expel the fetus. The fetus does not exit the uterus in a straight line but must complete a journey through a channel that varies in width and depth along its course. Since the channel is constructed primarily of ligament and bone, it is relatively inflexible. The fetus, on the other hand, is relatively flexible. During its journey to the outside world, the walls of the channel force the fetus to make adaptive movements. In order to appreciate the birth process, one must consider the limitations of the pelvis, size of the fetal head, and the path of the center of the fetus.

## The fetal head and the maternal pelvis

The type and diameters of the maternal pelvis determine the structure of the birth canal and the ease or difficulty of the passage of the fetus (Figure 1). The fetal head is both the largest and least compressible part of the fetus, and its relation to the maternal pelvis critically influences the ease or possibility of normal birth.

### Maternal pelvis

The rigid structure of the maternal pelvis is the most limiting factor in the relationship between the fetal head and maternal pelvis. A stylized view of the birth channel is presented in Figure 1. Figure 1a illustrates the funnel-like nature of the female pelvis; Figure 1b illustrates the three-dimensional form at several different levels.

### Pelvic types

There are four basic types of female pelvis based on shape: gynecoid, android, anthropoid, and platypelloid (Figure 2). The gynecoid pelvis is found in approximately 50 percent of all women and represents the normal female pelvis. Generally, this pelvic type forces the fetal head to rotate into an occipitoanterior position. The android pelvis represents the typical male-type of pelvis that is characterized by limited space at all points. The effect of this structural type is to force the fetal head into an occipitoposterior position. Commonly, the descent of the fetus is

arrested with this type of pelvis. The anthropoid pelvis forces the fetus to engage in the anteroposterior diameter, most commonly the occipitoposterior position. The platypelloid pelvis only occurs in 3 percent of the female population. This type pelvis forces the fetal head to engage in the transverse position.

### Pelvic diameters

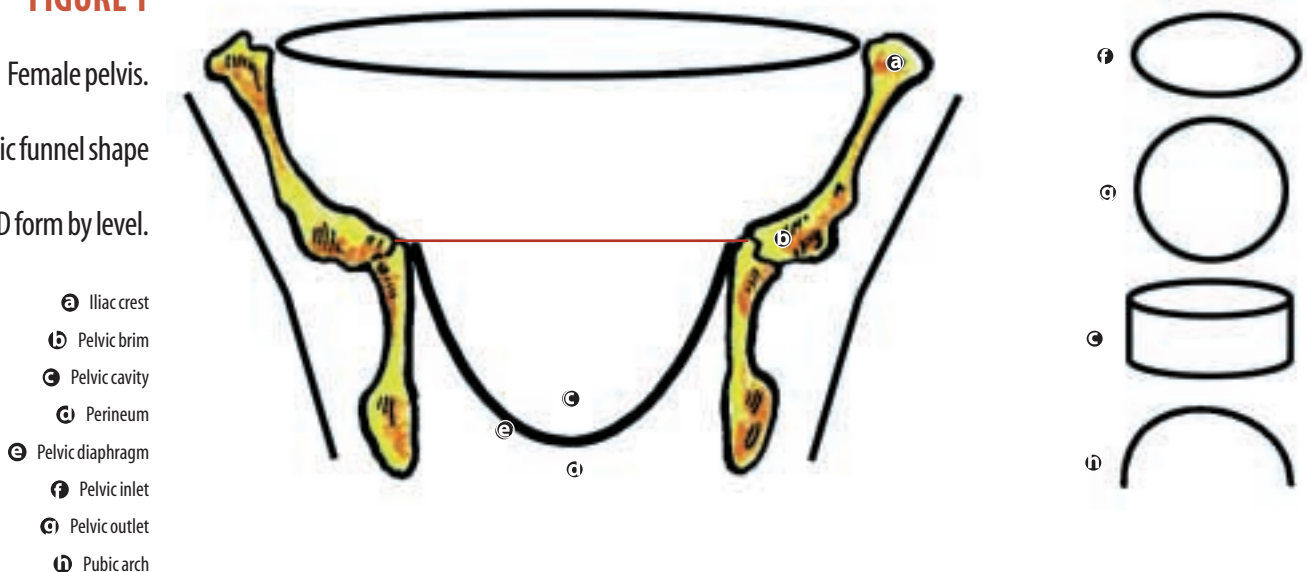
The pelvis is divided into planes that are imaginary flat surfaces, extending across the pelvis at different levels. Diameters are measured at these levels to provide a detailed chart of the space available at a given point in the birth canal (Figure 3). Normal pelvic diameters are listed in Table 1.

### Fetal skull

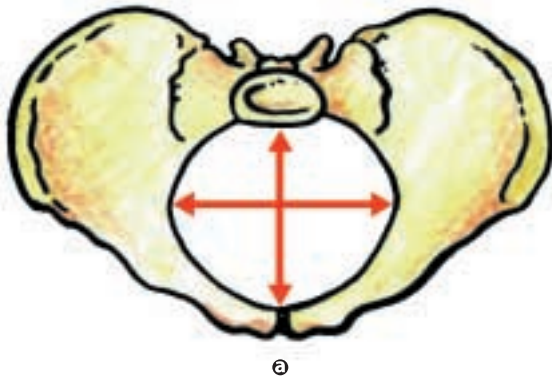
The fetal skull that grows around the developing brain from mesenchyme, includes two parts, the neurocranium and the viscerocranium. The neurocranium forms a protective case around the brain, and the viscerocranium is the primary jaw skeleton. During both fetal and infant stages, dense connective tissue membranes, called sutures, separate the bones of the skull (Figure 4a).

Membrane-filled spaces located at the point where sutures intersect are called fontanelles. The sutures and fontanelles provide critical landmarks for evaluating the position of the fetal

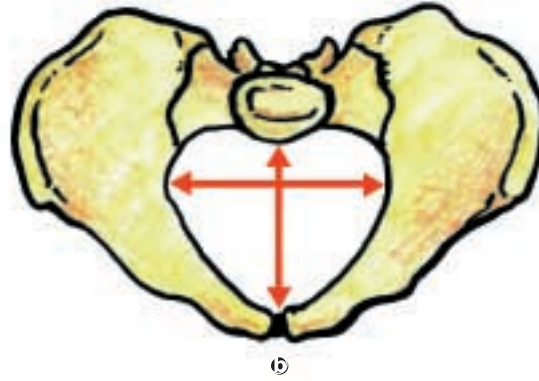
**FIGURE 1**  
Female pelvis.  
Basic funnel shape  
and 3-D form by level.



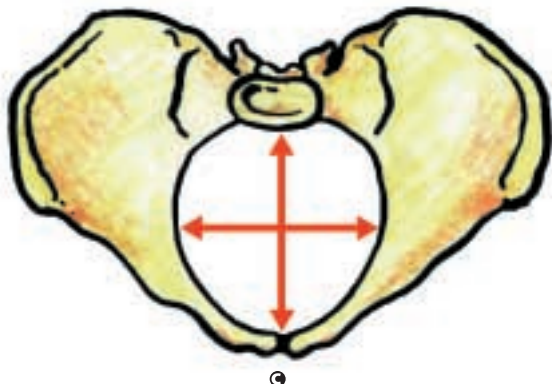




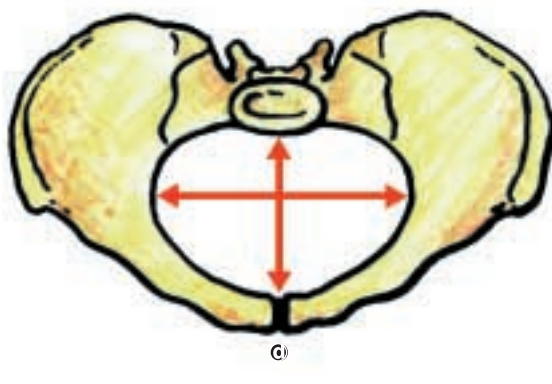
a



b



c



d

**FIGURE 2**

Female pelvic  
types

- a Gynecoid
- b Android
- c Anthropoid
- d Platypelloid

head during birth. The two main fontanelles are the anterior (bregma) and posterior (lambda) fontanelles. The diamond-shaped anterior fontanelle lies at the junction of the frontal, sagittal, and two lateral-coronal sutures. The triangular-posterior fontanelle exists at the junction of the sagittal and the two oblique-lambdoid sutures. This network of skull bones is relatively elastic and held together with loose sutures. Their fontanelle connections allow the skull to undergo considerable molding during labor and delivery.

Extending in an anteroposterior direction between the fontanelles, the sagittal suture lies between the parietal bones and divides the crani-

um into right and left halves. The lambdoid suture moves laterally from the posterior fontanelle and separates the occipital from parietal bones. The coronal suture passes laterally from the anterior fontanelle and separates the parietal and frontal bones. The frontal suture lies between the frontal bones and extends from the anterior fontanelle to the glabella.

A number of other landmarks exist on the fetal skull (Figure 4b):

- Nasion—the root of the nose
- Glabella—an elevated area that lies between the orbital ridges
- Sinciput—the area that lies between the anterior fontanelle and the glabella

- Vertex—the area between fontanelles that is bounded laterally by the parietal eminences
- Occiput—the area behind and inferior to the posterior fontanelle and the lambdoid sutures

Using these markers, a number of diameters can be established for the fetal skull. These diameters are illustrated in Figure 4b. The size of the fetal head bears clinical significance when compared to the maternal pelvis. Average diameters at term are presented in Table 2.

### Cephalopelvic disproportion

Cephalopelvic disproportion (CPD) occurs when the head of the fetus is unable to pass through the pelvis safely. This may be because the pelvis is too small, and/or the head is too large. Potentially severe consequences for CPD are uterine rupture, vesicovaginal fistula, and maternal/fetal death and birth injury. Causative factors are pelvic shape, size of the fetus, and a space-occupying lesion. The two most common space-occupying lesions are an ovarian cyst or a cervical fibroid. In the primigravida patient, CPD should be suspected if any the following conditions exist:

- head remains three-fifths to four-fifths palpable through the abdomen
- latent phase of labor is prolonged
- cervical dilation is retarded
- cervix is poorly applied to the fetal head
- head molding appears excessive
- anterior rotation appears stopped
- fetal heart rate abnormalities occur.

The definitive treatment for CPD is cesarean section.

### Fetal position in utero

Beginning at 28 weeks of pregnancy, the abdomen must be examined carefully to identify the attitude, lie, presentation, and position of the fetus. These related factors are used in combination to produce a full picture of the infant's position in the uterus and its journey through the birth canal. Attitude refers to the relationship of parts of the fetus to one another. The typical attitude is one of complete flexion. The fetus is

**Table 1. Normal pelvic diameters**

Start Pelvic Plane	Diameter	Average length (cm)
Inlet	true conjugate	11.5
	Obstetric conjugate	11
	Transverse	13.5
	Oblique	12.5
	Posterior sagittal	4.5
	Anteroposterior	12.75
Greatest diameter	Transverse	12.5
Midplane	Anteroposterior	12
	Bispinous	10.5
	Posterior sagittal	4.5
Outlet	Anatomic anteroposterior	9.5
	Obstetric anteroposterior	11.5
	Bituberous	11
	Posterior sagittal	7.5

convex with the fetal head over the abdomen. Lie describes the relationship of the long axis of the fetus to the long axis of the mother. The lie may be longitudinal, transverse, or oblique. Presentation refers to the portion of the fetus that descends first in the birth canal.

These factors affect each other. For instance, if the lie is longitudinal, both the long axes of the fetus and mother are oriented in the same direction. The presenting part must be the head in a cephalic presentation or buttocks in a breech presentation. However, if the lie is transverse, the presenting part could be the shoulder. Position indicates the relationship of some definite part of the fetus to the maternal pelvis. For example,

**Table 2 Normal diameters of the fetal skull**

Diameter	Average (cm)
Suboccipitobregmatic	9.5
Occipitofrontal	11
Supraoccipitometal	13.5
Submentobregmatic (Transverse)	9.5
Biparietal	9.5
Bitemporal	8
Circumference	34.5

in a vertex presentation, the occiput is the denominator (structure or reference point used to calculate position), but in a breech presentation the sacrum is the denominator.

**Normal cephalic presentation and select malpresentations**

Normally, the fetus is flexed in a longitudinal lie (Figure 5). The presentation is cephalic with the chin tucked on the chest. The fetal head faces the mother’s buttocks. The advantage to this position is that the smallest fetal diameter leads the way.

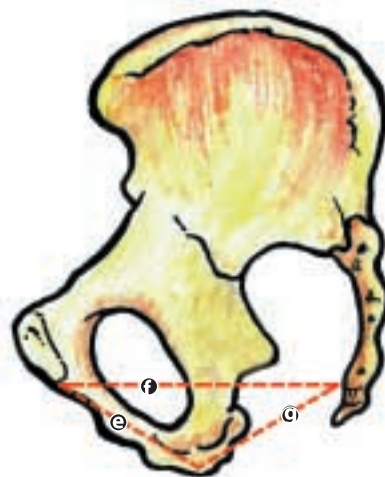
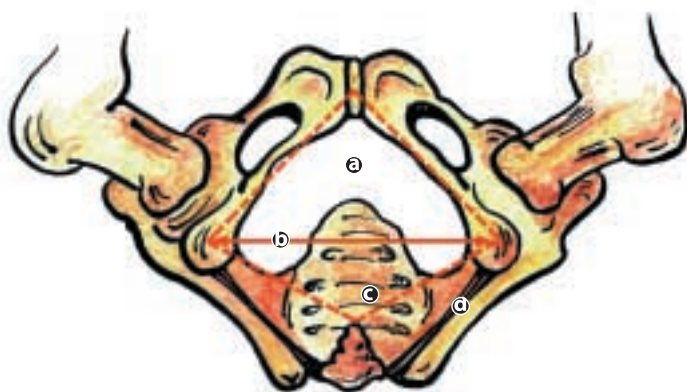
**Occiput posterior**

A relatively common malpresentation of the cephalic presentation finds the fetal head down with the chin tucked. Called the occiput-posterior position, the face is oriented toward the mother’s abdomen or with the chin extended. This orientation forces the larger surface of the fetal head to lead the descent. This position often results in prolonged labor and increased perineal tears. It is associated with severe labor pains experienced in the back. CPD is a frequent result of this fetal position (Figure 6a).

The occiput-posterior position also serves to illustrate the mechanics of labor in another way. Maternal position can affect the progress of labor. Positioning the mother on her hands and knees allows the uterus to move away from the back. This may relieve back pain, and the more relaxed uterus may allow the fetus to turn to the normal position. Occiput posterior-positioned fetuses can be delivered vaginally provided adequate pelvic space is present. CPD and cesarean section are common results.

**Face presentation**

In approximately two of every 1,000 births, the chin is not tucked. The extended neck forces a presentation of the top of the head, face, or forehead (Figure 6b). Even with adequate pelvic space, these presentations usually result in extended labor and increased perineal tearing.



**FIGURE 3**

Female pelvic diameters

- a** Anterior triangle
- b** Transverse diameter
- c** Posterior triangle
- d** Sacrotuberous ligament
- e** Anterior sagittal
- f** Obstetric anteroposterior diameter
- g** Posterior sagittal

## FIGURE 4

### Critical markers on the fetal skull

#### A. Superior view

#### B. Lateral view

Diagnosis of this condition is likely to be delayed until vaginal examination at the time of labor. About 60 percent are mentoanterior, 25 percent mentoposterior, and 15 percent mento-transverse. The pelvic presentation is typically submentobregmatic. Forced internal rotation places the chin under the symphysis pubis with delivery requiring the head moved to a flexed position. (See fetal movements section.) The chin and mouth typically present first to the vulva. It must be noted that term vaginal delivery can not be performed with the mentoposterior position, because the head is already flexed at its maximum. Cesarean section should be consid-

ered in the primigravida, and vacuum extraction or forceps delivery may be required.

### Brow presentation

The brow presentation (one in 1,400 births) occurs when the fetal head is neither flexed nor hyperextended. It is in a middle position, presenting the supraoccipital diameter. Seventy-five percent will convert to a vertex or face presentation. This presentation can not be safely delivered vaginally, unless the fetus is quite small.

### Shoulder presentation

This is a rare presentation (0.3 percent) that usually converts to either a longitudinal or transverse lie. Vaginal delivery is not possible, unless the fetus is very small. Cesarean section is the intervention of choice.

### Breech presentation

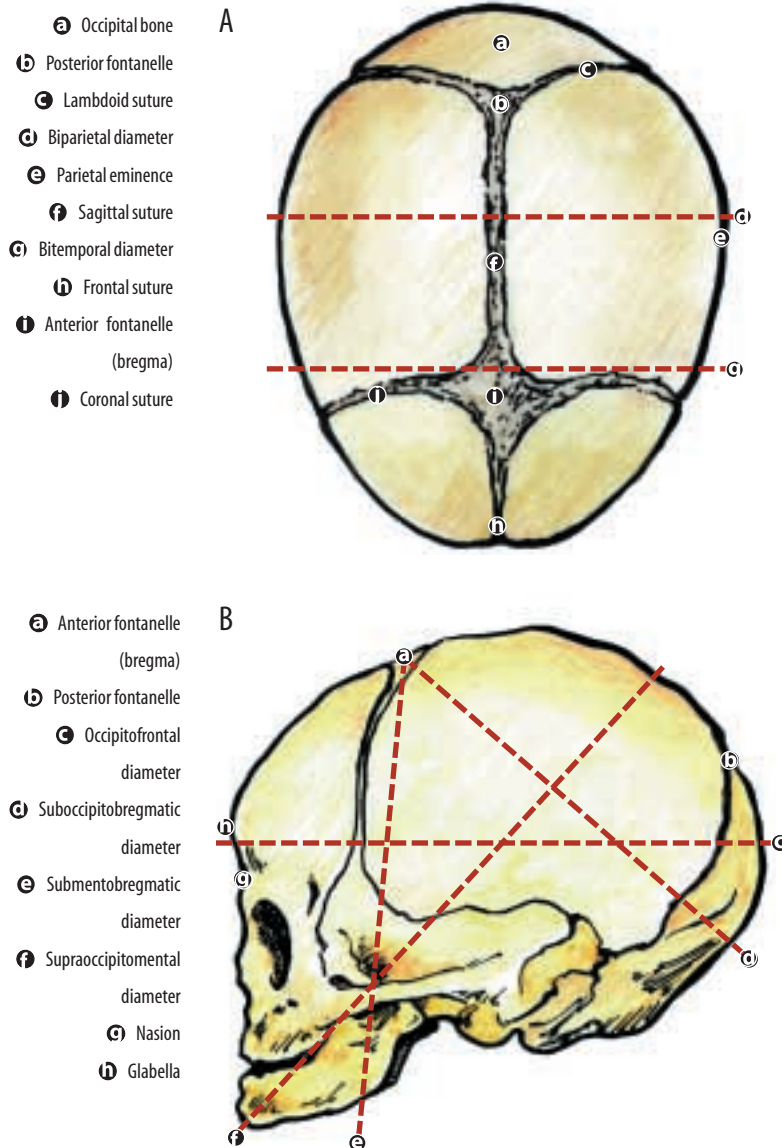
Most fetuses turn to a cephalic presentation approximately three weeks prior to the onset of labor. A few do not make this transition. Breech or rear-end down presentations occur in approximately 3 percent of pregnancies.

Identifiable risk factors associated with breech presentations are:

- multiple pregnancy
- premature birth (before 37 weeks)
- fetus less than 5.5 pounds
- multiparity
- irregular uterine shape (leiomyomas)
- placenta previa
- abnormal amount of amniotic fluid.

### Types of breech presentation

There are three types of breech presentation: (1) frank, (2) complete, and (3) footling (Figure 7). In the frank presentation, the buttocks present breech, legs are held in extension, and the torso is flexed, bringing feet to the face. The legs are folded at the knees, and the feet crossed in a complete breech presentation. In the footling presentation, one or both legs point down and become the leading part.





## Management of the breech position

These positions present two inherent mechanical problems: (1) delivery of the legs without damage to the hips and (2) the greatest fetal diameter, the head, remains in a potentially dangerous position while the body is free. The risk of aspiration is greatly multiplied.

At times, the fetus can be repositioned by external version. Usually, this external manipulation is successful, but many of the fetuses return to their original position. Options decrease as the delivery date approaches.

The standard criteria for attempted vaginal delivery of breech presentations are:

- must be a frank or complete presentation
- minimum 36-week gestational age
- fetal weight 2,500-3,800 grams
- flexed fetal head
- adequate maternal pelvis
- no other reason for cesarean section exists
- anesthesiologist in attendance
- assistant scrubbed and prepared to help guide the head
- experienced obstetrician.

## Fetal movements

The fetus cannot proceed in a straight line through the maternal pelvis. Six movements enable the fetus to adapt to the shape of the maternal pelvis and exit to the outside world. Descent is progressive throughout the labor and delivery process. Uterine contractions, maternal bearing-down efforts and, under certain conditions, gravity affect the rate of the descent. Resistance from the cervix, walls of the pelvis, and pelvic floor cause flexion that, in turn, strengthens the natural flexion found in the fetus in utero. When the fetus is in the occipitoanterior position, flexion changes the presenting part from the occipital frontal to the smaller suboccipitobregmatic.

As descent continues, the fetal head remains in an occipitoanterior position. However, at the vaginal outlet, it moves upward and forward, consequently requiring the head to be extended. As descent continues, the perineum begins to bulge. Crowning indicates the point at which the

largest diameter of the fetal head is encircled by the vulvar ring. The episiotomy, if selected, occurs now. At the time of crowning, the bony pelvis and muscular sling encourage greater flexion. Typically, the forehead, sinciput, and occiput are born as the fetal chin approaches its chest. The occiput then falls back as the head extends and the nose, mouth, and chin are born.

Once the head is delivered, the shoulders follow. The anterior shoulder is assisted by placing gentle pressure toward the floor on the head. This is followed by pressure toward the ceiling to assist the posterior shoulder. Once the shoulders are delivered, the remainder of the body follows quickly. After the cord is cut and the infant is passed to the mother or pediatrician, the placenta is delivered. Next, repairs of lacerations or the episiotomy incision begins.

## Fetal monitoring during labor

Labor is a stressful time for both mother and fetus. Fetal response to labor depends on a number of factors: fetal reserve, umbilical blood flow, adequacy of placental function, intravillous blood flow, uterine blood flow, maternal health and environment, cardiopulmonary function of the mother, as well as the maternal and fetal responses to drugs.

Fetal heart rate provides significant clues about the baby's welfare; therefore, intrapartum monitoring of the fetal heart rate is very important. There are number of ways to monitor the fetal rate, including auscultation. Today, the most common technique is to use an electronic monitoring device. A baseline heart rate should be established and compared to established normal criteria:

- marked tachycardia greater than 180 beats/min
- moderate tachycardia 161-180 beats/min
- normal 120-160 beats/min
- moderate bradycardia 100-119 beats/min
- marked bradycardia less than 100 beats/min.

Variability is the most important feature in assessing the meaning of the fetal heart rate. Short-term changes are controlled by the parasympathetic nervous system. Long-term



## FIGURE 5

### Normal fetal position

changes are controlled by the sympathetic system. Comparisons are made between changes in fetal heart rate in relation to uterine contractions. Some generalizations can be made about variability. Accelerations are always a good sign. Early decelerations have low clinical significance. Mild to moderate decelerations need continued evaluation but are usually not significant. Prolonged, repetitive, or deep decelerations raise the level of suspicion. Late decelerations occur at the contraction, decelerate slowly and return to baseline slowly. These result from vagal stimulation secondary to hypoxia and/or from myocardial depression caused by acidosis. They are clear signs of uteroplacental insufficiency.

## FIGURE 6

### Cephalic malpresentations

- Ⓐ Brow presentation
- Ⓑ Face presentation
- Ⓒ Military attitude

When fetal monitoring results in increased clinical concern, intervention strategies include the following:

- decrease uterine activity by stopping oxytocin infusion,
- correct maternal hypertension, change maternal position, and administer high-flow oxygen,
- rule out prolapse of the umbilical cord, and/or
- stimulate the fetus.

### Summary

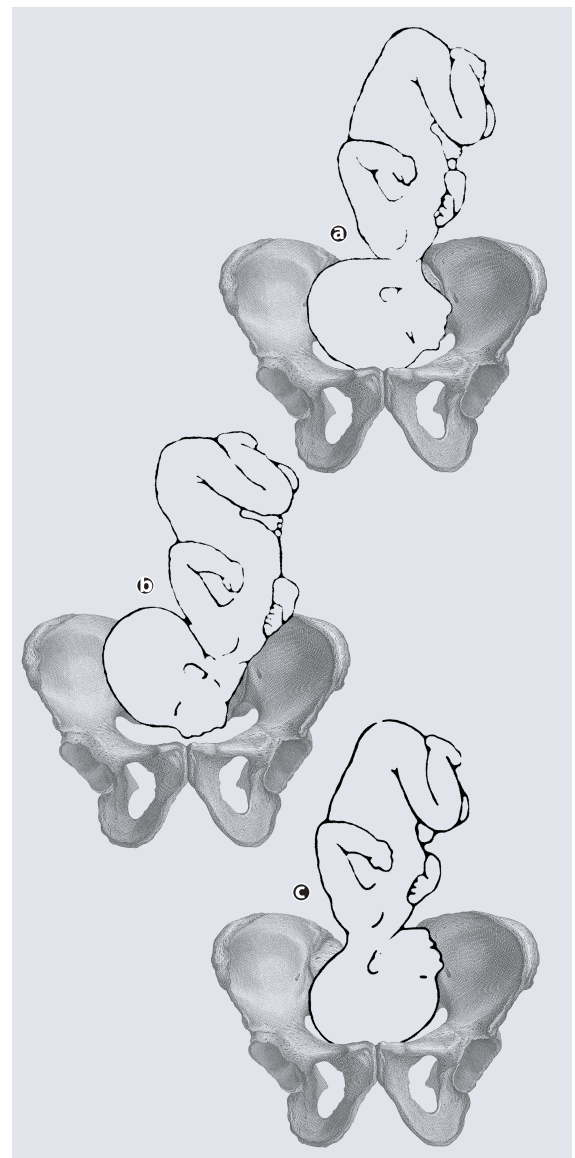
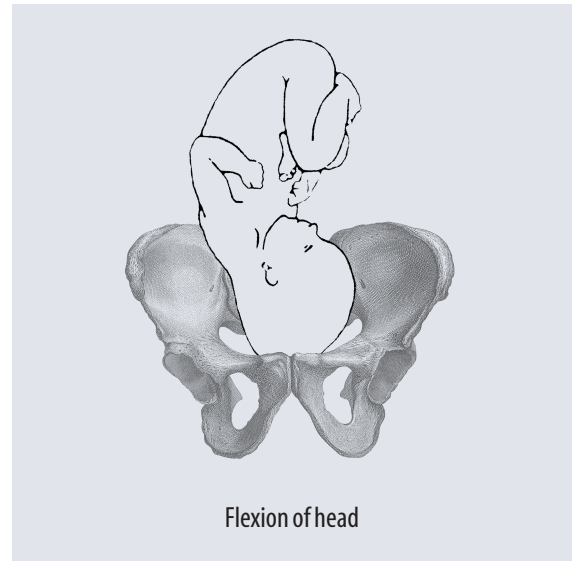
The birth process is a biomechanical event involving:

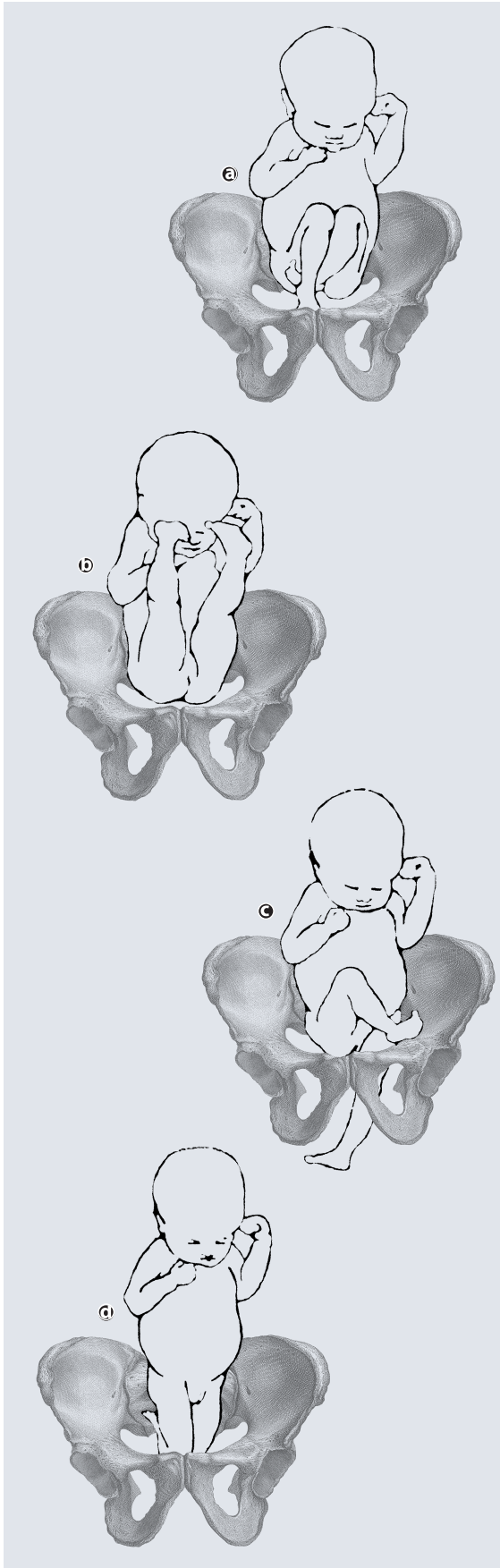
- uterine contractions
- maternal pelvic type
- maternal pelvic space (diameters)
- fetal head size
- intrauterine position of the fetus
- adaptive movements during descent.

The birth process requires adequate monitoring and the ability to intervene as necessary.

### About the Author.

Bob Caruthers, CST, PhD, has been the deputy director of AST and continues to write for the association. He has been a surgical technologist since 1970 and was the surgical technology program director at Austin Community College in Austin, Texas. Deeply committed to surgical technology education, he has authored more





**FIGURE 7**

**Breech**

**presentations**

- a** Complete breech
- b** Frank breech
- c** Footling breech
- d** Kneeling breech

than 20 publications in the field and is the executive editor of AST's new textbook *Surgical Technology for the Surgical Technologist: A Positive Care Approach* (Delmar Thompson Learning, c2000).

**Bibliography**

- De Lancy, JOL. Surgical Anatomy of the Female Pelvis. In *Te Linde's Operative Gynecology*, 8th ed. JA Rock and JD Thompson, eds. Philadelphia, PA: Lippincott-Raven Pub; 1997.
- Ferguson JE, Newbrerry YG, DeAngelis Ga, Finnerty JJ, Agarwal S, Turkheimer E. The fetal-pelvic index has minimal ability in predicting fetal-pelvic disproportion. *American Journal of Obstetrics and Gynecology*. Nov 1998;179(5):1186-92.
- Hacker, NF and Moore, JG. *Essentials of Obstetrics and Gynecology*, 3rd ed. Philadelphia: WB Saunders Co; 1998.
- Holmberg NG, Lillieqvist B, Magnusson S, Segerbrang E. The influence of the bony pelvis in persistent occiput posterior position. *Acta Obstetrics and Gynecology* (Scandinavia) Supplement. 1997;(66):49-54.
- Morgan MA ,Thurnau GR. Efficacy of the fetal-pelvic index in nulliparous women at high risk for fetal pelvic disproportion. *American Journal of Obstetrics and Gynecology*. Mar 1992;166(3):810-4.
- Sakala, EP. *Obstetrics and Gynecology, Board Review Series*. Baltimore, MD: Williams and Wilkins; 1997.

# Structural and mechanical factors associated with the birth process

## Earn CE credit at home

You will be awarded one continuing education (CE) credit for recertification after reading the designated article and completing the exam with a score of 70% or better.

If you are a current AST member and are certified, credit earned through completion of the CE exam will automatically be recorded in your file—you do not have to submit a CE reporting form. A printout of all the CE credits you have earned, including Journal CE credits, will be mailed to you in the first quarter following the end of the calendar year. You may check the status of your CE record with AST at any time.

If you are not an AST member or not certified, you will be notified by mail when *Journal* credits are submitted, but your credits will not be recorded in AST's files.

Detach or photocopy the answer block, include your check or money order made payable to AST and send it to the Accounting Department, AST, 6 West Dry Creek Circle, Suite 200, Littleton, CO 80120-8031.

**Members: \$6 per CE, nonmembers: \$10 per CE**

- Which type of female pelvis shape is considered normal?
  - android
  - anthropoid
  - gynecoid
  - platypelloid
- \_\_\_\_\_ are membrane-filled spaces located at the intersection points of the bones of the skull.
  - fontanelles
  - vertexes
  - sutures
  - diameters
- Uterine rupture and fetal death are two potentially severe consequences of \_\_\_\_\_.
  - ovarian cyst
  - occiput posterior
  - brow presentation
  - cephalopelvic disproportion
- Which refers to the relationship of the long axis of the fetus to that of the mother?
  - attitude
  - lie
  - position
  - presentation
- In which presentation does the baby's head face toward the mother's abdomen?
  - occiput posterior
  - cephalic
  - face
  - normal
- Cephalopelvic disproportion is a frequent result of which fetal position?
  - cephalic
  - face
  - breech
  - occiput posterior
- Only .3 percent of fetuses present as \_\_\_\_\_.
  - breech
  - cephalic
  - shoulder
  - occiput posterior
- Which is not a standard criteria for attempted vaginal delivery of a breech presentation?
  - flexed fetal head
  - fetal weight between 2500-3800 g
  - footling presentation
  - minimum 36-week gestational age
- If needed, the episiotomy occurs during \_\_\_\_\_.
  - descent
  - flexion
  - crowning
  - shoulder delivery
- \_\_\_\_\_ is the most important aspect of fetal monitoring.
  - umbilical blood flow
  - uterine blood flow
  - variability of maternal heartbeat
  - variability of fetal heartbeat

## Structural and mechanical factors . . . birth process

		a	b	c	d		a	b	c	d
<input type="checkbox"/> Certified Member	<input type="checkbox"/> Certified Nonmember	1	<input type="checkbox"/>	<input type="checkbox"/>	<input type="checkbox"/>	6	<input type="checkbox"/>	<input type="checkbox"/>	<input type="checkbox"/>	<input type="checkbox"/>
Certification No _____		2	<input type="checkbox"/>	<input type="checkbox"/>	<input type="checkbox"/>	7	<input type="checkbox"/>	<input type="checkbox"/>	<input type="checkbox"/>	<input type="checkbox"/>
Name _____		3	<input type="checkbox"/>	<input type="checkbox"/>	<input type="checkbox"/>	8	<input type="checkbox"/>	<input type="checkbox"/>	<input type="checkbox"/>	<input type="checkbox"/>
Address _____		4	<input type="checkbox"/>	<input type="checkbox"/>	<input type="checkbox"/>	9	<input type="checkbox"/>	<input type="checkbox"/>	<input type="checkbox"/>	<input type="checkbox"/>
City _____ State _____ ZIP _____		5	<input type="checkbox"/>	<input type="checkbox"/>	<input type="checkbox"/>	10	<input type="checkbox"/>	<input type="checkbox"/>	<input type="checkbox"/>	<input type="checkbox"/>
Telephone _____										

Mark one box next to each number. Only one correct or best answer can be selected for each question.