




PART 1

GENERAL PRINCIPLES AND INSTRUMENTATION FOR CRANIAL NEUROSURGERY

ALBERT L. RHOTON, JR., MD

*Editors Note: This is part one of a two-part article.
This section focuses on the procedure; part two will
cover instrumentation in depth.*

*The surgical technologist plays a key role in success-
fully completing a neurosurgical operation. Achiev-
ing a satisfactory operative result depends on the
performance of the surgical technologist and the
whole operative team and a host of details related
to accurate diagnosis and careful operative plan-
ning. Essential to this plan is having a patient and
family members who are well informed about the
contemplated operation and who understand the
associated side effects and risks. The team's most
important ally in achieving a satisfactory postoper-
ative result is a well-informed patient.*



Scheduling in the operating room should include information about the side and site of the pathology and the position of the patient so that the instruments and equipment can be positioned properly before the arrival of the patient (Figure 1A-D). Any unusual equipment needs should be listed at the time of scheduling. There are definite advantages to operating rooms dedicated to neurosurgery and to having the same surgical technologists for neurosurgical cases who know the equipment and procedures.

Before induction, there should be an understanding regarding the need for steroids, hyperosmotic agents, anticonvulsants, antibiotics, barbiturates, intraoperative evoked potential, electroencephalogram or other specialized monitoring, and lumbar or ventriculostomy drainage. Elastic or pneumatic stockings are placed on the patient's lower extremities to prevent venous stagnation and postoperative phlebitis and emboli. A urinary catheter is inserted if the operation is expected to last more than two hours. If the patient is positioned so that the operative site is significantly higher than the right atrium, a Doppler monitor is attached to the chest or inserted in the esophagus, and a venous catheter is passed into the right atrium so that venous air emboli may be detected and treated. At least two intravenous lines are established if significant bleeding is likely to occur.

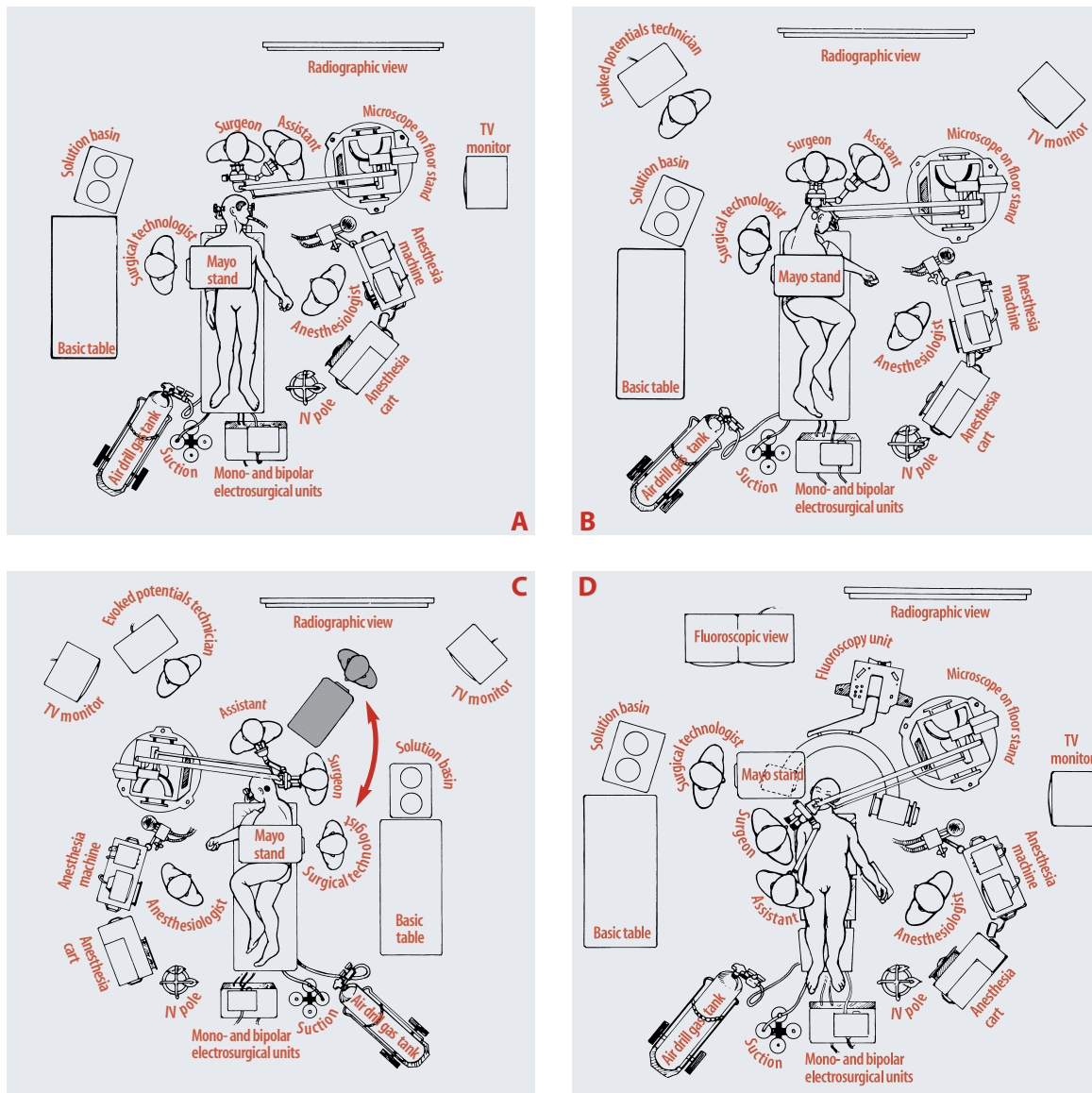
Most intracranial procedures are done with the patient in either the supine or three-quarter prone (lateral oblique or park bench) position, with the surgeon sitting at the head of the table. The supine position, with appropriate turning of the patient's head and neck and possibly elevating one shoulder to rotate the upper torso, is selected for procedures in the frontal, temporal, and anterior parietal areas and for many skull base approaches. The three-quarter prone position with the table tilted to elevate the head is used for exposure of the posterior parietal, occipital and suboccipital areas (Figure 2). Some surgeons still prefer to have the patient in the semi-sitting position for operations in the posterior fossa and cervical region, because the improved venous drainage may reduce bleeding

and because cerebrospinal fluid and blood do not collect in the depth of the exposure. Tilting the table to elevate the head in the lateral oblique position also reduces venous engorgement at the operative site. Extremes of turning of the head and neck which may lead to obstruction of venous drainage from the head, should be avoided. Points of pressure or traction on the patient's body should be examined and protected.

Careful attention in the selection of the position of operating room personnel and equipment ensures greater efficiency and effectiveness. The anesthesiologist is positioned near the head and chest on the side toward which the head is turned to provide easy access to the endotracheal tube and the intravenous and intra-arterial lines, rather than at the foot of the patient, where access to support systems is limited. If the patient is operated on in the supine or three-quarter prone position, the anesthesiologist is positioned on the side toward which the face is turned, and the surgical technologist is positioned at the other side, with the surgeon seated at the head of the patient (ie for a left frontal or frontotemporal approach, the anesthesiologist is positioned on the patient's right side, and the surgical technologist is on the left side).

Greater ease of positioning the operating team around the patient is obtained when instruments are placed on Mayo stands that can be moved around the patient. In the past, large, heavy overhead stands with many instruments were positioned above the body of the patient. The use of Mayo stands, which are lighter and more easily moved, allows the surgical technologist and the instruments to be positioned and repositioned at the optimal site to assist the surgeon. It also allows the flexibility required by the more frequent use of intraoperative fluoroscopy, angiography, and image guidance. The control console for drills, suction, and coagulation is usually positioned at the foot of the operating table, and the tubes and lines are led upward to the operative site.

In the past, it was common to shave the whole head for most intracranial operations, but hair removal now commonly extends only 1.5-2 cm



A Right frontotemporal craniotomy: The anesthesiologist is positioned on the left side of the patient, giving the physician easy access to the airway, monitors on the chest, and the intravenous and intra-arterial lines. The microscope stand is positioned above the anesthesiologist. The Surgical Technologist (ST), positioned on the right side of the patient, passes instruments to the surgeon's right hand. The position is reversed for a right frontotemporal craniotomy, placing the anesthesiologist and microscope on the patient's right side and the ST on the left side. Mayo stands have replaced the large, heavy instrument tables that were positioned above the patient's trunk and restricted access to the patient. The suction, compressed air for the drill, and electro-surgery units are situated at the foot of the patient, and the lines from these units are led up near the Mayo stand so that the ST can pass them to the surgeon as needed. A television monitor is positioned so that the technologist can anticipate the instrument needs of the surgeon.

B Positioning for a right suboccipital craniotomy directed to the upper part of the posterior fossa, such as a decompression operation for trigeminal neuralgia. The anesthesiologist and ST shift sides for an operation on the left side.

C Positioning for a left suboccipital craniotomy for removal of an acoustic neuroma. For removal of a left acoustic tumor, the ST and Mayo stand may move up to shaded area, where instruments can be passed to the surgeon's right hand. For right suboccipital operations or for a midline exposure, the position is reversed, with the ST and Mayo stand positioned above the body of the patient. In each case, the anesthesiologist is positioned on the side toward which the patient faces.

D Positioning for transsphenoidal surgery. The patient's head is rotated slightly to the right to provide the surgeon with a view directly up the patient's nose. The microscope stand is located just outside the C-arm on the fluoroscopy unit. The ST and Mayo stand are positioned near the patient's head above one arm of the fluoroscopy unit.

FIGURE 1

Positioning of staff and equipment in the operating room.

beyond the margin of the incision and in some cases, the hair may be parted without shaving to provide a site for the incision. Care is taken to drape a wide enough area to allow extension of the incision if a larger operative field is needed and allow drains to be led out through stab wounds.

Head fixation devices

A precisely maintained position of the firmly fixed cranium is required. Fixation is best achieved by a pinion head holder in which the essential element is a clamp made to accommodate three relatively sharp pins (Figure 3). When the pins are placed, care should be taken to avoid

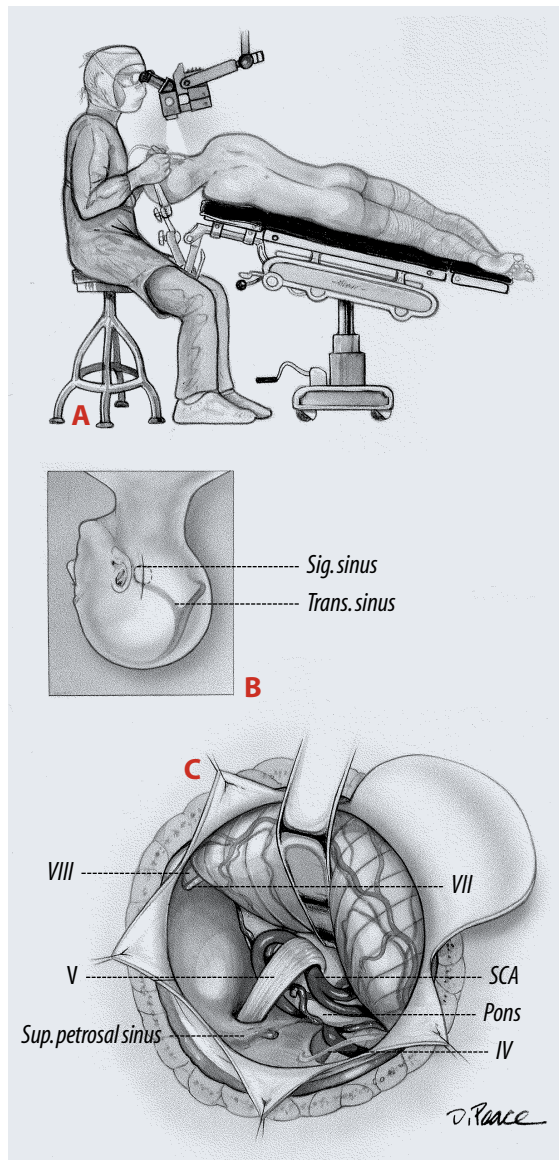
a spinal fluid shunt, thin bones such as those that overlie the frontal and mastoid sinuses, and the thick temporalis muscle, where the pins, however tightly the clamp is applied, tends to remain unstable. The pins should be applied well away from the eye or where they would be a hindrance to making the incision. Special shorter pediatric pins are available for thin skulls. The pins should not be placed over the thin skulls of some patients with a history of hydrocephalus.

After the clamp is secured on the head, the final positioning is done, and the head holder is fixed to the operating table. The clamp avoids the skin damage that may occur if the face rests against a padded head support for several hours. The skull clamps do not obscure the face during the operation as do padded headrests, facilitating intraoperative electromyographic monitoring of the facial muscles and monitoring of auditory or somatosensory evoked potentials. Until recently, all the head clamps were constructed of radiopaque metals, but the increasing use of intraoperative fluoroscopy and angiography has prompted the development of head holders constructed of radiolucent materials. The pinion head clamp commonly serves as the site of attachment of the brain retractor system.

FIGURE 2

Retrosigmoid approach to the trigeminal nerve for a decompression operation.

- a three-quarter prone position (upper left)
- b vertical paramedian suboccipital incision
- c superior cerebellar artery, trochlear (IV), facial (VII), and vestibulocochlear nerves (VIII) exposed



Surgical markers

The surgeon may find it helpful to outline several important landmarks on the scalp prior to applying the drapes. Sites commonly marked include the coronal, sagittal, and lambdoid sutures; the rolandic and Sylvian fissures; and the pterion,inion, asterion, and keyhole (Figure 4). Approximating the site of the Sylvian and rolandic fissures on the scalp begins with noting the position of the nasion,inion, and frontozygomatic point. The nasion is located in the midline at the junction of the nasal and frontal bones at the level of the upper rims of the orbit. The inion is the site of a bony prominence that overlies the torcular and the attachment of the tentorium to the inner table of the skull. The frontozygomatic point is the site of the frontozygomatic suture situated where the frontal bone, which forms the upper margin of the orbit, joins the zygomatic

bone, which forms the lateral margin of the orbit. The frontozygomatic point is located just below the junction of the lateral and superior margins of the orbital rim. It is situated on the orbital rim 2.5 cm above the level where the upper edge of the zygomatic arch joins the orbital rim.

The next step is to construct a line along the sagittal suture and, using a flexible measuring tape, to determine the distance along the mid-sagittal line from the nasion to inion and to mark the midpoint and three-quarter point (50 and 75% points) along the line. The Sylvian fissure is located along a line which extends backward from the frontozygomatic point across the lateral surface of the head to the three-quarter point on the nasion to inion-midsagittal line. The pterion, the site on the temple, approximating the lateral end of the sphenoid ridge, is located 3 cm behind the frontozygomatic point on the Sylvian fissure line.

The Rolandic fissure, which separates the motor and sensory areas of the cerebrum, is located by identifying the upper and lower rolandic points that correspond to the upper and lower ends of the rolandic fissure. The upper Rolandic point is located 2 cm behind the midpoint (50% plus 2 cm point) on the nasion to inion-midsagittal line. The lower Rolandic point is located where a line extending from the midpoint of the upper margin of the zygomatic arch to the upper Rolandic point crosses the line defining the Sylvian fissure. A line connecting the upper and lower Rolandic points approximates the Rolandic fissure. The lower Rolandic point is located approximately 2.5 cm behind the pterion on the Sylvian fissure line.

Another important point is the keyhole, the site of a burr hole, which, if properly placed, has the frontal dura in the depths of its upper half and the orbit in its lower half. The keyhole is located immediately above the frontozygomatic point. It is approximately 3 cm anterior to the pterion, just above the lateral end of the superior orbital rim and under the most anterior point of attachment of the temporalis muscle and fascia to the temporal line. Familiarity with these points

and lines aids placement of a bone flap over the appropriate lobe and intracranial compartment.

Scalp flaps

Scalp flaps should have a broad base and adequate blood supply (Figure 5A). A pedicle that is narrower than the width of the flap may result in the flap edges becoming gangrenous. An effort is made to make scalp incisions so that they are behind the hairline and not on the exposed part of the forehead. A bicoronal incision situated behind the hairline is preferred to extending an incision low on the forehead for a unilateral frontal craniotomy. An attempt is made to avoid the branch of the facial nerve that passes across

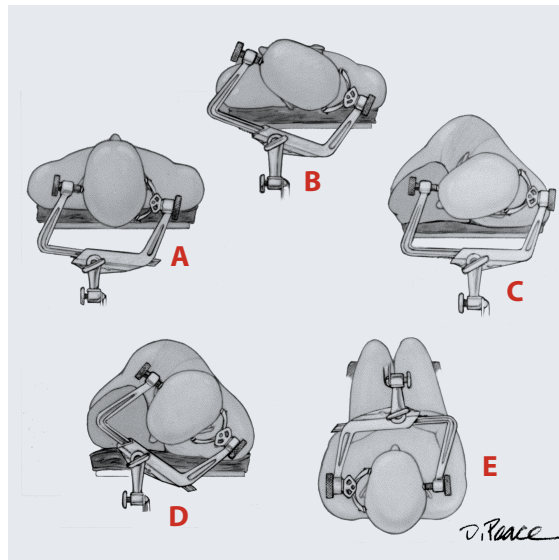


FIGURE 3

Positioning of a pinion head holder for craniotomy.

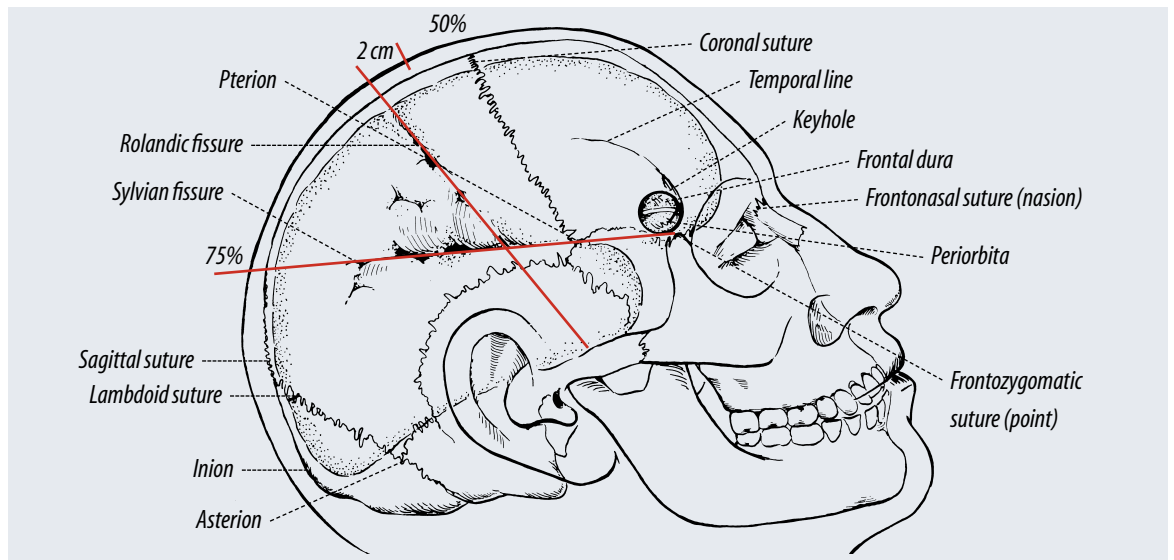
the zygoma to reach the frontalis muscle. Incisions reaching the zygoma more than 1.5 cm anterior to the ear commonly interrupt this nerve unless the layers of the scalp in which it courses are protected. The superficial temporal and occipital arteries should be preserved if there is the possibility that they will be needed for an extracranial to intracranial arterial anastomosis.

In elevating a scalp flap, the pressure of the surgeon's and assistant's fingers against the skin on each side of the incision is usually sufficient to control bleeding until hemostatic clips or clamps are applied. The skin is usually incised with a sharp blade, but the deeper fascial and muscle layers may be incised with cutting electro-surgical

- A** Position for a unilateral or bilateral frontal approach
- B** Position for a pterional or frontotemporal craniotomy
- C** Position for retrosigmoid approach to the cerebellopontine angle
- D** Position for a midline suboccipital approach
- E** Position for a midline suboccipital approach (semi-sitting position)

current. The ground plate on the electrosurgical unit should have a broad base of contact to prevent the skin at the ground plate from being burned. Bipolar coagulation is routinely used to control bleeding from the scalp margins, on the dura, and at intracranial sites. At sites where even gentle bipolar coagulation could result in neural damage, such as around the facial or optic nerves, an attempt is made to control bleeding with a lightly applied gelatinous sponge. Alternatives to gelatinous sponge include oxidized regenerated cellulose, oxidized cellulose, or a microfibrillar collagen hemostat. Venous bleeding can often be controlled with the light application of gelatinous sponge. Metallic clips, often

they extend across an internal bony prominence such as the pterion or across a major venous sinus. The risk of tearing the dura or injuring the brain is reduced by drilling several holes and making shorter cuts. A hole is placed on each side of a venous sinus, and the dura is carefully stripped from the bone, after which the bone cut is completed rather than cutting the bone above the sinus as a part of a long cut around the whole margin of the flap. Bleeding from bone edges is stopped by the application of bone wax. Bone wax is also used to close small openings into the mastoid air cells and other sinuses, but larger openings in the sinuses are closed with other materials, such as fat, muscle, or a pericranial



used on the dura and vessels in the past, are now applied infrequently except on the neck of an aneurysm, because they interfere with the quality of the CT and MRI scan and, if utilized, should be made of nonmagnetic materials.

In the past, bone flaps were often elevated using a series of burr holes, made with a manual or motor driven trephine, that were connected with a Gigli saw. Today, high speed drills are used to place burr holes and cut the margins of a bone flap (Figure 5B). Commonly, a hole is prepared using a burr on a high-speed drill and a tool with a footplate to protect the dura cuts around the margins of the flap (Figures 5C and D). Extremely long bone cuts should be avoided, especially if

graft, sometimes used in conjunction with a thin plate of methylmethacrylate or bone substitute.

After elevating the bone flap, it is common practice to tack the dura up to the bony margin with a few 3-0 black silk sutures brought through the dura and then through small drill holes in the margin of the cranial opening (Figure 5E). If the bone flap is large, the dura is also “snuggled up” to the intracranial side of the bone flap with the use of a suture brought through drill holes in the central part of the flap. Care is taken to avoid placing drill holes for tack-up sutures that might extend into the frontal sinus or mastoid air cells. Tack-up sutures are more commonly used for dura over the cerebral hemispheres than

FIGURE 4

Sites commonly marked on the scalp before applying drapes.

over the cerebellum. If the brain is pressed tightly against the dura, the tack-up sutures are placed after dealing with the intradural pathology when the brain is relaxed and the sutures can be placed with direct vision of the deep surface of the dura. Tack-up sutures can also be led through adjacent muscles or pericranium rather than a hole in the margin of the brain.

In the past, there was a tendency for bone flaps to be elevated and replaced over the cerebral hemispheres and for exposures in the suboccipital region to be done as craniectomies without replacement of the bone. Laterally placed suboccipital exposures are now commonly done as craniotomies with replacement of the bone flaps. Midline suboccipital operations are more commonly done as craniectomies, especially if decompression at the foramen magnum is needed, because this area is protected by a greater thickness of overlying muscles.

Bone flaps may be held in place with sutures brought through drill holes in the flap margin, but nonmagnetic metallic plates are used if sutures passed through the edge of the flap and adjacent bony margins might result in cosmetic deformity due to inward settling of the flap. Holes in the bone are commonly filled with methylmethacrylate or bone substitute, which are allowed to harden in place before closing the scalp or covered with small nonmagnetic plates (Figure 5F).

The dura is closed with 3-0 silk interrupted or running sutures. Small bits of fat or muscle may be sutured over small dural openings caused by shrinkage of the dura. Larger dural defects are closed with pen cranium or temporalis fascia taken from the operative site or with sterilized cadaveric dura or fascia lata, or other approved dural substitutes. The deep muscles and fascia are commonly closed with 1-0, the temporalis muscle and fascia with 2-0, and the galea with 3-0 synthetic absorbable suture. The scalp is usually closed with metallic staples, except at sites where some 3-0 or 5-0 nylon reinforcing sutures may be needed. Skin staples are associated with less tissue reaction than other forms of closure.

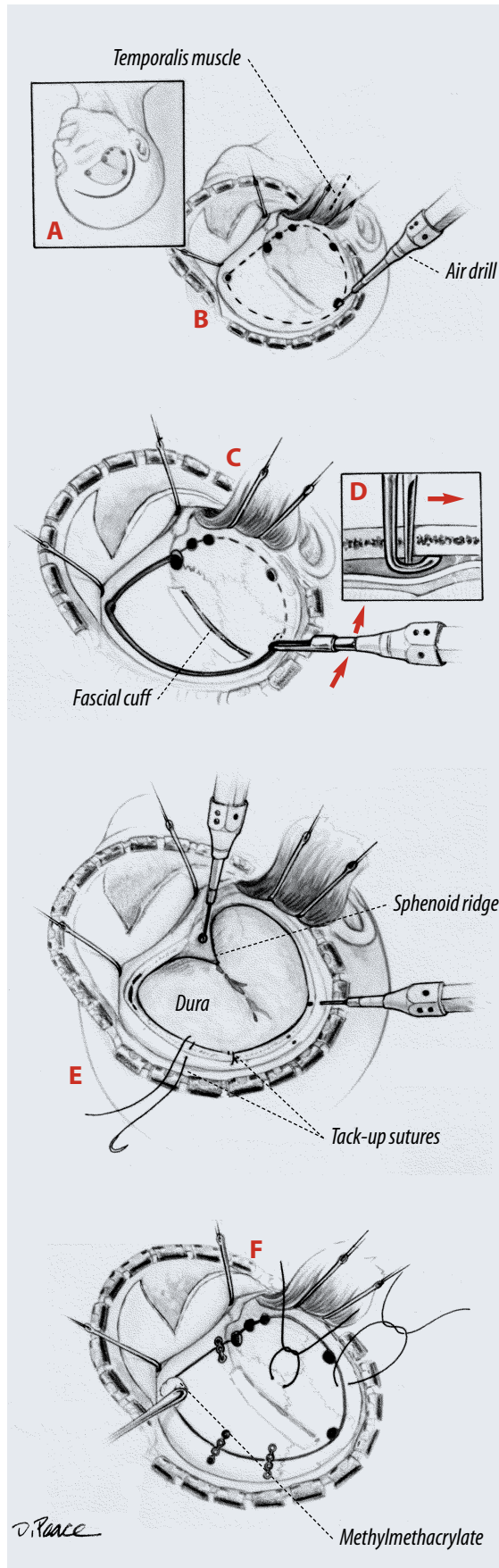


FIGURE 5

Technique of craniotomy using a high-speed air drill.

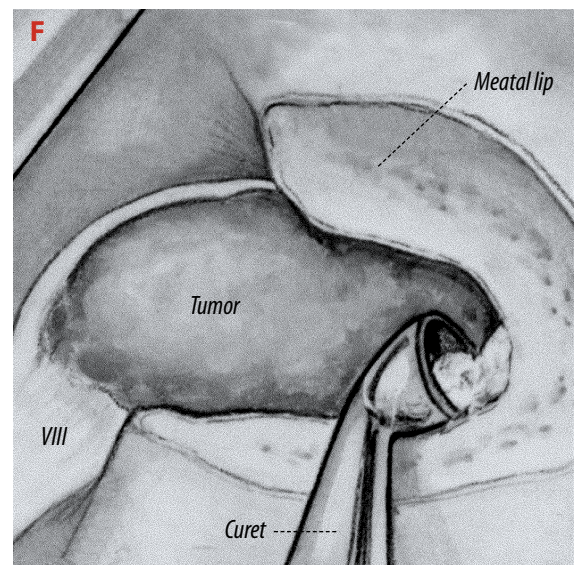
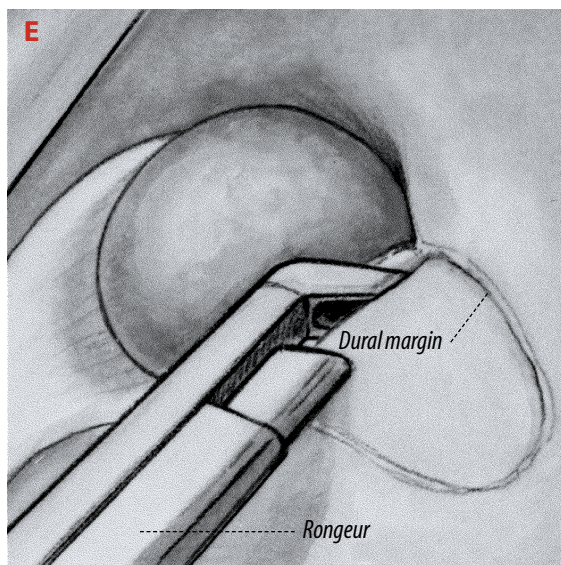
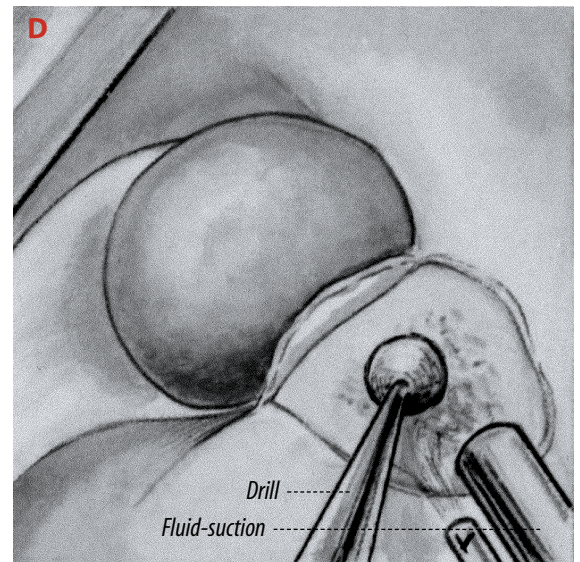
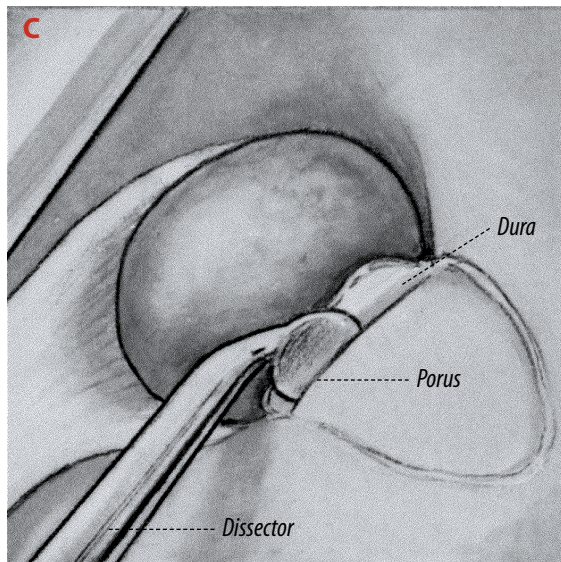
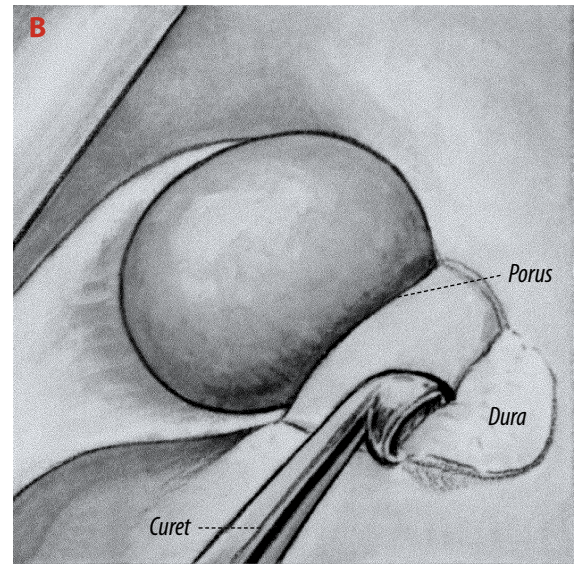
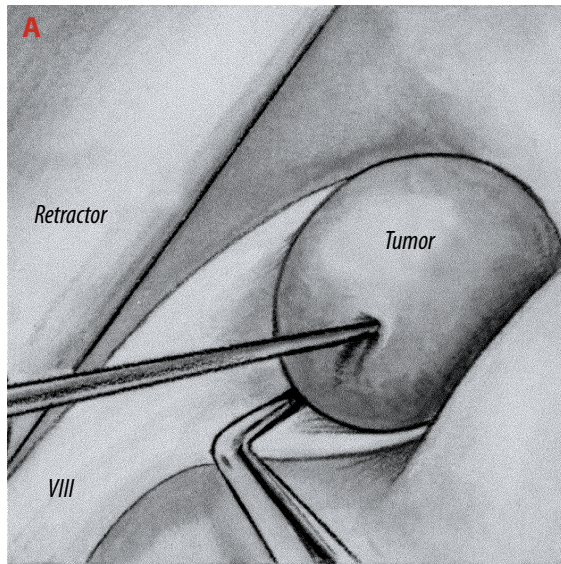
- a** A right frontotemporal scalp flap and free bone flap are outlined.
- b** The scalp flap has been reflected forward and the temporalis muscle downward. The high-speed drill prepares holes along the margin of the bone flap (interrupted line).
- c** A narrow tool with a foot plate to protect the dura connects the holes.
- d** Cross-sectional view of the cutting tool to show how the foot plate strips the dura away from the bone.
- e** The high-speed drill removes the lateral part of the sphenoid ridge. A drill bit makes holes in the bone edge for tack-up sutures to hold the dura against the bony margin.
- f** The bone flap is held in place with either silk sutures or nonmagnetic plates. Some methylmethacrylate or bone substitute is molded into the burr holes to give a firm cosmetic closure.

FIGURE 6

Microinstruments used in the cerebellopontine angle.

This illustration was prepared from 16-mm movie frames taken at the time of removal of an acoustic neuroma in the right cerebellopontine angle. This operation resulted in preservation of the facial, acoustic, and vestibular nerves.

- a** The brain retractor on the left gently elevates the cerebellum to expose the tumor. Small, pointed instruments called needles separate the tumor from the eighth nerve (VIII). The straight needle retracts the tumor, and the 45-degree needle develops a cleavage plane between the tumor and the nerve. The facial nerve is hidden in front of the vestibulo-cochlear nerve.
- b** The microcuret with a 1.5-mm cup strips dura mater from the posterior wall of the meatus.
- c** The 1.0-mm round dissector separates dura from the bone at the pores and within the meatus.
- d** A drill is used to remove the posterior wall of the meatus. Suction irrigation cools and removes bone dust.
- e** Alternative method of removal of the posterior wall after it has been thinned by a drill using a Kerrison microrongeur with a 1 mm-wide bite.
- f** The microcuret with a 1.5-mm cup removes the last bit of bone from the posterior meatal wall.

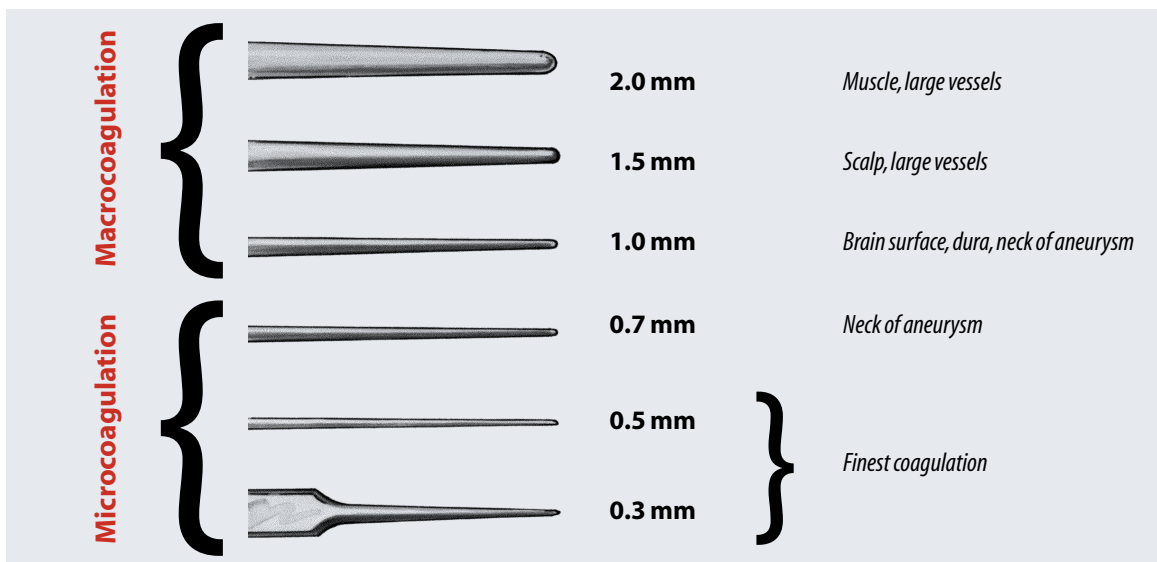


Drills

High-speed drills are commonly used in neurosurgery as a replacement for the trephine and Gigli saw and for removal of thick plates of bone, traditionally removed with rongeurs that require great strength if the bone is especially hard and thick. Drills reduce the thickness of such bone so that it can be easily removed without the use of great force. A drill typically is used during operations in the posterior fossa for removing the anterior clinoid process, the wall of the internal acoustic canal, part of the mastoid, or protrusions of the cranial base (Figure 5D and E). Cutting burs are suitable for removal of thick bone in non-critical areas but diamond coated

burr. A large burr is used when possible. The greatest accuracy and control of the drill are obtained at higher speeds if a light brush action is used to remove the bone. Dangerous skidding may ensue at lower speeds because greater pressure is needed to cut the bone. Accidental running of the burr across bone is avoided by using light, intermittent pressure rather than constant pressure of the burr on one spot.

Overheating near nerves may damage them. Constant irrigation with physiological saline reduces heat transmission to nearby neural structures. The field may also be irrigated by the use of a suction-irrigation system. The teeth of the burr are kept clean of bone dust. A coarse burr that clogs



burs are used for the most delicate drilling in close proximity to critical structures. After a drill has reduced the thickness of an area, such as the posterior lip of the internal acoustic meatus, a Kerrison microrongeur with a 1 mm lip or a microcuret may be used to remove the remaining thin layer of bone.

The operation should be planned, if possible, so that the burr rotates away from critical structures so that if skidding occurs, it will be away from these areas. The surgeon and the surgical technologist should be trained in the application of the drill before using it in a neurosurgical operation.

The drill is held like a pen. Cutting is done with the side rather than with the end of the

less easily is harder to control and runs across bone more easily, but this is reduced with irrigation.

A burr should not be used to blindly make a long, deep hole, but rather the hole should be beveled and as wide open as possible. A small curet may be used to follow a small track rather than pursuing it with a drill. Bone dust should be meticulously removed because of its potent osteogenic properties.

Bipolar coagulation

The bipolar electrocoagulator has become fundamental to neurosurgery because it allows accurate, fine coagulation of small vessels, minimizing dangerous spread of current to adjacent

FIGURE 7

Forceps tips

needed for

macrocoagula-

tion and micro-

coagulation.

neural and vascular structures (Figure 7).^{2,3} It allows coagulation in areas where unipolar coagulation would be hazardous, such as near the cranial nerves, brain stem, cerebellar arteries, and fourth ventricle.

When the electrode tips touch each other, the current is short-circuited, and no coagulation occurs. There should be enough tension in the handle of the forceps to allow the surgeon to control the distance between the tips, because no coagulation occurs if the tips touch or are too far apart. Some types of forceps, attractive for their delicacy, compress with so little pressure that a surgeon cannot avoid closing them during coagulation, even with a delicate grasp. The

fluid through a long tube in the shaft of the forceps to the tip with each coagulation (Figure 8). To avoid sticking after coagulation, the points of the forceps should be cleaned after each application to the tissue. If charred blood coats the tips, it should be removed with a damp cloth rather than by scraping with a scalpel blade, because the blade may scratch the tips and make them more adherent to tissue during coagulation. The tips of the forceps should be polished if they become pitted and rough after long use.

Conclusion

The surgical technologist plays a pivotal role in smoothly and successfully completing a neuro-

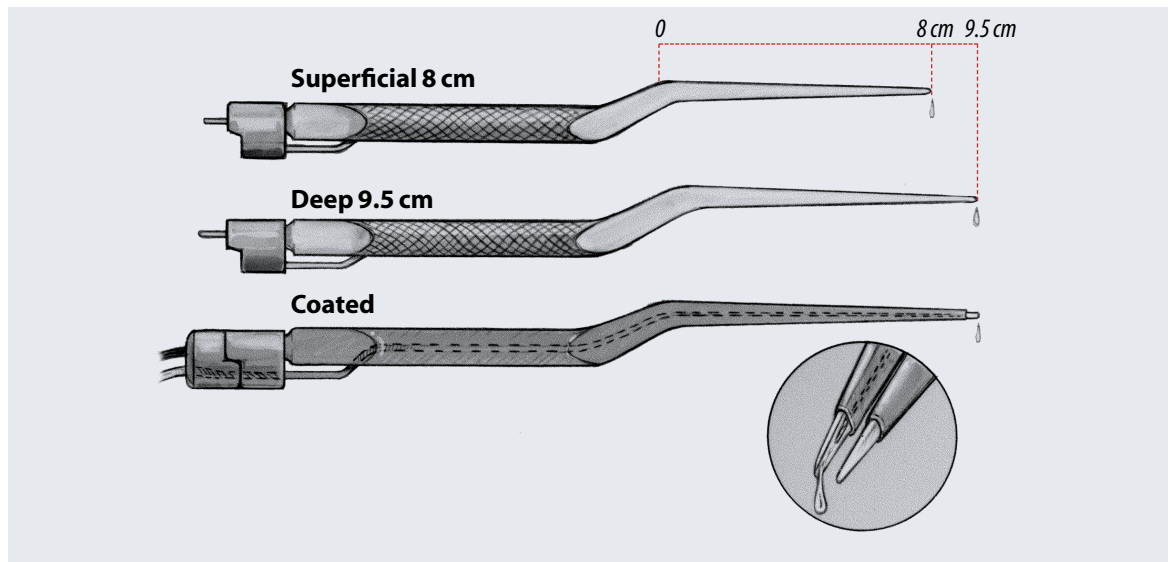


FIGURE 8

Rhoton irrigating bipolar forceps. A small amount of fluid is dispensed at the tip of the forceps with each coagulation.

cable connecting the bipolar unit and the coagulation forceps should not be excessively long, because longer cables can cause an irregular supply of current.

Surgeons with experience in conventional coagulation are conditioned to require maximal dryness at the surface of application, but with bipolar coagulation, some moistness is preferable. Coagulation occurs even if the tips are immersed in saline, and keeping the tissue moist with local cerebrospinal fluid or saline irrigation during coagulation reduces heating and minimizes drying and sticking of tissue to the forceps. Fine irrigation units and forceps have been developed that dispense a small amount of

surgical procedure. With careful operative planning and experience, they are often able to anticipate what the surgeon's needs are before the surgeon realizes what is needed. The cooperative application of the principles outlined in this paper will increase the sense of well being of the operative team and improved outcome for the patient.

About the author

Albert L Rhoton, Jr attended Washington University Medical School where he graduated with the highest academic standing in the class of 1959. He completed his internship at Columbia Presbyterian Medical Center in New York City and returned to Washington University in St

Louis for his neurosurgical training. After completing residency training in 1965, he joined the staff of the Mayo Clinic in Rochester, Minnesota, where he served as a staff neurosurgeon until 1972 when he became the professor and chairman of the Department of Neurological Surgery at the University of Florida. Rhoton has served as president of the American Association of Neurological Surgeons, the Congress of Neurological Surgeons, the Society of Neurological Surgeons, the North American Skull Base Society, the Interdisciplinary Congress on Craniofacial and Skull Base Surgery, the Florida Neurosurgical Society, and the International Society for Neurosurgical Technology and Instrument Invention. In 1998 he was the recipient of the Cushing medal, the highest honor granted by the American Association of Neurological Surgeons. He has published more than 250 scientific papers and one book, and has served on the Editorial Boards of six different surgical journals.

References

1. Greenberg IM. Self-retaining retractor and handrest system for neurosurgery. *Neurosurgery* 8:205, 1981.
2. Greenwood J. Two point coagulation. A new principle and instrument for applying coagulation current in neurosurgery. *Amer J Surg* 50:267, 1940.
3. Malis LL. Bipolar coagulation in microsurgery. In Yasargil MG, ed. *Microsurgery Applied to Neurosurgery*. New York: Academic Press, 1969, 41-45.
4. Rhoton AL Jr. General and Micro-operative Techniques. In: Youmans JR, ed. *Neurological Surgery*. Vol. 1. Philadelphia: WB Saunders Co. 1996, 724-766.
5. Rhoton AL Jr. Anatomic Foundations of Aneurysm Surgery. *Clin Neurosurg* 41:289, 1994.
6. Rhoton AL Jr. Instrumentation. In Apuzzo MJL, ed. *Brain Surgery: Complication, Avoidance and Management*, Vol. 2. New York: Churchill-Livingstone, 1993, 1647-1670.
7. Rhoton AL Jr. Microsurgery of the internal acoustic meatus. *Surg Neurol* 2:311, 1974.
8. Rhoton AL Jr. Microsurgical Anatomy of Decompression Operations on the Trigeminal Nerve. In Rovit RL, ed. *Trigeminal Neuralgia*, Baltimore: Williams & Wilkins, 1990, 165-200.
9. Rhoton AL Jr. Ring curets for transsphenoidal pituitary operations. *Surg Neurol* 18:28, 1982.
10. Rhoton AL Jr, Merz W. Suction tubes for conventional or microscopic neurosurgery. *Surg Neurol* 15:120, 1981.
11. Rizzoli H. Personal communication.
12. Yasargil MG. Suturing techniques. In Yasargil MG, ed. *Microsurgery Applied to Neurosurgery*. New York: Academic Press, 1969, 87-124.
13. Yasargil MG. Suture material. In Yasargil MG, ed. *Microsurgery Applied to Neurosurgery*. New York: Academic Press, 1969, 55.
14. Yasargil MG, Vise WM, Bader DCH. Technical adjuncts in neurosurgery. *Surg Neurol* 8:331, 1977.

Figures 1, 3, 4, 5, 7 and 8 from Rhoton AL Jr. General and Micro-operative Techniques. In: Youmans JR, ed. *Neurological Surgery*. Vol. 1. Philadelphia: WB Saunders Co; 1996: 724-766. Used with permission of WB Saunders © 2001. Figure 2 from Rhoton AL Jr. Microsurgical Anatomy of Decompression Operations on the Trigeminal Nerve. In: Rovit RL, ed. *Trigeminal Neuralgia*. Baltimore: Williams & Wilkins; 1990: 165-200. Used with permission of Lippincott Williams & Wilkins © 2001. Figure 6 taken from Rhoton AL, Jr. Microsurgical Removal of Acoustic Neuromas. *Surg Neurol* 2:211, 1976:213-214, used with permission of Elsevier Science © 2001.

Cranial neurosurgery, part 1

Earn CE credit at home

You will be awarded one continuing education (CE) credit for recertification after reading the designated article and completing the exam with a score of 70% or better.

If you are a current AST member and are certified, credit earned through completion of the CE exam will automatically be recorded in your file—you do not have to submit a CE reporting form. A printout of all the CE credits you have earned, including Journal CE credits, will be mailed to you in the first quarter following the end of the calendar year. You may check the status of your CE record with AST at any time.

If you are not an AST member or not certified, you will be notified by mail when *Journal* credits are submitted, but your credits will not be recorded in AST's files.

Detach or photocopy the answer block, include your check or money order made payable to AST and send it to the Accounting Department, AST, 6 West Dry Creek Circle, Suite 200, Littleton, CO 80120-8031.

Members: \$6 per CE, nonmembers: \$10 per CE

1. Which is another term for the 3/4 prone position?
 - a. supine
 - b. lateral oblique
 - c. right lateral recumbent
 - d. none of the above

2. When the patient is in the supine or 3/4 position, the CST should be _____.
 - a. seated at the head of the table
 - b. in front of the patient's face
 - c. behind the patient's back
 - d. at the patient's feet

3. The ____ is the site of a bony prominence that overlies the torcular and the attachment of the tentorium to the inner table of the skull.
 - a. frontozygomatic point
 - b. Sylvian fissure
 - c. nasion
 - d.inion

4. The ____ separates the motor and sensory areas of the cerebrum.
 - a. frontozygomatic point
 - b. nasion
 - c. Sylvian fissure
 - d. Rolandic fissure

5. The ____, the site on the temple, is located 3 cm behind the frontozygomatic point on the Sylvian fissure line.
 - a. pterion
 - b.inion
 - c. orbital rim
 - d. tentorium

6. ____ interfere with CT or MRI scans, so are only used with aneurysms.
 - a. pinion head clamps
 - b. rongeurs
 - c. metallic clips
 - d. bone wax

7. ____ is/are used to close small openings in the mastoid air cells and sinuses.
 - a. silk suture
 - b. pericranial grafts
 - c. metallic clips
 - d. bone wax

8. The greatest accuracy and control of the drill is achieved _____.
 - a. at high speeds
 - b. through constant pressure
 - c. with low speeds
 - d. using minimal irrigation

9. Bipolar coagulation will not occur if _____.
 - a. tips are too far apart
 - b. tips are touching
 - c. a and b
 - d. none of the above

10. In which areas would unipolar coagulation be hazardous?
 - a. brain stem
 - b. fourth ventricle
 - c. near cranial nerves
 - d. all of the above

Cranial neurosurgery, part 1

Certified Member

Certified Nonmember

Certification No _____

Name _____

Address _____

City _____ State _____ ZIP _____

Telephone _____

	a	b	c	d		a	b	c	d
1	<input type="checkbox"/>	<input type="checkbox"/>	<input type="checkbox"/>	<input type="checkbox"/>	6	<input type="checkbox"/>	<input type="checkbox"/>	<input type="checkbox"/>	<input type="checkbox"/>
2	<input type="checkbox"/>	<input type="checkbox"/>	<input type="checkbox"/>	<input type="checkbox"/>	7	<input type="checkbox"/>	<input type="checkbox"/>	<input type="checkbox"/>	<input type="checkbox"/>
3	<input type="checkbox"/>	<input type="checkbox"/>	<input type="checkbox"/>	<input type="checkbox"/>	8	<input type="checkbox"/>	<input type="checkbox"/>	<input type="checkbox"/>	<input type="checkbox"/>
4	<input type="checkbox"/>	<input type="checkbox"/>	<input type="checkbox"/>	<input type="checkbox"/>	9	<input type="checkbox"/>	<input type="checkbox"/>	<input type="checkbox"/>	<input type="checkbox"/>
5	<input type="checkbox"/>	<input type="checkbox"/>	<input type="checkbox"/>	<input type="checkbox"/>	10	<input type="checkbox"/>	<input type="checkbox"/>	<input type="checkbox"/>	<input type="checkbox"/>

Mark one box next to each number. Only one correct or best answer can be selected for each question.