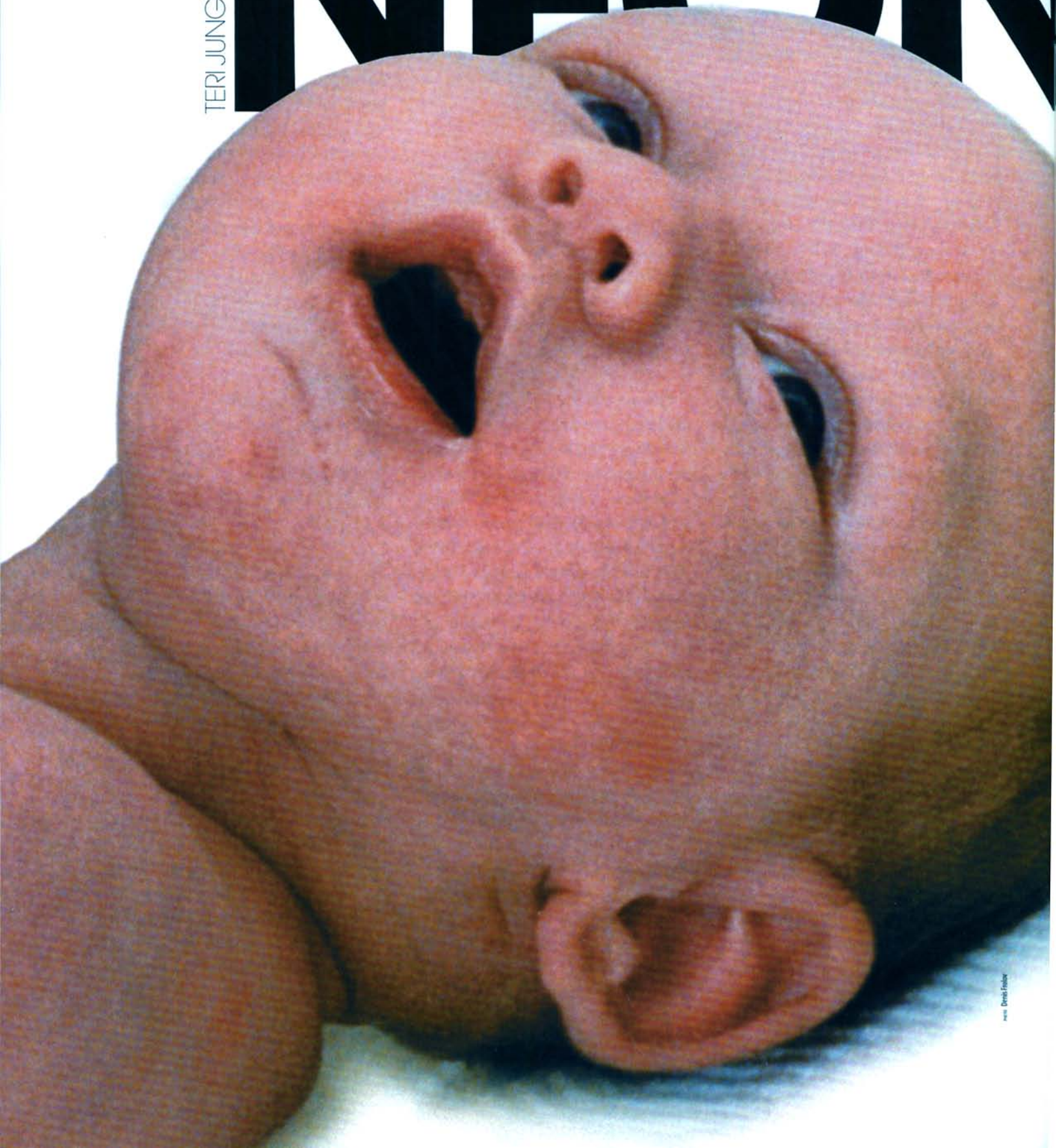

TERI JUNGE, CST/CFA

NEON



INITIAL ASSESSMENT

Many types of assessments are used to determine the condition of the neonate. The first is a general visual and physical examination of the neonate that takes place in the delivery room and is often accompanied by assignment of the Apgar score. Any major congenital malformations (eg cheiloschisis, neural tube abnormalities) are identified during this brief initial exam. An abnormal finding may necessitate transfer of the neonate to the intensive care unit rather than the newborn nursery.

The surgical team should be aware of the detailed process that is involved in these assessments and be prepared to provide preventive, supportive, or resuscitative measures as needed.

Case study

C Martin was born via Cesarean section approximately five minutes ago. His mother is undergoing a general anesthetic. His initial Apgar score was five. The neonatal care team provided Martin with supportive treatment that included clearing his airway, providing oxygen therapy, and vigorous external physical stimulation. His five-minute Apgar score has improved to eight.

1. What is the most likely cause for Martin's low initial Apgar score?
2. How do you explain the improvement in Martin's Apgar score in such a short time?

Gestational agea

Gestational age is determined by the time that is spent in utero. Time spent in utero is measured, in weeks, from conception to birth. Gestational age is most often assigned according to maternal history, but may also be determined by measurement of fundal height and/or the use of ultrasound. The normal gestational period (term) is considered 40 weeks, a variance of two weeks earlier or later is considered within the normal range. The neonate is considered premature if born before 38 weeks and postmature if born after 42 weeks gestation.⁷

Additional classifications are given according to neonatal size at birth. Most term neonates are

Table 1 Apgar scoring system using APGAR acronym^{3,11}

| | Component | 0 Points | 1 Point | 2 Points |
|---|-------------------------------|--------------|--------------------------------|-----------------------------------|
| A | Activity (Muscle Tone) | Absent | Extremities flexed | Active |
| P | Pulse | Absent | Less than 100 beats per minute | Greater than 100 beats per minute |
| G | Grimace (Reflex Irritability) | No Response | Grimace | Sneeze, cough, pulls away |
| A | Appearance (Skin Color) | Blue or pale | Body pink, extremities blue | Normal |
| R | Respiration | Absent | Slow, irregular | Good, crying |

3. Due to his low initial Apgar score, is Martin expected to suffer any permanent neurological deficit?

Appearance

The physical appearance of the neonate may be alarming to those unfamiliar with the peculiarities. The skin may be covered with vernix caseosa, the body with lanugo, and the head moulded. All of these conditions may be normal according to the gestational age of the neonate and the type of delivery (vaginal vs Cesarean section).

classified as being the appropriate for gestational age (AGA); meaning that the weight is between 2,500-4,000 grams (5.5-8.75 pounds). A term neonate weighing less than 2,500 grams is considered small for gestational age (SGA) and the term neonate weighing greater than 4,000 grams is considered large for gestational age (LGA). Neonates classified as AGA are at low risk for complications. Those classified as SGA or LGA suffer greater morbidity and mortality. Neonatal size is affected by several factors that include maternal size, maternal health (eg diabetes, hypertension), genetics, exposure to adverse environmental conditions (eg intrauterine infections, maternal drug and alcohol use, radiation),

errors of metabolism, and placental insufficiency.⁸

The Dubowitz/Ballard exam is used as needed to assess gestational age if the neonate is unusually large, small, or appears premature. The Dubowitz/Ballard exam evaluates neuromuscular and physical maturity in 12 categories. The exam is performed in two phases: the first to assess external characteristics is best performed at birth and the second to assess neuromuscular capabilities within 24 hours of birth. Based on the neonate's total score, the gestational age in weeks from the time of conception is estimated. Complete information concerning the Dubowitz/Ballard

The five-component (activity—muscle tone; pulse; grimace—reflex irritability; appearance—skin color; and respiration) system is used to quickly assess the condition of the neonate shortly after birth and to determine the success of supportive or resuscitative efforts (if necessary). A score from 1 to 3 is given for each component at one minute, five minutes, and occasionally 10 minutes after birth. The scores from each component are added together to determine the total score.^{4,5,6} The following is a basic interpretation of the total Apgar score.

- A total score of 7 or above is considered normal.

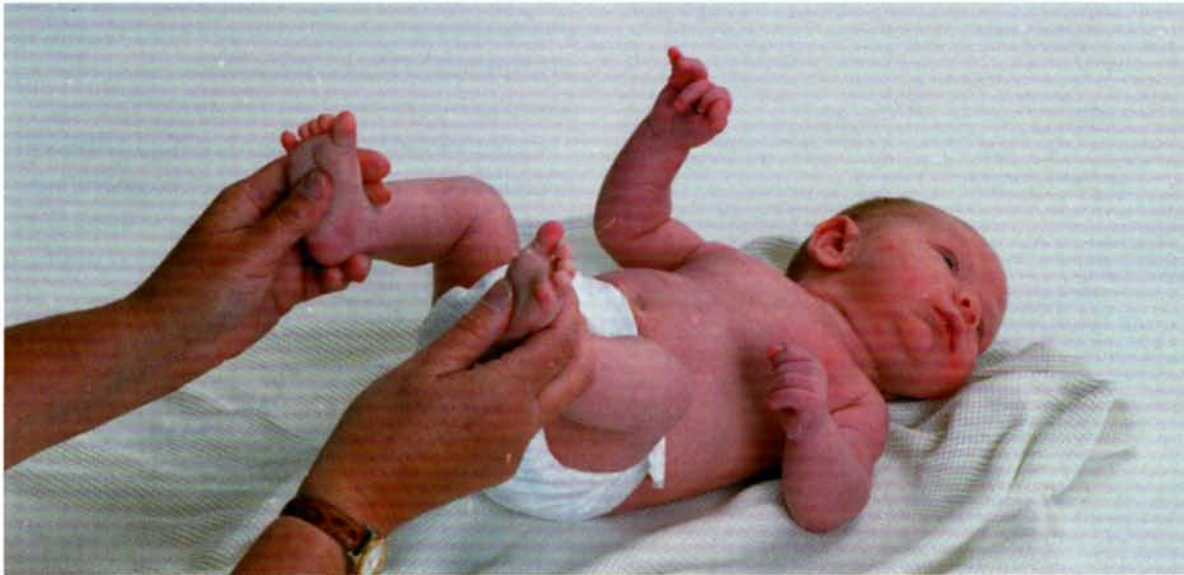

FIGURE 1

Babinski reflex.

exam can be found on the Neonatology Web site at www.neonatology.org/ref/dubowitz.html.⁸

Apgar score

The first formalized, standardized newborn assessment criteria were created by Virginia Apgar, MD. These simple criteria marked a new standard for care and evaluation of the neonate. Apgar first presented her scoring system in 1952 at the Annual Congress of Anesthetists and published it along with supporting research in *Current Researches in Anesthesia and Analgesia*, July-August 1953. A modification to the Apgar score, using the letters of Apgar's name as an acronym, was suggested and adopted in 1962 (Table 1).

- A total score of 4-6 may indicate the need for supportive measures.
- A total score of 3 or below indicates the need for immediate resuscitation.

The American Academy of Pediatrics supports the use of the Apgar score for immediate neonatal assessment and intervention in the delivery room. However, the Academy warns against correlation of the neonate's future neurologic outcome based solely on the Apgar score. Low scores can result from perinatal hypoxia, infection, gestational age (physiologic maturity), and/or the effect of maternal medications.¹³

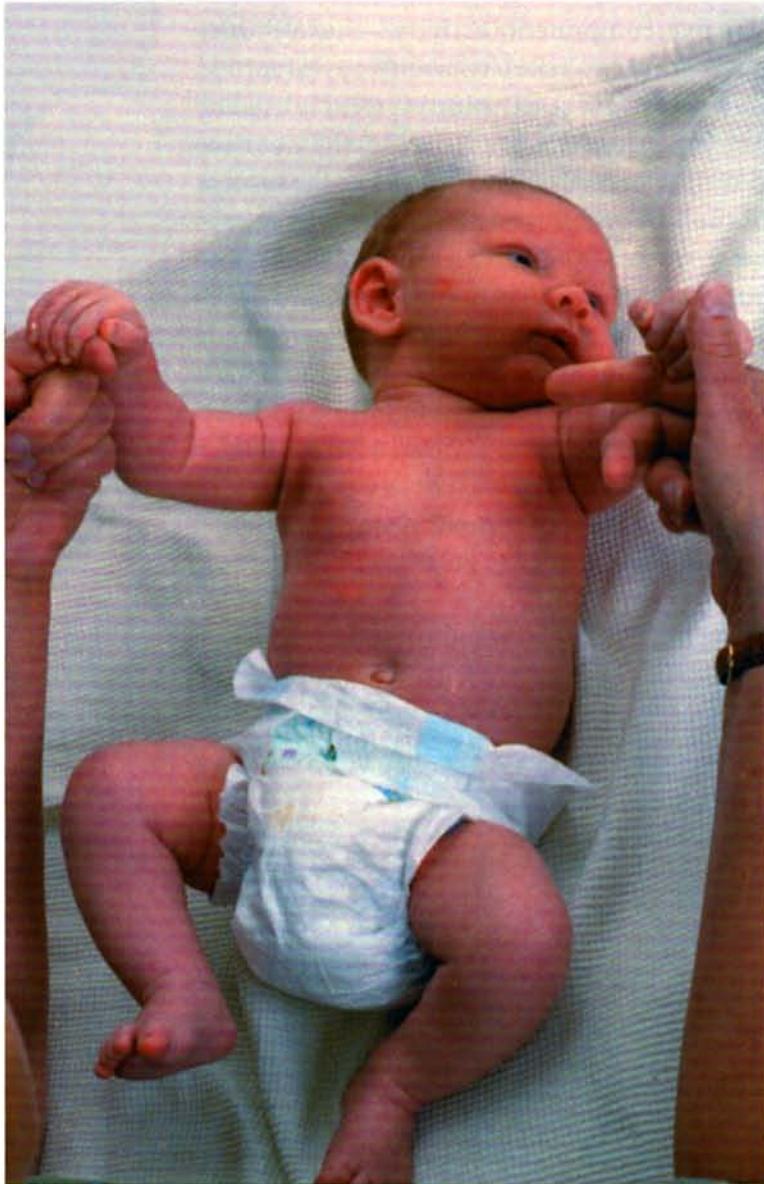

FIGURE 2 Complete physical examination

Grasp reflex.

The neonate's first complete physical examination usually occurs in the neonatal care unit (intensive care unit or newborn nursery) following the first bath. Maternal history is an important component in determining the physical condition of the neonate. This exam is typically conducted using an organ or system analysis.

Vital statistics

Neonatal vital signs (heart rate and rhythm, abnormal heart sounds (murmur), respiratory rate and rhythm, abnormal respiratory sounds (eg stridor), temperature, and blood pressure, weight, height (length), and head circumference

are measured and recorded. Table 2 lists normal neonatal vital signs. Normal height, weight, and head circumference are charted in percentiles according to the recommendations of the US Department of Health and Human Services. The complete set of clinical growth charts are available online at www.cdc.gov/nchs/about/major/nhanes/growthcharts/clinical_charts.htm. The charts are age and gender specific, as well as nationally representative for race, ethnicity, breast-fed, and formula-fed individuals.

Neurological system

The neonate's general state of alertness is assessed and any alteration (eg irritability, lethargy) noted. Additionally, the overall muscle tone is assessed. Flaccid or tonic conditions lead to suspicion of the presence of a neuromuscular disorder.

Reflex responses are used to determine the general condition of the neonate's central nervous system. Reflex responses must be demonstrated bilaterally. The three primary functions of the nervous system are tested. The three primary functions are:

1. *Sensory*—An alteration of internal and/or external stimuli is detected.
2. *Integration*—An appropriate response is selected based on analysis of the sensory information received.
3. *Motor*—Implementation of the appropriate response.

The following are some of the common primitive reflex examinations performed on the neonate; the expected response to each is described.^{8,11}

- *Babinski reflex*—The soles of the neonate's feet are stroked gently. The neonate's feet turn inward and the toes flare upward (Figure 1).
- *Grasp reflex*—Pressure is applied to the neonate's palms. The neonate clenches his or her fists (Figure 2).

...continued on page 16

Related terms and definitions

Bilirubin—Bile pigment produced by breakdown of heme that normally circulates in the plasma. Excess concentration of bilirubin may result in jaundice.

Cheiloschisis—Cleft lip.

Cyanosis—Bluish discoloration of the skin and mucous membranes due to low oxygen concentration in the blood.

Hypoxemia—Deficient oxygen concentration in the blood.

Jaundice—Yellowish discoloration of the skin, sclera, and mucous membranes due to hyperbilirubinemia.

Lanugo—Fine hair that covers the neonatal body; especially if born prematurely.

Methemoglobinemia—Presence of methemoglobin (transformation product of oxyhemoglobin) in the circulating blood that causes inadequate oxygenation of the tissues. Methemoglobin causes the blood to have a brownish color.

Micrognathia—Unusually small jaw size, especially of the mandible. Associated with a number of congenital defects.

Moulding—Changes that occur in the shape of the neonate's head during passage through the birth canal.

Neonate—A newborn. The first 28 days of extrauterine life is referred to as the neonatal period.

Omphalocele—Congenital protrusion of a portion of the intestine through a defect in the abdominal wall at the umbilicus.

Ophthalmia neonatorum—Inflammation of the conjunctiva of the neonate due to transmission of sexually transmitted disease (eg *Neisseria gonorrhoeae*, chlamydia trachomatis) from an infected mother. Can lead to abscess formation, corneal scarring, perforation of the globe, and permanent blindness.

Palatoschisis—Cleft palate.

Pallor—Paleness of the skin.

Phenylketonuria (PKU)—Metabolic error that prevents conversion of phenylalanine to tyrosine that results in mental retardation. Preventable with dietary restrictions.

Plethora—A reddish or rosy complexion marked by an over production of red blood cells.

Polycythemia—An increase in the total cell mass of the blood; especially the red cells.

Reflex—An automatic (instinctive) response by the CNS to a stimulus.

Stridor—High pitched, harsh respiratory sound.

Vernix caseosa—Substance covering the skin of a neonate that consists of desquamated epithelial cells and sebum.

Table 2 Normal neonatal vital signs⁷

| Temperature | Pulse rate | Respiratory rate | Blood pressure |
|--------------------------|---------------|--------------------|-----------------|
| Oral 98.6°F (37°C) | 130-160 beats | 30-60 respirations | 50-52 systolic/ |
| Rectal 99.6°F (37.6°C) | per minute | per minute | 25-30 diastolic |
| Axillary 97.6°F (36.5°C) | | | |

Table 3 Common problems associated with neonatal skin tone

| Skin tone | Potential associated problem |
|------------------|------------------------------|
| Cyanosis | Hypoxemia |
| Jaundice | Elevated bilirubin |
| Pallor | Low hemoglobin |
| Plethora | Polycythemia |
| Slate grey color | Methemoglobinemia |

- *Moro reflex*—The neonate's head is supported and the body held at an angle. The head is tilted back slightly and the neonate should respond by extending his or her arms and legs. A similar response, called the startle reflex is expected when a loud sudden noise occurs (Figure 3).
- *Rooting reflex*—Actions of the neonate when searching for the maternal breast. The rooting reflex may be stimulated by stroking the side of the neonate's cheek; he or she will respond by turning the head in the direction

auscultation. The umbilical cord is examined and the number of vessels verified. The abdominal organs are palpated and any masses noted.

The back is palpated for any midline neural tube defects or abnormal spinal curvatures (eg scoliosis). Presence of the anus is verified and the area is inspected for the presence of fistulas; anal patency is verified with the use of a soft tube, if necessary. The first bowel movement should occur within the first 24 hours of life.⁸

Cardiovascular

The point of maximal impulse (PMI) of the heart is located by palpation. Abnormal location may indicate an abnormality (eg pneu-

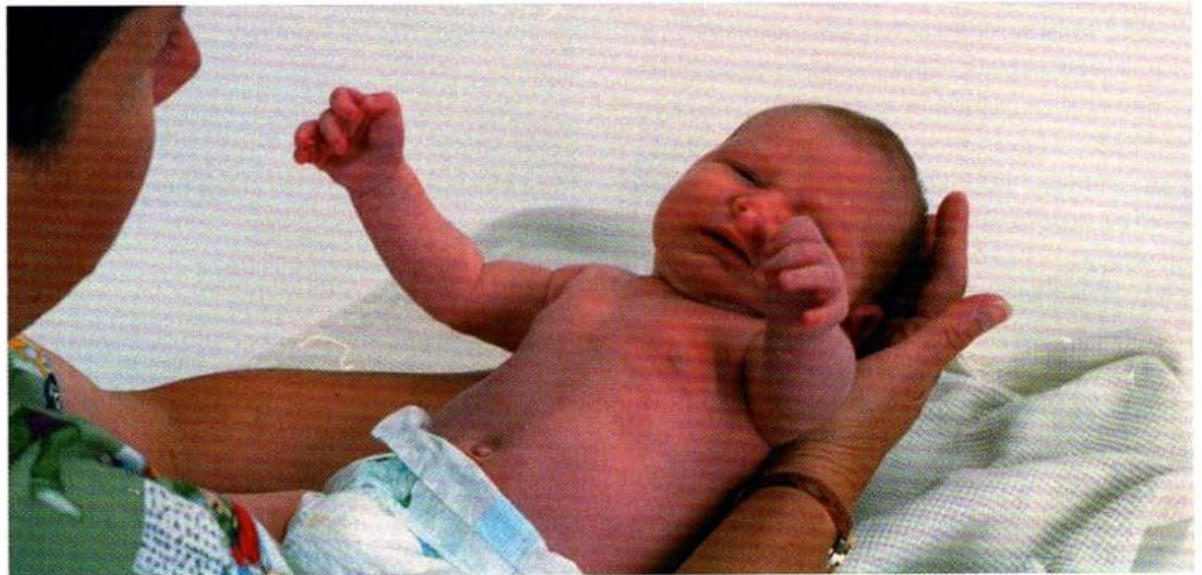

FIGURE 3

Moro reflex.

of the finger. His or her mouth will be open in anticipation of feeding (Figure 4).

- *Walking reflex*—The neonate is held upright while being supported underneath the arms, with the feet resting on a hard surface. The legs will immediately make a stepping or marching action. Performance of this reflex does not indicate readiness to walk (Figure 5).

Abdomen and back

The integrity (eg umbilical or inguinal hernia, omphalocele) and shape of the abdomen are noted. A flat or distended abdomen may indicate an abnormality. Bowel sounds are verified by

mothorax, diaphragmatic hernia). Pulses are verified and the character is noted (eg thready) and capillary refill is verified.⁸

Ears

A visual examination of the external ear is performed to verify symmetry, regular shape, and correct location. An otoscope is used to examine the tympanic membrane.⁸

Extremities

Verify the presence of all extremity structures. The Ortolani maneuver is used to check for congenital hip dislocation.

The normal neonate in the supine position will display the hips and knees partially flexed with the hips abducted. The fists are clenched (enclosing the thumb within the fingers) and the arms are flexed at the elbow and adducted.⁸

Eyes

The eye examination includes a visual inspection to verify symmetry (eg size, shape, color), presence of all tissues, and proper formation of the tissue. The corneas are inspected for clarity and the conjunctiva for hemorrhage, discoloration (eg erythema, jaundice), discharge, and/or edema. Pupillary size and reactivity to light are checked. An ophthalmoscope may be used to verify the red reflex of the retina. Absence of the red reflex may suggest retinoblastoma or congenital cataracts.⁸

Ocular prophylaxis for the prevention of ophthalmia neonatorum is routinely performed and may be required by law in many areas. The CDC recommends the use of erythromycin, tetracycline, or silver nitrate. However, it must be noted that silver nitrate is not effective in the treatment of chlamydia trachomatis and can result in chemical conjunctivitis.²⁰

Genitourinary

The location of the kidneys is verified by palpation. Urination should occur within the first eight hours of life.

The external male genitalia are examined. The prepuce is retracted to locate the urethral meatus and the presence of bilateral testes is verified.

The external female genitalia are examined. Presence and location of the labia, clitoris, vaginal vault, and urethral meatus are verified. Presence of a white discharge or minimal bleeding from the vagina (secondary to maternal hormone withdrawal) is normal.⁸

Head and neck

The head and neck are visualized to rule out any abnormality in shape or birth trauma. Presence and location of all external facial features are verified. Absence of encephalocele is noted. The number of fontanelles, their size, and fullness (eg

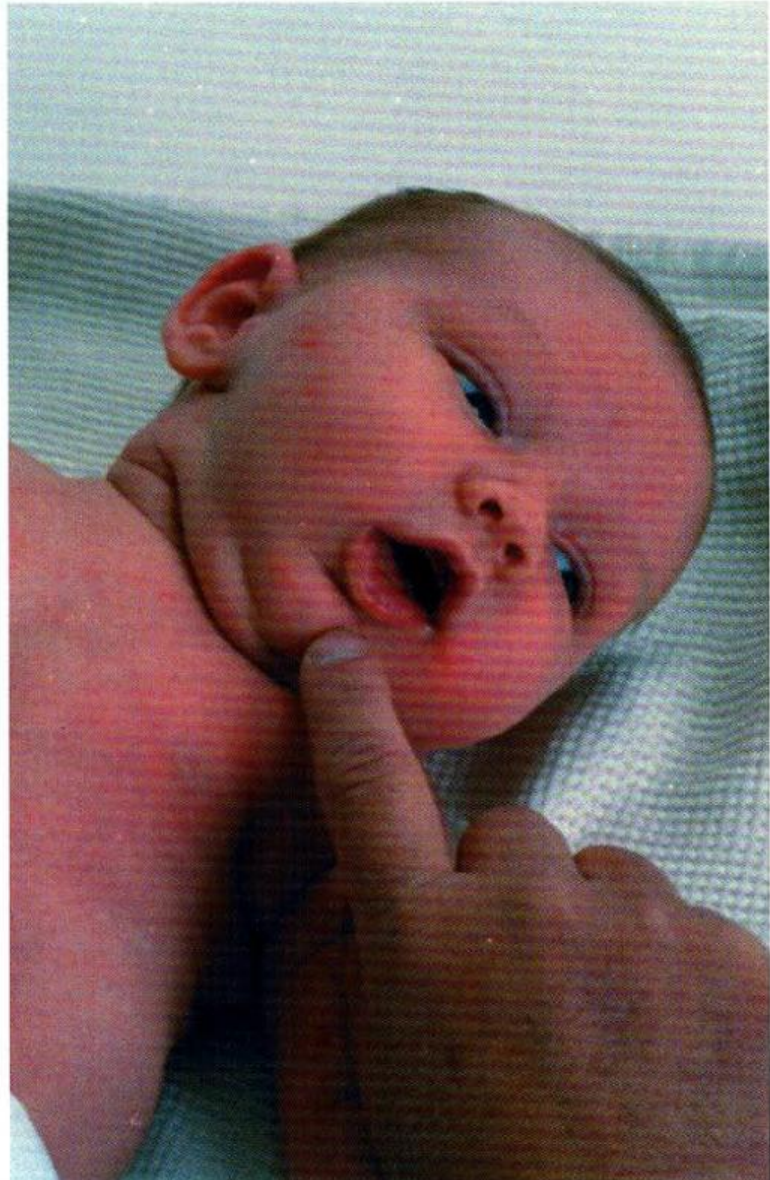


FIGURE 4
Rooting reflex.

depressed, bulging) are recorded. Palpation of the head is performed to check for overriding sutures and the neck is palpated to rule out the presence of a clavicular fracture (radiography may be indicated) or any masses. Chin size is also noted.⁸

Integumentary system

The skin is examined for the presence of any lesions (eg birth trauma, rash) or lacerations. The skin tone (coloration) is also noted. Common problems that correlate with skin tone are described in Table 3.⁸

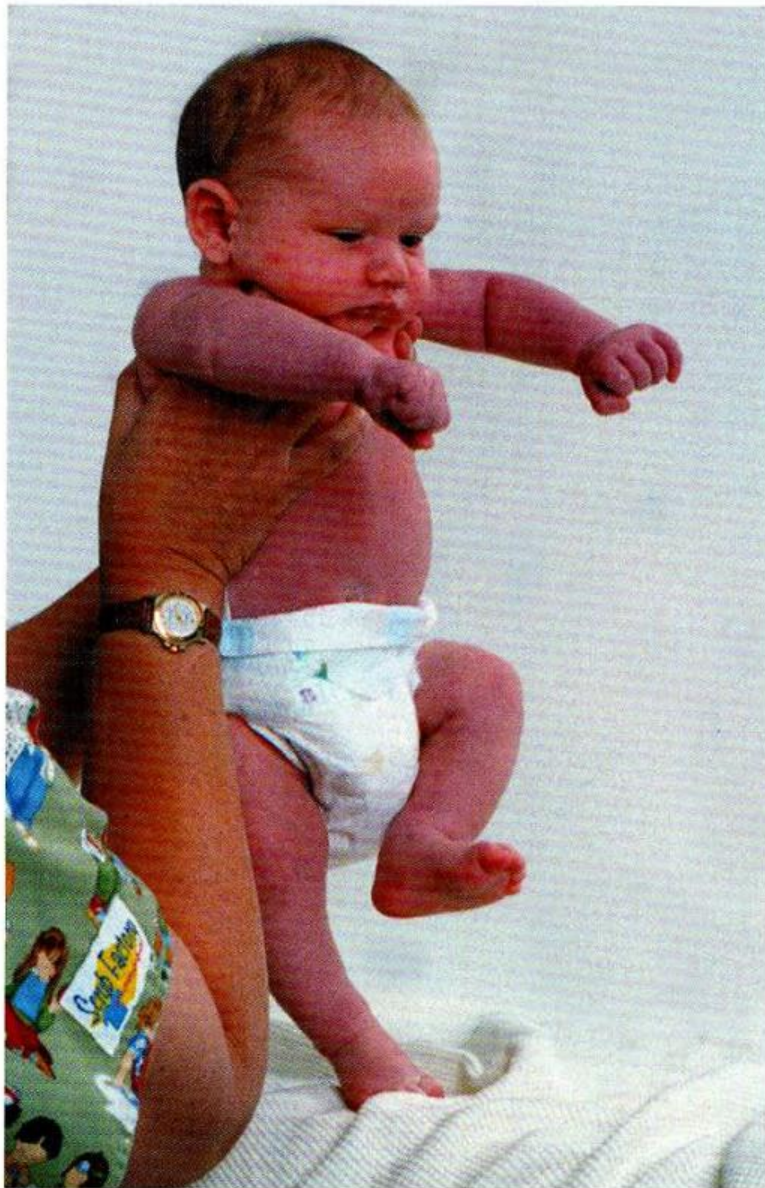


FIGURE 5 *Laboratory screening*

Walking reflex.

Screening for certain treatable metabolic disorders are mandated by law in some areas. For example, all 50 states require testing for phenylketonuria (PKU) and congenital hypothyroidism, while not all states require testing for cystic fibrosis and other disorders. Additional laboratory examinations are ordered according to the situation (eg HIV).⁸ A complete listing of mandated neonatal screening tests is available at www.newbornscreening.com.

Thorax

The thorax is observed during respiration for symmetrical movement and retraction of the

sternum. Bilateral breath sounds should be equal. Secondary breast enlargement due to maternal hormones may be noted.⁸

Upper aerodigestive tract

Visual examination of the external nose is performed to verify symmetry and regular shape. The location of the nose to the other facial structures is noted. Excess fluid is removed with the use of a bulb syringe. The internal nose is visualized (the otoscope may be used) and if necessary a soft tube may be passed through each nostril to confirm patency. Flaring of the nostrils may indicate respiratory distress.

The size and shape of the mouth are visualized, and the presence of any natal teeth or lesions is noted. A tongue blade may be used to verify presence of internal structures and to rule out palatoschisis. Size, shape, and mobility of the tongue are noted. If necessary, a soft tube may be passed into the stomach to confirm patency of the esophagus.⁸

Conclusion

Neonatal assessment is performed to identify (or rule out) any congenital malformation or condition that may require further intervention. All involved with the care of the neonate, from the healthcare provider to the parent, should be aware of the detailed process that is involved and be prepared to provide preventive, supportive, or resuscitative measures, as needed.

Acknowledgment

Specials thanks to the Sisneros family for allowing 25-day-old Cameron James to model for the photographs that accompany this article.

About the author

Teri Junge, CST/CFA, has written a number of articles and educational materials for AST, including chapters for the textbook, *Surgical Technology for the Surgical Technologist: A Positive Care Approach*. She is currently the medical editor for the association and has a background as a surgical assistant and as a surgical technology educator.

References

1. Calmes SH. And What About the Baby? Virginia Apgar and the Apgar Score. *American Society of Anesthesiologists Newsletter*. September 1997:20-22. apgarfamily.com/Selma4.html
Accessed 10-10-01
2. Apgar E. Article for the *Apgar Association Newsletter* 1995. apgarfamily.com/Apgar_Article.html Accessed 10-10-01
3. Assessing Newborns' Vital Signs—The Apgar Score. Medical College of Georgia. May 1996. www.mcg.edu/News/96features/Apgarscore.html Accessed 10-10-01
4. Apgar V. A Proposal for a New Method of Evaluation of the Newborn Infant. *Current Researches in Anesthesia and Analgesia*. July-August 1953. apgarfamily.com/Apgar_Paper.html
Accessed 10-10-01
5. Calmes SH. Development of the Apgar Score. *Anesthesia—Essays on Its History* 1985. apgarfamily.com/selma2.html Accessed 10-10-01
6. Dr Virginia Apgar Biography. 1995. apgarfamily.com Accessed 10-10-01
7. MEDLINEplus Medical Encyclopedia. www.nlm.nih.gov/medlineplus Accessed 10-10-01
8. Neonatology on the Web. www.neonatology.org
Accessed 10-10-01
9. Caruthers et al. *Surgical Technology for the Surgical Technologist: A Positive Care Approach*. Albany, NY: Delmar Thompson Learning, 2001.
10. The Lemelson-MIT Prize Program: Virginia Apgar. May 1997. web.mit.edu/invent/www/inventorsA-H/apgar.html Accessed 10-10-01
11. The Miracle of Life—Your Newborn's Reflexes. genesis.co.za/child/chreflex.html Accessed 10-10-01
12. The VATER Connection FAQ. www.vaterconnection.org/faq.htm Accessed 10-10-01
13. Use and Abuse of the Apgar Score (RE9621). American Academy of Pediatrics Policy Statement. www.aap.org/policy/01457.html
Accessed 10-10-01
14. VACTERL Association www.thefetus.net/sections/articles/Syndromes/Vacterl_association.html
Accessed 10-10-01
15. Calmes SH. Virginia Apgar, MD: At the Forefront of Obstetric Anesthesia. *American Society of Anesthesiologists Newsletter*. October 1992: 9-12. apgarfamily.com/Selma3.html
Accessed 10-10-01
16. Calmes SH. Virginia Apgar, MD, Inducted into National Women's Hall of Fame. *American Society of Anesthesiologists Newsletter*, Vol. 59, No. 12. December 1995. apgarfamily.com/Selma5.html Accessed 10-10-01
17. Calmes SH. Virginia Apgar: a woman physician's career in a developing specialty. *Journal of the American Medical Women's Association* Vol. 39, No. 6;1984:184-188. apgarfamily.com/selma1.html Accessed 10-10-01
18. What Does the APGAR Score Really Mean? www.alexian.org/progwerv/babies/thridtri/apgar_score.html Accessed 10-10-01
19. Women In The Workplace—Medicine. www.thehistorynet.com/WomensHistory/articles/19965_text.htm Accessed 10-10-01
20. 1998 Guidelines for Treatment of Sexually Transmitted Diseases Centers for Disease Control and Prevention. www.cdc.gov/mmwr/preview/mmwrhtml/00050909.htm Accessed 10-15-01

Additional information

1. US Department of Health and Human Services, Centers for Disease Control and Prevention, National Center for Health Statistics, Division of Data Services, 301-458-4636 www.cdc.gov/nchs/about/major/nhanes/growthcharts/clinical_charts.htm
2. www.newbornscreening.com

Neonatal assessment

Earn CE credit at home

You will be awarded one continuing education (CE) credit for recertification after reading the designated article and completing the exam with a score of 70% or better.

If you are a current AST member and are certified, credit earned through completion of the CE exam will automatically be recorded in your file—you do not have to submit a CE reporting form. A printout of all the CE credits you have earned, including Journal CE credits, will be mailed to you in the first quarter following the end of the calendar year. You may check the status of your CE record with AST at any time.

If you are not an AST member or not certified, you will be notified by mail when *Journal* credits are submitted, but your credits will not be recorded in AST's files.

Detach or photocopy the answer block, include your check or money order made payable to AST and send it to the Accounting Department, AST, 6 West Dry Creek Circle, Suite 200, Littleton, CO 80120-8031.

Members: \$6 per CE, nonmembers: \$10 per CE

1. What condition may be suspected if the neonate is displaying plethora?
 - A. Hypoxemia
 - B. Polycythemia
 - C. Methemoglobinemia
 - D. Elevated bilirubin

2. Pallor is described as a/an _____.
 - A. Paleness of the skin
 - B. Desquamated epithelial cells and sebum covering the skin
 - C. Change in the shape of the neonate's head from passage through the birth canal
 - D. Bluish discoloration of the skin due to low oxygen concentration in the blood

3. The neonatal period is described as the _____.
 - A. Time of labor and delivery
 - B. Last 28 days in the womb
 - C. First 28 days of extrauterine life
 - D. 28 days to 18 months of age

4. Polycythemia is _____.
 - A. An increase in the total cell mass of the blood; especially the red cells
 - B. A reddish or rosy complexion marked by an over production of red blood cells
 - C. An automatic response by the CNS to a stimulus
 - D. Fine hair that covers the neonatal body; especially if born prematurely

5. Apgar first presented her scoring system in _____.
 - A. 1952
 - B. 1953
 - C. 1962
 - D. 1963

6. A total Apgar score of 4-6 _____.
 - A. Indicates a negative future neurologic outcome
 - B. Is considered normal
 - C. Indicates the need for immediate resuscitation
 - D. May indicate the need for supportive measures

7. The rooting reflex _____.
 - A. Is also known as the startle reflex
 - B. Indicates readiness to walk
 - C. Is demonstrated when pressure is applied to the neonates palms and the neonate responds by clenching his or her fists
 - D. Is the action of the neonate when searching for the maternal breast

8. The normal range for the neonatal respiratory rate is _____ respirations per minute.
 - A. 25-30
 - B. 30-60
 - C. 50-52
 - D. 130-160

9. Bluish discoloration of the skin and mucous membranes due to low oxygen concentration in the blood is _____.
 - A. Cyanosis
 - B. Hypoxemia
 - C. Pallor
 - D. Plethora

10. The "P" in the APGAR acronym refers to _____.
 - A. Pallor
 - B. Plethora
 - C. Pulse
 - D. Polycythemia

Neonatal assessment

Certified Member

Certified Nonmember

Certification No _____

Name _____

Address _____

City _____ State _____ ZIP _____

Telephone _____

| | a | b | c | d | | a | b | c | d |
|---|--------------------------|--------------------------|--------------------------|--------------------------|----|--------------------------|--------------------------|--------------------------|--------------------------|
| 1 | <input type="checkbox"/> | <input type="checkbox"/> | <input type="checkbox"/> | <input type="checkbox"/> | 6 | <input type="checkbox"/> | <input type="checkbox"/> | <input type="checkbox"/> | <input type="checkbox"/> |
| 2 | <input type="checkbox"/> | <input type="checkbox"/> | <input type="checkbox"/> | <input type="checkbox"/> | 7 | <input type="checkbox"/> | <input type="checkbox"/> | <input type="checkbox"/> | <input type="checkbox"/> |
| 3 | <input type="checkbox"/> | <input type="checkbox"/> | <input type="checkbox"/> | <input type="checkbox"/> | 8 | <input type="checkbox"/> | <input type="checkbox"/> | <input type="checkbox"/> | <input type="checkbox"/> |
| 4 | <input type="checkbox"/> | <input type="checkbox"/> | <input type="checkbox"/> | <input type="checkbox"/> | 9 | <input type="checkbox"/> | <input type="checkbox"/> | <input type="checkbox"/> | <input type="checkbox"/> |
| 5 | <input type="checkbox"/> | <input type="checkbox"/> | <input type="checkbox"/> | <input type="checkbox"/> | 10 | <input type="checkbox"/> | <input type="checkbox"/> | <input type="checkbox"/> | <input type="checkbox"/> |

Mark one box next to each number. Only one correct or best answer can be selected for each question.