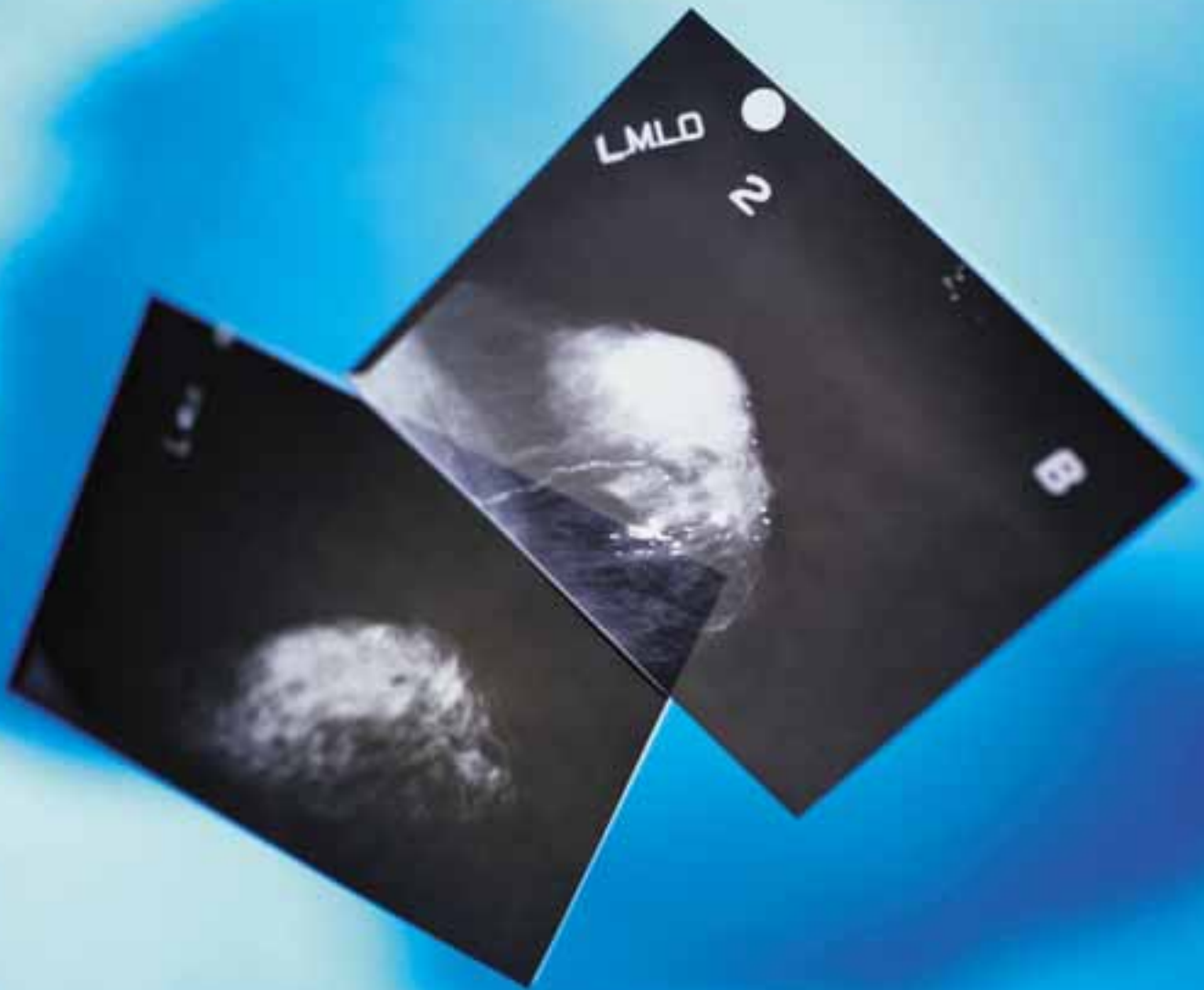

Sentinel



AMY D'AMOURS, ST

Lymph Node

BIOPSY AND LYMPHOSCINTIGRAPHY

RADICAL LYMPH NODE DISSECTION HAS BEEN THE SURGERY OF CHOICE TO STAGE BREAST CANCER AND MELANOMA, AS WELL AS OTHER CARCINOMAS FOR MANY YEARS. IT HAS BEEN USED TO DETERMINE THE EXTENT, IF ANY, OF METASTASIS AND REGIONAL LYMPH NODE INVOLVEMENT IN ORDER TO STAGE THE DISEASE. THIS MAJOR PROCEDURE CARRIES WITH IT MANY SIDE EFFECTS THAT CAN BECOME PROBLEMATIC, SUCH AS LARGE SCARS, INFECTION, HEMATOMA, PAIN, NUMBNESS, AND MOST SIGNIFICANTLY, REGIONAL SWELLING CALLED LYMPHEDEMA.^{1,2,3,4} THE PRACTICE OF A MUCH LESS INVASIVE PROCEDURE IS RAPIDLY BECOMING A STANDARD OF CARE FOR THESE PATIENTS. THIS PROCEDURE, CALLED SENTINEL LYMPH NODE BIOPSY, HAS EMERGED AS THE PROCEDURE TO ASSESS LYMPH NODE STATUS, REPLACING RADICAL LYMPH NODE DISSECTION.

The lymphatic system

The lymphatic system consists of a network of lymphatic vessels, lymph nodes, lymph fluid (transparent fluid containing white blood cells, mostly lymphocytes) and a number of other lymphoid organs, such as the tonsils, thymus and spleen. As arteries and veins circulate the blood to nourish the body's tissues, some fluid escapes and surrounds the cells. Lymphatic capillaries found throughout the body collect the clear, intercellular (interstitial) fluid, called lymph. (The Greek word *lymph* means "pure, clear stream.") The lymphatic capillaries carry the fluid to lymphatic collecting vessels, then to lymphatic trunks, and finally back into the vascular system through one of two large ducts in the thoracic region. Through these ducts, the lymph is carried to heart (Figure 1).

Lymph carrying vessels have valves, similar to those found in our veins, which carry the fluid in one direction towards the heart, so that all this fluid ends back in our circulatory system. As the lymph enters the lymph vessels, it is pumped along by our contracting muscles.⁸ As lymph fluid travels through the system, it is filtered by lymph nodes. Lymph nodes are oval shaped masses of lymph tissue covered by a fibrous capsule of connective tissue.⁸ The size of the nodes varies from the size of a pinhead to the size of a lima bean, or 2 mm to 20 mm in length with a longitudinal diameter up to 15 mm.²

Lymph nodes are arranged in specific clusters in our body, called basins. The major basins in the human body are in the axillary, the inguinal, and the cervical regions.⁸ In these nodes, large particles of foreign matter are filtered from the traveling lymph, hopefully before re-entry into the bloodstream. Tumor cells are one example of these "foreign bodies." When a primary tumor spreads, or metastasizes, these tumor cells move through the lymphatic vessel to the regional basin and become trapped in a lymph node or nodes. By definition, a sentinel node is the first node, or nodes in some cases, that receives the primary lymphatic flow from the tumor site. Studies have shown any specific basin may contain more than one sentinel node. One study found a single sen-

tinell node in 59% of patients, two sentinel nodes in 37%, and three sentinel nodes in 3% of patients.⁹ The sentinel node has also been called a "gatekeeper" or a "node on watch" (as a sentinel would be at a gate) over the years.^{5,6}

Some lymph drainage follows a fairly reliable lymphatic flow path, such as in the breast, which may cause metastasis to the regional basin in the axilla (Figure 2). However, in the case of melanoma, the drainage is similar, but can vary, depending on the location. For example, melanomas of the leg usually travel to the groin area (inguinal nodes) and melanomas on the arm usually travel to the axillary basin (axillary nodes). If the melanoma is on the patient's back, however, the lymphatic channel can vary. The metastasis may travel to the axillary or the groin area. In all of these cases the tumor cells become trapped in these nodes as a "large particle" and can begin to multiply.⁷

The use of a lymphatic mapping procedure, called lymphoscintigraphy, has become vital in highlighting the lymphatic drainage from the primary tumor. This procedure is carried out in the nuclear medicine department of the hospital.

Cancer and lymphatic dissection

Because lymph nodes play such a vital role in removing foreign matter (eg tumor cells) from our bodies, surgeons have used lymphatic dissection for years to stage cancer and to determine the extent or spread, if any, of the cancer. Staging of the cancer via evaluation of the lymph node(s) is a way of predicting the prognosis and determining further treatment for the patient. These radical dissections are a considerable surgical procedure and carry with them numerous side effects as well as a longer recovery period.

Lymph node dissections are done following a positive diagnosis of cancer, either by a lumpectomy, a biopsy, a wide incision, or an X-ray-guided needle biopsy. The size of the tumor and its histology aid in the process of staging the disease.¹ Staging procedures include studies such as blood work and diagnostic imaging studies to assess the organ(s) that the cancer is known to target. For example,

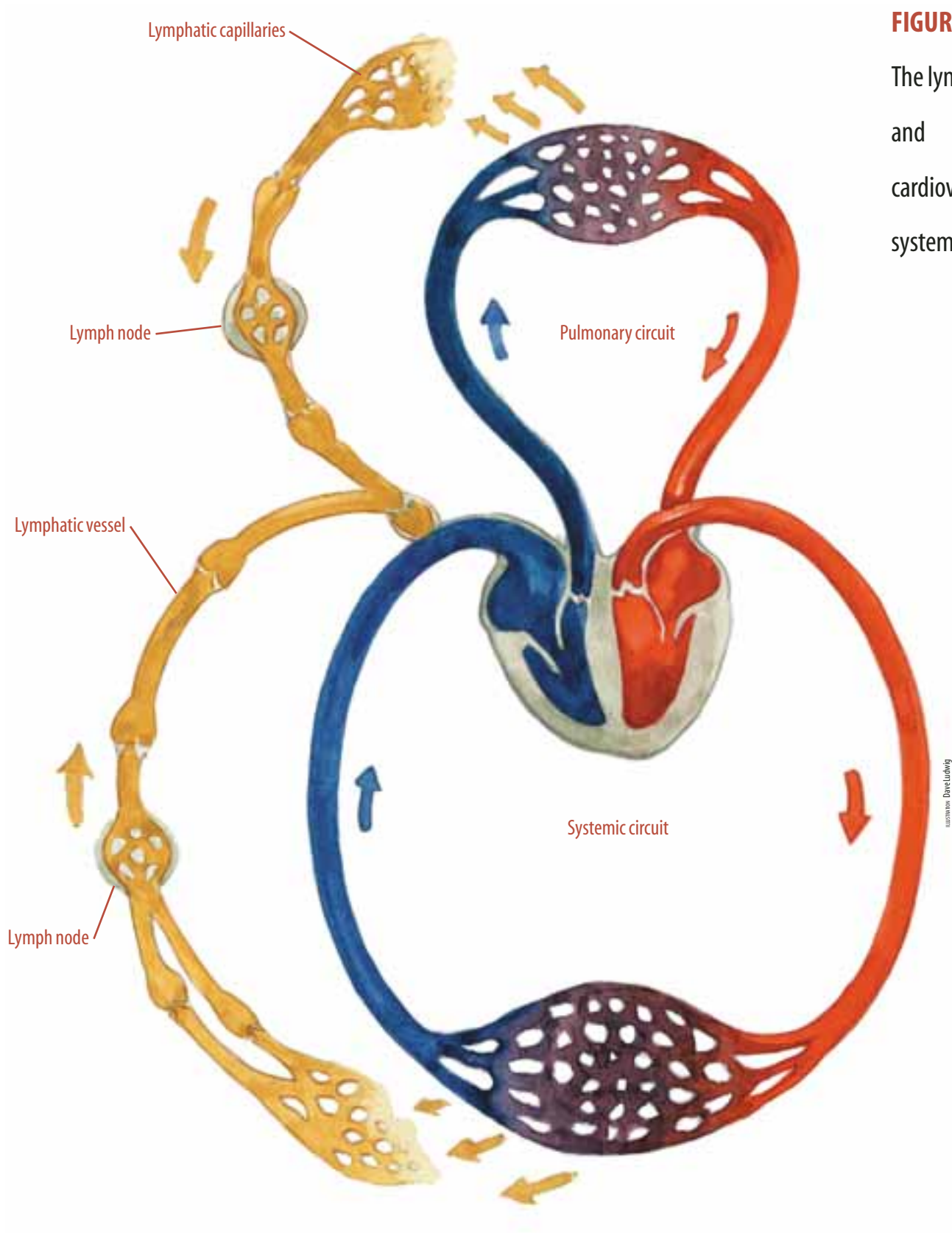


FIGURE 1
The lymphatic
and
cardiovascular
systems.

in breast cancer the target organs are bone, the other breast, the liver, lungs, and the brain. The patient will have tests to determine distant metastasis; whereas, the sentinel node assesses regional metastasis, if any.

In complete (radical) lymph node dissections, there may be removal of 15-25 lymph nodes.¹ These nodes and surrounding tissue will go to the pathology department for analysis. In removing the many nodes and the surrounding tissue, the patient is left with a significant scar, possible infections, or wound breakdown. She/he may also be left with a decreased range of motion near the surgical site. But most importantly, this extensive removal of lymph tissue can significantly reduce the lymphatic drainage in the region, resulting in a painful and lifelong condition known as lymphedema.^{1,3}

Lymphedema is an accumulation of fluid (lymph) in soft tissue, and regional swelling that may cause severe swelling in the regional limb and continue for the patient's lifetime.⁶ Lymphedema can be permanent in 7-37% of breast cancer patients that undergo a standard axillary node dissection.² Patients must use extreme care to prevent infections due to the decreased removal of lymph in a specific region. Some preventive measures include wearing gloves when gardening, having no blood drawn from the arm that has had surgery, and to avoid blood pressure readings taken on the affected arm.

Radical node dissections are also more expensive. For example, in 1998 the cost of an axillary lymph node dissection was approximately \$11,000. In comparison, lymphatic mapping along with sentinel node biopsy done on an outpatient basis costs only \$1,200.¹⁰ It is also important to remember that many patients may have no metastasis or lymph node involvement at all. Studies show that approximately 55% of those who have had an axillary node dissection had negative nodes, making the practice of automatic lymph node dissection economically impractical, especially if other diagnostic procedures can be effective.⁴

History

Sentinel lymph node biopsies have been used since the late 1970s, beginning with melanoma studies.³ Over the next 20 years, many studies were done using lymphoscintigraphy and blue dye. The procedure became quite popular by the 1980s. In the 1990s, Donald Morton, MD, previously professor of surgery at UCLA and now medical director and surgeon at John Wayne Cancer Institute in Santa Monica, California, presented the concept of using lymphatic mapping and sentinel node biopsy to stage breast cancer at an oncology seminar.¹¹ He was the first to describe the "sentinel node" as the first node in the basin that receives lymphatic flow from the primary tumor. Morton also stated that if the first lymph node is negative for metastasis, then the rest should also be negative.¹ Numerous studies since have validated his theory. Since the 1990s, sentinel lymph node biopsy has become increasingly popular for breast cancer staging, as well as for melanoma and other cancers.¹¹

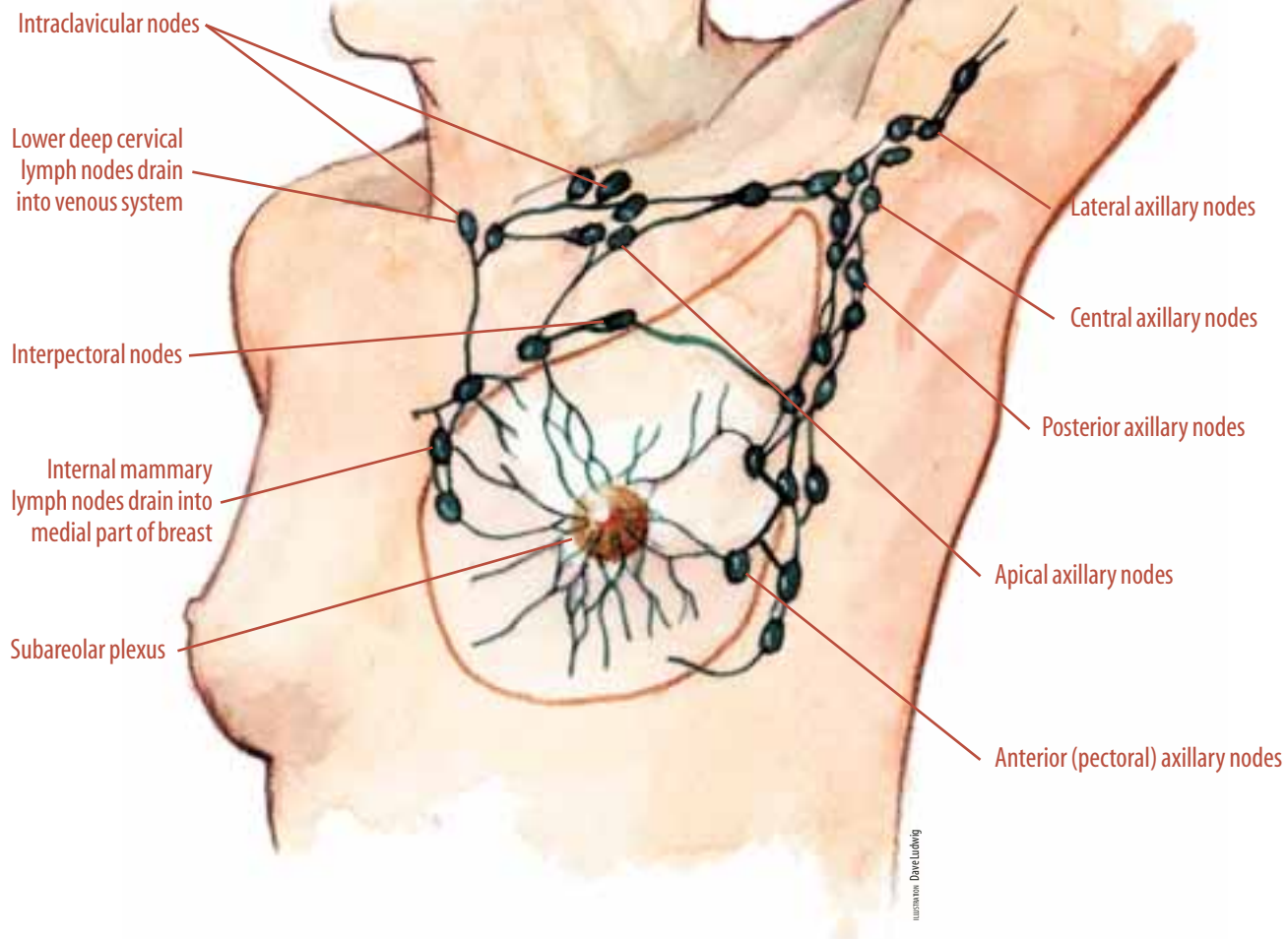
Sentinel lymph node biopsy is contraindicated in some patients. Examples of this are those who had previous axillary dissection, regional trauma or an infection that might have changed the lymphatic drainage from the tumor site, allergies to the dyes used, palpable nodes, and extensive breast cancer. Also it should not be used in pregnant or nursing mothers until further studies are performed on this population.^{2,3}

Procedural overview

The sentinel lymph node procedure begins following a diagnosis of cancer. This diagnosis may follow a routine mammography, a needle biopsy performed by a radiologist, or during a routine visit to the patient's primary physician. The patient may be sent to a surgeon for further evaluation, followed by a needle biopsy (if one has not been done) or by an excisional biopsy for breast cancer. A biopsy from the melanoma or other tumor may be performed in order to diagnose the tumor as either benign or malignant.^{1,3} At this time, the surgeon will need to determine

FIGURE 2

Axillary basin.



if the cancer has spread or metastasized, and further tests are prescribed. This staging process will help determine the patient's prognosis, as well as further treatment options.

Sentinel lymph node procedures are performed today in an ambulatory surgery setting to determine the extent of the cancer. Within a few hours of the scheduled surgery, the patient goes to the nuclear medicine department and possibly to the radiology department, if a needle localization is needed on a nonpalpable tumor.^{1,3} If needed, the radiologist places a localization wire to pinpoint the tumor, for the nuclear medicine department as well as for the surgeon. The patient is then taken to the nuclear

medicine department for mapping of his/her lymphatic system. This mapping is done to highlight the drainage of the patient's lymph from the tumor site. The procedure is explained to the patient and their questions are answered. A radioactive isotope (tracer), technetium-99, is injected at or around the tumor site.^{1,2,5} This is a very important step, since not everyone's lymph vessels are located exactly the same, and do not drain the same.

The tracer enters the lymphatic system and is transported to the regional basin. It will settle in the first sentinel node(s) as it travels. This process of migration can take 10 to 30 minutes. The radiologist will then use a gamma camera

Instrumentation and supplies

I. Used prior to sterile prep

- Gamma counter
- Gamma tracer probe with sterile disposable sleeve
- Isosulfan 1%, 5 ml single dose vial; 5 cc syringe to inject; 21- or 25-gauge needle
- Alcohol wipes and nonsterile gauze sponges (used prior to injection)

II. Skin Prep

- Betadine prep or Duraprep (according to surgeon's preference)

III. Surgical procedure

- Marking pen
- Local anesthesia; Lidocaine 2% (20 cc); Bupivacaine 0.25%-0.5% (20 cc) with or without epinephrine
- Sodium Bicarbonate (4 cc) (surgeon's preference)
- General anesthesia; Bupivacaine 0.5% (surgeon's preference)
- 10 cc syringe/25-gauge needle
- #3 knife handle/#10 and #15 blades (enough to change skin knife and use after dissecting nodes)
- Electrosurgical unit with dispersing pad
- Suction tubing with Yankauer suction tip
- Small self-retaining retractors (Weitlaner, etc), double skin hooks, Senn retractors, small rakes (see surgeon's preference cards)
- Sterile normal saline with bulb syringe
- Sterile radiopaque 4"x4" sponges
- Peanuts
- Minor Set (Crile, Kelly, Allis, toothed, and non-toothed forceps, toothed Adson forceps, needle holders, US Army retractors, Mayo and Metzenbaum scissors)
- Ligating clip applicators and clips (assorted sizes)
- 4-0 Vicryl, 5-0 Vicryl, 2-0 silk (tissue marking)(see surgeon's preference)
- Skin stapler (available)
- Medicine cups (approximately five) for specimens
- Gown and towel and linen pack
- Drain: eg Jackson Pratt 7 mm flat (available for axillary dissection)
- Dressings, skin-closure tapes, tincture of benzoin (surgeon's preference)^{1,3}

to map the drainage of this radioactive substance. A hard copy or scan (similar to an X-ray) is made for the surgeon to view before and during surgery. It will guide him/her in locating the "sentinel node". The sentinel node location may also be marked on the patient's skin like a tattoo-type in the nuclear medicine department.¹

Studies have pointed to the importance of timing between the injection given in lymphoscintigraphy and the time that the first surgical incision is made to isolate the sentinel node. One to four hours between these two procedures is recommended.²

Intraoperative procedure

Within a few hours following lymphoscintigraphy, the patient will enter the operating room. He/she will be positioned supine for breast surgery; however, the position will vary according to the tumor location in melanoma or other type of cancer. Anesthesia, which may be local or general, will then be administered.

At this time, the surgeon injects 3-5 cc of a blue dye, usually 1% isosulfan blue, about five minutes before initiation of the first incision at or around the tumor site.² (Since its particles are too small to be trapped in the nodes, methylene blue should not be used for this procedure.) The closer the tumor is to the regional basin, the shorter the interval; increased distance lengthens the interval. If the incision is made too soon, the dye will not have had time to travel through the afferent lymphatic vessel to the node. Waiting too long decreases detectability of the sentinel node because nearby nodes will also have absorbed the dye.²

Typically, the surgeon massages the area to facilitate the flow of the dye into the draining lymphatic vessels. The blue dye provides a visible marker, as well as an auditory marker from the sound made by the gamma ray (Geiger) counter as it detects the radioactive isotope. Some surgeons then use the nonsterile gamma probe to confirm the path of lymphatic drainage.

The circulator proceeds with prepping the surgical site. While the circulator is performing

Staging options for cutaneous melanoma

Since the late 1980s, there has been debate within the medical community regarding the staging for cutaneous melanoma that centers on the different approaches for thin, intermediate or thick lesions. Therapy is determined by analyzing the characteristics and depth of the tumor. Thin lesions are defined as less than 0.75 mm in Breslow thickness, thick cancers, greater than 4 mm, and intermediate, everything in between. The greatest prospects for complete curative treatment remains with patients with the intermediate and thin range lesions.

Since the mid-1990s the gold standard for accurate staging of melanoma patients has become the sentinel lymph node biopsy (SLNB). SLNB is most suitable for malignant melanoma patients with lesions greater than 0.76 mm Breslow thickness and breast cancer patients with invasive disease up to 5 cm in dimension.

Melanoma patients

Minimally invasive SLNB is designed for staging of patients who have a solid tumor lesion with a high risk of metastases. Malignant Melanoma is one of the most aggressive cancers. There are two schools of thought regarding lymphatic evaluation in patients with clinically node negative disease. One group (elective lymph node dissection) believe all patients with intermediate thickness melanomas and clinically negative lymph node basins should undergo complete lymphadenectomy to identify occult disease and prevent spread of disease to other organs. The second group (therapeutic lymph node dissection) would argue lymphadenectomy to prevent metastases could create greater complications than improve survival rates. These complications include lymphedema, nerve injury, wound complications, such as a seroma and infection. The surgical intervention (elective lymph node dissection) group has taken a much more aggressive position on staging these patients. Their approach was to remove all or most of the draining lymph nodes, most often many more than necessary. The Sentinel Lymph Node Biopsy (SLNB) eliminates this contro-

versy by providing a minimally invasive solution by identifying metastatic disease in clinically node negative patients.

Lymphatic mapping

SLNB provides the same histopathological information as a radical lymph node dissection with minimal morbidity and far less complications; a far better surgical outcome. Generally, the surgeon removes only one or two lymph nodes that are interrogated rigorously and subjected to specialized histochemical staining techniques in addition to routine H&E sections. If these sentinel nodes are free of disease (80% of the time), the rest of that lymph node basin is likely to be free of metastases with confidence limits to 98%. Many multi-site trials have validated these findings with a false negative rate of less than 2.6% nationally.

Source: "Sentinel Lymph Node Biopsy: The Standard of Care for Staging Malignant Melanoma." [press release] Boca Raton, Florida: Gamma Surgery; 2002. www.gammasurgery.com

the prep, the surgeon(s) scrub, gown and glove. Having already set up the back table and Mayo stand, the surgical technologist assists the surgeon with draping.

The surgeon uses the gamma probe (wand), which has been covered with a sterile sleeve to find the radioactive "hot spots" by listening for the loudest noise as well as reading the numbers displayed on the gamma counter. The higher the number shown, the more radioactivity at the site. The surgeon may also refer to the lymphatic map at this time, which is in the operating room and ready to be viewed. Marking of the skin is then performed with a marking pen above the first (sentinel) node, and the incision above the sentinel node begins.^{3,5}

The surgeon carefully dissects down, using blunt dissection, following the lymphatic drainage from the tumor and using the blue color of the Lymphazurin to direct the approach. When the node is located, the probe will again be used to take a reading to confirm the amount of radioactive isotope amount in the node. All of these readings must be documented by the circulating nurse.¹

The sentinel node is excised, and placed in a sterile specimen cup. With the surgeon's permission, it is passed to the circulator to be labeled with the location of the node and sent to pathology for a frozen section analysis or touch prep analysis. Numerous specimen cups should be available for this purpose, each specifically labeled.³ Another reading from the gamma counter is taken, and the circulator continues to record all results. The surgeon looks for further sentinel nodes in the same manner.

If the lumpectomy or wide excision has not been performed previously, it would be completed while waiting for the pathology report. If the pathology results come back negative for metastasis in the sentinel node(s), the surgical site(s) will be irrigated and closed. If the results are positive, further lymphatic dissection will be performed and a drain may be inserted at the surgical site. Dressings will be applied and the patient will be moved to the post anesthesia care unit.

Radiation safety

Facility policies differ concerning radiation exposure safety due to the use of the radioactive isotope used in this procedure. The policy in the past was to use disposable paper goods and to isolate these goods with all used instruments and supplies and trash until the amount of radiation decreased to a certain predetermined level.³ This isolation process took up to 72 hours, but varied according to policy from one facility to another. Radiation monitoring badges were worn by the surgical team to determine the amount of radiation exposure. However, research has now shown that the amount of radiation exposure during this procedure is not high enough to necessitate this process.¹

Many facilities today do not require the use of paper goods or any special disposal process. However, facilities may specify special handling of the sentinel node specimen when it is sent to pathology, as well as during the time it is in the pathology department. With the rapidly changing regulations and hospital policies, it is of utmost importance that the surgical technologist be fully aware of their facility's policy on this subject, to evaluate the practice from time to time, and to work to change practices when they become obsolete. As procedures evolve, the early restrictions may no longer be theoretically or clinically significant.

The future

The American Cancer Society estimates that there will be 205,000 new cases of breast cancer and 53,600 new cases of melanoma in 2002 in the United States alone.¹² As more clinical trials continue to show positive results, the number of new cases of these types of cancer should impact on the increased use of sentinel lymph node biopsy. With the trend in today's health care to improve diagnosis with less invasive surgery and to keep the cost of surgery as low as possible, including minimizing the patient's hospital stay, these minimally invasive procedures should continue to increase. Surgical technologists' understanding of the different phases of this procedure as well as the time involved for the patient are key

to set the standards of care and to improve the care given to these patients.

About the author

Amy D'Amours graduated from Springfield Technical Community College in Springfield, Massachusetts, with an associate's degree in surgical technology in May 2002. She now works as a surgical technologist at Maple Surgery Center, an affiliate of Baystate Health Systems, in Springfield. Amy is married and has three teenage children.

Acknowledgments

Special thanks to the operating room staff and nuclear medicine staff at Mercy Medical Center and Baystate Medical Center in Springfield, Massachusetts, for their cooperation in preparing this manuscript. Additional thanks to Kathleen Flynn, surgical technology program director at Springfield Technical Community College, as well as to the STCC library staff.

References

1. Giuliano R. Lymphatic Mapping and Sentinel Node Biopsy [video and study guide] CineMed: 1-9.
2. Bland K. Lymphatic Mapping and Sentinel Lymphadenectomy for Breast Cancer. In: *The Breast: Comprehensive Management of Benign and Malignant Diseases*. Bland KI and Copeland III EM, eds. 2nd ed. Philadelphia, Pennsylvania: WB Saunders; 1998: 1105-1108.
3. Kellar S. Sentinel Lymph Node Biopsy for Breast Cancer. *AORN Journal*. August 2001;74(2): 197-200.
4. Smeltzer SC and Bare BG, eds. *Textbook of Medical-Surgical Nursing*. 9th ed. Philadelphia, Pennsylvania: Lippincott; 2000:11295-11297.
5. Meeker MH and Rothrock JC, eds. *Alexander's Care of the Patient in Surgery*. 11th ed. St Louis, Missouri: Mosby; 1999:626-627.
6. Anderson KN, revision ed. *Mosby's Medical, Nursing and Allied Health Directory*. 5th ed. St Louis, Missouri: Mosby; 1998: 967-968.
7. Poole CM. *Melanoma: Prevention, Detection and Treatment*. New Haven, Connecticut: Yale University Press; 1998:61-66.
8. Marieb EN. *Human Anatomy and Physiology Laboratory Manual*. 6th ed. Menlo Park, California: Benjamin Cummings; 2000:368-369.
9. Davita VT Jr, Hellman S, Rosenberg SA, eds. *Cancer: Principles and Practices of Oncology*. 6th ed. Philadelphia, Pennsylvania: Lippincott, Williams & Wilkins; 2001:2033-2037.
10. Imaging System Pinpoints Sentinel Lymph Nodes: Lymphoscintigraphy is inexpensive, Simple and Excellent. *Medical Post* [online]. 6/30/1998. eLibrary. ask.elibrary.com/index.asp
Assessed 12/13/02
11. John Wayne Cancer Institute. About Us. www.jwci.org/aboutus.html Assessed 12/13/02
12. Cancer Statistics 2002. *CA*. 2002;52:25.

Sentinel lymph node biopsy

Earn CE credit at home

You will be awarded one continuing education (CE) credit for recertification after reading the designated article and completing the exam with a score of 70% or better.

If you are a current AST member and are certified, credit earned through completion of the CE exam will automatically be recorded in your file—you do not have to submit a CE reporting form. A printout of all the CE credits you have earned, including Journal CE credits, will be mailed to you in the first quarter following the end of the calendar year. You may check the status of your CE record with AST at any time.

If you are not an AST member or not certified, you will be notified by mail when *Journal* credits are submitted, but your credits will not be recorded in AST's files.

Detach or photocopy the answer block, include your check or money order (\$6 for members or \$10 for nonmembers) made payable to AST and send it to the Accounting Department, AST, 7108-C South Alton Way, Centennial, CO 80112-2106.

- Which is not part of the lymphatic system?
 - thyroid gland
 - spleen
 - lymph nodes
 - tonsils
- Which statement about lymph is not accurate?
 - it contains lymphocytes
 - it is a clear fluid
 - it is initially collected by the vascular system
 - it is eventually carried to the heart
- Basins are clusters of
 - lymphatic capillaries
 - lymph vessels
 - lymphocytes
 - lymph nodes
- What is the primary characteristic of the sentinel node(s)?
 - it is the only one that filters tumor cells
 - it is the size of a lima bean
 - it receives the primary lymphatic flow from the tumor site
 - it is located in the sentinel basin
- The main purpose of lymphoscintigraphy is to _____.
 - map the lymphatic drainage
 - assess lymph for tumor cells
 - locate the spleen
 - determine distant metastasis
- Possible complications of lymph node dissection include:
 - increased susceptibility to infections
 - decreased range of motion
 - scarring
 - all of the above
- Which is true about lymphedema?
 - caused by accumulation of lymph in the tissue
 - may follow axillary node dissection
 - may be permanent
 - all of the above
- The time between isosulfan injection and the first injection is critical because:
 - dye must have time to reach the sentinel node
 - dye must not have time to absorb into surrounding nodes
 - both a and b
 - none of the above
- Radioactive dye is used to _____.
 - audibly locate the sentinel node
 - confirm the path of lymphatic drainage
 - visually map the surgical site
 - all of the above
- A _____ may be performed while waiting for the pathology report.
 - lumpectomy
 - mastectomy
 - Geiger count
 - all of the above

Sentinel lymph node biopsy

Certified Member

Certified Nonmember

Certification No _____

Name _____

Address _____

City _____ State _____ ZIP _____

Telephone _____

	a	b	c	d		a	b	c	d
1	<input type="checkbox"/>	<input type="checkbox"/>	<input type="checkbox"/>	<input type="checkbox"/>	6	<input type="checkbox"/>	<input type="checkbox"/>	<input type="checkbox"/>	<input type="checkbox"/>
2	<input type="checkbox"/>	<input type="checkbox"/>	<input type="checkbox"/>	<input type="checkbox"/>	7	<input type="checkbox"/>	<input type="checkbox"/>	<input type="checkbox"/>	<input type="checkbox"/>
3	<input type="checkbox"/>	<input type="checkbox"/>	<input type="checkbox"/>	<input type="checkbox"/>	8	<input type="checkbox"/>	<input type="checkbox"/>	<input type="checkbox"/>	<input type="checkbox"/>
4	<input type="checkbox"/>	<input type="checkbox"/>	<input type="checkbox"/>	<input type="checkbox"/>	9	<input type="checkbox"/>	<input type="checkbox"/>	<input type="checkbox"/>	<input type="checkbox"/>
5	<input type="checkbox"/>	<input type="checkbox"/>	<input type="checkbox"/>	<input type="checkbox"/>	10	<input type="checkbox"/>	<input type="checkbox"/>	<input type="checkbox"/>	<input type="checkbox"/>

Mark one box next to each number. Only one correct or best answer can be selected for each question.