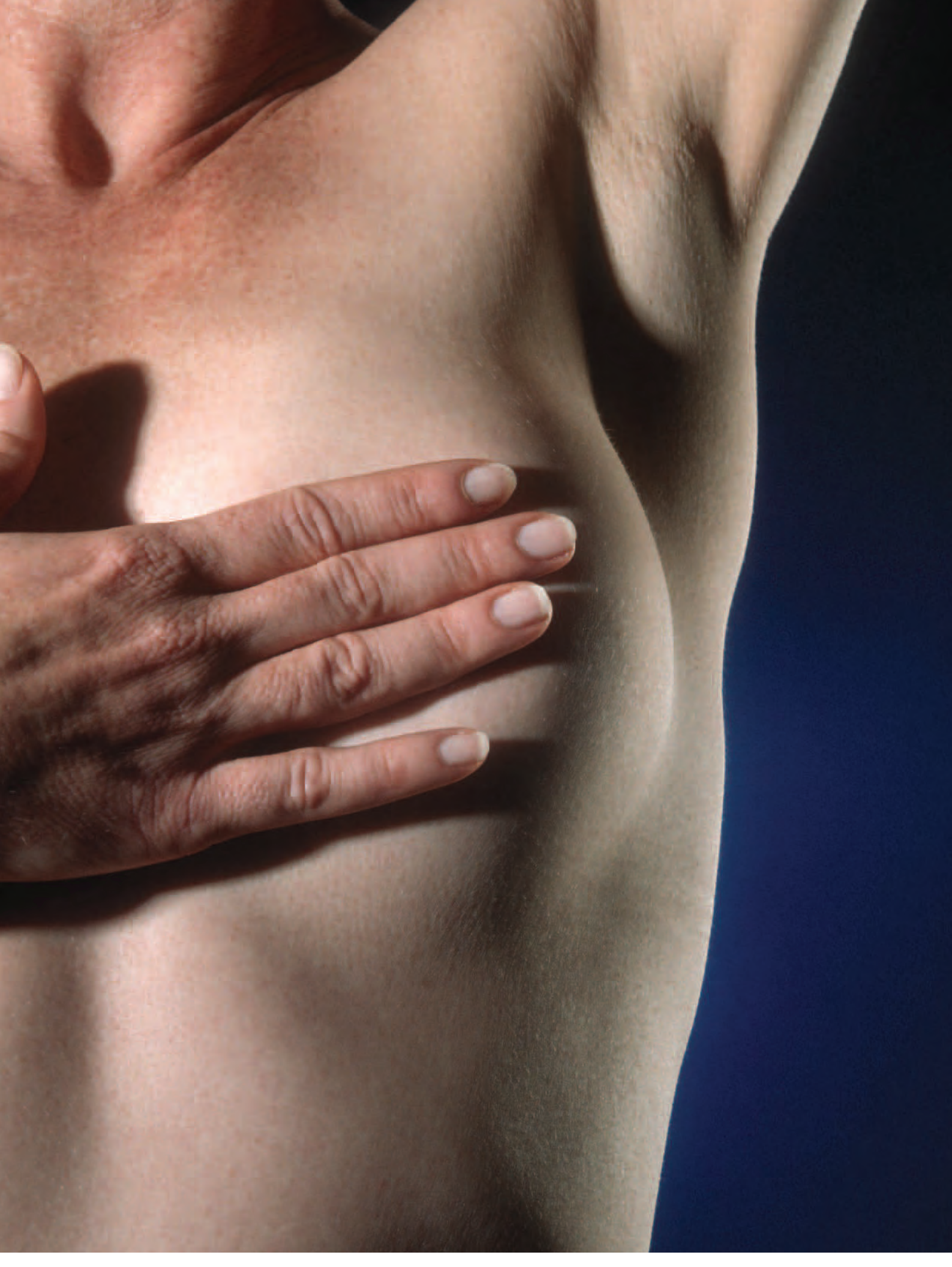



Radical Mastectomy and Reconstruction

by Brittany Stapp-Caudell

As thousands of women every year are being diagnosed with breast cancer, bilateral mastectomies are becoming both the prophylactic as well as the therapeutic procedure of choice for women young and old to prevent as well as to combat the aggressive, potentially deadly breast cancers. This article will investigate the indications for mastectomy surgery, as well as a case study of a bilateral modified radical mastectomy in the clinical setting.

INTRODUCTION

In today's society, the term "mastectomy" is commonplace in medical terminology, as well as in the postings of an operating room's surgery schedule and insurance billing requests. As thousands of women every year are being diagnosed with breast cancer, bilateral mastectomies are becoming both the prophylactic, as well as therapeutic procedure of choice for women, young and old, to prevent and combat aggressive, potentially deadly, breast cancers.

BREAST ANATOMY

The female breasts are paired anatomical structures on the anterior portion of the thoracic region of a human being. Both males and females have breasts, although the normal anatomy and physiology of the structures varies vastly between the two sexes.

The base of the breast is the attached surface of the breast. It attaches to the deep fascia of the pectoralis major muscle, which overlies the chest cavity. The base of the breast extends vertically over the ribs numbered two through six, and transversally from the sternum to the midaxillary line.¹ The upper region of the

LEARNING OBJECTIVES

- ▲ Examine the evolution of the mastectomy procedure
- ▲ Explore the affected anatomy
- ▲ Compare and contrast different surgical options for breast cancer
- ▲ Evaluate the breast cancer staging process
- ▲ Analyze the step-by-step procedure for a bilateral mastectomy

breast can extend as far as the lateral margin of the pectoralis major muscle and into the axilla.

In general, the breasts consist of secretory glands, superficial fascia and overlying skin, and subcuticular fat. Anatomically, in the pectoral region on each side of the anterior thoracic wall, the mammary glands are modified sweat glands in the superficial fascia anterior to the pectoral muscles and the anterior thoracic wall.¹ In each breast, the mammary glands and their associated duct systems are arranged in an array of lobules situated in a circumferential pattern around a central nipple, or papilla. In culmination, the ducts and the lobules converge to form approximately 20 lactiferous ducts that exit separate of one another onto the nipple.¹ Additionally, in relation to breast anatomy, the circular area of pigmented skin immediately surrounding the nipple is referred to as the areola.

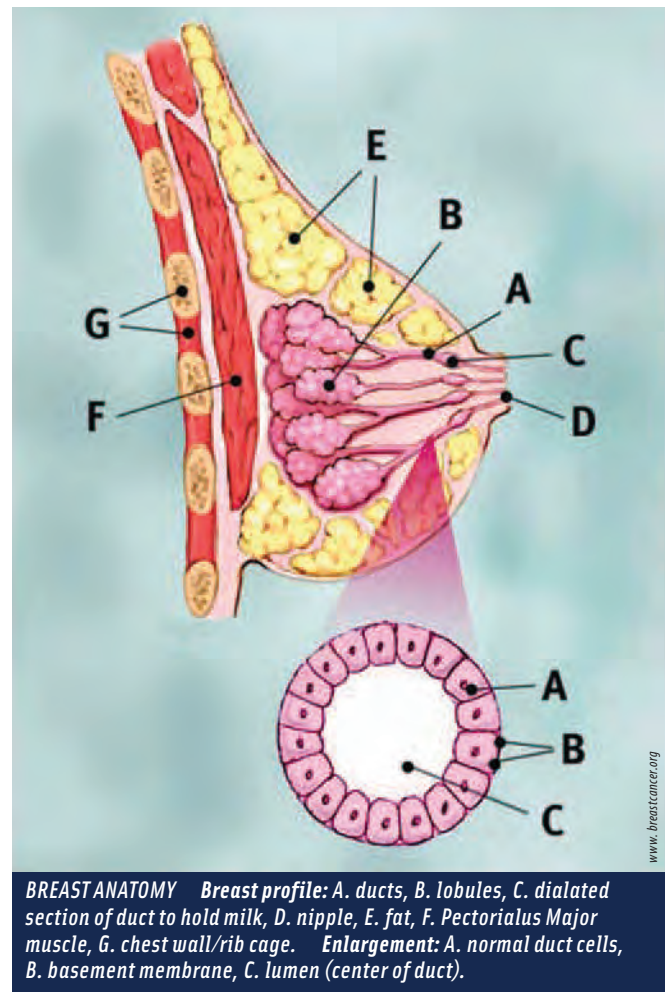
In each breast, a developed connective tissue stroma surrounds the individual ductal and lobule systems of the mammary glands. In certain regions, this connective tissue stroma condenses into ligaments. These are the suspensory ligaments of the breast, and are continuous with the dermal and epidermal tissue of the breast. In general, the suspensory ligaments are responsible for supporting the independent structures of the breasts.¹

The lateral arterial blood supply to the breast provided by the vessels from the superior thoracic axillary artery, the thoracoacromial artery, the lateral thoracic artery and the subscapular arteries.¹ Additionally, the medial breast receives arterial blood flow through the branches from the internal thoracic artery, as well as through the second

Breast cancers account for about 30 percent of all cancer cases found in women and 16 percent of cancer deaths. The highest rates of breast cancer are in North America and Europe.³

through the fourth intercostal arteries via arterial branches that perforate the thoracic wall, and the overlying pectoralis musculature.¹ Venous drainage from the breast occurs through veins that parallel the arteries and drain into the axillary, internal thoracic and intercostal veins.¹

The normal breast is innervated by a number of nervous branches. Innervation of the breast is via the anterior and later-



al cutaneous branches of the second to sixth intercostal nerves. The nipple is innervated by the fourth intercostal nerve.¹

Nearly 75 percent of the lymphatic drainage of the breast drains laterally and superiorly to the axillary lymph nodes. The remaining lymphatic drainage occurs into the parasternal nodes, as well as through lymphatic vessels that follow the lateral branches of the posterior intercostal arteries.¹ The axillary lymph nodes, therefore, are the primary region to sample for cancer metastasis into the lymphatic system.

In males, the breast anatomy differs greatly. The male breast is a rudimentary system composed of small ducts and strings of breast cells that do not typically extend beyond the areolar region of the male breast.

BREAST PHYSIOLOGY

The female breast is physiologically responsible for the production of milk for the purpose of nursing an infant. Specifically, the mammary glands are responsible for the production of milk. These glands are present at birth in the female,

yet do not begin developing until puberty. The glands do not become completely functional, however, until the end of pregnancy. Placental lactogen (hPL), a hormone given off by the placenta, prepares the breasts for lactation.² Additionally, prolactin, a hormone excreted by the anterior pituitary, stimulates the secretory cells of the breast for lactation. In the male, the breast serves no physiological function.

The initial products of the secretory glands of the breast is termed colostrum and is a thin, white liquid that is “let down” immediately following the birth of a neonate. Milk secretion typically begins within a few days of the birth of a neonate and can extend as long as a few years as long as an infant or toddler is suckling on the breast. The process of an infant suckling the breast acts to remove the created milk and further stimulates additional milk production through the release of Oxytocin, an additional hormone, from the posterior pituitary.² In non-lactating women, the predominant component of the breasts is fat, while glandular tissue is more abundant in lactating women.²

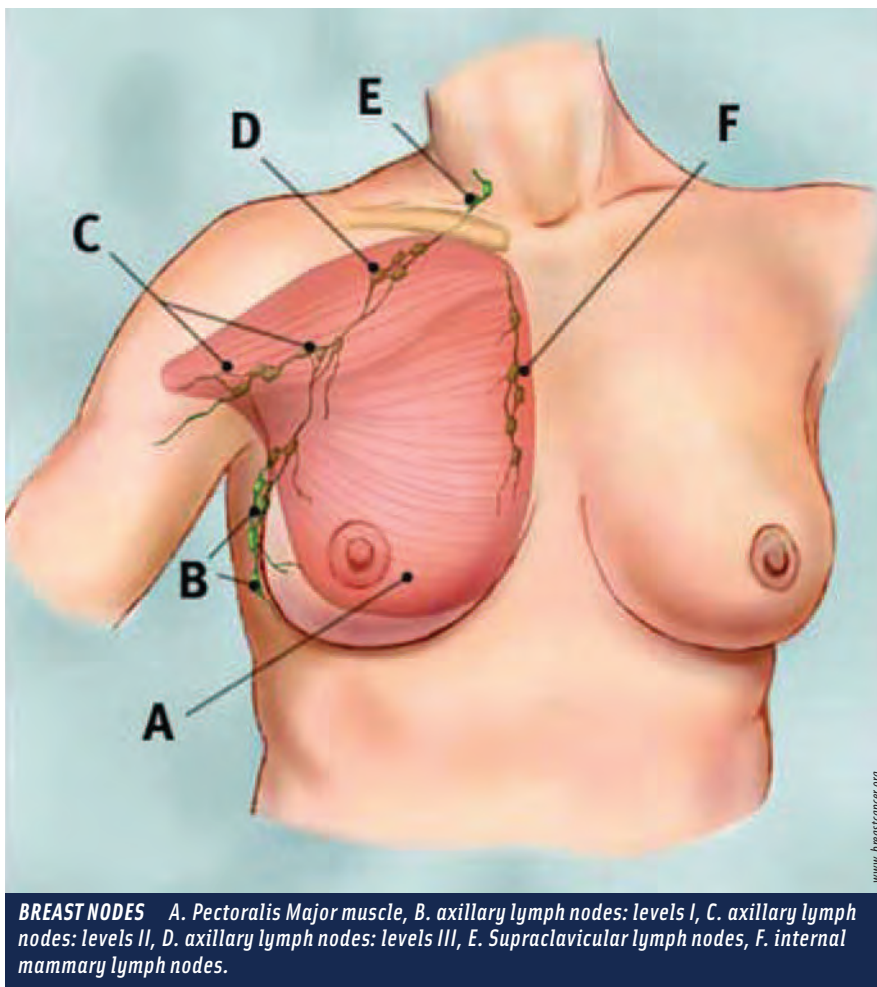
BREAST CANCER

Breast cancer is the most common cancer that affects American women today. Additionally, it is the leading cause of death in women ages 40-44 years of age, and is the second most common killer of all ages after lung cancer.³ The incidence of invasive breast cancer in the female is on the rise, and has increased in incidence since the 1990s. The increase in the incidence rate of invasive breast cancers in today’s society may be a direct result of early detection by means of mammography. Breast cancers account for about 30 percent of all cancer cases found in women and 16 percent of cancer deaths. The highest rates of breast cancer are in North America and Europe.³

Breast cancer should be treated as soon as possible, once a firm diagnosis has been made. Early detection and treatment of breast cancer improves the chances of a successful outcome and full recovery. The risk factors of breast cancer can be classified as reproductive, hormonal, environmental and familial, however, the majority of breast cancers occur in women whose only known risk factors are gender and age.³

The risk for developing breast cancer in women is affected by her age when her first child is born. The younger a female is when she gives birth to her first child, the lower that particular female’s risk is for developing aggressive and invasive breast cancer.³

Additionally, familial factors have an implication in the prevalence of breast cancer development among women. In terms of genetics, breast cancer can be divided into three main groups. The first genetic group is termed sporadic. These women, approximately 40 percent of those diagnosed with breast cancer, have no familial history in the development of the disease.³ The second group of women has an inherited autosomal-dominant set of cancer-causing genes. The final group is a classification of women who *do* have a family history, yet do not possess genes that are passed on in a dominant gene fashion.



www.breastcancer.org

BREAST NODES A. Pectoralis Major muscle, B. axillary lymph nodes: levels I, C. axillary lymph nodes: levels II, D. axillary lymph nodes: levels III, E. Supraclavicular lymph nodes, F. internal mammary lymph nodes.

“A history of breast cancer in first-degree relatives (mother or sister) increases a woman’s risk of breast cancer two to three times.³ The risk of breast cancer in these particular women increases exponentially if there is a history of a second first-degree relative who is suffering or suffered from breast cancer, especially if the disease occurred before menopause, and if the disease was bilateral in fashion.³ The most common and important of the breast cancer susceptibility genes are the BRAC1 and BRAC2 genes. BRAC1 is located on chromosome 17 and BRAC2 is located on chromosome 13.³ The BRAC1 and BRAC2 genes are two tumor-suppressing genes that, when mutated, allow a woman to have a higher chance of developing breast cancer.

SYMPTOMS OF BREAST CANCER

The widespread use of screening mammograms, as well as the overall increase in societal information in relation to breast cancer, has increased the number of breast cancers identified before any symptoms are noticed. There are still, however, some cases in which breast cancers are not diagnosed until certain symptoms become noticed by the patient themselves.

The most common sign of breast cancer is a new lump or mass.⁴ A lump felt by either a patient or a health care practitioner that is painless to the touch, hard, and/or has uneven edges is more likely to be cancer when compared to a smoother breast mass.⁴ Additional signs of breast cancer include, but are not limited to, swelling of all or a portion of the affected breast, skin dimpling accompanied by breast pain, nipple pain or an inversion of the nipple, redness in the breast region, thickening of the nipple or breast skin, nipple discharge and/or a lump in the axillary regions.⁵

Table 1: Stages of Breast Cancer⁴

PRIMARY TUMOR (T)	
TX:	Primary tumor cannot be assessed.
T0:	No evidence of primary tumor.
Tis:	Carcinoma in situ
T1:	Tumor is 2 cm (3/4 of an inch) or less across.
T2:	Tumor is more than 2 cm but not more than 5 cm (two inches) across.
T3:	Tumor is more than 5 cm across.
T4:	Tumor of any size growing into the chest wall or skin. This includes inflammatory breast cancer.
NEARBY LYMPH NODES (N) (based on looking at them under a microscope)	
NX:	Nearby lymph nodes cannot be assessed (for example, removed previously).
N0:	Cancer has not spread to nearby lymph nodes.
N1:	Cancer has spread to one to three axillary (underarm) lymph node(s), and/or tiny amounts of cancer are found in internal mammary lymph nodes (those near the breast bone) on sentinel lymph node biopsy.
N2:	Cancer has spread to four to nine axillary lymph nodes under the arm, or cancer has enlarged the internal mammary lymph nodes.
N3:	One of the following applies: <ol style="list-style-type: none"> 1. Cancer has spread to 10 or more axillary lymph nodes. 2. Cancer has spread to the lymph nodes under the clavicle (collar bone). 3. Cancer has spread to the lymph nodes above the clavicle. 4. Cancer involves axillary lymph nodes and has enlarged the internal mammary lymph nodes. 5. Cancer involves four or more axillary lymph nodes, and tiny amounts of cancer are found in internal mammary lymph nodes on sentinel lymph node biopsy.
METASTASIS (M)	
MX:	Presence of distant spread (metastasis) cannot be assessed.
M0:	No distant spread.
M1:	Spread to distant organs is present. (The most common sites are bone, lung, brain, and liver.)

BREAST CANCER STAGING

Every cancer in the human body is assigned a particular stage. This stage number influences the type of treatment that a patient will receive to treat the cancer. The stage of a given cancer attempts to describe the overall presence and extent of that cancer in the body. The assigned staging number is dependent on a number of factors, including whether or not the cancer is invasive in nature, the size of the cancerous tumor, how many, if any, lymph nodes are involved, as well as whether or not the cancer has metastasized to other regions of the body.⁴ In short, staging is the process of determining how widespread a cancer is upon initial diagnosis.

The staging system for cancers acts as a standardized way for the physician team to generalize information about how far a given cancer has spread within the body once diagnosed.⁴ In society today, the most common staging system

is the American Joint Committee on Cancer (AJCC) Tumor Nodal Metastasis (TNM) system.⁴

The stage of a breast cancer can be based either on the results of a physical exam, biopsy, and imaging tests (called

The stage of a breast cancer can be based either on the results of physical exam, biopsy, and imaging tests (called the clinical stage), or on the results of these tests plus the results of surgery (called the pathologic stage).⁴

the clinical stage), or on the results of these tests plus the results of surgery (called the pathologic stage).⁴ The most common type of cancer staging done in the medical community today is the pathological staging. Pathological staging includes the results of a lumpectomy, where a pathologist has studied samples of the removed breast tissue. The process of pathologic staging proves to be more accurate due to the fact that it provides the physician with the knowledge of the extent of spread of a given cancer.

The TNM staging system classifies the various types of cancers based on the stages of T, the size of the tumor, as well as how far the tumor has spread to nearby anatomical structures; N, the spread of the cancer to the nearby lymph nodes; and M, the level of cancer metastasis to distant organs and structures.

Additional letters and numbers are often seen following the TNM classification. These numbers and letters lend further information regarding the cancer's spread, size and lymphatic association of the cancer. The letter T is typically followed by a number ranging anywhere from zero to four. These numbers describe the size of the tumor, as well as the level of spread to the skin or the chest wall. The higher T numbers describe a larger tumor or a wider spread to tissues surrounding the breast tissue.⁴ In addition, the letter N is typically trailed by a number ranging from zero to three. These numbers indicate the degree of cancer spread, if any, to the surrounding lymph nodes and if so, how many lymph nodes are affected. Finally, the letter M is followed by either number zero or one. These numbers indicate whether or not the cancer has metastasized to distant organs or anatomical structures.

Table 1. is taken directly from the American Cancer Society's Web site, and further illustrates the complexity of breast cancer staging that is used in the medical society of today.

BREAST CANCER STAGE GROUPING

Once the breast cancer has been staged by a physician with the TNM system, the results are further compiled and combined in a process referred to as stage grouping. Cancers with similar stages tend to have

a similar outlook and thus are often treated in a similar way.⁴ The stage of the diagnosed breast cancer is typically expressed through the use of Roman numerals and varies from stage I, or the least advanced stage of breast cancer, to stage IV, the most advanced stage of breast cancer. A stage of zero refers to a non-invasive cancer.

Table 2. (below), derived directly from the American Cancer Society's Web site (www.cancer.org), refers to the overall survival rates of treated breast cancers and their respective stages.

Stage	5-year Relative Survival Rate
0	100%
I	100%
II	86%
III	57%
IV	20%

DIAGNOSTIC STUDY OF BREAST CANCER

Breast cancers can be diagnosed through a number of means. Typically, breast masses are felt by palpation, or touch, by either the patient or the health care provider during a routine breast examination. If a breast mass is found, a patient will typically undergo a mammogram study that includes both breasts. The mammogram enables the visualization of dense areas of breast tissues that can diagnose either a malignant or a benign breast mass. Additionally, the mass is usually biopsied to determine whether or not the mass is benign or malignant.

If a malignant mass or masses are found within the breast, a physician may further suggest certain imaging tests such as X-rays, bone scans, CT scans, PET scans or MRI scans in an attempt to help aid in the staging of the cancer, as well as the level, if any, of cancer metastasis. Finally, blood tests and white blood cell counts may be performed on the patient in an attempt to evaluate the overall health of the patient as well as to rule out the complexity of cancer spread.

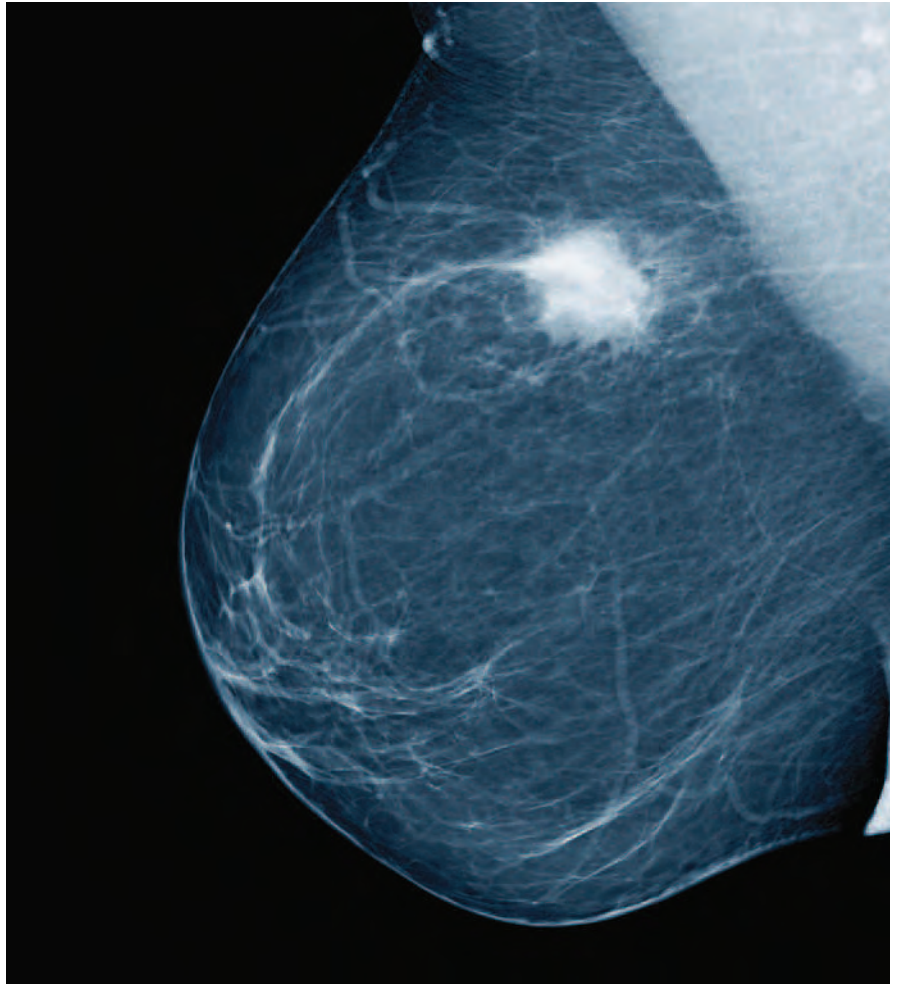
TREATMENT OF BREAST CANCERS

Although there has been a noticeable increase in the number of women being affected by breast cancer, there has additionally been an increase in the number of treatment options available to combat the potentially lethal pathology. Today, rather than only one or two options of treatment, a patient diagnosed with breast cancer can opt for a complex mix of treatment options that fight the complex nature of each individual's breast cancer. A patient can choose from an assortment of surgical treatments, radiation therapy, hormonal therapy and even chemotherapy, or can choose, with the guidance of her health care provider, to attempt a combination of treatment methods to overcome the debilitating cancer.

Surgical treatment of breast cancer is typically the first line of treatment for a patient suffering from breast cancer. Treatments can range anywhere from a lumpectomy to a total bilateral mastectomy. Lumpectomy, also known as breast-conserving surgery, refers to the removal of only the tumor and a small amount of surrounding tissue.⁵ In contrast, a mastectomy is the removal of all of the breast tissue.⁵ Today, mastectomy surgery is more refined and less intrusive than what the procedure entailed in the past. A typical mastectomy spares the muscles located below the breast unless there has been known cancer metastasis to the area. With both surgical treatments, the patient can additionally choose to have the axillary lymph nodes removed in an attempt to determine whether the aggressive breast cancers have spread into the nearby lymphatic system.

In a less invasive lumpectomy procedure, also known as needle localization and wide excision, a radiologist uses a live mammogram to localize a cancerous area in the breast and then inserts a needle into the cancerous tissue. Following the needle localization, the patient is taken to the operating room, with the needle still in place. During the wide excision portion of the procedure, the needle acts as a locator guide for a surgeon to excise all of the cancerous

mass from the breast tissue.⁶ In contrast to a mastectomy, a lumpectomy, or needle localization with wide excision, only removes a small volume of breast tissue and thus conserves the relevant anatomy of the breast.⁶



MASTECTOMY

Mastectomy is the medical term for the surgical removal of one or both of the breasts of either a male or a female patient. One or both of the breasts can be partially or completely removed with a mastectomy surgical procedure. Due to the invasive nature of the surgical intervention and the selected means of tissue removal, a mastectomy is considered to be a local therapy when compared to systemic therapies such as chemotherapy, immunotherapy and hormone therapy.⁵ Currently, mastectomies are the surgery of choice for both the prophylactic and the therapeutic treatment of all known breast cancers.⁷ A mastectomy is not always the most suitable treatment, but in many cases it has proved to be very effective in treating breast cancer.

Although breast cancers are more prevalent in female patients, males can also suffer from the debilitating cancer and thus are also candidates for this procedure.

In the past, it was commonplace in the case of breast cancer to perform a radical mastectomy and remove all of the breast tissues, as well as the underlying musculature and lymphatic drainage system.⁷ There are current changes, however, in today's medical arena in which the election to perform a mastectomy versus a lumpectomy is now based on a number of patient-related factors, such as the size of the patient's breast, the number of cancerous lesions located within the breast tissue, the overall aggressiveness of the diagnosed breast cancer, as well as patient preference. Outcome studies comparing mastectomy to lumpectomy with radiation have suggested that routine radical mastectomy surgeries will not always prevent later distant secondary tumors arising from micro-metastases prior to discovery, diagnosis, and operation.⁵

TYPES OF MASTECTOMY

There are a variety of types of mastectomy procedures being performed in today's medical community. The type that a patient decides to undergo depends on factors such as size, location, and behavior of the tumor, whether or not the surgery is prophylactic, and whether or not the patient intends to undergo reconstructive surgery following the mastectomy.⁷

A simple mastectomy, also referred to as a total mastectomy, involves the complete surgical removal of the entire breast tissue. The axillary components, however, are left in place. Additionally, this surgery is sometimes done bilaterally as a prophylactic measure on patients who wish to undergo mastectomy as a cancer-preventative measure.⁷

A modified radical mastectomy is an alternative type of mastectomy procedure. When a modified radical mastectomy is performed, the entire affected breast is removed along with the axillary lymph nodes and axillary fat.⁷ When compared to a modified radical mastectomy, the pectoralis muscles are left in their proper anatomical location during the modified procedure.

Conversely, a radical mastectomy, sometimes referred to as a "Halstead Mastectomy," involves the surgical removal of all of the breast tissue, the axillary components as well as the pectoralis major and the pectoralis minor muscles

of the chest wall.⁷ This procedure is the most invasive and disfiguring mastectomy procedure due to the fact that the patient is left with a large portion of his or her chest removed for the treatment of cancer. Although this type of mastectomy was performed very often in the past, it has since been replaced with the more modified version of the radical mastectomy. The complete radical mastectomy is typically only performed in today's medical community in extreme cases of breast cancer metastasis that involves the pectoralis muscles.⁷

Mastectomy procedures of today are being further modified to be as minimally-invasive as possible, as well as to provide the patient with some degree of normalcy following the disfiguring surgical procedure. One such modification being performed today is a skin-sparing mastectomy. In this surgery, a conservative areolar incision is made to accommodate the separation of the breast tissue from the overlying skin.⁷ This type of mastectomy provides a large pocket of skin that facilitates a breast reconstructive procedure following the mastectomy. As long as the breast tissue is completely separated from the dermis of the skin, the skin can be left without any incurrance of cancer metastasis. Patients with cancers that involve the skin, however, are not considered to be candidates for skin-sparing mastectomy.⁷

Today, rather than only one or two options of treatment, a patient diagnosed with breast cancer can opt for a complex mix of treatment options that fight the complex nature of each individual's breast cancer.

Similar to a skin-sparing modification of the mastectomy procedure, a subcutaneous mastectomy can be performed in an attempt to preserve the nipple and areola of the patient.

These skin-sparing mastectomies and subcutaneous mastectomies are ideal for patients undergoing prophylactic mastectomies, as well as for patients who wish to undergo an immediate breast reconstructive procedure following the removal of the breast tissue.⁷ The benefit of these procedures is that more of the breast skin envelope is preserved to make it easier to recreate the normal anatomical shape of the breast and aids in the psychology of the disfiguring aspect of the mastectomy procedure.

MASTECTOMY INDICATIONS

A patient is recommended to undergo a mastectomy in a number of instances. Some of these specific groups of patients include a patient who has had radiation therapy to the affected breast, a patient suffering from a cancer that is in two or more isolated locations within a single breast, or a patient in whom a lumpectomy failed to completely remove all of the cancerous cells and a cancer recurrence has occurred.⁸ A mastectomy is additionally recommend-

The election to perform a mastectomy versus a lumpectomy is now based on a number of patient-related factors, such as the size of the breast, the number of cancerous lesions in the breast tissue, the aggressiveness of the cancer, as well as patient preference.

ed to a pregnant patient who cannot undergo radiation or chemotherapy due to the potential of harming the fetus, patients who have cancerous breast masses larger than two inches in size or, as a prophylactic measure, for patients who have proved to be genetically positive for the BRCA 1 or BRCA 2 gene mutations.⁸ Finally, mastectomies are normally indicated for male patients who are diagnosed with breast cancer.

CASE STUDY

The following will investigate a case study of a female patient who had been diagnosed with stage II cancer of the right breast. The patient was a 45-year old Hispanic female. This female patient had a family history of breast cancer and thus had been undergoing mammography visualization of the breast for five years prior to her diagnosis of breast cancer.

In February 2009, a medium-sized mass was felt by the patient during a breast self-exam, and a mammogram was ordered. The mammogram revealed a medium-sized mass confined to the right breast. Additionally, blood samples and an MRI were taken to attempt to determine if the mass was cancerous. Both the MRI and the blood sampling were inconclusive as to whether or not the mass was cancerous and thus, the patient was scheduled for a lumpectomy with sentinel node biopsy. Following the procedure, the mass was removed *en bloc*, and the sentinel node biopsied. Both specimens were sent to pathology. The breast mass was found

to be level II cancer, however, the sentinel lymph node was void of cancer and thus it was determined that the cancer was confined specifically to the breast and had not metastasized to surrounding tissue types.

This patient chose a total, bilateral mastectomy as a means to stop the spread of the aggressive cancer in the right breast, as well as to totally remove the breast tissue of the left breast as a prophylactic measure. After extensive genetic testing due to the patient's family history of breast

cancer, it was found that the patient was positive for the breast cancer BRAC1 and BRAC2 gene mutations following a complete genetic analysis.

PREOPERATIVE PROCEDURE

The patient is placed in the supine position with both arms extended on arm boards. All of the patient's bony prominences are padded and the feet

are placed in padded anti-embolitic compression booties. The anti-embolitic booties both protect the calcaneus, as well as help to aid in venous return to the legs and the prevention of blood clot formation.

A large minor surgical instrumentation set is used for the procedure. Equipment that is needed for a bilateral modified total radical mastectomy includes the following: an electrosurgical pencil with a plume evacuator, attached to the electrosurgical pencil and the suction apparatus. The plume evacuator allows for the removal of the smoke plume that is created through the use of the electrosurgical pencil. Additionally, a Bair Hugger™ warming unit is applied to the patient and a fluid warmer is utilized throughout the procedure to maintain proper body temperature.

In this particular case, the patient had been receiving chemotherapy and radiation therapy prior to the mastectomy surgery, so extra care was taken by the operating room personnel to keep the patient warm. Additionally, care was taken to prevent bruising on areas of the body where bruising could have occurred (padding across the legs where the safety strap was applied, padding around the anti-embolitic hose, etc). Warm blankets were placed over the patient's arms and legs to aid in temperature regulation following the induction of general anesthesia, and a plastic bag was placed over the patient's head after the introduction of the endotracheal tube.

The patient's skin is cleansed with a betadine soap solution and sponges. The soap solution is then allowed to sit on

the skin for five minutes before being wiped off. The umbilicus is cleaned first. The prep starts at each nipple and then the solution is applied in a circular motion, extending outward to the boundaries of the prep area. Once the soap prep is wiped off of the patient's skin, the surgical region is prepped with DuraPrep™ solution. The skin is prepped from the patient's chin to the iliac crest and as far laterally as possible.

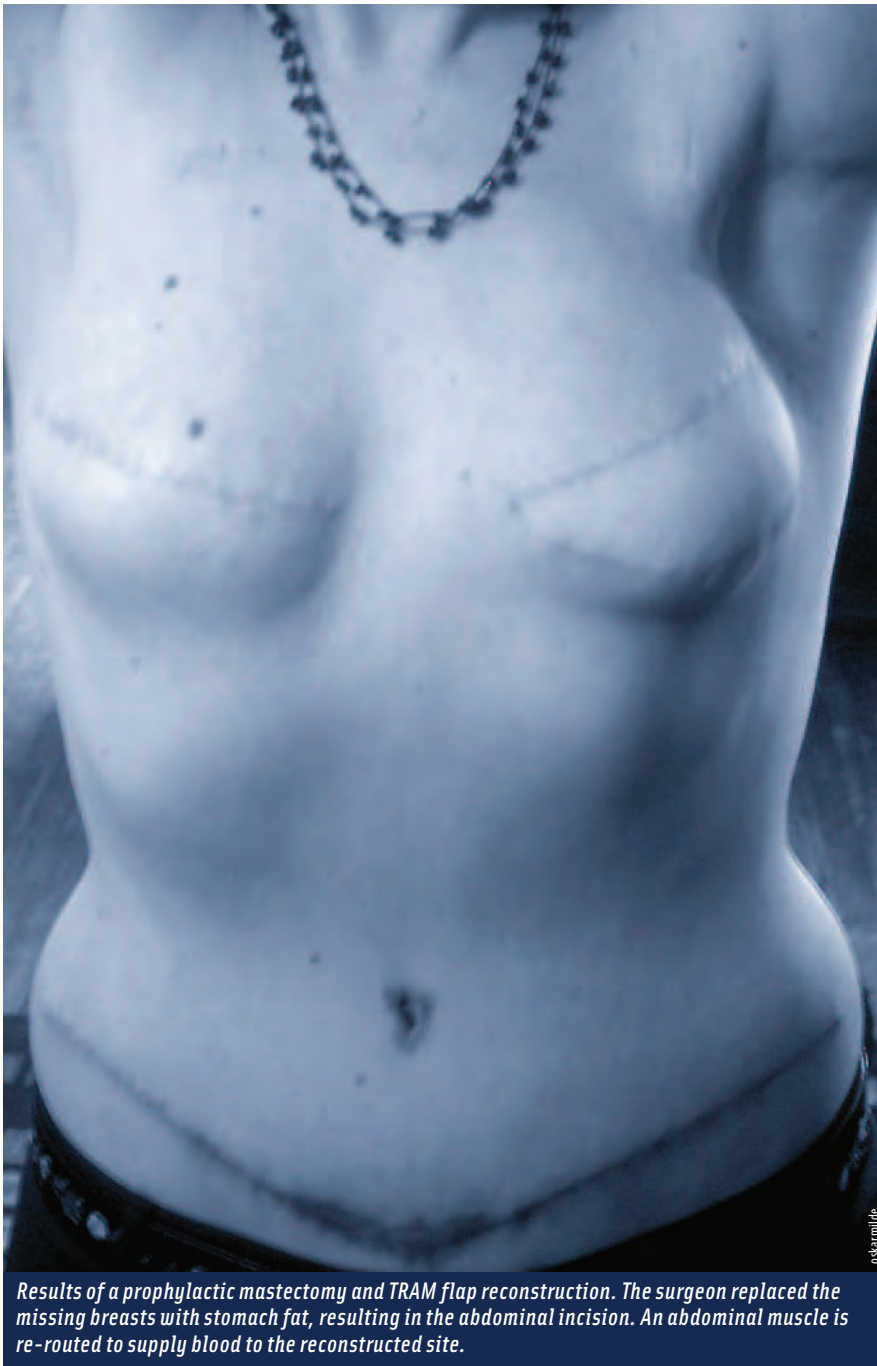In order to drape the surgical area, both of the patient's breasts are outlined with four sterile towels (eight towels

total). Following the placement of the sterile towels to outline the incisional areas, a sterile, adhesive laparotomy drape is applied over the breast region of the patient. The drape sheet is extended caudally and handed to the anesthesiologist. It is then extended toward the feet of the patient, creating a sterile field. Following the application of the sterile drapes and the creation of a sterile field, the suction tubing, light handles and ESU surgical pencil are positioned on the sterile field by the surgical technologist in the scrub role.

Prior to the skin incision, a time-out is performed, when the patient's name, procedure, position, allergies and approach are all stated and agreed upon by participating members of the surgical team. The surgeon is then passed a sterile 10 cc syringe and an 18-gauge needle. The circulating nurse provides an ampule of methylene blue, from which the surgeon draws up 10 cc of the dye. The surgeon is then passed a sterile, 25-gauge needle. The surgeon uses the syringe and hypodermic needle to inject methylene blue dye into the areolar space and nipple of the patient's affected breast. The dye is taken up by the lymphatic duct system of the breast and outlines the sentinel node.

Once the methylene blue has been injected into the areolar area, 10 ml on a 25 gauge needle of 0.5 percent bupivacaine is passed to the surgeon by the surgical technologist. The drug is in a 10 cc syringe, capped with a 25-gauge hypodermic needle. It is administered for local pain control to the skin and musculature surrounding the intended areolar incision locations.

After the injection of the drugs, a #15 blade, loaded onto a #3 knife handle, is passed to the surgeon. The surgeon creates an areolar incision, which is carried circumferentially around the entire areola. The knife is then passed back to the surgical technologist, who places it on the sterile Mayo stand. The electro-surgical pencil, with suc-



Results of a prophylactic mastectomy and TRAM flap reconstruction. The surgeon replaced the missing breasts with stomach fat, resulting in the abdominal incision. An abdominal muscle is re-routed to supply blood to the reconstructed site.

tion attached, is passed to the surgeon. The surgeon uses the electro-surgical pencil to dissect the breast tissue away from the overlying skin extending from the areola down to the fascia of the pectoralis minor muscle. As the dissection is carried deeper into the patient, the surgical technologist anticipates the need of X-ray-detectable sponges, clamps, retractors and pick-ups.

Once the pectoralis muscle is reached, the dissection is then carried laterally to dissect out the sentinel node of the lymphatic system. All breast tissue, with the sentinel lobe attached, is separated from the skin, lymphatic system and underlying musculature. After the complete dissection is complete, the electro-surgical pencil is handed safely back to the surgical technologist, who cleans the tip and places it back into the holster to prevent burns to the patient.

Breast cancer is the most common cancer that affects American women today. Additionally, it is the leading cause of death in women ages 40–44 years of age, and is the second most common killer of all ages after lung cancer.³

Once the breast tissue has been dissected, the tissue is removed through the areolar area and handed to the surgical technologist. The surgical technologist labels the specimen on a piece of sterile towel and hands it off to the circulating nurse. The nurse then labels the specimen and immediately takes it to pathology. As the surgery continues, the pathology department personnel examine the sentinel node under the microscope to see if the cancer has metastasized to the lateral margins of the breast. Once the specimen has been carefully examined under the microscope, the pathology department calls the operating room to let the surgeon know if the lateral margins of the breast, as well as the lymphatic system, are indeed clear of the aggressive breast cancer.

In this particular case, the lateral margins of the breast and the lymphatic system showed no signs of the aggressive cancer.

Once the breast specimen is removed, a new #15 blade, loaded onto a #3 knife handle, is handed to the surgeon, who uses it to make a three-inch incision into the fascia between the pectoralis minor and the pectoralis major muscles. Once the incision is made, the patient's original

saline implant is removed by the surgeon and handed to the surgical technologist. The surgical technologist hands the specimen off of the field to the circulator, who places it in a bucket and correctly identifies and labels it. The surgeon then uses the electro-surgical pencil to further open the capsule that has been created by the saline implant. Additional remaining breast tissue is removed and hemostasis is achieved. At the completion of the mastectomy, the wound is irrigated with sterile water to prevent cancer seeding.

All instruments from this point on are considered contaminated as a result of the cancer. A clean set-up is already prepared prior to this portion of the procedure and is utilized for the remaining portions of the procedure on the right, once-cancerous breast. AlloDerm®, a collagen matrix that preserves all the elements necessary for revascular-

ization and cellular repopulation, is placed into the pocket created by the implant/dissection, located within the muscle layers. The material is first soaked in sterile saline for five minutes before it is transferred to another kidney basin full of saline for another five minutes prior to passing to the plastic surgeon. It is then cut to size and placed into the pocket. Non-

absorbable sutures are used to keep the graft in place.

Following the insertion of the AlloDerm® into the pocket to create a posterior border to the breast pocket, a sterile tissue expander is passed to the plastic surgeon and placed into the newly-created pocket. A butterfly needle is passed to the surgeon and attached to a sterile, infusible IV tube, attached to a pressurized IV infuser filled with warm saline. The surgeon inserts the butterfly needle into the port on the tissue expander, inflating the tissue expander with 540 cc of warm, sterile saline.

For closure, two Jackson-Pratt drains are placed from the muscle pocket to the outside of the body. A 3-0 silk suture is utilized to keep the drains secured in place to the skin. Additionally, absorbable 3-0 polyglactin sutures are passed to the surgeon on a Mayo-Hegar needle holder along with toothed forceps. The sutures are used to close the muscle pocket. Finally, a skin stapler and two Adson, toothed forceps are used to close the areolar incision in a longitudinal fashion.

Following the closure of the right breast, a different, clean set-up is used to carry out the same procedure on the left breast. The sentinel lobe is not removed from the left

side because there is no evidence of cancer present. Only one drain is placed on the left side, which is considered “clean,” due to the fact that it is cancer free. Once the left breast incision is closed with staples, 3-0 undyed polyglactone 25 suture is passed on a Crile-Wood needle holder to close the skin. The staples are removed as individual mattress sutures are placed, and then a continuous running suture is placed to close the skin incisions on both sides. Straight Mayo scissors are used to cut the suture edges.

After complete closure on both sides, one-inch wound-closure strips are applied over the incisional area. A wet towel is used to clean the breast and abdominal areas, followed by a dry towel to dry the breast and abdominal area. Two sterile, abdominal pads are placed over the skin incision site, the drapes are removed and the ABD pads are secured with a bandeau-style wrap. Finally, the patient is taken off of anesthesia and extubated. Following extubation, the patient is transported to the post-anesthesia care unit.

Complications of the total bilateral modified radical mastectomy include bleeding, infection, reactions to anesthesia, adhesion formations, thrombi or emboli formation, cancer metastasis, psychological disfigurement problems and death. Additionally, the patient undergoing a radical mastectomy may additionally suffer from phantom breast pain, swelling of the breast area and the possibility of seroma formation. Complications to the tissue expanders include, but are not limited to, infection, bleeding, rupture of implants, dimpling of the skin as well as visualization impedance during follow-up return mammograms.

The advantage to immediate breast reconstruction, as this particular patient opted for, include not waking up to the trauma of losing the anatomical look of the breasts and eliminating the need for additional reconstructive surgery.

ABOUT THE AUTHOR

Brittany Stapp-Caudell is working as a surgical technologist at Community Regional Medical Center in Fresno, California. She graduated from the surgical technology program at San Joaquin Valley College in Fresno, in September 2009, and is currently awaiting the results of her certification examination.



References

1. Drake. *Gray's Anatomy for Students*. Elsevier Churchill Livingstone. Spain. 2005.
2. Cohen B. Memmler's *The Human Body in Health and Disease*. Lippincott Williams & Wilkins. USA. 2005.
3. Huether, McCance. *Understanding Pathophysiology*. Mosby. St Louis. 2008.
4. American Cancer Society. 2009. Accessed: April 25, 2009. Available at: <http://www.cancer.org/docroot/home/index.asp>
5. Frazier. D. (2008). 'Breast cancer' breastcancer.org. Retrieved April 24, 2009, from breastcancer.org
6. Medline Plus. *Mastectomy*. 2009. Accessed: April 25, 2009. Available at: <http://www.nlm.nih.gov/medlineplus/mastectomy.html>
7. eMedicineHealth. *Mastectomy*. 2009. Accessed: April 27, 2009. Available at: http://www.emedicinehealth.com/mastectomy/article_em.htm
8. Mastectomy. 2007. Accessed April 24, 2009. Available at: <http://en.wikipedia.org/wiki/Mastectomy>

Additional Resources

eMedicineHealth.com. *Mastectomy*. 2009. Available at: http://www.emedicinehealth.com/mastectomy/article_em.htm


Imaginis.com. *Mastectomy*. 2009. Available at: <http://www.imaginis.com/breasthealth/mastectomy.asp>

Breastcancer.org. *Stages of Breast Cancer*. 2009. Available at: <http://www.breastcancer.org/symptoms/diagnosis/staging.jsp>

AlloDerm is a trademark of LifeCell Corp.

Bair Hugger is a trademark of Arizant Inc.

DuraPrep is a trademark of 3M.



Earn CE Credits at Home

You will be awarded continuing education (CE) credit(s) for recertification after reading the designated article and completing the exam with a score of 70% or better.

If you are a current AST member and are certified, credit earned through completion of the CE exam will automatically be recorded in your file—you do not have to submit a CE reporting form. A printout of all the CE credits you have earned, including Journal CE credits, will be mailed to you in the first quarter following the end of the calendar year. You may check the status of your CE record with AST at any time.

If you are not an AST member or are not certified, you will be notified by mail when Journal credits are submitted, but your credits will not be recorded in AST's files.

Detach or photocopy the answer block, include your check or money order made payable to AST, and send it to Member Services, AST, 6 West Dry Creek Circle, Suite 200, Littleton, CO 80120-8031.

Note this exam awards three continuing education credits.
Members: \$18, nonmembers: \$30

Radical Mastectomy and Reconstruction

310 OCTOBER 2009 3 CE credits

1. **Breasts consist generally of _____.**
 - a. Secretory glands
 - b. Subcuticular fat
 - c. Overlying skin
 - d. All of the above
2. _____ **are modified sweat glands.**
 - a. Breasts
 - b. Mammary glands
 - c. Nipples
 - d. Superficial fascia
3. _____ **compose the suspensory ligaments of the breast.**
 - a. Connective tissue stroma
 - b. Individual ductal and lobule systems
 - c. Dermal tissues of the breast
 - d. None of the above
4. **The lateral arterial blood supply to the breast does not include the _____.**
 - a. Fourth intercostal artery
 - b. Thoracoacromial artery
 - c. Lateral thoracic artery
 - d. Superior thoracic axillary artery
5. **Nearly _____ percent of lymphatic drainage of the breast drains laterally and superiorly to the axillary lymph nodes.**
 - a. 65
 - b. 70
 - c. 75
 - d. 80
6. **The _____ are the primary region to sample for cancer metastasis into the lymphatic system.**
 - a. Parasternal lymph nodes
 - b. Axillary lymph nodes
 - c. Lymphatic vessels
 - d. Intercostal veins
7. **The mammary glands are completely functional at _____.**
 - a. Puberty
 - b. The end of pregnancy
 - c. Birth
 - d. Conception
8. **hPL is a hormone given off by the _____.**
 - a. Placenta
 - b. Pituitary gland
 - c. Secretory glands
 - d. None of the above
9. _____ **is the leading cause of death in women aged 40-44.**
 - a. Heart disease
 - b. Lung cancer
 - c. Breast Cancer
 - d. None of the above
10. **The risk of developing breast cancer is related to _____.**
 - a. Age when first child is born
 - b. Genetic factors
 - c. Family history
 - d. All of the above

RADICAL MASTECTOMY AND RECONSTRUCTION PART 1 OF 3 310 OCTOBER 2009 3 CE credits

Certified Member Certified Nonmember

My address has changed. The address below is the new address.

Certification No. _____

Name _____

Address _____

City _____ State _____ Zip _____

Telephone _____

	a	b	c	d		a	b	c	d
1	<input type="checkbox"/>	<input type="checkbox"/>	<input type="checkbox"/>	<input type="checkbox"/>	6	<input type="checkbox"/>	<input type="checkbox"/>	<input type="checkbox"/>	<input type="checkbox"/>
2	<input type="checkbox"/>	<input type="checkbox"/>	<input type="checkbox"/>	<input type="checkbox"/>	7	<input type="checkbox"/>	<input type="checkbox"/>	<input type="checkbox"/>	<input type="checkbox"/>
3	<input type="checkbox"/>	<input type="checkbox"/>	<input type="checkbox"/>	<input type="checkbox"/>	8	<input type="checkbox"/>	<input type="checkbox"/>	<input type="checkbox"/>	<input type="checkbox"/>
4	<input type="checkbox"/>	<input type="checkbox"/>	<input type="checkbox"/>	<input type="checkbox"/>	9	<input type="checkbox"/>	<input type="checkbox"/>	<input type="checkbox"/>	<input type="checkbox"/>
5	<input type="checkbox"/>	<input type="checkbox"/>	<input type="checkbox"/>	<input type="checkbox"/>	10	<input type="checkbox"/>	<input type="checkbox"/>	<input type="checkbox"/>	<input type="checkbox"/>

Mark one box next to each number. Only one correct or best answer can be selected for each question.

11. _____ stimulates the secretory cells for lactation.
- Placental lactogen
 - Prolactin
 - Oxytocin
 - B & C
12. Breast cancers account for _____ percent of all cancers in women and _____ percent of cancer deaths.
- 30, 16
 - 43, 30
 - 16, 30
 - 43, 16
13. _____ provides a standardized way for physicians to determine information about a cancer's metastasis.
- Staging
 - Mammogram
 - Lumpectomy
 - None of the above
14. The most common staging system is the _____.
- Mammogram
 - Lumpectomy
 - Tumor Nodal Metastasis
 - None of the above
15. Pathological staging includes the results of a _____.
- Mammogram
 - Lumpectomy
 - Tumor Nodal Metastasis
 - All of the above
16. Patients have many treatment options, including _____.
- Radiation therapy
 - Chemotherapy
 - Hormonal therapy
 - All of the above
17. In TNM classification, the number following a T indicates _____.
- Size of the tumor
 - If the cancer has metastasized
 - If the cancer has spread to the lymph nodes
 - All of the above
18. _____ is considered a "breast-conserving surgery."
- Mastectomy
 - Breast reconstruction
 - Needle localization and wide excision
 - B & C
19. In a _____, the surgeon removes a small volume of breast tissue.
- Mastectomy
 - Breast reconst.
 - Lumpectomy
 - B & C
20. Removal of one or both breasts in a male or female patient is a _____.
- Mastectomy
 - Breast reconstruction
 - Lumpectomy
 - Needle localization and wide excision

RADICAL MASTECTOMY AND RECONSTRUCTION PART 2 OF 3

	a	b	c	d		a	b	c	d
11	<input type="checkbox"/>	<input type="checkbox"/>	<input type="checkbox"/>	<input type="checkbox"/>	16	<input type="checkbox"/>	<input type="checkbox"/>	<input type="checkbox"/>	<input type="checkbox"/>
12	<input type="checkbox"/>	<input type="checkbox"/>	<input type="checkbox"/>	<input type="checkbox"/>	17	<input type="checkbox"/>	<input type="checkbox"/>	<input type="checkbox"/>	<input type="checkbox"/>
13	<input type="checkbox"/>	<input type="checkbox"/>	<input type="checkbox"/>	<input type="checkbox"/>	18	<input type="checkbox"/>	<input type="checkbox"/>	<input type="checkbox"/>	<input type="checkbox"/>
14	<input type="checkbox"/>	<input type="checkbox"/>	<input type="checkbox"/>	<input type="checkbox"/>	19	<input type="checkbox"/>	<input type="checkbox"/>	<input type="checkbox"/>	<input type="checkbox"/>
15	<input type="checkbox"/>	<input type="checkbox"/>	<input type="checkbox"/>	<input type="checkbox"/>	20	<input type="checkbox"/>	<input type="checkbox"/>	<input type="checkbox"/>	<input type="checkbox"/>

Mark one box next to each number.
Only one correct or best answer can be selected for each question.

21. An example of a minimally-invasive procedure is a _____.

- a. Simple mastectomy
- b. Skin-sparing mastectomy
- c. Halstead mastectomy
- d. A & B

22. Methylene blue is used during a mastectomy to _____.

- a. Sterilize the surgical site
- b. Provide local anesthetic
- c. Outline the sentinel node
- d. None of the above

23. The complete removal of the entire breast tissue is a _____.

- a. Simple mastectomy
- b. Radical mastectomy
- c. Modified radical mastectomy
- d. Halstead mastectomy

24. A/an _____ is used to separate the breast tissue from the skin.

- a. Electrosurgical pencil
- b. #15 blade
- c. Harmonic scalpel
- d. None of the above

25. In a TRAM flap reconstruction, the surgeon reconstructs the breasts with _____.

- a. Warm saline
- b. Autologous fat
- c. AlloDerm®
- d. Artificial fillers

26. Axillary components and the pectoralis muscles are removed in a _____.

- a. Simple mastectomy
- b. Radical mastectomy
- c. Modified radical mastectomy
- d. Bilateral mastectomy

27. To prevent cancer seeding, the wound is _____.

- a. Cauterized
- b. Closed with absorbable suture
- c. Irrigated with sterile water
- d. All of the above

28. Complications of a mastectomy include _____.

- a. Infection
- b. Disfigurement
- c. Cancer metastasis
- d. All of the above

29. In a modified radical mastectomy, _____ are removed.

- a. Only axillary components
- b. Axillary components & pectoralis muscles
- c. Both breasts, in their entirety
- d. Only suspicious lumps

30. Specimens from mastectomy patients are examined _____ by the pathology department.

- a. Prior to scheduling surgery
- b. Intraoperatively
- c. Postoperatively
- d. At follow-up appointments

RADICAL MASTECTOMY AND RECONSTRUCTION PART 3 OF 3

	a	b	c	d		a	b	c	d
21	<input type="checkbox"/>	<input type="checkbox"/>	<input type="checkbox"/>	<input type="checkbox"/>	26	<input type="checkbox"/>	<input type="checkbox"/>	<input type="checkbox"/>	<input type="checkbox"/>
22	<input type="checkbox"/>	<input type="checkbox"/>	<input type="checkbox"/>	<input type="checkbox"/>	27	<input type="checkbox"/>	<input type="checkbox"/>	<input type="checkbox"/>	<input type="checkbox"/>
23	<input type="checkbox"/>	<input type="checkbox"/>	<input type="checkbox"/>	<input type="checkbox"/>	28	<input type="checkbox"/>	<input type="checkbox"/>	<input type="checkbox"/>	<input type="checkbox"/>
24	<input type="checkbox"/>	<input type="checkbox"/>	<input type="checkbox"/>	<input type="checkbox"/>	29	<input type="checkbox"/>	<input type="checkbox"/>	<input type="checkbox"/>	<input type="checkbox"/>
25	<input type="checkbox"/>	<input type="checkbox"/>	<input type="checkbox"/>	<input type="checkbox"/>	30	<input type="checkbox"/>	<input type="checkbox"/>	<input type="checkbox"/>	<input type="checkbox"/>

Mark one box next to each number. Only one correct or best answer can be selected for each question.