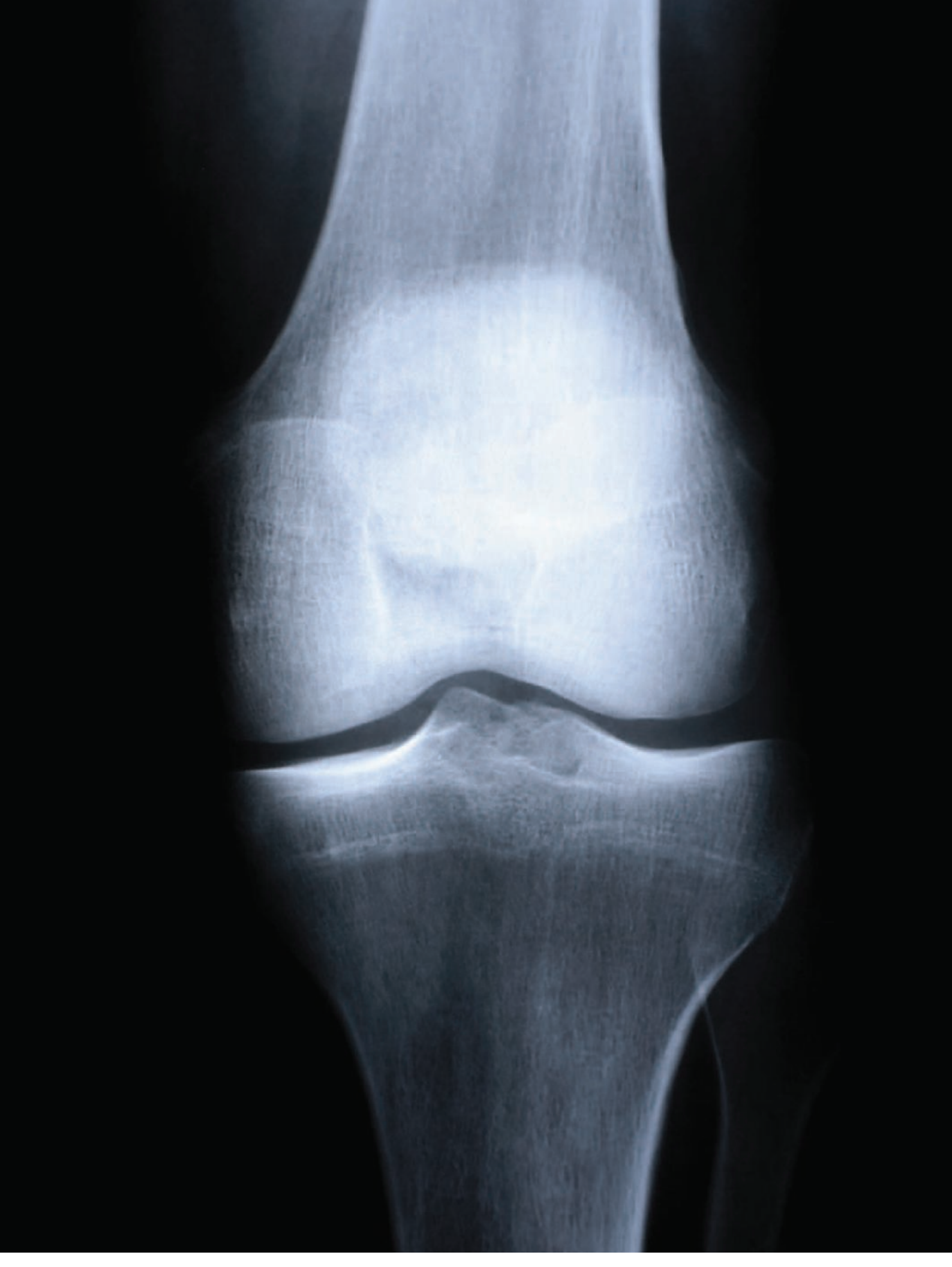

# Total Knee Arthroplasty

by Linda Bauer, CST

Total knee arthroplasty is one of the most extensive and technically difficult elective surgeries performed today. From the patient's point of view, the decision to have an important joint deliberately obliterated and replaced with manufactured components cannot be an easy one, and is further complicated by considering the potentially-devastating effects of a failed procedure.

**F**or the surgeon, knee replacement presents formidable technical challenges, as careful planning and precise execution are critical in providing the patient with full postoperative function. Planning and precision are central in the surgical technologist's role as well, as instrumentation for this procedure is extensive and highly specialized. The introduction of navigation systems to aid in knee replacement adds another level of complexity for the surgical team, a prospect that can be quite daunting for a new or inexperienced surgical technologist. This article will discuss computer-assisted total knee arthroplasty and present information to help surgical technologists participate effectively in this surgery.

The basic principles of total knee replacement are fairly straight forward. The knee is a hinge joint, in which the distal condylar surface of the femur articulates with the proximal surface of the tibia. This articulation is maintained by a system of strong ligaments, and the joint is protected by the patella bone, which is held in place by thick tendons. Injury, age and arthritic changes can contribute to deterioration of the joint surfaces, resulting in significant pain and loss of function. The surgery

## LEARNING OBJECTIVES

- ▲ Compare and Contrast the standard and navigation knee replacement systems
- ▲ Evaluate the benefits of the imageless navigation system
- ▲ Analyze the step-by-step process of the total knee procedure using an imageless navigation system
- ▲ Explore the history and development of the total knee procedure

involves the removal of the ends of the femur and tibia by means of a series of chamfered saw cuts, and the addition of artificial joint components to both bones, as well as to the inner surface of the patella.

The success of the total knee procedure depends on many factors, including patient selection, prosthesis design, the preoperative condition of the joint, surgical technique (including soft tissue balancing and limb alignment) and postoperative rehabilitation.

The success of the total knee procedure depends on many factors, including patient selection, prosthesis design, the preoperative condition of the joint, surgical technique (including soft tissue balancing and limb alignment) and postoperative rehabilitation.

#### HISTORY AND DEVELOPMENT

Total knee replacement has advanced considerably since the first attempts more than a century ago, when Theophilus Gluck designed and implanted a total knee made of ivory, stabilizing the implants with plaster of paris and colophony (a translucent, brittle substance produced from pine oleo resin, which is used in varnishes and inks).<sup>1</sup> Gluck's total knee failed for a variety of reasons, including poor bearing surface, improper fixation, and frequent infections. With many improvements, the Walldius hinge was introduced in 1951. Made of acrylic, and later upgraded to cobalt chromium (CO-CR) in 1958, this implant was used until the early 1970s. In 1968, Frank H Gunston, MD, a Canadian surgeon, designed the first polycentric knee.<sup>1</sup> Two basic flaws in his design limited its success: it did not replace all the condylar surfaces, and it had a small contact area. This polycentric knee was made of stainless steel and only replaced the weight-bearing part of the knee, which is not a true condylar knee. A narrow, polycentric metal replaced the weight-bearing part of the condyles, and the tibia was replaced with narrow, plastic runners. This allowed for minimal rota-

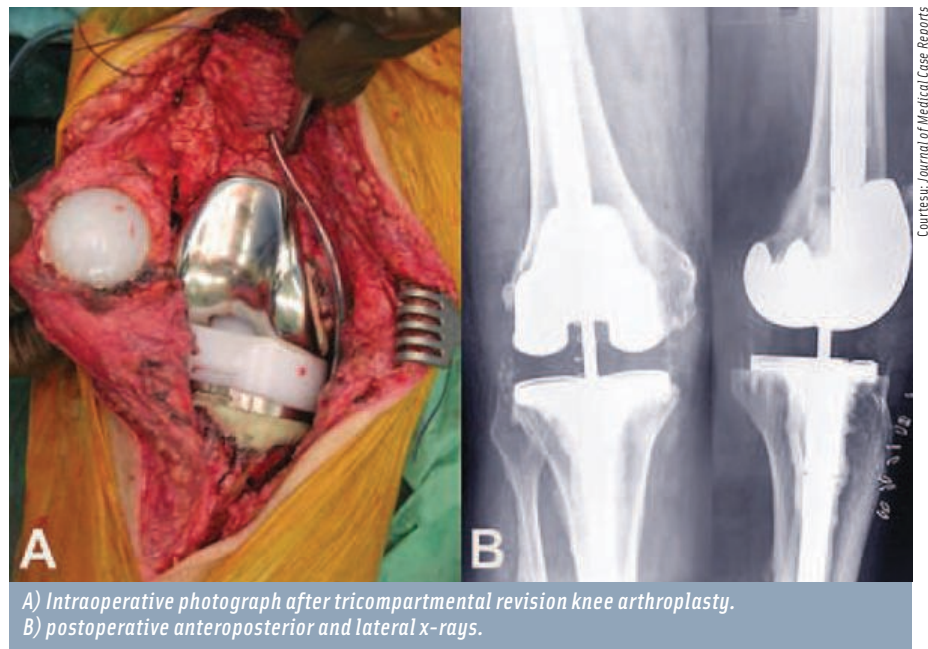
tion. Consequently, these components loosened after a while, which resulted in failure of this polycentric knee.

By the 1970s, the race was on to create the perfect condylar knee. Between 1970-73, three implants were developed independently.<sup>1</sup> In New York, Walker, Ranawet and Insall came up with their version. At the same time, Coventry and Turner introduced the geometric prosthesis, and Towley, from Huron, Mich, came up with the anatomic knee. There were two common threads that each of these

prostheses had. One was preserving the cruciates to ensure stability, and the other was using polymethylmethacrylate cement for fixation. The geometric knee had rotational constraint resulting in a high failure rate and was later discontinued. The anatomic knee replaced the troclear surfaces. This requires minimal removal of tibia and femur bone and allows the preserva-

tion of both cruciates. Failure occurred because of a thin tibia component and lack of fixation. As a result, the anatomic knee was also discontinued.

In 1971, Freeman and Swanson began using the Imperial College London Hospital (ICLH) knee.<sup>2</sup> It relied completely upon component geometry and soft-tissue balance to provide stability with both cruciate ligaments being sacrificed. This procedure was practiced until 1975. A study of complications and failures showed that an acceptable outcome



A) Intraoperative photograph after tricompartmental revision knee arthroplasty.  
B) postoperative anteroposterior and lateral x-rays.

Courtesy: Journal of Medical Case Reports

could not be achieved reliably. The tibial components tended to sink and loosen and patella pain was persistent and sometimes resulted in a patellectomy (removal of the patella bone).<sup>2</sup> In addition, the poly surface of the tibia showed surface damage, which was attributed to the cement being left in the posterior compartment of the knee. Last but not least, alignment of the knee and the control of instability could not be achieved accurately and reliably by the eye.<sup>2</sup>

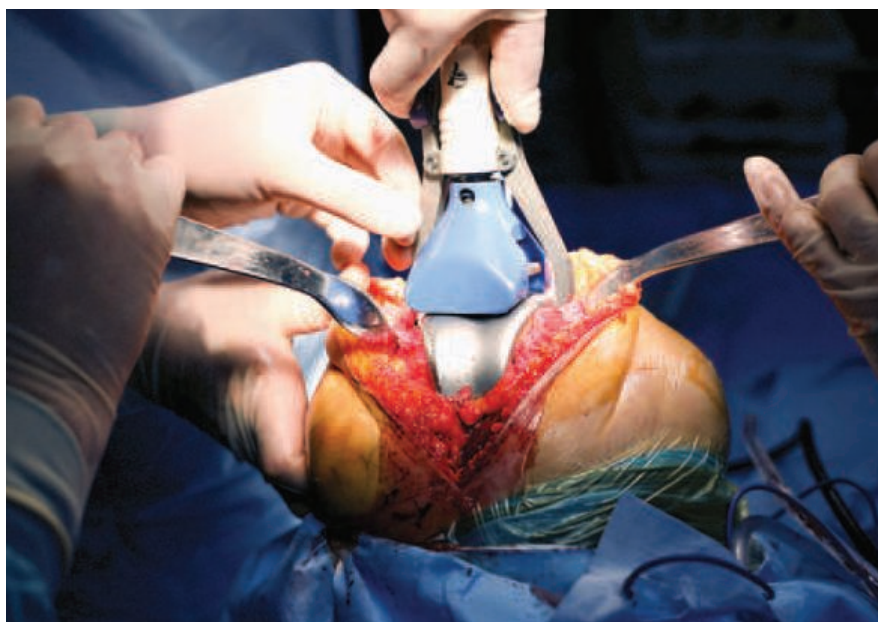
Over the next several years, many designs were attempted without success. Optimal material for the prosthesis had not been found, and stability could not be reliably maintained. In 1978, Johns Hopkins introduced the concept of universal instrumentation,<sup>1</sup> regardless of manufacturer. By the 1980s and 90s, most of the condylar designs incorporated universal instrumentation. Additional improvements in condylar design allowed better fixation with and without cement, reducing wear, enhanced kinematics and increased range of motion.<sup>1</sup>

### **SURGICAL NAVIGATION SYSTEMS**

Surgical navigation was developed to help reduce errors in component alignment during total knee arthroplasty<sup>3</sup> and to help surgeons install implants more accurately and reproducibly. Navigation systems also record quantitative information, such as joint range-of-motion, laxity, and kinematics, intraoperatively.<sup>3</sup>

Computer-assisted surgical systems have been developed for procedures such as total hip replacement, anterior cruciate ligament reconstruction, high tibial osteotomy, revision total knee arthroplasty, and many others. The earliest and most complex were active robotic systems, in which the robot performed surgical tasks, such as drilling, without the direct intervention of the surgeon.<sup>3</sup> This robotic system was not widely used because of the cost and complexity.

Semi-active systems do not perform surgical tasks, but may limit placement of surgical tools. With this system, the surgeon first indicates the desired position and orientation of the femoral prosthetic component on a three-dimensional digitizing template. The robot then positions the saw and drill guides so that the surgeon can make the necessary cuts and holes.<sup>3</sup>



The passive system receives information such as cut plane orientation and limb alignment that is displayed on a computer monitor in the operating room. Preoperative image systems rely on models derived from CT images, or by morphing a generic model to match the bony geometry of a particular patient.

This article focuses on the imageless navigation system by Stryker.

### **IMAGELESS NAVIGATION SYSTEMS**

Imageless systems collect information needed for navigation through direct measurement of bony landmarks, or through kinematic algorithms to determine joint centers.<sup>3</sup> Stryker entered the surgical navigation market in 2000, and introduced imageless navigation to orthopedics in 2001. The imageless system does not require preoperative CT or MRI scans. This navigation system is an interactive operative monitoring system designed to improve the surgical performance and clinical outcome of knee replacement surgery. As a PC-based imageless guidance system, the knee navigation system helps to facilitate improved decision-making for alignment and orientation of instruments, trials and implants as well as for balancing soft tissue.<sup>4</sup> It has an open platform, which means that it has dedicated instruments that are compatible with different implant systems. With the imageless system, the medical team can use either Articular Mounted Surface (ASM) or Precision 4.0. Precision 4.0 can be used in the manual implant sizing mode or the automatic implant sizing mode, according to surgeon preferences.

To implement the Stryker navigation system, the surgical team will need: a camera, trackers, pointer, cutting jigs and fixation pins.

Navigation systems have a few basic components. An optical tracking system measures the position and orientation of the trackers that are attached to the femur and tibia with bicortical screws or drill points. The pointer digitizes

Surgical navigation was developed to help reduce errors in component alignment during total knee arthroplasty<sup>3</sup> and to help surgeons install implants more accurately and reproducibly.

bony landmarks, monitored by a camera that is attached to the computer. The influence of navigation on the alignment is unclear. Surgical complications associated with navigation are very minimal. There is a chance of stress fractures from the tibial and femoral pin sites. Operating time increases slightly using navigation—usually by approximately 10-20 minutes. No long-term studies have proven that navigation improves postoperative functions, kinematics, allows for more rapid recovery or decreases complication rates. Debate exists on the utility of navigation,<sup>3</sup> but it can provide valuable feed back during surgery.

Instrumentation and equipment used in navigation is not very different from setting up a regular total knee. The surgical technologist will need all of the regular total knee instruments, omitting a few of the standard jigs and replacing them with the navigation jigs. Whether the surgeon uses ASM or Precision 4.0, determines when and where he or she will put in the fixation pins. This article focuses on Precision 4.0.

The first step is to register the trackers. Lithium batteries are placed into each of the trackers and the pointer. The trackers and pointer are then registered with the computer. This is accomplished by holding the tracker up to the computer and pressing the register button. Then, two Ortholock anchoring devices are placed on the femur and tibia. On the femur, the pins are positioned close to the knee joint. To minimize muscle load, pins are placed with the knee in flexion. On the tibia, the pins can be positioned distal to the tibial tubercle to avoid the patella tendon and collisions with the tibial implant. The Ortholocks will hold the femoral and tibial trackers.

Establishing a patient's mechanical axis is critical to a successful procedure. The mechanical axis runs from the center of the femoral head through the center of the knee, then through the center of the ankle. The mechanical axis is used to determine a patient's correct standing anatomy.

The position of the camera is very important. The camera is brought into alignment with the knee joint so that

all instruments are centered in the working volume, signified by the grey circles on the monitor. The femur is registered next. By digitizing femoral landmarks, the following axes and references are defined: mechanical femur axis, femoral rotation axis, reference for resection level and reference for notching. It is very important to find the hip center, because this is the gene-

sis of all subsequent points. Hip center is the first point that is mapped after determining a patient's mechanical axis, and is accomplished by slowly and smoothly rotating the hip.

Next, the pointer's tip is placed into the sulcus of the medial epicondyle and the pointer's select button is pressed, which registers those points. The pointer is then placed on the most prominent point of the lateral epicondyle and registered. Next, the pointer is placed at the center of the troclear sulcus, anterior toward the distal end of the femoral shaft to determine the femur center. This is essentially where one would place the intramedullary rod when using conventional instrumentation. Next, the pointer is aligned with the most posterior point of the trochlea and the most anterior point of the intercondylar fossa, also referred to as Whiteside's line, and the point is registered. The medial distal condyle is then digitized, along with the lateral distal condyle and anterior cortex. This completes registration of the femur. The next step is to register the tibia.

By digitizing tibial landmarks, the following axes and references are defined: mechanical tibia axis, tibial rotation axis and reference for resection level. The leg is flexed with a retractor being placed behind the tibia, to bring it into view. First, the tibia is registered center, followed by the tibial A/P axis. The pointer is placed midpoint, at the posterior cruciate ligament and the medial third of the tibial tuberosity. Then the medial and lateral compartments are digitized. It is important to determine the most prominent aspect of the medial malleolus and the most prominent aspect of the lateral malleolus and register these points. Upon completion of femur and tibia registration, the surgeon has established

a defined reference system. The digitized reference landmarks and axes are now used to assess the kinematics and calculate the alignment of instruments and bone cuts.

When the surgical procedure is finished, all of the procedure-related information can be saved in the computer. At the surgeon's request, the information can be transferred to a CD and printed on paper. Care of the navigation trackers is very important. They can only be wiped off with an enzymatic cleaner. They cannot be immersed in water. The navigation instruments can be cleaned in the usual manner. The trackers and the navigation instruments can be autoclaved so that they can be ready for the next procedure. The monitor should be wiped down with water and a sponge, as well as a disinfectant, after every case to remove any debris.

## CASE STUDY

### History

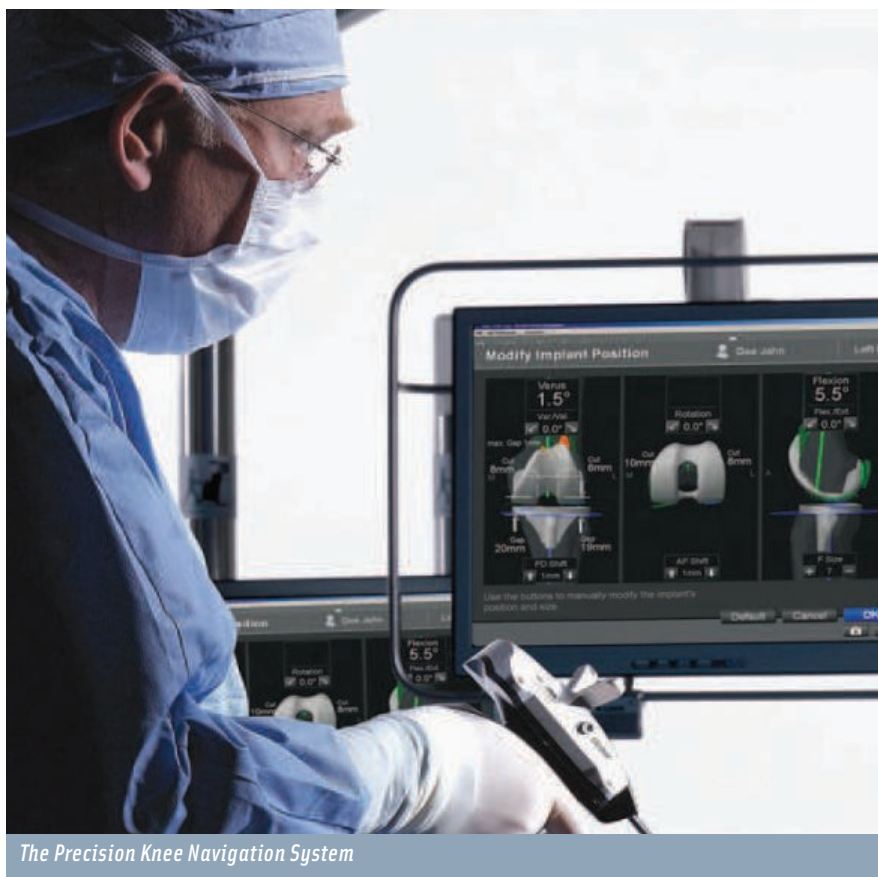The patient is a 53-year old female, who first went to her doctor in 2004, at the age of 46, due to an injury caused by a fall at her work place. She is a runner and very active. After examination, it is concluded that the patient does not have any mechanical symptoms of locking. She has a negative Lachman test and negative pivot shift. She was sent for an MRI, which showed a medial meniscal tear. X-rays show narrowing of the medial joint space, and probable chondromalacia with infusion. At the time of her initial appointment, the patient chose not to treat the tear, she was stable.

Over the next five years, she was treated with numerous steroid shots, due to pain in her knee. Then she was treated with a hyaluronate injection, which involved a series of three injections, two weeks apart. Subsequently, she experienced some relief. After six months, she repeated the hyaluronate injection protocol. In June 2009, she opted for a total knee replacement with 4.0 navigation.

### Procedure

After anesthesia is administered, a well-padded tourniquet is placed about the left upper extremity. The patient is prepped with an antimicrobial, antiseptic skin cleanser,

then painted with chlorhexidine gluconate solution and draped in the usual sterile fashion. The extremity is exsanguinated and the tourniquet is inflated to 300 psi, and deflated prior to wound closure. Pins are placed from lateral to medial in the femur and the tibia for navigation. The midline incision is made. Parapatellar arthrotomy is carried out, and in this case, a large amount of clear joint fluid emerged. The joint is exposed and registered with Stryker 4.0. This patient has a very thick, plain white synovial tissue throughout the knee. It is not in fronds, and is more membranous in nature. A synovectomy will be performed at the conclusion of the case.<sup>5</sup>



The Precision Knee Navigation System

Having registered the knee, the distal femur is resected 9mm from the high side. Rotation is centered on the average of the transverse epicondylar and A/P axis, which correlates with about three degrees external rotation relative to the posterior transcondylar axis. The patient is then shifted 1.5mm anterior so as not to notch her. Anterior and posterior beveled cuts thus created for a size four Triathlon knee. The tibia is subluxated, meniscal remnants are taken, and the posterior cruciate ligament is preserved. The tibia

is cut zero degrees mechanical axis rotation centered on the juncture of the medial middle third of the tibial tubercle with a four-degree posterior slope. The surgeon resects 1mm below the low point of the low side. Posterior osteophytes are removed. After a medial release, it is determined that the patient balances well with a 13mm insert. With full extension and flexion to 144, the knee is stable throughout a range of motion. The patella is then measured with a caliper. Osteotomy is created at the appropriate level, and resurfaced

Instrumentation and equipment used in navigation is not very different from setting up a regular total knee. The surgical technologist will need the regular total knee instruments, omitting a few of the standard jigs and replacing them with the navigation jigs.

with an asymmetric 9x29 patella. The trial components are removed and copious irrigation is carried out. Cement is packed into dried interstices of the bone and the components are placed. The Stryker Triathlon system is used: a size four femur CR (cruciate retaining), size four tibia, 13mm CR insert and an asymmetric 9x29 patella. Final kinematics are excellent—within one degree of the mechanical axis throughout the full range of motion—and the knee is stable. The tourniquet is deflated.<sup>5</sup>

In this case, the patella tracks well, and does not require lateral release. Copious irrigation is carried out. The wound is injected with a ropivacaine cocktail. A drain is placed in the depths of the wound. The arthrotomy is closed with #1 polyglactin 910, subcutaneous: #2-0 Polyglactin 910, skin running subcuticular poliglecaperone 25, followed by a topical skin adhesive. The patient is placed in a soft-tissue dressing and a cold-therapy unit, and returned to the recovery room in good condition.<sup>5</sup>

The patient spent three days in the hospital. After returning home, she underwent six-eight weeks of physical therapy, consisting of formal physical therapy two times a week, and continued the exercises on the off days. Seven weeks after surgery, the patient returned to work on light duty for two weeks, followed by two weeks of restricted light duty, meaning she could not lift more than 20 pounds. After that, she returned to full duty. After 11 weeks, the patient was doing well, continuing her exercises. The patient reported that after three months, it was the best thing she ever did.

One piece of advice that the patient strongly encourages others to follow is to take the full time off and follow the prescribed protocol exactly. The patient is a surgical technologist, working full time at a hospital in Austin, Texas.

## CONCLUSION

Future research and development of navigation systems should address three major challenges in total knee arthroplasty: ensuring consistent postoperative outcomes, treating

younger and more active patients, and enabling less invasive surgery.<sup>3</sup> Over the years, the medical field has seen the evolution of joint replacements. The procedures have improved from ivory implants being held in place with plaster of paris, to cobalt chromium (CO-CR) implants and a computer aiding the surgeon in getting just the right fit. The success of the total knee

still depends on many factors, including patient selection, preoperative conditions of the joint, and surgical technique. At the same time, it is such an exciting time for surgical technologists. There are so many exciting opportunities for learning new and more advanced procedures.


## ABOUT THE AUTHOR

Linda J Bauer has been a surgical technologist for 32 years, and has been a CST since 1992. She currently works at Seton Medical Center in Austin, Texas, where she is a lead tech and specializes in orthopedics.



## References

1. Ranawat C. *SOA Textbook*. "History of Total Knee Replacement." The Southern Orthopaedic Association and Data Trace Publishing Company. 2006.
2. Freeman MAR; Todd RC; Bamert P; Day WH. "ICLH Arthroplasty of the knee: 1968-1977" *The Journal of Bone and Joint Surgery*. 1978;60-B,3:339-344. Also available at: <http://www.jbjs.org.uk/cgi/reprint/60-B/3/339.pdf>.
3. Siston, Robert; Giori, Nicholas; Goodman, Stuart; Delp, Scott. "Surgical navigation for total knee arthroplasty: a perspective." *Journal of Biomechanics*. 2007;40:728-735. Also available at: [http://www.mecheng.osu.edu/nmbi/files/nmbi/JoB\\_2007\\_ASB\\_Award\\_Navigation\\_Perspective.pdf](http://www.mecheng.osu.edu/nmbi/files/nmbi/JoB_2007_ASB_Award_Navigation_Perspective.pdf).
4. Stryker Precision Knee Navigation. Stryker Leibinger GmbH. Available at: [http://www.stryker.com/stellent/groups/public/documents/web\\_prod/056838.pdf](http://www.stryker.com/stellent/groups/public/documents/web_prod/056838.pdf)
5. Carter, Shelby MD. Surgical notes. [www.shelbycartermd.com](http://www.shelbycartermd.com)



### Earn CE Credits at Home

You will be awarded continuing education (CE) credit(s) for recertification after reading the designated article and completing the exam with a score of 70% or better.

If you are a current AST member and are certified, credit earned through completion of the CE exam will automatically be recorded in your file—you do not have to submit a CE reporting form. A printout of all the CE credits you have earned, including Journal CE credits, will be mailed to you in the first quarter following the end of the calendar year. You may check the status of your CE record with AST at any time.

If you are not an AST member or are not certified, you will be notified by mail when Journal credits are submitted, but your credits will not be recorded in AST's files.

Detach or photocopy the answer block, include your check or money order made payable to AST, and send it to Member Services, AST, 6 West Dry Creek Circle, Suite 200, Littleton, CO 80120-8031.

**Members: \$6, nonmembers: \$10**

## Total Knee Arthroplasty

314 FEBRUARY 2010 1 CE credit

1. The first known total knee implant was made of \_\_\_\_\_.
  - a. Ivory
  - b. Plaster of paris
  - c. Wood
  - d. Acrylic
2. From 1951 through the early 70s, the \_\_\_\_\_ was the primary knee replacement system.
  - a. Polycentric knee
  - b. Condylar knee
  - c. Walldius hinge
  - d. Geometric prosthesis
3. Universal instrumentation was introduced in \_\_\_\_\_.
  - a. 1975
  - b. 1987
  - c. 1978
  - d. 1971
4. Surgical navigation systems can record \_\_\_\_\_ intraoperatively.
  - a. Joint range-of-motion
  - b. Laxity
  - c. Kinematics
  - d. All of the above
5. The greatest detriment to early robotics systems was \_\_\_\_\_.
  - a. Inaccuracy
  - b. Cost and complexity
  - c. Training personnel
  - d. None of the above
6. A system with dedicated instruments that are compatible with different implant systems is considered \_\_\_\_\_.
  - a. Open platform
  - b. Interchangeable
  - c. Imageless navigation
  - d. Precision 4.0
7. The \_\_\_\_\_ digitizes bony landmarks, monitored by a camera attached to a computer.
  - a. Optical tracking system
  - b. Fixation pin
  - c. Camera
  - d. None of the above
8. The \_\_\_\_\_ is used to determine a patient's correct standing anatomy.
  - a. Femoral tracker
  - b. Femoral rotation axis
  - c. Mechanical axis
  - d. Reference for resection level
9. Pins are placed with the knee in flexion to reduce \_\_\_\_\_.
  - a. Incidence of fracture
  - b. Muscle load
  - c. Collisions with the tibial implant
  - d. All of the above
10. When setting up for a total knee using navigation, the ST will need \_\_\_\_\_.
  - a. Navigation jigs
  - b. Standard jigs
  - c. All regular total knee instruments
  - d. A&C only

TOTAL KNEE ARTHROSCOPY 314 FEBRUARY 2010 1 CE credit

NBSTSA Certification No. \_\_\_\_\_

AST Member No. \_\_\_\_\_

My address has changed. The address below is the new address.

Name \_\_\_\_\_

Address \_\_\_\_\_

City \_\_\_\_\_

State \_\_\_\_\_

Zip \_\_\_\_\_

Telephone \_\_\_\_\_

	a	b	c	d		a	b	c	d
1	<input type="checkbox"/>	<input type="checkbox"/>	<input type="checkbox"/>	<input type="checkbox"/>	6	<input type="checkbox"/>	<input type="checkbox"/>	<input type="checkbox"/>	<input type="checkbox"/>
2	<input type="checkbox"/>	<input type="checkbox"/>	<input type="checkbox"/>	<input type="checkbox"/>	7	<input type="checkbox"/>	<input type="checkbox"/>	<input type="checkbox"/>	<input type="checkbox"/>
3	<input type="checkbox"/>	<input type="checkbox"/>	<input type="checkbox"/>	<input type="checkbox"/>	8	<input type="checkbox"/>	<input type="checkbox"/>	<input type="checkbox"/>	<input type="checkbox"/>
4	<input type="checkbox"/>	<input type="checkbox"/>	<input type="checkbox"/>	<input type="checkbox"/>	9	<input type="checkbox"/>	<input type="checkbox"/>	<input type="checkbox"/>	<input type="checkbox"/>
5	<input type="checkbox"/>	<input type="checkbox"/>	<input type="checkbox"/>	<input type="checkbox"/>	10	<input type="checkbox"/>	<input type="checkbox"/>	<input type="checkbox"/>	<input type="checkbox"/>

Mark one box next to each number.

Only one correct or best answer can be selected for each question.