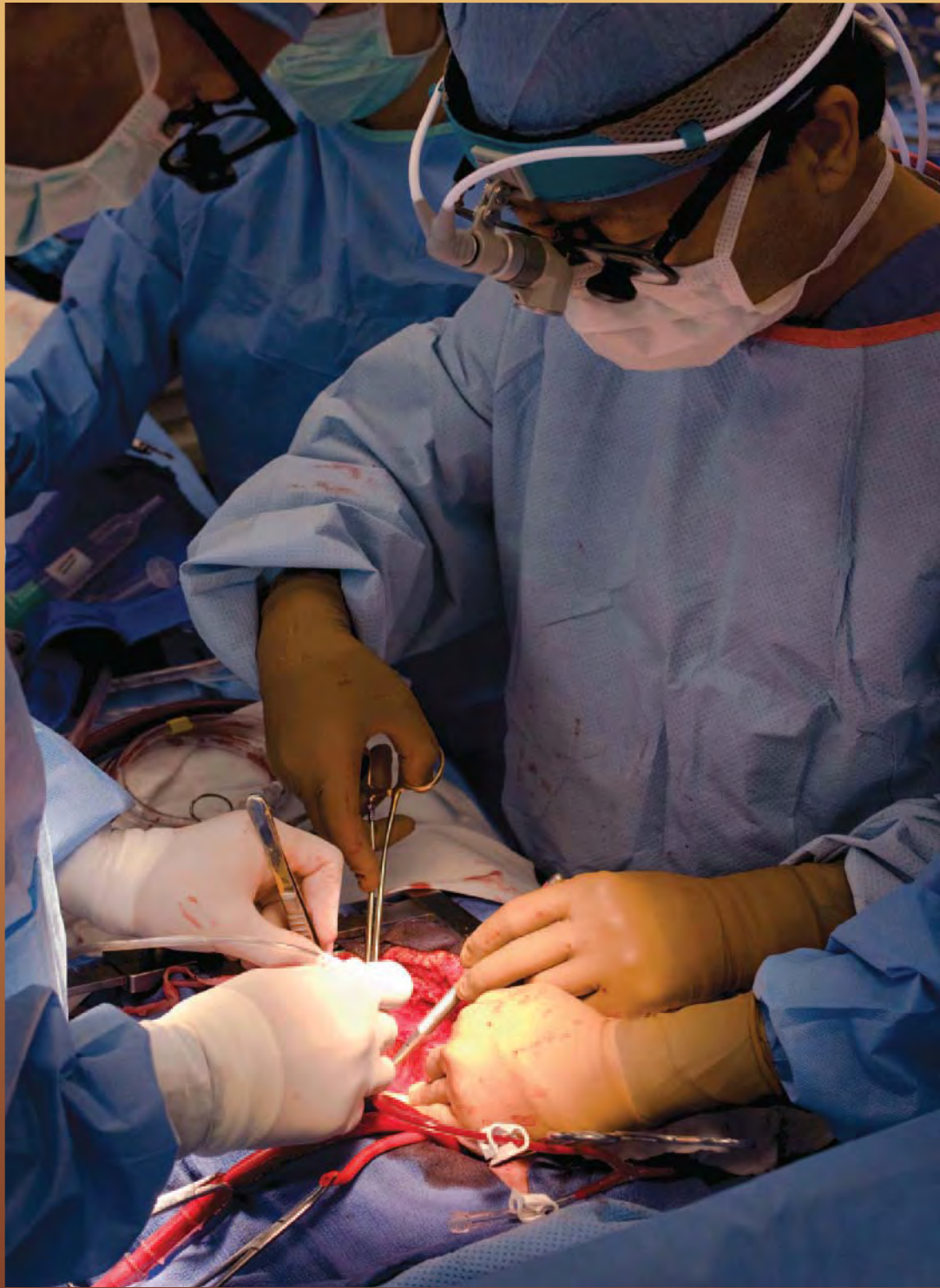



The Open Thoracotomy Approach to Bronchoesophageal Fistulae Repair

by Sophanna Pech and Grant Drake

Bronchoesophageal fistulae are a relatively uncommon clinical condition that may present within a number of patient populations. Etiologies will include congenital malformation, trauma, malignancies, or secondary-to-inflammatory processes or infection.¹ Diagnosis of bronchoesophageal fistulae may be difficult due to its often-insidious nature of presentation.¹ The open thoracotomy and video-assisted thoracotomy are effective modalities of surgical intervention.²

This article will examine the common approach to clinical assessment and diagnosis of this disease state, as well as detail surgical technique with an emphasis on the specific role of surgical technologists in the open-thoracotomy-type procedure.

ETIOLOGY

Fistulae may result from congenital malformations, often presenting with esophageal atresia,³ a disordered formation of the esophagus in utero, which may cause disruption of the esophageal tissue and, in some cases, communication with the trachea and bronchi.⁴ Bronchoesophageal fistulae of a congenital nature are categorized into four typical presentations by Baimbridge and Keith.⁵

Type one fistulae occur as an esophageal diverticulum becomes subject to inflammatory processes, causing the endpoint to perforate the pleura to communicate with the bronchial lumen.

Type two fistulae are the most common,¹ and are also known as “H-type” fistulae. This configuration will feature direct tissue communication between esophageal and tracheal lumen.

LEARNING OBJECTIVES

- ▲ Review the relevant anatomy for this procedure
- ▲ Examine the set-up and surgical positioning for this procedure
- ▲ Compare and contrast the osteoplasty-cam procedure and the acetabuloplasty-pincer procedure.
- ▲ Assess the indications for femoroacetabular impingement
- ▲ Evaluate the recovery and rehabilitation process following FAI

Type three consists of fistulous tissue connection between the esophagus and a lobar cyst, which in turn communicates with the bronchus.

Type four involves fistulous tract connection with sequestered parenchyma. Parenchymal sequestration occurs as a congenital malformation in which an area of parenchymal tissue is separated from the bronchial tree and is not vascularized by the pulmonary vasculature in the typical fashion,⁶ nor does it participate in oxygenation or ventilatory activity. This parenchymal lesion is instead supplied blood by the systemic circuit, according to Boetzkes *et al*, “[it] is supplied with blood from an aberrant artery mostly originating in the thoracic aorta.”⁷

More commonly, bronchoesophageal fistula may present secondary to a variety of malignancies,⁸ including but not limited to Hodgkin’s lymphoma, esophageal carcinomas and bronchogenic carcinomas. Additionally, bronchoesophageal fistula may present secondary to occupational exposure to respiratory irritants such as asbestos and silicone, or as a complication of infectious processes where cavitating lesions may occur as in the fungal infection histoplasmosis.⁸

PATHOPHYSIOLOGY

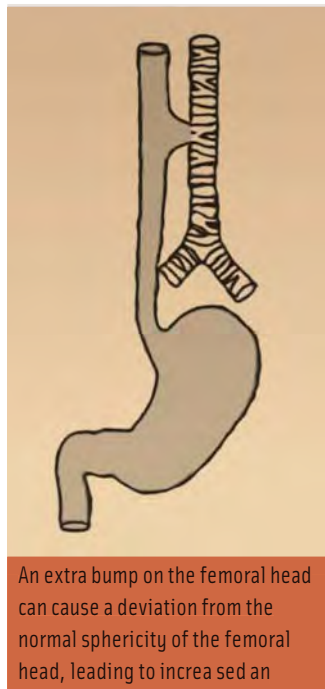Bronchoesophageal fistulae may originate in either the trachea or esophagus but will eventually involve each tissue type. This article examines the anatomical makeup of each organ and discusses pathological changes that may occur as fistulae evolve from both conducting airways and the esophagus.

The respiratory system is subdivided into two main regions. The first is the upper respiratory tract, which consists of the nose, nasopharynx, mouth, and oropharynx, where air is drawn inward upon inhalation and released during exhalation. The second is the lower respiratory tract,¹⁰ which starts at the laryngopharynx and continues through the larynx (which includes the epiglottis), trachea, carina (where the trachea bifurcates), and the bronchi. At

the carina, the bronchi separate into the right and left mainstem bronchi. As air moves distally throughout the bronchi, the conductive airways become progressively smaller in diameter, contain a decreasing amount of cartilage, and bifurcate numerous times, eventually reaching respiratory bronchioles and finally the alveoli where the actual gas exchange occurs. The alveoli make up the majority of the parenchymal surface area of the lung along with the pulmonary capillaries.

The esophagus begins at the level of the epiglottis and continues posterior to the trachea which is typically 10-11 cm long and typically will be 1.5-two cm in diameter in adults and is made up of semi-circular cartilaginous rings which are “c” shaped with no cartilage over the area where tracheal smooth muscle sits in direct contact with the esophagus.¹⁰ The one exception to the “c” shaped cartilaginous rings is the cricoid cartilage, which is a continuous cartilaginous ring and sits at the base of the larynx directly inferior to the thyroid cartilage. Patency of the alveoli is maintained by radial traction,¹² the pressure of the alveolar units themselves creating negative pressure against the parietal pleura pulling the small airways open. The trachea and both mainstem bronchi contain smooth muscle, connective tissue and a luminal surface of ciliated columnal epithelium interspersed with mucous-producing goblet cells. The trachea, mainstem bronchi, and conducting airways are lumenally coated with a sol and gel type colloid,¹³ or according to Schürch, “an aqueous substrate which covers the surface of the conducting airways consist[ing] of water, ions, sugars, proteins, proteoglycans, glycoproteins and lipids,”¹⁴ which is moved upward in airway clearance by cilia and smooth muscle function as in a cough.

In the case of bronchoesophageal or tracheoesophageal fistula, the most common type of communicating fistulae will occur as this posterior noncartilagenous area of trachea or mainstem bronchus is perforated. In neoplastic disease states, such as a squamous cell carcinoma, neoplasia within tracheal smooth muscle may result in exophytic or ulcerative lesions,⁸ causing erosion of the tracheal wall from within the epithelium moving outward, or beginning with disruption of the superficial layer of ciliated columnar epithelium, and leading to eventual erosion of connective tissues and basal cells until perforation occurs. Neoplasms may then extend extraluminally into the esophagus, eventually creating a communication between trachea and esophagus as the neoplasm expands and invades esophageal tissue.



Congenital type bronchoesophageal fistulae often occur in embryonic development. In gestational-week four, lungs begin to form as respiratory diverticuli emerge from the foregut epithelium,¹⁵ and in subsequent weeks, a tracheoesophageal ridge and the tracheoesophageal septum form to separate trachea from esophagus. In the case that this septum is not formed completely, bronchoesophageal fistula will result.

The esophagus connects the laryngopharynx with the stomach and digestive organs of the alimentary tract. It is composed of smooth muscles and is an average of 25 cm long and terminates at the lower esophageal sphincter (also called the cardiac sphincter),¹⁰ the entrance to the stomach. As the esophagus contains no cartilaginous surfaces, it is subject to constriction in areas where it meets with other anatomic surfaces. Narrowing occurs as the esophagus passes by the aortic arch, the left mainstem bronchus and the diaphragm. Histologically, the esophagus is composed of four tissue layers, the luminal mucosa layer, submucosa, muscularis and an outer layer called the serosa or adventitia.¹⁰ The mucosal layer is made up of stratified squamous epithelial cells, but also contains goblet cells, which produce mucous. The

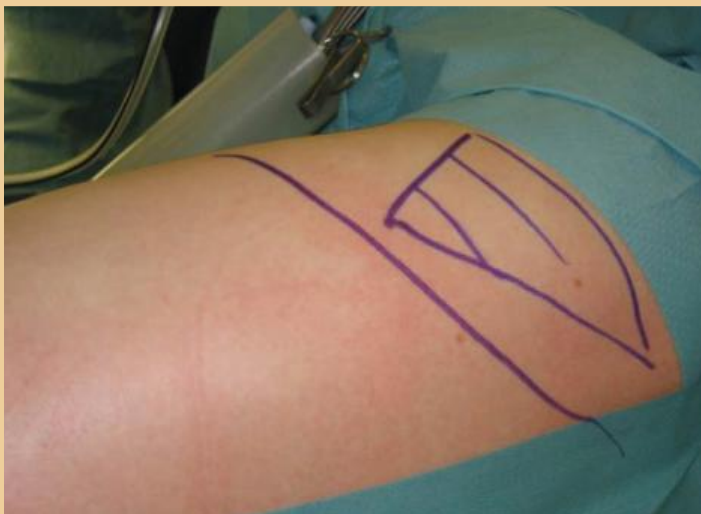submucosal layer also contains mucous-producing cells, as well as vasculature, nerve fibers and some smooth muscle

Since most hip joint pathology is found within the intra-articular region, distraction is necessary to achieve arthroscopic access.¹ Determining the signs and symptoms that suggest intra-articular pathology are essential.

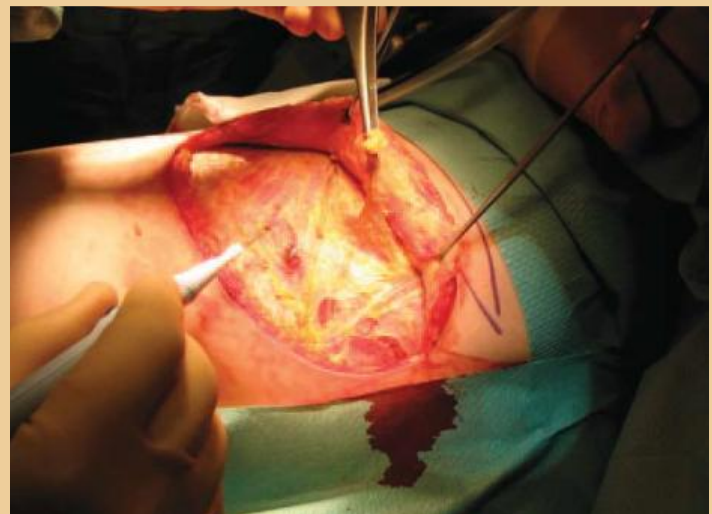
fibers. The muscle tissue contained in the third layer consists of longitudinal and circular smooth muscle tissue, which carries the major workload of peristaltic activity. The outer layer of the esophagus contains a thin, fascial layer of connective tissue housing vasculature and is considered an adventitial layer except when in contact with the trachea, when it is then considered the outer serosa.¹¹

DIAGNOSIS

Diagnosis of bronchoesophageal fistula is considerably complex in that congenital-type fistulae may go undiagnosed for a number of years if the configuration is such that both the esophagus and conducting airways maintain relatively



The patient is prepped and draped in routine fashion. The skin incision and its relation to the scapula are marked with a sterile marking pen. The patient is prepped and draped in routine fashion.



The skin is incised with a scalpel. Fat and fascia are divided with cautery as far as the muscle fascia. The triangle of fascia between the trapezius and latissimus is rasied, exposing serratus and the rhomboid muscles deeply

Images courtesy of Kieran McManus

normal patency.¹ In cases such as this, bronchoesophageal fistula may be considered when a patient has a significant history of pneumonia and respiratory infection, particularly if these are found to be associated with aspiration-type events. A patient may present with a chronic cough of moderate to paroxysmal characteristics. Paroxysmal cough is a very sudden and severe form of cough, a “coughing attack,” which involves extreme muscle stricture and spastic movement of airway musculature. Cough may present in either a productive or nonproductive nature, dysphagia and, less commonly, hemoptysis may also occur.¹

Common diagnostic procedures for any of the malignant or congenital types include bronchoscopy, esophago-gastroduodenoscopy⁹ and contrast esophogram with barium swallow or methylene blue instillation. Imaging may show chronic, inflammatory-type changes to the airway including bronchiectatic configurations of the bronchus,¹⁴ consistent with multiple aspiration events and esophageal pathologies including, but not limited to, diverticuli or esophagomalachia.

INDICATIONS FOR SURGICAL INTERVENTION

Dysphagia is of particular concern in judging surgical candidacy as this may lead to aspiration events, chronic cough, chronic infection and suppurative-type pulmonary lesion.

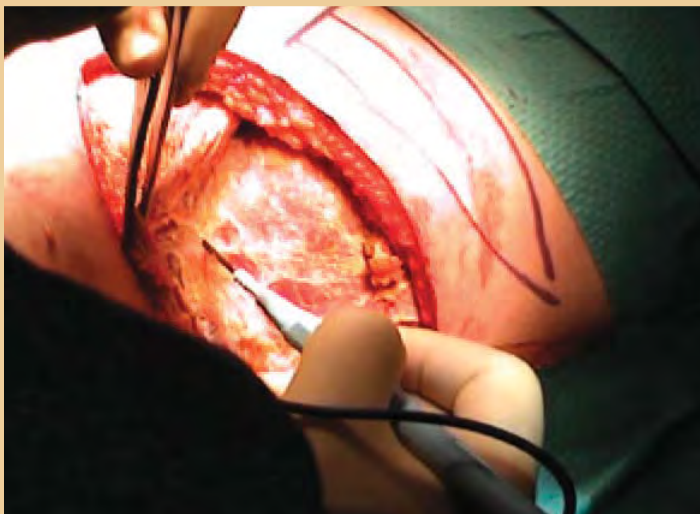
It has been recommended by Altorki and colleagues that all patients with thoracic esophageal diverticulae consider surgery as fistula may result.¹⁷ Additionally, surgical management in malignant-type cases is with precedent, and timely excision in some cases may be prophylactic to development of fistulae. In cases where recurrent infection and lack of maintainable patency in either airway or esophagus occur, surgical intervention is indicated.

SURGICAL TECHNIQUE

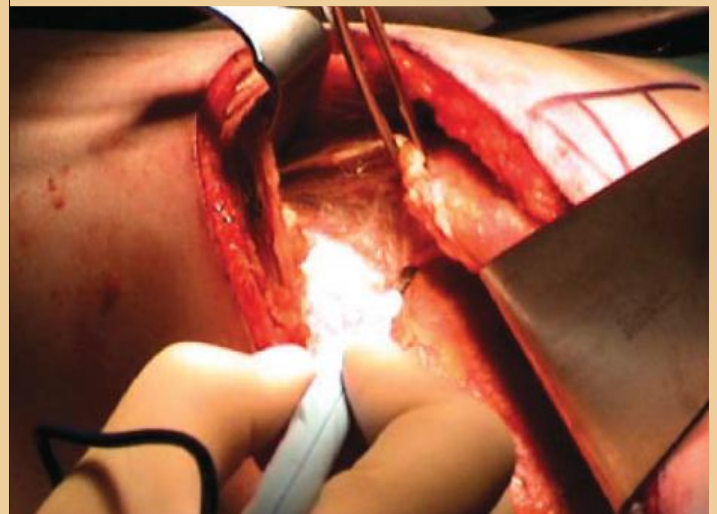
Bronchoesophageal fistulae are managed according to configuration and location of the fistula. Both open surgery and video-assisted thoracotomy are utilized and have proven to be effective in fistulae closure.

Preoperatively, the patient is positioned according to ease of access to the fistula. This will typically be lateral or supine positioning.¹⁸ The example used in this article shall assume lateral positioning and fistula between lower respiratory tract, for instance the right middle lobe segmental bronchi and esophagus.

Prior to positioning, the patient will be anaesthetized and intubated with a double lumen endotracheal tube in the supine position. If available, two compatible ventilators may be synchronized to allow for independent lung ventilation to anticipate upcoming deflation of the operative lung.



The latissimus is freed from the underlying serratus. Care must be taken not to damage the neurovascular supply to the serratus, which lies on the superficial surface of the muscle. Similarly, the trapezius is freed from the underlying rhomboids.



The serratus fascia is now incised as in a standard postero-lateral thoracotomy.

The nonsterile surgical team members then position the patient in the left lateral position. The patient will be positioned so as their nonoperative side will contact the table. Sequential compression devices are applied to the legs to prevent embolic activity, then the leg proximal to the oper-

relieve pressure placed on the brachial plexus. Rolled blankets are placed under the scapula on the nonoperative side. Finally, three-inch safety straps are placed over the thigh and shoulder to ensure stability.

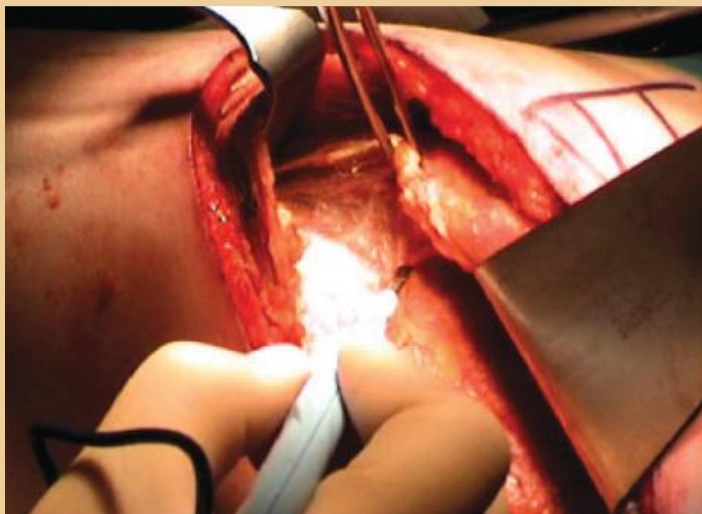
During the procedure, an initial diagnostic arthroscopy is performed and the structures of the hip joint are examined.¹ The femoral head is observed for chondral deformities or damage, as well as the surface of the acetabulum, the condition of th

ating table will be slightly flexed at the knee and abducted toward the chest. A pillow is then placed under the knee. The leg will be padded so contact with the table will not disturb the peroneal nerve. Arms are placed and secured on padded armboards with the superior arm pronated and slightly flexed, and the inferior arm positioned so the wrist is supinated and exposed so radial pulse may be palpated if necessary, and to protect the ulnar nerve. Additionally, a small roll is placed under the patient just below the last rib along the axillary line to allow for chest expansion, and to

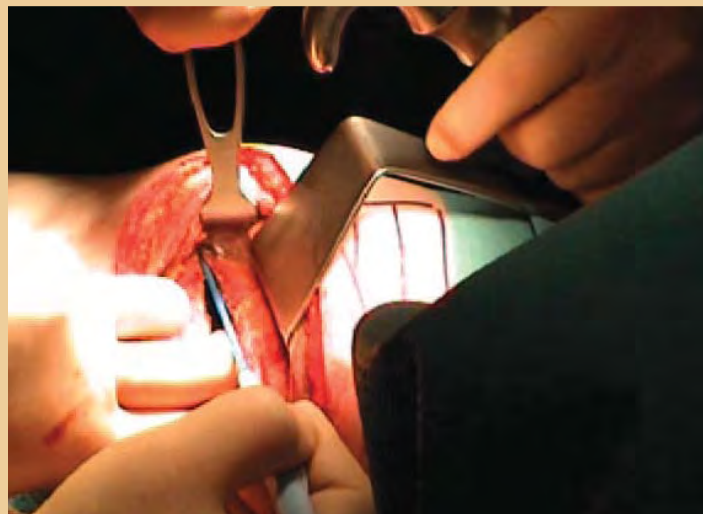
When positioning is complete, the patient is prepped for initial incision with application of topical anti-microbial preparatory agents to the area from the axilla to iliac crest, and bilaterally beyond the midline or to the table top. The incision site is then draped in a square configuration with towels, then a laparotomy drape is applied exposing only the incision site.

Various supplies are required to ensure proper patient and clinician safety in the thoracotomy procedure. The required equipment may include Bair-hugger®, cell saver, electro-surgical generator, smoke evacuator, arm boards and connected and functional suction.

Instrument sets commonly utilized are the thoracotomy tray, minor orthopedic tray and major vascular set.¹⁸ Blades required are #10, #15, and electro-surgical unit. Thoracotomy trays will typically contain large ratcheting, self-retaining retractors such as the Toufier and Reinhoff, which may be used to retract large areas of tissue, a Davidson scapula



The serratus is further dissected off the underlying ribs



The intercostal incision continues anteriorly.

Images courtesy of Kieran McManus

retractor and various smaller handheld retractors.

The thoracotomy tray may also include sternal needle holders and Duvall lung-grasping forceps, which are important for manipulation of the lung. The minor orthopedic tray is also commonly used and contains a variety of available retractors and forceps types as well as bone and soft tissue-cutting instruments, such as the Metzenbaum, which

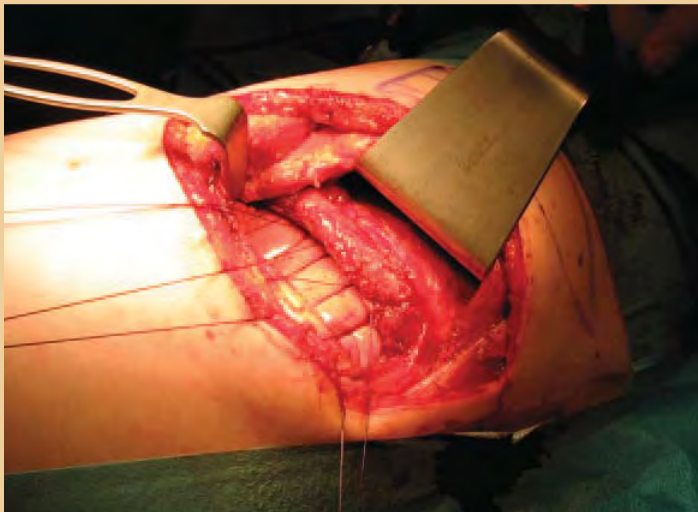
In order to prevent a possible fracture, a resection of less than 30 percent of the head-neck junction is recommended because this has been shown not to alter the load-bearing capacity of the femoral neck.^{4,8}

may be utilized at the surgeon's preference in place of the ESU or scalpel. Frasier suction tips are included for suction, and skin hooks for manipulation of distal tissues, the double prong hooks may be particularly useful in this respect.

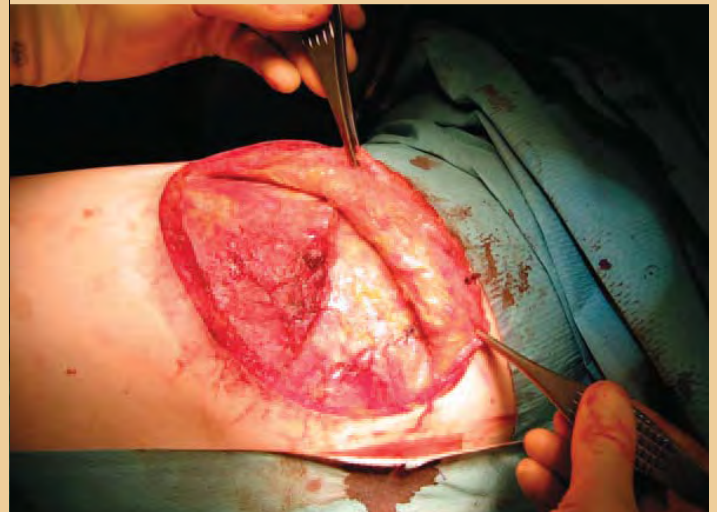The initial incision via #10 blade is made in the fourth or fifth intercostal space following the line of the rib.⁸ The incision runs laterally across the area of the fifth rib and is extended around the scapula cranially to the midline of the

scapula. Subcutaneous tissue is divided with an ESU. The latissimus dorsi is divided, and then deep to the latissimus dorsi, the serratus anterior is divided. The rhomboid muscle may be divided as well to allow retraction of the scapula.¹⁸ The surgical assistant may retract the musculature with a Richardson hand-held retractor to allow access to the intercostal muscle. When the intercostal muscle is visualized, the fascia and muscle are divided with an ESU. Care is taken to make the incision as low in the intercostal space as possible to avoid the intercostal blood supply and innervation.

Next, a rib-spreader is placed, allowing for ease of visualization and access to a fistula between lower respiratory tract and esophagus. At this time, the surgeon may elect to partially dissect the laterally-running band of intercostal muscle from the posterior aspect of the muscle to later use as a pedicle upon fistula closure in the case of large fistula.⁸ The #10 blade, or ESU, continues to incise deeper until the lungs are visualized. The lung is deflated. Upon visualization of the lung, Duval clamps are used to manipulate the lung. The surgical assistant will assist the surgeon in holding the clamps to allow for visualization of the fistula. Upon visu-



The upper blade of the retractor is inserted directly adjacent to the rib, applying no pressure to the intercostal nerve.



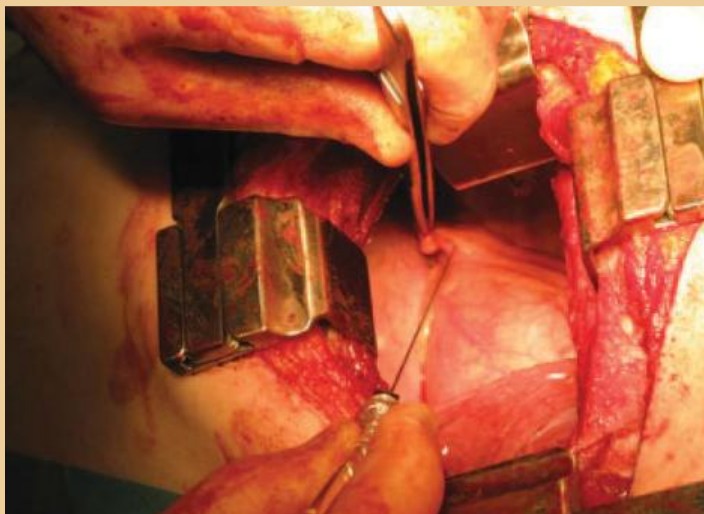
A second DeBakey rib spreader is placed at right angles to the first to retract the latissimus and serratus forward and the trapezius backwards.

alization of fistula, the esophagus is dissected immediately superior and inferior to the fistula⁸ and hand-held retractors may be placed and held with the help of the surgical assistant to separate bronchus from esophagus allowing for a clean visualization of the communicating portions of tissue. A #15 blade or ESU is then used to longitudinally incise the fistulous tissue. The surgical technologist will provide the surgeon with a series of 4-0 polyglactin 910 sutures, at which time the bronchus and esophagus are sutured in an interrupted technique.

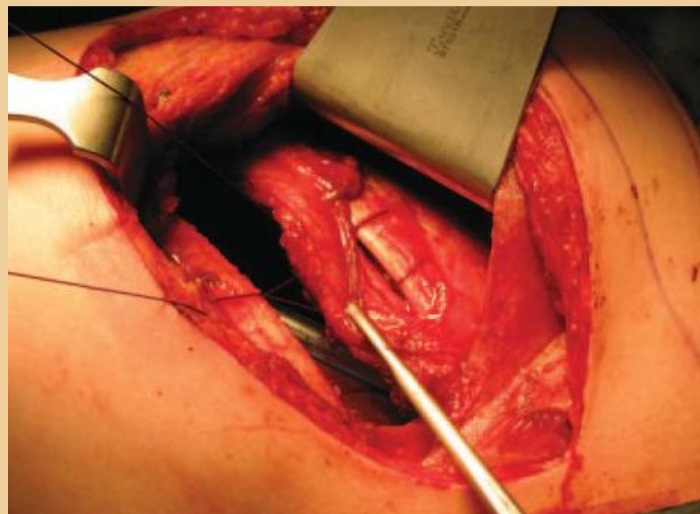
In cases involving large fistula or circumferential compromise of tissue integrity, resection and anastomosis is performed at this point if the lesion is found to be too large to be managed in a more tissue sparing fashion. The compromised tissue is excised via #15 blade or ESU in a lateral incision running the entire distance of the tissue surface slightly superior and inferior to damaged tissue. The surgical assistant will then assist with dandy nerve hooks to maintain the desired position and allow the surgeon visualization and access to the luminal space. Several traction sutures of 4-0 polyglactin 910 are placed around the circumference of the resection above the incision site. The sutures are placed in interrupted fashion and serve the purpose of relieving some of the tension placed on the anastomosis itself. Several techniques have been utilized in anastomosis and have been

found to be effective, including continuous or interrupted suturing.¹⁷

Pericardial fat is commonly used^{19,20} in bronchial closure during pneumonectomy, and Grillo has recommended utilizing pericardial pedicle placement in bronchoesophageal fistula closure using the Brewer technique²¹ in cases requiring resection of trachea and esophagus. The Brewer technique is a surgical technique that utilizes the fatty tissue that overlays the parietal pericardium anteriorly or laterally. A flap is made from the pericardial fat, which is not excised completely but remains connected on one side and has its innervation and vasculature preserved. According to Komanipalli and Sukumar, the pedicle will retain its connection to arterial flow via the superior, inferior and middle branches of the internal mammary artery and its venous return via the pericardiophrenic vessels.²² Pericardial fat pad placement involves ligation of the aforementioned vasculature and possibly the azygous vein if a large flap is necessary. Ligation is accomplished with a 0 silk suture on a needle because silk sutures are considered nonabsorbable. These ligations will need to remain in place for the pedicled tissue to retain blood flow. As this lateral strip of pericardial adipose tissue is mobilized, it is then wrapped around anastomosis sites of both the trachea and esophagus.²³ The surgical technologist then hands the surgeon a 4-0 polyglactin 910



Prior to closure, drains are placed and a long-acting anesthetic is injected into the phrenic nerve fat pad, reducing shoulder-tip pain.



Three or four pericostal sutures are placed in such a way that the neurovascular bundle is elevated. The lower intercostal nerve is protected by the groove in the rib.

Images courtesy of Kieran McManus

mounted on a needle and the fat pad is sutured in, mattress-style.⁸ In order to complete graft placement between the lower airway bronchus and esophagus, as in this example, intercostal muscle that was incised upon initial incision is sutured between the repaired fistula with mattress-style sutures, again using 4-0 polyglactin 910. Pedicle selection will ultimately depend on the location of the fistulae. After pedicle placement, all counts are performed and the thorax is closed per standard practice. A chest tube connected to a Pleurevac® is inserted to allow for drainage and to maintain inflation of the lung. Its sizing will depend on patient size, but a 30 French tube is common in adults. This will be sutured in place with a 2-0 monofilament cutting needle and dressed with a center split 4x4 sponge, which will be placed around the tube. The wound site is dressed with vaseline gauze and an adhesive, non-woven wound dressing.

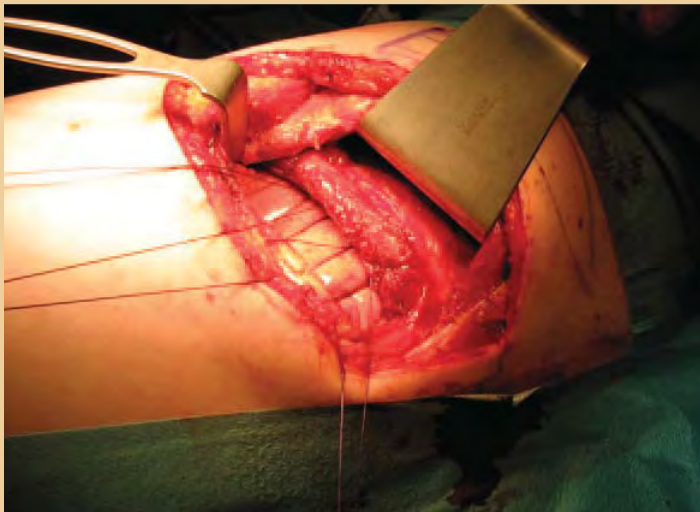
POSTOPERATIVE CONSIDERATIONS

The patient will be managed postoperatively in the surgical intensive care unit or post-anesthesia care unit as the potential for serious postoperative complications, such as hemorrhage and pneumothorax, exists and careful monitoring is essential. The patient is particularly at risk for nosocomial infection, particularly hospital-acquired pneumonia related to mechanical ventilation and sepsis secondary to opera-

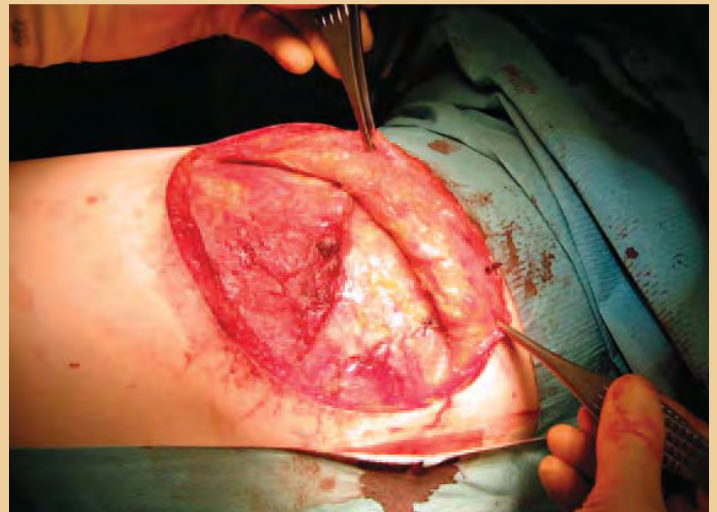tive site infection if dressings are not carefully managed and antisepsis is not meticulously maintained. The patient will initially arrive in the unit intubated, but as anesthesia and sedation levels begin to dissipate and pulmonary mechanics and arterial blood gasses return to clinically acceptable levels, the patient is quickly weaned from mechanical ventilation and extubated. Prolonged mechanical ventilation may significantly increase morbidity and mortality.¹¹

In order to prevent compromise or infection of the anastomosis or fistula closure, patients are initially placed on parenteral nutrition and, after several days, may be allowed liquids as indicated by successful swallowing evaluation. Swallowing evaluations are typically conducted by speech therapists. These evaluations may include a request for a barium swallow and contrast radiography.

The patient will swallow a liquid barium solution and X-rays will be taken to assure patency of the fistula repair and that aspirative events are not occurring. Care is taken to provide the patient with hyperinflation therapy and secretion clearance techniques as bronchial hygiene is vital to reducing the risk of incision-site infection and postoperative pneumonia. The patient will typically follow a regimen of respiratory therapy treatment including incentive spirometry or intermittent positive pressure breathing therapies to ensure adequate deep breathing and prevent



The pericostal sutures are tightened to re-approximate the ribs



The fascia of the auscultatory triangle is now re-sutured to the latissimus and the trapezius to maintain their anatomical positions.

atelectasis. During incentive spirometry, the patient inhales through the incentive spirometer device, which will measure the volume of air the patient is able to inspire. This is used to encourage deep breathing, provide the patient with a visualization of deep breathing goals and allows the respiratory therapist to measure the volume of gas inspired to assess lung expansion and respiratory effort. Therapies such as intermittent positive pressure breathing function in the same manner, but provide the patient assistance by delivering an additional degree of ventilation upon inspiratory effort.

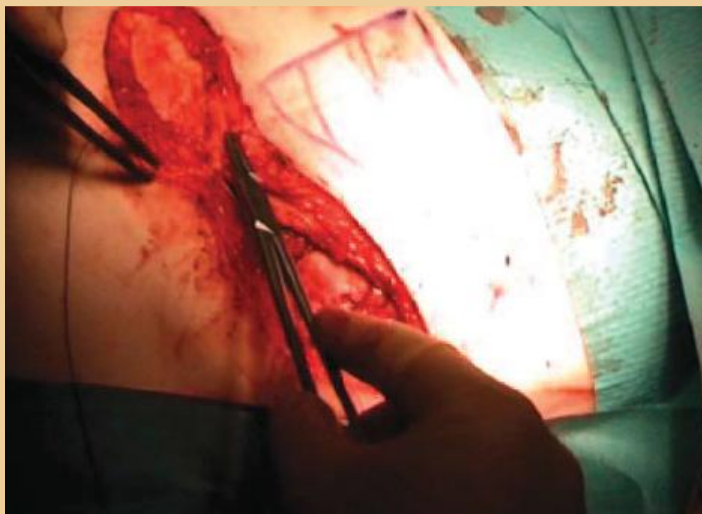
CONCLUSION

Although tracheoesophageal fistula and bronchioesophageal fistula are relatively rare, understanding the pathology of their surgical technique will aid the surgical technologist in developing critical and anticipatory thinking in regards to instrument choice as well as gaining an understanding of thoracic and pulmonary anatomy and physiology. Surgical literature includes various additional techniques that may be utilized in these cases, including bronchial or esophageal stenting, video-assisted thorascopic approaches and various wound-sealing choices, including surgical gluing and endoscopic clipping. These techniques may be used as an adjunct or alternative to the open technique examined herein.

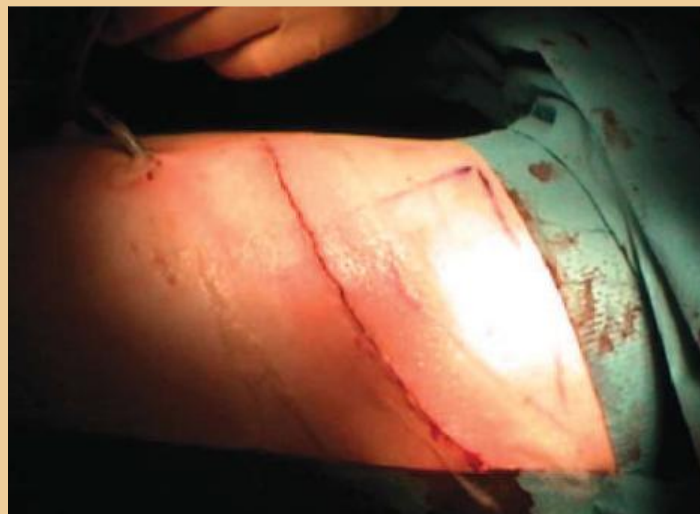ABOUT THE AUTHORS

Sophie Pech is currently employed as a surgical technologist in the St Luke's Regional Medical Center cardiovascular surgery unit in Boise, Idaho. She is a recent graduate of The College of Western Idaho Surgical Technology Program and is currently awaiting the results of her credentialing examination.

Grant Drake is a recent graduate of the Boise State University Respiratory Therapy Program. In August 2010, he will begin the post-Baccalaureate pre-Medical program at Duquesne University and hopes to attend medical school in the future.



After placing a stay suture at the midpoint of the fascial layer to ensure the two sides are properly aligned, the subcutaneous fascia is closed with running polyglactin 910. A routine subcuticular polyglactin 910 suture closes the skin.




The final result.

Images courtesy of Kieran McManus

References

1. Matilla S; Ramo O; Salo J. "Congenital bronchoesophageal fistula in the adult." *Ann Thorac Surg*. 1995. 59(6):887-890.
2. Braghetto I; Cardemil G; Schwartz E; *et al*. "Videothoroscopic management of middle esophageal diverticulum with secondary bronchoesophageal fistula: report of a case." *Surg Today*. 2008. 38(12):1124-8.
3. Aksoy T; Ceran C; Demircan M; Kafkasli A. "Tracheal agenesis and esophageal atresia with proximal and distal bronchoesophageal fistulas." *J Ped Surg*. 2008. 43(8): e1-e3.
4. Spitz L. 2007. "Oesophageal atresia." *Orphanet J Rare Dis*. 2:24. Accessed: November 12, 2009. Available at: <http://www.ocrd.com/content/2/1/24>.
5. Baimbridge M; Keith H. "Oesophago-bronchial fistula in the adult. Thorax." 1965. 20:226-233.
6. De Boeck K; Devlieger H; Van Raemdonck D; *et al*. "Pulmonary sequestration: a comparison between pediatric and adult patients." *Eur J Cardiothorac Surg*. 2001. 19;(4):388-95.
7. de Beukelaar T; Boetzkes S; Ramet J; Wojciechowski M; Van Schil P. "Intralobar bronchopulmonary sequestration with mixed venous drainage in a 10-year-old girl." *Acta Chir Belg*. 2009. 109(4): 501-3.
8. Grillo H. *Surgery of the Trachea and Bronchi*. Hamilton, Ontario. 2004. 576-579, 592-594
9. Cooperman R; Paragi P; Shah S. "Adult congenital bronchoesophageal fistula." *Thorac Cardiovasc Surg*. 2007. 55(5):334-6.
10. Bannister L; Berry M; Collins P; Dyson M; Dussek J; Ferguson M; Williams P. "Respiratory system." *Gray's Anatomy 38th ed*. New York. Pearson. 1995. 1648-1656.
11. King D. 2010. "Histology at Southern Illinois School of Medicine." Accessed March 15, 2010. Available at: <http://www.siuedu.edu/~dking2/erg/giguide.htm>.
12. Wilkins R; Stoller J; Kacmarek R *et al*. *Egan's Fundamentals of Respiratory Care 9th ed*. Mosby. 2008.
13. Anderson J. *Cardiopulmonary Renal Physiology Lecture*. Boise State University. September 2008.
14. Schürch S; Geiser M; Lee M; Gehr P. "Particles at the airway interfaces of the lung." *Colloids and Surfaces B: Biointerfaces*. 1999. 15(3-4):339-353.
15. Langman T; Sadler J. *Langman's medical embryology 9th ed*. Philadelphia. Lipincott&Williams. 2003. 278-285.
16. Iwazawa T; Imazato M; Ohnishi T; Kimura Y; Yano H; Monden T. "Double congenital bronchoesophageal fistulae in an adult." *Jpn J Thorac Cardiovasc Surg*. 2004. 52(8):386-9.
17. Altorki N; Sunagawa M; Skinner D. "Thoracic esophageal diverticula. Why is operation necessary?" *J Thorac Cardiovasc Surg*. 1993. 105(2):260-4.
18. Frey K; Ross T. *Surgical Technology for the Surgical Technologist: A Positive Care Approach 3rd ed*. Clifton Park, NY. Dlelmar Cengage Learning. 2008. 942-945.
19. Durrleman N; Massard G. "Posterolateral thoracotomy." *MMCTS*. 2006. (0810):1453.
20. Bardini R; Bonavina L; Asolati M; Ruol A; Castoro C; Tiso E. "Single-layered cervical esophageal anastomoses: a prospective study of two suturing techniques." *Ann Thorac Surg*. 1994. 58:1087-1089.
21. Taghavi S; Marta G; Lang G; *et al*. "Bronchial Stump Coverage with a Pedicled Pericardial Flap: An Effective Method for Prevention of Postpneumectomy Bronchopleural Fistula." *Ann Thorac Surg*. 2005. 79(1):284-288.
22. Anderson T; Miller J. "Surgical technique and application of pericardial fat pad and pericardiophrenic grafts." *Ann Thorac Surg*. 1995. 59(6):1590-1591.
23. . Komanapalli C; Sukumar M. "Pericardial Fat Pad Flap Buttress." The Cardiothoracic surgery network. Accessed March 27, 2010. Available at: http://www.ctsnet.org/sections/clinicalresources/thoracic/expert_tech-28.html.
24. Brewer L; King E; Lilly L; Bai A. "Bronchial closure in pulmonary resection: a clinical and experimental study using pedicled pericardial fat graft reinforcement." *J Thorac Surg*. 1953. 26(5):507-532.
25. Anderson T; Miller J. "Use of Pleura, Azygos Vein, Pericardium, and Muscle Flaps in Tracheobronchial Surgery." *Ann Thorac Surg*. 1995. 60:729-733.



Earn CE Credits at Home

You will be awarded continuing education (CE) credit(s) for recertification after reading the designated article and completing the exam with a score of 70% or better.

If you are a current AST member and are certified, credit earned through completion of the CE exam will automatically be recorded in your file—you do not have to submit a CE reporting form. A printout of all the CE credits you have earned, including Journal CE credits, will be mailed to you in the first quarter following the end of the calendar year. You may check the status of your CE record with AST at any time.

If you are not an AST member or are not certified, you will be notified by mail when Journal credits are submitted, but your credits will not be recorded in AST's files.

Detach or photocopy the answer block, include your check or money order made payable to AST, and send it to Member Services, AST, 6 West Dry Creek Circle, Suite 200, Littleton, CO 80120-8031.

Members: \$6, nonmembers: \$10

Bronchoesophageal Fistula Repair

318 JUNE 2010 1 CE credit

- Bronchoesophageal fistulae are categorized into _____ typical presentations.
 - 1
 - 2
 - 3
 - 4
- During embryonic development, the lungs begin to form during gestational week _____.
 - 2
 - 3
 - 4
 - 5
- Bronchoesophageal fistulae may present secondary to _____.
 - Hodgkin's lymphoma
 - Certain respiratory irritants
 - Cavitating lesions
 - All of the above
- The _____ is made up of stratified squamous epithelial cells.
 - Mucosal layer
 - Submucosa
 - Mainstem bronchus
 - Muscularis
- The most common type of fistula is _____.
 - Type 1
 - H-type
 - Sequestered parenchyma
 - None of the above
- _____ has been proven as an effective surgical method in fistula closure.
 - Endotracheotomy
 - Open thoracotomy
 - Video-assisted thoracotomy
 - b & c
- According to ease of access to the fistula, the typical patient is preoperatively positioned in either _____ or _____ position.
 - Lateral/Trendelenburg
 - Supine/Fowler's
 - Supine/Lateral
 - No proper combination
- An "H-type fistula" refers to a direct connection between the esophagus and the _____.
 - Tracheal lumen
 - Bronchus
 - Parenchymal tissue
 - None of the above
- Postoperative swallowing evaluations may include _____.
 - Speech therapy
 - Barium swallow
 - Contrast radiography
 - b & c
- Postoperative complications may include _____.
 - Hemorrhage
 - Pneumothorax
 - Nosocomial infection
 - All of the above

OPEN THORACTOMY APPROACH TO BRONCHESOPHAGEAL FISTULA REPAIR 318 JUNE 2010 1 CE credit

NBSTSA Certification No. _____

AST Member No. _____

My address has changed. The address below is the new address.

Name _____

Address _____

City _____ State _____ Zip _____

Telephone _____

	a	b	c	d		a	b	c	d
1	<input type="checkbox"/>	<input type="checkbox"/>	<input type="checkbox"/>	<input type="checkbox"/>	6	<input type="checkbox"/>	<input type="checkbox"/>	<input type="checkbox"/>	<input type="checkbox"/>
2	<input type="checkbox"/>	<input type="checkbox"/>	<input type="checkbox"/>	<input type="checkbox"/>	7	<input type="checkbox"/>	<input type="checkbox"/>	<input type="checkbox"/>	<input type="checkbox"/>
3	<input type="checkbox"/>	<input type="checkbox"/>	<input type="checkbox"/>	<input type="checkbox"/>	8	<input type="checkbox"/>	<input type="checkbox"/>	<input type="checkbox"/>	<input type="checkbox"/>
4	<input type="checkbox"/>	<input type="checkbox"/>	<input type="checkbox"/>	<input type="checkbox"/>	9	<input type="checkbox"/>	<input type="checkbox"/>	<input type="checkbox"/>	<input type="checkbox"/>
5	<input type="checkbox"/>	<input type="checkbox"/>	<input type="checkbox"/>	<input type="checkbox"/>	10	<input type="checkbox"/>	<input type="checkbox"/>	<input type="checkbox"/>	<input type="checkbox"/>

Mark one box next to each number.

Only one correct or best answer can be selected for each question.