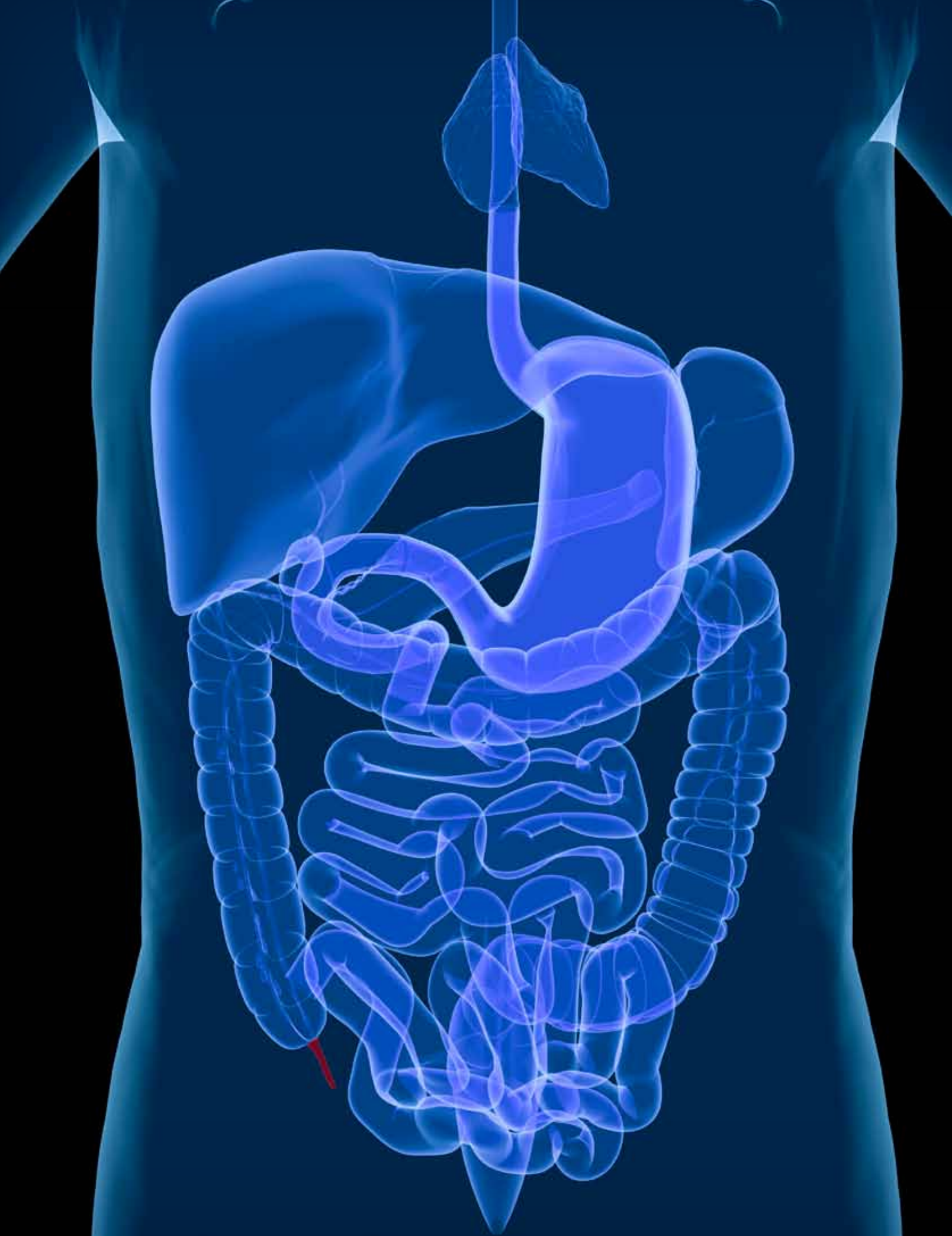



Adenocarcinoma of the Appendix

KATRINA CRAIG, CST

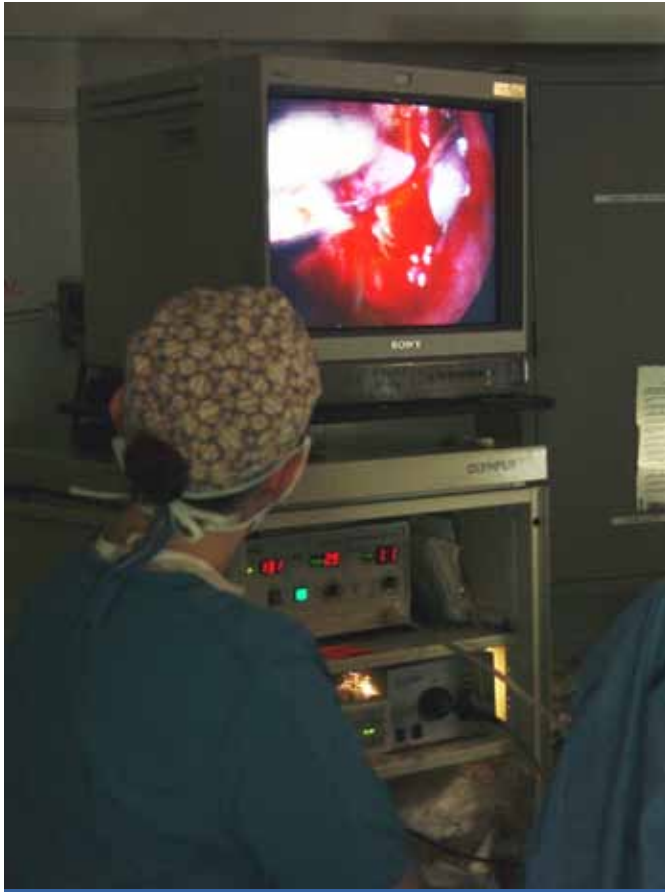Once in a while, what is thought to be a routine appendectomy becomes a more critical issue when cancer is discovered in the appendix. This is a rare occurrence as cancer in this area accounts for a small percentage of all intestinal tumors. Since this is a rare type of malignancy, which is generally not caught until it is in advanced stages, treatment options are limited. Finding probable causes or even genetic predispositions has been challenging as there are not enough cases to obtain the kind of data needed to narrow down such issues.⁶

ANATOMY OF THE APPENDIX

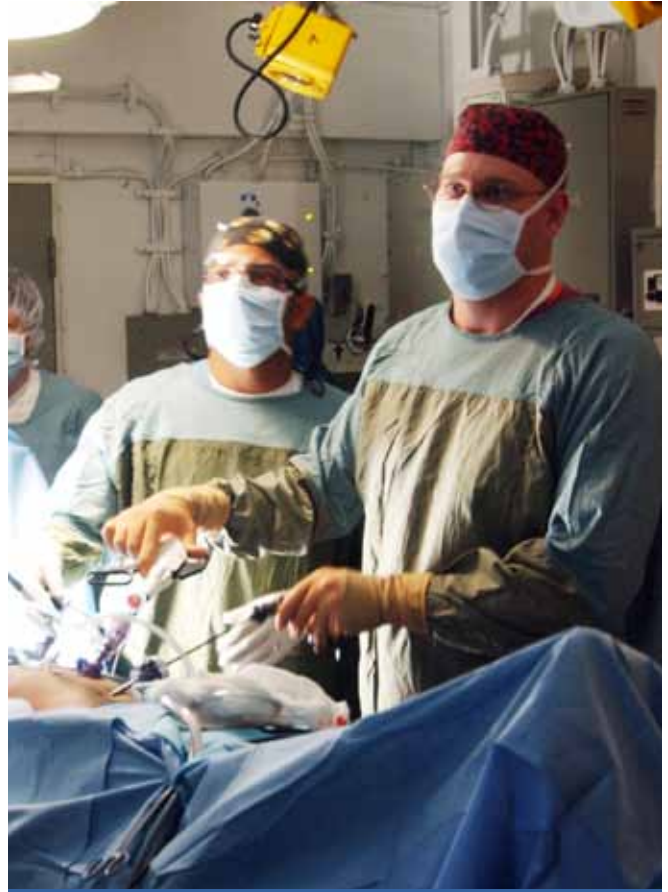The appendix is a small gland, about four inches long, and extends off the cecum of the large intestine. It is long and thin, resembling a worm, which prompted it to be named vermiform appendix. Just as the other organs of the gastrointestinal tract, the appendix has four layers of tissue: the innermost being the mucosal layer, then the submucosal layer, followed by the muscle layer and the external serosal layer. The muscle layer of this structure is thin as it is not involved in peristalsis. The appendix is composed of lymphatic tissue which is contained in the submucosa layer, but is not considered part of the lymphatic system, even though it does contain a lumen. The function of the appendix is not fully understood, but some believe it contains fluids to help reboot the intestinal tract after its balance has been upset by diarrhea. There is also the theory that the appendix has a special function in the immune system, although removal of this gland does not have an adverse effect on one's health.⁹

LEARNING OBJECTIVES

- ▲ Review the anatomy of the appendix
- ▲ List the supplies needed to perform an appendectomy
- ▲ Analyze which procedures may be necessary for various advancing stages of cancer
- ▲ Study the procedure for the removal of the appendix
- ▲ Determine which operations prove to have the best overall success rates



An appendectomy is observed on a laparoscopic monitor



Surgeons watch the laparoscopic monitor while performing an appendectomy

ANATOMY OF CANCER

“Tumors that occur in the appendix comprise a large group of both benign and malignant diseases. Appendix cancer is extremely rare, affecting an estimated 600 to 1,000 Americans each year. Most patients are diagnosed after undergoing surgery for acute appendicitis, or when an abdominal mass is seen during a CT scan for an unrelated condition.”⁷

The cellular layer of the appendix that is involved in the development of the tumor is the determining factor in the type of cancer that is diagnosed. In about two-thirds of cases diagnosed, carcinoid tumors are found at the distal end of the appendix, which does not cause an obstruction between the appendix and colon. It is more common to find a carcinoid tumor in a female than in a male, and usually occurs when the patient is in their 40s.⁷ When a patient is examined for other issues, 66 percent of appendiceal tumors that are classified as carcinoid, are found by accident.¹¹

Tumors that originate in the epithelial cells of the inside

lining of the appendix, or mucosa, are classified as non-carcinoid cancer. Because of the mucus produced by these cells, a noncarcinoid tumor may spread into the abdominal cavity and, if not treated, eventually may cause bowel obstruction and cachexia.⁷ While this condition may be life-threatening, it is not malignant.

Goblet cell carcinomas are classified as adenocarcinoid tumors which are similar to both the carcinoid and adenocarcinoma tumors occurring in the appendix.⁷ Adenocarcinoid tumors occur most frequently in patients in their 50s and are found when the symptoms of acute appendicitis present themselves.⁷ When the appendix develops goblet cell carcinoma, it usually infiltrates the entire gland which makes it easier to detect during a CT scan.⁸ This type of tumor is very rare, occurring in less than one percent of appendiceal tumors, and usually is diffused along the appendix wall.¹¹

Cystadenocarcinoma occurs in 20 percent of appendi-

ceal tumors and is found in varying places in the gland.¹¹ This classification of tumor is found in the mucosa cells of the appendix which develop into cysts. In 90 percent of cases this cancer remains localized and presents symptoms of appendicitis.¹¹

Adenocarcinoma develops at the base of the appendix and accounts for about 10 percent of appendiceal tumors. It involves the cells of the epithelial layer which has a higher

risk of metastasis into the abdominal cavity or colon. As with some of the other classifications of appendiceal cancer it is usually diagnosed after the patient presents symptoms of acute appendicitis.^{4,11} Signet ring is a rare form of adenocarcinoma, so named for the way the cells appear under the microscope, and is found in less than one percent of tumors. This particular type of adenocarcinoma is very aggressive and difficult to successfully treat.¹¹

ANATOMY OF CANCER

The word cancer strikes fear into the heart of almost anyone familiar with the term, but it is not a single disease. Cancer is the term given to hundreds of different diseases that have similar characteristics. What they have in common is uncontrolled abnormal cell growth and the spread of those cells.¹⁰ It is the altering of the DNA of a particular cell that can begin the cascade of events that leads to a malignancy. If the mutated cell is not destroyed by the immune system it will begin to replicate which will produce many more cells with a mutated genetic code.

In normal tissue there is a code that regulates growth, but if there is a mutation in that code, the cells may begin to reproduce uncontrollably. Hyperplasia begins to take place and a tumor begins to form, this is still considered a benign state. If left unchecked, the cells may continue to change which may lead to dysplasia, which follows the classification of hyperplasia, which is rapid over growth of the tissues. As the cells continue to grow unchecked the purpose of those cells may begin to change. When the cells of a tissue lose the ability to carry out their original function, and the only purpose they fulfill is reproduction, a diagnosis of cancer is given. Once carcinogenesis has begun, the cancer will begin not only destroying the surrounding tissues but will eventually metastasize to other parts of the body. As the cancerous tissue spreads throughout different systems it takes up residence and begins the destruction of the organs, glands and tissues, eventually causing death.¹⁰

Malignant neoplasms can originate in any of the different tissues and are named accordingly.

A malignancy that develops in the epithelial tissue is considered a carcinoma, connective tissue sarcoma, and lymphatic tissue cancer is a lymphoma. Malignant tumors in the brain, breast or stomach that occur outside of lymphatic tissue are considered extranodal lymphomas.

CLASSIFICATIONS OF CANCER

One of the first parts of diagnosing cancer is to determine the size and spread of the malignant tumor or cells. This is called grade and stage of the disease. How a treatment for cancer is determined, depends on the grade and stage of the tumor as the cells will react differently at different levels.

"Grading is a means of affixing a value to a clinical opinion of the degree of dedifferentiation (anaplasia) of cancer cells, or how much the cells appear different from their original form."¹⁰ A pathologist will examine the tissue sample and assign a grade from I to IV. The numbers determine the severity of the cancerous cells, the higher the grade the worse the cancer is thought to have progressed. In healthy tissue there is good differentiation of the cells, but in cancer this is the opposite, and the poor differentiation progresses as does the disease.

The higher the grade assigned to a tissue sample, the more advanced the cancer is, or the more dedifferentiated the cells have become. The next step in determining how advanced a malignancy is depends on the staging. There are different systems used for this purpose, if it is done in a clinical setting it is considered clinical staging. If the value given is assigned by a pathologist it is considered pathologic staging. One example is the TNM staging system. The T will give a value for the size of the tumor, the N is for the number of lymph nodes that test positive for cancer, and the M represents how far the cancer has metastasized. The values given to T, N and M are added together to give the staging number, which will help to determine the best course of treatment.¹⁰

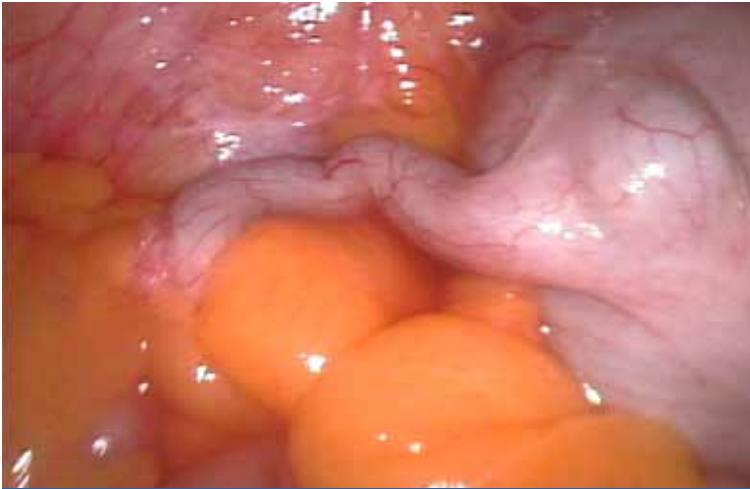If the cancer has not spread past the original site and has not invaded the organ it is considered to be carcinoma in situ (CIS). The site of the original tumor is called the primary location and if the cells metastasize to another location this is considered secondary locations. An example of this would be when adenocarcinoma of the appendix has metastasized to the liver, the malignant cells in the liver will be composed of the same type of tissue as the original cancer in the appendix.¹⁰

DIAGNOSIS OF CANCER

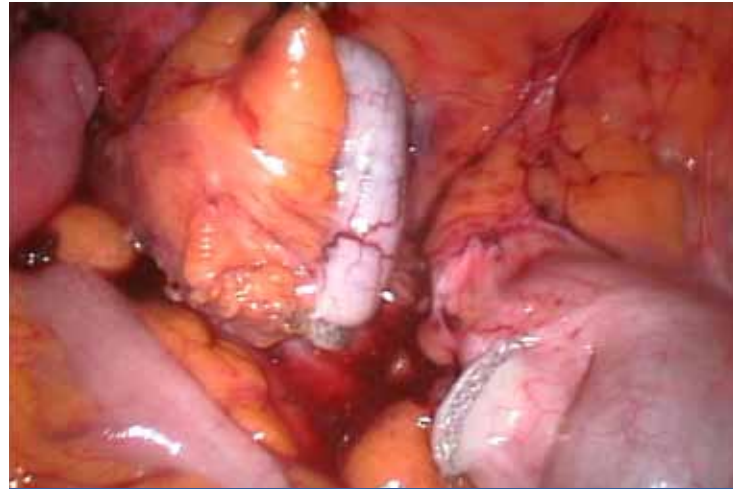A diagnosis of cancer in the appendix usually does not occur until the tumor has reached stage IV and the gland has ruptured. It is during what is thought to be a routine appendectomy for acute appendicitis that this rare form of

TREATMENT

Once it is determined that cancer is present in the appendix a course of action is chosen. If the tumor is a carcinoid and less than 1 centimeter in size with no metastasis, then an appendectomy is usually performed as this approach has



Before the removal of the appendix



At the removal of the appendix

cancer is found. Intermittent pain in the lower right quadrant in the initial stages, followed by continuous pain and abdominal tenderness are some of the first symptoms that may be noticed. Most neoplasms are found once the appendix has been removed and sent to pathology for analysis.^{7,8} Signs and symptoms of adenocarcinoma of the appendix prior to stage IV development are difficult to track as most cases are asymptomatic. Even in advanced disease sometimes the only symptoms are abdominal discomfort and bloating.

Some appendiceal neoplasms may be found because the patient is having secondary symptoms in the genitourinary area. If the cancer has metastasized it is possible that the reproductive organs or urinary system may have neoplastic cells which may cause symptoms.⁷ The mass also may be palpable or there may be gastrointestinal bleeding which would be cause for investigation.⁸

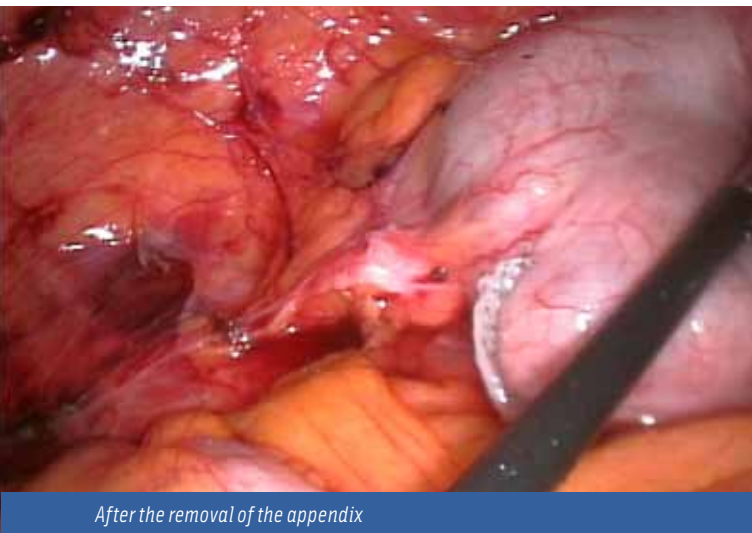
been shown to be sufficient at this stage of development of the tumor.¹¹ When the tumor is larger than two centimeters the recommendation is a right colectomy, and if the cancer cells are locally advanced cytoreductive surgery is recommended along with the right colectomy. If the carcinoid has metastasized to the liver, the recommended surgery is the right colectomy with cytoreductive surgery and hepatic resection.¹¹ As the cancer cells become more invasive and

It is more common to find a carcinoid tumor in a female than in a male, and usually occurs when the patient is in their 40s.⁷ When a patient is examined for other issues, 66 percent of appendiceal tumors that are classified as carcinoid, are found by accident.¹¹

progress to different locations in the body the recommended treatment will change.

Neoplasms of epithelial origin in the appendix have similar recommendations for treatment, regardless of the type of carcinoma diagnosed. For adenocarcinoma of the appendix that is nonperforated and localized, a right hemicolectomy is the preferred treatment. This radical approach

offers the best long-term outcome for the patient.^{4,11} The 10-year survival rate for patients that have been treated with a right hemicolectomy is 85 percent compared with only a 50 percent survival rate for those patients who were treated with just an appendectomy.¹¹



After the removal of the appendix

Perforated adenocarcinoma of the appendix requires more radical treatment. A right hemicolectomy would be recommended along with intraoperative intraperitoneal hyperthermic chemotherapy.⁵ This involves circulating heated solutions containing cancer-killing chemicals through the abdominal cavity for a couple of hours post-surgically. This treatment is known as hipectreatment or HPEC.³ Washing the intraperitoneal area with chemotherapy drugs is performed to eliminate any remaining cancer cells that may have been missed during surgery. If the adenocarcinoma has progressed with peritoneal carcinomatosis, the recommendation for treatment will include the right hemicolectomy, intraperitoneal chemotherapy and three cycles of IV chemotherapy to try to eradicate the cancer.¹¹

Surgery beyond the appendectomy to prevent recurrence of adenocarcinoma of the appendix is the recommendation in most cases. The right hemicolectomy is the same procedure that is recommended for colon cancer of the ascending colon. In this type of surgery the ascending colon is removed along with, in most cases, the hepatic flexure, as well as the cecum and appendix.¹ The reason for the radical excision of almost half of the large intestine is due to the way the blood is supplied to the organ, rather than because of spread of the disease. If parts of the colon are left with less than adequate blood supply it could induce dead bowel

which becomes fatal if not quickly removed surgically. The associated lymph nodes are tested, and if positive for cancer, they are removed. The ileum of the small intestine is then anastomosed to the remaining transverse colon.¹

The best approach for a good prognosis is surgery to remove all the cancerous tissue and to look for any seeding, or spread of cancerous cells in the abdominal cavity, which must be removed as well.⁶ If the cancer returns the recommendation is for surgical removal again, with intraperitoneal chemotherapy.¹¹

PROGNOSIS

Statistics vary when it comes to long-term survival rates for patients who are diagnosed with cancer of the appendix. Part of the reason for the lack of information is that this type of cancer is rare and therefore more difficult to track. Most statistics show that the prognosis is much better for patients who undergo right hemicolectomy as opposed to an appendectomy. Tumor size at the time of discovery is one of the most important factors in long term prognoses for this disease.² The smaller the tumor size usually equals the better the chance for long-term survival.

A follow-up study performed on seven patients who were diagnosed with adenocarcinoma of the appendix in 1999 to 2000 found that at the seven-year mark survival rate was 100 percent. This included one patient whose appendix was ruptured with metastasis of the cancer at the time of the original surgery. At the six-year mark, this patient developed metastasis to the liver and was treated with a liver resection.²

Another study conducted by TD Yan, LB Bijelic and PH Baker, found that the 10-year survival rate for those treated for cancer of the appendix (out of 402 patients with stage IV disease) resulted in 85 percent of those patients still alive. These patients were treated with cytoreductive surgery and intraperitoneal chemotherapy even if the disease was localized. This aggressive form of treatment was performed to give the best chances for a good outcome. The study is quick to point out, however, that the majority of patients who were included had tumors of low histological grade, which may have had an effect on the survival percentage at the 10-year mark.⁵

While the statistics from different studies show five and 10-year survival rates varying from 60 percent to 100 percent, it is clear that the more radical approach to treatment has improved the life expectancy of patients.

APPENDECTOMY PROCEDURE

Equipment

- Suction apparatus
 - Electrosurgical unit with dispersive electrode
 - Headlamp available
-

Instruments

- Minor instrument set
 - Major instrument set available
-

Supplies

- Prep set
 - Basic pack
 - Basin set
 - Gloves
 - 2 #10 blades
 - Sutures
 - Laparotomy drapes
 - Electrosurgical pencil
 - Dressing material
 - Culture tubes
 - Penrose drain
 - Irrigation solution
-

PREPARATION AND PROCEDURE

Patients will be administered general anesthesia and the patient will be prepped in the supine position. A shave may be necessary and prep will start from mid-chest to thighs and laterally as far as possible. The right lower quadrant will be outlined with towels secured with adhesive or towel clips and draped with a laparotomy sheet.

The McBurney's incision is usually used and the appendix is identified by following the cecal taenia to the appendiceal base. Mobilization of the cecum into the wound may be necessary. Once the appendix is identified, it is removed from the wound and grasped with a Babcock. The mesoappendix is then transected from the free end tip of the appendix toward the base by a series of double clamping, cutting and ligation with 3-0 absorbable ties. This procedure may be reversed if the appendix is adhered or otherwise distorted.

A clamp is placed near the base of the appendix, crushing it, and then it is removed and reapplied distally. If the surgeon prefers, the surgical technologist should prepare pursestring suture. Then the surgical technologist should replace the Babcock with a Crile grasping the tip of the appendix. A 3-0 absorbable suture on a small taper needle may be passed through the cecum and around the base of the appendix in a pursestring manner.

The crushed base of the appendix is then ligated with an 0 absorbable tie and is amputated with the electrosurgical pencil, scissors or a scalpel, depending on the surgeon's preference. The appendiceal stump is inverted within the lumen of the cecum followed by the tightening and tying of the pursestring suture. The surgical technologist should gently push the stump into the lumen with the Crile hemostat. As the pursestring suture is tightened, the surgical technologist will unclamp the hemostat and remove it. A basin should be in the field to collect the appendix and any contaminated instruments. A Penrose drain may be placed.

The appendectomy incision is closed in layers. Since the incisions are generally small, surgical technologists should be prepared to quickly perform counts.

POST-OP CONSIDERATIONS

Following the procedure, the patient will be transported to the PACS and monitored for the following complications: hemorrhaging, infections, stump rupture, sepsis or intestinal obstruction due to resultant adhesions. If it determined the operation was a success and the patient has no complications, he or she may return to normal activities within four to six weeks.

The removal of the appendix may also be performed via laparoscopic approach.

REFERENCES

Frey, K B; et al. Surgical Technology for the Surgical Technologist – A positive care approach, 3rd ed. General surgery – appendectomy. 2008. 3:14;434-438.

CONCLUSION

Even though there are only a few thousand cases of appendiceal cancer diagnosed each year, tremendous advances have been made toward extending the life expectancy of those who do develop this disease. The five-year survival rate was around 50 percent 35 years ago and today those percentages have risen drastically. For someone faced with the odds of dealing with a cancer diagnosis of any kind, the hope of a cure or long-term survival can make a tremendous difference for them. The aggressive type of surgery performed on patients who are diagnosed with adenocarcinoma of the appendix may seem excessive, but statistics show that it drastically increases the chances of a living longer.

For adenocarcinoma of the appendix that is nonperforated and localized, a right hemicolectomy is the preferred treatment. This radical approach offers the best long-term outcome for the patient.^{4,11}



ABOUT THE AUTHOR

Katrina Craig, CST, graduated from San Joaquin Valley, Fresno, California, earlier this year.

REFERENCES

1. Cedars-Sinai. Right hemicolectomy. 2011. <http://www.cedarsinai.edu/Patients/Programs-and-services/colorectal-cancer-center/services-and-treatment>
2. Farnaro, R.; Frascio, M.; Sticchi, C.; DeSalvo, L.; Stabilini, C.; Mandolino, F.; Ricci, B.; Gianetta, E. Appendectomy or right hemicolectomy in the treatment of appendiceal carcinoid tumors. 2007. <http://www.ncbi.nlm.nih.gov/pubmed/18338494>
3. Hipec Treatment. 2011. Retrieved from http://www.hipectreatment.com/awlp/peritoneal_cancer_treated_with_hipec.php?gclid=CObbt-X3-6gC-FRpVgwodHxIXTA
4. Lester, S. Manual of surgical pathology. Philadelphia, PA: Elsevier. 2010.
5. Levine, E A. Appendiceal carcinoma with peritoneal dissemination: outcome for the best of the best. *Ann of Surg Oncol*. 2007. 14:2440-2442.
6. Mahtene, H.; Sugarbaker, PH.; Surg, Br J. Appendix cancer. 2004. <http://www.aboutncancer.com>
7. MD Anderson. Appendix cancer. 2001. <http://www.mdanderson.org/patient-and-cancer-information/index.html>
8. Pickhardt, P.; Levy, A.; Rohrmann, C.; Kende, A. 2003. <http://radiographics.rsna.com>
9. Scanlon, V.; Sanders, T. Essentials of anatomy and physiology (6th edition). Philadelphia, PA: F. A. Davis. 2011.
10. Shiland, B. Mastering healthcare terminology (3rd edition). St. Louis, MO: Elsevier. 2010.
11. Sugarbaker, PH. Atlas of Appendix cancer. 1996. <http://www.surgicaloncology.com/atintro.html>

Digestive System Review

Name the three main functions of the digestive system.

1. _____
2. _____
3. _____

Describe the four layers of the digestive tract wall.

1. _____
2. _____
3. _____
4. _____

Differentiate between the two layers of the peritoneum.

Parietal _____

Visceral _____

Name and describe the functions of organs of the digestive tract.

Mouth _____

Pharynx _____

Esophagus _____

Stomach _____

Small Intestine _____

Large Intestine _____

Rectum _____

Anus _____

4. Name and describe the functions of the accessory organs of digestion.

Salivary Glands _____

Liver _____

Gall Bladder _____

Pancreas _____

5. Describe the functions of bile in digestion. _____

6. Name and locate the ducts that transport bile from the liver to the digestive tract. _____

7. Define absorption. _____

8. Define the villi and state their function in absorption. _____

9. Differentiate between catabolism and anabolism.


Catabolism _____

Anabolism _____

**Pages 261, 262 and 263 are for the reader's benefit only. Please do not submit these pages to AST. The CE exam follows on 264.*

Write the meaning of each word element in the space provided.

Word Element	Definition
10. amyl/o	
11. appendic/o, append/o	
12. bil/i	
13. bucc/o	
14. cec/o	
15. cheil/o	
16. chol/e	
17. col/o	
18. colon/o	
19. dent/o	
20. cholecyst/o	
21. duoden/o	
22. -estasia	
23. -emesis	
24. enter/o	
25. esophag/o	
26. gastr/o	
27. gingiv/o	
28. gloss/o	
29. gluc/o, glyc/o	
30. hepat/o	
31. ile/o	
32. jejun/o	
33. lapar/o	
34. lingu/o	
35. lip/o	
36. lith/o	
37. -lysis	
38. mandibul/o	
39. odont/o, dent/o	
40. or/o	
41. rect/o	
42. peritone/o	
43. -pepsia	
44. sial/o	
45. sigmoid/o	
46. steat/o	
47. stomat/o	
48. -tresia	
49. -tripsy	



Earn CE Credits at Home

You will be awarded continuing education (CE) credits toward your recertification after reading the designated article and completing the test with a score of 70% or better. If you do not pass the test, it will be returned along with your payment.

Send the original answer sheet from the journal and make a copy for your records. If possible use a credit card (debit or credit) for payment. It is a faster option for processing of credits and offers more flexibility for correct payment. When submitting multiple tests, you do not need to submit a separate check for each journal test. You may submit multiple journal tests with one check or money order.

Members this test is also available online at www.ast.org. No stamps or checks and it posts to your record automatically!

Members: \$6 per credit

(per credit not per test)

Nonmembers: \$10 per credit

(per credit not per test plus the \$400 nonmember fee per submission)

After your credits are processed, AST will send you a letter acknowledging the number of credits that were accepted. Members can also check your CE credit status online with your login information at www.ast.org.

3 WAYS TO SUBMIT YOUR CE CREDITS

Mail to: AST, Member Services, 6 West Dry Creek Circle Ste 200, Littleton, CO 80120-8031

Fax CE credits to: 303-694-9169

E-mail scanned CE credits in PDF format to: memserv@ast.org

For questions please contact Member Services - memserv@ast.org or 800-637-7433, option 3. Business hours: Mon-Fri, 8:00a.m. - 4:30 p.m., MT

ADENOCARCINOMA OF THE APPENDIX

342 June 2012 1.5 CE credits - \$9

- The appendix is a small _____ that extends off the cecum of the large intestine.
 - Muscle
 - Organ
 - Gland
 - Ligament
- The function of the appendix is not fully understood, but some believe _____.
 - It helps balance the intestinal tract
 - It plays a special function in the immune system
 - Only b
 - Both a and b
- Appendix cancer is rare, affecting as few as _____ Americans each year.
 - 850
 - 1,020
 - 600
 - 200
- The majority of _____ that are classified as carcinoid are found by accident.
 - Appendiceal Tumors
 - Noncarcinoid Tumors
 - Adenocarcinoid Tumors
 - Malignant Tumors
- In initial stages of cancer in the appendix, pain usually occurs in the _____.
 - Upper left quadrant
 - Lower right quadrant
 - Stomach
 - Lower right thigh
- An appendectomy is usually performed if the carcinoid tumor is less than _____ in size with no metastasis.
 - 1 cm
 - 11 cm
 - 2 cm
 - 0.5 cm
- If the carcinoid has metastasized to the liver, the recommended surgery is _____ with cytoreductive surgery and hepatic resection.
 - Colectomy
 - Hemicolectomy
 - Right hemicolectomy
 - Right colectomy
- An appendectomy procedure includes usage of the following:
 - Suction apparatus
 - Basin set
 - Electrosurgical pencil
 - All of the above
- This incision is usually used to begin the removal of the appendix:
 - Crile
 - McBurney's
 - Longitudinal
 - Cherney
- Depending on the surgeon's preference, the crushed base of the appendix is amputated with (a) _____.
 - Scissors
 - Scalpel
 - Electrosurgical pencil
 - Any of the above

11. The removal of the appendix may also be performed via (a) _____.

- a. Laparoscopic approach
- b. Laparotomy
- c. Fistulotomy
- d. Open Cholecystectomy

12. If cancer has not spread past the original site and has not invaded the organ, it is considered to be _____.

- a. Carcinomic
- b. Carcinoma in situ
- c. Malignant
- d. Benign

13. Malignant tumors in the _____ that occur outside of the lymphatic tissue are considered extranodal lymphomas.

- a. Stomach
- b. Brain
- c. Both a and b
- d. Neither a and b

14. During an appendectomy, the surgical technologist should gently push the stump into the _____ with the Crile hemostat.

- a. Stomach
- b. Lumen
- c. Intestine
- d. Heart

15. In which procedure is the ascending colon removed along with the appendix?

- a. Right hemicolectomy
- b. Right colectomy
- c. Colectomy
- d. All of the above

ADENOCARCINOMA OF THE APPENDIX 342 June 2012 1.5 CE credits - \$9

NBSTSA Certification No. _____

AST Member No. _____

My address has changed. The address below is the new address.

Name _____

Address _____

City _____ State _____ Zip _____

Telephone _____

Check enclosed Check Number _____

Visa MasterCard American Express

Credit Card Number _____

Expiration Date _____

	a	b	c	d		a	b	c	d
1	<input type="checkbox"/>	<input type="checkbox"/>	<input type="checkbox"/>	<input type="checkbox"/>	11	<input type="checkbox"/>	<input type="checkbox"/>	<input type="checkbox"/>	<input type="checkbox"/>
2	<input type="checkbox"/>	<input type="checkbox"/>	<input type="checkbox"/>	<input type="checkbox"/>	12	<input type="checkbox"/>	<input type="checkbox"/>	<input type="checkbox"/>	<input type="checkbox"/>
3	<input type="checkbox"/>	<input type="checkbox"/>	<input type="checkbox"/>	<input type="checkbox"/>	13	<input type="checkbox"/>	<input type="checkbox"/>	<input type="checkbox"/>	<input type="checkbox"/>
4	<input type="checkbox"/>	<input type="checkbox"/>	<input type="checkbox"/>	<input type="checkbox"/>	14	<input type="checkbox"/>	<input type="checkbox"/>	<input type="checkbox"/>	<input type="checkbox"/>
5	<input type="checkbox"/>	<input type="checkbox"/>	<input type="checkbox"/>	<input type="checkbox"/>	15	<input type="checkbox"/>	<input type="checkbox"/>	<input type="checkbox"/>	<input type="checkbox"/>
6	<input type="checkbox"/>	<input type="checkbox"/>	<input type="checkbox"/>	<input type="checkbox"/>					
7	<input type="checkbox"/>	<input type="checkbox"/>	<input type="checkbox"/>	<input type="checkbox"/>					
8	<input type="checkbox"/>	<input type="checkbox"/>	<input type="checkbox"/>	<input type="checkbox"/>					
9	<input type="checkbox"/>	<input type="checkbox"/>	<input type="checkbox"/>	<input type="checkbox"/>					
10	<input type="checkbox"/>	<input type="checkbox"/>	<input type="checkbox"/>	<input type="checkbox"/>					

Mark one box next to each number. Only one correct or best answer can be selected for each question.