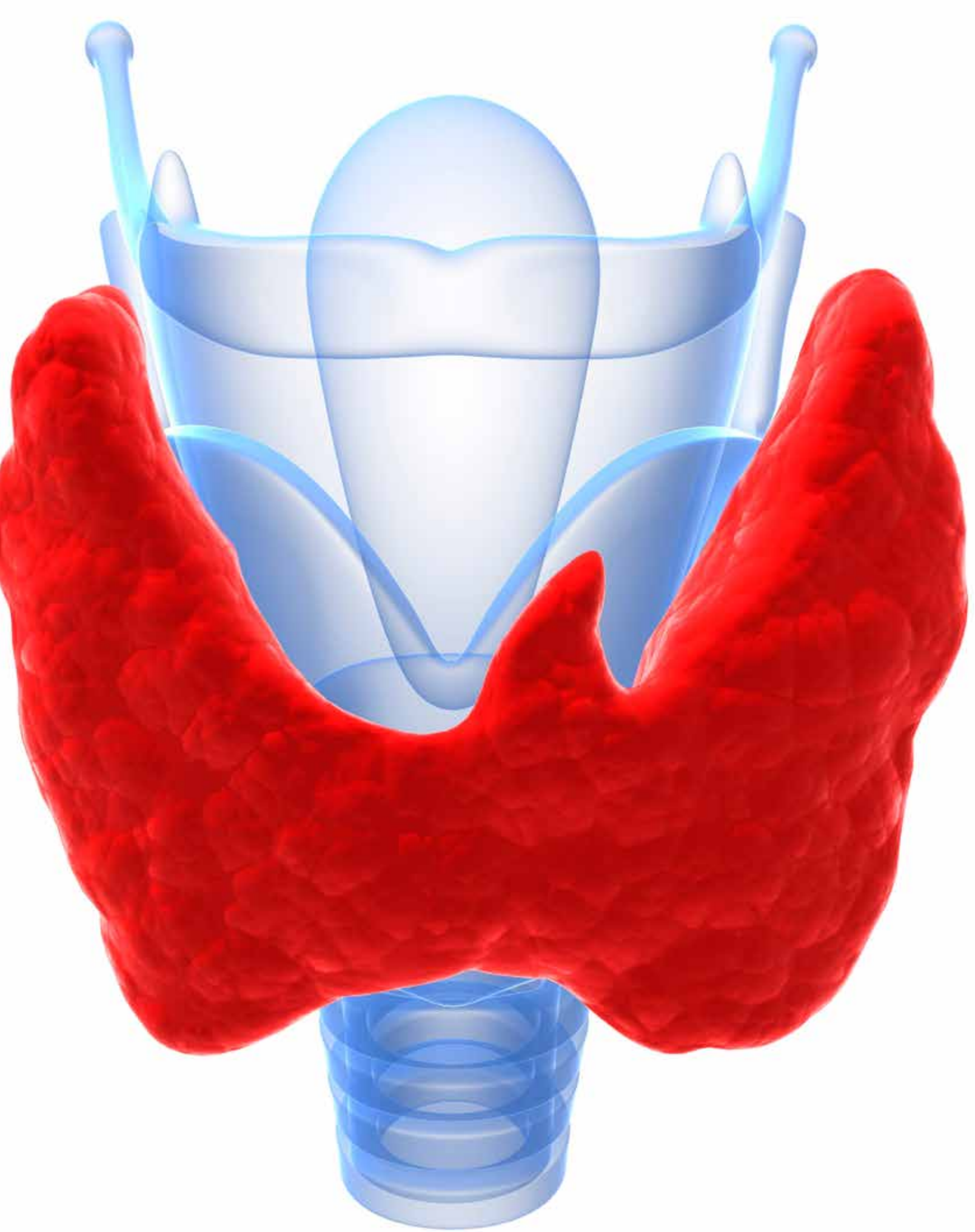

Total Thyroidectomy

CAROLYN MARTINEZ, CST

Hyperthyroidism affects many people in different ways. There are several treatment options that are available depending on the severity and type of hyperthyroidism. For this article, the procedure is based on an elderly woman who was diagnosed with a bilateral thyroid mass and surgical intervention was decided on to remove the thyroid en bloc. The patient had a history of hyperthyroidism and had a known goiter for 20 years. The patient was on medication for hyperthyroidism, but started to have trouble swallowing and felt like she was choking. After completing exams, her doctor determined she was suffering from bilateral thyroid nodules, for which total thyroidectomy was called for.

ANATOMY/PHYSIOLOGY

There are two main causes of hyperthyroidism. The first is Grave's disease, which accounts for approximately 95% of people who are diagnosed with hyperthyroidism. The remaining 5% are usually diagnosed with a condition called nodular thyroid disease.⁵ The thyroid is a gland that is shaped like a butterfly and positioned at the base of the neck. The body's metabolism is regulated by thyroid hormones because it produces two hormones: thyroxine (T-4) and triiodothyronine (T-3). These hormones sustain body temperature, the production of protein and how quickly or slowly the body uses fats and carbohydrates.⁶

The hypothalamus works with the pituitary gland indicating when the gland needs to produce the thyroid stimulating hormone, or TSH. The amount released by the gland is regulated by the amount of T-4 and T-3 in the blood. If there is too much of the hormone, the amount of TSH released will decrease, and if there is too few T-4 or T-3, the amount of TSH will increase, keeping the thyroid balanced. When the thyroid gland is diseased, releasing too little or too much of the

LEARNING OBJECTIVES

- ▲ Examine the technical considerations taken into account for a total thyroidectomy
- ▲ List the instrumentation and equipment needed for this procedure
- ▲ Analyze the procedural steps for this specific case's operation
- ▲ Evaluate the anatomy and physiology related to the thyroid
- ▲ Review the special considerations for an operation involving the thyroid

Equipment

- Suction apparatus
- Electrosurgical unit with dispersive electrode
- Roll or thyroid rest of extending the neck

Instrument

- Thyroidectomy set
- Bipolar forceps with cord
- Ligating clip applicators and clips

Supplies

- Prep set
- Gloves
- Dressing material
- Basic pack
- Blades (#10, #15)
- Basin set
- Suture
- ¼-inch Penrose drain
- Thyroid drapes
- Electrosurgical pencil

**Surgeon's preference will dictate the variance of equipment and instruments used.*

hormones without prompting, the TSH levels will remain too low or too high.⁶ When the thyroid produces too much T-4, a person could acquire an autoimmune disorder named Grave's disease. This disorder is caused when antibodies produced by the immune system encourages the thyroid to make more T-4 than is necessary and is the most widespread cause of hyperthyroidism. With Grave's disease, the immune sys-

tem fails to keep antibodies from attaching to the thyroid, and may even go as far as to allow them to attach to the skin, most often in the shin, which causes Grave's dermatopathy. In 25% of those afflicted with Grave's disease, antibodies attach to the tissue behind the eyes causing Grave's ophthalmology, or GO. Symptoms of moderate to severe GO include eye pain, periorbital edema, changes in color vision, restriction of ocular movement and exophthalmoses. Patients with these symptoms of Grave's ophthalmology must have additional care from an ophthalmologist to determine what additional care they may need in conjunction to traditional treatment for Grave's disease.⁶

Another form of hyperthyroidism is Plummer's disease, or hyperfunctioning thyroid nodule, which occurs when one or more thyroid adenomas produce too much T-4. An adenoma is a lump in the thyroid, which is caused when a part of the gland has enclosed itself from the rest of the gland. These lumps are noncancerous and not all of them produce excess T-4.⁶ While doctors are unsure of why some produce an overload of T-4 and others do not, it

is more prevalent in older hyperthyroidism sufferers. Unlike Grave's disease, there are no other associated issues such as skin or eye ailments.

Surgically removing all or part of the thyroid gland or nodule is another permanent cure for hyperthyroidism. This is not used as frequently as the other treatments. However, there are some patients that will need to have surgical removal of the thyroid because they cannot tolerate medicines, or who refuse radioactive iodine. This type of treatment should provide a long-term cure. A potential downside to the surgical approach is that there is a small risk of injury to structures near the thyroid gland including the nerve to the recurrent laryngeal nerve. This occurs in about 1% of patients.⁷

PREOPERATIVE PROCEDURE

After the room is prepared, the anesthesia is administered and the patient is placed in the supine position with a rolled sheet under the patient's shoulder to slightly hyperextend the neck area. A foam donut is placed under the patient's head and her arms are tucked at her sides with a sheet. A pillow is placed under her knees, and a safety strap is placed across her upper thighs. An electrosurgical pad is placed on the side of the patient's left thigh.

The surgeon enters the operating room and places the subdermal pins in the left and right shoulder of the patient and covers the pins with waterproof transparent dressing. The surgeon draws an outline with a sterile marking pen for a low-collar incision. This is followed by an injection along the outlined site of 1% lidocaine mixed with 1:100,000 epinephrine. A first count is performed followed by the skin prep. In this case, the patient is allergic to iodine so an iodine-free solution is used. Preps begin at the anterior neck, extending just below the lower lip to a level just above the mid-chest and down to the table on each side. The sides of the neck are prepped and both shoulders down to the table. Folded towels are placed on each side of the neck to avoid pooling. Once the skin prep is complete, the patient is draped. A time out is performed.

OPERATIVE PROCEDURE

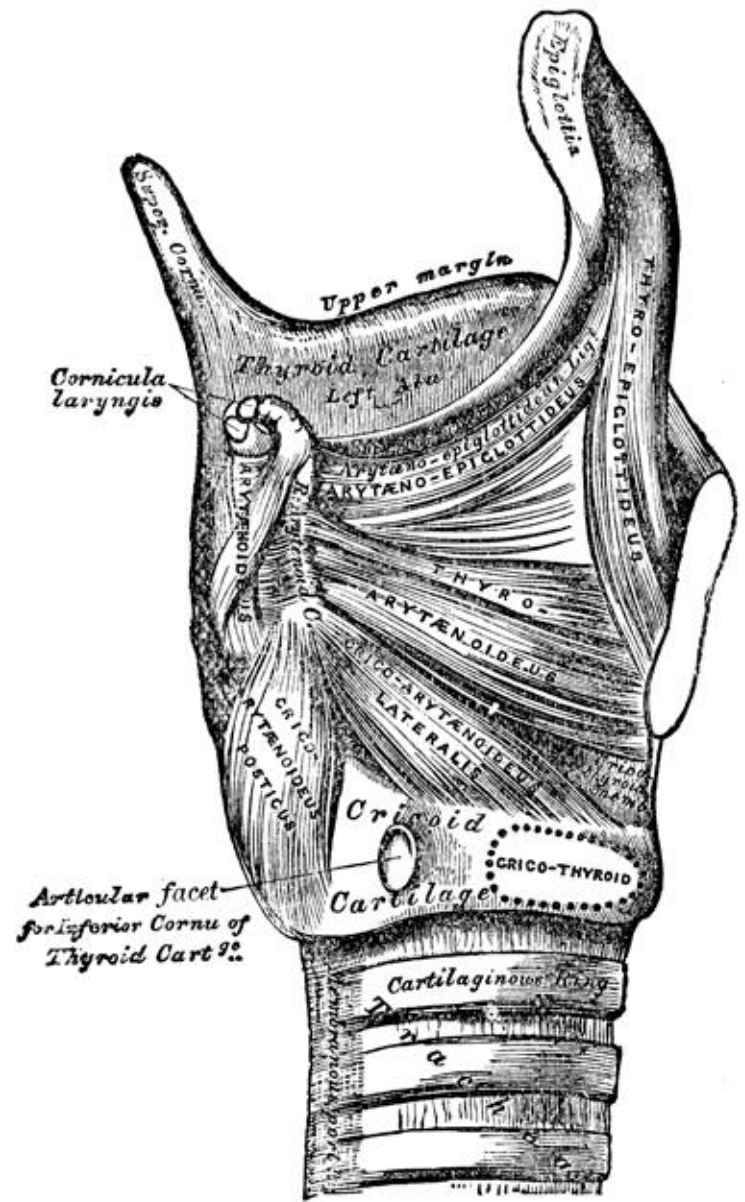
The surgeon requests from the anesthesia provider that the table be placed in a slight reversed Trendelenburg to begin the procedure. The surgical technologist places two X-ray detectable sponges on the field and hands the surgeon a #10 blade which he uses to make the initial incision along a

previously outlined path. This transverse incision is parallel to the normal skin line of the neck, approximately 7cm in length and is carried down through the epidermis, dermis, subcutaneous tissue and platysma. Hemostasis is achieved using the bayonet bipolar and sponges. The surgical technologist prepares double skin hooks and the thyroid retractor is used. Using the skin hooks, the dermis is retracted anteriorly and superiorly to facilitate dissection. A lower flap is undermined to the sternoclavicular joint. A tonsil clamp is used to achieve these flaps. A subplatysma flap is elevated superior to the thyroid notch and inferior to the manubrium. Any bleeding vessels are clamped using the Kelly clamps and ligated with ties.

When the thyroid produces too much T-4, a person could acquire an autoimmune disorder named Grave's disease. This disorder is caused when antibodies produced by the immune system encourages the thyroid to make more T-4 than is necessary and is the most widespread cause of hyperthyroidism.

The thyroid retractor is used to retract the superior and inferior flaps. The surgical technologist hands the surgeon the #15 blade and the surgeon uses this blade to divide the strap muscles along the midline down to the isthmus of the thyroid. The superior aspect of the isthmus and pyramidal lobe is mobilized off the thyroid notch and left attached to the isthmus. This was further freed off the cricoids and first and second tracheal ring. Superiorly the dissections was carried into the left lobe in which the superior aspect of the left lobe was delineated and dissected free of its attachment to the strap musculature and surrounding soft tissue.

The surgeon identifies the superior vessels and ligates them with the harmonic ligator. The remainder of the superior pole, which is extended down to the level of the aorta, is dissected superiorly with superior retraction on the superior pole. The substernal component of the upper mediastinum is identified and the inferior vessels are also ligated with the harmonic ligator. The left lobe is further retracted medially,



which allows for blunt dissection along the tracheoesophageal groove until the recurrent laryngeal nerve is identified.

The superior and inferior parathyroid glands are identified and are left attached to the normal vasculature. The gland is then detached at the lateral thyrohyoid ligament and two Babcock forceps are used to hold the gland. The isthmus is further dissected off the anterior tracheal ring to the junction of the right lobe. The middle vessels, the thyroid's internal maxillary artery, are ligated with the harmonic ligator. The medial aspect of the right lobe is extended even further substernally and the left side is mobilized and ligated. The superior pole on the right was delineated and dissected

using blunt dissection. The vessels are isolated and ligated and further freed off the carotid sheath and prevertebral fascia allowing the superior pole to be used as traction to help facilitate delivering the inferior portion of the thyroid off the substernal thyroid out of the upper mediastinum.

The medial thyroid vein is isolated with blunt dissection using a tonsil clamp and ligated with a harmonic ligator. Further dissection is carried underneath the clavicle into the superior upper mediastinum freeing the thyroid tissue off of the innominate artery and the carotid artery at that junction. This allows for further traction and delivery of the inferior aspect of the substernal thyroid into the neck. The inferior vessels are identified and ligated. The right lobe is then further retracted medially toward the trachea and the recurrent laryngeal nerve is visualized. The gland is detached at the Berry's ligament and the medial vessels are

Another form of hyperthyroidism is Plummer's disease, or hyperfunctioning thyroid nodule, which occurs when one or more thyroid adenomas produce too much T-4.

further delineated and ligated. The entire right and left lobe as well as the isthmus are removed en bloc with a suture placed on the right superior lobe. All pieces that have been removed are placed into a container filled with formalin. Pathology arrives for the specimen container, which also notes the patient's identifying information on the label.

The surgical technologist prepares the active collagen hemostat, which is used for postoperative bleeding. The surgeon uses a medium-size Jackson-Pratt drain, which he or she secures to the upper chest with a 3-0 silk suture. The strap musculature is reapproximated across the midline with 3-0 polyglactin 910. The platysma and subcutaneous tissue is approximated with 3-0 polyglactin 910 and the skin is closed subdermally using 5-0 polyglactin 910. A final count is performed while the surgical technologist prepares one wet and one dry lap sponge for the surgeon.

The surgeon cleans the operative site with the prep solution and adhesive skin closures are used to reinforce the wound closure.

POSTOPERATIVE PROCEDURE

The patient will be transferred to PACU and his or her vitals will be monitored within a few hours of surgery. Immediately after the procedure, the patient will be asked to speak so the medical staff can ensure the laryngeal nerve was not affected during the procedure. The patient will be instructed to clean the site with mild soap before drying and applying clean bandages. A thyroid gland prescription will be issued, and the patient will take this for the duration of his or her life. The patient will be instructed to use over-the-counter medication such as acetaminophen or ibuprofen if he or she experiences any pain. A follow-up appointment will be scheduled two weeks from the time of the discharge to remove the sutures. Typically following this type of procedure, a patient should be able to resume normal activities after a few weeks of rest.¹

SPECIAL CONSIDERATIONS/COMPLICATIONS

Special considerations for this type of procedure pertain to potential airway obstruction. When the patient is taken to PACU, a tracheostomy tray may go along with the patient due to the risk of an airway obstruction from hematoma, or possibly edema of the glottis or surrounding tissue.⁴ Due to this risk, the surgical technologist needs to be prepared to perform a tracheostomy while the patient is still in the operating room.

Complications from this procedure include numbness or tingling around the lips, hands and bottom of feet, muscle cramps and spasms, headaches, pain when swallowing and neck stiffness. These symptoms usually subside within a day or two following surgery, with a low percent of patients experiencing such symptoms for longer than 72 hours.

Damage to the laryngeal nerves also is a concern. "In an estimated 1 out of every 250 thyroid surgeries, damage is done to the laryngeal nerves, the nerves that control the voice."¹⁰ If damage does occur, these symptoms include difficulty projecting the voice, hoarse voice, voice fatigue and decreased vocal range. Voice changes are usually temporary and the voice typically returns to normal within a few weeks. It is rare that voice changes become permanent.



ABOUT THE AUTHOR

Author's Note: This article is dedicated in loving memory of my father, who passed away in November 2007. His passing motivated me to change professions, going from the banking and mortgage industry to the medical field.

To my mother and my wife, who never doubted my determination to go back to school 22 years after graduating college, in order to feel like I could make a difference. Thank you.

Carolyn Martinez, CST, lives in Fresno, California. She graduated from the surgical technology program at San Joaquin Valley College in Fresno, making the Dean's List all four terms. She then worked as a CST at Clovis Community Medical Center for two years before becoming a surgical technology instructor at San Joaquin Valley College in July 2013.

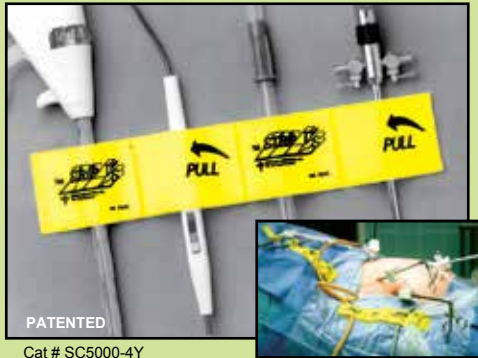REFERENCES

1. DeBakey, M. (2010) Thyroidectomy. Retrieved March 25, 2011. <http://www.debakeydepartmentofsurgery.org>
2. Evans, A. Total thyroidectomy preference card. (2011) Unpublished surgical preference card. St Agnes Medical Center.
3. Frey, K. (2008) Surgical technology for the surgical technologist. A positive care approach. 3rd edition. New York. Delmar Cengage Learning. 482-484.
4. Golden, M. (2008). Pocket guide to the operating room. 3rd edition. FA Davis.
5. Health Information Publications. (2011) What causes hyperthyroidism? Retrieved March 20, 2011. <http://ehealthmd.com>
6. Mayo Clinic Staff. (2010) Hyperthyroidism (overactive thyroid). Retrieved March 20, 2011. <http://www.mayoclinic.com>
7. Norman, J. (2010) Hyperthyroidism overactivity of the thyroid gland. Retrieved March 26, 2011. <http://www.endocrineweb.com>
8. Rothrock, J. (2007) Alexander's care of the patient in surgery. Mosby Elsevier.
9. St Agnes Medical Center, Patient Card. (2011) Unpublished patient chart, patient name excluded due to HIPPA regulations.
10. Shomon, M. (2007) Thyroid disease complications after thyroid surgery. Retrieved March 25, 2011. <http://thyroid.about.com>



Sterile Adhesive Organizer

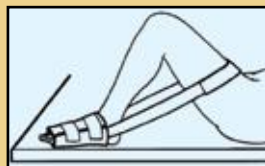
FAST • EASY • SECURE • VERSATILE



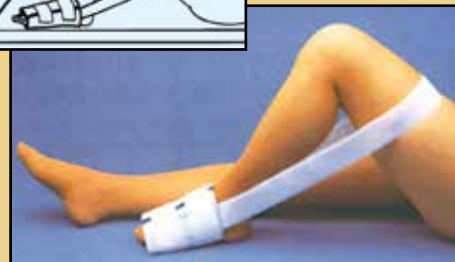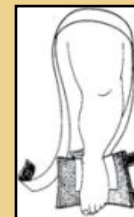- Latex free self-adhesive back - for attachment to the surgical field
- Keeps sterile appliances from hitting the floor
- Economical - Easy to use
- Saves pre-op time. Can be used on every surgery.
- Several sizes and configurations. Yellow or Red Iridescent color for laser surgery.
- Sterile shelf life 2 years
- Call for FREE samples

Surgical Knee Immobilizer

- Secure flexion & extension stabilization
- Easy hook & loop closure and adjustment
- Frees surgical practitioner's hands to retract soft tissue
- Economical Solution
- Sterile & disposable
- Single use only - no need for re-sterilization



PATENTED
CAT#KS-9930



KAPP SURGICAL INSTRUMENT INC.
4919 Warrensville Center Rd, Cleveland Oh 44128
Phone 216-587-4400 / Fax 216-587-0411 / 800-282-5277
www.kappsurgical.com / info@kappsurgical.com

ISO
13485 : 2003

Total Thyroidectomy

368 AUGUST 2014

1 CE credit - \$6

1. **Ninety-five percent of people who suffer from effects of hyperthyroidism have been inflicted with this disease?**
 - a. Nodular thyroid disease
 - b. Tumors
 - c. Grave's disease
 - d. Parkinson's disease
2. **In Grave's disease, 25% of patients suffer from antibodies that attach to the tissue behind the _____.**
 - a. Ears
 - b. Eyes
 - c. Nose
 - d. Knees
3. **This is caused when a part of the gland has enclosed itself from the rest of the gland.**
 - a. Adenoma
 - b. T-3 is overproduced
 - c. T-3 is underproduced
 - d. T-4 is underproduced
4. **The patient is placed in what position at the beginning of this procedure?**
 - a. Lateral
 - b. Prone
 - c. Supine
 - d. Midline
5. **Using the skin hooks, the dermis is retracted _____ and superiorly to facilitate dissection.**
 - a. Superiorly
 - b. Anteriorly
 - c. Distally
 - d. Inferiorly
6. **The superior pole is extended down to the level of the _____.**
 - a. Atrium
 - b. Aorta
 - c. Cricoids
 - d. Trachea
7. **_____ is used along the tracheoesophageal groove until the recurrent laryngeal nerve is identified.**
 - a. Ligation
 - b. Suture
 - c. Tracing
 - d. Dissection
8. **Complications from this type of procedure may include:**
 - a. Voice fatigue
 - b. Headaches
 - c. Neck stiffness
 - d. All of the above
9. **Babcock forceps are used to hold the _____.**
 - a. Superior gland
 - b. Parathyroid gland
 - c. Superior parathyroid gland
 - d. Inferior gland
10. **A pillow may be used to prop up the patient's _____.**
 - a. Head
 - b. Knees
 - c. Thighs
 - d. Ankles

TOTAL THYROIDECTOMY 368 AUGUST 2014 1 CE CREDIT - \$6

NBSTSA Certification No. _____

AST Member No. _____

My address has changed. The address below is the new address.

Name _____

Address _____

City _____ State _____ Zip _____

Telephone _____

Check enclosed Check Number _____

Visa MasterCard American Express

Credit Card Number _____


Expiration Date _____

	a	b	c	d
1	<input type="checkbox"/>	<input type="checkbox"/>	<input type="checkbox"/>	<input type="checkbox"/>
2	<input type="checkbox"/>	<input type="checkbox"/>	<input type="checkbox"/>	<input type="checkbox"/>
3	<input type="checkbox"/>	<input type="checkbox"/>	<input type="checkbox"/>	<input type="checkbox"/>
4	<input type="checkbox"/>	<input type="checkbox"/>	<input type="checkbox"/>	<input type="checkbox"/>
5	<input type="checkbox"/>	<input type="checkbox"/>	<input type="checkbox"/>	<input type="checkbox"/>
6	<input type="checkbox"/>	<input type="checkbox"/>	<input type="checkbox"/>	<input type="checkbox"/>
7	<input type="checkbox"/>	<input type="checkbox"/>	<input type="checkbox"/>	<input type="checkbox"/>
8	<input type="checkbox"/>	<input type="checkbox"/>	<input type="checkbox"/>	<input type="checkbox"/>
9	<input type="checkbox"/>	<input type="checkbox"/>	<input type="checkbox"/>	<input type="checkbox"/>
10	<input type="checkbox"/>	<input type="checkbox"/>	<input type="checkbox"/>	<input type="checkbox"/>

Make It Easy - Take CE Exams Online

You must have a credit card to purchase test online. We accept Visa, MasterCard and American Express. Your credit card will only be charged once you pass the test and then your credits will be automatically recorded to your account.

Log on to your account on the AST homepage to take advantage of this benefit.



Earn CE Credits at Home

You will be awarded continuing education (CE) credits toward your recertification after reading the designated article and completing the test with a score of 70% or better. If you do not pass the test, it will be returned along with your payment.

Send the original answer sheet from the journal and make a copy for your records. If possible use a credit card (debit or credit) for payment. It is a faster option for processing of credits and offers more flexibility for correct payment. When submitting multiple tests, you do not need to submit a separate check for each journal test. You may submit multiple journal tests with one check or money order.

Members this test is also available online at www.ast.org. No stamps or checks and it posts to your record automatically!

Members: \$6 per credit

(per credit not per test)

Nonmembers: \$10 per credit

(per credit not per test plus the \$400 nonmember fee per submission)

After your credits are processed, AST will send you a letter acknowledging the number of credits that were accepted. Members can also check your CE credit status online with your login information at www.ast.org.

3 WAYS TO SUBMIT YOUR CE CREDITS

Mail to: AST, Member Services, 6 West Dry Creek Circle Ste 200, Littleton, CO 80120-8031

Fax CE credits to: 303-694-9169

E-mail scanned CE credits in PDF format to:
memserv@ast.org

For questions please contact Member Services - memserv@ast.org or 800-637-7433, option 3. Business hours: Mon-Fri, 8:00a.m. - 4:30 p.m., MT

Studying for the CST Exam? There's an App for That

The only AST-authored study guide with more than 1,400 questions has gone mobile! AST recently published its first app – AST Study Guide – and it's available in the iTunes Store and Google Play.

The app includes six tests to review and utilize while preparing for the CST examination sponsored by the National Board of Surgical Technology and Surgical Assisting. Now, all the study tips are conveniently in the palm of your hand.

Study with confidence whenever and wherever you are!

