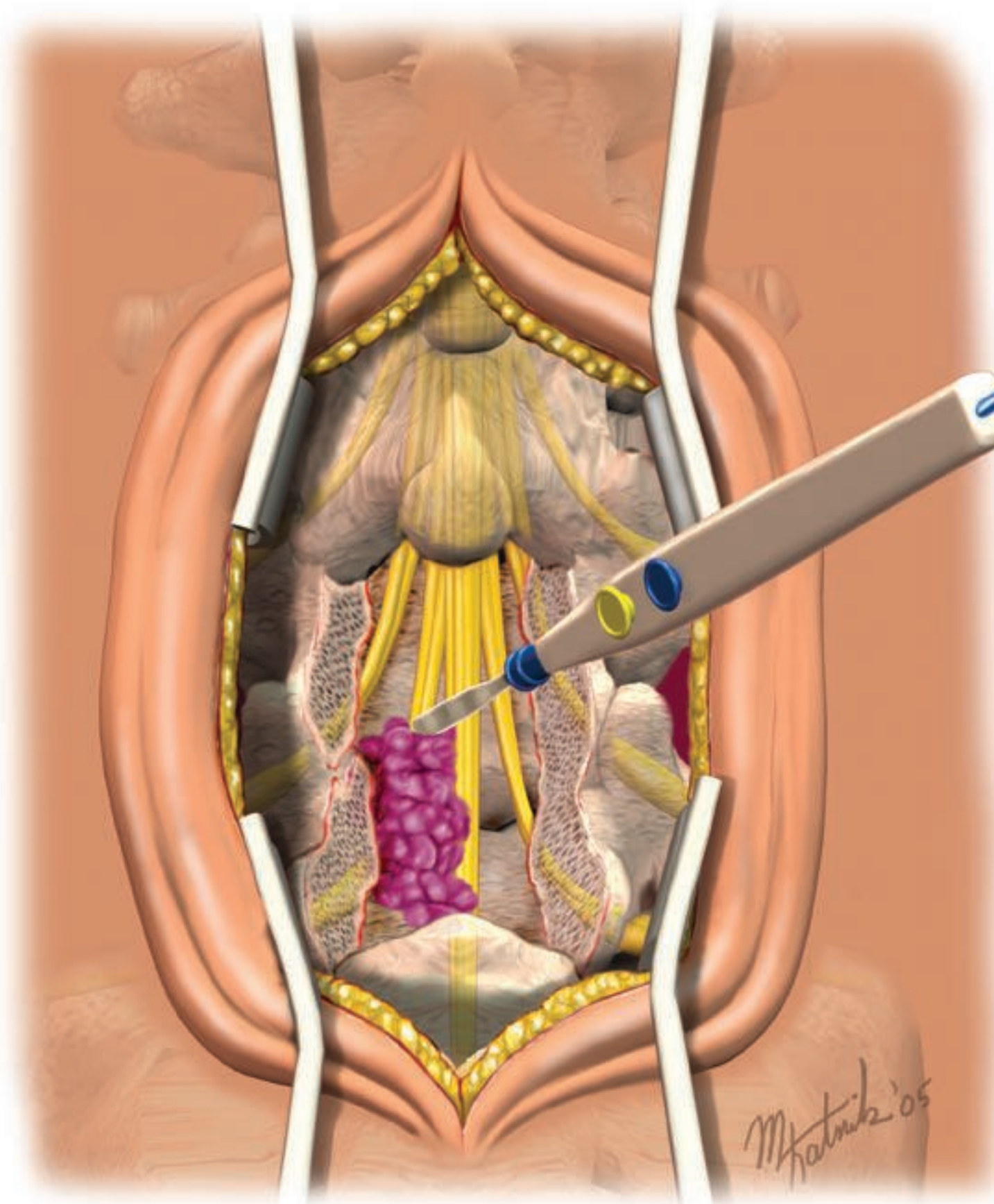

M. Hatnik '05

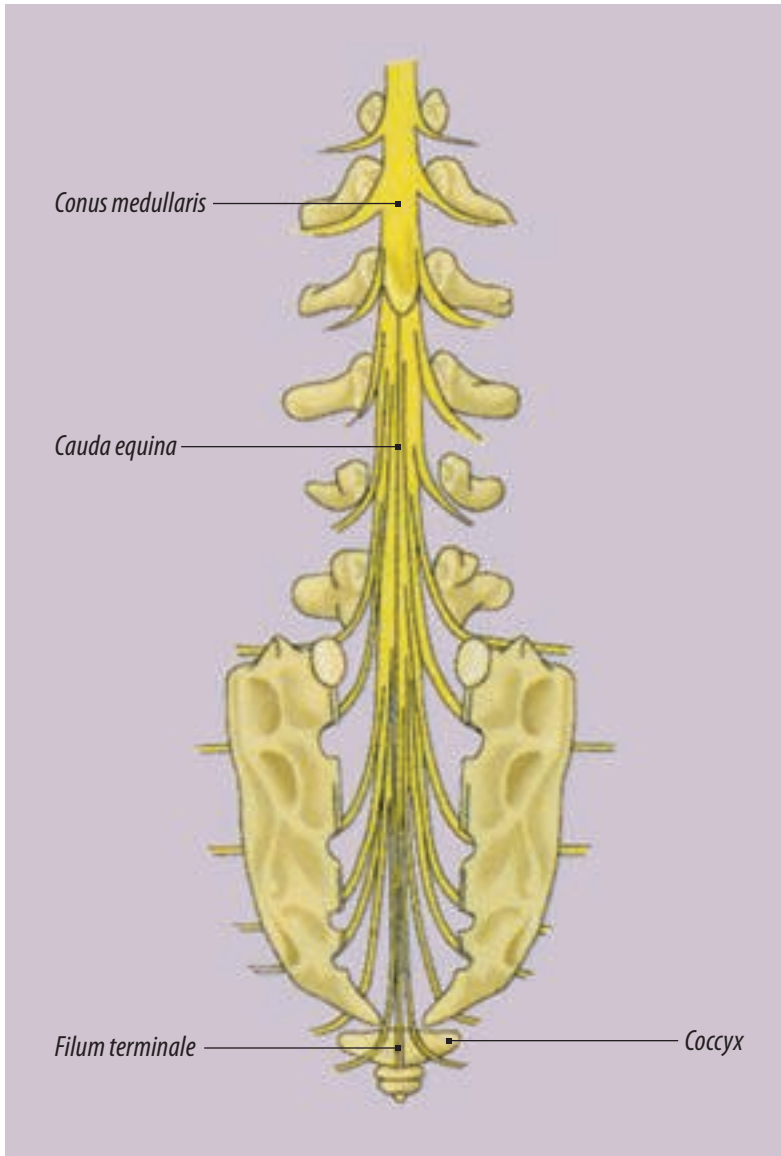
CAUDA EQUINA LIPOMA RESECTION WITH SPINAL CORD UNTETHERING IN AN ADULT

JEFFREY J CORTESE, CST, BHSA

Normally the spinal cord is a freely moving structure within the spinal canal. The term “tethered spinal cord” describes a condition in which the spinal cord is abnormally fastened to an immovable structure, such as a lipoma, vertebra, dura or skin. Although often initially asymptomatic, any lesion that tethers the spinal cord puts the individual at risk of eventual neurological dysfunction. This dysfunction may occur during periods of axial growth in children or during periods of adipose deposition, which in the case of tethering may cause lipomatous structures to enlarge. Although the signs and symptoms may include pain, most often they include loss of control of bowel or bladder, loss of sensation in the feet, or motor dysfunction in the sacral and lower lumbar segments. Surgical intervention of any of the lesions is directed at release of the tethering. One such case is presented in this article.

Spinal cord anatomy

The spinal cord is a cylindrical bundle of nerve pathways that is 42 to 45 cm long and 2.5 cm wide in the normal adult. Its rostral (cranial) end is continuous with the brain stem, whereas the distal end forms a conical tapering, the conus medullaris. This is usually located at the border of the first lumbar vertebrae. On occasion, it may reach only to the body of T12 or extend to the L2 level in the adult. From the conus medullaris, the lumbar and sacral nerve roots descend in a bundle known as the cauda equina. The most terminal portion of the spinal cord is the filum terminale. This connective tissue filament extends from the tip of the conus medullaris and attaches to the first segment of the coccyx (Figure 1). At birth, the conus medullaris is located near the L3 vertebrae; in the adult, it sits between the L1 and L2 vertebrae and occupies only the upper two-thirds of the vertebral canal.



Reprinted from *Surgical Technology for the Surgical Technologist: A Positive Care Approach*, Thomson-Delmar Learning, ©2004.

FIGURE 1:
Spinal cord
anatomy.

The 31 pairs of spinal nerves associated with localized regions of the spinal cord produce external segmentation. On this basis, the spinal cord is considered to consist of 31 segments, each of which is traversed by paired dorsal and ventral root filaments (Figure 2).

Physiology

Neurons, glia, and pia mater have their own elasticities and viscosities. The interlacing fibers of these tissues resist traction in the longitudinal direction. If the traction is sufficient to stretch the spinal cord, the viscoelasticity of each structure can provide some protection to neurons, and glia cells and can help maintain neuronal function.

Thickened filum terminale

The most elementary form of tethering of the spinal cord occurs when the filum terminale is excessively thickened.² In these cases, the filum terminale is often infiltrated with fatty tissue. Normally the filum is a fibrous structure that is a continuation of the arachnoid, which becomes the conus medullaris. A diameter greater than 2 mm, excluding fatty elements, is considered abnormal.⁵

Lipoma

Even though lumbosacral lipomas account for 29% of occult spinal dysraphisms, the embryological development of spinal cord lipoma is not well understood.⁴ As in other forms of spinal dysraphism, normal elements are present, but are found in abnormal locations. One hypothesis is that disruption occurs during embryological development after the neural tube is formed, and subcutaneous fat is allowed to herniate into the region of the neural tube. The lipomatous tissue fuses with the neural tissue, and the resulting lipoma tethers the spinal cord. Tethering may result in neurological dysfunction.

The frequency of fat infiltrate within the filum terminale has been identified by several authors as described by Marchiori and Firth. Emery and Lendon found fat infiltrate in 4% to 6% of normal adult subjects at postmortem. Modic et al reported that 5% of the population exhibits this condition, and Guiffre identified the condition in less than 2%.⁵

Symptoms

The symptoms of adult tethered cord syndrome (TCS) have been described previously by Chapman.¹ The predominant symptom of adult TCS is pain in the lower back and legs that is exacerbated by physical activity, particularly flexion and extension of the lumbar spine. In practically all-adult patients with TCS, lower back and leg pain is characterized by the “three B signs.” These are: inability to sit with their legs crossed (like *Buddha*); difficulty *bending* slightly over the sink for dishwashing, or the podium while preaching or teaching classes;

and difficulty holding a *baby* or light object (5 lb or less) at waist level while standing.¹

Neurologic signs are motor and sensory deficits in the lower extremities, hyporeflexia of one or more tendons, increased urinary retention, and musculoskeletal deformities. These include scoliosis, hyperlordosis, and deformities of the lower extremities, such as atrophy, hammertoes, and high-arched feet.¹

Differential Diagnosis

Chapman described a vast array of differential diagnoses and other possible causes of symptoms that must be ruled out. These include:¹

- intrinsic spinal cord tumors (ependymomas, astrocytomas)
- multiple sclerosis
- lumbosacral syringomyelia
- arteriovenous malformations
- poliomyelitis
- an epidural or intradural mass compressing the spinal cord, such as schwannomas, neu-

- rofibromatosis, meningiomas, dermoid or epidermoid tumors
- polyneuropathy or isolated peripheral neuropathy
- incomplete forms of viral infection of the peripheral nerve
- Guillain-Barre
- early stages of degenerating diseases and familial spastic paraplegia
- any disorder that causes incontinence
- scoliosis of other etiology, such as tuberculosis of vertebrae and epidural space
- congenital or acquired deformities due to musculoligamentous or bony abnormalities, particularly those of the lumbar vertebrae
- articular facets that cause referred pain in the groin, buttock, or greater trochanteric area
- skeletal system disorders, such as herniated disc (Table 1), spondylosis, spondylolisthesis, osteoarthritic spondylosis, and lumbar canal stenosis

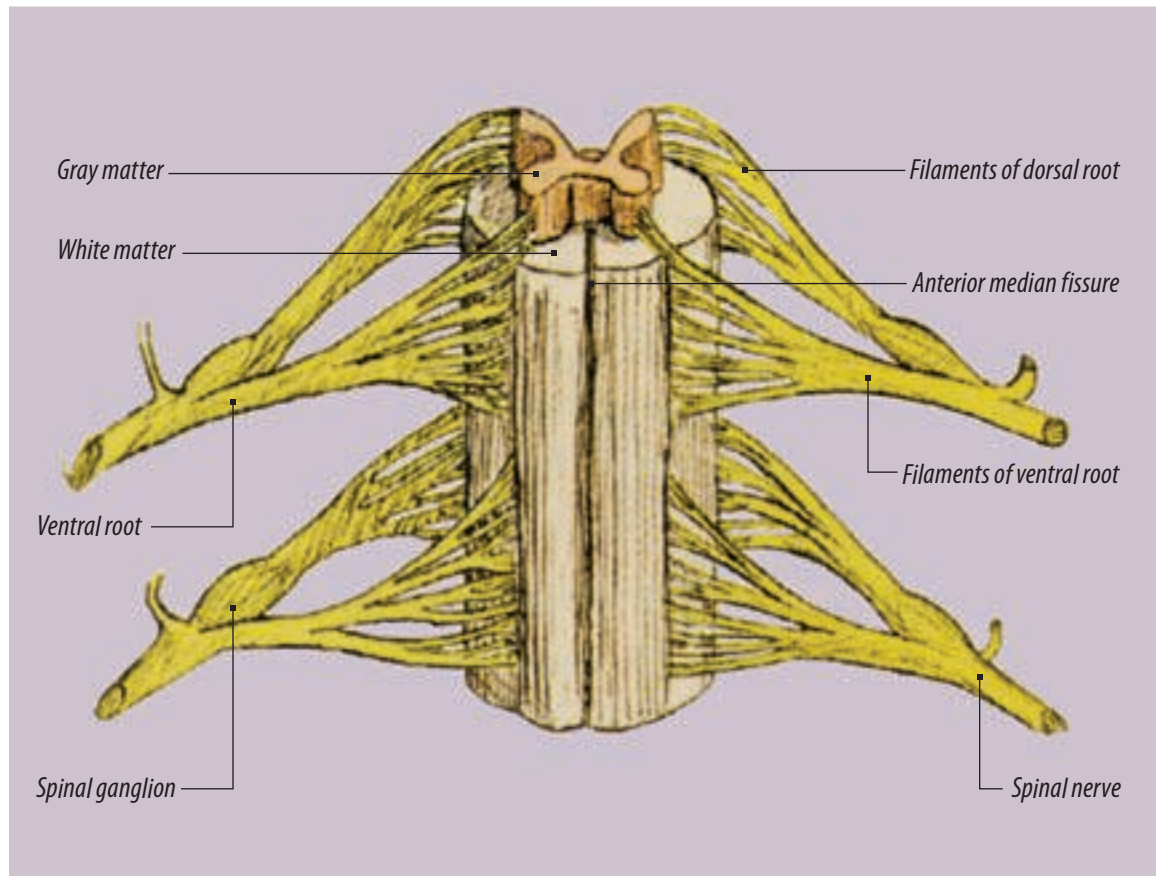


FIGURE 2:
Anterior view
of the spinal
cord.

Imaging studies

Imaging studies are useful for making the diagnosis of TCS: plain film studies, MRI, and myelography combined with CT and ultrasonography. Magnetic resonance imaging is currently the most useful imaging study for patients with TCS. There are several imaging clues used to help in the diagnosis:

- a thick filum terminale (>2 mm in diameter),
- the presence of structures that suggest lack of viscoelasticity, such as fibroadipose tissue in the filum terminale, and obliteration of the subarachnoid space, which suggests adhesion around the caudal spinal cord or nerve roots
- an elongated spinal cord
- a posteriorly displaced conus medullaris or filum, directly attached to the posterior thecal lining at or near the L5 lamina

A capacious sacral subarachnoid space is found in 50% of patients and is associated with posterior displacement of the filum.⁴ During the opera-

tion, the dura is found to be significantly thinner than in normal individuals.

Surgical technique

The surgical release of the tethered cord presents a challenge to even the most experienced neurosurgeon. Complete understanding of the anatomy involved and meticulous microsurgical techniques are called upon.

The goal of surgery is to release the tethered neural elements and reduce the bulk of the associated lipoma.¹ This is more easily achieved in dorsal or caudal lesions than with traditional ones. With the latter, the presence of important neural elements within the lipoma may make it impossible to safely achieve complete untethering.

The risk of neural injury is also affected by the confusing relationships between neural elements, lipoma, and the extent of the dural defect in cases of extensive lateral asymmetry of the lesion with distortion of the conus. In such cases, there is little normal anatomy to provide the surgeon with adequate intraoperative orientation. The surgeon must rely on neurophysiological monitoring techniques to avoid neural injury.

The patient is administered general anesthesia via endotracheal intubation, and a Foley catheter is placed. He or she is rotated into the prone position onto a well-padded operating table fitted with a Wilson frame or a similar type of device. Extreme attention is paid to the protection of all pressure points, as the surgery can last several hours. If needed, the head can be suspended in a Mayfield or Sugita head-holding device to reduce the risk of direct intraocular pressure. The patient should receive 1 gram of Cefazolin, 2 grams of Solumedrol, 250 cc of 20% Mannitol, and 40 mg of Lasix prior to the incision. Continuous monitoring of the somatosensory evoked potential (SSEP), as well as the motor evoked potentials (MEP) should be employed during the resection of the lipoma due to dissection around vital nervous structures.

The patient is prepped and draped in the usual sterile fashion. A preliminary radiograph may be obtained to reduce the length of the incision. A midline incision is made with a #20 blade

FIGURE 3:
Bipolar
coagulation
of epidural
vessels.

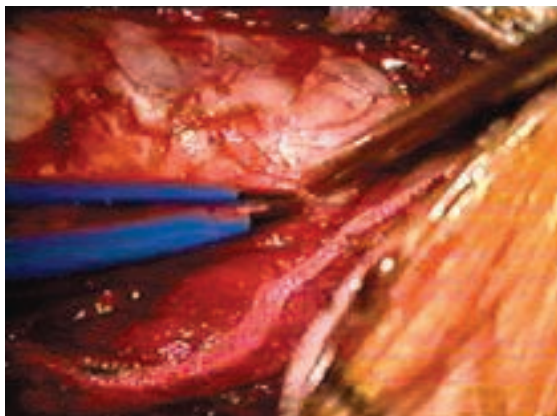
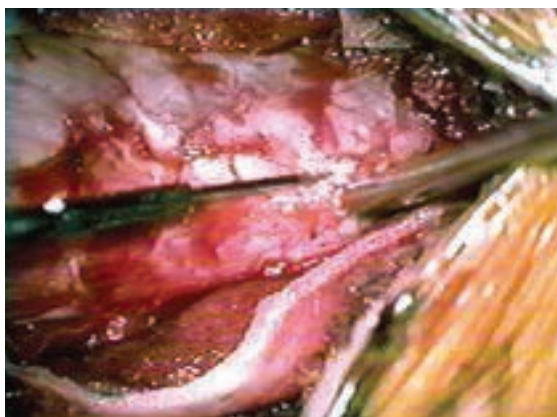


FIGURE 4:
Durotomy
started at
upper level
of lipoma.



centered over the operative site. Monopolar electrosurgery is used to obtain hemostasis and is used to carry the dissection to the fascia. Two curved Weitlaner retractors are placed into the wound. The fascia is opened in the midline with the electrosurgical pencil. Subperiosteal dissection is further carried out from the spinous processes to the facets of each vertebra bilaterally utilizing monopolar electrosurgery and periosteal elevators. Once sufficient soft tissue exposure has been achieved, the Weitlaner retractors are replaced with a bilateral self-retaining Meyerding retractor.

A bilateral laminectomy is performed first by removing the spinous processes with a Leksell or Stille-Horsley rongeur. The extent is determined by the amount of removal that will adequately expose the conus medullaris and filum terminale. Any bone bleeding can be controlled with the application of bone wax. Finer removal of the lamina is achieved by using a Kerrison rongeur and a high-speed drill where necessary. The laminectomy is carried laterally as far as the facet joints. If needed, a minimal facetectomy may be performed to gain adequate exposure of the dura. Attention must be paid not to remove too much facet, as that level will become unstable and will require a fusion arthrodesis. After fine hemostasis is achieved with bipolar electrosurgery, the intradural portion of the operation will begin.

Intradural phase

A well-balanced surgical microscope is brought into the field. Any small epidural vessels are coagulated and divided using bipolar electrosurgery and microscissors (Figure 3). A durotomy is performed using a micro #11 blade (Figure 4). An arachnoid plane is created between the dura and arachnoid using a blunt Rhoton micro-nerve hook. Care must be taken when dissecting, as the lipoma will sometimes be situated at the location of the durotomy. Once the arachnoid has been opened, a surge of cerebral spinal fluid (CSF) will escape from the durotomy, and the spinal cord will relax (Figure 5). Further opening of the dura is carried out superior and inferior to the lipoma with the aid of the arachnoid knife and

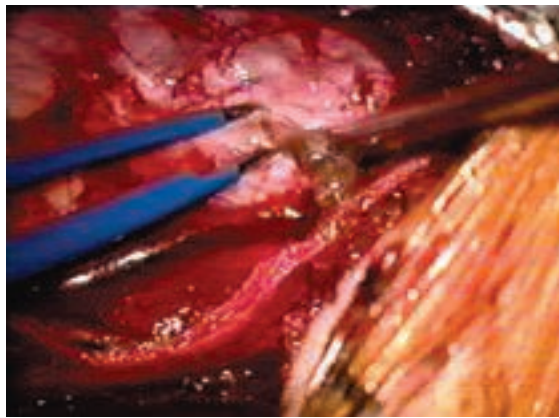


FIGURE 5: Surge of CSF seen as arachnoid membrane is punctured with bipolar forceps.

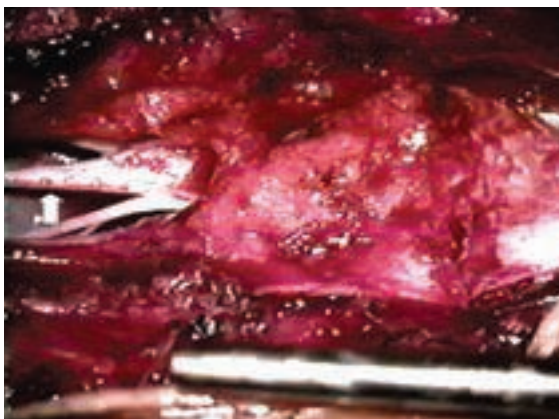


FIGURE 6: Overall image of lipoma and tethered cord.

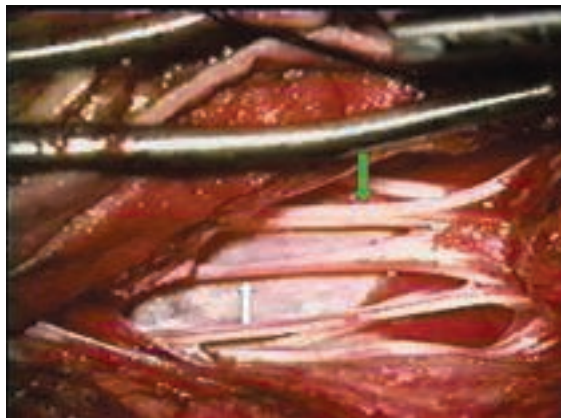
microscissors. Any small bleeding points on the edges of the dura are coagulated with the bipolar unit. Tacking sutures of 4-0 braided nylon on a taper needle are used to hold open the dura at the edges. These are tagged with mosquito hemostats and secured to the surgical drapes.

Once sufficient exposure of the lipoma has been created, attention is directed to the identification of normal anatomy within the thecal sac. The microscope is used to identify the lowest coccygeal nerve root exit and to confirm the junction of the spinal cord and filum (Figure 6). The nerve roots are usually grossly displaced by the lipoma, making identification tedious and difficult. Bipolar stimulation of suspected nerve roots confirmed by spinal cord monitoring would help distinguish the normal anatomy from the lipoma or thickened arachnoid (Figure 7).

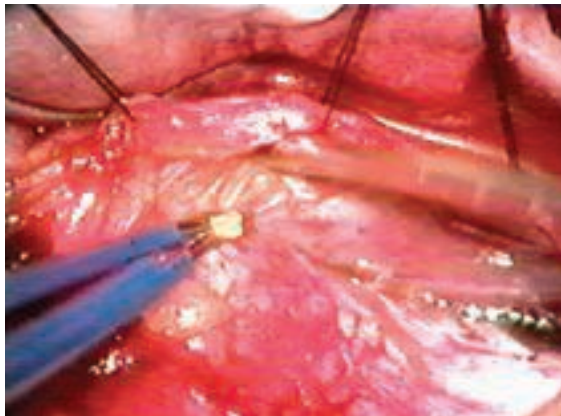
Once the nerve roots have been successfully identified, resection of the lipoma is carried out using a 36 kHz ultrasonic aspirator with a 1.5-2 mm tip, such as the CUSA EXel™. Since the lipoma is mostly water, the tumor will appear

FIGURE 7:

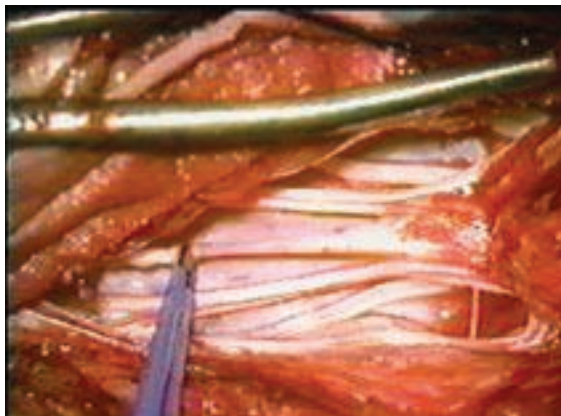
Filum terminale (white arrow) and cauda equina with sacral nerve roots (green arrow).

**FIGURE 8:**

Bipolar coagulation of lipoma to reduce the overall bulk of the tumor.

**FIGURE 9:**

Bipolar coagulation of filum terminale prior to transection with microscissors.



to vaporize with the application of the CUSA. Alternatively, a CO₂ laser with an energy level of 6 to 15 W can be utilized to debulk the tumor. Yet, another method of debulking is the use of bipolar forceps and microscissors to dissect the lipoma away from the spinal cord (Figure 8).

Any blood vessels encountered in the resection can be coagulated with the 0.5 mm tip bipolar forceps and transected with microscissors. Resection is carried out as close to the spinal cord and nerve roots as possible. Once inelastic-

ity of the filum is confirmed, the filum is carefully transected using bipolar electrocautery and the micro scissors (Figure 9). If the anterior spinal artery and vein encountered are larger than 500 μm, they are left intact. Resection of a 0.5 cm long filum will prevent scar formation from bridging the two sectioned ends, later resulting in cord retethering.

The wound is copiously irrigated with saline containing a Bacitracin antibiotic. The arachnoid and dural layers are closed with a watertight, continuous, locking suture of 4-0 braided nylon on a taper needle. Fibrin glue or a dural matrix (DuraGen®) may be placed on the suture line to further inhibit CSF leakage. The retractors are removed, and fine hemostasis is achieved with mono- and bipolar electrocautery.

Each layer is irrigated with the Bacitracin antibiotic solution on the way out. The fascia is approximated with 0 polyglactin 910 on a taper needle in an interrupted fashion. The subcutaneous and subcuticular layers are closed by an interrupted suture of 3-0 polyglactin 910 suture on a cutting needle. Any skin irregularities are corrected with 5-0 plain gut. A sterile dressing is applied, and the patient is rotated back onto the gurney.

Surgical complications

Skandar et al reported in 2001 on the release of TCS in 34 adults. The authors studied the hospital records of 34 consecutive patients who presented in adulthood with tethered cord syndrome and conducted follow-up phone interviews with 28 of them.

Long-term surgical results and patient outcome ratings were encouraging in these patients. After a mean clinical follow-up period of four years, significant improvement occurred in 22 of 27 patients presenting with pain, 13 of 27 patients with motor or sensory dysfunction, and 11 of 18 patients with bowel and bladder disturbance. In addition, telephone interviews were obtained after a period of 8.6 years.

Twenty-two (79%) of 28 patients called the operation a long-term success; 21 (75%) of 28 patients believed that they had significant post-

operative improvement, not just stabilization, in pain and/or neurological function.

Surgical complications were generally minor. Among these complications included one cerebrospinal fluid leak and five pseudomeningoceles. Two patients complained of worsening motor or sensory dysfunction and one of worsening bladder dysfunction, whereas four patients experienced persistent pain and one complained of worsening pain postoperatively. According to the patients, the vast majority of these complications were minor.

Conclusion

It is commonly believed that children who have a congenital tethered spinal cord benefit from surgical untethering because it prevents neurological deterioration. However, controversy has surrounded the issue of surgery in newly diagnosed adult patients. The incidence of occult spinal dysraphism is unknown and, although it is likely that some patients remain asymptomatic, a diagnosis is never made. A subset of patients with the congenital syndrome develops progressive symptoms and signs in adulthood. Such deterioration may occur after sudden movements

that cause traction on the spinal cord. These may include bending movements, the lithotomy position during childbirth, movement occurring during motor vehicle accidents, and others.

In adult patients, intradural structures are frequently scarred and surrounded by significant arachnoidal adhesions that are very likely to contribute to the patient's symptoms; this scarring is often severe enough to make it more difficult to dissect the edge of the spinal cord from the surrounding dura. In addition, the anatomy may be very unusual and confusing. Therefore, caution should be exercised during the dissection, and preoperative computerized tomography and magnetic resonance images must be studied very carefully before surgery.

The risks of surgery must be weighed against the potential benefit to the patient. In cases in which there is documented clinical deterioration, there is little question about the advisability of operative treatment. In cases of patients who are asymptomatic or have long standing stable neurological deficits, there is greater controversy regarding the usefulness of prophylactic surgery.

TABLE 1. Differential Diagnosis: Herniated disc vs. tethered cord syndrome

Herniated disc	Tethered cord syndrome
Radiating pain in a dermatomal pattern	Pain extending to various locations: medial, lateral, anterior, and posterior
Pain rare in the groin or rectum	Pain in groin or rectum common
Aggravation by coughing, sneezing	Coughing, sneezing have no effect
Little effects of three "B" postures	Three "B" postures aggravate pain (100% of patients)
Pain relief by slouching, worse by sitting straight	Prefer sitting straight to slouching
Pain relief after lying supine on hard bed	Aggravation after sleeping supine
Motor dysfunction in 1 or 2 myotomes	Wide distribution without a simple myotomal pattern
Dermatomal deficit (1 or 2)	Patchy distribution; perineal hyperalgesia
Incontinence rare, except with midline hernia	Urinary or rectal incontinence common
Aggravation by straight leg-raising	No effect of straight leg-raising test
No specific deformity	Exaggerated lordosis; high arched feet; difference in size of legs or feet

Acknowledgments

I wish to thank my fiancé, Jennifer N Prigg, DO, for her support and companionship throughout the past two years. I wish, as always, to thank, John L Zinkel, MD, PhD, FACS, for his support and friendship throughout the past 11 years.

About the author

Jeffrey J. Cortese, CST, BHSA, has been a certified surgical technologist for since 1996. A graduate of Baker College-Mt Clemens Campus, Cortese is employed at Upper Cumberland Physicians Surgery Center in Cookeville, Tennessee, and Livingston Regional Hospital in Livingston, Tennessee. Jeff earned his bachelor's of health service administration degree from Baker College in Clinton Township, Michigan, in May 2005.

References

1. Chapman P. Spinal Lipoma Controversy. *Neurosurgery*. January 1999;44: 186-193.
2. Flannery AM. Diagnosis and Surgical Treatment of Congenital Lesions of the Nervous System. In: MB Allen, Jr and RH Miller, eds. *Essentials of Neurosurgery, A Guide to Clinical Practice*. New York: McGraw-Hill, Inc; 1995:121-131.
3. Intraoperative participation and discussion of presented surgical case with John L Zinkel, MD, PhD, FACS
4. Koch SE, Koch TK, and Edwards MS. A subtle sign of spinal cord lipoma. *Clinical Pediatrics*. March 1995; 34(3):156-7.
5. Marchiori DM and Firth R. Tethered Cord Syndromes. *Journal of Manipulative & Physiological Therapeutics*. May 1996; 19(4): 265-267.
6. Skandar JI, Fulmer BB, Hadley MN, & Oakes WJ. (2001). Congenital spinal cord syndrome in adults. *Neurosurgery Focus*. 10(1): Article 7.



Ready, Set PASS!



The Self-Assessment Exam

Find out how ready YOU are to take the CST exam for the all-important certification designation. The official CST Self-Assessment Exam shows you how prepared you are to meet the challenges of the operating room.

Take it now on-line! www.lccsae.org



liaison council on certification
for the surgical technologist

6 West Dry Creek Circle,
Suite 100
Littleton, CO 80120.
1-800-707-005