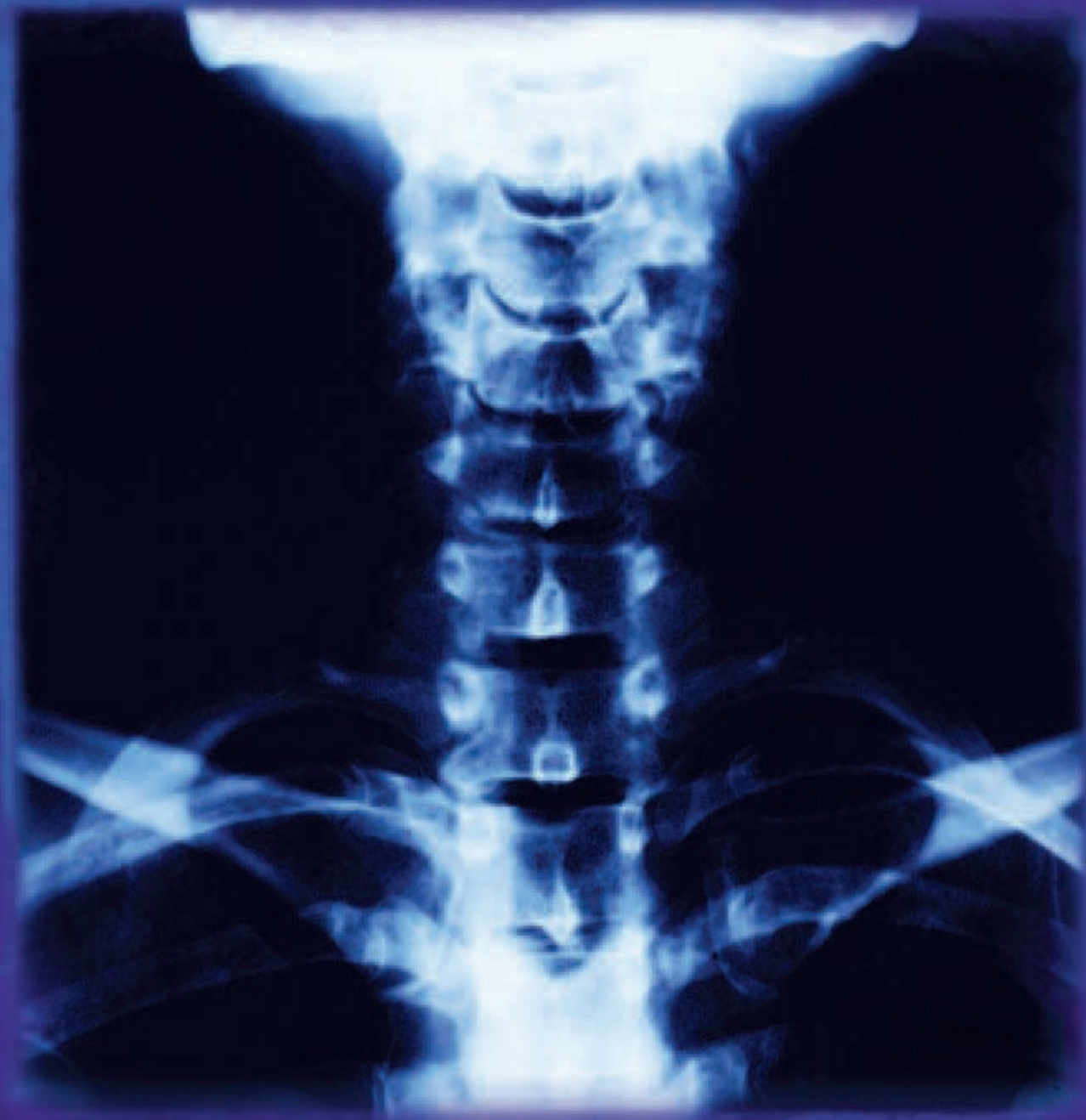

Anterior Internal Fixation of Type II Odontoid Process Fractures

Jeffrey J Cortese, CST, BHSA

Overview of cervical spine injuries

Cervical spine injuries comprise approximately 10,000 new spinal cord injuries annually. Approximately 80% of the injured individuals are male and less than 40 years of age. The most common etiology of these injuries is motor vehicle accidents, and midcervical spine (C4-C6) injuries are most frequently involved. The occurrence of odontoid process fractures comprise 10% to 20% of all cervical spine fractures seen in patients.⁴

In addition to immobilization of the cervical spine through utilization of halo jackets and cervical collars, there are specific types of odontoid process fractures that require surgical intervention. This can be achieved either with fixation of the C1-2 articulation, via a posterior approach, or with the fixation of the odontoid process, via an anterior approach. The anterior approach will be discussed in this article.

Special anatomical considerations of C1 and C2

The atlas, C1, and the axis, C2, are two distinct cervical vertebrae. The most distinguishing feature of C1 is the absence of a vertebral body or a spinous process. However, it does have two lateral masses and two arches. The facets of C1 articulate with the occipital condyles superiorly and the facets of C2 inferiorly.

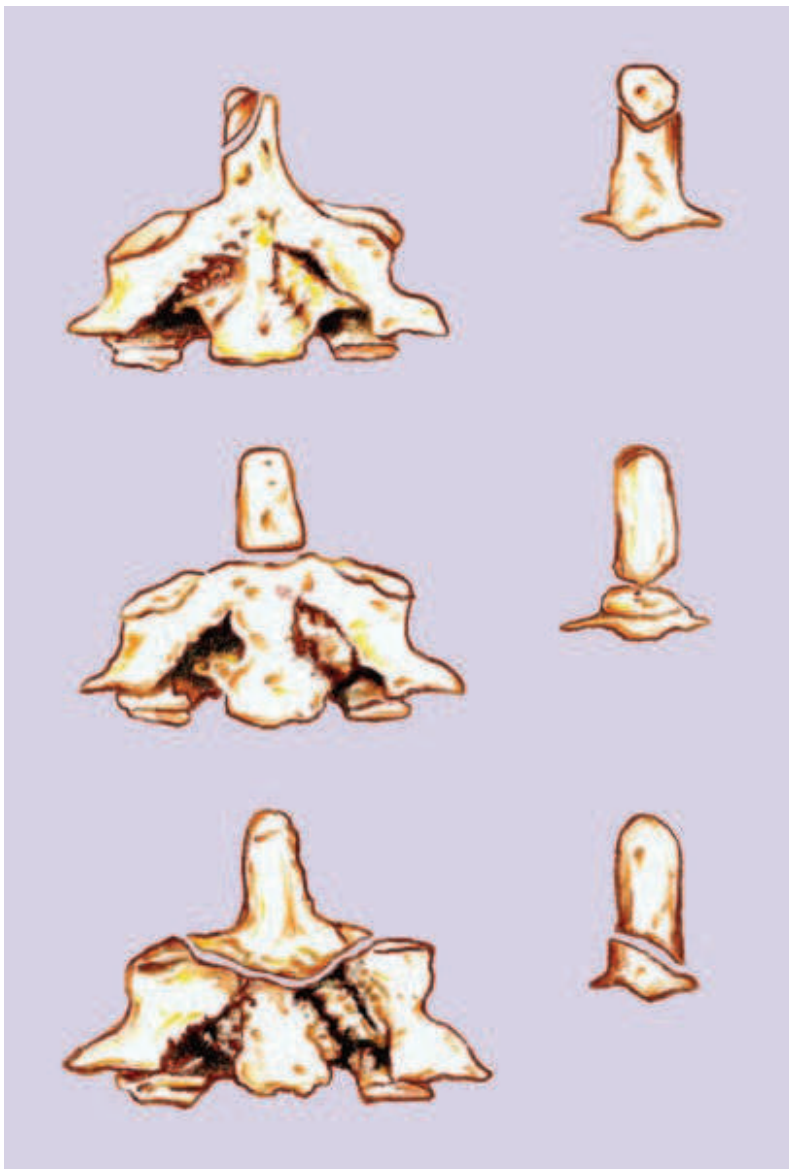


FIGURE 1: Anderson and D'Alonzo classification of odontoid process fractures. From top to bottom: Types I, II, and III.

The most distinguishing feature of C2 is the large odontoid process, the dens, which surfaces from the body of C2. The odontoid is prone to fracture by a traumatic injury and can be compromised by vascular insufficiency or a “watershed” zone at the base of C2.

Along with the bony characteristics of the C1-2 articulation, there are several key ligamentous attachments to consider when dealing with odontoid process fractures. The first is the cruciate ligament, which is shaped like a cross and helps stabilize the odontoid process. This ligament extends from the odontoid process rostrally to the basion, caudally to the body of the axis, and laterally to the lateral masses of the atlas.

Lateral extensions are called transverse ligaments, which help form a band or sling across the dorsal aspect of the odontoid. The alar ligaments are paired bands, which attach each side of the odontoid process to the medial aspect of the occipital condyle. The apical ligaments attach the tip of the odontoid to the basion. These ligaments help limit rotation and flexion of the head.

Classifications of fractures

Odontoid fractures were first described by Lambotte more than a century ago in 1894.³ Anderson and D'Alonzo developed a classification system of the various types of odontoid fractures that had been observed.¹ (Figure 1)

Type I fractures usually involve an avulsion of the tip of the odontoid process. This rarely seen condition is prone to significant ligamentous injury but can be treated with cervical collar immobilization.

Type II fractures involve a fracture at the base of the odontoid. These injuries are associated with ischemic necrosis of the process and are divided into three subtypes.¹ Subtype A includes transverse fractures. Subtype B involves fractures through the posterior superior to anterior inferior aspect of the dens. Finally, Subtype C involves fractures through the posterior inferior to anterior superior oblique aspects of the dens. Of these subtypes, the posterior inferior to anterior superior oblique is the most serious.

Type II fractures also involve anterior displacement of the dens and are more commonly seen than posterior displacement. These types of displacements can originate from flexion and extension injury, respectively.

The final classification factor of Type II fractures involves a nonunion of 20% to 80%.¹ This is frequently seen in injuries in patients older than 50 years of age. It is also seen in injuries that have more than 4 mm of displacement, including posterior displacement.

Type III odontoid fractures involve a fracture through the body of C2. These can be either non-displaced, requiring cervical outhouses or halo application, or displaced, requiring the application of a halo for three months.¹

Radiological examination of odontoid fractures

Suspect fractures of the odontoid process should be assessed by evaluating the initial preoperative lateral and anterior posterior (AP) plain X-ray films and/or unenhanced CT scans of the odontoid.⁴

Fracture type can be determined by the criteria delineated previously by Anderson and D'Alonzo. Fracture orientation should be classified according to the AP direction of the fracture line (anterior oblique, posterior oblique, or horizontal).¹ The degree of displacement is determined by the percentage of displacement of the fractured odontoid fragment, relative to the underlying body of C2.

Treatment of Type II odontoid fractures

In Type II odontoid fractures, there are several treatment options available to the surgeon.² The first option involves putting the patient in halo traction to reduce the fracture to less than 4 mm. The halo jacket should be worn for a period of 12 weeks, then a cervical collar should be worn for a period of six weeks to ensure proper healing of the fracture site.

If there is a delayed or nonunion of the fracture, the surgeon should initially consider placing the patient in a halo jacket before surgical intervention. In addition, the patients who are at a higher risk of nonunion—those who have more than 4 mm of displacement or older patients—should also be placed within a halo jacket.²

Treatment options for odontoid fractures associated with C1 ring fractures may utilize a halo application to allow C1 to heal; subsequently, a posterior C1-2 fusion is performed if nonunion occurs. In addition, the surgeon may choose to perform a posterior C1-2 fusion or an anterior odontoid screw fixation.⁴

Surgical technique

The patient is positioned supine on a well-padded operating room table and administered general anesthesia via endotracheal intubation. If not previously performed, the patient is placed in traction, either utilizing halo traction or Gardner-Wells tongs with 15 pounds of traction.

The head should be extended to help facilitate the trajectory of the screw(s). A small roll may be placed across the patient's scapulae to bring the anterior border of the sternocleidomastoid muscle into view.

After administering one gram of cefazolin, in combination with two grams of Solu-Medrol, the patient is prepped and draped in the proper sterile method. The surgical approach is identical to that of an anterior cervical discectomy, with fusion as described by Smith-Robinson.

A transverse skin incision is made at the C4-5 level. The reason for such depth is that the drill guide must be angled in, so that the guide itself is in total alignment with the central portion of the process. After using monopolar electrocautery to halt any bleeding in the subcutaneous tissue, a small Weitlaner retractor may be placed. The platysma muscle is split, either longitudinally or transversely with Metzenbaum scissors and monopolar electrocautery.

The pretracheal fascia is incised, using coagulation immediately anterior to the sternocleidomastoid muscle. Either blunt-finger dissection, or blunt dissection using a pusher, is employed to create a plane to the vertebral bodies. A handheld retractor, such as a Cloward retractor, is placed to retract the carotid sheath and the esophagus, trachea, and strap muscles medially. Care must be taken to avoid damaging the recurrent laryngeal nerve as it ascends in the neck between the trachea and esophagus on the left side. Any bleeding encountered is controlled by the use of bipolar electrocautery. The normal amount of bleeding encountered with this dissection should be less than a teaspoon. The dissection is carried superiorly to the base of C2. The longus colli muscles are stripped away from the vertebral body, leaving the anterior longitudinal ligament exposed.

A self-retaining retractor, such as an Apfelbaum, is employed to help maintain exposure of the body of C2. A draped fluoroscopic imaging unit is brought into place. An anterior posterior view is first obtained to confirm the correct level of the exposure and medial/lateral alignment. The C-arm is then positioned to obtain a lateral

image in preparation of the screw(s) placement. A biplane fluoroscopic unit is advantageous, because it is capable of producing several AP and lateral images in fast succession, in order to confirm the correct trajectory of the screw within the odontoid process.

The anterior longitudinal ligament is stripped away from the anterior-inferior portion of the vertebral body of C2 with monopolar electro-surgery, exposing the cortex. If the ligament is left intact, it will give a false measurement of the screw and will result in suboptimal purchase of the screw within the dens. A drill guide is inserted into the wound at the base of C2. The drill guide angulation is confirmed with AP and lateral fluoroscopic imaging. A guide wire is drilled into the vertebral body and the odontoid process. This placement is again confirmed with fluoroscopic imaging. Although not mandatory, but advantageous, a second guide wire may be advanced adjacent to the first for optimal fixation of purchase of the screw within the dens. The wire(s) should span the gap of the fracture and stop just before the inner cortex of the process. The wire(s) should be aimed 2 mm posterior to the apex of the odontoid process. Once satisfactory placement of the guide wire(s) has been confirmed, a cannulated depth gauge is inserted over the wire to determine the screw length needed. Partially threaded screws are preferred over fully threaded screws to act as a lag screw to compress the fractured dens into the body of C2. The partially threaded screws, however, can be changed out for fully threaded screws after optimal reduction is achieved in the two-screw technique.

Although the majority of the cannulated screws on the market for odontoid fixation are self-drilling and self-tapping, the surgeon may opt to drill and tap through the cortex of the body of C2 (Figure 2). This must be done with extreme care, and fluoroscopic confirmation must be used; because when the drill is advanced over the wire, the wire may also advance superiorly into the brainstem, thereby causing catastrophic results. The screw(s) are then inserted over the guide wire(s) with the same caution as mentioned above. The screw(s) are then tight-

ened down by hand until satisfactory fixation and purchase of the screw is felt (Figure 3).

The guide wire(s) are removed from the screw(s), and final images are then obtained to confirm placement and reduction of the odontoid process (Figure 4). The wound is adequately irrigated with saline containing bacitracin, polymyxin, and gentamicin. Any bleeding points are controlled with bipolar electro-surgery. The retractors are removed, and the platysma muscle is reapproximated with 3-0 Vicryl® (X-1 needle) in a simple, interrupted technique. An interrupted subcuticular suture of 3-0 Vicryl® (X-1 needle) is placed in the subcutaneous and subcuticular layer. Any skin irregularities can be corrected with 5-0 plain gut (PS-4 needle). Adhesive solution along with Steri-strips™ are placed on the wound and dressed according to aseptic technique. The patient can be placed in a cervical collar postoperatively.

Postoperative CT scanning should be employed to augment plain X-ray film studies, if needed. The presence of trabeculation across the fracture site, in combination with the absence of movement on lateral flexion and extension radiographs, along with the anatomical alignment of the fracture fragment, are indicators that the fusion of the fragment can be considered successful.

Complications

Although neurological- and respiratory-related complications are not commonly associated with odontoid fractures, Przybylski has discussed two articles in which the epidemiology of spinal cord injury in odontoid fractures was described.⁴

The fracture displacement and spinal canal size are identified as factors associated with risk of neurological injury. Whereas posteriorly displaced fractures have been more commonly associated with nonunion after external immobilization therapy, the risk of acute respiratory failure during surgical reduction of these fractures has only been described anecdotally.⁴ A frequent incidence of respiratory distress associated with possible death has been presented by

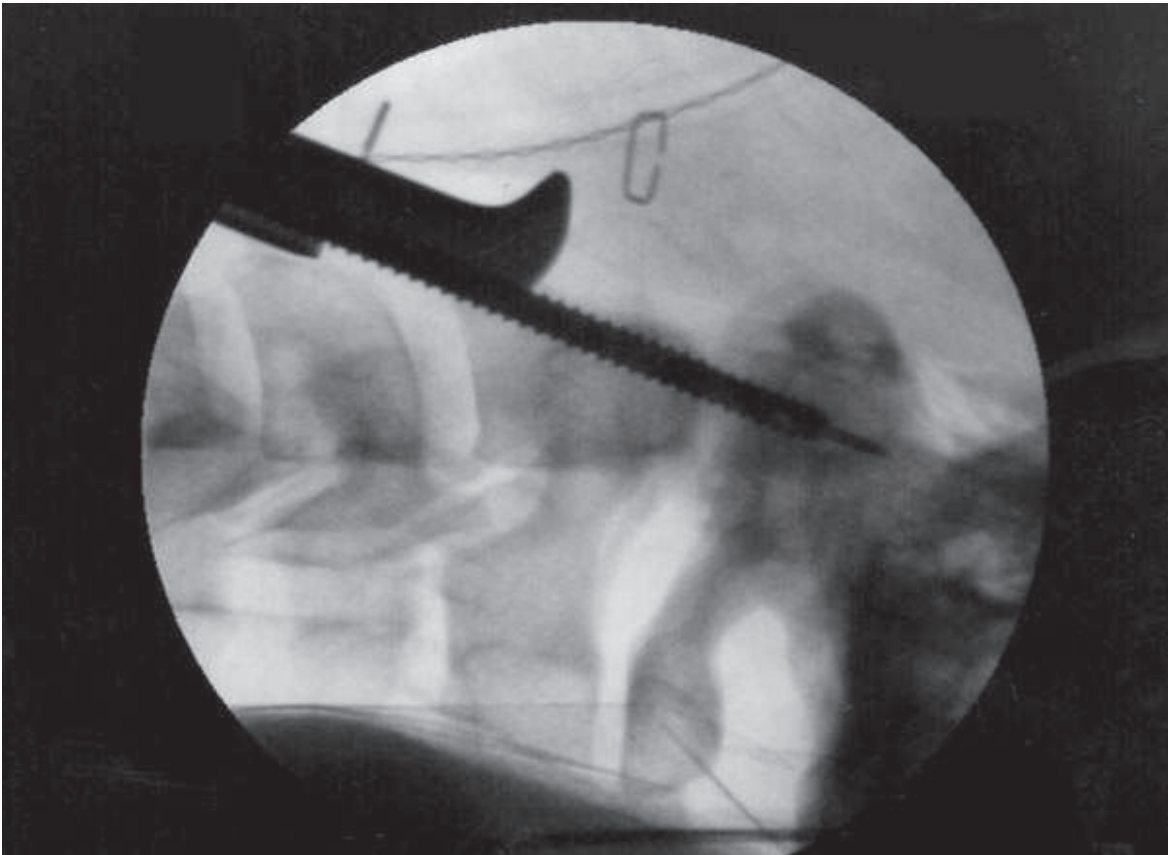


FIGURE 2: Lateral radiograph showing the guide wire in place, spanning the fracture line in the odontoid process with a cannulated tap being advanced along the wire.

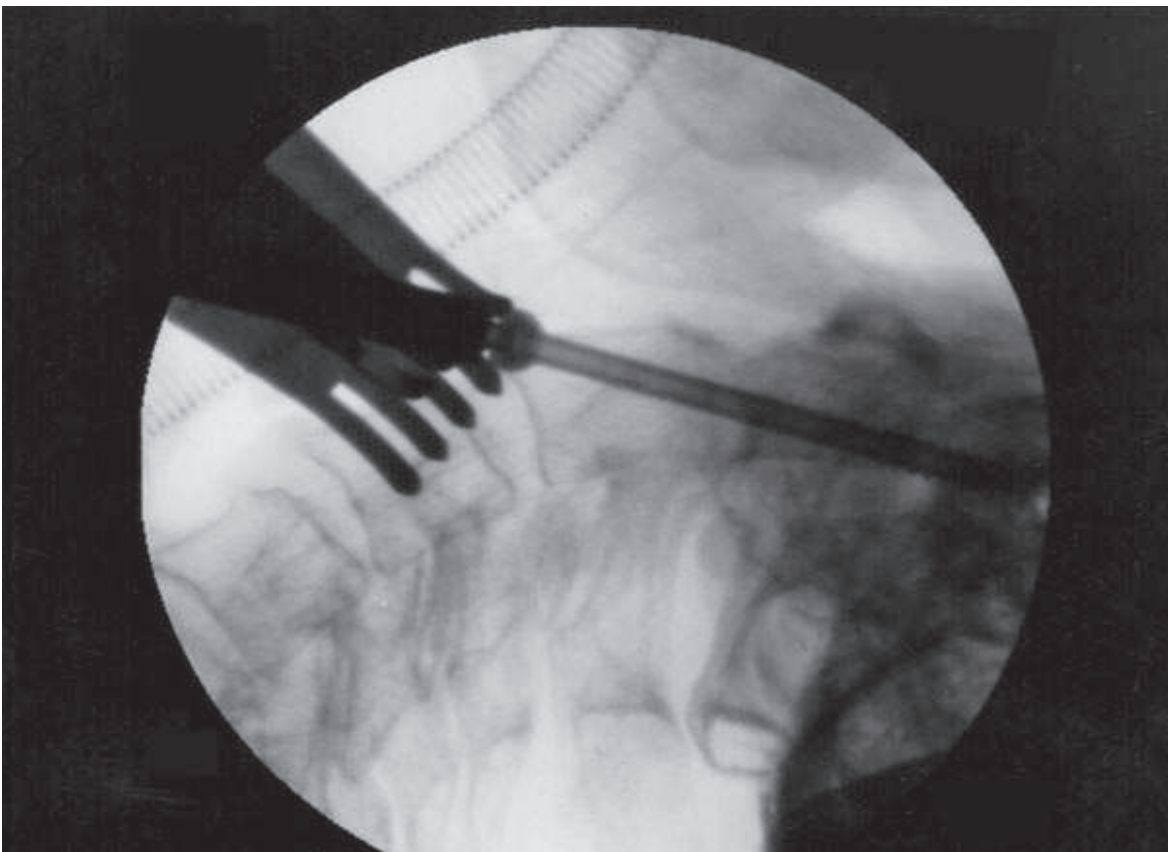


FIGURE 3: Lateral radiograph showing the final tightening of the cannulated, partially threaded, cancellous screw across the fracture site.

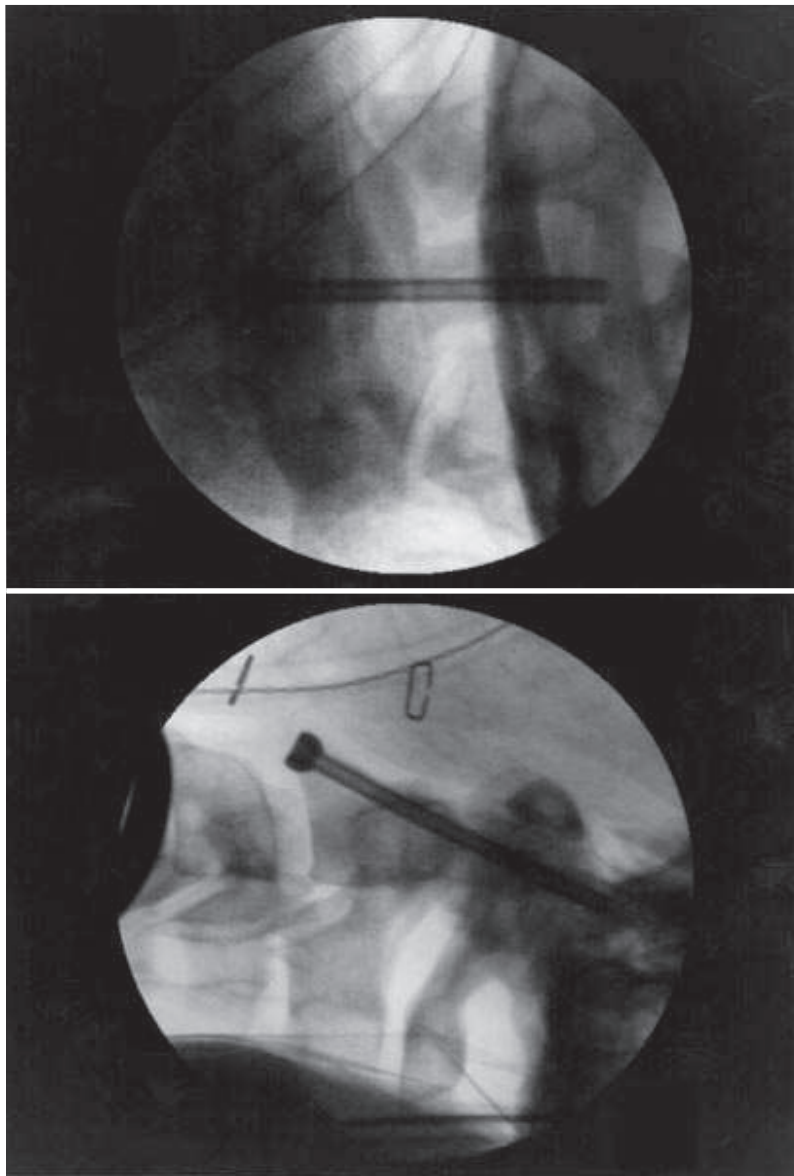


FIGURE 4: Final anterior posterior and lateral radiographs showing good reduction and fixation of the odontoid process fragment.

Przybylski with reference to the setting of cervical traction for the reduction of posteriorly displaced fractures.

Conclusion

Several factors have to be considered in the treatment of odontoid fractures. In the first instance, the fracture pattern must be analyzed in three dimensions to establish both the level and the direction of the fracture line, the rotation or translation of the fracture fragments, and the stability of the lesion. Similarly, account has to be taken of the age and general condition of the patient, and a painstaking search has to be made to detect any neurological impairment. How-

ever, direct anterior screw fixation is an easily learned, cost-effective, and relatively straightforward technique for treating odontoid fractures. It confers immediate stability and provides an optimum anatomical environment for bone healing.

Acknowledgments

I wish to thank my wife, Jennifer N Prigg, DO, for her support. I also wish to thank John L Zinkel, MD, PhD, for the opportunity to participate in the wonderful world of neurosurgery throughout the years. I am forever grateful.

About the author

Jeffrey J Cortese, CST, BHSA, has been a Certified Surgical Technologist since 1996. He is a graduate of Baker College, Mt. Clemens Campus. Cortese is employed at Livingston Regional Hospital in Livingston, Tennessee. He earned his bachelor's of health service administration degree from Baker College in Clinton Township, Michigan.

References

1. Anderson LD, D'Alonzo RT. Fractures of the odontoid process of the axis. *Journal of Bone and Joint Surgery*. 1974; 56: 1663-1674.
2. Direct anterior screw fixation for recent and remote odontoid fractures. American Association of Neurological Surgeons. <http://www.aans.org/education/journal/neurosurgical/june00/8-6-2.pdf>. Accessed 12/13/2005.
3. Fractures of the Odontoid. http://www.maitrise-orthop.com/corpusmaitri/orthopaedic/mo68_odontoid/index.shtml. Accessed 12/13/2005.
4. Introduction to Odontoid Fractures: Controversies in the Management of Odontoid Fractures. American Association of Neurological Surgeons. <http://www.aans.org/education/journal/neurosurgical/june00/intro-pdf>. Accessed 12/13/2005.

Editor's Note: For additional information about spinal cord anatomy, please refer to Jeffrey J Cortese's previous article, "Cauda Equina Lipoma Resection with Spinal Cord Untethering in an Adult," in the October 2005 issue of The Surgical Technologist.