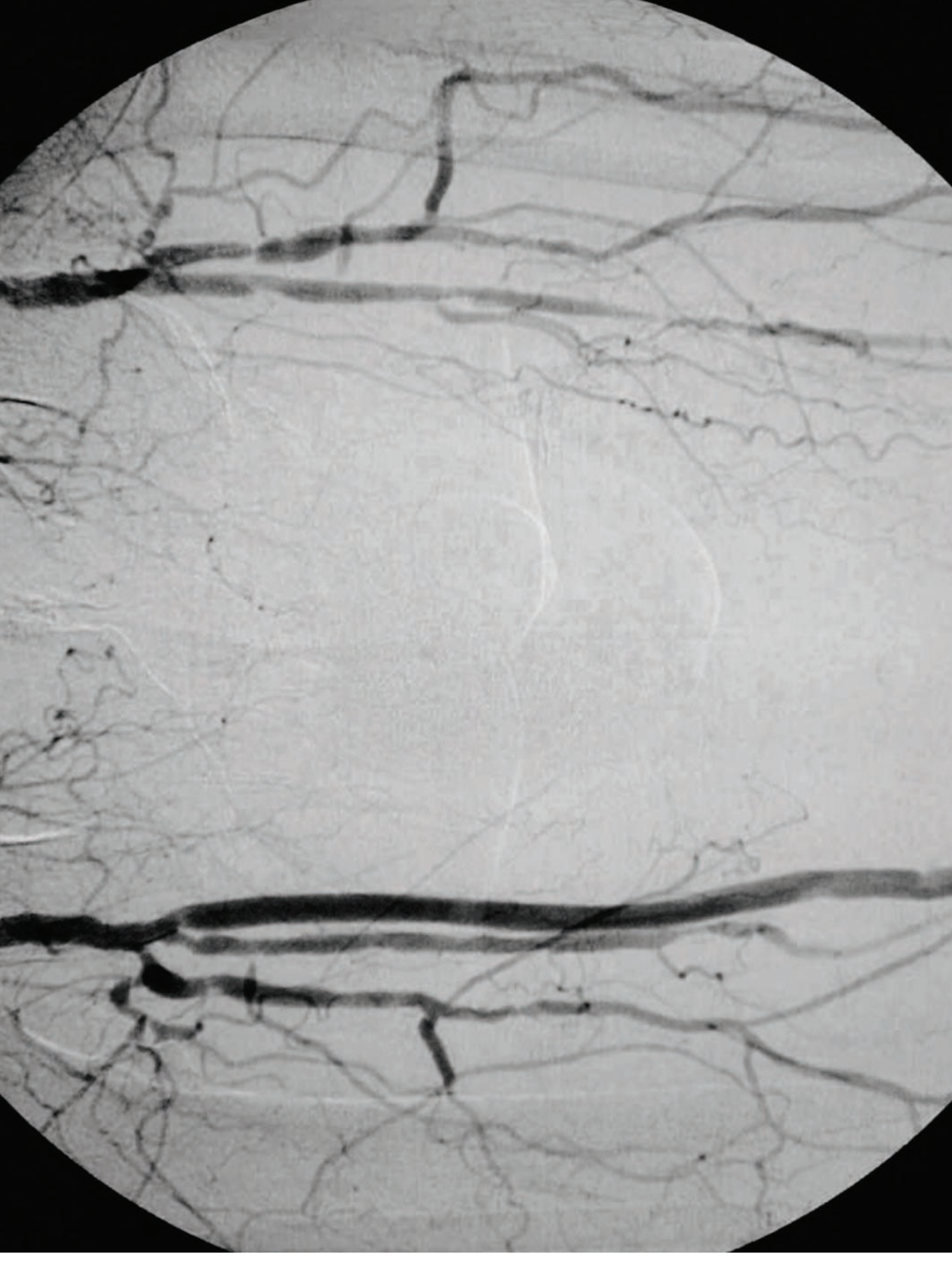

# Bilateral Femoral-Popliteal Bypass— From Supine to Prone

*Candice A Montgomery, CST*

**A**femoral-popliteal bypass grafting procedure is usually performed to treat patients who have an arterial occlusion situated in the femoral and/or popliteal arteries distal to the inguinal ligament.<sup>3</sup> The occlusion is typically caused by atherosclerosis, which prohibits or substantially reduces the flow of oxygenated arterial blood to the lower extremities. If left untreated, this occlusion can lead to necrosis of the tissue of the lower extremities and, inevitably, amputation.<sup>3</sup>

## **PATIENT'S MEDICAL HISTORY**

The patient is a 56-year-old male, six feet tall, weighing 267 lbs. He has been a cigarette smoker for 40 years, at a rate of 20–30 cigarettes per day. He was diagnosed with type 2 diabetes mellitus approximately 16 years ago and has been treated with insulin injections for six years.

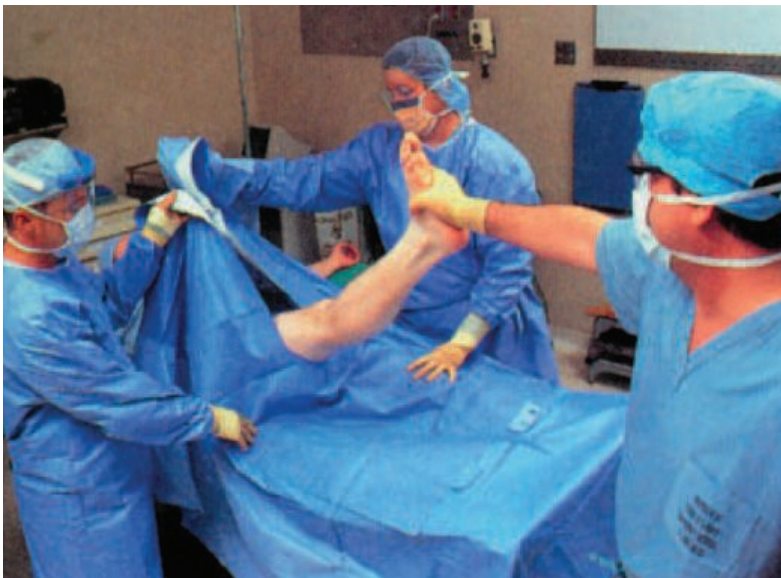## **PREOPERATIVE DIAGNOSIS**

The patient has been diagnosed with peripheral vascular disease secondary to type 2 diabetes mellitus and hyperlipidemia. He has atherosclerotic occlusion of both the right and left popliteal arteries with severe stenosis.

**Preoperative exam**

Blood pressure	115/53
Pulse	71
Temperature	98.5°F
Respirations	12
Glucose FBS	226 mg/dL

No positive popliteal or pedal pulses were noted. The patient was given 1 gm of cefazolin sodium. The patient was known to be on the following medications: pioglitazone, insulin glargine, lisinopril hydrochlorothiazide, pentoxifylline, metformin, glipizide, and pravastatin.



Courtesy: Thomson Delmar Learning. *Surgical Technology for the Surgical Technologist: A Positive Care Approach*. ©2004.

**FIGURE 1:**

An example of a split sheet being placed under a patient's leg.

The patient's last tobacco cigarette was smoked at midnight the day before surgery. The day of surgery, the patient complained of mild nausea, which he admitted was attributable to anxiety in relation to the surgery.

**SPECIAL PREOPERATIVE PREPARATION**

Since this procedure entails a patient position change, the most important preparation a surgical technologist should account for is the need for double the supplies required to reposition the patient. Sterile supplies include drapes, skin preparation solution, towels, gowns, gloves, ESU pencils, suction and light handle covers. Non-sterile repositioning supplies include an additional Bair Hugger® blanket, prone headrest,

prone under-ankle padding, and prone under-shoulders, -arms and -hands padding.

Additional preoperative preparation includes soaking vessel loops in saline and attaching them to mosquito clamps; placing rubber shods or ligaboots on the mosquito clamps; preloading small and medium hemoclip applicators with appropriate hemoclips and verifying they are attached securely; attaching free ties to tonsil clamps, in case the surgeon requests a tie on a pass; preloading vascular suture on a Castroviejo needle holder, in case the surgeon decides to make a quick vascular repair; arranging all free ties in correct order, so they're readily accessible if a vessel needs to be ligated immediately; flushing the olive tip catheter extension on the heparinized syringe with heparin saline solution before handing it to the surgeon; and verifying that the asepto syringe is full and prepared with heparinized saline for quick irrigation.

Since a second surgeon is assisting, the surgical technologist needs to be able to accommodate both surgeons simultaneously. For example, if the surgeon requests forceps, the assistant will typically require forceps at the same time.

In addition, since the procedure is bilateral, both surgeons may want to close at the same time. The surgical technologist should have available two needle holders preloaded with the appropriate suture.

The surgical technologist also should anticipate the use of Doppler and C-arm fluoroscopy, which will require lead shields for all surgical team members and, possibly, a lead-shielded wall to stand behind. Additional large drapes also will be needed to cover the fluoroscope and to protect the sterile field and patient from intraoperative contamination.<sup>2</sup>

**SAPHENOUS VEIN GRAFT PROCUREMENT IN SUPINE****ANESTHESIA AND MEDICATIONS**

General anesthesia was administered. Adjuncts to the anesthesia included oxygen, nitrous oxide, dolasetron, metoclopramide, fentanyl, vecuronium bromide, propofol, esmolol, ephedrine, lidocaine, morphine, glycopyrrolate, neostigmine



bromide and lactated Ringers solution. The surgeon also requested that intravenous heparin be available.

#### POSITIONING, SKIN PREPARATION AND DRAPING

The head of the operating table was removed and placed at the foot of the table to facilitate intra-operative C-arm X-rays. Padding was checked to determine whether repositioning was necessary to match the new configuration.

Gel padding was placed on the full length of the table. The patient was positioned in supine with both arms tucked in at the sides, a donut headrest under the head, and a safety strap across the chest.

The circulator shaved the patient's anterior medial thigh to prepare for the saphenous vein graft procurement. Shaved hair was removed with tape.

The circulator applied skin preparation solution to the left leg while it was being abducted by the surgical technologist, using a sterile, impervious stockinette to hold the foot. The left leg was prepped from umbilicus to just distal to the knee and circumferentially around the left leg.

The groin was then prepped and covered with a sterile towel folded in thirds. The groin area was not shaved due to surgeon's preference.

A large drape was placed underneath both legs. A split sheet was placed underneath the left thigh, and slits were secured around the thigh. A fenestrated sheet was placed with fenestration over the intended vein procurement site. The fenestration was then extended to include the entire thigh from abdominocrural crease to distal knee.

#### PROCEDURAL OVERVIEW

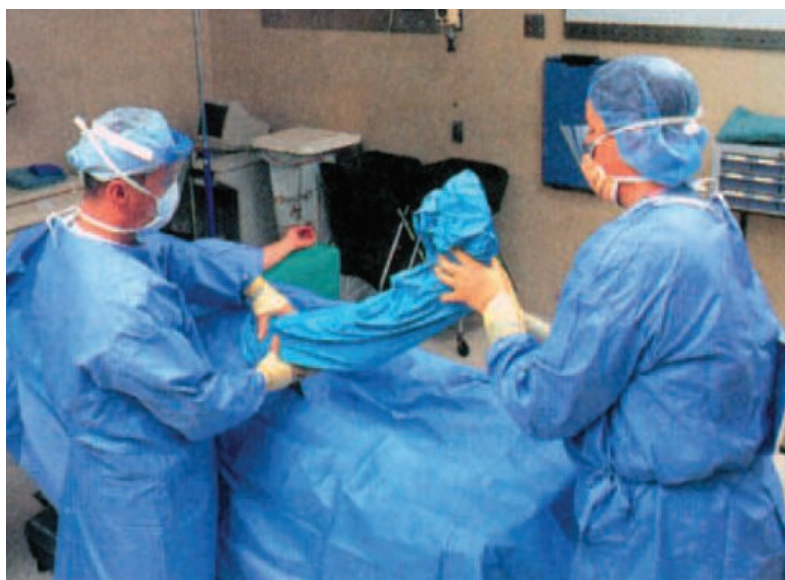The surgeon used a #10 blade on a #3 knife handle to make small, two-inch interrupted incisions along a previously marked saphenous vein site on the anterior medial thigh. The electro-surgical unit was used to achieve hemostasis. DeBakey forceps were given to the surgeon, and Army-Navy retractors were given to the assistant surgeon.

Dissection was continued down to the saphenous vein, which was then examined for branches.

The previous interrupted two-inch incisions were extended from the primary proximal incision to the distal incision.

Remaining tissue was dissected down to the saphenous vein using Metzenbaum scissors and DeBakey forceps. Blunt Weitlaner retractors were then used to retract the tissue.

Approximately 35 cm of saphenous vein were exposed for graft procurement. The surgeon used a right-angle clamp, a mosquito clamp and a vessel loop to isolate the proximal end of the exposed saphenous vein.



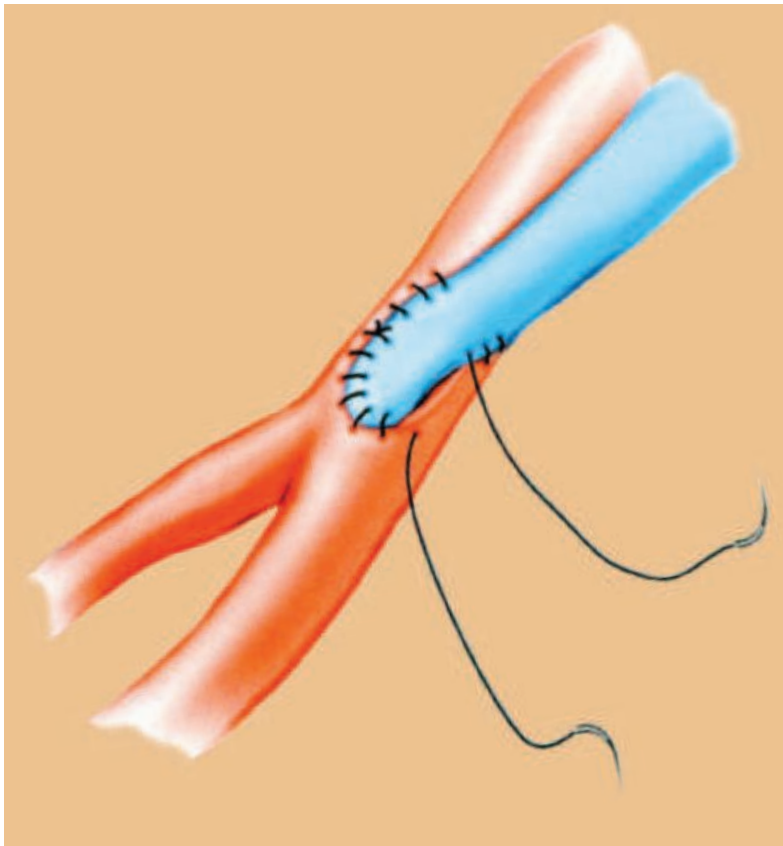
Courtesy Thomson Delmar Learning. Surgical Technology for the Surgical Technologist: A Positive Care Approach. ©2004.

**FIGURE 2:** An example of a stockinette being applied and unrolled to the proper level.

The surgeon repeated these steps using the same instrumentation and supplies to isolate the distal portion of the exposed saphenous vein. Tributaries and branches of the exposed saphenous vein were ligated with small hemoclips and 3-0 nonabsorbable silk 18-inch ties.

The distal end of the saphenous vein was marked with a straight line using a sterile marking pen. The proximal and distal ends of the saphenous vein were ligated with medium hemoclips, and the vein was removed.

The vein was untwisted and flushed with heparinized saline using an olive-tip cannula on a 30-cc syringe. The vein was then placed in a kidney basin containing a solution of heparinized saline.



**FIGURE 3:**

Popliteal artery—  
saphenous vein  
anastomosis.

A soft goods and sharps count was initiated, and wound closure was begun. Subcuticular tissue was closed with 2-0 synthetic polyester suture on a GS-21 needle. The skin was closed with staples.

**Points to remember:**

- When passing ligating suture ties, pass them in forceps, or pass them onto the field near the surgeon where the suture is visible.
- When passing vessel loops, make sure they are premoistened in saline solution before passing them to the surgeon.
- Due to the vein's oily surface, the sterile marking pen may not be effective, and an alternative should be available.
- When handing the stapler to the surgeon, also pass off two Adson forceps with teeth.

**BILATERAL FEMORAL-POPLITEAL BYPASS GRAFTING IN PRONE**

**POSITIONING, SKIN PREPARATION AND DRAPING**

The stretcher was brought back into the room to facilitate patient repositioning. The patient was rolled over onto the stretcher in a prone position and then transferred back to the table with the roll board still in prone position.

The patient was properly padded and secured with the donut headrest in correct position to ensure a proper airway. The arms were tucked in at both sides, and rolls were placed underneath both shoulders to pad pressure points. A roll was also placed under each ankle.

Light covers, drapes, gowns and gloves were changed for all team members. The circulating nurse prepared each leg circumferentially from just underneath the buttocks to the toes. The legs were abducted for the skin preparation with a sterile, impervious stockinette for each leg to grip each foot.

The perineal area was covered with two sterile towels. A large drape was placed underneath both legs. Two split sheets were positioned for each leg. Then a fenestrated drape was placed in position for each leg.

**Points to remember:**

- Position the back table and Mayo stand out of the way to ensure they remain sterile during repositioning. The surgical technologist should then remove his or her gown and outer gloves and assist with patient repositioning.
- Additional supplies, such as gowns, gloves, drapes and light handle covers, should have already been opened and available on the back table. A second scrub is necessary.
- Special care should be taken when placing the perineal towel on the patient, so that sterility is not compromised.

**PROCEDURAL OVERVIEW**

The surgeon made the popliteal artery incision on the right leg first, using a #10 blade on a #3 knife handle. The incision was then dissected down to the femoropopliteal artery using DeBakey

Courtesy Thomson Delmar Learning, *Surgical Technology for the Surgical Technologist: A Positive Care Approach*, ©2004.

forceps, Metzenbaum scissors and right-angle clamps. Blunt Weitlaner retractors were used proximally and distally to expose the bypass site.

The surgeon then made a popliteal artery incision on the left leg and dissected down to the femoropopliteal artery in the same manner as was performed on the right leg. Additional blunt Weitlaners were used proximally and distally to expose the bypass site on the left leg.

The femoropopliteal arteries in both legs were isolated proximally and distally using large, red artery vessel loops, right-angle clamps and mosquito clamps in the same manner as was performed on the saphenous vein. The saphenous vein was sized for both bypass sites to ensure sufficient length before cutting.

The saphenous vein was then rotated 180 degrees, so that the distal end became the proximal end. This was done to prevent use of the valvulotome, which could cause damage to the vein. The femoral artery was clamped with DeBakey vascular clamps proximally and distally on the right leg.

An incision was made into the femoral artery using a #11 blade on a #7 knife handle just distal to the proximal clamp on the right leg. DeBakey vascular forceps and a Freer elevator was used to remove the plaque that was occluding the artery. The removed plaque was placed on the back table and was cared for later.

Small tributaries and bleeders were ligated using small and medium hemoclips and 3-0 non-absorbable silk 18-inch ties. The saphenous vein was flushed again with heparinized saline and then shaped in a toe-to-heel fashion to facilitate anastomosis. Potts-Smith scissors were used to cut the graft into proper shape.

The surgeon requested that the patient be treated systemically with heparin. After a sufficient amount of time passed to ensure sufficient circulation, the saphenous vein was anastomosed to the proximal portion of the femoral artery using 6-0 nonabsorbable, polypropylene sutures on double-armed CV-1 needles, a Castroviejo needle holder, and a DeBakey vascular forceps with a 1-mm tip. Rubber shods on straight mosquito clamps were used to isolate and protect one

of the double-armed needles while the other was used to suture.

Before suture closure, the arterial vascular clamp was released, and the artery was flushed with arterial blood. The distal portion of the saphenous vein was shaped in the same toe-to-heel fashion and then anastomosed in the same way to the distal femoropopliteal artery just proximal to the distal clamp using the same suture and instrumentation described above. The arterial vascular clamp was released to allow the blood to flow. Suture lines were verified and found stable.

The same procedure with the same suture and instrumentation was then repeated on the left leg.

The surgeon used his fingers to verify palpable pulses in both arteries. A Doppler probe was sterile-draped and used to test the distal popliteal arteries of both legs.

C-arm fluoroscopy was then requested to determine sufficient blood flow. The C-arm was draped with sterile towels and enabled for use. To ensure sterility, a large drape was placed next to the operative site where the C-arm gets closest to the field.

Team members used lead shields and a lead-shielded wall to protect themselves from radiation. A contrast agent was injected into the patient's arteries, and X-rays were taken. The surgeons then verified sufficient blood flow to the lower extremities and the absence of any arterial occlusion.

The C-arm was removed from the field, and the large drape used to protect the operative site was discarded. Each surgeon simultaneously used interrupted sutures to bilaterally close the subcuticular tissue with 2-0 synthetic polyester suture on a GS-21 needle, a Mayo-Hegar needle holder and DeBakey forceps.

Staples and two pairs of Adson forceps with teeth were used by both surgeons simultaneously to approximate and close the skin. A soft goods and sharps count was initiated at the start of wound closure.

Dressings for both incision sites included nonadhesive pads, 4x4 pads, a gauze roll and three-inch paper tape. After dressing the femoropopliteal incision sites, the patient was returned

to supine position, and the same dressings were applied to the saphenous graft incision site.

The back table and Mayo stand were removed from the field and isolated to remain sterile until the patient left the room.

**Points to remember:**

- During any peripheral vascular surgery, tissue forceps need to be given with any cutting tool, including suture.
- Mosquito clamps should always be passed after vessel loops to clamp the loops.
- If the surgeon requests a right-angle clamp, a vessel loop or free tie will typically be requested, too.
- If the surgeon asks for a hemoclip, a second hemoclip typically will be needed, followed by Metzenbaum scissors, in accordance with the clamp-clamp-cut routine. Always keep hemoclip appliers loaded.
- Metzenbaum scissors may be used for cutting suture in peripheral vascular surgeries, because Mayo scissors are large and bulky in tight spaces.
- Double-armed needles often require rubber shods to follow.
- If the surgeon is wearing loops, remember that loops provide only a limited view, and take care when passing items to the surgeon.
- When the surgeon uses double-armed vascular suture, place a sterile towel over the retractors and clamps to prevent the suture from catching on these items.
- While the surgeon flushes the arteries to check for stable suture lines, preload vascular suture in a Castroviejo needle holder, in case the surgeon needs to throw a repair stitch.
- If intraoperative X-rays are performed, the surgical technologist is responsible for protecting him- or herself from radiation.
- After the procedure is completed, the surgical technologist should remain sterile and should keep the back table and Mayo stand sterile until the patient has left the room, due to the increased risk of hemorrhage during any kind of vascular graft procedure.

**PATIENT POSTOPERATIVE CONDITION**

The patient stayed in the hospital for seven days. He exhibited no known complications. He reported mild to moderate pain, which was relieved by pain medications. Prior to discharge, the patient was instructed to quit smoking, eat healthy foods, exercise and monitor his diabetes carefully.

**POTENTIAL COMPLICATIONS**

Possible complications following this procedure include infection, hemorrhage, dehiscence, recurrence of stenosis, and amputation.<sup>5</sup>

**ABOUT THE AUTHOR**

Candice Montgomery, CST, graduated valedictorian from San Joaquin Valley College in Fresno, California, in February, 2007. Prior to graduation, she sat for and passed the certification exam. She is currently working as a CST at Saint Agnes Medical Center in Fresno. She was recently inducted into the AST National Honor Society.

**References**

1. Fortunato N. *Berry and Kohn's Operating Room Technique, 9th ed.* St Louis, Mo; Mosby, Inc:2000.
2. Goldman M. *Pocket Guide to the Operating Room, 2nd ed.* Philadelphia, Pa: FA Davis Company:1996.
3. Houck P. *Advanced Training for Operating Room Specialties.* Garden Grove, Ca; Medcom, Inc:1993.
4. Moses K. *Atlas of Clinical Gross Anatomy.* Philadelphia, Pa; Elsevier Mosby:2005.
5. Price P, Frey K, Junge T, eds. *Surgical Technology for the Surgical Technologist: A Positive Care Approach, 2nd ed.* Association of Surgical Technologists, Inc. New York: Delmar Learning:2004.
6. Rothrock J. *Alexander's Care of the Patient in Surgery, 12th ed.* St Louis, Mo; Mosby, Inc:2003.

Bair Hugger is a registered trademark of Arizant, Inc.