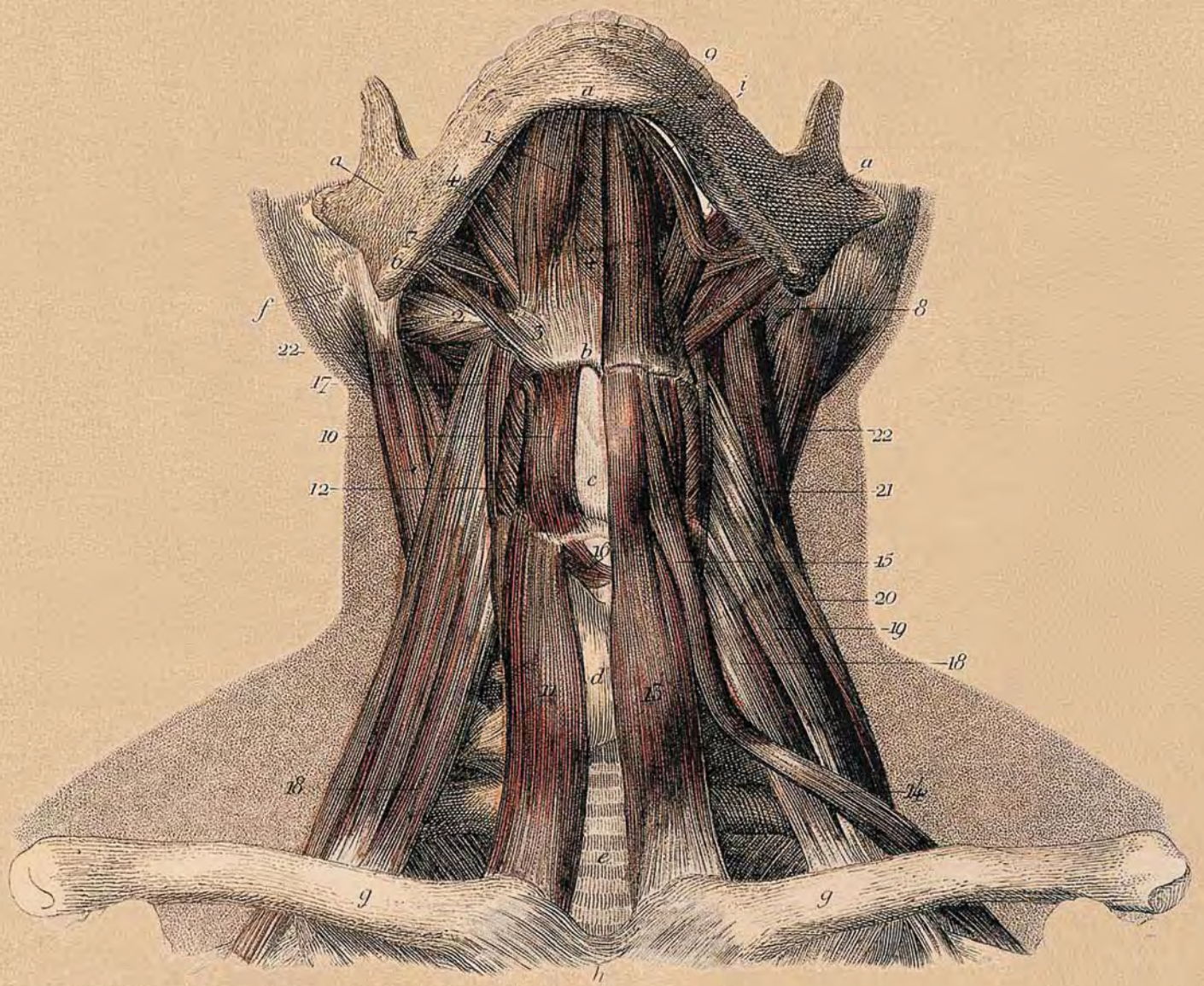



# Platysmaplasty

*A surgical resolution for the “turkey neck”*

by Nydia I Morales, CST

The term “turkey neck” refers to the lateral ptosis of the frontal neck derma. This can occur when the platysma muscles separate, a result of natural weakening of the ligaments in the cervical region, as well as excessive lipid build-up. Other causes of this condition include genetics, bone loss and decline of skin elasticity—possibly from weight loss. It is most commonly regarded as a factor of aging, although sun exposure and smoking may also contribute.

**F**or patients who are interested in reducing the loose look of sagging skin in the neck area under the jaw line, a platysmaplasty, or neck lift, is an option. It can be performed in conjunction with a face lift, but it is often performed as a stand-alone procedure. This article examines the surgical options for resolving turkey neck, as well as alternatives to surgery.

## ETIOLOGY AND ANATOMY

The platysma muscle is one of a pair of plate-like, wide muscles at the side of the neck. It arises from the fascia covering the superior parts of the pectoralis major and the deltoideus. It crosses the clavicle and rises obliquely and medially along the side of the neck. The platysma covers the external jugular vein as the vein descends from the angle of the mandible to the clavicle. It is innervated by the cervical branch of the facial nerve and serves to draw down the lower lip and the corner of the mouth. When the platysma fully contracts, the skin over the clavicle is drawn toward the mandible, increasing the diameter of the neck.<sup>1</sup>

The muscle has several distinct points of reference. It is attached to the mentum and the inferior madibular edge and

## LEARNING OBJECTIVES

- ▲ Review the relevant anatomy for this procedure
- ▲ Examine the set-up and surgical positioning for this procedure
- ▲ Compare and contrast the differences between an in-office procedure and a typical OR procedure
- ▲ Assess the indications for platysmaplasty
- ▲ Evaluate the recovery process, as well as the potential postoperative complications for platysmaplasty

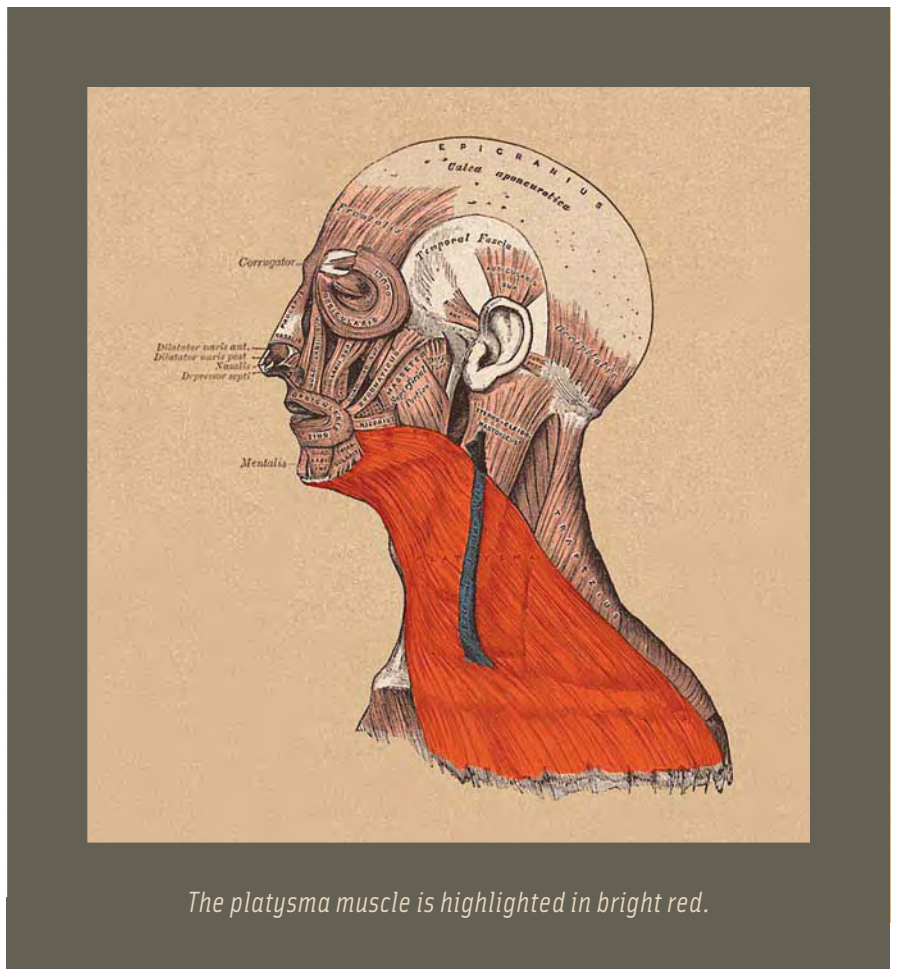
intersects the orbicularis oris laterally and the depressor anguli oris.<sup>2</sup> The skin of the cheek and the anterior neck is comprised of three interconnected layers: the superficial epidermal-dermal layer; the underlying subcutaneous fat; and a gliding membrane composed of fibro-elastic connective tissue and muscle. This gliding membrane is called the superficial musculo-aponeurotic system (SMAS).<sup>2</sup> The SMAS aids in reattaching the muscle, producing a younger, smoother facial appearance. The fat of this superficial layer consists of lobes that lie randomly on the face and intersect with the fibrous tissues of the SMAS. Thicker layers of fat are found in the neck and cheek area. The deep fat layer is thin and divided by fibrous bands. The ligaments hold the soft tissue and anchor it to the bone.<sup>3</sup>

#### PREOPERATIVE PREPARATION

The patient is required to cease smoking and consuming alcohol for two weeks prior to the procedure. This is to help ensure proper healing postoperatively. In addition, aspirin should not be taken preoperatively as it can cause bleeding. The patient should wear comfortable clothing during and after the procedure to facilitate nonrestrictive circulation. Baggy clothing or a sweat suit is encouraged.

Vital signs, including blood pressure and pulse oximeter readings are recorded and close attention is given to any irregularities, such as cardiac dysrhythmia.

The surgeon will review the procedure with the patient, as well as take a complete medical history. Photos of the patient are taken to provide a before-and-after comparison. The surgical technologist remains in the OR suite for the duration of the procedure to monitor the patient at all



*The platysma muscle is highlighted in bright red.*

times. There is no circulating nurse or anesthesiologist present. Prior to the procedure, the surgical technologist confirms that the consent form has been signed and counter signs it. He or she also reviews all medical entries at this time. Vital signs, including blood pressure and pulse oximeter readings are recorded and close attention is given to any irregularities, such as cardiac dysrhythmia.

The choice of anesthetic will vary depending on several factors, including the patient's overall health, medications the patient is currently taking and the number and length of time of the procedures being performed. Patient and surgeon preference are

also considered. A platysmaplasty alone can be performed under general anesthesia, with IV sedation or local anesthesia. Most cases are done in-office and are performed under local anesthesia.

The local anesthetic for this procedure is a tumescent solution: a combination of 400 ml normal saline, 90 ml one percent lidocaine without epinephrine, 10 ml 8.4 percent sodium bicarbonate and one ml of epinephrine 1:1000.

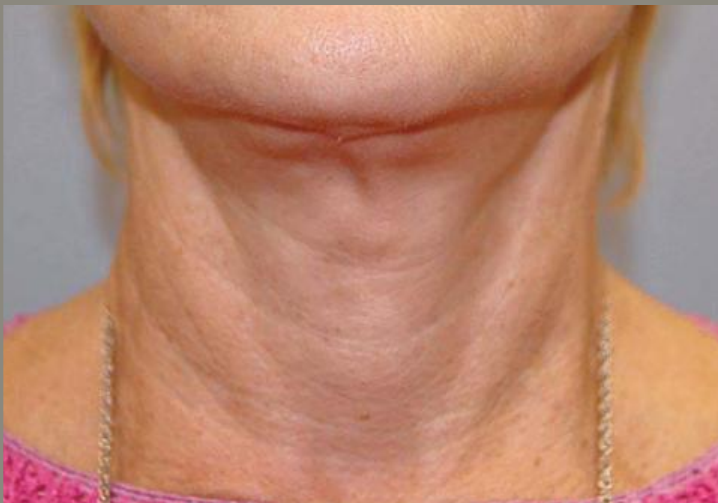
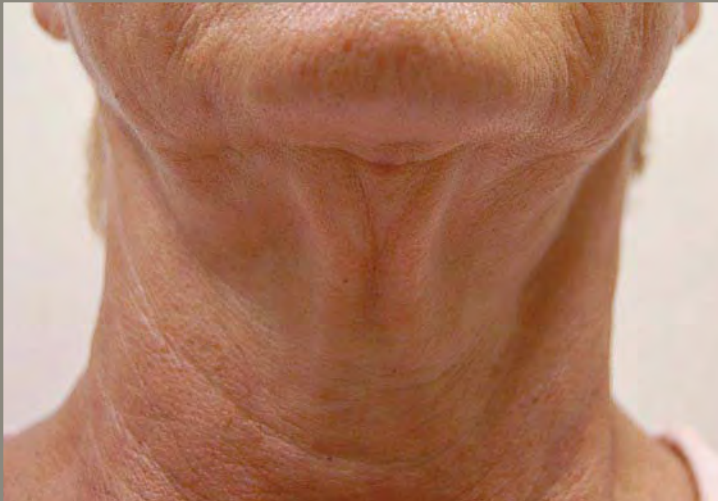Preoperative antibiotics are also administered to prevent bacterial infections. Cephalexin is the primary antibiotic of choice as it can be used in patients with certain heart problems as a means to prevent coronary infection (bacterial endocarditis). Cleocin may be used to fight bacterial infections in patients who are allergic to penicillin. Azithromycin—known as z-pack—may be used postoperatively. In most cases, a sedative is used. Five to 10 mg of diazepam is administered sublingually to treat anxiety in patients who request it. The sedative is used based on patient preference; however, the surgeon will dictate the dose to be administered.

The patient is placed in the seated position and the surgical technologist cleans the patient's neck with surgis-crub. The patient's thoracic region is draped in order to create and maintain the sterile field during the procedure. The surgeon then outlines the planned incisions with a sterile marking pen on the submental region. The local anesthetic is administered by injection into the surrounding area.

The surgical technologist sets up the Mayo stand with the following instrumentation:

- ▲ #15 knife blade and knife handle
- ▲ Army-Navy retractor
- ▲ Adson forceps with teeth
- ▲ DeBakey tissue forceps
- ▲ Needle holder
- ▲ Curved and straight Metzenbaum scissors
- ▲ Small mosquito (placed to the side in case it is needed)
- ▲ 4x4s
- ▲ 5.0 nylon suture
- ▲ 2.0 PDS

- ▲ Surgeon's magnified intense glasses
- ▲ Electrosurgical pencil with needle-tip electrode (ESU)
- ▲ 0.9 percent sodium chloride for irrigation and kidney basin
- ▲ Long tip cotton applicator
- ▲ Elastic bandage (wrap)
- ▲ Sutures and dressings of the surgeon's preference



Copyright/property of Kamran S. Ja'fari, MD

In addition, the surgical technologist will lay out the sterile gloves, bouffant/cap and the head light source to be used during the procedure.

## OPERATIVE PROCEDURE

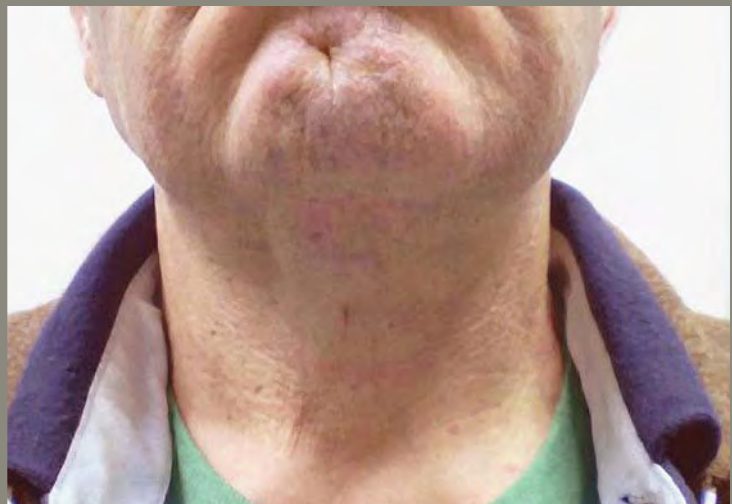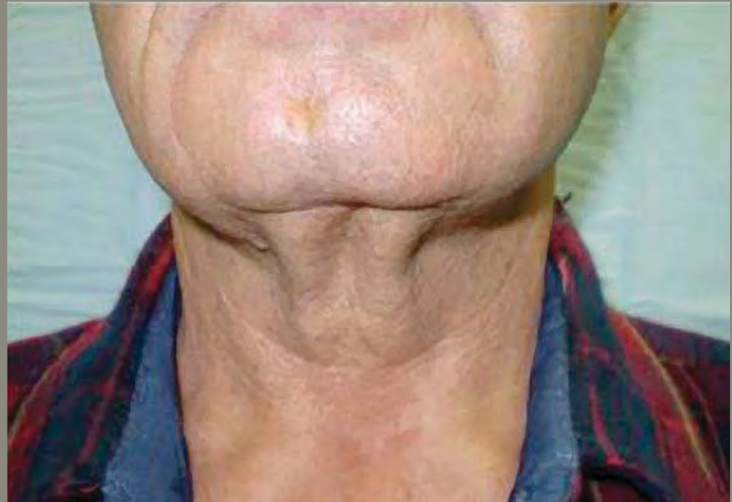Using the #15 blade, the surgeon makes a one-inch submental incision. The ESU is then used to coagulate the blood vessels while the surgical technologist pats the area dry using the sterile 4x4s. Using a toothed Adson forceps to grasp the external derma, the dissection is continued subcutaneously, in a horizontal direction of the submental region. Using a straight Metzenbaum scissor, the surgeon separates the subcutaneous layer from the platysma muscle and exposes the fat pad.

The surgeon inserts an Army/Navy retractor approximately one inch into the incision, creating an open pocket, which is held in place by the surgical technologist. The surgeon then removes any excess adipose tissue by grasping it with a DeBakey in one hand and cutting it using a curved Metzenbaum scissor with the other. The surgical technologist removes the excised fat from the DeBakey with a 4x4. The ESU is used throughout to coagulate additional blood vessels as needed. Opened and elongated 4x4s are saturated in saline and inserted momentarily into the subcutaneous path for irrigation purposes, during which time the Army/Navy retractor is removed. When the 4x4 is extracted, the Army/Navy retractor is reinserted. The surgical technologist must keep an accurate count of the 4x4s during this process. This series of actions is repeated until the surgeon is satisfied that all necessary excess fat has been removed and the platysma muscle is sufficiently exposed.

Using the DeBakey, the surgeon collects both posterior ends of the platysma muscles that have separated and trims any uneven edges in order to suture them together with a 2.0 PDS (non-coated, monofilament polydioxanone suture), using a reverse mattress stitch, to load and release the memory. The external submental derma is then flattened out and the excess is approximated to determine the

appropriate length to trim based on the initial incision line or cervicoplasty.

Using an Adson forceps with teeth, the surgeon holds the external derma with one hand and, with the other, trims away the excess skin using curved Metzenbaum scissors.



Copyright/property of Kamran S. Jafri, MD

sors. The amount of skin removed is customized for each patient. Using a 5.0 nylon suture, a subcutaneous stitch is applied with slight tension. Alternatively, a simple, uninterrupted stitch on the natural crease may be used. The method of suturing is based on the surgeon's preference and is chosen based on the amount of fat that has been removed,

thus it will vary from patient to patient. The suture ends are cut short to prevent them from causing interference. The 4x4 with antibiotic ointment should not adhere to the stitches and snag the skin when wrapped with the elastic bandage wrap.<sup>3</sup>

Another suturing technique that may be used is the “corset platysmaplasty,” so named for its similarity in appearance to the “X” pattern of an old-fashioned corset when fully laced. In this alternative, the muscle is gathered and sutured with a snug jaw line and a right-angled neck contour. This produces a successful restructuring of the platysma muscle at the midline.<sup>4</sup>

Once the procedure is completed, the patient’s vital signs are taken and recorded again. Prescriptions for antibiotics, which are mandatory, and any necessary pain relievers are noted. Many patients’ pain-relieving needs can be met with over-the-counter extra strength acetaminophen. A follow-up appointment is scheduled for the following week, and the patient is provided with written postoperative instructions. The surgeon will call the patient to follow up, but the patient is also instructed to call the surgeon with any concerns or to report any changes in their condition.

#### **POSTOPERATIVE CARE**

An elastic bandage should be wrapped around the head and neck for the first 24 hours postoperatively, and patients should be monitored by a friend or family member during this time. The bandage should be snug and comfortable, but not tightly wrapped. At the patient’s discretion, it may be worn for five days following the surgery for support, however, it should be removed to bathe and eat. Patients are advised to keep ice packs on the surgical area every three to four hours for the first 48-72 hours after surgery. The patient’s head must be elevated while sleeping to minimize edema, and it is suggested that patients sleep with two pillows to ensure this is maintained. No strenuous exercise is allowed, although short walks are acceptable. The patient’s diet must also be monitored as a restricted salt intake will reduce facial swelling. In addition, patients are encouraged to eat foods that are enriched with vitamin C, zinc and iron to promote healing.

Mild swelling in the surgical area may be present for up to six months postoperatively. Patients must also use a ther-

момeter to monitor increases in temperature, which may be an early sign of a possible surgical site infection. During this time, the patient should cleanse the surgical site using sterile gauze and a 50-50 mixture of hydrogen peroxide and water. Antibacterial ointment should be applied to the incision site after each cleansing.

All antibiotics must be finished as prescribed, and aspirin, ibuprofen, vitamin E and fish oil supplements are not allowed during the first week following surgery to help prevent bleeding.

The bandage should be snug and comfortable, but not tightly wrapped. At the patient’s discretion, it may be worn for five days following the surgery for support, however, it should be removed to bathe and eat.

#### **POSTOPERATIVE RISKS AND COMPLICATIONS**

Swelling, bruising and mild discomfort are common and should be expected in the week following a procedure. Infections, seroma, bleeding and hematoma, while not normally considered serious, may occur and should be monitored carefully. If a hematoma is detected—generally indicated by excessive swelling within 12 hours of the procedure’s completion—the patient must return to the surgeon’s office to have it drained with a needle in a sterile setting. Left untreated, it may become infected and possibly cause necrosis of the derma around the surgical site or enter the blood stream, leading to more complications.<sup>6</sup> If the incision site acquires a green or yellow coloration, it could signify a possible infection or that blood circulation to the area is impaired.

Follow-up visits are scheduled for one week post-procedure, two weeks post-procedure and four weeks post-procedure. At the final visit, another set of photographs are taken to compare to the pre-surgical images.

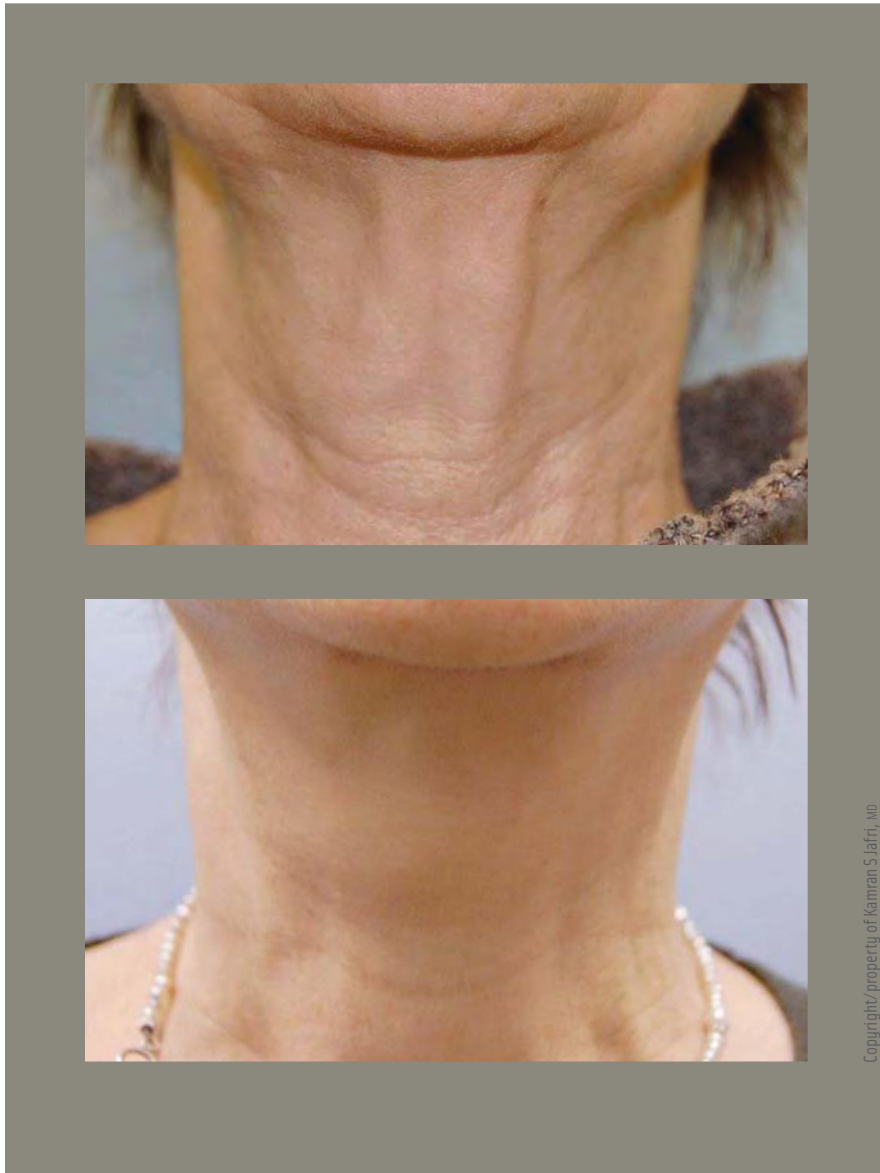
#### **CONCLUSION**

The end result of a successful platysmaplasty is a refined, smooth neck that enhances the patient’s features for a more youthful appearance. It can be combined with a face lift, filler, chemical peel and botulinum toxin injections.

Neck lifts may also be performed endoscopically, which is less invasive. This procedure lasts about an hour and a small incision is made under the chin through which the endoscope is inserted. Another alternative is a liposuction procedure, which also lasts about an hour and involves a small incision under the chin through which the fat is extracted. Finally, botulinum toxin injected directly into the platysma muscles will counteract muscle weakening and stop contractions.

#### ABOUT THE AUTHOR

Nydia I Morales, CST, was an elementary school teacher before entering the medical field. She graduated from New York University Langone Medical Center's surgical technology program in New York City, and became certified in September 2007. She presently assists Kamran Jafri, MD, as his surgical technologist in facial plastic surgery in New York City. She is also an adjunct lecturer (clinical site: Maimonides Medical Center) in the surgical technology program at Kingsborough Community College in Brooklyn, New York.



#### References

1. Mosby's Medical Dictionary, 8th ed. 2009. Elsevier.
2. Owsley J. 2007. drjohnowsley.com. "What is the 'SMAS'?" SMAS-Platysma Face-lift. Accessed: 5/7/2010. Available at: <http://www.drjohnowsley.com/html/smas.html#smas>.
3. Fuller J. Surgical Technology: Principles and Practice, 5th ed. 2010. Elsevier. p 746.
4. Feldman, J. Neck Lift. Quality Medical Publishing Inc. p 50.
5. Jafri K. Custom-Lift. Accessed: 5/7/2010. Available at: [www.custom-lift.com](http://www.custom-lift.com).
6. WebMD. 2010. "Cosmetic Surgery and the Neck Lift." Accessed: 5/7/2010. Available at: <http://www.webmd.com/skin-beauty/guide/cosmetic-procedures-neck-lift>

Copyright/property of Kamran S Jafri, MD