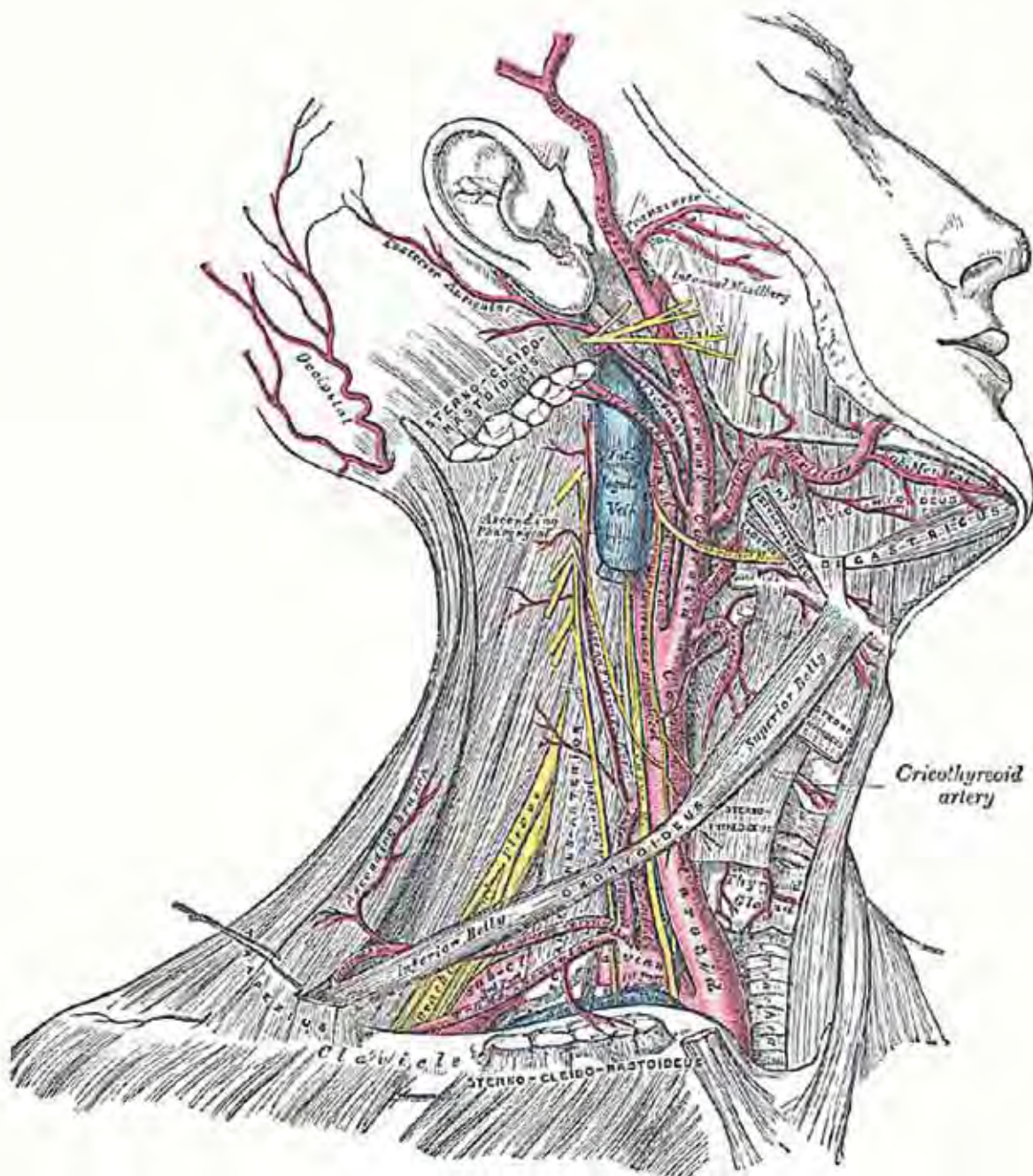

Radical Neck Dissection

Deborah D. Lamb, CST

A radical neck dissection is performed when malignant lesions are found in a patient's head and/or neck, as well as in his or her cervical nodes. This metastasis happens through the lymphatic channels via the bloodstream. The disease can affect the oral cavity, lips and the thyroid gland, which in turn can cause the cancer to spread slowly to the neck.

HISTORY

The first radical neck dissection was described and performed by George Washington Crile at the Cleveland Clinic in 1906.¹ The revolutionary procedure marked a great step forward in the treatment of metastatic neck diseases. At the time, Crile, a founding member of both the Cleveland Clinic and the American College of Surgeons, was already well known for his work in thyroidectomies, of which he performed more than 25,000 in his career.¹

As performed by Dr Crile, the radical neck dissection called for the removal of all the lymph nodes on one side of the neck, as well as the spinal accessory nerve, internal jugular vein and sternocleidomastoid muscle. The main drawback to this procedure was shoulder dysfunction, which occurred due to the sacrificing of the accessory nerve.² Future practitioners eventually established more conservative measures.

It wasn't until the 1940s that surgery began to take over as the treatment of choice for the majority of cancers of the head and neck. It was in this time frame that advances in the field of anesthesiology allowed for more elaborate surgeries. Additionally, the introduction of antibiotics during the second World War allowed

LEARNING OBJECTIVES

- ▲ Review the relevant anatomy for this procedure
- ▲ Examine the set-up and surgical positioning for this procedure
- ▲ Compare and contrast the modifications of the radical neck dissection
- ▲ Assess the risks and benefits of skin and nerve grafts
- ▲ Evaluate the step-by-step procedure for a radical neck dissection

surgery to emerge as the primary choice for management of cancers of the head and neck.³

In the 1940s and 50s, Hayes Martin, MD, performed radical neck dissections on a routine basis in order to manage neck metastasis. The main objective, as he saw it, was to remove and block the entire ipsilateral lymphatic structures from the mandible to the clavicle and from the infrahyoid muscles to the anterior border of the trapezius. His method also resected the spinal accessory nerve, the internal jugular vein, the sternocleidomastoid muscle and the submandibular gland. The remaining structures, including the carotid arteries, vagus nerve, hypoglossal nerve, brachial plexus and phrenic nerve were left intact.⁴

In the early 1960s, an Argentinean surgeon, Oswaldo Suarez, described the facial compartments in the neck and facial envelope covering a selective group of lymph nodes. He proposed a modification of Crile and Martin's radical neck dissection, which he termed as a functional neck dissection. Suarez's method was to remove a selected group of lymph nodes and preserve the vital structures, including the accessory nerve, jugular vein and sternomastoid muscle that Crile's procedure had originally designated for extraction.² This method was further popularized in Europe by Ettore Bocca and Caesar Gavilan, and in the United States by Richard Jesse, Alando Ballantyne and Robert Byers.²

The last four decades have made way for progressive advances to occur, giving an understanding of cervical fascial planes, lymphatic drainage patterns, preoperative staging and extracapsular spread. In 1991, a report was published by the American Academy of Otolaryngology-Head and Neck Surgery that standardized the terminology for the different types of neck dissections. In 2001, the report was updated with very few changes. These changes dealt with the application of various types of selective neck dissection procedures for oral cavity, pharyngeal and laryngeal, thyroid and cutaneous malignancies.

The modifications to the radical neck dissection are as follows:

Type I: The spinal accessory nerve is preserved.

Type II: The spinal accessory nerve and the internal jugular vein are preserved.

Type III: The spinal accessory nerve, internal jugular vein and the sternocleidomastoid muscle are preserved.

Extended Radical Neck Dissection: The lymph node groups and/or additional structures not included in the classic neck dissection are resected.

PRE-SURGICAL PREPARATION

The patient is placed on the OR table in the supine position. The anesthesiologist administers general endotracheal anesthesia, after which the patient is positioned for surgery. The patient's head is extended moderately with the affected side of the face and neck facing upward. The shoulder on the operative side is slightly rotated so that the surgical field from the posterior midline of the neck to the anterior midline of the neck is accessible. The face and neck skin prep is extensive and starts at the hairline and goes down to the nipples, as well as down to the table both anterior and posterior. If a skin graft is to be harvested, the thigh is also prepped and draped using sterile towels that are placed over the sterile area for later use as the dermal skin graft before the neck wound is closed. This graft is used to protect the carotid artery due to the possibility that the patient has undergone extensive previous or preoperative radiation therapy.

The patient is draped with a head drape, which consists of a drape sheet and two towels under the head with the upper towel wrapped around the head and clamped. The neck is draped with folded towels and secured with sterile plastic adhesive. Some surgeons' preference is to suture or staple the sterile towels to the skin. Once the sterile towels are in place, the fenestrated sheet, (diagram A), is then placed over the patient.

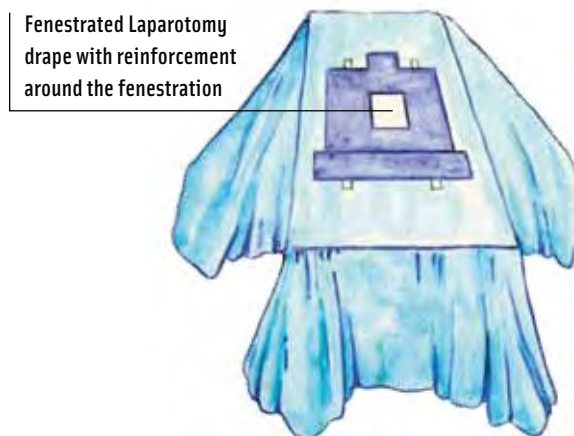

Diagram A

Instrumentation setup for this surgical procedure varies, depending on the surgeon's preference. The surgical technologist should familiarize him or herself with the surgeon's preference card, however, each setup does include the following:

- 50 Mosquito hemostats, curved
- 8 Allis forceps
- 8 Kelly hemostats
- 8 Pean forceps
- 4 Thyroid tenacula
- 4 Babcock forceps
- 2 Right angle clamps
- Assorted needle holders
- 12 Towel clamps
- 2 Tonsil suction tubes
- 1 Trousseau tracheal dilator
- 2 Rake retractors
- 2 Army-Navy retractors
- 2 Richardson retractors
- 2 Vein retractors
- 4 Skin hooks, 2 single and 2 double
- 1 Gelpi retractor
- 4 knife handles, no. 3, with no. 10 and no. 15 blades
- 1 Tracheal hook
- 2 Mayo scissors, straight and curved
- 2 Metzenbaum scissors
- 2 scissors, small, curved, sharp and blunt
- 4 Tissue forceps, 2 with and 2 without teeth
- 2 Adson tissue forceps
- 2 Brown-Adson tissue forceps
- 1 Periosteal elevators
- 2 Freer elevators
- 1 Bayonet forceps
- Brown or Stryker dermatome (if a skin graft is anticipated)

EQUIPMENT:

- Suction
- Electrosurgical unit (ESU)
- Scales (to weigh sponges)

SUPPLIES:

- Foley catheter and urimeter
- Basin set
- Marking pen
- Suction tubing
- Electrosurgical pencil

- Needle magnet or counter
- Graduate
- Bulb syringes (2)
- Dissectors (peanut)
- Umbilical tapes, vessel loops
- Nerve stimulator (locator)
- Suction drainage unit (Hemovac)
- Lap sponges
- 4x4 Raytech sponges

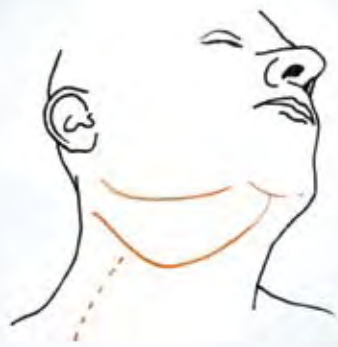As with instruments, equipment and supplies vary depending on surgeon preference, so it is always a good idea to familiarize oneself with the surgeon's preference card.

The last four decades have made way for progressive advances to occur, giving an understanding of cervical fascial planes, lymphatic drainage patterns, preoperative staging and extracapsular spread.

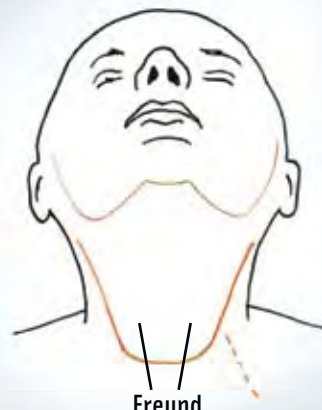THE SURGICAL PROCEDURE

The surgical incision is made starting at the lateral neck from beneath the jaw to the supraclavicular area (diagram B). Skin flaps are mobilized while hemostasis is achieved using fine hemostats as well as ligatures on bleeding vessels. Once the skin flaps are freed, the surgeon places a traction suture in different areas of the skin flap and then places a hemostat on the end. This is done to retract the skin flap for better exposure. Using curved scissors, the anterior trapezius muscle is exposed, as well as the external jugular vein. The trapezius muscle and the external jugular vein are clamped, ligated and divided. The internal jugular vein is then found, isolated and divided. The omohyoid muscle is identified and transected. The fatty tissue in the neck houses lymph nodes. These lymph nodes are dissected away from other structures and the common carotid artery and vagus nerve are identified (diagram C).

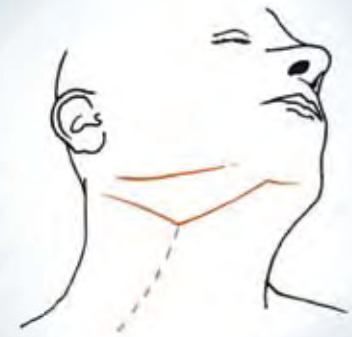The thyrocervical artery is then clamped, divided, and ligated. The posterior triangle are dissected starting at the anterior of the trapezius muscle and continuing to the bra-



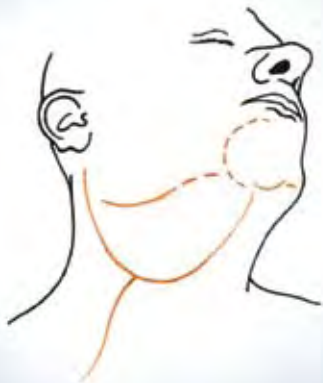Latyshevsky and Freund



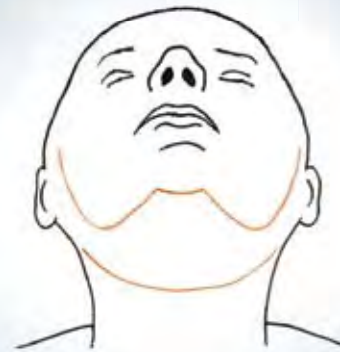Freund



Crile



Incision used for unilateral supra-omohyoid neck dissection



Incision used for bilateral supra-omohyoid neck dissection

Diagram B

chial plexus, the levator scapulae and the scalene muscles. Branches of the cervical and suprascapular arteries are identified then clamped, ligated, and divided. Once the anterior portion dissection is complete, the omohyoid muscle is severed where it attaches to the hyoid bone. Once hemostasis is controlled, all hemostats are removed. The surgical field is then covered with warm, moist, sterile laparotomy packs. Next, the sternocleidomastoid muscle is cut and retracted out of the way. At this point the submental space is dissected from fatty tissue that houses lymph nodes, starting upward and working down. The fascia that is deep on the lower portion of the mandible is then incised and the facial vessels are then divided and ligated.

Entering the submandibular triangle, the submandibular duct is divided and ligated. The submandibular glands that have fatty tissue and lymph nodes surrounding them

are dissected going toward the digastrics muscle. The facial branch of the external carotid artery is identified and divided. Parts of the digastrics, as well as the stylohyoid muscles, are then cut where they attach to the hyoid bone and mastoid. The top end of the internal jugular vein is elevated and divided, and the mass is removed.

The entire surgical site is checked for any bleeding and irrigated with warm saline solution. If a skin graft is needed, it is placed over the bifurcation of the carotid artery downward about four inches, then sutured using 4-0 absorbable suture on a small cutting needle. Tubing for the Hemovac drain, if that is the surgeon's preference, is placed in the wound. The skin flaps are then approximated and closed with interrupted, fine non-absorbable sutures or skin staples. A pressure dressing is applied to the neck, which also depends on the surgeon's preference.

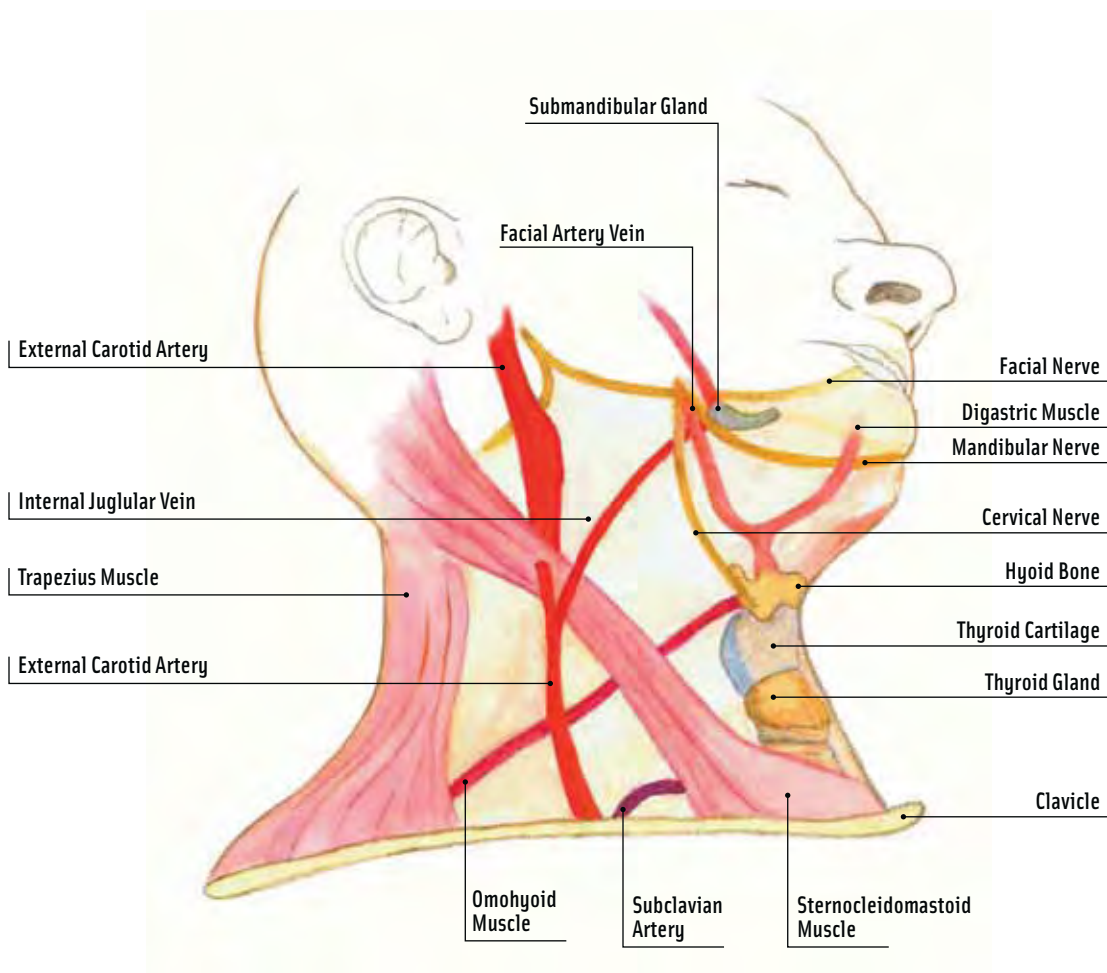
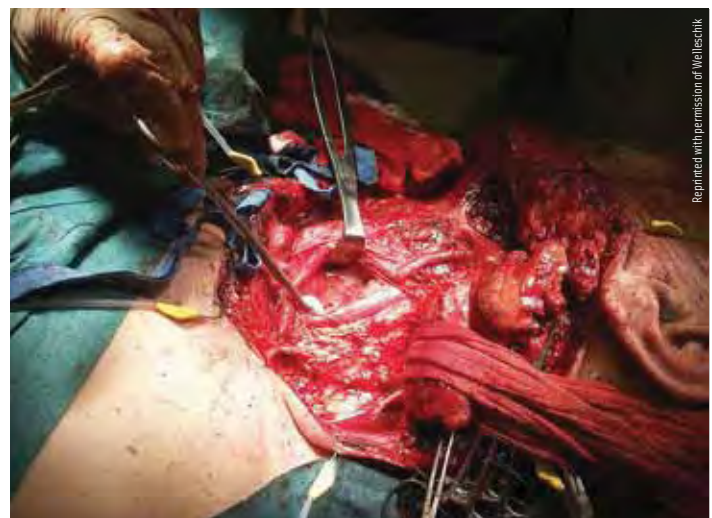

Diagram C

RECONSTRUCTIVE PROCEDURES

When reconstructive procedures are performed, the method used depends on the surgical defect. The surgical wound may be closed primarily or with split-thickness skin grafts. Local flaps may be used. These skin grafts are used for facial or intraoral defects. For nasal and facial defects, full-thickness skin grafts are used. The pectoralis major musculocutaneous flap is an example of a regional flap. The radial forearm flap, free jejunal flap and rectus abdominis flap are used for microvascular tissue transfer. The iliac crest flap is used for microvascular osteocutaneous flaps. All of these flaps are used to restore function and cover defects. The grafts and flaps listed above are performed when it is deemed necessary due to large defects that are created. When microvascular flaps are used, surgical and anesthesia time increase significantly. This is because veins and arteries are connected



Radical Neck Dissection

microscopically. Nerve grafts and bone grafts may also be used, and must be connected by using plates and screws.

In a 2000 study, published in *The Laryngoscope*, it was determined that allograft, or cadaveric tissue, may be useful in this type of procedure. Benefits of allograft include a reduction in the the surgical time, as well as the amount of time that a patient is under general anesthesia. AlloDerm® is a dermal graft that is derived from banked human tissue. Because it has been decellularized, AlloDerm® does not induce an immune response in the body, reducing the probability that the graft will be rejected.⁵ The study concludes that a previously-irradiated field does not adversely affect the integration of AlloDerm®, making it a potentially viable alternative to an autograft option—or the harvesting of the patient’s own tissue for reconstructive purposes. Originally developed for use in burn patients, it has recently made strides toward wider acceptance and utilization in different surgical settings.

Doppler units are used intraoperatively as well as postoperatively. It is paramount to have thorough nursing assessment skills so that occlusions and/or spasms of the vessels can be spotted in order for the transplanted flap to survive. The patient’s average hospital stay is 13-15 days.

SPECIAL NOTE:

- * Make sure the blood bank has blood available and ready for the patient as ordered.
- * The surgical sponges must be weighed and the irrigation fluids measured accurately.

ABOUT THE AUTHOR




Deborah D Lamb, CST, graduated from Hinds Community College in Jackson, Mississippi as a President’s Scholar in 1997. She worked at a Level I trauma center in Jackson until 1998, when she transferred to a small hospital in Athens, Alabama, where she worked until 2000. After spending six years as a vet tech, Ms Lamb decided to retire, but she continues to maintain her certification.

AlloDerm® is a registered trademark of LifeCell Corp.

References

1. Kazi, RA. “The Life and Times of George Washington Crile: An Outstanding Surgeon.” *The Internet Journal of Otorhinolaryngology*. 2003. Vol 2, No 2.
2. Shaha, A. 2007. “Editorial: Complications of Neck Dissection for Thyroid Cancer.” *Annals of Surgical Oncology*. Accessed: August 19, 2010. Available at: <http://www.ncbi.nlm.nih.gov/pmc/articles/PMC2244697/>.
3. American Head & Neck Society. 2005. “Hayes Martin Biography.” Accessed: August 19, 2010, Available at: <http://www.ahns.info/foundation/hayesmartin.php>.
4. Martin, H. “The Treatment of Cervical Metastatic Cancer.” *Annals of Surgery*. 1941. Vol 114, No 6. Available online at: <http://www.ncbi.nlm.nih.gov/pmc/articles/PMC1385835/pdf/annsurg00378-0016.pdf>.
5. Dubin, M; Feldman, M, et al. “Allograft Dermal Implant (AlloDerm) in a Previously Irradiated Field.” *The Laryngoscope*. Lippincott Williams & Wilkins, Inc. Philadelphia. 2000.



Earn CE Credits at Home

You will be awarded continuing education (CE) credits toward your recertification after reading the designated article and completing the test with a score of 70% or better. If you do not pass the test, it will be returned along with your payment.

Send the original answer sheet from the journal and make a copy for your records. If possible use a credit card (debit or credit) for payment. It is a faster option for processing of credits and offers more flexibility for correct payment. When submitting multiple tests, you do not need to submit a separate check for each journal test. You may submit multiple journal tests with one check or money order.

Members this test is also available online at www.ast.org. No stamps or checks and post to your record automatically!

Members: \$6 per credit
(per credit not per test)

Nonmembers: \$10 per credit
(per credit not per test plus the \$400 nonmember fee per submission)

After your credits are processed, AST will send you a letter acknowledging the number of credits that were accepted. Members can also check your CE credit status online with your login information at www.ast.org.

3 WAYS TO SUBMIT YOUR CE CREDITS

Mail to: AST, Member Services, 6 West Dry Creek Circle Ste 200 Littleton, CO 80120-8031

Fax CE credits to: 303--694-9169

E-mail scanned CE credits in PDF format to: memserv@ast.org

For questions please contact Member Services - memserv@ast.org or 800-637-7433, option 3. Business hours: Mon-Fri, 8:00a.m. - 4:30 p.m., mountain time