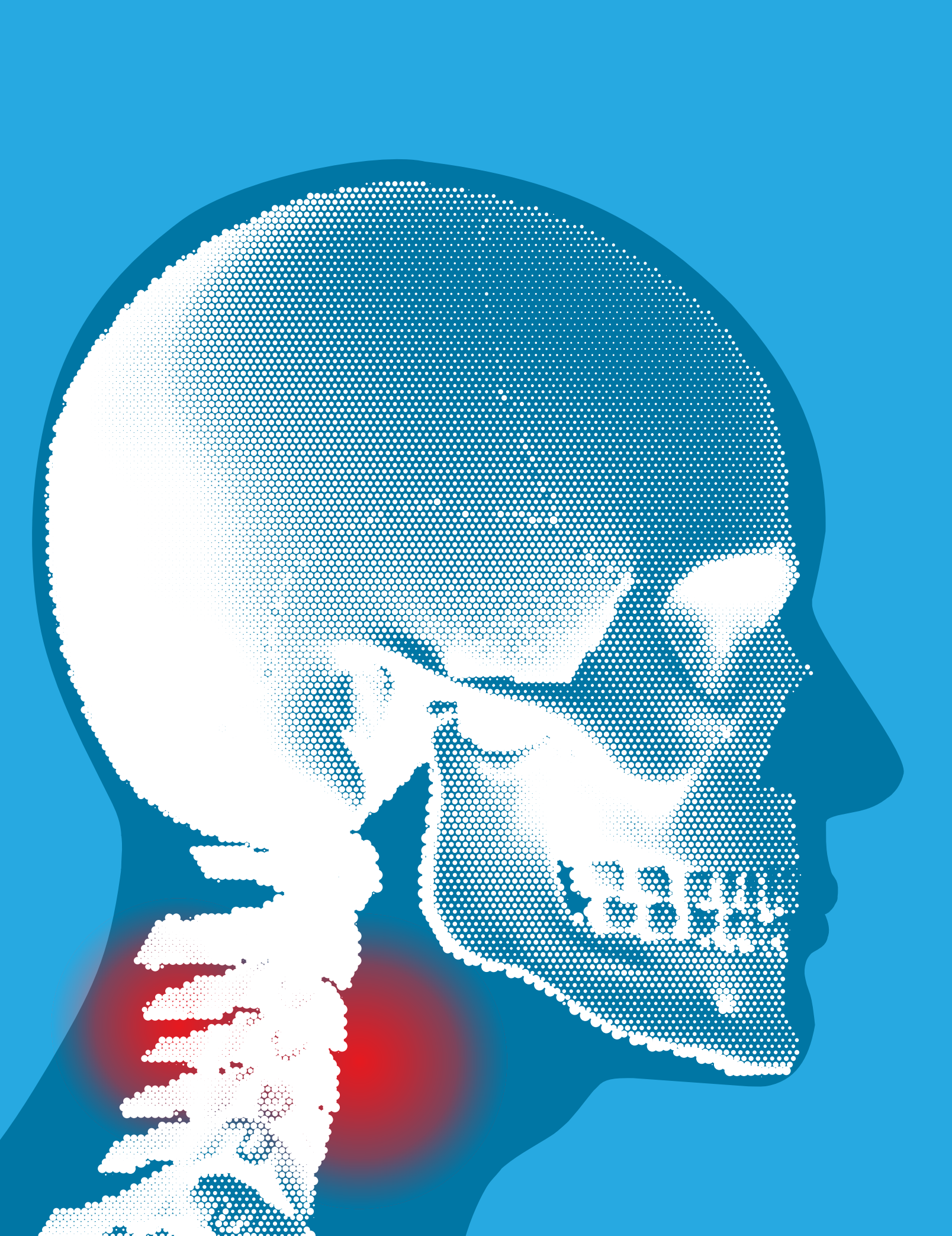

# Cervical Laminoplasty

MURRIAH EPIDENDIO, CST

Laminoplasty is the surgical repair of the lamina, which is the bony roof of the spine. This consists of hinging one side of the lamina and completely freeing the other side, which allows millimeters of extra space for the spine. To keep the hinged lamina open, metal plates are placed along the open side, which are often coupled with a bone graft. The bone graft will eventually fuse with the lamina to create a complete vertebral body. The procedure can be done for many reasons; however, the most common diagnosis being cervical stenosis – the abnormal narrowing of the cervical spine due to traumatic injury or degeneration of the cervical spine.

## PATHOPHYSIOLOGY

**G**eneral pathophysiology of the cervical spine is vast, and can be broken down into two divisions: cervical trauma and degenerative cervical spine.

For cervical trauma, classification systems have been developed to predict instability and to standardize the injury types. These systems are broken into two categories: upper cervical spine and subaxial cervical spine. The cervical spine has its own classifications due to each unique injury pattern and level of injury. The subaxial cervical spine also has its own classifications. One of the first and most commonly employed systems is the Allen and Ferguson classification. This system identifies six injury types: compression-flexion, compression-extension, vertical-compression, distraction-flexion, distraction-extension and lateral flexion. Each of these six groups has its own patterns that further characterize a patient's injuries. These types of injuries include occipitocervical dissociation, occipital condyle fractures, atlas frac-

## LEARNING OBJECTIVES

- ▲ Review the general pathophysiology for cervical laminoplasty
- ▲ Examine the techniques used when performing this procedure
- ▲ Identify the instruments and equipment necessary to a cervical laminoplasty
- ▲ List the complications associated with this type of operation
- ▲ Grasp a better understanding of the cervical spine

tures, atlantoaxial rotatory instability, atlantodens instability, odontoid fractures, traumatic spondylolisthesis, subaxial cervical spine trauma, flexion injuries, vertical compression injuries, extension injuries and vertebral artery injuries.

Degenerative cervical spine may occur from traumatic injuries, or more commonly from degenerative cervical disorders. Those disorders include cervical spine stenosis, cervical disc herniation and cervical spondylosis.

Degenerative cervical spine is defined as disc degeneration that is chronic and also affiliated with facet arthropathy that may lead to cervical myelopathy, cervical radiculopathy and/or discogenic neck pain. Degenerative compression may progress to where a patient's neurological functions deteriorate, thus resulting in a surgical procedure to spare the patient from further decline. Degenerative cervical spine may occur from traumatic injuries, or more commonly from degenerative cervical disorders. Those disorders include cervical spine stenosis, cervical disc herniation and cervical spondylosis.

All of these injuries or disorders have their own symptoms and levels of pain, which can vary greatly and include neck stiffness to pain radiating in the neck, head and arms to muscle weakness to more severe symptoms of loss of motor milestones and neurological deterioration.

## DIAGNOSTICS

Physicians will most likely run several tests to diagnose conditions and traumatic injuries to the cervical spine. These can include spiral CT scans, discography, nerve conduction studies and CT myelography. A procedure will be determined by the patient's test results and level of pain. For this article's purpose, the case study reflects a cervical laminoplasty C-3 to C6. The patient was complaining of difficulty swallowing, neck pain and left upper extremity pain. The patient had a cervical discectomy and fusion of levels C5 to C7 in a previous operation. After current X-rays and an MRI, the surgeon determined that patient was being affected from cervical spinal stenosis and myelomalacia within the canal from levels C2-C7.

After consultation with the surgeon, the patient decided on surgery posteriorly to try to decompress the cervical spine for stabilization.

## SURGICAL INTERVENTION

Once the room is prepared and the surgical technologist is gowned and gloved, the surgical technologist organizes the Mayo stand and back table. The distributor of cervical plates, screws and other case-specific instrumentation also is placed on the back table and organized. After the surgical technologist receives confirmation from the surgeon about which plates and screws will be used, the patient is given anesthesia and positioned in prone position using an OSI Jackson spine table with a long draw sheet on top of the hip pads. Four pillows will be placed under the patient's bony prominences and pressure points, and a prone view cushion will be used for the patient's face. Egg-crate padding is placed under the patient's arms and the arms are wrapped with a draw sheet to lock the arms next to the patient's side. A Bair hugger and warm blanket is placed over the patient's lower body. The surgical site is prepped with an antimicrobial solution from just below the ears down to just above the shoulder blades, and down the side of the neck bilaterally to the table.

## DRAPING

Draping will include four towels to square off the incision site, with another four half sheets placed in the same manner as the previous four towels. An antimicrobial incise drape is placed over the incision site, and the lap drape is placed where the anesthesiologist will place the superior end around the poles and clip them with the foot end extended out.

After the surgeon and assist are gowned and gloved, the surgical technologist moves the Mayo stand to its position and after a time out is performed, the operation can begin. The posterior incision is made starting just below the ear line in the middle of the neck, three to four inches down to just below the base of the neck with a #10 blade on a #3 handle. The surgeon uses the electro-surgical pencil to dissect through the subcutaneous tissue. Once the muscle is reached, the surgeon applies a cerebellar retractor to hold the subcutaneous layer. The electro-surgical pencil is used to dissect the muscle, assisted with blunt dissection from the Cobb elevator. The muscle is dissected on the left and right

sides of the cervical vertebra column. Once the spinous process of the cervical spine is in view, the cerebellar retractor is removed and the McCullough retractor is placed. A Kocher clamp is placed on the spinous process and the c-arm is used to view which level the Kocher clamp is on. This will serve as a beginning landmark for the procedure. The tissues around the affected levels are dissected further with the electro-surgical pencil. The Yankauer is used during dissection to keep the site free of fluids and small debris, and removes the cautery plume. A Weitlaner retractor is used to keep the dissected tissue out of view and mark the cervical level on the c-arm. The c-arm again is employed to check the level the Weitlaner is at.

The electro-surgical pencil is used to dissect more tissue from the vertebral bodies of levels affected. Once both the left and right sides of the lamina are in clear view, the left sides are scored to create the hinge effect using the burr. While the first assistant continues to suction, the surgeon uses an absorbable porcine gelatin on the hinged sides to minimize bleeding. Using the burr, the right side lamina is cut through, and the surgeon is careful not to damage the intervertebral discs and spinal cord. An absorbable porcine gelatin is used on the incision side to minimize bleeding. As the surgeon uses a Kerrison rongeur, a sponge should be used to clean up bone fragments. The surgeon then employs the Scoville curette to lift the right side to verify it is completely free.

If the surgeon decides to make the incision longer on the inferior end, the electro-surgical pencil with suction is used. Once the incision is elongated, the McCullough and Weitlaner retractors are repositioned to accommodate the larger incision. The surgeon dissects the muscle at the inferior end of the incision with the electro-surgical pencil to uncover level C6. The burr is used to score the left side of C6 to create a hinge and the right side is cut completely through. The surgeon checks its freeness with the Scoville curette and the first assistant changes the Rhoton suction tip. As the uses the Love-Kerrison rongeur, the surgical technologist uses a sponge to clear away bone fragments. When larger bone pieces need to be removed, the surgeon uses the Love-Kerrison rongeur to cut them.

Once the sides of the lamina are free, the surgeon uses the trial measurement tool to decipher the size of the bone graft needed to fit the opening of the level. Once the size of the bone grafts is determined, it is screwed into the center-piece plate provided by the distributor. After the bone graft

SUPPLIES AND EQUIPMENT
ESU pad
Cottonoids with string ½ X 2"
Cover cart
Antimicrobial skin prep
Foley strap
Yankauer hip suction
C-arm drape
Foley catheter
Rhoton traumatic suction tips
Large gelfoam for hemostasis
OSI Jackson bed for the patient
Suction apparatus
Electrosurgical unit
C-arm with a radiology tech to take X-rays during and after the procedure
A lead door/wall to protect staff in the room when the c-arm is employed
An operating microscope
Bair hugger
Suture, surgeon's preference
Laminectomy set
Distributor's set
Neurosurgery electrical drill
Burrs

is in place, the surgeon applies the centerpiece plate to the incised side of the level being worked on and aligns both ends of the plate with the respective bone. After alignment is achieved, the surgeon drills holes for the corresponding screws. A manual screwdriver is used to screw them into place. These steps are repeated for each affected level, following that order of action, respectively. Once all bone grafts, plates, and screws are in place, the surgeon pours a sodium chloride solution with bacitracin into the wound. The retractors are removed and the c-arm is employed to verify the centerpiece hardware and its placement. The bacitracin solution is then suctioned from the wound.

The cerebellar retractor stays in place so the wound remains open for placement of the drain. The surgeon makes a half-inch incision one inch away from the right side of the wound and uses a hemostat to dissect through the half-inch incision until the hemostat tips are seen

inside the original wound. The tip of the drain tubing is clamped with a hemostat and it is threaded through the half-inch incision until tubing enters the wound. A portion of the tubing is cut and a 4-0 poliglecaprone 25 is used to keep the drain tubing in place. The surgeon closes the muscle and fascia layers with a 0 polyglactin 910 on a CP-1 needle. The subcutaneous tissue is closed using a 2-0 polyglactin 910 on a CP-2 needle. Before closing the patient's skin, the surgeon uses a bupivacaine hydrochloride solution just under the skin to help with pain. The skin is then closed using a 4-0 poliglecaprone 25 on a PS-1 needle. A betadine ointment is poured over the incision site and a dressing is placed over the area. The patient was extubated and woken up after transferred to the gurney.

### SPECIAL CONSIDERATIONS

Special considerations for this type of procedure include placing of a soft neck brace to keep the patient from moving their head to prevent further complications, as well as watching the drain and catheter bag during movement of the patient from the operating bed to the gurney.

Activity, especially walking, will be promoted as movement is the best way to heal tissue. Patients should limit lifting objects heavier than 10 pounds, especially over their head, for four to six weeks post-op.

### COMPLICATIONS

Hemorrhage, infection and destabilization of the spine can all occur following the procedure. The hardware used could potentially malfunction at any time and/or the screws could become loose and release from the bone. Fracturing of the hinged side of the lamina can occur and serious damage could occur if it fractures completely loose. Some patients have reported an incidence of wound complications due to the increased tension created by the effect of elevating the posterior structures. Nerve root palsy and axial neck pain also can occur following this type of procedure. A patient's range of motion may decrease and never fully return to normal.

### POST-OP

During the patient's hospital stay following surgery, the patient may experience issues with feeling, pain, or motor and/or sensory function and his or her neurological function will be closely monitored. Medication will be prescribed to help reduce pain. Once the patient is capable of moving on their own, the nurse will remove the catheter as long as the patient's urine is normal. Immediately after surgery, the nurse will confirm that there is no sign of nausea or vomiting of the patient due to anesthesia. The patient will stay in the hospital until the drain is removed, which is approximately three to six days. Once the patient is discharged, he or she should avoid bathtubs, pools, and hot tubs for at least three weeks or until the incision site has healed completely. Activity, especially walking, will be prescribed as movement is the best way to heal tissue. Patients should limit lifting objects heavier than 10 pounds, especially over their head, for four to six weeks post-op. Patients may be issued a neck brace and pain medications as needed. Sutures will be removed two to three weeks after surgery during a post-op visit.

### ABOUT THE AUTHOR




Murriah Epidendio, CST, attended San Joaquin Valley College - Fresno.

### REFERENCES

1. Ahn, UM. (2001). *Occipitocervical fusion: A review of indications, techniques of internal fixation, and results*. Retrieved on January 25, 2013. [http://journals.lww.com/neurosurgery-quarterly/Abstract/2001/06000/Occipitocervical\\_Fusion\\_\\_A\\_Review\\_of\\_Indications.1.aspx](http://journals.lww.com/neurosurgery-quarterly/Abstract/2001/06000/Occipitocervical_Fusion__A_Review_of_Indications.1.aspx)
2. Allen, DJ. (2013). *Cervical laminoplasty*. Retrieved on January 25, 2013. <http://www.emoryhealthcare.org/spine/procedures/surgical-procedures/cervical-laminoplasty.html>
3. Farlex. (2013). *Cervical orthosis*. Retrieved on January 25, 2013. <http://medical-dictionary.thefreedictionary.com/cervicalorthosis>
4. Frey, KB. (2008). *Surgical technology for the surgical technologist: A positive care approach*. (Third ed.). Clifton Park, NY: Delmar Cengage Learning.
5. Horowitz, SH. (2012, February 16). *Overview of nerve conduction studies*. Retrieved on January, 25, 2013. <http://www.uptodate.com/contents/overview-of-nerve-conduction-studies>
6. Kim, PD. (2012, May 02). *Occipital condyle fractures*. Retrieved on January 25, 2013. <http://www.orthobullets.com/spine/2013/occipital-condyle-fractures>

7. Kim, PD. (2013, January 13). *Occipitocervical instability & dislocation*. Retrieved on January 25, 2013 from <http://www.orthobullets.com/spine/2014/occipitocervical-instability-and-dislocation>
8. Meyler, Z. (2013). *What is cervical radiculopathy?* Retrieved on January 25, 2013, <http://www.spine-health.com/conditions/neck-pain/what-cervical-radiculopathy>
9. Moore, D. (2012, November 08). *Cervical vertebral body fracture*. Retrieved on January, 25 2013 from <http://www.orthobullets.com/spine/2018/cervical-vertebral-body-fracture>
10. Moore, D. (2012, November 08). *Cervical spondylosis*. Retrieved on January 25, 2013, <http://www.orthobullets.com/spine/2029/cervical-spondylosis>
11. Moore, D. (2013, January 11). *Cervical facet dislocations & fractures*. Retrieved on January 25 2013 from <http://www.orthobullets.com/spine/2064/cervical-facet-dislocations-and-fractures>
12. Moore, D. (2013, January 17). *Traumatic spondylololthesis of axis (hangman's fracture)*. Retrieved on January 25, 2013. <http://www.orthobullets.com/spine/2017/traumatic-spondylololthesis-of-axis-hangmans-fracture>
13. Moore, D. (2013, January 09). *Atlantoaxial instability*. Retrieved on January, 25 2013 from <http://www.orthobullets.com/spine/2049/atlantoaxial-instability>
14. Moore, D. (2013, January 22). *Atlas fracture & transverse ligament injuries*. Retrieved on January 25, 2013. <http://www.orthobullets.com/spine/2015/atlas-fracture-and-transverse-ligament-injuries>
15. Moore, D. (2013, February 24). *Cervical myelopathy*. Retrieved on January 25, 2013. <http://www.orthobullets.com/spine/2031/cervical-myelopathy>
16. NASS. (2006). *Discography*. Retrieved on January 25, 2013. [http://www.spine.org/Documents/discography\\_2006.pdf](http://www.spine.org/Documents/discography_2006.pdf)
17. RSNA. (2012, July 06). *What is myelography?*. Retrieved on January 25, 2013. <http://www.radiologyinfo.org/en/info.cfm?pg=myelography>
18. Saint Agnes Medical Center. (2013). *Patient chat*. Unpublished paper chart, patient name excluded due to HIPPA regulations
19. Sasso, RC. (2013, January 24). *Cervical herniated disc or ruptured disc*. Retrieved on January 25, 2013. <http://www.spineuniverse.com/conditions/herniated-disc/cervical-herniated-disc-or-ruptured-disc>
20. Watson TC. (2013). *Cervical Laminoplasty Preference Card*. Unpublished surgical preference card, Saint Agnes Medical Center, California
21. Wygod, MJ. (2010, July 21). *Degenerative disc disease - topic overview*. Retrieved on January 25, 2013. <http://www.webmd.com/back-pain/tc/degenerative-disc-disease-topic-overview>
22. Wygod, MJ. (2011, April 27). *Definition of hemorrhage*. Retrieved on January 25, 2013. <http://www.medterms.com/script/main/art.asp?articlekey=14263>
23. Wygod, MJ. (2011, April 27). *Definition of morquio syndrome*. Retrieved on January 25, 2013. <http://www.medterms.com/script/main/art.asp?articlekey=11632>
24. Wygod, MJ. (2011, June 13). *Computed tomography (ct) scan of the body*. Retrieved on January 25, 2013. <http://www.webmd.com/a-to-z-guides/computed-tomography-ct-scan-of-the-body>



### Earn CE Credits at Home

You will be awarded continuing education (CE) credits toward your recertification after reading the designated article and completing the test with a score of 70% or better. If you do not pass the test, it will be returned along with your payment.

Send the original answer sheet from the journal and make a copy for your records. If possible use a credit card (debit or credit) for payment. It is a faster option for processing of credits and offers more flexibility for correct payment. When submitting multiple tests, you do not need to submit a separate check for each journal test. You may submit multiple journal tests with one check or money order.

**Members this test is also available online** at [www.ast.org](http://www.ast.org). No stamps or checks and it posts to your record automatically!

**Members: \$6 per credit**

(per credit not per test)

**Nonmembers: \$10 per credit**

(per credit not per test plus the \$400 nonmember fee per submission)

After your credits are processed, AST will send you a letter acknowledging the number of credits that were accepted. Members can also check your CE credit status online with your login information at [www.ast.org](http://www.ast.org).

### 3 WAYS TO SUBMIT YOUR CE CREDITS

**Mail to:** AST, Member Services, 6 West Dry Creek Circle Ste 200, Littleton, CO 80120-8031

**Fax CE credits to:** 303-694-9169

**E-mail scanned CE credits in PDF format to:**  
[memserv@ast.org](mailto:memserv@ast.org)

For questions please contact Member Services - [memserv@ast.org](mailto:memserv@ast.org) or 800-637-7433, option 3. Business hours: Mon-Fri, 8:00a.m. - 4:30 p.m., MT