



CE Credit Package 3A
10 Credits for \$15⁰⁰



Please submit your completed Master Answer Sheet along with payment to
AST Member Services
6 W. Dry Creek Circle, Suite 200
Littleton, CO 80120



CE Credit Package 3A

10 Credits for \$15⁰⁰



Please submit your completed Master Answer Sheet along with payment to

AST Member Services

6 W. Dry Creek Circle, Suite 200 Littleton, CO 80120

Table of Contents
CE Credit Package 3



Cerebral Artery Aneurysm Clipping: Anatomy, Approach and Technique Explored

High Grade Astrocytoma in the Adult: Biology, Pathology, Diagnostics and Treatment, Part 1

High Grade Astrocytoma in the Adult: Biology, Pathology, Diagnostics and Treatment, Part 2

The Autonomic Nervous System

General Principles and Instrumentation for Cranial Neurosurgery, Part 1

General Principles and Instrumentation for Cranial Neurosurgery, Part 2

Creutzfeldt-Jakob Disease

Glioblastoma Multiforme: From Biology to Treatment

Microvascular Decompression for Control of Trigeminal Neuralgia

Type II Odontoid Process Fractures





Cerebral artery anatomy, approach, and technique explored aneurysm clipping

Jeffrey J Cortese, CST

Although existing literature states that aneurysms are congenital lesions, supporting evidence is limited. Aneurysms are most probably degenerative acquired lesions, the effect of hemodynamic stress. Connective tissue disorders with loss of tensile strength are aggravating rather than causal factors.

Studies estimate that 1% to 5% of the general population, or as many as 400,000 people, have a brain aneurysm. Unfortunately, 85% to 90% are not diagnosed until rupture. At highest risk are people between the ages of 50 and 69. Most diagnosed cases occur between the ages of 40 and 65. Diagnosis is typically done through CT scan, MRI, or cerebral angiography.

Surgical clipping with a nonferromagnetic clip is the most effective means of preventing rupture and subarachnoid hemorrhage (Figure 1), thus effectively shutting off flow to the thin-walled aneurysm while maintaining the blood flow and integrity of the surrounding vessels.

anatomy of the scalp

The scalp is composed of five layers (Figure 2): the skin, the subcutaneous tissue, epicranial aponeurosis (galea), loose areolar tissue, and pericranium (periosteum).¹ The skin is thick and contains hair and sebaceous glands. The subcutaneous tissue is fibro-fatty, has a network of fibrous septa, and is richly vascular as branches of the external and internal carotid arteries anastomose in this layer. The epicranial aponeurosis is a strong, tendinous sheet with three attachments: anteriorly to the frontalis muscle, posteriorly to the occipital muscle, and laterally to the small temporoparietalis muscles.

The galeal closure is the key for ensuring scalp flap integrity in the postoperative neurosurgical patient. Loose areolar tissue connects the galea to the pericranium of the skull. The areolar layer contains the valveless emissary veins, which connect the scalp veins with the diploic veins of the skull and, ultimately, the intracranial venous sinuses.² At the skull suture lines, the periosteum becomes continuous with the endosteum on the inner surface.

Brain topography

The average adult male brain weighs approximately 1400 g, of which 80% is water.³ Grossly, the brain is divided into the cerebrum, cerebellum, and brain stem. The cerebral surface is marked by gyri (eminences) and sulci (fissures). The major lateral sulcus (Sylvian fissure) is present at the base of the brain and extends posteriorly and upward.

The Sylvian is the most important fissure in relation to accessing the base of the aneurysm. It provides a easy route to clip a variety of aneurysms. The major central sulcus, or rolandic fissure, extends from the hemispheric midline downward and forward until it nearly meets the Sylvian fissure. The central sulcus demarcates the key precentral gyrus, or motor cortex, and postcentral gyrus, or sensory cortex.

The hemispheres of the brain

The cerebral hemisphere is divided schematically into four lobes: the frontal, parietal, occipital,

and temporal lobes. The frontal lobe occupies roughly one third of the hemisphere, beginning anteriorly and ending at the central sulcus, with lateral extension to the Sylvian fissure. On the convexity, it is divided into superior, middle, inferior, and precentral gyri. The parietal lobe begins at the central sulcus and extends posteriorly to the parietooccipital fissure. Its lateral boundaries are marked by a line tangent to the Sylvian fissure. It is divided into postcentral, supramarginal, and angular gyri. The occipital lobe is situated posterior to the parietooccipital fissure and extends inferiorly to the preoccipital notch. The temporal lobe lies inferiorly to the Sylvian fissure and extends posteriorly to the parietooccipital fissure. The lateral surface is divided into three gyri—superior, middle, and inferior—respectively.

Cerebral arterial system

Although the brain comprises only 2% of total body weight, it consumes 20% of the total oxygen.⁴ This requires a blood flow of 750 ml/min and makes the brain sensitive to even a few seconds of reduced vascular flow. Gray matter has a higher oxygen requirement due to the density of synapses rather than the number of neurons.

Brain stem circulation

The vertebral arteries supply blood to the rostral spinal cord and the caudal medulla (Figure 3). The anterior spinal artery is a branch of the vertebral arteries, which serve the anterior portion of the spinal cord as well as the pyramids of the medulla. The posterior inferior cerebellar arteries (PICAs) are also branches of the vertebral arteries and serve the posterior spinal cord and much of the caudal portion of the medulla. Occlusion of the PICAs can interfere with function in the spinal trigeminal nucleus and tract, nucleus ambiguus, and vestibular nuclei. In addition, the PICAs also supply blood to the inferior cerebellum including the vestibulocerebellum.

At the junction of the medulla and pons, the right and left vertebral arteries fuse to form the basilar artery, which runs along the basilar pons (Figure 4). Just after they fuse, they give rise to

the anterior inferior cerebellar arteries (AICA) to serve the dorsal medulla/pons area. Along the midpontine portion of the basilar artery are numerous small paramedian branches that perforate the basilar pons.

At the pontine-midbrain junction, the basilar artery gives rise to the superior cerebellar arteries which carry blood to the anterior cerebellum, the dorsal pons and midbrain. Within the interpeduncular fossa of the midbrain, the basilar artery splits into the two posterior cerebellar arteries. These arteries serve the tectum of the midbrain as well as the posterior-medial cerebral cortex.

The circle of Willis

The two arteries that give rise to the Circle of Willis are the vertebral and the internal carotid arteries.

The arteries that comprise the Circle of Willis are the basilar, the posterior cerebral arteries, the posterior communicating arteries, the middle cerebral arteries, the anterior cerebral arteries, and the anterior communicating artery.

Internal carotid artery

The internal carotid arteries branch as they enter the cavernous sinus, giving rise to two large arteries (the middle cerebral artery and the anterior cerebral artery) and two relatively small arteries (the posterior communicating artery and the anterior choroidal artery). The internal carotid artery is divided into five segments: the cervical, petrous, cavernous, clinoidal, and supraclinoidal segments. The supraclinoidal segment exits from the dura mater, which forms the roof of the clinoidal segment, and then enters the intradural space on the medial side of the anterior perforated substance. It bifurcates in the area below the anterior perforated substance at the

medial end of the sylvian fissure into the anterior and middle cerebral arteries.⁵

Middle cerebral artery

The middle cerebral artery continues laterally and enters the lateral sulcus, separating the temporal lobes from the frontal and parietal lobes, and then travels along the lateral surface of these lobes, as well as the superior temporal gyrus and middle temporal gyrus. In fact, virtually all of the blood to the lateral portions of the cerebrum is supplied by the middle cerebral arteries.

As the middle cerebral artery passes through the lateral sulcus, it gives off a series of branches (lenticulostriate arteries) that serve most of the internal capsule and the neostriatum. The middle cerebral artery arises from the bifurcation of the internal carotid artery, below the anterior perforated substance, and is divided into four segments:⁶

M1, from the carotid bifurcation to the limen insulae; M2, all branches related to the insula from the limen insulae to the opercula of the temporal, frontal, or parietal lobes; M3, all branches related to the opercula of the temporal, frontal, or parietal lobes; and M4, the cortical branches of the middle cerebral artery after exiting the Sylvian fissure.

Only the M1 segment is related to the mesial temporal lobe. Because of differences in topographical anatomy, the M1 segment can be divided into a proximal and a distal half. The proximal half of the M1 segment is related superiorly to the anterior perforated substance, posteriorly to the semilunar gyrus and temporal amygdala, and inferiorly to the entorhinal area of the uncus.

Anterior cerebral artery

The anterior cerebral artery continues anterior-medially and enters the superior longitudinal

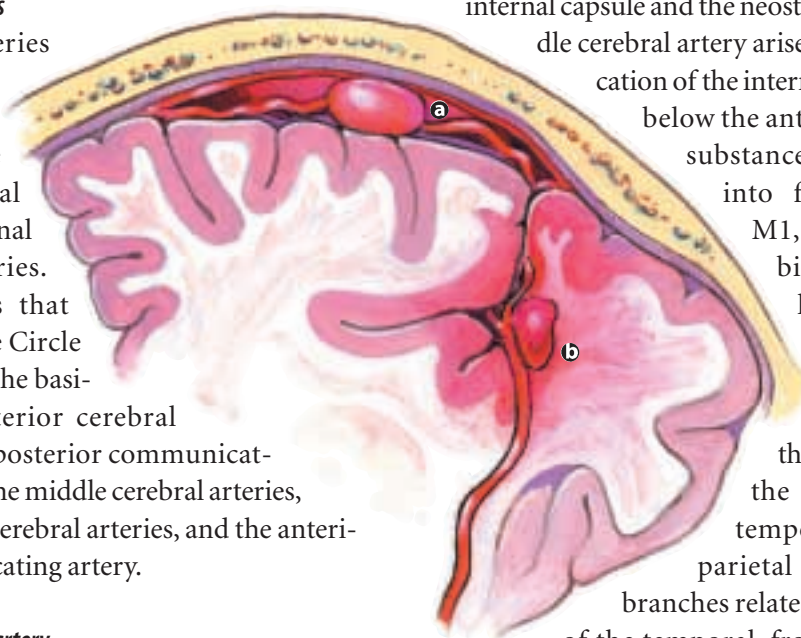


FIGURE 1

A subarachnoid hemorrhage due to aneurysm rupture.

- Ⓐ Subarachnoid hemorrhage
- Ⓑ Intracerebral hemorrhage

fissure separating the right and left cerebral hemispheres. Soon after entering the superior longitudinal fissure, the two anterior cerebral arteries come together to form a very small anterior communicating artery. The anterior cerebral arteries continue anteriorly and follow the superior surface of the corpus callosum. The anterior cerebral artery provides, therefore, most of the blood supply for the medial surfaces of the frontal and parietal lobes.

FIGURE 2

Anatomy of the scalp

Posterior communicating artery

The posterior communicating artery arises from the posteromedial or posterolateral wall of the supraclinoid segment of the internal

Anterior choroidal artery

In most cases, the anterior choroidal artery arises distal to the posterior communicating artery from the posterolateral wall of the internal carotid artery.⁷ Initially, it runs posteriorly, superiorly, and medially behind the internal carotid artery in the carotid cistern, medial to the anteromedial surface of the uncus to reach the optic tract superolateral to the posterior communicating artery. At this point, it diverges from the posterior communicating artery and runs posteriorly, superiorly, and laterally under the optic tract to enter the crural cistern between the superior part of the posteromedial surface of the uncus and the crus cerebri. After passing the posterior edge of the intralimbic gyrus, it enters the temporal horn of the lateral ventricle. The anterior choroidal artery supplies blood to the central portion of the internal capsule and the globus pallidus.

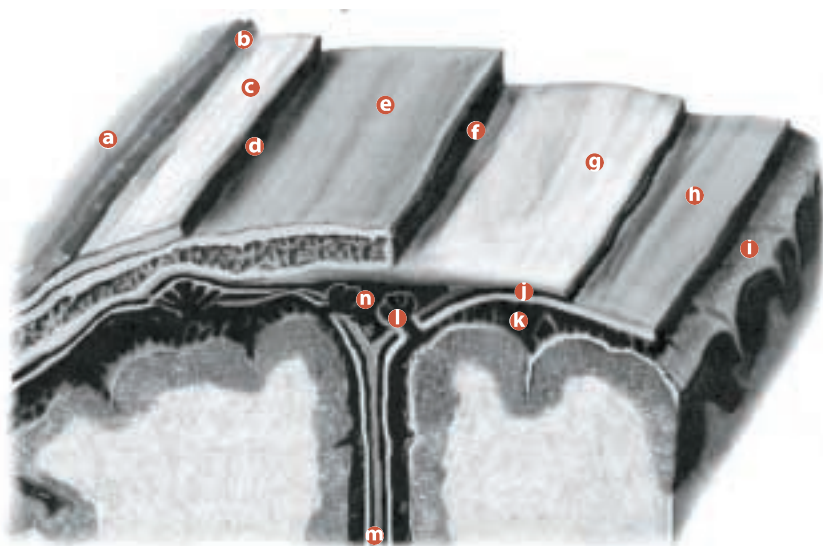
Posterior cerebral artery

The posterior cerebral arteries arise as the terminal branches of the basilar artery in the interpeduncular cistern and are divided into four segments.⁸ P1 extends from the basilar bifurcation to the posterior communicating artery. P2A extends from the posterior communicating artery to the posterior edge of the crus cerebri. P2P extends from the posterior edge of the crus cerebri to the posterior margin of the midbrain. P3 begins at the posterior midbrain, runs within the quadrigeminal cistern, and ends at the anterior limit of the calcarine fissure. P4 is the cortical segment of the posterior cerebral artery. The posterior cerebral arteries serve the medial portions of the occipital lobe, some of the lateral occipital lobe, as well as the inferior portions of the temporal lobe, including the inferior temporal gyrus and parahippocampal gyrus.

Pterional approach for aneurysm clipping

Scalp incision/flap

All aneurysms of the Circle of Willis and the upper basilar artery can be approached through a frontotemporal, sphenoidal approach, or the



carotid artery⁵ and runs posteromedially between the tuber cinereum and the sella turcica and the oculomotor nerve. It continues close to the overlying dura of the posterior clinoid process before piercing the Lilliequist membrane of the interpeduncular cistern where it joins the posterior cerebral artery. Along the short length of the posterior communicating arteries, small branches supply blood to the overlying hypothalamus.

The posterior communicating artery joins the anterior and posterior circulatory routes. The sizes of posterior communicating arteries vary, being quite large in some individuals and quite small in others.

- a Skin
- b Subcutaneous tissue
- c Galea
- d Areolar tissue
- e Periosteum
- f Bone
- g Dura mater
- h Arachnoid mater
- i Pia mater
- j Subdural space
- k Subarachnoid space
- l Arachnoid villi
- m Falx cerebri
- n Superior sagittal sinus

pterional approach promoted by Yasargil.⁹ Its advantages are: maximal surface exposure, expendable wide bone removal from the cranial base, wide arachnoid and basal cistern dissection, and minimal brain retraction. The patient lies supine, with the head elevated, turned 45° away, extended 15°, and secured to a 3- or 4-pin head rest.

The incision is made behind and parallel to the hairline, extending from midline to the zygoma just anterior to the tragus. A #20 blade is used to avoid the ascending frontotemporal branch of the facial nerve and the superficial temporal artery. Raney clips are applied to the scalp edges to provide hemostasis. Using electrocautery, the scalp flap is reflected forward with the periosteum, which is separated from the superior temporal line, and retracted with scalp hooks or a self-retaining retractor.

The temporal fascia is separated into an outer layer, attached to the lateral zygoma surface of the temporal bone, and a deeper layer, attached to the medial zygomatic border. The fascia is opened and split near the frontozygomatic process. The outer fascial layer is reflected forward toward the orbit and forms a sleeve to protect the nerve to the frontalis muscle. The inner fascial layer is reflected along with the bulk of the temporalis muscle inferior-posteriorly toward the ear and is retracted with scalp hooks. An alternative approach is to reflect the temporalis muscle forward. This exposes the bony surface of the lateral orbital ridge and temporal fossa.

After the surgeon is satisfied with the margins of the flap, an X-ray detectable sponge is rolled lengthwise and placed under the flap that is secured with scalp hooks. This maneuver ensures that the vessels in the scalp flap are not occluded, reducing the chance for ischemic necrosis of the flap.

Bone flap creation

The first and most important burr hole is drilled just behind the zygomatic process of the frontal bone so the cosmesis is protected by preserving the orbital and temporal bony ridges. Exposure of the dura along the floor of the anterior fossa

is accomplished utilizing a high-speed drill, a Craniotome, or a Hudson brace fitted with a McKenzie perforator. If the surgeon chooses to do so, three to four additional burr holes are drilled along the circumference of the exposure frontally and temporally. A free bone flap is raised using a high-speed drill fitted with a foot-plate on the end of the drill cutter to protect the underlying dura and brain surfaces.

The flap should be big enough to expose the anterior and middle fossae separated by the greater wing of the sphenoid bone as it merges laterally with the great wing of the pterion. The bone flap is dissected from the dura mater using an Adson periosteal elevator, taking care not to

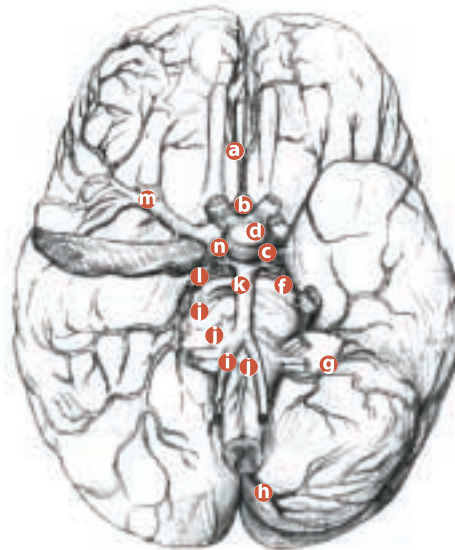


FIGURE 3

Cerebral arterial system

- Ⓐ Anterior cerebral artery
- Ⓑ Anterior communicating cerebral artery
- Ⓒ Circle of Willis
- Ⓓ Pituitary gland
- Ⓔ Superior cerebellar arteries
- Ⓕ Anterior inferior cerebellar arteries (AICAs)
- Ⓖ Posterior inferior cerebellar arteries (PICAs)
- Ⓗ Vertebral artery
- Ⓙ Pontine branches
- Ⓚ Basilar artery
- Ⓛ Posterior cerebral artery
- Ⓜ Middle cerebral artery
- Ⓝ Posterior communicating artery

tear the dura from the underside of the flap. Stop any bone bleeding by applying bone wax to the cut edges. The lesser wing of the sphenoid bone is removed with a high-speed drill and rongeurs after careful epidural dissection, exposing the dural reflection of the superior orbital fissure. The middle meningeal artery is coagulated with bipolar cautery and transected.

Bony removal of the lateral sphenoid wing and orbital plate gives access to the Sylvian fissure and basal cisterns with minimal retraction of the frontal lobe and temporal lobe. The dura from the frontal to temporal base is opened in a semilunar fashion using a #11 blade and Metzenbaum scissors, exposing the Sylvian

region. The dura is then sutured to the exposed temporalis muscle using 4-0 Neurolon suture. Once the opening of the dura is complete, the microscope, which is enclosed in a sterile drape, is brought into the field.

Dissection of the cisterns

Retraction is accomplished with a self-retaining cable system attached to the head holder. Retractor blades are bent and the cables are adjusted to lay flat to project a low unencumbered surface profile. Nonadherent gauze is placed on the brain's surface underneath the retractor blades to disperse their force onto the gauze and reduce the potential for brain injury.

section of the arachnoidal attachments. Lifting the arachnoid with a micro-hook and cutting it with a #11 blade works well.

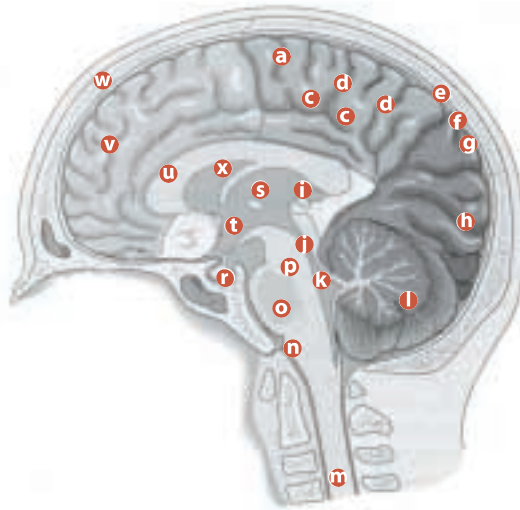
The internal carotid artery (ICA) is isolated at the dural base just lateral to the optic nerve. The ICA can be controlled with a temporary clip, if necessary. Control of the ICA should be the first strategic maneuver. This may require dissecting the dura of the anterior clinoid process and gradually drilling the clinoid away to expose the rostral fibrous ring of the carotid. Sometimes the fissure must be opened to gain access to the anterior superior compartment of the cavernous sinus (CVS). The membrane of Lilliequist (arachnoid sheath from the mammillary bodies to the posterior clinoids) is opened sharply to release CSF and gain access to the interpeduncular and prepontine cisterns en route to the basilar artery.

When dissecting the carotid cistern, the small arterioles supplying the optic nerve and chiasm should be preserved. The posterior communicating artery (PCA) is seen coursing posterolaterally from the lateral carotid wall close to the tentorial edge. The oculomotor cranial nerve (CN III) is seen lateral to the PCA as it enters the superior lateral wall of the CVS. Multiple arterial perforating branches course rostrally from the PCA. It is not necessary to disturb these structures unless approaching the basilar artery. Aneurysms arising at the ICA-PCA junction are most common (60%).¹⁰ They may locally compromise the third cranial nerve. These aneurysms usually project posterolaterally.

The neck is dissected circumferentially and must be separated from the PCA and the anterior choroidal artery. When a micro dissecting instrument can be passed between the aneurysmal neck and the adjacent branches, the neck can be clipped without disturbing the fundus or dome. The anterior choroidal artery (AchA) arises from the ICA just rostral to the PCA. It is protected as dissection of the ICA is continued rostrally. Retractor blades are readjusted to distract the open cisterns and expose the rostral ICA at its bifurcation. The arachnoidal shelf at the medial Sylvian fissure is opened sharply,

FIGURE 4

Structures of the brain



- a Parietal lobe
- b Gyri
- c Sulci
- d Dura mater
- e Arachnoid
- f Pia mater
- g Occipital lobe
- h Third ventricle
- i Cerebral aqueduct
- j Fourth ventricle
- k Cerebellum
- l Spinal cord
- m Medulla oblongata
- n Pons
- o Midbrain
- p Pituitary gland
- q Thalamus
- r Hypothalamus
- s Corpus callosum
- t Frontal lobe
- u Skull
- v Lateral ventricle
- w

The frontal lobe is gently lifted from the orbital plate until the optic nerve is visualized. The ipsilateral optic nerve identifies the chiasmatic cistern medially and the carotid cistern laterally. The arachnoid, which surrounds the cisterns, is opened by sharp dissection using a #11 blade and microscissors to release cerebrospinal fluid (CSF) and ease retraction. Malleable, fine-tip adjustable suction is used to evacuate CSF and gently disperse fine vessels and arachnoidal trabeculae. The cistern furthest from the aneurysm is dissected first to gain exposure and avoid disturbing the aneurysm prematurely. Sharp dissection with a knife or scissors is safer and less traumatic than blunt dis-

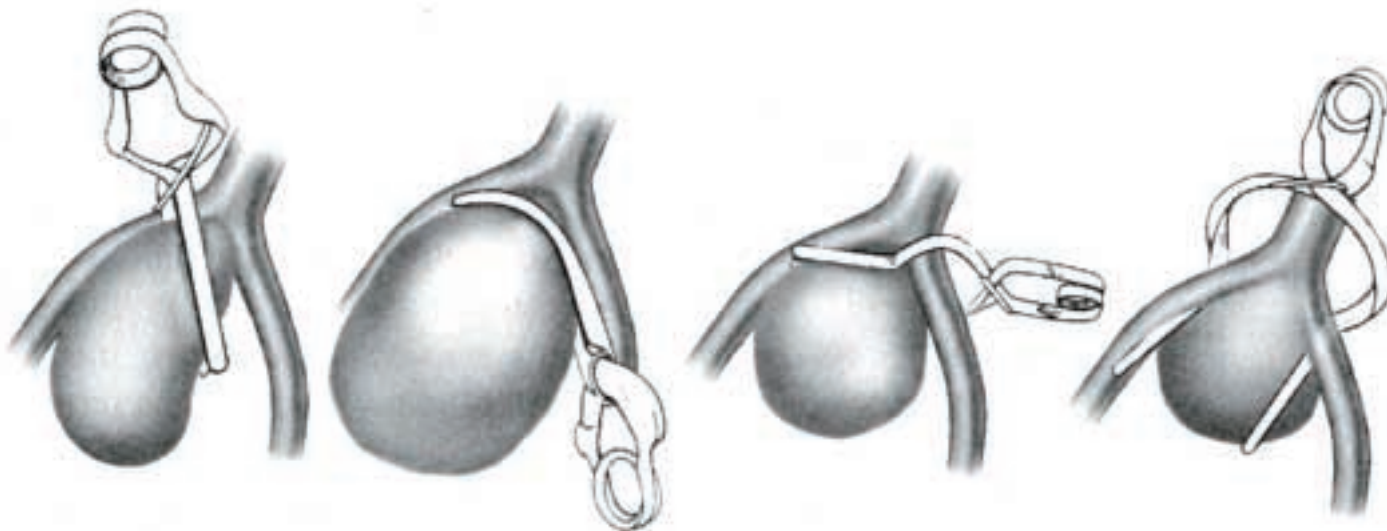
facilitating a view of the proximal anterior cerebral (A1) and the proximal middle cerebral arteries (M1).

Lesion exposure

Sharp, wide dissection in the natural anatomical planes of the sulci, fissures, and cisterns allows retraction of overlying brain to expose the aneurysm. Anatomical landmarks, such as dural reflections, major arachnoidal planes, cranial nerves, and arterial trunks, provide appropriate orientation. Limited resection of brain tissue may produce less injury to normal overlying brain tissue than retraction for treatment of aneurysms in selected locations.

A wiggle motion while applying the jaws of the clip, like a dissector upon application, helps prevent tears of the neck. After closing the clip, the tips are inspected to ensure that complete closure and inadvertent clipping of perforating vessels. If the surgeon is not satisfied, the clip may be removed and adjusted, guaranteeing optimal placement. In the event of migration or slippage, a booster clip or double clip may be applied. If a temporary clip was applied, it is removed at this time.

To confirm occlusion of the aneurysm, a 30-gauge needle mounted on a tuberculin syringe is inserted into the dome. If any gross blood is appreciated, the clip may have to be repositi-



Aneurysm clip application

After complete circumferential dissection of the aneurysm neck with a spatula-type microdissector, a clip is chosen, mounted on a applier, and inserted for trial on the neck to ensure the best fit. Once the surgeon is completely satisfied that the clip will occlude the neck, the field is prepared for permanent clip application. The brain is irrigated to prevent instruments from sticking to the tissues. If the surgeon chooses, a temporary clip is placed on the parent artery. This stops the blood flow inside the aneurysm, allowing manipulation of the neck while decreasing the risk of rupture. The permanent clip is then inserted onto the neck of the aneurysm (Figure 5).

tioned. Gelfoam cut into 3 x 3 inch pieces, soaked in Papaverine, is placed around the clip and parent vessels to help decrease the chance of vasospasm. After the surgeon is completely satisfied with the placement of the clip, the wound is irrigated with saline containing Bacitracin antibiotic, the retractors are removed, and the microscope is taken out of the field.

Closure

The dural edges are approximated using a running locking suture of 4-0 Neurolon on a TF needle. Braided suture is preferred because it swells and plugs the holes caused by the needle in the dura, reducing the potential for a CSF leak.

FIGURE 5

Examples of cerebral aneurysms with various types of clips.

A piece of Gelfoam is cut into the shape of the bone flap and placed on top of the dura. The bone flap is replaced and secured using titanium mini-plates and screws. Any large bony defects may be filled with a hydroxyapatite cement to ensure a good cosmetic result.

The Raney clips are removed, and the temporalis muscle is approximated using 0 Vicryl on a CT-2 needle in an interrupted fashion. Interrupted sutures of 3-0 Vicryl on a X-1 needle is used to approximate the galea and subcutaneous tissue. The skin is closed by a running stitch of 5-0 plain gut suture, eliminating the need to remove a nonabsorbable suture or staples post-operatively. Skin adhesive, adhesive strips, and 1x3-inch bandages are applied as a final dressing. The pins are removed from the head, and the patient is transferred to the gurney. The head is wrapped turban style with gauze and secured with tape.

Conclusion

A cerebral aneurysm is a common cerebrovascular disorder caused by a weakness in the wall of a cerebral artery. The disorder may exist as a result of congenital defects or from preexisting conditions such as hypertensive vascular disease and atherosclerosis, or from head trauma. Microsurgical clipping remains the cornerstone of therapy for intracranial aneurysms. The aim of modern aneurysm surgery is the total elimination of the aneurysm sac with complete preservation of the surrounding normal arteries. The aneurysm neck is clipped with a titanium or other non-ferromagnetic clip. By using a combination of patient positioning, medications administered by the anesthesia team, and release of the patient's own cerebrospinal fluid, the neurosurgical team is able to safely manipulate and dissect the structures surrounding the cerebral aneurysm and clip it successfully.

Acknowledgments

I wish to thank John L Zinkel, MD, PhD, FACS, for his friendship, his help and patience with my relentless questioning, and his guidance in my present career.

About the author

Jeffrey J Cortese, CST, has been a certified surgical technologist for five years. He is employed at Bon Secours Hospital in Grosse Pointe, Michigan, where he functions as the department's neurological surgery coordinator. Cortese is a third-year biology major at Oakland University, where he is studying to become a neurological surgeon.

References

1. Snell RS. *Clinical Anatomy for Medical Students*. Boston: Little, Brown; 1973.
2. Osborn AG. *Introduction to Cerebral Angiography*. Philadelphia: Harper and Row; 1980.
3. Gilman S, Newman SW. *Manter's and Gatz's Essentials of Clinical Neuroanatomy and Neurophysiology*. Philadelphia: FA Davis; 1989.
4. Drake CG. The treatment of aneurysms of the posterior circulation. *Clin Neurosurgery*. 26:96-144, 1979.
5. Rhoton AL Jr, Gibo H, Lenkey C. Microsurgical anatomy of the supraclinoid portion of the internal carotid artery. *J Neurosurgery*. 55:560-574, 1981.
6. Markinkovic SV, Konacevic MS, Markinkovic JM. Perforating branches of the middle cerebral artery: Microsurgical anatomy of their extracerebral segments. *J Neurosurgery*. 63:226-271, 1985.
7. Wen HT, Rhoton AL Jr, de Olivera E. Transchoroidal approach to the third ventricle: An anatomic study of the choroidal fissure and its clinical application. *Neurosurgery*. 42:1205-1219, 1998.
8. Nagata S, Rhoton AL Jr, Barry M. Microsurgical anatomy of the choroidal fissure. *Surg Neurol*. 30:3-59, 1998.
9. Yasargil MG, Fox JL. The microsurgical approach to intracranial aneurysms. *Surg Neurol*. 3:7-15, 1975.
10. Hacker RJ, Krall JM, Fox JL. *Data I. In: Intracranial Aneurysms, vol 1*. Fox JL (ed). New York: Springer-Verlag; 1983 chap 3, 19-62.
11. Brain Aneurysm Foundation. *The Brain Aneurysm Report*. vol 1, no 1, winter 1995-1996. neurosurgery.mgh.harvard.edu/baf/rpt111.htm

Accessed 2/5/01

RP: U.S. EX: 10000

Se: 3

Im: 62

24 5

HIGH GRADE ASTROCYTOMA IN THE ADULT

**BIOLOGY,
PATHOLOGY,
DIAGNOSTICS,
AND TREATMENT**

PART 1: BIOLOGY AND PATHOLOGY

BY BOB CARUTHERS, CST, PHD

GRADE ASTROCYTOMA

The definitive classification of primary brain tumors is histologic and based on the normal cell of origin within the central nervous system. While more than one cell type may be present, the predominant cell type found within a tumor is used to define the tumor. Even with the great advances made in histological and biochemical techniques, it remains difficult to identify the cell type of origin in some tumors. In the central nervous system, a tumor may be composed of a mixture of different neoplastic cell types, but the tumor is considered to be mixed only when a significant component of each cell type is found within the tumor.⁵ Histopathological features of the tumor determine malignancy or anaplasia.

This article focuses on the high-grade adult tumor to provide a deeper understanding of the biology, diagnostics, treatment options and outcomes associated with high-grade astrocytomas and, specifically, glioblastoma multiforme.

Biology of the glioma

One critical principle of oncology is that an understanding of the normal biology of the cell of tumor origin provides information necessary to comprehend the oncogenesis of a tumor cell and potential treatment options. In order to survive, any cell needs the following:

- adequate blood supply
- adequate nutrients
- protection and communication through an intact and properly functioning cell membrane
- production and exportation of growth factors.

In the brain, there is an added need for protection against wastes or organisms that may travel in the blood stream. This protection must be in a "gated" form, able to open to nutrients and oxygen and to close for protection from potentially harmful substances. As described in the treatment section, the ways a tumor survives are also methods by which the tumor can be attacked.^{4,5}

g

glial cells

The term glial evolves from the Greek word meaning glue. Glial cells are non-neuronal cells of the central and peripheral nervous systems. There are 10 glial cells for every neuron, approximately 100 billion total glial cells, providing both structural and metabolic support for the neurons. In the central nervous tissue, types of glial cells include oligodendroglial cells, astrocytes, ependymal cells, and microglial cells. In the peripheral nervous system, the satellite cells of the ganglia and the Schwann cells around peripheral nerve fibers can be interpreted as the oligodendroglial cells.

Glial cell differentiation

How do glial cells begin? Undifferentiated neural epithelium serves as progenitor to a number of differentiated structures (Figure 2). Precisely how this task is accomplished remains unknown, but the basic mechanism has been outlined. A progenitor cell produced by the stem cell is reduced to a bipotential cell that produces two cell lineages, neurons and glial cells. The process, under DNA control, requires a specific sequence of gene activation and deactivation that occurs in sequential phases:

- differentiation of the neuroectoderm^{3,9,10,15}
- formation and segmental patterning of the neural tube^{5,9}
- determination of neuronal and glial phenotypes.^{3,5,7,9,29,30,33,35}

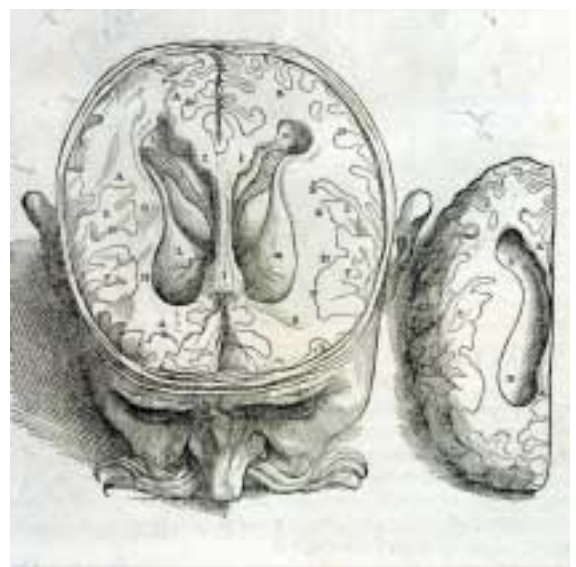
This brief description focuses on the glial lineage. These precursor cells arise from an undifferentiated, multipotential glial-cell progenitor. The multipotential glial-cell progenitor can produce some precursor cells that are only capable of producing an astrocyte. Under the proper environmental conditions, this cell will produce an (A1) astrocyte. Other progenitor cells are capable of producing both astrocytes and oligodendroglial cells.^{3,5,9,10,15}

Another route to astrocyte formation may also be simple and direct—a multipotential glial-cell progenitor to a bipotential intermediate cell to an (A1) astrocyte. However, the bipotential precursor cell can also produce an immature oligodendroglial cell depending on

environmental conditions. If the immature oligodendroglial cell is located in a cellular environment in which (A1) astrocytes are present, a mature oligodendroglial cell develops. If (A1) astrocytes are not present, the immature oligodendroglial cell becomes an (A2) astrocyte.

Normal cell cycle

The cell cycle (Figure 3) is too complex to describe in detail. However, it is important to understand that, under normal conditions, it is the precisely sequenced and timed series of intracellular actions that result in controlled cell growth and reproduction. In dividing cells, the end product of a cycle is two daughter cells that



are clones of the originating cell. Nondividing cells are not considered part of the cell cycle.

The phases in the cell cycle are:

- (G1) Gap one:
- (S) S phase
- (G2) Gap two
- (M) Mitotic phase

G1 represents a period of time when the cell is growing larger and preparing for DNA replication, and when genes are expressed and protein synthesis occurs. Extracellular factors, such as hormones or electrical stimulation, regulate this phase. While the cell cycle has many checkpoints,

FIGURE 1

Brain plate—
National Library
of Medicine.

there is a “go/no-go” point near the end of G1. If G1 is completed successfully, the cell is prepared to move to the next phase.

During the S phase, DNA is replicated and chromosomes are duplicated. G2 is the second phase of protein synthesis and growth. The M phase represents the four stages of mitosis and is regulated by multiple growth factors (genes), such as cytoplasmic cyclins (eg DNA), cyclin-dependent kinases (CDK 2, 4, and 6) and a complex that promotes anaphase. The points at which these substances must activate or deactivate other mechanisms in the cycle are the key points of vulnerability in the processes of oncogenesis (the formation of tumors).

In essence, all cancer results from some type of malfunction in the cell cycle that makes the cell act outside the normal rules for growth and reproduction. More information in a readily available format can be found at The Biology Project at Arizona University (www.biology.arizona.edu) and at the Cancer Genetics organization Web site (www.cancer-genetics.org). More academically oriented information is available at PubMed at the National Library of Medicine Web site. (Click on “Related Organizations” on the AST Web site.)

Glial cell function

Until recently, glial cells were believed to have relatively limited functions and were viewed as sup-

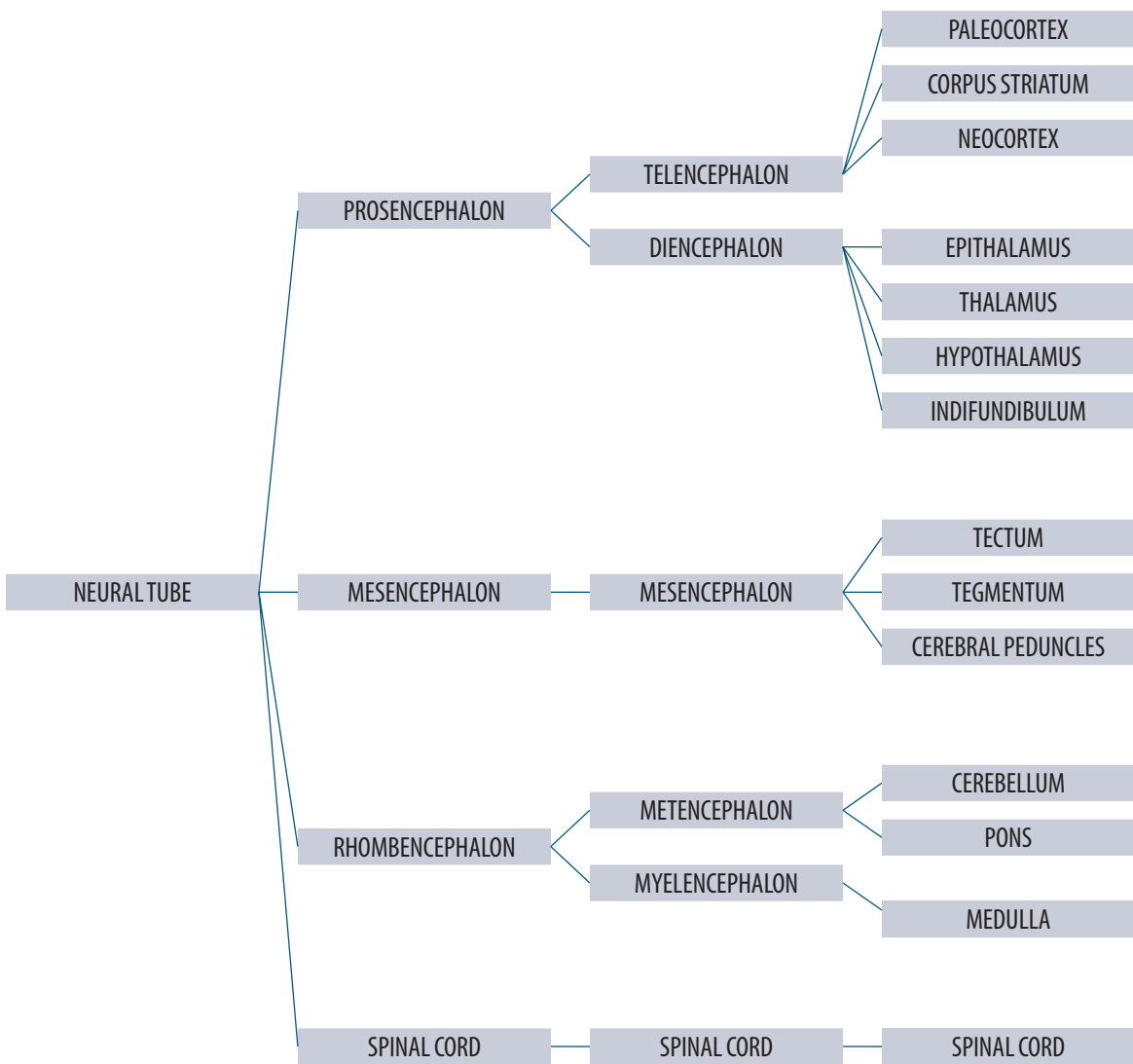


FIGURE 2
Cell differentiation process in the central nervous system—neuron, astrocyte and oligodendroglia.

Adapted from Carlson BM. *Human Embryology and Developmental Biology*. Mosby, St Louis, 1999.

porting cells, hence the concept as the glue of the nervous system. However, glial cells have important metabolic functions, since they are invariably interposed between neurons and the blood vessels supplying the nervous system. They are responsive to electrical input, produce substances that may function as neurotransmitters, and possibly play a role in the memory process.

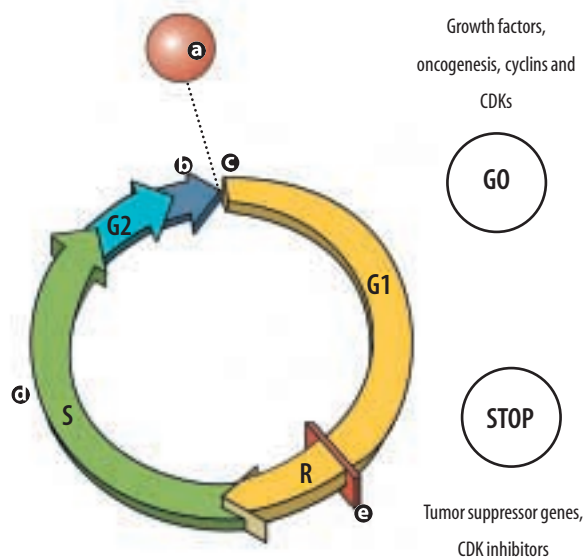
Glial cell oncogenesis

The term cancer can be applied to more than 100 diseases. In the last 25 years, tremendous advances have been made in understanding the mechanisms of cancer formation and therapeutic approaches, but much remains unknown. More-

ancestral cell that initiates this aberrant behavior. Depending on the location and type of cell, the proto-oncogene of the primary ancestral cell mutates and initiates the program of inappropriate reproduction that is carried forward by the cells of its familial line.

For a cell to become cancerous, then, a number of events are required:

- multiple genetic mutations in select genes^{5,18,36,37}
- activation of a proto-oncogene
- inhibition of tumor suppressor genes
- deactivation of the executive cell-cycle clock
- successful defense against apoptosis.



Oncogenes and suppressor genes

There are two gene classes that coordinate the life cycle of the cell and, specifically, the sequence of events governing cell growth and reproduction. Under normal conditions, a balance exists between the proliferation and suppression messages. Proto-oncogenes encourage growth and reproduction; whereas, tumor suppressor genes (the second class of genes) inhibit growth and reproduction. These two gene classes account for much of the normal growth of cells or, when mutated, the uncontrolled proliferation of cells.

Proto-oncogenes

Proto-oncogenes encode a form of protein that functions as part of a genetic relay team to move stimulating signals from the cell's external environment to its internal environment. Cancer cell development requires deregulated cell growth that results when a proto-oncogene continuously energizes proteins, which function as growth factors to act on nearby cells. More importantly, in the case of cancer cells, the new cells also turn back and drive the proliferation of parent cells. It is possible that the growth factor involved is manufactured in normal amounts, but the proteins produced are overly active. In either case, the growth-stimulation pathway is active when it should be inactive. Some known growth factors that present in primary brain-tumor formation are listed in Table 1.

over, in many instances, what is known in the research community is yet to be translated into clinical application.

There are some 30 trillion cells in the normal human body, most of which follow a very strict reproductive code. Reproduction is inhibited or facilitated by on-going local communication between cells. Cancer cells violate this rule. These cells function outside the normal controls and follow an internal, but altered, genetic agenda. Cancer cells are, in a human analogy, sociopathic. In most of the body, cancer cells are not restricted to local growth but have the ability to migrate from their site of origin to invade nearby tissues. Malignant masses begin from a common

FIGURE 3

Cell cycle.

- Ⓐ New daughter cell
- Ⓑ Mitosis (cell division)
- Ⓒ Begin cycle
- Ⓓ Synthesis (doubling of DNA)
- Ⓔ Restriction point (point of no return)

Table 1. Growth factors related to brain tumor formation

GROWTH FACTOR	FACTOR PRESENT ON AND SECRETED BY	SUSPECTED FUNCTION
Epidermal growth factor	Astrocytoma	Autocrine stimulation of astrocytoma cell growth
Fibroblast growth factor	Astrocytoma & meningioma	Autocrine stimulation of astrocytoma cell growth, migration and invasion
Insulin-like growth factor I	Normal brain, meninges and choroid plexus Meningiomas	Autocrine growth regulation in meningiomas
Insulin-like growth factor II	Autocrine stimulation of astrocytoma cell growth	Autocrine growth regulation in meningiomas
Platelet- driven growth factor AA	Astrocytoma	Autocrine stimulation of astrocytoma cell growth
Platelet- driven growth factor BB	Astrocytoma	Paracrine endothelial proliferation
Transforming growth factor- α	Astrocytoma & meningioma	Phenotypic transformation of normal cells
Transforming growth factor- β	Astrocytoma & meningioma	Inhibition of growth of astrocytoma cells
Vascular endothelial growth factor	Astrocytoma	Paracrine stimulation for endothelial proliferation

Note: autocrine designates a process of cellular self-stimulation through the production of both a growth factor and a specific receptor for it, whereas paracrine refers to a type of hormone function that is restricted to the local environment.

Adapted from Greenberg HS, Chandler WF, Sandler HW (1999). *Brain Tumors*. New York, Oxford University Press: Figure 2-1, pg 37.

Tumor suppressor genes

Cells have a number of mechanisms to combat cancer development, including tumor suppressor genes (RB and TP53) that function as brakes on unwarranted growth and reproduction. However, in the case of cancer, the tumor suppressor genes, instead of being activated, are inhibited or suppressed and are unable to stop the runaway cellular division.

G1 and point R

Most of the activities of the cell during a trip through the cell cycle are determined by intracellular factors. An exception occurs during the G1 phase prior to passing the point referred to as R (restriction point, a go/no-go decision). Part of the decision-making process is governed by autocrine growth factors. Other factors communicate with the extracellular environment and provide feedback to help regulate the cell cycle. A “go” decision allows the cell to move to the S phase, while a “no-go” decision stops the cycle and leads to cell death.

P53 and apoptosis

Under normal conditions, there is another mechanism that allows cells to regulate themselves—even when a proto-oncogene overstimulates production and the tumor suppressor cells are inhibited. Cells have the natural ability to commit suicide. The executive decision-

maker in the cell, the cell-cycle clock, regulates the cycle and, thereby, reproduction. A failure in this cycle stops the cell’s normal cell life span.

Even then, cells have one last opportunity to avoid becoming cancerous—apoptosis (cellular suicide), but there are restrictions. Developing cancer cells have several defense strategies they can employ to avoid apoptosis. A nuclear protein known to act as a tumor suppressor, called p53, is “the guardian of the genome,” and performs three critical tasks:

- a major role in the transcription of DNA
- regulation of cell growth
- regulation of cellular proliferation.

In the cell cycle, p53 functions as an emergency break and appears to be involved in apoptosis. Mutation in this protein results in the loss of its ability to block abnormal cell growth. (Interestingly, this mutation switches the protein’s role from a suppressor to a stimulator of cell division and a promoter of cancer development.) A p53 mutation occurs in nearly one half of all human cancers, including the more aggressive cancers of the breast, cervix, colon, lung, liver, bladder, and skin. P53 is mutated in most astrocytomas and almost universally in glioblastomas. This mutation is important to treatment success, because the effectiveness of radiotherapy and some chemotherapy depend on triggering cell suicide.

When the p53 protein mutates, tumors are more difficult to treat, reducing the likelihood of a successful response to therapy.^{5,11,16,20,27}

There are two basic mechanisms that control cell death: apoptosis and necrosis. Apoptosis is characterized by morphological changes in the nucleus and cytoplasm. The ability to kill a cell serves as a balance to mitosis and helps regulate cellular growth.^{5,11,16,20,27}

Essential to life, apoptosis governs which cells are programmed to die given certain physiological and developmental stimuli. P53 encodes a transcription factor that mediates cellular response to environmental damage, halts cell division so the cell can repair itself, or triggers apoptotic death. Several genes turn on the apoptotic process, but researchers are still looking for the underlying explanations.

Other genes also trigger the essential “off” message. For instance, cells in the immune system identify and kill “non-self” T-cells. In the brain, neural cells are connected by a process that “chips away” unwanted cells to create the desired synaptic pathway, much like a sculptor creating form from a piece of marble.

Select astrocytoma cell characteristics

Astrocytoma cells demonstrate several abnormal characteristics including:

- changes in DNA (chromosomes) and gene expression
- production of growth factors
- changes in kinase receptors.

This article includes only a brief discussion of each with select examples that do not represent the complex genetic and biochemical processes of the astrocytoma cell.

Chromosomal mutations

The astrocytoma shows a series of sequential changes that includes both the amplification and loss of genetic material as the tumor develops and the malignancy evolves. Early in development, there is a loss of genetic material on chromosomes 6, 13, 17, and 22. P53 is located on chromosome

17 and, in 75% of the cases of astrocytoma, has mutated. The effects of this mutation are probably exerted during early changes in the cell as it evolves from a normal to an abnormal cancer cell.

Cancer cell activities

Some cancers are capable of forming mass lesions well beyond the regional site. Malignant brain tumors do not metastasize to other areas of the body. However, high-grade gliomas are capable of aggressively invading surrounding tissue, crossing to the opposite hemisphere, and seeding the spinal cord with cancer cells.⁵

Angiogenesis

Although foreign in normal adult cells, angiogenesis is a natural part of embryonic development and requires two-way intracellular communication.^{5,9} Tumor cells need to create a new arterial supply to support their high-nutrient needs, and growth factors are produced in tumor cells that are not present in normal glial cells. In some instances, these growth factors may be correlated to the malignancy grade (eg a low-grade glioma may produce small amounts of the growth factor, while the high-grade glioblastoma produces large amounts). It is important to see that the fast-growing cell needs the blood supply, but the increasing blood supply makes it easier for the cell to grow and divide, promoting uncontrolled growth.

Glioma types and staging

The earliest system of histologic classification for gliomas was created by Bailey, a neuropathologist, and Cushing, a neurosurgeon, in 1926. In the introduction to their book on the subject the authors state the problem of the day.^{4,5,6}

“The impression in both laboratory and clinic that the microscopical examination of a specimen removed at operation will not serve to predict, with any degree of certainty, the future course of development of a true tumor of the brain substance. These lesions, which are commonly grouped together as gliomas, represent about forty per cent of all intracranial neoplasms. They exhibit a bewildering variety of microscopical structure, and

Table 2. Select tumors of the neuroepithelium

1	Astrocytoma
2	Anaplastic astrocytoma
3	Glioblastoma multiforme
4	Gliosarcoma
5	Pilocytic astrocytoma
6	Anaplastic pilocytic astrocytoma
7	Oligodendroglioma
8	Anaplastic oligodendroglioma
9	Oligo-astrocytoma
10	Anaplastic oligo-astrocytoma
11	Ependymoma
12	Anaplastic ependymoma
13	Choroid plexus tumors

*existing classifications have served to do little more than add confusion to a complicated subject.*⁵

Thus stated, they began the search for a histologically based classification system. The intent was to answer three questions:

1. What is the basis of the structural variability shown by gliomatous tumors?
2. What, if any, is the clinical significance of the various structures?
3. Can the histologic variability account for longer-than-expected survival periods following debulking of the tumor?

While techniques have changed radically, the basic questions remain. Bailey and Cushing produced a hierarchical system with 13 tumor types (Table 2) and a prognosis for each. Kernohan and Sayre offered a different system that defined five subtypes—astrocytoma, oligodendroglioma, ependymoma, gangliocytoma, and medulloblastoma.²⁷ More importantly, they added a grading system. The system used today was initially developed by neuropathologists under the oversight of the World Health Organization (WHO) and published by Zulch.³⁷ This effort was intended to clarify issues of the day and provide a single international grading system. New questions naturally arose, so Kleihues, Burger, Scheithaueer produced a revised version for WHO following two international meetings in the late 1980s.²⁴ The

primary question during the late 1980s was whether grading systems were helpful. The usefulness of a grading system for brain tumors seems to have depended on viewpoint. The scientific community found grading systems generally unhelpful, while the clinicians found them helpful. The revision was something of a compromise. It allows for a grading system because of its clinical usefulness, but it did not find a grading system helpful for histological identification and research. If used for these purposes, the grading system was required to be identified.

Grades

Once tumors were graded, some new issues arose. For instance, is a grade IV astrocytoma equivalent to a GBM, or is there a clinically identifiable distinction between the two (Table 3). Other questions that arise with grading are:

1. Does the grade assigned affect treatment strategy?
2. Does grade assignment correlate to prognosis?

There are some common features used in grading neuroepithelial tumors: (1) nuclear atypia, (2) cellular pleomorphism, (3) mitotic activity (4) angiogenesis or vascular proliferation, and (5) development of necrotic areas. The more features that are present, the more malignant the tumor.

The astrocytoma group

Pilocytic astrocytomas are benign, typically occur in children and young adults, and are frequently located in the thalamus or other important subcortical locations. The histologic borders are usually defined accurately by MRI contrast enhancement. Surgical removal is usually total and produces excellent results.

Grade 2 astrocytomas exhibit pleomorphism, an increase in the number of cells and show no indications of mitotic activity or necrosis, demonstrate hypodensity on CT and prolongation of T1 and T2 on MRI. Typically they do not show any contrast enhancement.^{5, 8, 20, 31, 38}

Frequently referred to as malignant astrocytomas, Grade 3 and 4 astrocytomas show contrast

enhancement on imaging studies. The contrast enhanced mass may be surrounded by an area of hypodensity on the CT scan or prolonged T1 and T2 on the MRI. This area consists of edematous brain parenchyma that has been infiltrated by isolated tumor cells. Commonly, Grade 3 astrocytomas are called anaplastic astrocytomas and Grade 4 astrocytomas, glioblastomas.^{5,8,20,31,38}

Anaplastic astrocytoma

The cells of Grade 3 or anaplastic, astrocytomas, are abnormal in appearance. Mitotic evidence also appears in some cells. Some cells may infiltrate individually into normal brain tissue; other malignant cells continue to divide, destroy

summary, CT and MRI scans show a contrast enhancing mass with a necrotic center which is surrounded by a zone of hypodensity on CT and prolonged T1 and T2 on MRI correlating to the infiltrated brain tissue.^{5,8,13}

Prognostic indicators

In general, it is clear that several factors correlate to length of survival. The greater the number of indicators present in any given tumor, the shorter the life expectancy.^{4,5,12,17} However not all indicators carry equal weight in a given tumor type and grade. Prognostic indicators for anaplastic astrocytomas include the presence of endothelial vascular proliferation and/or mitotic activity, both of which reduce survival time considerably.¹⁵ Age is a strong prognostic indicator for patients in their early 50s and younger, living significantly longer than those over 60 at the time of diagnosis.^{4,5,12,17}

Table 3. Select glioma types correlated to grades

TUMOR TYPE	GRADE 1	GRADE 2	GRADE 3	GRADE 4
Astrocytoma	NA	Yes	NA	NA
Anaplastic astrocytoma	NA	NA	Yes	NA
Glioblastoma multiforme	NA	NA	NA	Yes
Gliosarcoma	NA	NA	NA	Yes
Pilocytic astrocytoma	Yes	NA	NA	NA
Anaplastic pilocytic astrocytoma	NA	NA	Yes	NA
Oligodendroglioma	NA	Yes	NA	NA
Anaplastic oligodendroglioma	NA	NA	Yes	NA
Ependymoma	Yes	Yes	NA	NA
Anaplastic ependymoma	NA	NA	Yes	Yes
Choroid plexus carcinoma	NA	NA	Yes	Yes

Grade 1=benign; Grade 2=low grade malignancy; Grade 3=malignant; Grade 4=highly malignant.

the brain parenchyma at the site of origin, become attached, and form a mass lesion.^{5,17}

Glioblastoma multiforme

Grade 4 astrocytomas are commonly called glioblastoma multiforme, the most malignant type of brain tumors. Infiltrated areas of brain tissue may also have areas of mass lesion within them. Mitotic signs are frequently seen. These tumors grow so fast that they have a lot of angiogenic activity associated with them and readily enhance on diagnostic scans. Even with this angiogenic activity, the tumor often outgrows its blood supply. This results in cell death and areas of necrosis that show on diagnostic scans. In

Epidemiology of gliomas

Approximately 16,000 people were diagnosed with a primary brain tumor in 1991. In this group, 35% to 45% were diagnosed with a form of malignant astrocytoma. The average incidence for glioma in adults ranges between 5 and 5.4 per 100,000 annually. Of all gliomas diagnosed, 65% are malignant astrocytomas.

Age is a significant risk factor with the rate increasing from 2 per 100,000 at ages 35 to 44 years of age to 17 per 100,000 for ages 75 to 84. Looking only at the elderly (over 70 years) of Kumamoto, Japan, Kuratsu and Ushio (1997) researchers found that primary intracranial tumors were diagnosed in 271 cases with 155 being confirmed histologically. In Kumamoto, this produces an incidence rate of 18.1 per 100,000, with females having the greater overall risk, 20.3, with the average at 15.2 per 100,000. Interestingly, the 70-74 age group ran a higher risk than the older groups. Slightly more than 50% were meningiomas with the next highest type being malignant gliomas (all sub-types combined). These two were followed in order by pituitary adenomas, schwannomas, malignant lymphomas and benign astrocytomas.

In the United States, gender and race are also risk factors for malignant astrocytoma. Both anaplastic astrocytoma and glioblastoma multiforme are more common in men than women, with the ratio varying between 1.06 and 2.1. However, in a British study, Hopewell, Edwards, and Wiernik noted that it is not until one reaches the 45-49 age group that males show a significantly higher risk than females. In the African-American community only 37% of primary brain tumors are malignant astrocytomas, while in the Caucasian community astrocytoma and malignant astrocytoma occur more than 50% of the time.⁵ Genetics also appear to play a role in some types of primary brain tumor.

Increasing rate of incidence?

The incidence of primary malignant brain tumor in the industrialized countries has been reported to have grown dramatically over the past 25 years. This increase has been reported to be as high as 40% in the general population and 100% in those older than 65. The validity of this data is under current debate, with some researchers arguing that better diagnostic imaging techniques have produced the increase and not a true rise in per capita primary brain tumors.

In Rochester, MN, Radhakrishnan, et al (1995) reviewed the incidence of intracranial tumors from 1950 to 1990. The researchers concluded that the increased rate of primary brain tumors was due to a statistically significant increase in pituitary adenomas and better imaging techniques. They did not find a significant change in occurrence of other tumors. This study, too, has been challenged and debate continues. It seems likely two factors affect the overall increase in primary brain tumors: better imaging techniques and the increasing number individuals over 65 years of age.

About the author

Bob Caruthers received both his bachelor's and doctoral degrees from the University of Texas at Austin. His interest in neurology has persisted since his first scrub on a craniotomy in 1970. Dr

Caruthers has published several articles in the Surgical Technologist Journal.

References

1. Adelman LS (1994). Grading astrocytomas. *Neurosurgical Clinics of North America*, 5:1.
2. Fulling KH, Garcia DM (1985). Anaplastic astrocytoma of the adult cerebrum. Prognostic value of histologic features. *Cancer*. 55:5.
3. Arizona University (current). The biology project, www.biology.arizona.edu
4. Bailey P, Cushing HA (1926 [1971]). *Classification of the tumors of the glioma group on a histological basis with a correlated study of prognosis*. Philadelphia: JB Lippincott Co. [reprinted and republished by Argosy - Antiquarian Ltd, New York, NY].
5. Greenberg HS, Chandler WF, Sandler HM (1999). *Brain Tumors*. New York: Oxford University Press.
6. Bailey OT (1986). Genesis of the Percival Bailey-Cushing classification of gliomas. *Pediatr Neurosci*, 12:261-265.
7. Bruner JM (1994). Neuropathology of malignant gliomas. *Semin Oncol*. 21:2.
8. CancerNet (current). NOAH web site Lab. www.noah.cuny.edu
9. Carlson BM (1999). *Human Embryology & Developmental Biology*. Mosby: St Louis.
10. Chassande FO, Bilbaut G, Dehay C, Savatier S, Samarut J (1995). In vitro differentiation of embryonic stem cells into glial cells and functional neurons. *Journal of Cell Science*, 108:10.
11. Chung RY, Wiestler OD, Seizinger BR (1992). P53 mutations are associated with 17p allelic loss in grade II and grade III astrocytoma. *Cancer Research*, 52(10), 2987-2990.
12. Daumas-Duport C, Scheithauer B, O Fallon J, Kelly P (1988). Grading of astrocytomas. A simple and reproducible method. *Cancer*, 62(10), 2152-65.
13. Daumas-Duport C (1992). Histological grading of gliomas. *Current opinion in neurology and neurosurgery*, 5:6.
14. El-Azouzi M, Chung RY, Farmer GE, Maruza RL, Black PM, Rouleau GA, Hettlich C,

- Hedley-Whyte ET, Zervas NT, Panagopoulos K, Nakamura Y, Gusella JF, Seizinger BR (1989). Loss of distinct regions on the short arm of chromosome 17 associated with tumorigenesis of human astrocytomas. *Proceedings of the National Academy of Science*. USA 86:7186-7190.
15. Fraishard A, Chassande O, Bilbaut G, Dehay C, Savatier P, Samarut J (1995). In vitro differentiation of embryonic stem cells into glial cells and functional neurons. *Journal of cell science*, 108 (10): 3181-88.
 16. Frankel RH, Baytona W, Koslow M, Newcomb EW (1992). P53 mutations in human malignant gliomas: comparison of loss of heterozygosity with mutation frequency. *Cancer Research*, 52 :1427-1433.
 17. Fulling KH, Garcia DM (1985). Anaplastic astrocytoma of the adult cerebrum. Prognostic value of histologic features. *Cancer*, 55(5):928-31.
 18. Fults D, Brockmeyer D, Tullous MW, Pedone CA, Cawthon RM (1992). P53 mutations and loss of heterozygosity on chromosomes 17 and 10 during human astrocytoma progression. *Cancer Research*, 52: 674-689.
 19. Fults D, Pedone CA, Thomas GA, White R. Allotype of human malignant astrocytoma (1990). *Cancer Research*, 15: 50(18), 5784-9.
 20. Galton Lab (current). A genetic site with information provided on several levels. www.gene.ucl.ac.uk
 21. Helseth A (1995). The incidence of primary central nervous system neoplasms before and after computerized tomography availability. *Journal of Neurosurgery*, 83(6)999-1003.
 22. Hopewell JW, Edwards DN, Wiernik G (1976). Sex dependence of human intracranial gliomata. *British Journal of Cancer*, 34(6):666-70 .
 23. Kim TS, Halliday AL, Hedley-Whyte ET, Convery K (1991). Correlates of survival and the Daumas-Duport grading system for astrocytomas. *Journal of Neurosurgery*, 74:1.
 24. Kleihues P, Burger PC, Scheithauer (1994). *Histological Typing of Tumors of the Central Nervous System*, ed 2. World Health Organization, Geneva.
 25. Kondo T, Raff M (2000). Oligodendrocyte precursor cells reprogrammed to become multipotential CNS stem cells. *Science*, Sep 8:289.
 26. Malkin MG (2000). New medical therapies for malignant brain tumors. The Brain Tumor Society, www.tbts.org/newmed
 27. Kernohan JW, Sayre (1950). *Atlas of Tumor Pathology: Tumors of the Central Nervous System*. Armed Forces Institute of Pathology. Washington.
 28. Rao MS, Noble M, Mayer-Pröschel M (1998). A tripotential glial precursor cell is present in the developing spinal cord. *Neurobiology*, 95:7.
 29. Rao MS, Mayer-Pröschel M (1997). Glial-restricted precursors are derived from multipotent neuroepithelial stem cells. *Developmental Biology*, Aug 1:188.
 30. Tatter S Lab (current). The new WHO classification of tumors affecting the central nervous system. www.neurosurgery.mgh.harvard.edu
 31. Turner EE (2000). Research Interests. www.medline.uscd.edu/neurosci
 32. Vincent S, Vonesch JL, Giangrande (1996). Glide directs glial fate commitment and cell fate switch between neurones and glia. *Development*, 122(1):131-39.
 33. Von Deimling A, Eibl RH, Ohgaki H, Louis DN, von Ammon K, Petersen I, Kleihues P, Walker AE, Robins M, Weinfield (1985). *Neurology*, 35 (2):21926.
 34. Winberg ML, Perez SE, Steller H (1992). Generation and early differentiation of glial cells in the first optic ganglion of *Drosophila melanogaster*. *Development*, 115 (4):903-11.
 35. Weinberg RA (1996). How cancer arises. *Scientific American*, 275:3.
 36. Wu JK, Ye Z, Darras BT (1993). Frequency of p53 tumor suppressor gene mutations in human primary brain tumors. *Neurosurgery*, 33(5):824-830.
 37. Zulch KJ (1979). *Histological typing of tumors of the central nervous system*. World Health Organization, Geneva.

S16.0
DFOV 24.0 cm
choline / creatine
cursor 3x3

BY BOB CARUTHERS, CST, PHD

HIGH GRADE ASTROCYTOMA IN THE ADULT

**BIOLOGY,
PATHOLOGY,
DIAGNOSTICS,
AND TREATMENT**

PART 2

2511

R

1
2
0

-1

1	2	3	4	5	6
7	8	9	10	11	12
13	14	15	16	17	18
19	20	21	22	23	24
25	26	27	28	29	30
31	32	33	34	35	36
37	38	39	40	41	42
43	44	45	46	47	48

GRADE ASTROCYTOMA

The current WHO classification system (1993) for astrocytomas illustrates diagnostic concepts that have developed over the years. The first category, covering some 75% of the astrocytomas, is divided into three groups that demonstrate a spectrum of increasing malignancy—astrocytoma, anaplastic astrocytoma, and glioblastoma multiforme. This group of tumors tends to undergo malignant changes and invade the surrounding brain tissues and the meninges. The second category consists of the polycystic astrocytoma, pleomorphic xanthoastrocytoma, and subependymal giant cell astrocytoma.

The second grouping tends to have a better prognosis than the first because they do not demonstrate such an aggressive capacity for invasion of surrounding tissue and are somewhat limited in comparison to the first group in both growth rate and anaplastic progression. A significant histologic distinction can be made between group one and group two. Group one, high-grade astrocytomas, is adept at infiltrating surrounding tissue. The second tumor group, on the other hand, consists of micro-

scopically circumscribed neoplasms. This demonstrates a limited aggressiveness in comparison to the first group.

This article will focus on the tumors of group 1, specifically the high-grade astrocytomas: anaplastic astrocytoma and glioblastoma multiforme. (Part I, published in the March 2001 issue, provides a general discussion of these tumors). A case that began with a mild focal symptom and progressed to hemiparesis secondary to a large right frontoparietal mass will be used throughout the article for illustrative purposes. The treatment section will focus exclusively on the glioblastoma multiforme (GBM). It is presumed that a histologic distinction can be made consistently between the astrocytoma and the anaplastic astrocytoma and glioblastoma multiforme.²¹

Illustrative case

This case history will be used to demonstrate the application of diagnostic and treatment strategy, as well as modalities. The illustrative case concerns a Caucasian male in his early 50s, right handed with no history of neurological deficit, although he suffered two minor concussions during high school. His presenting complaint was a tingling sensation in the 4th and 5th fingers of his left hand, which he attributed to a compression of the ulnar nerve following a long car trip. Between the time that the appointment was scheduled and the patient's arrival at the doctor's office, a tingling sensation developed in the median nerve distribution. He had no history of headache, nausea, or vomiting, demonstrated no central neurological deficits during the exam, and had a positive Tinel's sign in the ulnar distribution.

The patient was started on prednisone and scheduled for an EMG. The EMG was performed approximately one week after the initial visit with normal results.

By that time, the patient began to notice what he called a "bizarre sensation" on the left half of his body. While attending a social event, he noted that someone caught his arm, and he had not recognized it until he felt off balance. By the next morning, he had developed a droop on the left side of his face and was experiencing difficulty walking without bearing to the left. At that time, he admitted himself to the emergency room and a CT scan was performed. The scan demonstrated a large right-frontoparietal mass consistent with a high-grade astrocytoma. Prior to surgery, a MRI with enhancement was also performed. The preoperative diagnosis was glioblastoma, which was confirmed by histological analysis following surgery.

Diagnostics

Intracranial mass

As with all diagnostic investigations, the diagnosis of an intracranial mass begins with a good history and physical. Risk factors for glioblastoma multiforme in the adult include: race (Caucasian > African American), gender (male

> female), and age (most common in the 50s and 60s). The most frequent symptom associated with these tumors is headache. However, headache is also common for almost any intracranial mass and a wide range of other diseases and conditions.

The most important signs and symptoms related to glioblastoma multiforme evolve from the specific area of the brain that is invaded. Tumors such as meningiomas do not invade brain tissue. They act as a well-differentiated, slow-growing mass lesion that pushes against the brain tissue. Symptoms from this type of tumor are related to pressure and cellular irritability. The diffuse invasion of the brain employed by the glioblastoma multiforme may allow it to go symptomless until it is quite large. Mild focal symptoms may appear for a period, but symptoms can rapidly progress. Hemiparesis is not uncommon in the emergency room.

Differential diagnosis

Headache and/or mild focal neurologic symptoms could indicate any number of neurologic problems. In practice today, the patient is sent immediately for a CT scan or MRI when the symptoms appear to have a central origin.

EMG

The electromyogram (EMG) is commonly referred to as a nerve conduction study. The EMG is based on the principle that electrically stimulating a nerve should produce a reaction somewhere along the course of the nerve. Properly placed electrodes measure both the response and the conduction time. Recording electrodes are placed on the appropriate muscle belly for motor nerves. For sensory studies, the electrodes are placed over the nerve. Superficial nerves may be stimulated using a skin electrode, but nerves deep within the skin require the use of an insulated needle electrode.

A grounding electrode or, more commonly, a grounding plate is placed between the stimulating and recording electrodes with the two being equidistant from the ground. Electrical current is applied to achieve a maximum response. The

current is then increased again to guarantee a maximum response.

CT scan

Godfrey Hounsfield conceptualized the technique of the CT scan, and the first clinical use occurred in 1972. This revolutionized the diagnostic approach to intracranial lesions and abnormalities. Because the CT scan allows for direct imaging and differentiation of soft-tissue structures, it is an effective means for identifying space-occupying lesions, tumors and metastases. The scan times with CT imaging vary between 500 milliseconds to a few seconds. This short scan time makes it especially attractive in the emergency room setting.

Developed for purely diagnostic procedures, the CT scan can be used for interventions such as guided biopsy and minimally invasive therapy, may be used to help plan radiation therapy for cancer and to follow the effects of radiation on the tumor. Today, the CT scan can be combined with other computerized-image manipulating techniques to produce three-dimensional images.

A CT scanner resembles a large box with a 60- to 70-cm hole, large enough to accommodate a human being, in the center. The covers of a CT scanner house a rotating device with an X-ray tube mounted on one side and a banana-shaped X-ray detector opposite. As the rotating frame spins the X-ray tube and detector around the patient, a fan-shaped beam is created. Each time the tube completes a 360° rotation, a thin image is produced, which represents a “slice or cut” through the brain. Each slice is focused between 1-10 mm. Each two-dimensional slice provides limited information alone. Since the scan produces both coronal and transverse slices, the combined films provide a solid interpretation of the three-dimensional aspects of the area being scanned. As the data from a slice is interpreted, the computer assigns a number to each level of density. This number is then converted and added to a color scale by the computer so an image can be produced.

The CT scan can be performed without any type of enhancement of the arteries;

however, it is common for diagnostic scans to involve a contrast agent when vascular information is required. There are four basic types of contrast agents used with the CT scan, which can be categorized based on the method of delivery:

- Intravenous contrast agents
- Oral contrast agents
- Contrast agents given rectally
- Contrast agents given as a gas that is inhaled (Xenon CT).

The most common approach is via intravenous infusion. Typically, between 75 and 100 cc of

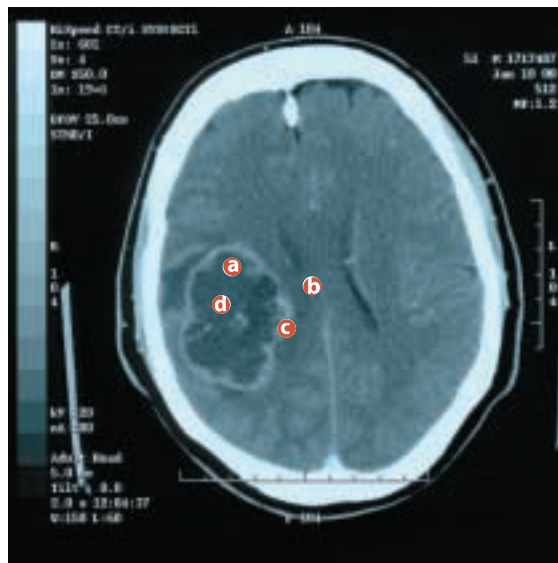


FIGURE 1

Illustrative case,
CT scan

performed in ER

contrast medium is used. This varies somewhat on the patient’s age, weight, and the area being scanned. The contrast agent has an iodine base, so allergies to iodine and shellfish must be checked prior to injecting this medium.

The CT scan uses an X-ray beam that is attenuated as it passes through the body. The different densities of organs create the various shades of gray that are recorded on an X-ray film. Blood vessels filled with the contrast medium are more dense and enhance the image. Although there is a relatively mild risk associated with the use of the contrast medium, the benefits clearly outweigh the risks in almost every situation (Figure 1).

- Ⓐ tumor mass (not radically different in appearance from normal brain tissue)
- Ⓑ mass has collapsed the ventricle
- Ⓒ active peripheral boundary of the tumor
- Ⓓ area ahead of the tumor is actively developing a new blood supply

Magnetic resonance imaging

Magnetic resonance imaging (MRI) is another noninvasive diagnostic procedure that uses magnets and radiowaves to produce a picture. Like the CT scan, the MRI produces images that are slices of a specific part of the body. Print-outs of the series of coronal and transverse images (Figures 2 and 3) allow the physician to evaluate the three-dimensional structures under consideration.

In comparison to the CT scan, the MRI images are more detailed and provide more overall information. This is particularly true when scanning soft tissues such as the brain. Perhaps the primary difference between the CT scan

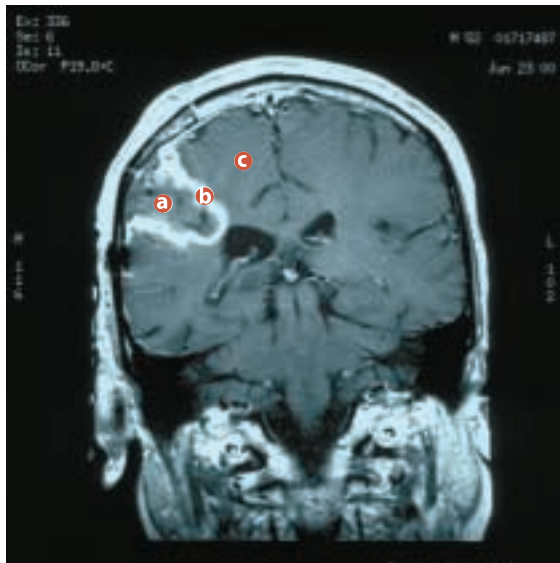


FIGURE 2

Illustrative case,
postoperative and
postradiation MRI
(coronal cut)

- Ⓐ postoperative cavity containing cellular debris
- Ⓑ enhanced area at remaining tumor border
- Ⓒ brain swelling (note effect on ventricle)

and the MRI is that the former produces images by exposing the body to X-rays. The latter creates a strong magnetic field that causes the atoms within the body to align. A radiowave is then directed at the body to trigger the atoms to respond with radiowaves of their own. These radiowaves create a signal that is detected by the scanner from thousands of different angles around the body. The radio signals are sent to a computer that processes the information and compiles it into a three-dimensional image. These images may be stored on photographic film or videotape.

The risks with MRI are minimal since ionizing radiation is not used. The magnets, however,

are very strong, so precautions must be taken to ensure that metallic objects do not exist inside the patient and that these objects are not carried into the area.

The CT scan is much faster than an MRI; therefore, the CT scan is preferred for emergency use. Large medical centers with a high volume of trauma may have a CT scan unit in their emergency room. Because of the potential problems associated with the strong magnets, the MRI scanner is usually placed in a highly restricted area of the radiology department.

Illustrative case—diagnostic notes

With the illustrative case patient, doctors first pursued the most likely diagnosis, a neuropathy of the ulnar nerve. (Remember, the patient had no history of headaches or seizures.) By the time the EMG had ruled out a peripheral neuropathy, the patient's condition had rapidly deteriorated making it clear that the problem was centralized. This left two likely possibilities, transient ischemic attack (TIA) or intracranial mass. TIAs were essentially ruled out by history. Symptoms had worsened progressively, not episodically. The CT scan confirmed the mass lesion.

Astrocytomas

Histological distinctions

CT and MRI scans will demonstrate the presence of a mass lesion in an overwhelming majority of the cases, and, as is to be expected, will provide considerable insight into the tumor type. The final diagnostic classification, however, must be made on the histologic nature of the tumor.

Tumors of the astrocytoma classification can be placed in one of three subcategories based on the cell of origin:

- *Fibrillary astrocytoma*—stellate astrocytes are commonly found in the white matter of the brain and spinal cord. These cells are characterized by the presence of long processes and bundles of glial filaments in its cytoplasm. Most astrocytomas originate from these cells.

- *Protoplasmic astrocytoma*—protoplasmic astrocytes are mostly found in gray matter and contain few fibrils but numerous branching processes.
- *Gemistocytic astrocytoma*—gemistocytic astrocytes are round or oval cells containing abundant cytoplasm, glial filaments and an eccentric nucleus (9-19% of astrocytomas).²¹ These tumors are often mixed, but greater than 60% of the cells must be gemistocytes to qualify for this designation. More importantly, an astrocytoma with more than 20% gemistocytes generally has a worse prognosis—as many as 80% develop into glioblastomas.²¹ Gemistocytic astrocytoma is, in effect, an anaplastic astrocytoma. This factor is sometimes expressed clinically with a comment like: “Grade 3 astrocytomas are always hurrying to become Grade 4 astrocytomas.”

Anaplastic astrocytoma

Anaplastic astrocytomas may occur as part of the anaplastic progression of a glioma or as their own entity. There is some thought that the number of these de novo anaplastic astrocytomas will decline as our diagnostic imaging abilities increase. The anaplastic astrocytoma differs from the low-grade astrocytoma in the following ways:

- Cellular differentiation
- Increased cellularity
- Increased mitotic activity
- Increased cellular atypia.²¹

Glioblastoma multiforme

Glioblastomas represent about 20% of all primary brain tumors and half of the astrocytoma type. Most glioblastomas develop in astrocytomas and anaplastic astrocytomas. Some develop as multi-lobar or bilateral tumors, or even multicentric tumors. Some glioblastomas appear to develop de novo. These tumors exhibit precisely the kind of histologic structures one would expect from a tumor so malignant:

Related Terms

Blood-brain barrier (BBB)

Certain characteristics of brain capillaries create a barrier that prevents potentially harmful substances from entering brain, while allowing oxygen and nutrients access to the tissues. These capillaries can also limit or prevent potentially beneficial medications from crossing the barrier.

Greenfield® filter

A multistrutted, spring-style filter designed to protect against pulmonary embolism. The permanent filter is percutaneously implanted in the vena cava.

Prednisone (corticosteroid)

Hydrocortisone and cortisone occur naturally as glucocorticoids and are essential. The synthetic analogs are used to treat many conditions because they have strong anti-inflammatory effects. Prednisone is usually given orally or by injection. (Other corticosteroids will play an important role in treatment once the mass lesion is identified.)

Peripheral neuropathy

A disease or syndrome characterized by muscle weakness, paresthesia, impaired reflexes, and autonomic symptoms in the hands and feet.

Tinel's sign

A sensation of tingling sometimes identified by the patient as “pins and needles,” that is felt in the distal portion of a limb when percussion is made over the site of an injured nerve. The tingling should occur in the normal area innervated by the nerve in question and should reproduce previous symptoms. A positive sign may confirm a lesion during the diagnostic phase or early regeneration in the nerve later on.

Transient ischemic attack (TIA)

A sudden focal loss of neurological function with complete recovery usually within 24 hours. TIAs are caused by a brief period of inadequate blood flow in a section of the carotid or vertebral basilar arteries.

- Demonstrates the extreme of cytologic pleomorphism
- Demonstrates the extreme of nuclear pleomorphism
- High cellularity
- Obvious mitosis
- Necrosis
- Marked endothelial proliferation
- Diffuse invasion of surrounding tissue.

The last four malignant features help explain typical features of a glioblastoma as seen on a CT or MRI scan. Endothelial proliferation is related to angiogenesis. The tumor is working to create its needed blood supply. This area of hypercellu-

acterized by giant cells that are highly varied in cytoarchitecture and often multinucleated. The gliosarcoma is apparently induced by the vascular stroma and may develop into a tumor that demonstrates more sarcomatous characteristics.

Treatment

Treatment strategy for glioblastoma has varied with the amount of information known about the tumor and with the treatment options available. Both pharmacological and technological advances have expanded the treatment options and the possibility of prolonged life with some acceptable quality of life. The basis for all the treatment schemes is relatively standard:

1. Tumor reduction
2. Radiation therapy
3. Chemotherapy
4. Continued monitoring
5. Treatment of other concerns
6. Adjustment of plan as necessary
7. Physical and occupational therapy

Treatment regimens

A number of therapeutic and chemotherapeutic regimens are used around the world. At this time, at least 64 chemotherapy clinical trials are in progress, not to mention 100 studies focused on treatment schemes—a considerable amount of research on the glioblastoma. Obviously, no singular solution or standard treatment is available and may not be for some time, if ever. Most of the current trials are focused on the use of various combinations of chemotherapeutic agents. To date, reports seem to indicate that the use of several chemotherapeutic agents is more effective than a single-agent approach.

Other treatment issues

Numerous other concerns are related to treatment of the glioblastoma. Two of these are obvious: the quality of the surgical resection and the complex drug interactions that occur secondary to the variety of medications required during treatment. Because of the tumor's frequent position, hemiparesis is not an unusual event related

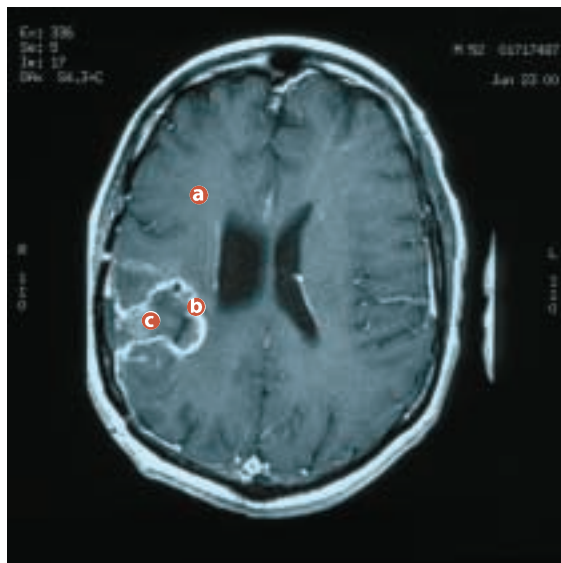


FIGURE 3

Illustrative case,
postoperative and
postradiation MRI
(transverse cut)

- Ⓐ brain swelling
- Ⓑ enhanced tumor border
- Ⓒ postoperative cavity containing cellular debris

larity causes the leading portions of the tumor to “light up” with the use of a contrast medium. While the tumor is working to produce an adequate blood supply, it often cannot supply the cells closer to the malignant cell of origin. These cells die producing an area of necrotic tissue that shows up on a scan as a darker area inside the tumor. Finally, an area around the tumor appears to be of decreased density and has been correlated to the area of cellular invasion into new tissue.

Glioblastoma subtypes

Two subtypes of glioblastoma are the giant cell glioblastoma and gliosarcoma. The first is char-

to glioblastoma. This requires physical and occupational therapy, at least, and may require psychological counseling also.

Glioblastomas also have been correlated to a higher-than-usual incidence of blood clot formation and embolism. Anticoagulants are required and must be carefully monitored. A Greenfield filter may be placed if clots form. The brain is generally edematous and subject to both pre- and postoperative swelling. Corticosteroids may be used for a significant period to combat this problem.

Many medications are used during the therapeutic effort. Constant vigilance is required to monitor white blood cell count, platelets, and the international normalized ratio (INR). A change in one medication may cause a change in the effectiveness of all the others. These are monitored weekly.

Surgical intervention

Tumor reduction, especially in small, low-grade tumors may be accomplished by radiation therapy, but reduction of the typical high-grade GBM is generally accomplished by a surgical procedure. Since many of these tumors are found in the frontoparietal area and may be large, reduction is accomplished via craniotomy. Technological advances, such as frameless stereotactic imaging and electrophysiologic measurement of action potentials (intraoperative mapping), have permitted the surgeon to remove more of the tumor while providing some safety to the patient. The primary purpose of tumor reduction is to dramatically reduce the number of tumor cells that need to be killed by radiation or chemotherapy. The amount that the tumor is reduced correlates strongly to the length of survival.

Radiation therapy

External beam therapy directs ionizing radiation from a machine to the tumor cells. The total dosage required is calculated using type, grade, and stage information. A fractionated approach is used for delivery (ie a fraction of the total dose is given each session). Typically, four to five radi-

ation sessions are given per week. Dose-time intervals are calculated and the precise angle of the beam is calculated from MRI data.

The affect of radiation on cells is very complex, but the critical factor is the radiation's ability to damage the nuclear DNA in the tumor cells while sparing normal cells. This inhibits reproduction and leads to apoptosis. Either X-rays or gamma rays may be used.

Initially, the patient goes through a simulation procedure where a firm but mesh-like mask is created. Alignment markings are placed on the mask. The mask attaches to the table, guaranteeing that the patient is properly positioned each time.

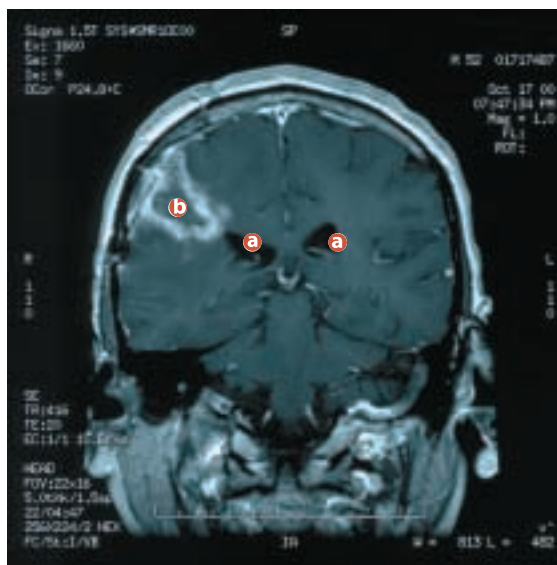

FIGURE 4

Illustrative case,
postoperative,
postradiation, and
post chemotherapy
(BCNU) MRI
(coronal cut)

- Ⓐ decreased brain swelling; ventricles about the same size
- Ⓑ postoperative site shows no tumor regrowth

Radiation therapy may produce a number of side effects, but these are minimal in most brain tumor cases and probably related to the relatively small area being irradiated.

Select medications and chemotherapy agents

Table 1 provides basic information about a select number of medications and chemotherapy agents. The illustrative case will be used to demonstrate one scheme for the use of these agents.

Illustrative case—treatment

The patient and family met with the neurological oncology team prior to surgery. The team

included a neurosurgeon, neurooncologist, neuropsychologist, director of rehabilitation, and a social worker. The patient, with full understanding of the potential complications, asked the neurosurgeon and neurooncologist to take an aggressive approach. The patient decided to participate in two studies being conducted by the faculty of the medical school. One study concerned the use of the light-activated substance Photofrin. The other was evaluating the use of Irinotecan in combination with other agents.

The patient began receiving dexamethasone following the diagnosis of an intracranial mass. Prior to surgery, an MRI with enhancement was performed. Approximately 24 hours prior to

six weeks. A blood clot formed in the left thigh. Medications were adjusted and a Greenfield filter was placed in the vena cava.

Treatment overview

An overview of treatment is as follows:

- Fractional radiation therapy was started as soon as the patient's condition allowed and continued on an outpatient basis for a total of 34 treatments.
- The first of the chemotherapeutic infusions was done during the last week the patient was in the rehabilitation unit. Chemotherapy cycles were scheduled at four-week intervals.

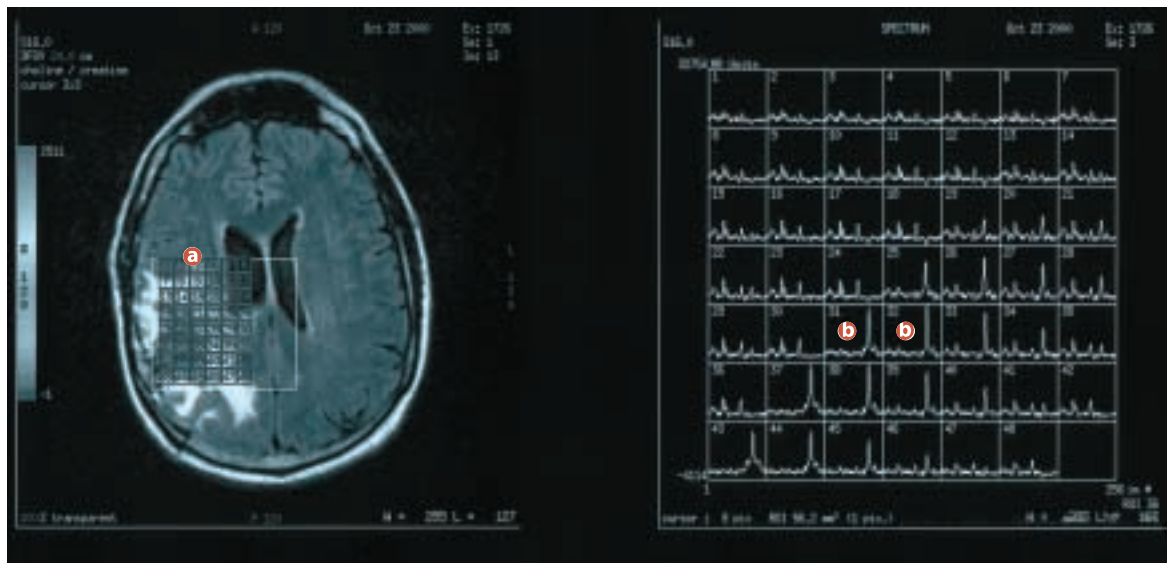


FIGURE 5

Illustrative case,
36 week
postoperative MR
spectroscopy

- Ⓐ computerized grid over area of study
- Ⓑ high spikes in 31-32 indicate active tumor cells

surgery, the patient received an infusion of Photofrin. A right frontoparietal craniotomy was performed, and the tumor was debulked. Because of the relationship between the tumor and the motor strip, a frameless stereotatic technique and electrophysiologic intraoperative mapping were used to assist the surgeon.

Following surgery, the patient was hemiparetic on the left side. He was admitted to the neuro intensive care unit, remained for three days before being transferred to the neuro-ortho unit, and moved to the acute rehabilitation unit four days later. Physical and occupational therapy, plus radiation and chemotherapy were initiated prior to dismissal. Total hospitalization time was

- Chemotherapy followed this pattern:
 1. Three cycles of Irinotecan infusion and oral Temodar
 2. Five cycles of Carmustine and Irinotecan infusion with oral Temodar
 3. Five cycles of Irinotecan infusion and oral Temodar
 4. Oral Tamoxifen, taken daily, was added after the first two cycles of Irinotecan.

Tamoxifen is a biologic agent that does not kill tumor cells directly, but slows cell growth with the intent of inducing apoptosis. It is not as toxic as chemotherapy agents and can be taken for a long period of time.

Total chemotherapy time, not including the biologic agent Tamoxifen, covered approximately one year from the date of surgery. Following the completion of radiation and at spaced intervals during chemotherapy, follow-up MRIs were done to monitor the progress of therapy or identify the recurrence of the tumor (Figure 4). MRI evaluations were performed at 24 and 36 weeks.

A new test, the magnetic resonance spectroscopy (Figure 5) uses the MRI machine to establish a grid for a chemical activity survey. Performed at 36 weeks, this imaging technique detects the presence of select chemicals related to tumor-cell activity in the patient. To date, the findings have not been confidently correlated with the clinical situation. Extremes are meaningful. For instance, a lack or significant decrease in these chemicals is clearly good news; a marked increase or return of activity points in the other direction. Most results are less clear. For instance, researchers do not know how long after cell death the chemicals remain and can be measured. Nevertheless, this test represents another step forward and offers a positive area of development.

Treatment schemes and prognosis

With all the advances and success in the treatment of cancer, why do outcomes for the glioblastoma seem to lag behind? My own experience gained while working with a neurosurgical group and patients suffering from glioblastoma, plus a review of scholarly and clinical literature and personal discussions with two neurosurgeons, a neurooncologist and a neuro-radiologist lead me to the following conclusions:

Biological factors contribute to the slow advance.

- GBMs have developed an unusual ability to resist mechanisms, such as a proptosis, that would ordinarily cause the cells to die.
- The blood brain barrier remains a significant problem in neurooncology.
- The tumors are usually quite large before being diagnosed.

Non-biological factors may be equally or more important.

- These tumors affect a relatively small portion of the population.
- Until recently, the treatment scheme of surgery, radiation, and chemotherapy caused such severe side effects that patients tended to surrender early in therapy.
- Until recently physicians and neurosurgeons typically saw patient after patient deteriorate and die in spite of their best efforts, leading to a palliative versus curative approach.

These factors created an environment in which a truly aggressive approach to GBMs was seldom taken. The highly malignant GBM followed its deadly course, reinforcing the generally perceived hopelessness. Treatment outcomes, then, became a self-fulfilling prophecy. Some of the most significant advances in treatment today have been made in radiation therapy and chemotherapy. Neither treatment mode tends to overwhelm the patient. This allows the patient's body to respond, and patient and oncologist to select an aggressive approach to the GBM.

Hope for the future

The battle against the glioblastoma multiforme is not only continuing, but in many ways, it has just begun. Hope for the future resides with the following:

- Biological knowledge and deepening understanding of tumor biology
- Technological advances in the area of diagnostics and therapy
- Pharmacologic advances
- A better understanding of the psychology and spirituality of survival.

One illustrative example of hope is the workup being done by JG Cairncross on the oligodendroglioma. These researchers have identified certain biochemicals that allow them to predict the response of a given tumor to chemotherapy and

	Agent	Admin	Action	Complications	Notes
Neurologic & other agents	Phenytoin (Dilantin)	Oral, IM, IV	An antiepileptic drug	CNS toxicity	IM & IV administration must be slow. Blood levels checked routinely.
	Decadron	Oral or IV	Used to decrease brain swelling secondary to tumor disruption of the blood brain barrier and fluid leakage into the surrounding tissue. The common and sought after response includes: a reduction in symptoms, a sense of well being, and improvement in neurologic status.	1-8	Corticosteroids can not be stopped quickly. A long monitored period of dose reduction is required.
	Lorazepam	Oral, IM, IV	Antianxiety agent used to stop or prevent seizures.	Large number of side effects possible. Critical—bronchospasm.	Beware of drug interactions. Patients may need extra help walking for a while.
	Warfarin sodium	Oral	Anticoagulant that interferes with vitamin K dependent clotting factors II, VII, IX, and X.	Hemorrhage	Glomas correlate to a higher incidence of blood clot formation than other brain tumors. Blood levels monitored. (Heparin may be used initially.)

Preparatory agents	Kytril	Oral or IV	Antiemetic and antivertigo medication used to prevent these complications secondary to chemotherapy.	4, 17	Kytril administration should be completed prior to initiating chemotherapy.
	Atropine sulfate	IV	Potent parasympatholytic that blocks acetylcholine action at postganglionic sites. Small doses inhibit salivary and bronchial secretions. Used as part of the chemotherapy preinfusion routine.	1, 2, 17, 21, 22	Inform patient to expect a very dry mouth.

Select chemotherapy agents (used in illustrative case)	Carmustine (BCNU)	IV	Chemotherapeutic agent	1, 2, 3, 14, 17	May be given alone or in combination with other chemotherapeutic agents.
	Irinotecan (CPT-11)	IV	Antineoplastic agent that interferes with DNA's ability to uncoil.	1, 2, 3, 25, 26, 27	May be given alone or in combination with other chemotherapeutic agents.
	Tamoxifen citrate	Oral	A nonsteroidal antiestrogen developed as an antineoplastic for breast cancer. Thought to affect nuclear DNA leading to apoptosis in brain tumors.	1, 2, 3, 4—Generally mild but can increase bone pain and tissue swelling in rare instances.	Originally developed for breast cancer.
	Temozolomide	Oral	Only oral chemotherapeutic agent demonstrated to cross the blood brain barrier. It affects tumor cell growth directly. Does not require metabolic activation.	1, 2, 19, 26	
	Photofrin	IV	Chemotherapeutic agent that is activated during surgery (Photo Dynamic Therapy).	27, 28	Infused 24 hours prior to surgery. Should be cleared from most healthy tissue in 12 hours, but remains in tumor cells.

Complications: 1 nausea, 2 vomiting, 3 diarrhea, 4 constipation, 5 stomach irritation, 6 neutropenia, 7 anemia, 8 thrombocytopenia, 9 increased appetite, 10 puffy moon shaped face, 11 mood swings, 12 depression, 13 CNS symptoms, 14 pulmonary complications, 15 renal complications, 16 liver complications, 17 headache, 18 lethargy, 19 skin rashes, 20 elevated liver enzymes, 21 tachycardia, 22 bradycardia, 23 dysrhythmias, 24 dizziness, 25 flushed, hot, dry skin, 26 allergic reactions, 27 birth defect in exposed fetus, 28 myelosuppression, 29 hyperglycemia, 30 water retention causing extreme weight gain

radiation therapy. If this is true for one glioma, one must suspect that it is true for all. Secondly, advances in the technique and clinical application should one day allow for the matching of a chemotherapeutic agent to a given tumor. The battle against the glioma multiforme is far from over, but it continues with high expectations.

About the author

Bob Caruthers received both his bachelor's and doctoral degrees from the University of Texas at Austin. His interest in neurology has persisted since his first scrub on a craniotomy in 1970. Caruthers has published several articles in *The Surgical Technologist Journal*.

References

1. Adelman LS (1994). Grading astrocytomas. *Neurosurgical clinics of North America*, 5:1. *Neurosurgery*, 17(3):231-51.
2. Bernstein M, Rutka J. Brain tumor protocols in North America. *Journal of Neurooncology*. 17(3):231-51.
3. Bruner JM (1994). Neuropathology of malignant gliomas. *Semin Oncol*, 21:2.
4. Burger PC (1983). Pathologic anatomy and CT correlations in the glioblastoma multiforme. *Applied Neurophysiology*, 46 (1-4) 180-7.
5. Cukier D, McCullough (current). *The basics of radiation therapy*. www.health.excite.com
6. Eyre HJ, Eltringham, Gehan EA, Vogel FS, Al-Sarraf M, Talley RW, Costanzi JJ, Athens JW, Oishi N, Fletcher WS (1986). Randomized comparisons of radiotherapy and carmustine versus decarbazine for the treatment of malignant gliomas following surgery: a southwest oncology group study. *Cancer Treatment Reports*, 70(9):1085-90.
7. Fulling KH, Garcia DM (1985). Anaplastic astrocytoma of the adult cerebrum. Prognostic value of histologic features. *Cancer*, 55:5.
8. Greenberg HS, Chandler WF, Sandler HM (1999). *Brain Tumors*. New York: Oxford University Press.
9. Janny P, Cure H, Mohr M, Heldt N, Kwiakowski F, Lemaire JJ, Plagne R, Rozan R (1994). Low grade supratentorial astrocytomas. Management and prognostic factors. *Cancer*, 73 (7):1937-45.
10. Jory VV. CPT-11 (Camptosar®, Irinotecan) Review. On-line paper, www.virtualtrials.com/cpt11
11. Kessel D (1998). Photodynamic Therapy. *Science & Medicine*, 11/Aug, 46-55.
12. Kim TS, Halliday AL, Hedley-Whyte ET, Convery K (1991). Correlates of survival and the Daumas-Duport grading system for astrocytomas. *Journal of Neurosurgery*, 74:1.
13. Kleihunes P, Burger PC, and Scheithauer (1994). *Histological typing of tumors of the central nervous system*, ed.2. World Health Organization, Geneva.
14. McLaren BR, Robinson BW, Lake RA (2000). New chemotherapeutics in mesothelioma: effects on cell growth and IL-6 production. *Cancer Chemotherapy Pharmacology*, 45 (6):502-8.
15. Mahaley MS Jr, Mettlin C, Natarajan N, Laws ER Jr, Peace BB (1989). National survey of patterns of care for brain tumor patients. *Journal of Neurosurgery*, 71 (6):826-36
16. Muller PJ, Wilson BC (1995). Photodynamic therapy for recurrent supra tentorial gliomas. *Seminars in Surgical Oncology*, 11: 346-54.
17. Malkin MG (2000). New medical therapies for malignant brain tumors. The Brain Tumor Society, www.tbts.org/newmed
18. Methodist health care system (current). External beam therapy www.methodisthealth.com/radiology
19. Tatter S Lab (current). The new WHO classification of tumors affecting the central nervous system www.neurosurgery.mgh.harvard.edu
20. VandenBerg SR (1992). Current diagnostic concepts of astrocytic tumors. *Journal of Neuropathology and Experimental Neurology*, 51(6) 644-57.



PHYSIOLOGY

THE AUTO NERVOUS

The nervous system is one of the most complicated systems in the human body. Along with the endocrine system, it controls many bodily activities. The nervous system senses changes both in the internal and external environments, interprets these changes, and then coordinates appropriate responses in order to maintain homeostasis.¹ In response to changing conditions, the autonomic nervous system (ANS) shunts blood to more needy areas, speeds or slows heart and respiratory rates, adjusts blood pressure and body temperature, and increases or decreases stomach secretions.² Most of this fine-tuning occurs without our conscious awareness or attention, implying a certain amount of functional independence. Hence the term autonomic (auto= self; nom=govern).

ERIC J ZELINSKAS, CST, BA

ONOMIC

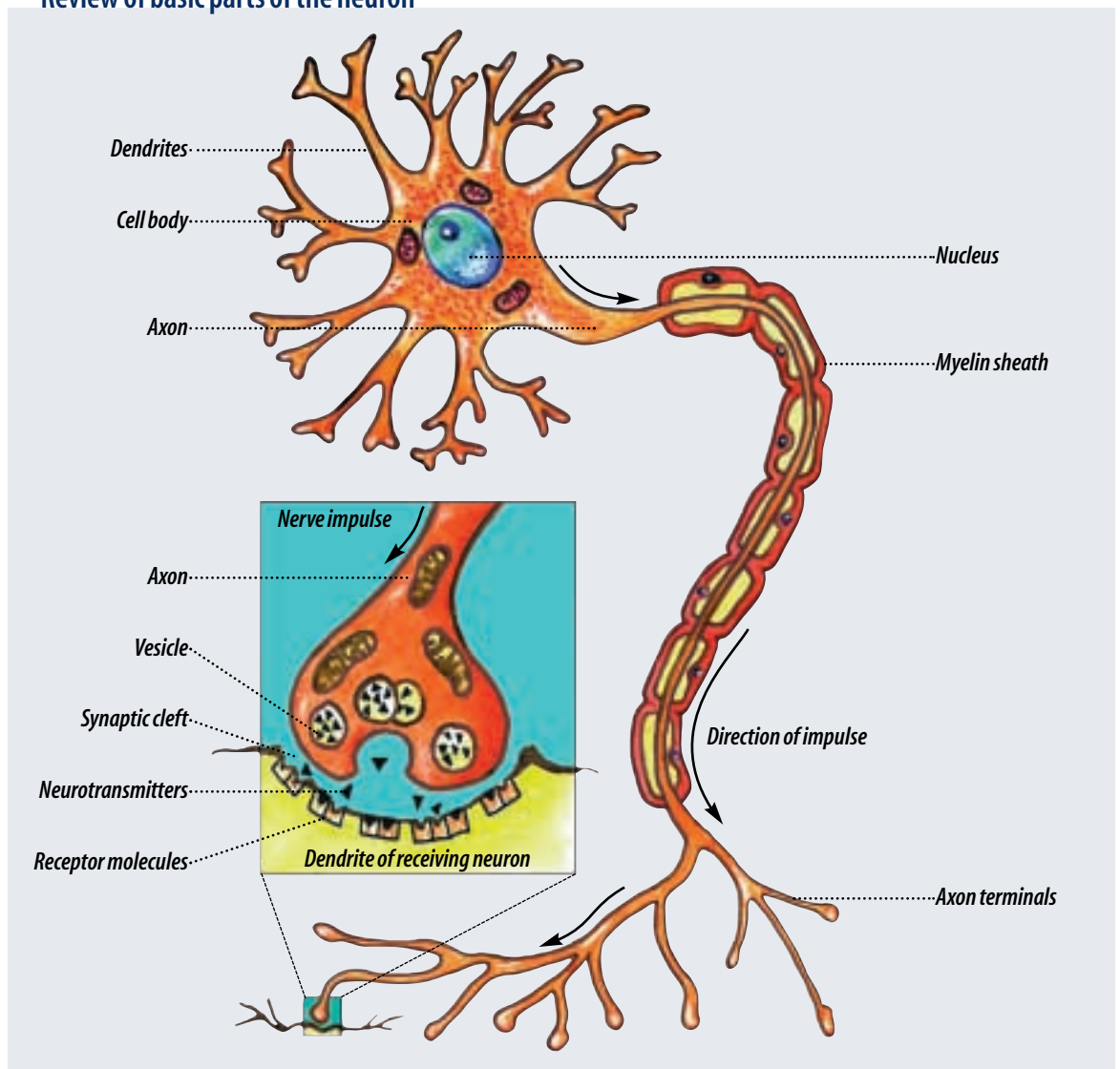
S SYSTEM

General organization

The nervous system includes the central nervous system (CNS), consisting of the brain and spinal cord, and the peripheral nervous system (PNS), consisting of 12 pairs of cranial nerves (which emerge from the base of the skull) and 31 pairs of spinal nerves (which emerge from the spinal cord). All of these nerves consist of fibers that may be sensory or motor or a mixture of both.¹ Nerves composed of both sensory and motor fibers are called mixed nerves. For example, the facial nerve CN VII consists of motor fibers that control facial expressions (eg frowning and smiling) and sensory fibers, which transmit taste sensations from the tongue to the brain.

Functionally, the PNS is subdivided into two specialized systems: the somatic nervous system (SNS) and the autonomic nervous system (ANS).¹ The SNS primarily innervates skeletal muscle, producing consciously controlled, voluntary movement (ie walking and talking). The ANS primarily innervates glands, smooth muscle and cardiac muscle. It's responsible for controlling visceral functions and involuntary muscles in the respiratory, circulatory, digestive and urogenital systems, and in the skin⁶ that are essential for the body to maintain homeostasis. The ANS operates without conscious control. The autonomic nervous system is activated mainly by centers located in the spinal cord, brain stem, and hypo-

Review of basic parts of the neuron



thalamus.³ Often the autonomic nervous system operates by means of autonomic reflexes. Sensory signals from peripheral nerve receptors relay signals into the centers of the cord, brain stem, or hypothalamus, and these in turn transmit appropriate reflex responses back to the peripheral organs or tissues to control their activities.⁴

Divisions of the autonomic nervous system

The autonomic nervous system (ANS) is further divided into two major subdivisions: the parasympathetic nervous system (PaNS) and sympathetic nervous system (SyNS). The two divisions are physiological antagonists and are in equilibrium with each other. Both divisions often innervate the same organ (eg iris of the eye and the heart). Structurally, each division differs in the location of their preganglionic neuron cell bodies within the CNS, the location of their autonomic ganglion, the relative lengths of their preganglionic and postganglionic axons, and the ratio of preganglionic and postganglionic neurons. They both integrate and operate continuously with the rest of the nervous system by responding in varying degrees to information provided by the sensory component of the nervous system.

The SyNS dominates during stressful or physically strenuous situations. It sends impulses that increase blood pressure, speed up rate and force of the heartbeat, dilate bronchioles, increase blood sugar concentration and reroute blood flow to skeletal muscle (fight or flight). Conversely, the PaNS dominates during times of emotional calm and/or physical rest. It sends impulses that decrease blood pressure, decrease heart rate and stimulate gastrointestinal motility (digestion and rest).

Parasympathetic nervous system

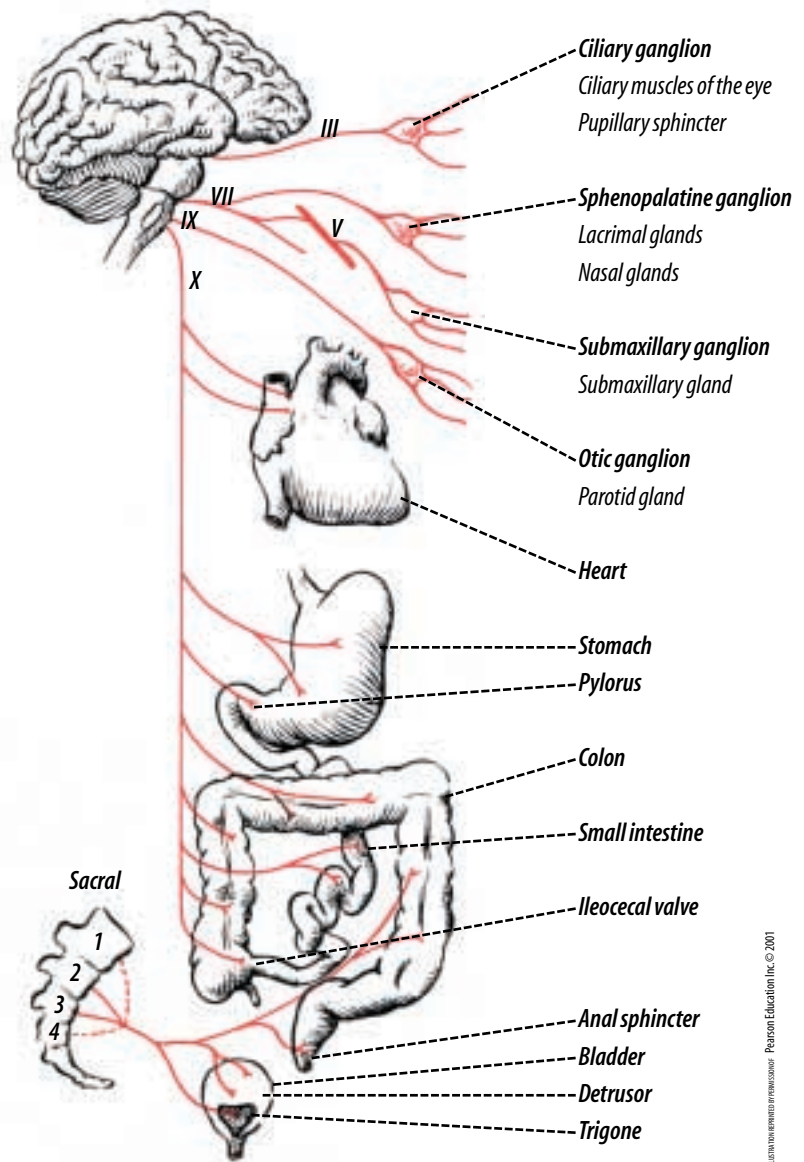
The PaNS is the craniosacral division of the ANS. Preganglionic fibers originate from nuclei in the midbrain, medulla and sacral portion of the spinal cord. Neurons of the PaNS emerge from the brainstem and pass through as part of the III, VII, IX, and X cranial nerves, and 2nd, 3rd, and 4th sacral nerves from the sacral region.⁴ They synapse with postganglionic neurons located in

autonomic (terminal) ganglia that lie near or within the walls of the organs innervated (Figure 1). Since the terminal ganglia are close to the innervated organs/structures, the axons of the postganglionic fibers are short. PaNS preganglionic neurons synapse with only a relatively few postganglionic neurons. For this reason they are much more precise and localized in their effects. Some effects of PaNS stimulation include:

- constriction of pupils
- contraction of smooth muscle of alimentary canal
- constriction of bronchioles
- slowing of heart rate

FIGURE 1

The parasympathetic nervous system.³



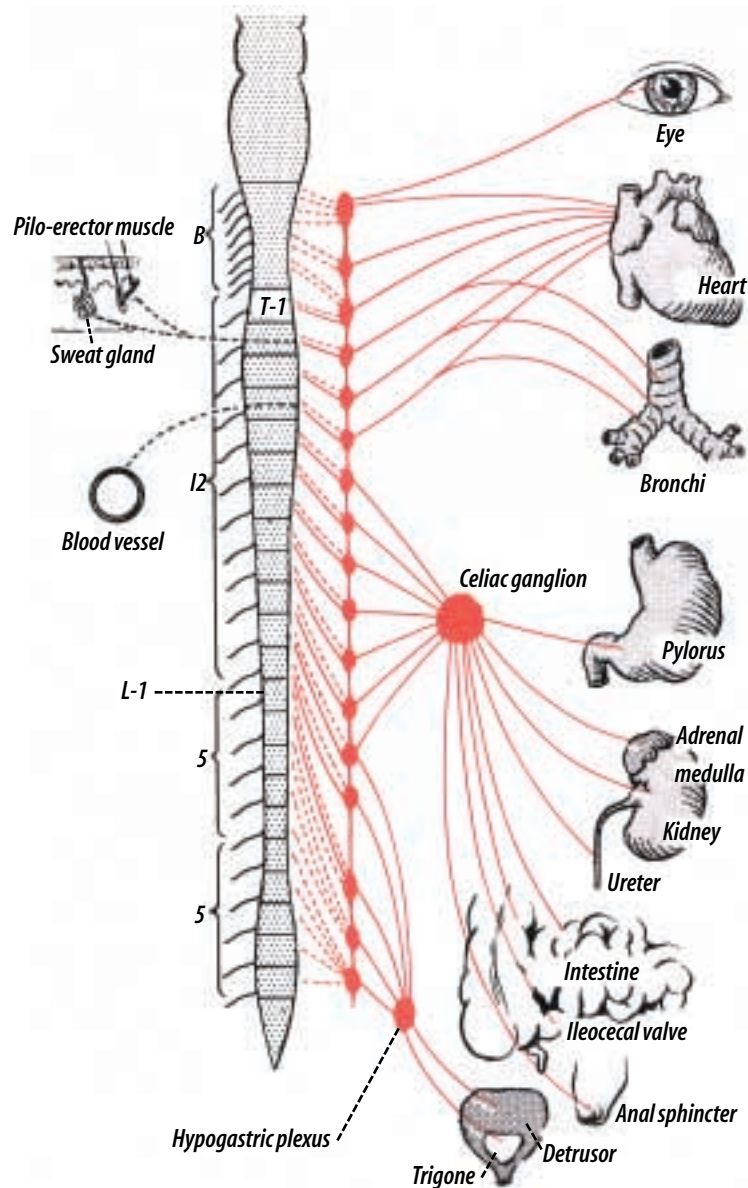


FIGURE 2

The sympathetic nervous system.³

Dashed lines represent postganglionic fibers in the gray rami leading into the spinal nerves for distribution to blood vessels, sweat glands, and pilo-erector muscles.


Transmission of an impulse between preganglionic and postganglionic fibers takes place at an electrochemical junction called a synapse. Both pre- and postganglionic neurons of the PaNS are cholinergic and utilize the neurotransmitter acetylcholine (ACh).⁴ When a nerve impulse reaches the terminus of a preganglionic fiber, it causes the release of ACh, which migrates across the synapse. The ACh combines with receptors on the synaptic membrane of the postganglionic fiber, causing depolarization and continuing the impulse down the postganglionic fiber. Once the impulse reaches the postganglionic terminus and depolarizes it, ACh migrates across the synapse and binds to specific

receptor sites in the effector gland, organ or muscle causing the desired effect (eg release of hormones, muscular contraction, etc). (Table 1)

The action of acetylcholine is relatively brief and usually lasts for only a fraction of a second. It is rapidly broken down by the enzyme cholinesterase, which is present both in the terminal nerve ending and on the surface of the receptor organ. Acetylcholine (cholinergic) receptor sites are classified as either nicotinic or muscarinic. Nicotinic receptor sites for ACh occur at the junction between the preganglionic fibers and postganglionic fibers in both the SyNS and the PaNS divisions of the ANS. Muscarinic receptor sites for ACh occur at the junction between the postganglionic fibers and effector sites in the PaNS division of the ANS.

Sympathetic nervous system

The SyNS is the thoracolumbar division of the ANS (Figure 2). Preganglionic fibers originate from cell bodies in the lateral gray horn of all thoracic and the first two or three lumbar segments of the spinal cord and leave the cord by way of the of the anterior (ventral) spinal nerve roots (Figure 3). They pass through the intervertebral foramina, enter a white rami communicans and connect with the ganglia of the paravertebral sympathetic chain, which are situated anterolaterally to the spinal cord. Each of these paired chains is a series of 22 ganglia spanning the length of the vertebral column.⁴ All preganglionic neurons in the SyNS are myelinated, which gives them a white appearance. Most preganglionic neurons end within the paravertebral sympathetic ganglia and synapse with postganglionic efferent neurons. Some of the postganglionic neurons re-enter the spinal nerves via the grey rami communicans. They appear grey because postganglionic neurons are nonmyelinated. These neurons extend with other neurons in the spinal nerves, eventually branch off and form visceral nerves that innervate smooth muscle and sweat glands. Other preganglionic neurons pass through the paravertebral sympathetic ganglia to a second set of ganglia called collateral ganglia located mainly in the

Table 1 ANS parasympathetic**Table 2** ANS sympathetic**Table 3** Cholinergic and adrenergic receptors²

Neurotransmitter	Receptor Type	Major locations	Effect of binding
Acetylcholine	Cholinergic		
	Nicotinic	All postganglionic neurons; adrenal medullary cells (also neuromuscular junctions of skeletal muscle)	Excitation
	Muscarinic	All parasympathetic target organs	Excitation in most cases; inhibition of cardiac muscle
		Selected sympathetic targets:	
		• Sweat glands	Activation
		• Blood vessels in skeletal muscles	Inhibition (causes vasodilation)
Norepinephrine (and epinephrine released by adrenal medulla)	Adrenergic		
	β_1	Heart, adipose tissue	Increases heart rate and strength; stimulates lipolysis
	β_2	Kidneys, lungs, and most other sympathetic target organs; abundant on blood vessels serving skeletal muscles and the heart	Stimulates secretion of renin; other effects mostly inhibitory; dilation of blood vessels and bronchioles; relaxes smooth muscle walls of digestive and urinary visceral organs
	α_1	Most important blood vessels serving the skin, mucosae, abdominal viscera, kidneys, and salivary glands; but virtually all sympathetic target organs except heart	Activation: constricts blood vessels and visceral organ sphincters
	α_2	Membrane of adrenergic axon terminals; blood platelets	Mediates inhibition of NE release from adrenergic terminals; promotes blood clotting

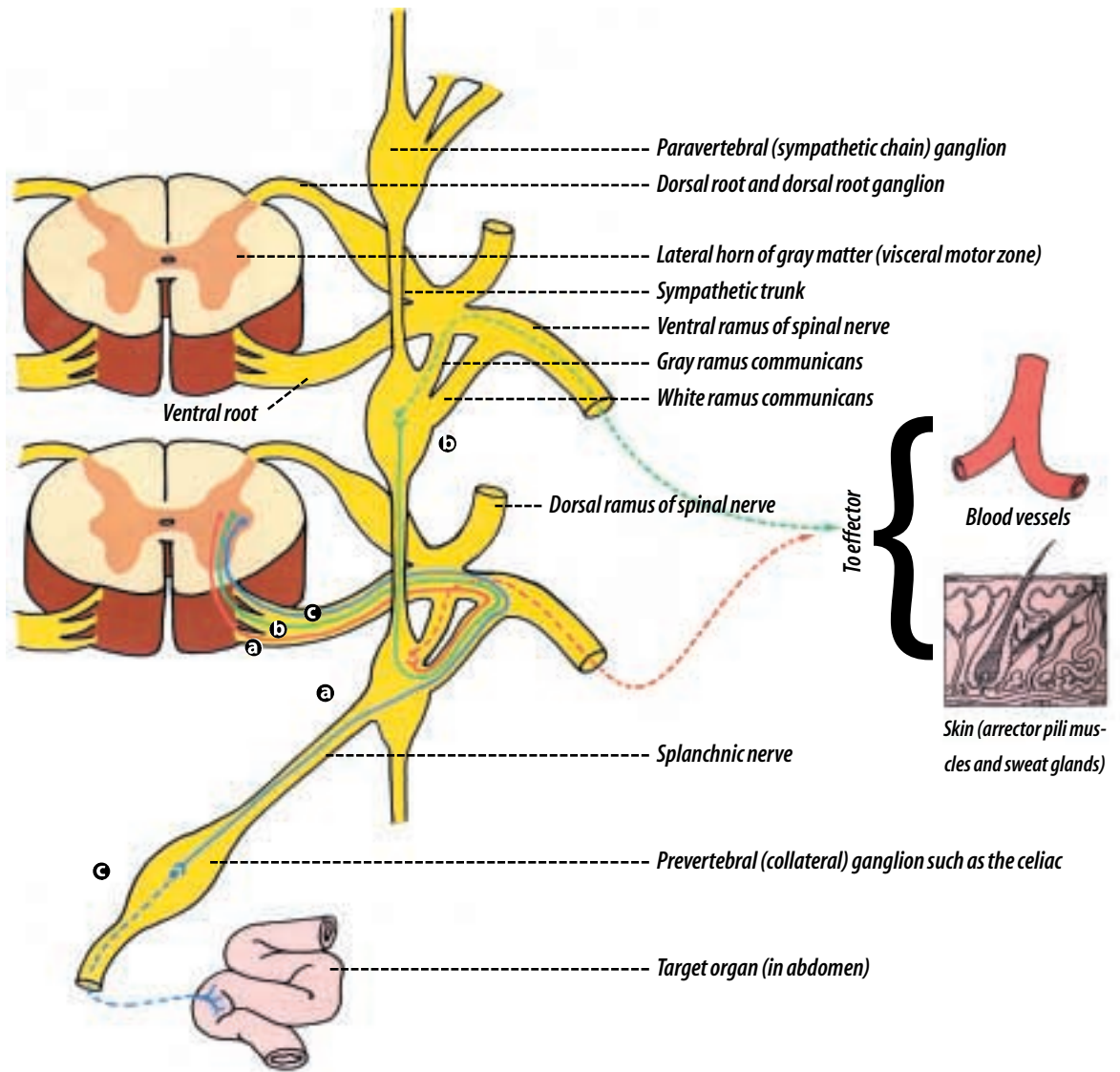


FIGURE 3

Sympathetic pathways.²

- Ⓐ synapse in a paravertebral (chain) ganglion at the same level
- Ⓑ synapse in a paravertebral ganglion at a different level
- Ⓒ synapse in a prevertebral (collateral) ganglion anterior to the vertebral column

abdomen close to the aorta and its major branches (eg celiac, superior mesenteric and inferior mesenteric arteries). These bundles of collateral ganglia are often called plexus.⁴ The preganglionic neurons synapse with nonmyelinated neurons in the collateral ganglion. The postganglionic neurons branch off and innervate the smooth muscles of the abdominal and pelvic viscera and the endocrine glands in that area. The effects of the SyNS are extremely widespread rather than specific to one organ or muscle.

Preganglionic neurons of the SyNS are cholinergic and utilize the neurotransmitter acetylcholine (ACh). A few of the postganglionic neurons of the SyNS are cholinergic and secrete

acetylcholine (ACh). They innervate the sweat glands of the skin, some blood vessels within the skeletal muscles and the external genitalia. But by far, the majority of the sympathetic postganglionic nerves are adrenergic and utilize the neurotransmitter norepinephrine (NE).³ The effect of NE released at the effector site produces different results (excitation or inhibition) depending on the receptor(s) to which it binds. (Table 2)

There are two major classes of adrenergic (NE-binding) receptors: alpha (α) and beta (β). Organs that respond to NE (or epinephrine, EPI) display one or both types of receptors. In general, NE or epinephrine binding to alpha receptors is stimulatory, while their binding to

beta receptors is inhibitory. However, there are notable exceptions. For example, binding of NE to the beta receptors of cardiac muscle prods the heart into more vigorous activity. These differences reflect that both alpha and beta receptors have two receptor subclasses (alpha 1 and alpha 2, beta 1 and beta 2). Each receptor type tends to predominate in certain target organs (Table 3).

Adrenal medulla

Some preganglionic sympathetic (thoracic splanchnic) nerve fibers pass through the celiac ganglion without synapsing and terminate by synapsing with hormone-producing medullary cells (chromaffin cells) of the adrenal gland. When stimulated by the preganglionic fibers, the chromaffin cells release large quantities of epinephrine and norepinephrine directly into the blood stream. These hormones are then carried to tissues throughout the body where they reinforce the effects of the SyNS.⁴

The epinephrine and norepinephrine released by the combined efforts of the SyNS and the adrenal glands is eventually dissipated either by being taken back into the synaptic nerve endings or by action of the enzyme monoamine oxidase.⁴

Sympathetic and parasympathetic tone

The autonomic system generally maintains a 'tone,' a basal level of activity, which then may be either increased or decreased by central control.⁵ The sympathetic and parasympathetic systems are continually active and the basal rates of stimulation are known, respectively, as sympathetic tone and parasympathetic tone.⁵ The value of tone is that it allows a single nervous system to increase or decrease the activity of an organ. For example, sympathetic tone normally keeps almost all the blood vessels of the body constricted to approximately half their maximum diameter. By increasing the degree of sympathetic stimulation, the vessels can be constricted even more; but, on the other hand, by decreasing the level of sympathetic stimulation, the vessels can be dilated.⁵

Another example of tone is that of the parasympathetics in the gastrointestinal tract.

Surgical removal of the parasympathetic supply to the gut by cutting the vagi can cause serious and prolonged gastric and intestinal atony, thus illustrating that in normal function the parasympathetic tone to the gut is strong. This tone can be decreased by the brain, thereby inhibiting gastrointestinal motility, or it can be increased, thereby promoting increased gastrointestinal activity.⁵ The presence of dual innervation and the possibility of either increasing or decreasing the tone permit a wide range of control.⁵

Conclusion

The art and science of medicine has changed very rapidly over the last 10 years. The high cost of hospital care has created an impetus for surgical technologists to master the knowledge and advanced procedural skills necessary to meet the growing demands of an ever more complex surgical environment. It is my hope this article has provided a useful framework upon which surgical technologists can advance their knowledge and understanding of human physiology as it relates to patient care, thus being better prepared to move into the realm of advanced practice.

References

1. Gyls BA, Wedding, ME. *Medical Terminology, A Systems Approach*. 3ed. Philadelphia: FA Davis Company; 1995: 318.
2. Marieb EN. *Human Anatomy and Physiology*. 2ed. Redwood City, CA: The Benjamin/Cummings Publishing Co, Inc; 1992: 457.
3. Guyton AC. *Human Physiology and Mechanisms of Disease*. 3ed. Philadelphia: WB Saunders Publishing Co; 1982:439.
4. The parasympathetic nervous system. greenfield.fortunecity.com Accessed 8/00
5. Regulation of Visceral Function. In: Selkurt EE, et al. *Physiology* 3ed., Selkurt EE, ed. Boston: Little, Brown and Company; 1971: 179-180.
6. Autonomic Nervous System. *Microsoft Encarta Online Encyclopedia 2000*. Microsoft Corporation. encarta.msn.com Accessed 8/24/00
7. *Dorland's Pocket Medical Dictionary*, 24th ed. Anderson DM, ed. Philadelphia: WB Saunders; 1989.

PART 1

GENERAL PRINCIPLES AND INSTRUMENTATION FOR CRANIAL NEUROSURGERY

ALBERT L. RHOTON, JR., MD

*Editors Note: This is part one of a two-part article.
This section focuses on the procedure; part two will
cover instrumentation in depth.*

*The surgical technologist plays a key role in success-
fully completing a neurosurgical operation. Achiev-
ing a satisfactory operative result depends on the
performance of the surgical technologist and the
whole operative team and a host of details related
to accurate diagnosis and careful operative plan-
ning. Essential to this plan is having a patient and
family members who are well informed about the
contemplated operation and who understand the
associated side effects and risks. The team's most
important ally in achieving a satisfactory postoper-
ative result is a well-informed patient.*

Scheduling in the operating room should include information about the side and site of the pathology and the position of the patient so that the instruments and equipment can be positioned properly before the arrival of the patient (Figure 1A-D). Any unusual equipment needs should be listed at the time of scheduling. There are definite advantages to operating rooms dedicated to neurosurgery and to having the same surgical technologists for neurosurgical cases who know the equipment and procedures.

Before induction, there should be an understanding regarding the need for steroids, hyperosmotic agents, anticonvulsants, antibiotics, barbiturates, intraoperative evoked potential, electroencephalogram or other specialized monitoring, and lumbar or ventriculostomy drainage. Elastic or pneumatic stockings are placed on the patient's lower extremities to prevent venous stagnation and postoperative phlebitis and emboli. A urinary catheter is inserted if the operation is expected to last more than two hours. If the patient is positioned so that the operative site is significantly higher than the right atrium, a Doppler monitor is attached to the chest or inserted in the esophagus, and a venous catheter is passed into the right atrium so that venous air emboli may be detected and treated. At least two intravenous lines are established if significant bleeding is likely to occur.

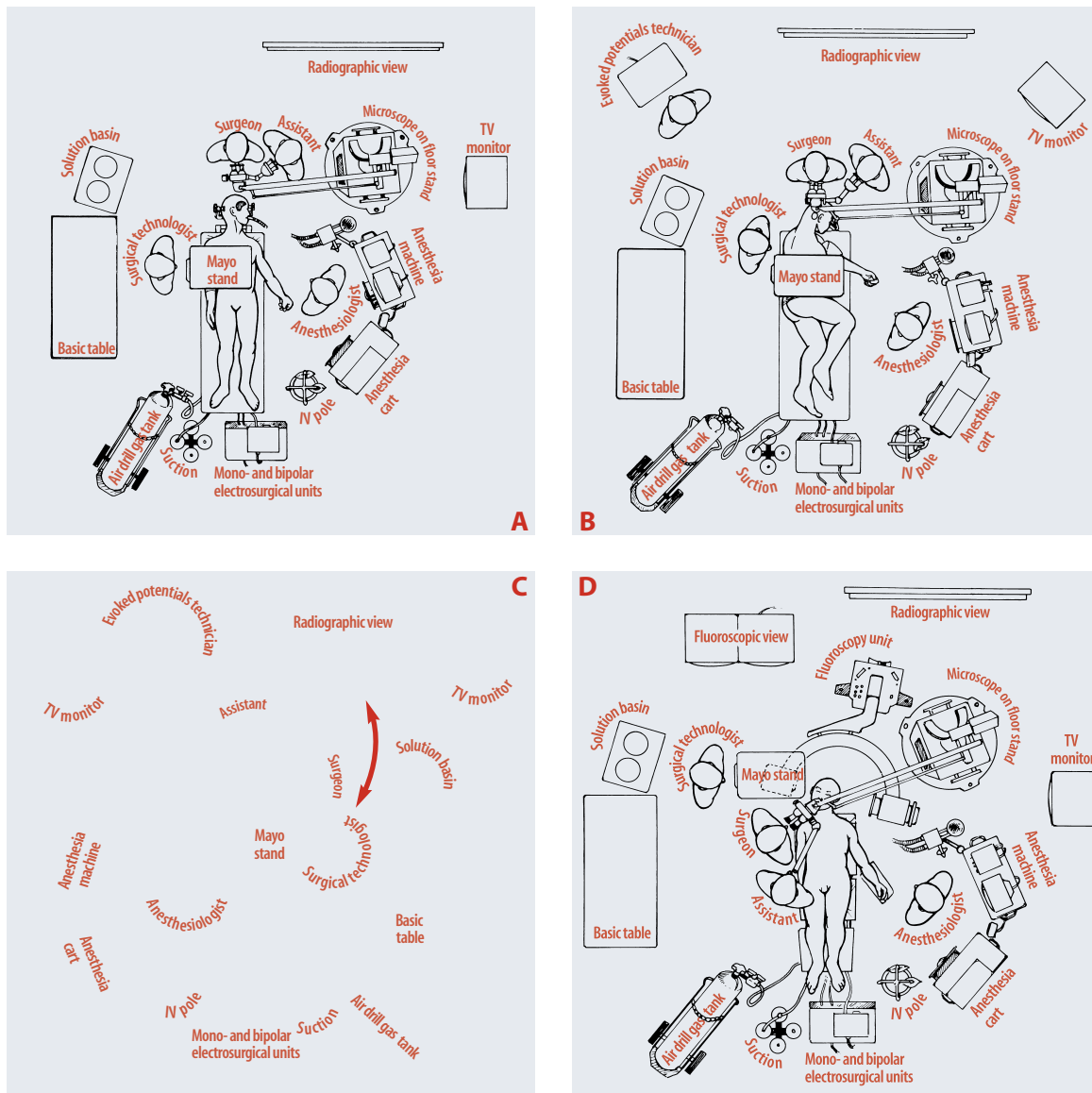
Most intracranial procedures are done with the patient in either the supine or three-quarter prone (lateral oblique or park bench) position, with the surgeon sitting at the head of the table. The supine position, with appropriate turning of the patient's head and neck and possibly elevating one shoulder to rotate the upper torso, is selected for procedures in the frontal, temporal, and anterior parietal areas and for many skull base approaches. The three-quarter prone position with the table tilted to elevate the head is used for exposure of the posterior parietal, occipital and suboccipital areas (Figure 2). Some surgeons still prefer to have the patient in the semi-sitting position for operations in the posterior fossa and cervical region, because the improved venous drainage may reduce bleeding

and because cerebrospinal fluid and blood do not collect in the depth of the exposure. Tilting the table to elevate the head in the lateral oblique position also reduces venous engorgement at the operative site. Extremes of turning of the head and neck which may lead to obstruction of venous drainage from the head, should be avoided. Points of pressure or traction on the patient's body should be examined and protected.

Careful attention in the selection of the position of operating room personnel and equipment ensures greater efficiency and effectiveness. The anesthesiologist is positioned near the head and chest on the side toward which the head is turned to provide easy access to the endotracheal tube and the intravenous and intra-arterial lines, rather than at the foot of the patient, where access to support systems is limited. If the patient is operated on in the supine or three-quarter prone position, the anesthesiologist is positioned on the side toward which the face is turned, and the surgical technologist is positioned at the other side, with the surgeon seated at the head of the patient (ie for a left frontal or frontotemporal approach, the anesthesiologist is positioned on the patient's right side, and the surgical technologist is on the left side).

Greater ease of positioning the operating team around the patient is obtained when instruments are placed on Mayo stands that can be moved around the patient. In the past, large, heavy overhead stands with many instruments were positioned above the body of the patient. The use of Mayo stands, which are lighter and more easily moved, allows the surgical technologist and the instruments to be positioned and repositioned at the optimal site to assist the surgeon. It also allows the flexibility required by the more frequent use of intraoperative fluoroscopy, angiography, and image guidance. The control console for drills, suction, and coagulation is usually positioned at the foot of the operating table, and the tubes and lines are led upward to the operative site.

In the past, it was common to shave the whole head for most intracranial operations, but hair removal now commonly extends only 1.5-2 cm



A Right frontotemporal craniotomy: The anesthesiologist is positioned on the left side of the patient, giving the physician easy access to the airway, monitors on the chest, and the intravenous and intra-arterial lines. The microscope stand is positioned above the anesthesiologist. The Surgical Technologist (ST), positioned on the right side of the patient, passes instruments to the surgeon's right hand. The position is reversed for a right frontotemporal craniotomy, placing the anesthesiologist and microscope on the patient's right side and the ST on the left side. Mayo stands have replaced the large, heavy instrument tables that were positioned above the patient's trunk and restricted access to the patient. The suction, compressed air for the drill, and electro-surgery units are situated at the foot of the patient, and the lines from these units are led up near the Mayo stand so that the ST can pass them to the surgeon as needed. A television monitor is positioned so that the technologist can anticipate the instrument needs of the surgeon.

B Positioning for a right suboccipital craniotomy directed to the upper part of the posterior fossa, such as a decompression operation for trigeminal neuralgia. The anesthesiologist and ST shift sides for an operation on the left side.

C Positioning for a left suboccipital craniotomy for removal of an acoustic neuroma. For removal of a left acoustic tumor, the ST and Mayo stand may move up to shaded area, where instruments can be passed to the surgeon's right hand. For right suboccipital operations or for a midline exposure, the position is reversed, with the ST and Mayo stand positioned above the body of the patient. In each case, the anesthesiologist is positioned on the side toward which the patient faces.

D Positioning for transsphenoidal surgery. The patient's head is rotated slightly to the right to provide the surgeon with a view directly up the patient's nose. The microscope stand is located just outside the C-arm on the fluoroscopy unit. The ST and Mayo stand are positioned near the patient's head above one arm of the fluoroscopy unit.

FIGURE 1

Positioning of staff and equipment in the operating room.

beyond the margin of the incision and in some cases, the hair may be parted without shaving to provide a site for the incision. Care is taken to drape a wide enough area to allow extension of the incision if a larger operative field is needed and allow drains to be led out through stab wounds.

Head fixation devices

A precisely maintained position of the firmly fixed cranium is required. Fixation is best achieved by a pinion head holder in which the essential element is a clamp made to accommodate three relatively sharp pins (Figure 3). When the pins are placed, care should be taken to avoid

a spinal fluid shunt, thin bones such as those that overlie the frontal and mastoid sinuses, and the thick temporalis muscle, where the pins, however tightly the clamp is applied, tends to remain unstable. The pins should be applied well away from the eye or where they would be a hindrance to making the incision. Special shorter pediatric pins are available for thin skulls. The pins should not be placed over the thin skulls of some patients with a history of hydrocephalus.

After the clamp is secured on the head, the final positioning is done, and the head holder is fixed to the operating table. The clamp avoids the skin damage that may occur if the face rests against a padded head support for several hours. The skull clamps do not obscure the face during the operation as do padded headrests, facilitating intraoperative electromyographic monitoring of the facial muscles and monitoring of auditory or somatosensory evoked potentials. Until recently, all the head clamps were constructed of radiopaque metals, but the increasing use of intraoperative fluoroscopy and angiography has prompted the development of head holders constructed of radiolucent materials. The pinion head clamp commonly serves as the site of attachment of the brain retractor system.

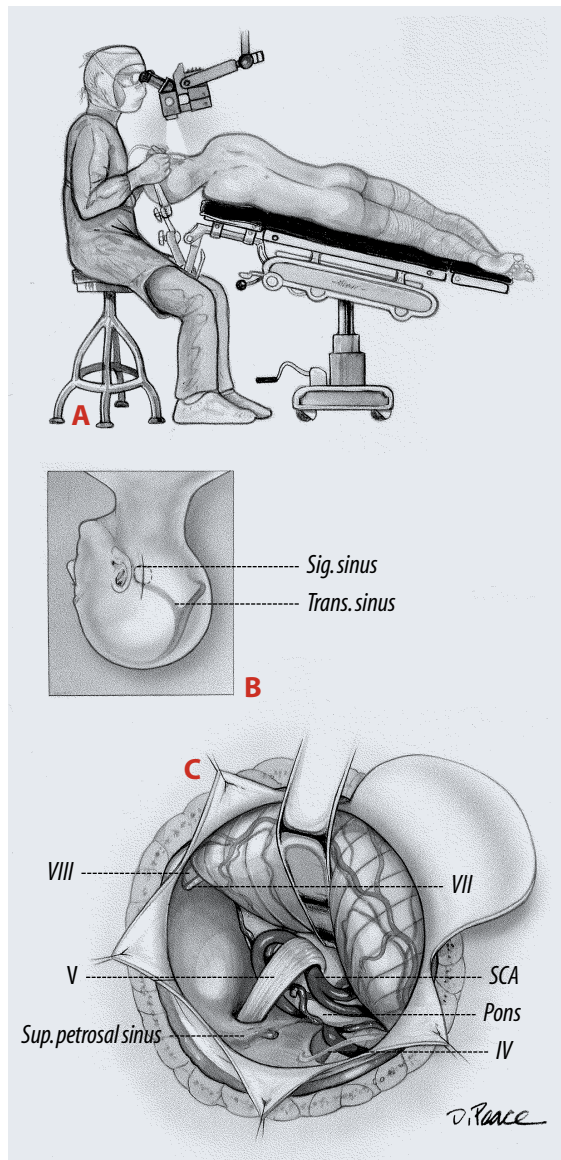


FIGURE 2

Retrosigmoid approach to the trigeminal nerve for a decompression operation.

- a three-quarter prone position (upper left)
- b vertical paramedian suboccipital incision
- c superior cerebellar artery, trochlear (IV), facial (VII), and vestibulocochlear nerves (VIII) exposed

Surgical markers

The surgeon may find it helpful to outline several important landmarks on the scalp prior to applying the drapes. Sites commonly marked include the coronal, sagittal, and lambdoid sutures; the rolandic and Sylvian fissures; and the pterion,inion, asterion, and keyhole (Figure 4). Approximating the site of the Sylvian and rolandic fissures on the scalp begins with noting the position of the nasion,inion, and frontozygomatic point. The nasion is located in the midline at the junction of the nasal and frontal bones at the level of the upper rims of the orbit. The inion is the site of a bony prominence that overlies the torcular and the attachment of the tentorium to the inner table of the skull. The frontozygomatic point is the site of the frontozygomatic suture situated where the frontal bone, which forms the upper margin of the orbit, joins the zygomatic

bone, which forms the lateral margin of the orbit. The frontozygomatic point is located just below the junction of the lateral and superior margins of the orbital rim. It is situated on the orbital rim 2.5 cm above the level where the upper edge of the zygomatic arch joins the orbital rim.

The next step is to construct a line along the sagittal suture and, using a flexible measuring tape, to determine the distance along the mid-sagittal line from the nasion to inion and to mark the midpoint and three-quarter point (50 and 75% points) along the line. The Sylvian fissure is located along a line which extends backward from the frontozygomatic point across the lateral surface of the head to the three-quarter point on the nasion to inion-midsagittal line. The pterion, the site on the temple, approximating the lateral end of the sphenoid ridge, is located 3 cm behind the frontozygomatic point on the Sylvian fissure line.

The Rolandic fissure, which separates the motor and sensory areas of the cerebrum, is located by identifying the upper and lower rolandic points that correspond to the upper and lower ends of the rolandic fissure. The upper Rolandic point is located 2 cm behind the midpoint (50% plus 2 cm point) on the nasion to inion-midsagittal line. The lower Rolandic point is located where a line extending from the midpoint of the upper margin of the zygomatic arch to the upper Rolandic point crosses the line defining the Sylvian fissure. A line connecting the upper and lower Rolandic points approximates the Rolandic fissure. The lower Rolandic point is located approximately 2.5 cm behind the pterion on the Sylvian fissure line.

Another important point is the keyhole, the site of a burr hole, which, if properly placed, has the frontal dura in the depths of its upper half and the orbit in its lower half. The keyhole is located immediately above the frontozygomatic point. It is approximately 3 cm anterior to the pterion, just above the lateral end of the superior orbital rim and under the most anterior point of attachment of the temporalis muscle and fascia to the temporal line. Familiarity with these points

and lines aids placement of a bone flap over the appropriate lobe and intracranial compartment.

Scalp flaps

Scalp flaps should have a broad base and adequate blood supply (Figure 5A). A pedicle that is narrower than the width of the flap may result in the flap edges becoming gangrenous. An effort is made to make scalp incisions so that they are behind the hairline and not on the exposed part of the forehead. A bicoronal incision situated behind the hairline is preferred to extending an incision low on the forehead for a unilateral frontal craniotomy. An attempt is made to avoid the branch of the facial nerve that passes across

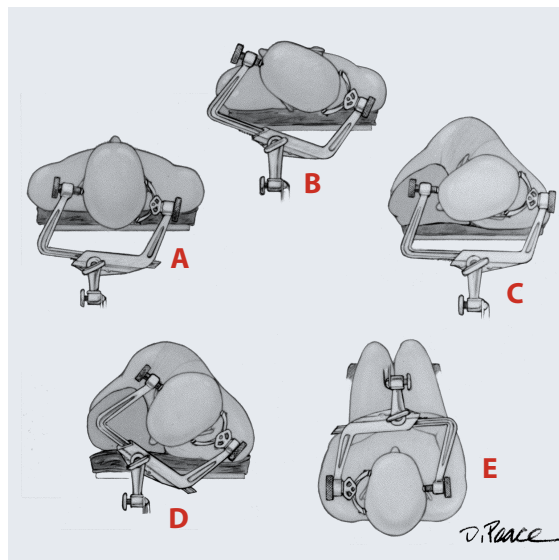


FIGURE 3

Positioning of a pinion head holder for craniotomy.

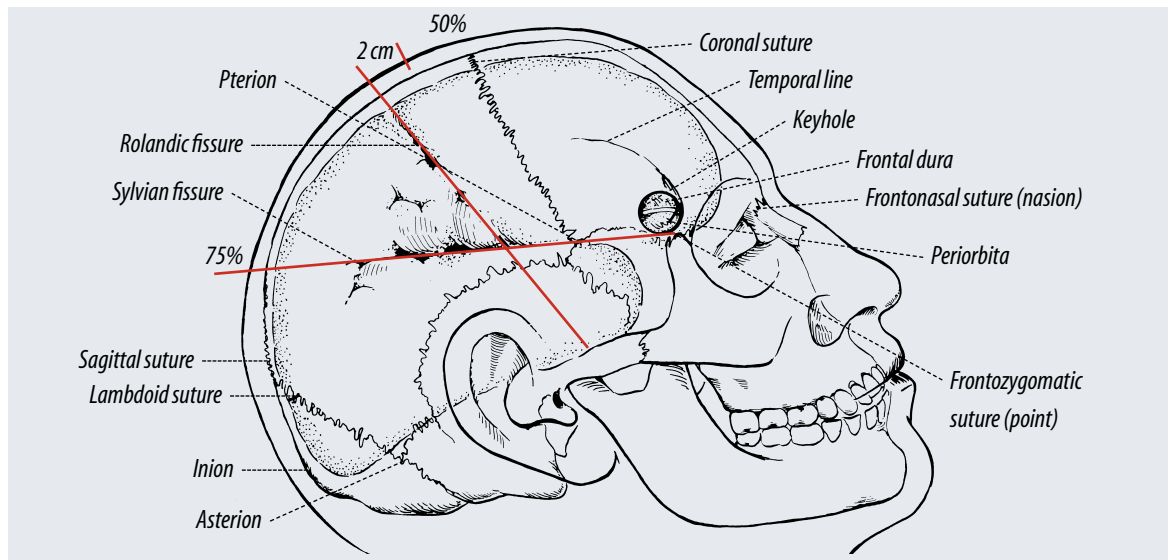
the zygoma to reach the frontalis muscle. Incisions reaching the zygoma more than 1.5 cm anterior to the ear commonly interrupt this nerve unless the layers of the scalp in which it courses are protected. The superficial temporal and occipital arteries should be preserved if there is the possibility that they will be needed for an extracranial to intracranial arterial anastomosis.

In elevating a scalp flap, the pressure of the surgeon's and assistant's fingers against the skin on each side of the incision is usually sufficient to control bleeding until hemostatic clips or clamps are applied. The skin is usually incised with a sharp blade, but the deeper fascial and muscle layers may be incised with cutting electro-surgical

- A** Position for a unilateral or bilateral frontal approach
- B** Position for a pterional or frontotemporal craniotomy
- C** Position for retrosigmoid approach to the cerebellopontine angle
- D** Position for a midline suboccipital approach
- E** Position for a midline suboccipital approach (semi-sitting position)

current. The ground plate on the electrosurgical unit should have a broad base of contact to prevent the skin at the ground plate from being burned. Bipolar coagulation is routinely used to control bleeding from the scalp margins, on the dura, and at intracranial sites. At sites where even gentle bipolar coagulation could result in neural damage, such as around the facial or optic nerves, an attempt is made to control bleeding with a lightly applied gelatinous sponge. Alternatives to gelatinous sponge include oxidized regenerated cellulose, oxidized cellulose, or a microfibrillar collagen hemostat. Venous bleeding can often be controlled with the light application of gelatinous sponge. Metallic clips, often

they extend across an internal bony prominence such as the pterion or across a major venous sinus. The risk of tearing the dura or injuring the brain is reduced by drilling several holes and making shorter cuts. A hole is placed on each side of a venous sinus, and the dura is carefully stripped from the bone, after which the bone cut is completed rather than cutting the bone above the sinus as a part of a long cut around the whole margin of the flap. Bleeding from bone edges is stopped by the application of bone wax. Bone wax is also used to close small openings into the mastoid air cells and other sinuses, but larger openings in the sinuses are closed with other materials, such as fat, muscle, or a pericranial



used on the dura and vessels in the past, are now applied infrequently except on the neck of an aneurysm, because they interfere with the quality of the CT and MRI scan and, if utilized, should be made of nonmagnetic materials.

In the past, bone flaps were often elevated using a series of burr holes, made with a manual or motor driven trephine, that were connected with a Gigli saw. Today, high speed drills are used to place burr holes and cut the margins of a bone flap (Figure 5B). Commonly, a hole is prepared using a burr on a high-speed drill and a tool with a footplate to protect the dura cuts around the margins of the flap (Figures 5C and D). Extremely long bone cuts should be avoided, especially if

graft, sometimes used in conjunction with a thin plate of methylmethacrylate or bone substitute.

After elevating the bone flap, it is common practice to tack the dura up to the bony margin with a few 3-0 black silk sutures brought through the dura and then through small drill holes in the margin of the cranial opening (Figure 5E). If the bone flap is large, the dura is also “snuggled up” to the intracranial side of the bone flap with the use of a suture brought through drill holes in the central part of the flap. Care is taken to avoid placing drill holes for tack-up sutures that might extend into the frontal sinus or mastoid air cells. Tack-up sutures are more commonly used for dura over the cerebral hemispheres than

FIGURE 4

Sites commonly marked on the scalp before applying drapes.

over the cerebellum. If the brain is pressed tightly against the dura, the tack-up sutures are placed after dealing with the intradural pathology when the brain is relaxed and the sutures can be placed with direct vision of the deep surface of the dura. Tack-up sutures can also be led through adjacent muscles or pericranium rather than a hole in the margin of the brain.

In the past, there was a tendency for bone flaps to be elevated and replaced over the cerebral hemispheres and for exposures in the suboccipital region to be done as craniectomies without replacement of the bone. Laterally placed suboccipital exposures are now commonly done as craniotomies with replacement of the bone flaps. Midline suboccipital operations are more commonly done as craniectomies, especially if decompression at the foramen magnum is needed, because this area is protected by a greater thickness of overlying muscles.

Bone flaps may be held in place with sutures brought through drill holes in the flap margin, but nonmagnetic metallic plates are used if sutures passed through the edge of the flap and adjacent bony margins might result in cosmetic deformity due to inward settling of the flap. Holes in the bone are commonly filled with methylmethacrylate or bone substitute, which are allowed to harden in place before closing the scalp or covered with small nonmagnetic plates (Figure 5F).

The dura is closed with 3-0 silk interrupted or running sutures. Small bits of fat or muscle may be sutured over small dural openings caused by shrinkage of the dura. Larger dural defects are closed with pen cranium or temporalis fascia taken from the operative site or with sterilized cadaveric dura or fascia lata, or other approved dural substitutes. The deep muscles and fascia are commonly closed with 1-0, the temporalis muscle and fascia with 2-0, and the galea with 3-0 synthetic absorbable suture. The scalp is usually closed with metallic staples, except at sites where some 3-0 or 5-0 nylon reinforcing sutures may be needed. Skin staples are associated with less tissue reaction than other forms of closure.

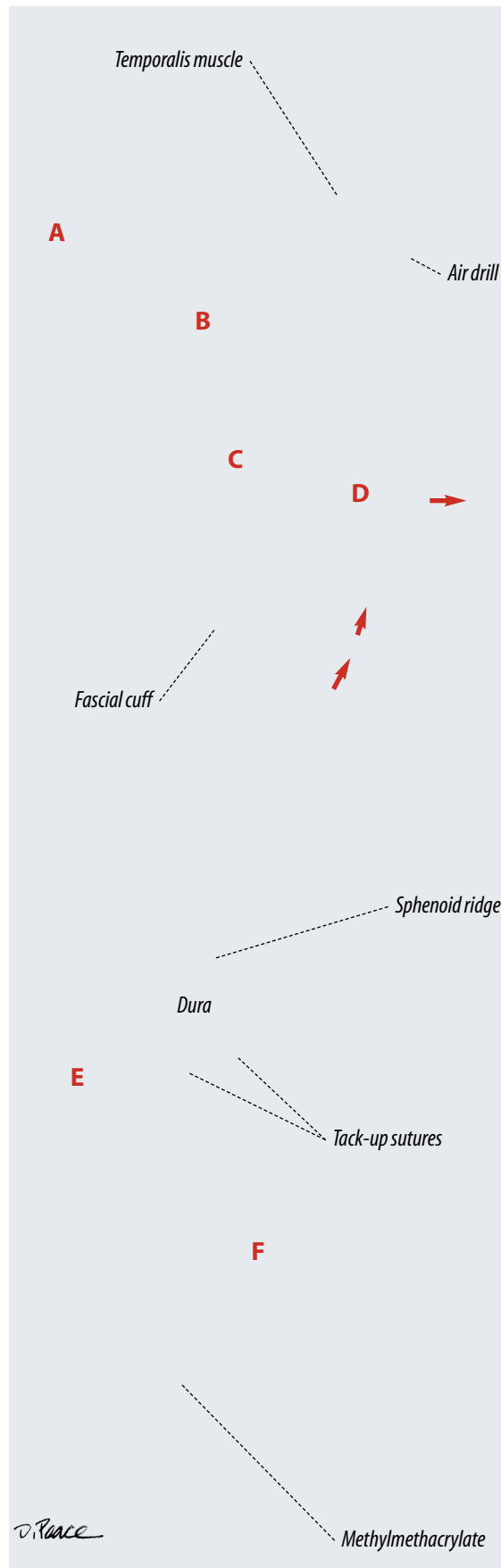


FIGURE 5

Technique of craniotomy using a high-speed air drill.

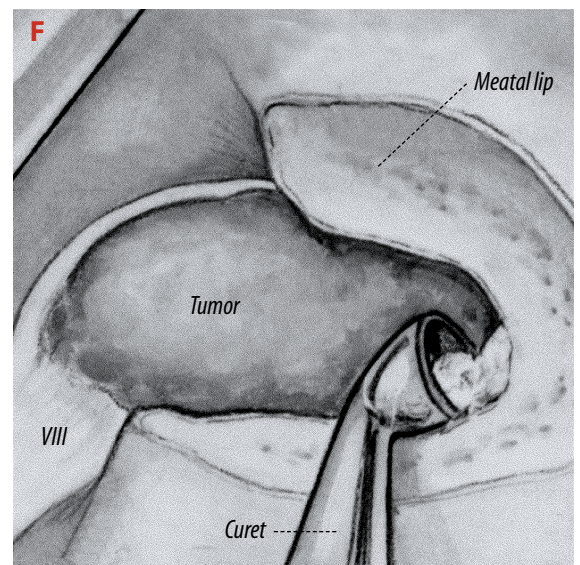
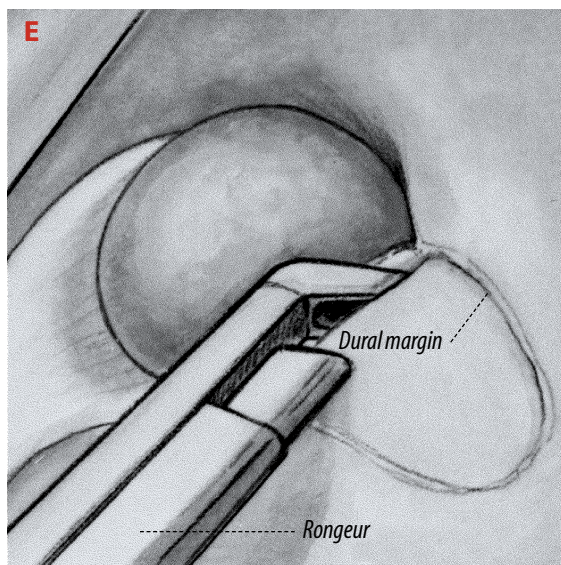
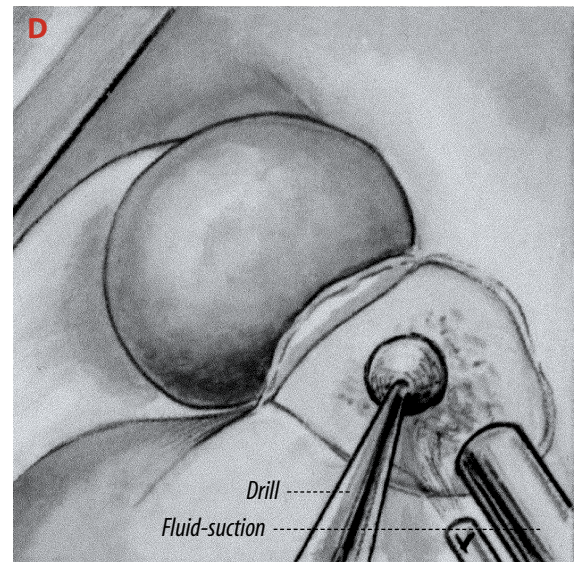
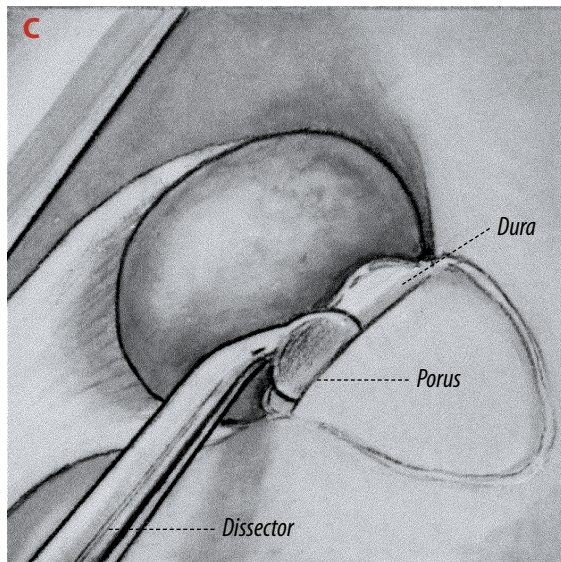
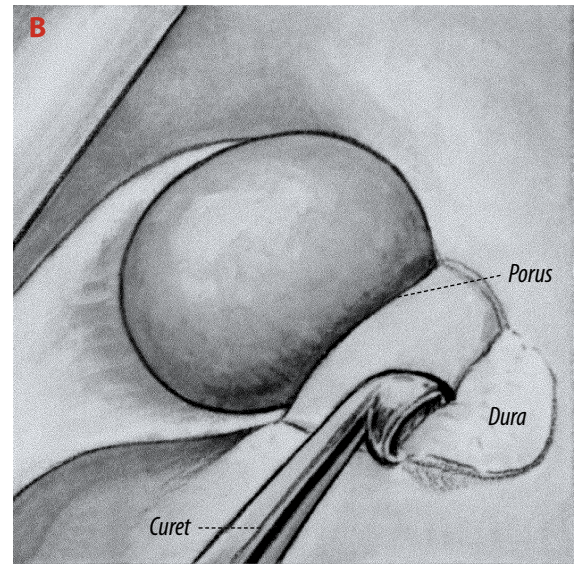
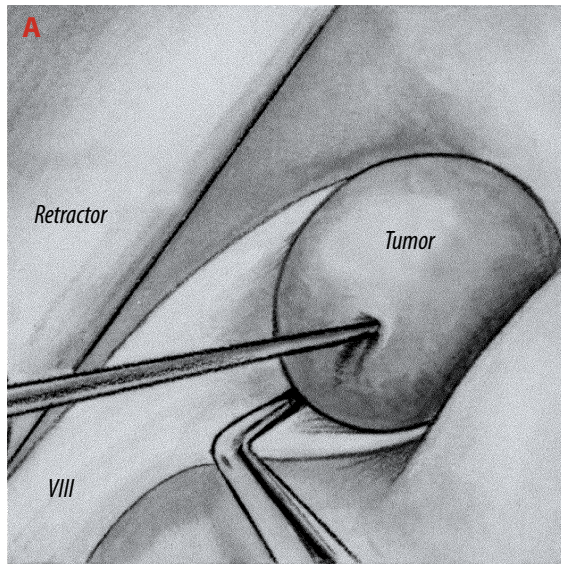
- a** A right frontotemporal scalp flap and free bone flap are outlined.
- b** The scalp flap has been reflected forward and the temporalis muscle downward. The high-speed drill prepares holes along the margin of the bone flap (interrupted line).
- c** A narrow tool with a foot plate to protect the dura connects the holes.
- d** Cross-sectional view of the cutting tool to show how the foot plate strips the dura away from the bone.
- e** The high-speed drill removes the lateral part of the sphenoid ridge. A drill bit makes holes in the bone edge for tack-up sutures to hold the dura against the bony margin.
- f** The bone flap is held in place with either silk sutures or nonmagnetic plates. Some methylmethacrylate or bone substitute is molded into the burr holes to give a firm cosmetic closure.

FIGURE 6

Microinstruments used in the cerebellopontine angle.

This illustration was prepared from 16-mm movie frames taken at the time of removal of an acoustic neuroma in the right cerebellopontine angle. This operation resulted in preservation of the facial, acoustic, and vestibular nerves.

- a** The brain retractor on the left gently elevates the cerebellum to expose the tumor. Small, pointed instruments called needles separate the tumor from the eighth nerve (VIII). The straight needle retracts the tumor, and the 45-degree needle develops a cleavage plane between the tumor and the nerve. The facial nerve is hidden in front of the vestibulo-cochlear nerve.
- b** The microcuret with a 1.5-mm cup strips dura mater from the posterior wall of the meatus.
- c** The 1.0-mm round dissector separates dura from the bone at the pores and within the meatus.
- d** A drill is used to remove the posterior wall of the meatus. Suction irrigation cools and removes bone dust.
- e** Alternative method of removal of the posterior wall after it has been thinned by a drill using a Kerrison microrongeur with a 1 mm-wide bite.
- f** The microcuret with a 1.5-mm cup removes the last bit of bone from the posterior meatal wall.

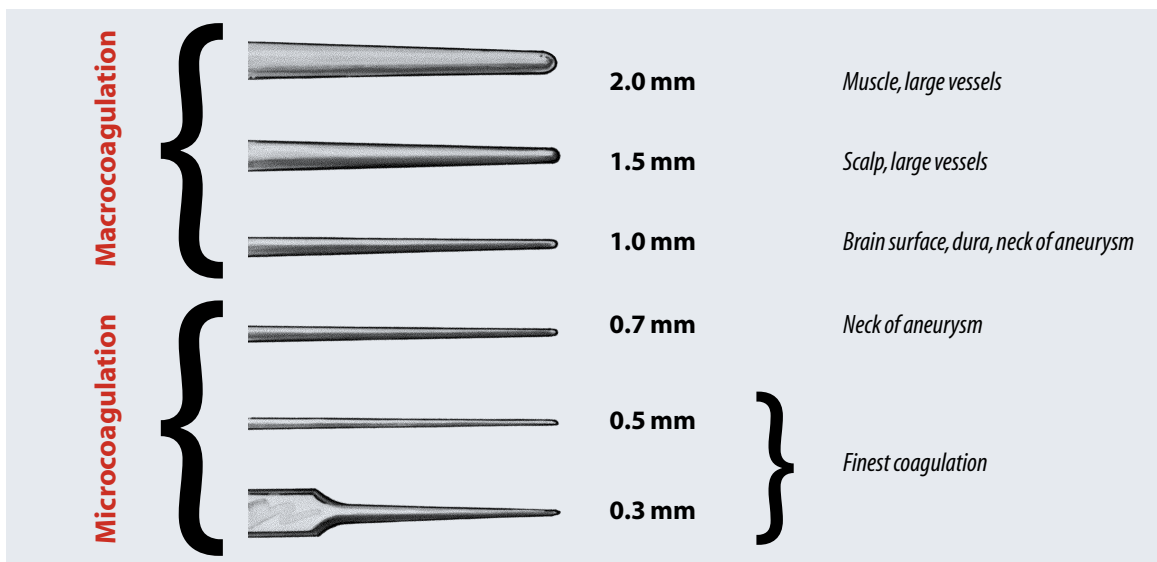


Drills

High-speed drills are commonly used in neurosurgery as a replacement for the trephine and Gigli saw and for removal of thick plates of bone, traditionally removed with rongeurs that require great strength if the bone is especially hard and thick. Drills reduce the thickness of such bone so that it can be easily removed without the use of great force. A drill typically is used during operations in the posterior fossa for removing the anterior clinoid process, the wall of the internal acoustic canal, part of the mastoid, or protrusions of the cranial base (Figure 5D and E). Cutting burs are suitable for removal of thick bone in non-critical areas but diamond coated

burr. A large burr is used when possible. The greatest accuracy and control of the drill are obtained at higher speeds if a light brush action is used to remove the bone. Dangerous skidding may ensue at lower speeds because greater pressure is needed to cut the bone. Accidental running of the burr across bone is avoided by using light, intermittent pressure rather than constant pressure of the burr on one spot.

Overheating near nerves may damage them. Constant irrigation with physiological saline reduces heat transmission to nearby neural structures. The field may also be irrigated by the use of a suction-irrigation system. The teeth of the burr are kept clean of bone dust. A coarse burr that clogs



burs are used for the most delicate drilling in close proximity to critical structures. After a drill has reduced the thickness of an area, such as the posterior lip of the internal acoustic meatus, a Kerrison microrongeur with a 1 mm lip or a microcuret may be used to remove the remaining thin layer of bone.

The operation should be planned, if possible, so that the burr rotates away from critical structures so that if skidding occurs, it will be away from these areas. The surgeon and the surgical technologist should be trained in the application of the drill before using it in a neurosurgical operation.

The drill is held like a pen. Cutting is done with the side rather than with the end of the

less easily is harder to control and runs across bone more easily, but this is reduced with irrigation.

A burr should not be used to blindly make a long, deep hole, but rather the hole should be beveled and as wide open as possible. A small curet may be used to follow a small track rather than pursuing it with a drill. Bone dust should be meticulously removed because of its potent osteogenic properties.

Bipolar coagulation

The bipolar electrocoagulator has become fundamental to neurosurgery because it allows accurate, fine coagulation of small vessels, minimizing dangerous spread of current to adjacent

FIGURE 7

Forceps tips

needed for

macrocoagula-

tion and micro-

coagulation.

neural and vascular structures (Figure 7).^{2,3} It allows coagulation in areas where unipolar coagulation would be hazardous, such as near the cranial nerves, brain stem, cerebellar arteries, and fourth ventricle.

When the electrode tips touch each other, the current is short-circuited, and no coagulation occurs. There should be enough tension in the handle of the forceps to allow the surgeon to control the distance between the tips, because no coagulation occurs if the tips touch or are too far apart. Some types of forceps, attractive for their delicacy, compress with so little pressure that a surgeon cannot avoid closing them during coagulation, even with a delicate grasp. The

fluid through a long tube in the shaft of the forceps to the tip with each coagulation (Figure 8). To avoid sticking after coagulation, the points of the forceps should be cleaned after each application to the tissue. If charred blood coats the tips, it should be removed with a damp cloth rather than by scraping with a scalpel blade, because the blade may scratch the tips and make them more adherent to tissue during coagulation. The tips of the forceps should be polished if they become pitted and rough after long use.

Conclusion

The surgical technologist plays a pivotal role in smoothly and successfully completing a neuro-

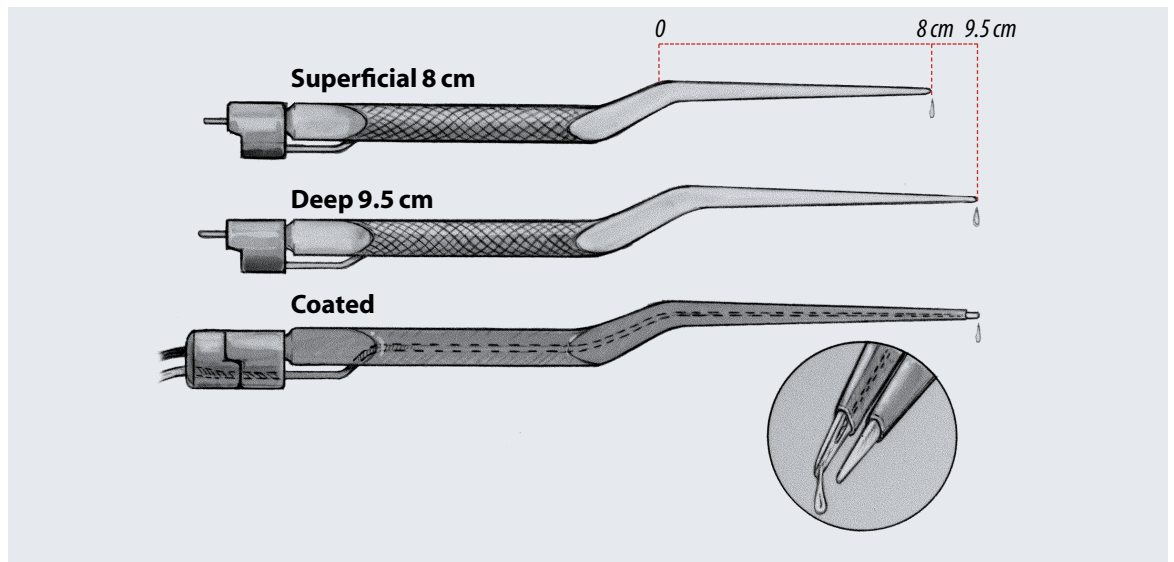


FIGURE 8

Rhoton irrigating bipolar forceps. A small amount of fluid is dispensed at the tip of the forceps with each coagulation.

cable connecting the bipolar unit and the coagulation forceps should not be excessively long, because longer cables can cause an irregular supply of current.

Surgeons with experience in conventional coagulation are conditioned to require maximal dryness at the surface of application, but with bipolar coagulation, some moistness is preferable. Coagulation occurs even if the tips are immersed in saline, and keeping the tissue moist with local cerebrospinal fluid or saline irrigation during coagulation reduces heating and minimizes drying and sticking of tissue to the forceps. Fine irrigation units and forceps have been developed that dispense a small amount of

surgical procedure. With careful operative planning and experience, they are often able to anticipate what the surgeon's needs are before the surgeon realizes what is needed. The cooperative application of the principles outlined in this paper will increase the sense of well being of the operative team and improved outcome for the patient.

About the author

Albert L Rhoton, Jr attended Washington University Medical School where he graduated with the highest academic standing in the class of 1959. He completed his internship at Columbia Presbyterian Medical Center in New York City and returned to Washington University in St

Louis for his neurosurgical training. After completing residency training in 1965, he joined the staff of the Mayo Clinic in Rochester, Minnesota, where he served as a staff neurosurgeon until 1972 when he became the professor and chairman of the Department of Neurological Surgery at the University of Florida. Rhoton has served as president of the American Association of Neurological Surgeons, the Congress of Neurological Surgeons, the Society of Neurological Surgeons, the North American Skull Base Society, the Interdisciplinary Congress on Craniofacial and Skull Base Surgery, the Florida Neurosurgical Society, and the International Society for Neurosurgical Technology and Instrument Invention. In 1998 he was the recipient of the Cushing medal, the highest honor granted by the American Association of Neurological Surgeons. He has published more than 250 scientific papers and one book, and has served on the Editorial Boards of six different surgical journals.

References

1. Greenberg IM. Self-retaining retractor and handrest system for neurosurgery. *Neurosurgery* 8:205, 1981.
2. Greenwood J. Two point coagulation. A new principle and instrument for applying coagulation current in neurosurgery. *Amer J Surg* 50:267, 1940.
3. Malis LL. Bipolar coagulation in microsurgery. In Yasargil MG, ed. *Microsurgery Applied to Neurosurgery*. New York: Academic Press, 1969, 41-45.
4. Rhoton AL Jr. General and Micro-operative Techniques. In: Youmans JR, ed. *Neurological Surgery*. Vol. 1. Philadelphia: WB Saunders Co. 1996, 724-766.
5. Rhoton AL Jr. Anatomic Foundations of Aneurysm Surgery. *Clin Neurosurg* 41:289, 1994.
6. Rhoton AL Jr. Instrumentation. In Apuzzo MJL, ed. *Brain Surgery: Complication, Avoidance and Management*, Vol. 2. New York: Churchill-Livingstone, 1993, 1647-1670.
7. Rhoton AL Jr. Microsurgery of the internal acoustic meatus. *Surg Neurol* 2:311, 1974.
8. Rhoton AL Jr. Microsurgical Anatomy of Decompression Operations on the Trigeminal Nerve. In Rovit RL, ed. *Trigeminal Neuralgia*, Baltimore: Williams & Wilkins, 1990, 165-200.
9. Rhoton AL Jr. Ring curets for transsphenoidal pituitary operations. *Surg Neurol* 18:28, 1982.
10. Rhoton AL Jr, Merz W. Suction tubes for conventional or microscopic neurosurgery. *Surg Neurol* 15:120, 1981.
11. Rizzoli H. Personal communication.
12. Yasargil MG. Suturing techniques. In Yasargil MG, ed. *Microsurgery Applied to Neurosurgery*. New York: Academic Press, 1969, 87-124.
13. Yasargil MG. Suture material. In Yasargil MG, ed. *Microsurgery Applied to Neurosurgery*. New York: Academic Press, 1969, 55.
14. Yasargil MG, Vise WM, Bader DCH. Technical adjuncts in neurosurgery. *Surg Neurol* 8:331, 1977.

Figures 1, 3, 4, 5, 7 and 8 from Rhoton AL Jr. General and Micro-operative Techniques. In: Youmans JR, ed. *Neurological Surgery*. Vol. 1. Philadelphia: WB Saunders Co; 1996: 724-766. Used with permission of WB Saunders © 2001. Figure 2 from Rhoton AL Jr. Microsurgical Anatomy of Decompression Operations on the Trigeminal Nerve. In: Rovit RL, ed. *Trigeminal Neuralgia*. Baltimore: Williams & Wilkins; 1990: 165-200. Used with permission of Lippincott Williams & Wilkins © 2001. Figure 6 taken from Rhoton AL, Jr. Microsurgical Removal of Acoustic Neuromas. *Surg Neurol* 2:211, 1976:213-214, used with permission of Elsevier Science © 2001.

PART 2

GENERAL PRINCIPLES AND INSTRUMENTATION FOR CRANIAL NEUROSURGERY

ALBERT L RHOTON, JR, MD

Optimizing operative results requires the careful selection of instruments for the macro-operative portion of the operation done with the naked eye and the micro-operative part done with the eye aided by the operating microscope.^{4,6} In the past, surgeons commonly used one set of instruments for performing conventional macro-surgery with the naked eye and another set with different handles and smaller tips for microsurgery done with the

eye aided by the microscope. A trend is to select instruments having uniform handles and tactile characteristics for macrosurgery and microsurgery and to change only the size of the tip of the instrument, depending on whether the use is to be macro-operative or micro-operative. For example, forceps for macrosurgery have grasping tips as large as 2 to 3 mm, and those for microsurgery commonly having tips measuring 0.3 to 1.0 mm.

f possible, the instruments should be held in a pencil grip between the thumb and the index finger rather than in a pistol grip with the whole hand (Figure 1). The pencil grip permits the instruments to be positioned by delicate movements of the fingers, but the pistol grip requires that the instruments be manipulated with the more coarse movements of the wrist, elbow and shoulder.

The author prefers round-handle forceps, scissors and needle holders, because they allow finer movement. It is possible to rotate these instruments between the thumb and forefinger rather than having to rotate the entire wrist (Figure 2). The author first used round-handled needle holders and scissors in performing superficial temporal-to-middle cerebral artery anastomosis and later found that the advantage of being able to rotate the instrument between the thumb and the fingers also improved the accuracy of other straight and bayonet instruments used for dissection, grasping, cutting, and coagulation. Round-handled straight and bayonet forceps may be used for both macrosurgery and microsurgery.

The addition of straight round-handled forceps with teeth, called tissue forceps, increases the use of the set of instruments with round handles to include grasping muscle, skin, and dura. A tissue forceps with large teeth is used on the scalp and muscle, and ones with small teeth are used on dura. The addition of round-handle for-

ceps, called dressing forceps, which have fine serrations inside the tips, makes the set suitable for grasping arterial walls for endarterectomy and arterial suturing.

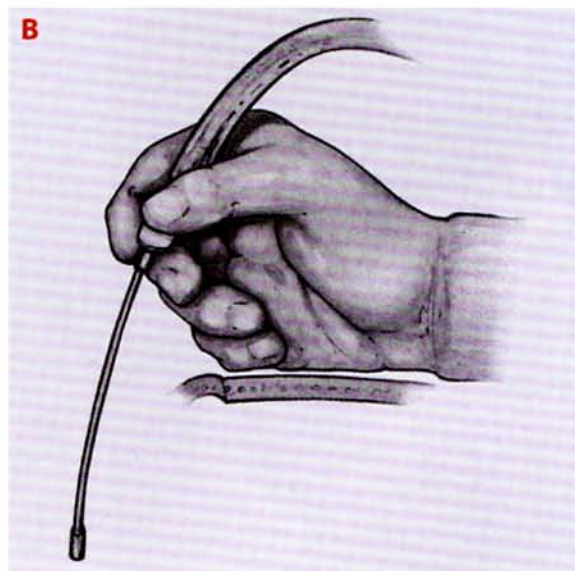
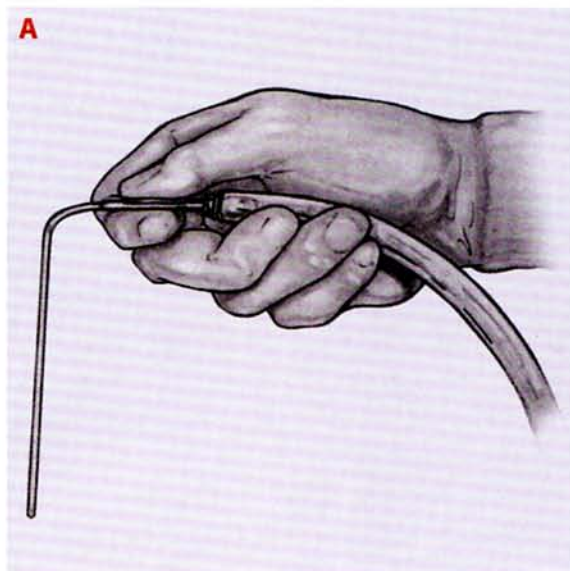
The instruments should have a dull finish, because the brilliant light from highly polished instruments reflected back through the microscope can interfere with the surgeon's vision and detract from the quality of photographs taken through the microscope. Sharpness and sterilization are not affected by the dull finish.

The separation between the instrument tips should be wide enough to allow them to straddle the tissue, the needle, or the thread to cut or grasp it accurately. The excessive opening and closing movements required for widely separated tips reduce the functional accuracy of the instrument during delicate manipulation under high-power magnification. The finger pressure required to bring widely separated tips together against firm-spring tension often initiates a fine tremor and inaccurate movement. Micro-operative tissue forceps should have a tip separation of no more than 8 mm; microneedle holder tips should open no more than 3 mm. Microscissors tips should open no less than 2 mm and no more than 5 mm, depending on the length of the blade and the use of the scissors.

The length of the instruments should be adequate for the particular task that is being contemplated (Figure 3). Bayonet instruments (eg,

FIGURE 1

The two most common grips for holding a surgical instrument. The grip is determined largely by the design of the instrument.



A pistol grip

B pencil grip

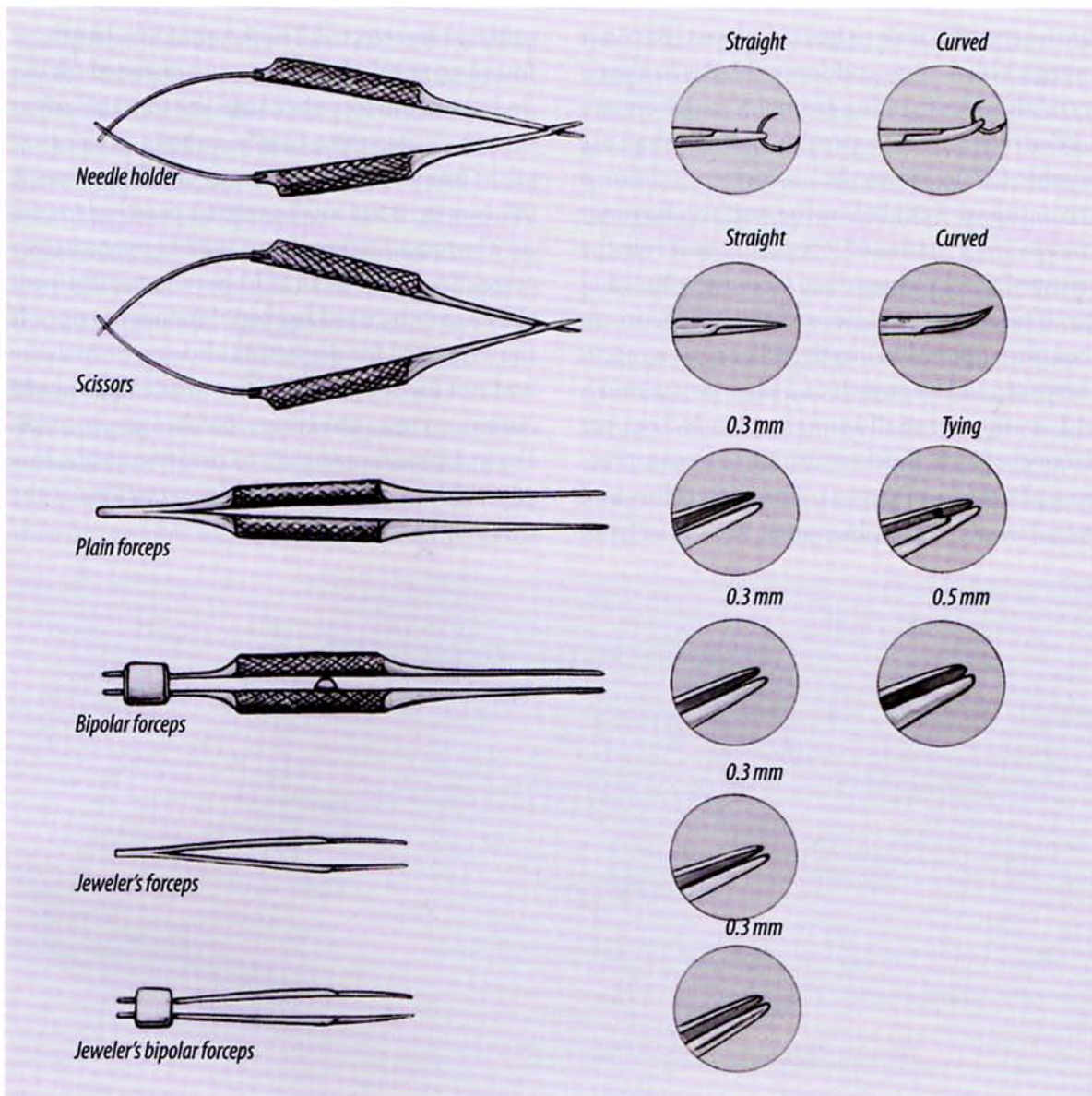


FIGURE 2

Straight Rhoton instruments with round handles and fine tips for use at the

forceps, needle holders, scissors) should be available in at least the three lengths needed for the hand to be rested while the surgeon operates at superficial, deep, and extra deep sites.

Bayonet forceps

Bayonet forceps are standard neurosurgical instruments. The bayonet forceps should be properly balanced so that when its handle rests on the web between the thumb and index finger and across the radial side of the middle finger, it remains there without falling forward when the grasp of the index finger and thumb is released. Poor balance prevents the delicate grasp needed for micro-operative procedures.

It is preferable to test forceps for tension and tactile qualities by holding them in the gloved rather than the naked hand. Forceps resistance to closure that is perceived as adequate in the naked hand may become almost imperceptible in the gloved hand. The forceps may be used to develop tissue planes by inserting the closed forceps between the structures to be separated and releasing the tension, so that the blades open and separate the structures. This form of dissection requires greater tension in the handles than is found in some delicate forceps.

In selecting bayonet forceps, one should consider the length of the blades needed to reach the operative site and the size of the tip needed

surface of the brain suitable for micro-operative procedures, such as an extra-cranial-to-intracranial arterial anastomosis.

for the specific task to be completed. Bayonet forceps with 8-, 9.5- and 11-cm blades in a variety of tip sizes ranging from 0.5 to 2.0 cm are needed. Bayonet forceps with an 8-cm shaft are suitable for use on the brain surface and down to a depth of 2 cm below the surface. Bayonet forceps with blades of 9.5 cm are suitable for manipulating tissues deep under the brain at the level of the circle of Willis (eg, in an aneurysm operation), in the sellar region (eg, in a transcranial approach to a pituitary tumor), and in the cerebellopontine angle (eg, for removal of an acoustic neuroma or decompression of a cranial nerve). For dissection and coagulation in extra deep sites, such as in front

mm tips are selected. The 0.3-mm tips, like those found on jeweler's forceps, are not suited for use on bayonet forceps because the fine tips often scissor rather than firmly oppose each other when prepared in the bayonet configuration. A 0.5-mm tip is the smallest that is practical for use on a bayonet forceps that is used in the posterior fossa. The forceps should have smooth tips if they are to be used for bipolar coagulation. If they are used for dissecting and grasping tissue and not for coagulation, the inside tips should have fine cross-serrations like dressing forceps. For grasping large pieces of tumor capsule, forceps with small rings with fine serrations at the tips may be used.

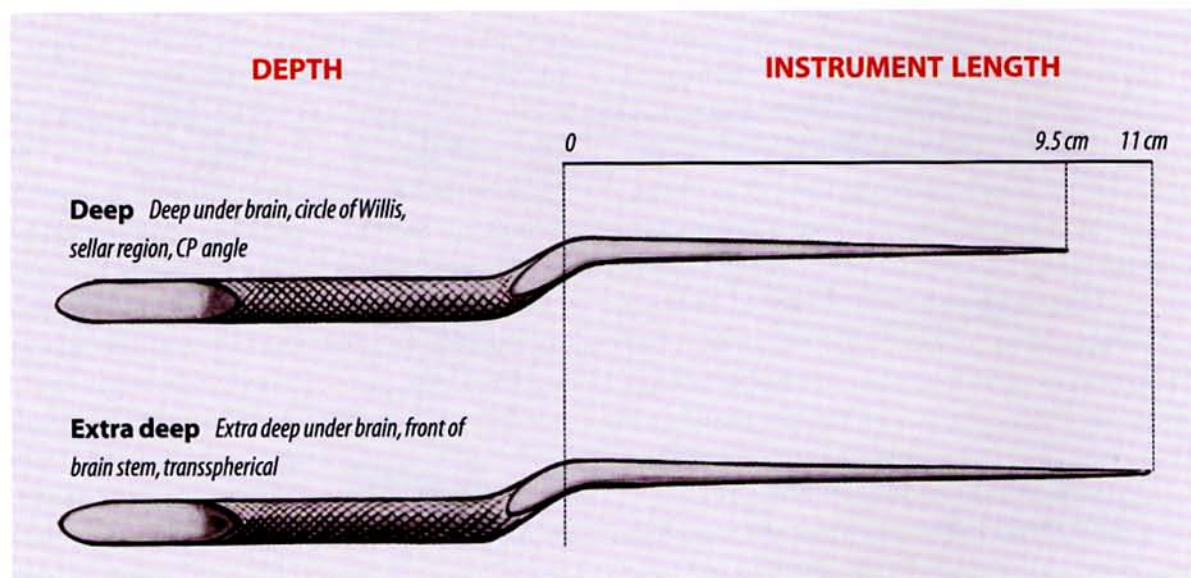


FIGURE 3

Rhoton dissecting bayonets with fine (0.5

cm) tips for use at deep and extra deep sites.

Fine cross-serrations inside the tips aid in grasping and manipulating tissue.

of the brain stem or in the depths of a transsphenoidal exposure, forceps having blades of 11 cm are used. Some surgeons prefer that the forceps be coated with an insulating material to ensure that the current is delivered to the tips, but the coating should not be so thick that it obstructs the view of the tissue being grasped when operating under the microscope.

A series of bipolar bayonet forceps having tips of 0.3 to 2.0 mm will allow coagulation of a vessel of almost any size encountered in neurosurgery. For coagulating larger structures, tips with widths of 1.5 and 2 mm are needed. For microcoagulation, forceps with 1.0-, 0.7-, or 0.5-

Scissors

Scissors with fine blades on straight and bayonet handles are frequently used in micro-operative procedures. Cutting should be done by the distal half of the blade. If the scissors open too widely, cutting ability and accuracy suffer. Delicate cutting near the surface, such as opening an artery for anastomosis or embolectomy, should be done with straight, not bayonet, scissors with fine blades approximately 5 mm long that open approximately 3 mm. Only delicate suture material and tissue should be cut with such small blades. Bayonet scissors with an 8-cm shaft and curved or straight blades are selected for areas 3 to 4 cm below the cranial surface. Bayonet scis-

sors with a 9.5-cm shaft are selected for deep areas, such as the cerebellopontine angle or suprasellar region. The blades should be 14 mm long and should open approximately 4 mm. For extra deep sites, such as in front of the brain stem, the scissors should have an 11-cm shaft. Scissors on an alligator-type shank with a long shaft are selected for deep, narrow openings, as in transsphenoidal operations (Figure 4).

Dissectors

The most widely used neurosurgical macrodissectors are of the Penfield or Freer types; however, the size and weight of these instruments make them unsuitable for microdissection around the

use the straight and angle, pointed instruments located in the 11 and 12 position, that the author calls needled dissectors.⁷ It may be difficult to grasp the margin of the tumor with forceps; however, a small needle dissector introduced into its margin may be helpful in retracting the tumor in the desired direction. This type of pointed instrument can also be used to develop a cleavage plane between tumor and arachnoid membrane, nerves, and brain. Spatula dissectors similar to, but smaller than, the No 4 Penfield dissector, located in the 6, 7, and 8 position, are helpful in defining the neck of an aneurysm and in separating the neck from the adjacent perforating arteries. The 40°-angled

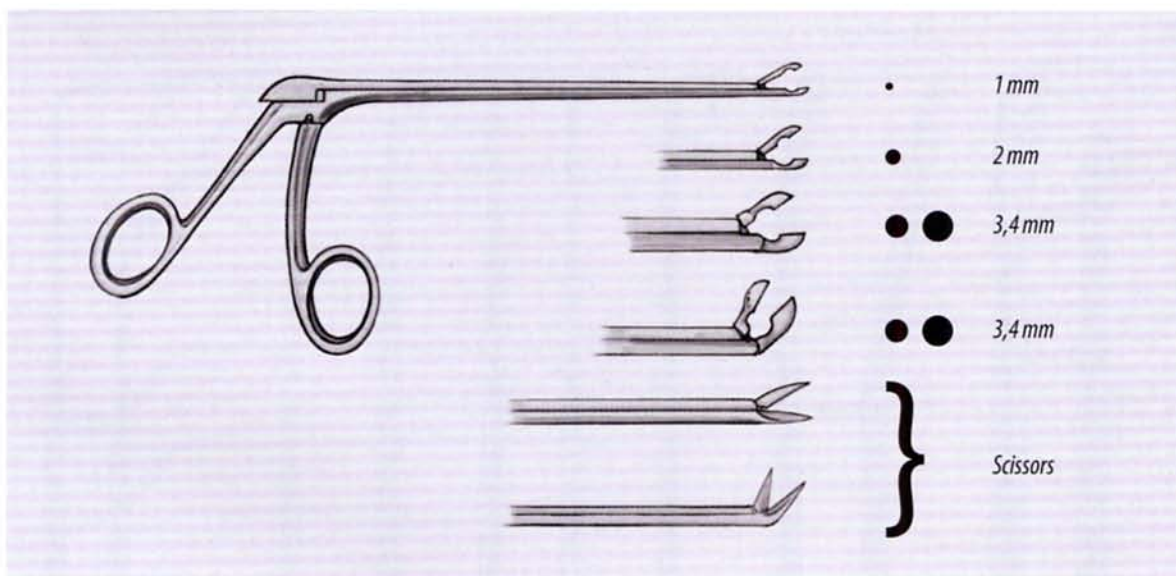


FIGURE 4

Straight and angled alligator cup forceps and scissors are needed in deep, narrow exposures, as in the depths of a transsphenoidal operation.

cranial nerves, brain stem, and intracranial vessels. The smallest Penfield dissector, the No 4, has a width of 3 mm. For microsurgery, dissectors with 1- and 2-mm tips, such as those on the Rhoton dissectors, are needed (Figure 5). Straight, rather than bayonet, dissectors are preferred for most intracranial operations, because rotating the handles of the straight dissector does not alter the position of the tip, but rotating the handle of a bayonet dissector causes the tip to move through a wide arc.

Round-tipped dissectors, called canal knives, in the number 1, 2, and 3 position in the Rhoton set, are used for separation of tumor from nerve. An alternative method of fine dissection is to

teardrop dissectors at the 16 and 17 position are especially helpful in defining the neck of an aneurysm and in separating arteries from nerves during vascular decompression operations, because the tip slides easily in and out of tight areas without inadvertently avulsing perforating arteries or catching on delicate tissue.^{5,8}

Any vessel that stands above the surface of an encapsulated tumor, such as an acoustic neuroma or meningioma, should be dealt with initially as if it were a brain vessel that runs over the tumor surface and can be preserved with accurate dissection. The surgeon should try to displace the vessel and adjacent tissue off the tumor capsule toward the adjacent

Table 1 Uses for suction tubes

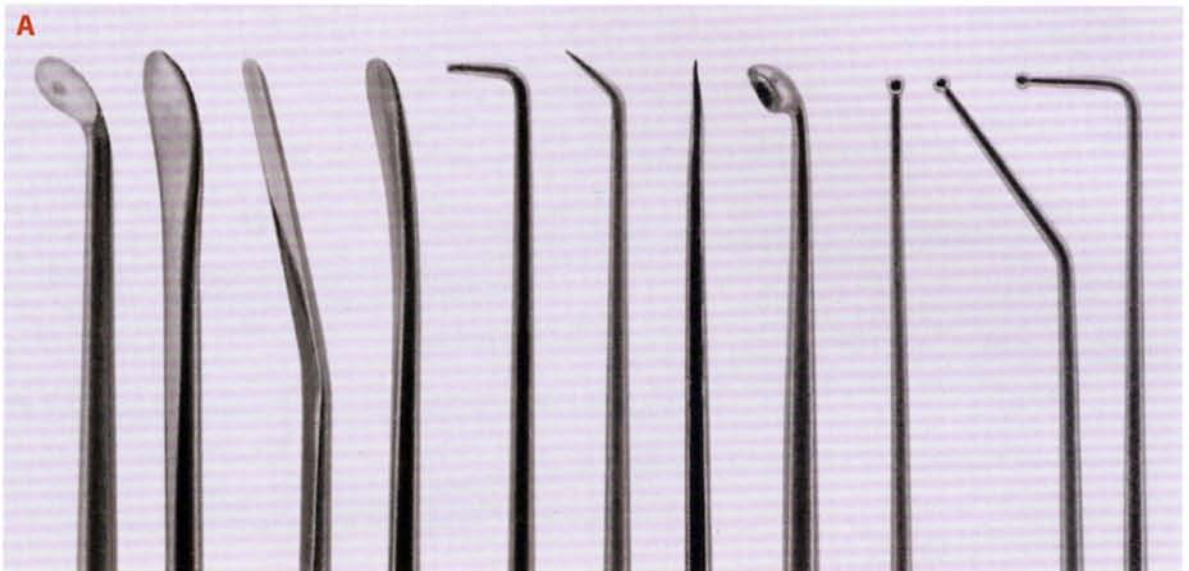
Diameter*	Use
3 French	Smallest nerves, vessel anastomosis
5 French	Aneurysm neck, pituitary gland, medium nerves
7 French	Microsurgical resection of larger tumors
10-12 French	Heavy bleeding, bone dust, flap elevation

*3 French = 1 mm outer diameter

neural tissues by using a small dissector after the tumor has been removed from within the capsule. Vessels that initially appear to be adherent to the capsule often prove to be neural vessels on the pial surface when dissected free of the capsule.

If the pia-arachnoid membrane is adherent to the tumor capsule or if a tumor mass is present within the capsule and prevents collapse of the capsule away from brain stem and cranial nerves, there is a tendency to apply traction to both layers and to tear neural vessels running on the pial surface. Before separating the pia-arachnoid from the capsule, it is important to remove all of the tumor so that

FIGURE 5
Rhoton
microdissectors
for neuro-
surgery.



- Ⓐ Beginning on the left: dissectors (round, spatula, flat, and micro-Penfield), right-angled nerve hook, angled and straight needle dissectors, a microcuret and straight, 40°, and right-angled teardrop dissectors.

- Ⓑ A storage case and full set of instruments.


the capsule is so thin that it is almost transparent. If the surgeon is uncertain about the margin between the capsule and the pia-arachnoid membrane, several sweeps of a small dissector through the area will help clarify the appropriate plane for dissection.

For transsphenoidal operations, dissectors with bayonet handles are preferred because the handles aid in preventing the surgeon's hand from blocking the view down the long, narrow exposure of the sella.⁹ The Rhoton blunt ring curets are frequently used during transsphenoidal operations to remove small and large tumors of the pituitary gland and to explore the sella (Figure 6). Initially, the author's transsphe-

noidal operations were done using a sublabial incision and extensive dissection along the nasal septum. More recently, this has evolved into an endonasal approach in which no incision is made under the lip or in the anterior nasal cavity and the speculum is introduced through the nasal passage to the front of the sphenoid sinus, which is opened without any incision under the lip or anterior part of the nose. A small Rhoton transsphenoidal speculum was developed for this approach. The advantages of the endonasal approach, in addition to the reduced operative trauma to the lip and nose, are the reduced operative discomfort and the elimination of postoperative nasal packing (Figure 7).

smooth movement that drives the needle easily. There should be no lock or holding catch on the microneedle. When such a lock is engaged or released, no matter how delicately it is made, the tip jumps, possibly causing misdirection of the needle or tissue damage.

Jeweler's forceps or straight needle holders are suitable for handling microneedles near the cortical surface. For deeper applications, bayonet needle holders with fine tips may be used. Bayonet needle holders with 8-cm shafts are suitable for use down to a depth of 3 cm below the surface of the brain. Shafts measuring 9.5 cm are needed for suturing vessels or nerves in deeper areas such as the suprasellar region,



Needles, sutures, and needle holders

The operating room should have readily available microsuture, ranging from 6-0 to 10-0, on a variety of needles, ranging in diameters from 50 to 130 microns.^{12,13} For the most delicate of suturing, as in an extracranial-to-intracranial arterial anastomosis, nylon or Prolene suture of 22-micron diameter (10-0) on needles approximately 50 to 75 microns in diameter is used.

Jeweler's forceps are commonly used as a holder for grasping a microneedle, but they are too short for most intracranial operations. The handles of the microneedle holders should be round rather than flat or rectangular so that rotating them between the fingers yields a

around the circle of Willis, or in the cerebello-pontine angle.

For tying microsuture, either microneedle holders, jeweler's forceps, or tying forceps may be used. Tying forceps have a platform in the tip to facilitate grasping the suture; however, most surgeons prefer to tie suture with jeweler's forceps or fine needle holders.

Suction tubes

Suction tubes of the Rhoton-Merz type with blunt, rounded tips are preferred. Dandy designed and used blunt suction tubes and his trainees have continued to use the Dandy-type tube.¹¹ Yasargil and colleagues and Rhoton and

FIGURE 6

Rhoton blunt instruments for transsphenoidal operations.

Merz reported using suction tubes having blunt, rounded tips that allowed them to be used for the manipulation of tissue as well as for suction.^{10,14} The thickening and rounding of the tips reduce the problem of the small S- and 5-French tubes becoming sharp when cut smoothly at right angles to the shaft. Some suction tubes, such as those of the curved Adson type, become somewhat pointed when prepared in sizes as small as 3- or 5-French, because the distal end of the tube is cut obliquely to the long axis of the shaft, making them less suitable for use around the thin walls of aneurysms.

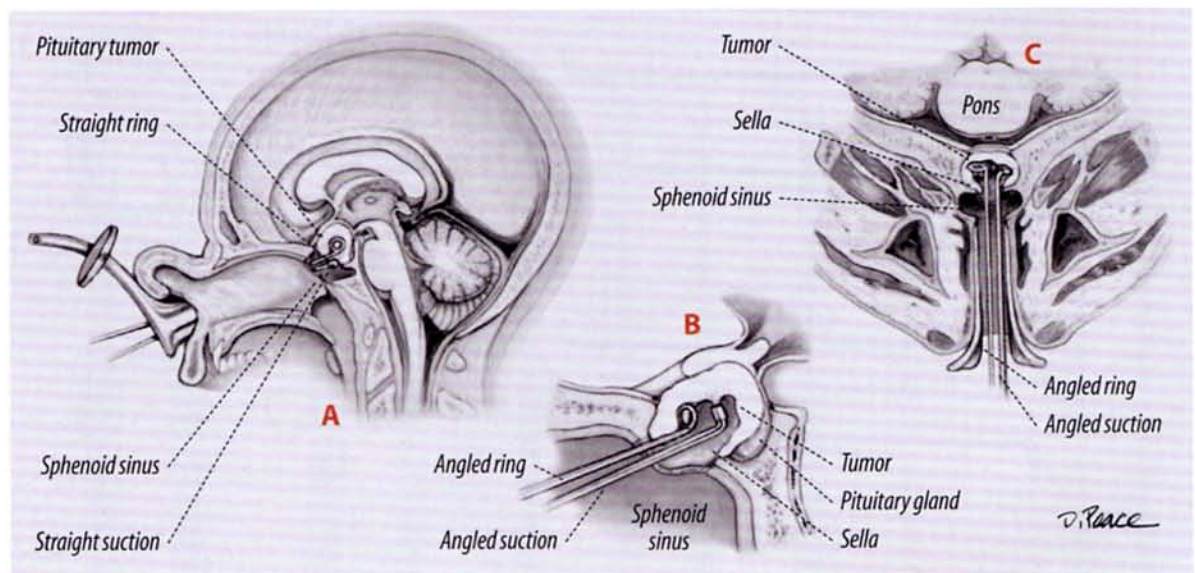
The suction tube should be designed to be held like a pencil, rather than like a pistol. Frazier suc-

tion tubes with 13-cm shafts may be used at extra deep sites such as in front of the brain stem and also for transsphenoidal operations. The suction tubes with 13-cm shafts, as used for transsphenoidal operations, in addition to having straight tips, have tips angled up and down for suction around the curves within the capsule of a tumor or for following asymmetrical extensions of tumor (Figure 9).

The suction tubes should encompass a range of diameters from 3 to 12 French, which allows

FIGURE 7
Transsphenoidal removal of a large pituitary tumor with suprasellar extension.

- A** Midsagittal view. The straight ring breaks up the intracapsular contents of a suprasellar tumor, and the straight transsphenoidal suction tube aspirates tumor tissue from within the capsule.
- B** Enlarged midsagittal view. The angled ring and angled suction tube are directed upward to remove the intracapsular contents of the suprasellar extension.
- C** Tumor removal from parasellar region using angled ring.



tion tubes are designed to be held like a pencil. The pencil-grip design frees the ulnar side of the hand so that it can be rested comfortably on the wound margin, affording more precise, delicate, and sturdier manipulation of the tip of the suction tube than is allowed by the unsupported pistol grip.

Selecting a tube of appropriate length is important because the arm tires during extended operations if the suction tube is too long to allow the hand to be rested. The Rhoton-Merz tubes with 8-cm shafts (ie, the length between the angle distal to the thumb piece and the tip) are used for suction at the level of the skull or near the surface of the brain (Figure 8). Tubes with 10-cm shafts allow the hand to rest along

them to be used for macrosurgery and microsurgery (Table 1). Conventional surgery done with the naked eye uses 9-, 10-, or 12-French size tubes. The French designation applies to the outer diameter. Three French units equal 1 mm. A 9-French tube has an outer diameter of 3 mm. The 10- and 12-French tubes are used during the opening of the scalp, muscle, and bone and for heavy bleeding. The most commonly used macrosuction tubes, the 9- and 10-French sizes, are too large for use after the dura is open. Stretched nerve fascicles or small vessels can easily become entrapped in such large tubes. Most micro-operative procedures require tube diameters of 5 and 7 French. The 3- or 5-French sizes

are suitable for delicate applications such as suction around the facial nerve during the removal of an acoustic neuroma. The 5-French suction tube with a 10-cm shaft may be used as a suction-dissector in defining the neck of an aneurysm or as a suction-dissector in the cerebellopontine angle and near the cerebellar arteries and cranial nerves. The 7-French tube is commonly used in completing the intracapsular removal of an acoustic neuroma or meningioma of medium or large size. The 3-French tube is too small for most micro-operative procedures, but it is suitable for applications such as suction along the suture line of an extracranial to intracranial arterial bypass.

the effectiveness of the bipolar coagulation forceps and reduces the adhesiveness of the tips to tissue. Constant bathing by cerebrospinal fluid has the same effect.

Irrigation with physiological saline is also helpful in cooling the drill tip, which may transmit heat to nearby neural structures, and in washing bone dust from the incision. The irrigation should be regulated so that the solution does not enter the operative field unless the surgeon's finger is removed from the suction release hole.

Brain retractors

Self-retaining retraction systems are routinely used for most intracranial operations.^{1,6,14} They

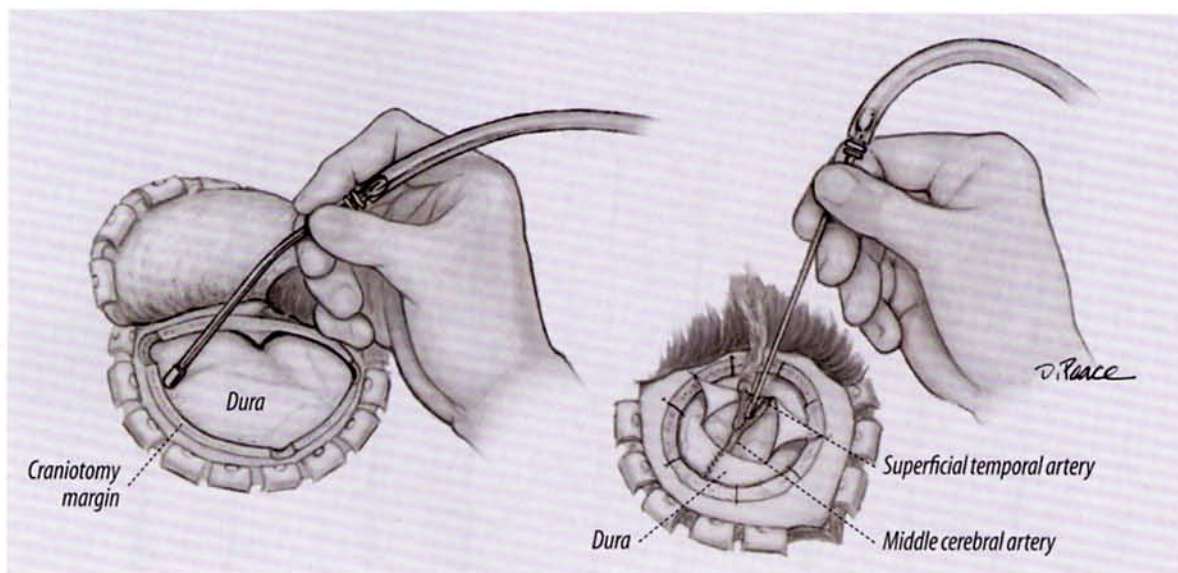


FIGURE 8

Short blunt suction tubes (8-cm shafts) are used when turning a bone flap or during other operations near the surface of the brain.

The power of the suction is regulated by adjusting the degree to which the thumb occludes an air hole. The air holes should be large enough that the suction at the tip is markedly reduced when the thumb is off the hole; however, the suction pressure may need to be adjusted at its source to avoid the danger of entrapping and damaging fine neural and vascular structures.

A continuous stream of irrigating fluid, which is often delivered through another tube that is fused to the suction tube, can be helpful during part of the operation. Irrigation discourages the formation of small blood clots and their adherence to the dissected surfaces; it also increases

allow the surgeon to work in a relatively confined space unhindered by an assistant's hand. They are more dependable than the surgeon's or assistant's hand in maintaining constant, gentle elevation of the brain. The retraction system should include tapered and rectangular brain spatulas that are applied to the protected surface of the brain; flexible arms that can support the brain spatulas in any position within the operating field; and a series of clamps and bars for attaching the system to the pinion head holder or the operating table (Figure 10). The most frequently used self-retaining retractor systems have flexible arms that consist of a series of ball-and-socket units, resembling a string of pearls, with

an internal cable that holds in the desired position when tightened.

The stability of the system is increased if the flexible arms that hold the brain spatulas are constructed so that they are tapered, having the largest pearls near the bar to which the arm attaches and the smallest pearls on the end that holds the brain spatulas. Two lengths of flexible arms (30 and 48 cm) will allow the system to be used at diverse operative sites. Greater flexibility in positioning the flexible arms can be achieved if the arms are attached to the rigid bars with the use of a coupling that allows them to be rotated through a 360° arc. The flexible arms are directed to a short bar that is fixed to the pinion head

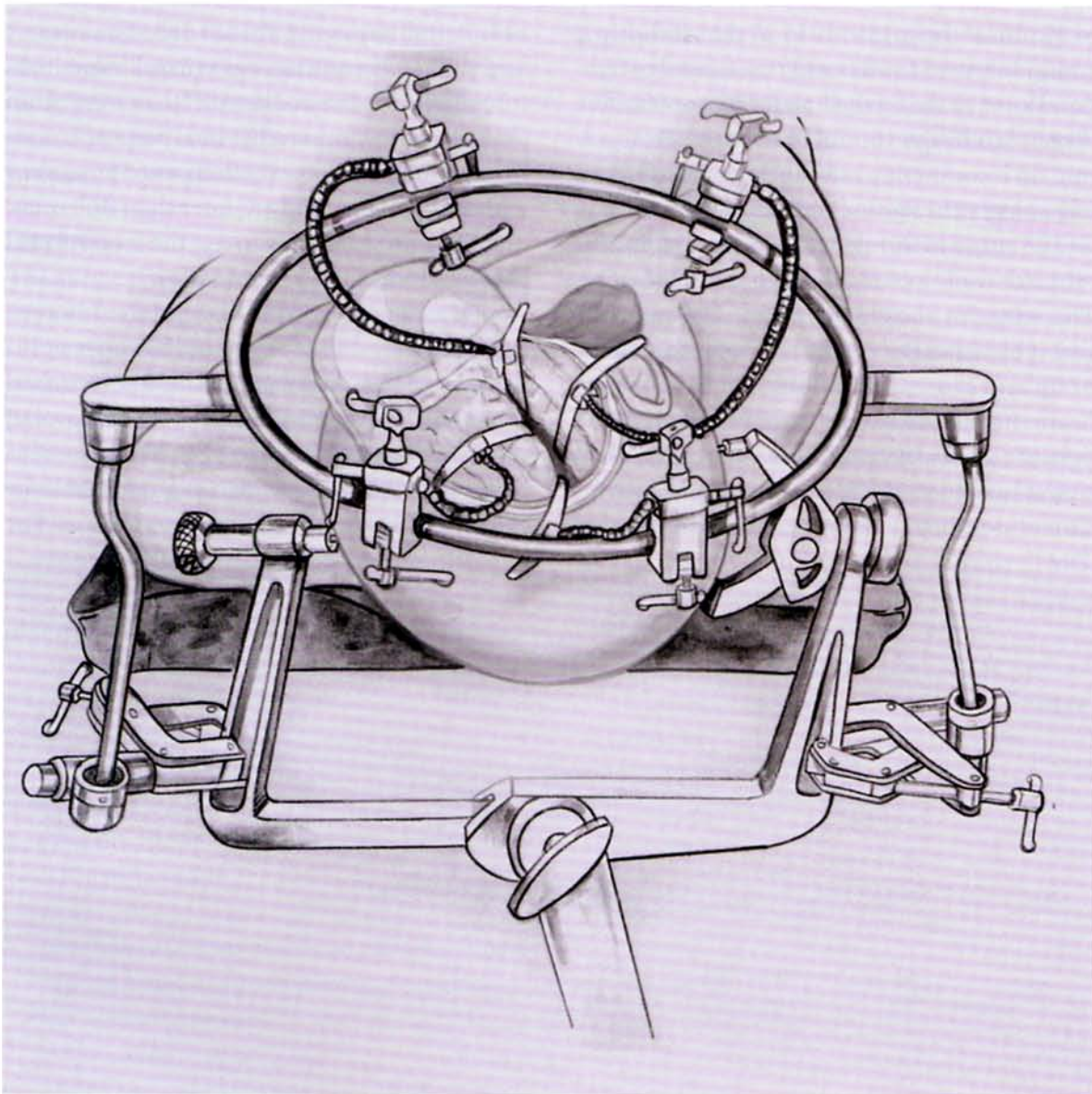
holder, or they may be attached to longer bars that are attached to the operating table or head holder. The short handles used to tighten the flexible arms and joints in the system should be broad and flat rather than narrow and round, as found in some systems. The broad, flat handles increase the ease of adjustment of the arms and joints.

The clamps that attach the retractor system to the head holder or operating table should be firmly fixed in place prior to affixing the flexible arm. The clamps should be affixed to the head holder as close to the operative field as possible and yet should not block the ease and freedom with which the surgeon moves other instru-

FIGURE 9

Rhoton-Merz suction tubes for transsphenoidal operations. The transsphenoidal tubes have 13-cm shafts and are made in three sizes: 5-, 7- and 10 French. They have straight, angled-up, and angled-down tips in each of the three sizes.





ments into the operative site. The retractor system should include straight and curved bars, a jointed bar, and a ring that can be attached to a clamp that fits on the head holder and a long bar that can be attached to the operating table.

The flexible arms should be led into the operative site in such a way that they rest closely against the drapes around the margin of the operative site. If the flexible arms are not positioned close to the drapes, the suctioned tubing or cable on the bipolar coagulator may become entangled with the arms and brain spatulas. Positioning near the drapes also reduces the chance that the hand passing instruments will bump the flexible arms. If the bar for holding the

flexible arms is positioned between the head of the patient and the surgeon, the bar should be sufficiently close to the patient's head that the surgeon does not bump against it if he or she moves from one position to another around the head of the patient.

A series of tapered and rectangular brain spatulas of the Rhoton or other types should be available at the various operative sites (Figure 11). Paired brain spatulas of the same size are frequently used for separating the edges of the Sylvian fissure or a cortical incision, and a single spatula is commonly used for elevating the surface of the brain away from the cranial base, tentorium or falx. A single spatula tapered from 15

FIGURE 10

Self-retaining
retractor system
developed by
Rhoton and
Merz

(V Mueller, Chicago, IL)

to 25 mm at the base to 10 to 20 mm at the tip is commonly used for elevating the frontal or temporal lobes or the cerebellum for tumor removal. A spatula having a 10-mm base that tapers to a 3-mm tip is commonly used during operations for trigeminal neuralgia or hemifacial spasm.

The surgeon should learn to manipulate the retractor while looking through the microscope. The retractor should not be applied so firmly that it blanches the vessels on the surface of the brain and causes infarction of the underlying brain. Infarction occurs infrequently if blood pressure is normal; however, if induced hypotension is used intraoperatively, inadequate perfusion under the retractor may cause infarction

as 1.5 mm frequently are needed. The curet is held so that the cutting edge is in full view. Pressure should be directed parallel to or away from important structures rather than perpendicularly toward them. Properly sharpened curets cut with less pressure and are safer than dull ones. The surgeon should try to use the largest curet that can do the job.

Cup forceps

A cup forceps such as that used for intravertebral disc removal is commonly used for removal of tumors. The most frequently used cup forceps have a tip 3, 4, or 5 mm wide, which is suitable for the intracapsular removal of large tumors. For




FIGURE 11

Rhoton-tapered

brain spatulas shown in various widths (measured in mm) may be needed depending on the site and size of the lesion.

and subsequent hemorrhage after the retractor is removed.

Bone curets

Small curets are frequently used for removing the last shell of bone between a drill surface and neural or vascular structures. Straight and angled curets located in the 13 and 14 position in the Rhoton rack are used frequently. Curets angled at 45° frequently are used for special purposes, such as removing the last thin shell of bone over the internal acoustic meatus or anterior clinoid process or curetting a fragment of tumor from the lateral margin of the acoustic meatus or other areas. Curets with tips as small

removal of small tumors or small fragments of tumor in critical locations, such as on the cranial nerves, in the acoustic meatus, or within the fourth ventricles, cup forceps with a diameter of 1 to 2 mm are used. For grasping small bits of tumor directly on or within the cranial nerves, the 1-mm cup forceps is used. The 2- and 3-mm cups are suitable for the intracapsular removal of small tumors. Angled microcup forceps enable the surgeon to reach around a corner to grasp tissue or remove tumor. A cup forceps angled to the right is used to reach laterally to the right (eg, to reach a right parasellar extension of a pituitary adenoma or behind the facial and acoustic nerves in the right acoustic meatus), and the cup

forceps angled to the left is used on the left side. The angled cup forceps can also be used to reach to either side of a small capsular opening for intracapsular removal or for reaching laterally into an intervertebral foramen for disc removal.

Conclusion

The surgical technologist plays a pivotal role in smoothly and successfully completing a neurosurgical procedure. With careful operative planning and experience, they are often able to anticipate what the surgeon's needs are before the surgeon realizes what is needed. The cooperative application of the principles outlined in this paper will increase the sense of well being of the operative team and improved outcome for the patient.

About the author

Dr Rhoton was a speaker at AST's Annual National Conference in Orlando, Florida, in 1999. See related story on page 26.

References

1. Greenberg IM. Self-retaining retractor and handrest system for neurosurgery. *Neurosurgery* 8:205, 1981.
2. Greenwood J. Two point coagulation. A new principle and instrument for applying coagulation current in neurosurgery. *Amer J Surg* 50:267, 1940.
3. Malis LL. Bipolar coagulation in microsurgery. In Yasargil MG, ed. *Microsurgery Applied to Neurosurgery*. New York: Academic Press, 1969, 41-45.
4. Rhoton AL Jr. General and Micro-operative Techniques. In: Youmans JR, ed. *Neurological Surgery*. Vol. 1. Philadelphia: WB Saunders Co. 1996, 724-766.
5. Rhoton AL Jr. Anatomic Foundations of Aneurysm Surgery. *Clin Neurosurg* 41:289, 1994.
6. Rhoton AL Jr. Instrumentation. In Apuzzo MJL, ed. *Brain Surgery: Complication, Avoidance and Management*, Vol. 2. New York: Churchill-Livingstone, 1993, 1647-1670.
7. Rhoton AL Jr. Microsurgery of the internal acoustic meatus. *Surg Neurol* 2:311, 1974.
8. Rhoton AL Jr. Microsurgical Anatomy of Decompression Operations on the Trigeminal Nerve. In Rovit RL, ed. *Trigeminal Neuralgia*, Baltimore: Williams & Wilkins, 1990, 165-200.
9. Rhoton AL Jr. Ring curets for transsphenoidal pituitary operations. *Surg Neurol* 18:28, 1982.
10. Rhoton AL Jr, Merz W. Suction tubes for conventional or microscopic neurosurgery. *Surg Neurol* 15:120, 1981.
11. Rizzoli H. Personal communication.
12. Yasargil MG. Suturing techniques. In Yasargil MG, ed. *Microsurgery Applied to Neurosurgery*. New York: Academic Press, 1969, 87-124.
13. Yasargil MG. Suture material. In Yasargil MG, ed. *Microsurgery Applied to Neurosurgery*. New York: Academic Press, 1969, 55.
14. Yasargil MG, Vise WM, Bader DCH. Technical adjuncts in neurosurgery. *Surg Neurol* 8:331, 1977.

Figures 1 and 9 from Rhoton AL Jr, Merz W: Suction tubes for conventional and microscopic neurosurgery. *Surg Neurol* 15:121, 1981. Used with permission of Elsevier Science, © 2002. Figures 2-8, 10 and 11 from Rhoton AL Jr: General and Micro-operative Techniques. In: Youmans JR (ed): *Neurological Surgery*. Vol. 1. Philadelphia, WB Saunders Co. 1996, pp 724-766. Used with permission of WB Saunders Co, © 2002.

Creutzfeldt-Jakob Disease

Tracey A Ross, CST, MEd

Creutzfeldt-Jakob Disease (CJD) is a rare, fatal neurological disorder, which causes rapid, progressive dementia and associated neuromuscular disturbances. This form of prion disease affects approximately one in one million people per year worldwide.¹⁰ Most cases occur in patients between 50 and 70 years of age. The duration of illness after patients become symptomatic is an average of six months. At the present time, no treatments exist for CJD; the disease always ends in death.

Creutzfeldt-Jakob Disease was first reported in medical literature in the 1920s when Drs Jakob and Creutzfeldt reported cases of a transmissible and fatal neurodegenerative disease. Recent outbreaks of Mad Cow Disease in Europe and a misunderstanding of this disease have heightened the public's fear of a CJD outbreak among humans.

Transmission

General etiology

Cases of CJD have been classified by etiology as inherited, iatrogenic, or sporadic. Genetic or inherited CJD accounts for only 5% to 10% of the total number of cases. Inherited forms of prion disease include CJD, fatal familial insomnia (FFI), and Gerstmann-Strausler-Scheinker syndrome (GSS).

Approximately 90% of CJD cases are sporadic. When CJD occurs as a sporadic disease, no recognizable pattern of transmission has been reported. Researchers have found that prions occur naturally in humans but in a slightly different shape (Figure 1). The pathogenic shape is folded (Figure 2) and researchers hypothesize that a mutation, followed by an infectious altering of normal prions, leads to the spontaneous form. Reasons for this mutation remain unclear.^{11,13}

Of the three forms of CJD, iatrogenic CJD occurs in less than 1% of the cases.² There have been documented cases of iatrogenic transmission of CJD linked to pituitary extracts (including human growth hormone), dura mater, corneal transplants, and to instruments and devices that have penetrated the brain, such as stereotactic electrodes.⁶

New variant CJD

A new variant of the disease, vCJD or nvCJD, has been documented in the United Kingdom and several other European countries. New variant CJD is linked to eating beef from cattle infected with bovine spongiform encephalopathy (BSE), also called Mad Cow Disease. This form of the disease afflicts individuals between 16 and 48 years of age. Onset of symptoms is much quicker and duration can last up to 14 months. Pathology of vCJD (characterized by amyloid plaques) differs significantly from that of normal CJD, and patients tend to get a related form of tonsil disease, which may make it easier to diagnose.¹²

Diagnosis

CJD is one of a group of encephalopathies known as transmissible spongiform encephalo-

pathies (TSEs), characterized by the sponge-like pathology of the brain.¹² The incubation period for CJD can vary from years to decades. Symptoms including depression, poor memory and, in latter stages, dementia and loss of physical functioning, may take decades to appear. The organism was originally labeled a "slow virus" because of the long incubation period. (Variant CJD is characterized by a more rapid onset of clinical symptoms.)

A definite diagnosis of CJD requires a histologic examination of the affected brain tissue.⁸ Craniotomy and stereotactic brain biopsy can be utilized to obtain brain tissue. Ideal sampling includes thalamus, cerebellum, all cortical lobes, the basal ganglia, and brain stem, so definite diagnosis is usually not obtained until a post-mortem autopsy.² Reported in most CJD patients has been the presence of 14-3-3 protein in the cerebrospinal fluid and/or atypical electroencephalogram (EEG) pattern, both of which are believed to be diagnostic.¹

Causative agent

Prions, proteinaceous infectious particles, are believed to cause CJD. Prions are unlike all other known pathogens. They do not contain genetic material and have the unique ability to survive routine sterilization and disinfection processes. Several recent reports issued by the Joint Commission on Accreditation of Healthcare Organizations (JCAHO) and the Centers for Disease Control (CDC) have signaled a renewed awareness of preventative infection control measures. (See "Much Ado About Prions," page 13)

Infection control case study

Exempla Saint Joseph Hospital in Denver, Colorado, encountered exposure to CJD in 2000. Hospital officials have encouraged JCAHO to share the results of a root cause analysis with other health care organizations in order to prepare risk reduction strategies. A patient who did not present with CJD symptoms underwent brain biopsy to rule out vasculitis in November

continued on page 14...

When Stanley Prusiner introduced the prion (pronounced "pree-on"), short for a proteinaceous infectious particle, in 1982, the idea was considered preposterous. (See History of Surgery, page 26) Prusiner's prion theory was controversial because the scientific community believed that infectious material had to contain genetic material such as DNA or RNA. The human body is built from proteins: How could one be infectious?^{13,14}

Prusiner resolved to find the answer. He and his associates confirmed that the human body naturally produces the same protein responsible for CJD, called PrP, but that protein's structure is slightly different than that of an infectious protein, or prion.¹³ Natural PrP was discovered on nerve cells, white blood cells, muscle cells and in other tissues throughout the body. This protein consists of three helix-shaped chains comprised of 208 amino acids and a tail of 27 amino acids extending from one end.¹¹

In its infectious form, PrP changes from an alpha-helical (spiral) shape to a beta-sheet (folded or accordion) form. Upon contact with normal PrP, a prion creates a chain reaction that replicates itself by "folding" the alpha form into a beta configuration. Several theories attempt to explain how the beta-sheet prion converts normal PrP, but none of those theories have been proven.¹⁴

In the brain, the PrP converts from the alpha-helical form to the beta-sheet form inside neurons. The beta-sheet prions accumulate in the lysosomes, eventually killing the neuron (the action of which is still unknown). Death of the neurons creates sponge-like holes in the brain and releases the prions to infect neighboring neurons.¹⁴

Scientists have linked inherited forms of CJD to a DNA mutation on codon 102, and later discovered mutations in the genetic code for FFI and GSS. These DNA mutations create an inherited susceptibility to prion disease, but the disease won't develop unless the alpha form flips into the beta form.^{13,14}

Although prions are an infectious agent, prion diseases are not contagious in the same way as viruses or bacteria. Human-to-human transmission is a con-

sequence of tainted instruments during a medical procedure or tissue transplantation from an infected individual.¹⁵

Prion diseases exist in humans, but are more common in animals. Animal forms of prion disease include bovine spongiform encephalopathy (Mad Cow Disease), scrapie (sheep), transmissible mink encephalopathy, feline spongiform encephalopathy, and chronic wasting disease (mule deer and elk).¹³

The PrP protein sequence is key to understanding a species ability to develop prion disease. If two species have a similar amino acid sequence in susceptible positions of their PrP, exposure is more likely to create the disease.¹³ It is a well-known fact that bovine spongiform encephalopathy originated from adding ground-sheep parts to feed given to cows.^{11,13} PrP proteins in cattle and sheep differ at seven positions, making the disease easily transferrable between species. Although human and cattle PrP differ at more than 30 positions, they are similar at specific vulnerable regions, making humans susceptible.^{13,14}

Much about prions remains a mystery. Scientists continue their search for a better understanding of and a cure for prion diseases.

They hope this body of knowledge will also shed light on other neurological disorders, such as Alzheimer's and dementia.

Normal PrP is found on nerve cells, white blood cells, muscle cells and other tissues throughout the human body.

2000. The patient died in December 2000 and following a postmortem brain biopsy, Creutzfeldt-Jakob disease was confirmed. In the meantime, six patients underwent brain biopsy procedures using the same sterilized instruments.³

Exempla Saint Joseph Hospital had a manual tracking system in place that identified patients that were operated on using those specific surgical instruments. The hospital informed the six patients about their possible exposure to CJD. Similar incidents have occurred at the Hotel-Dieu Hospital in Canada and at Tulane University Hospital in Louisiana.³

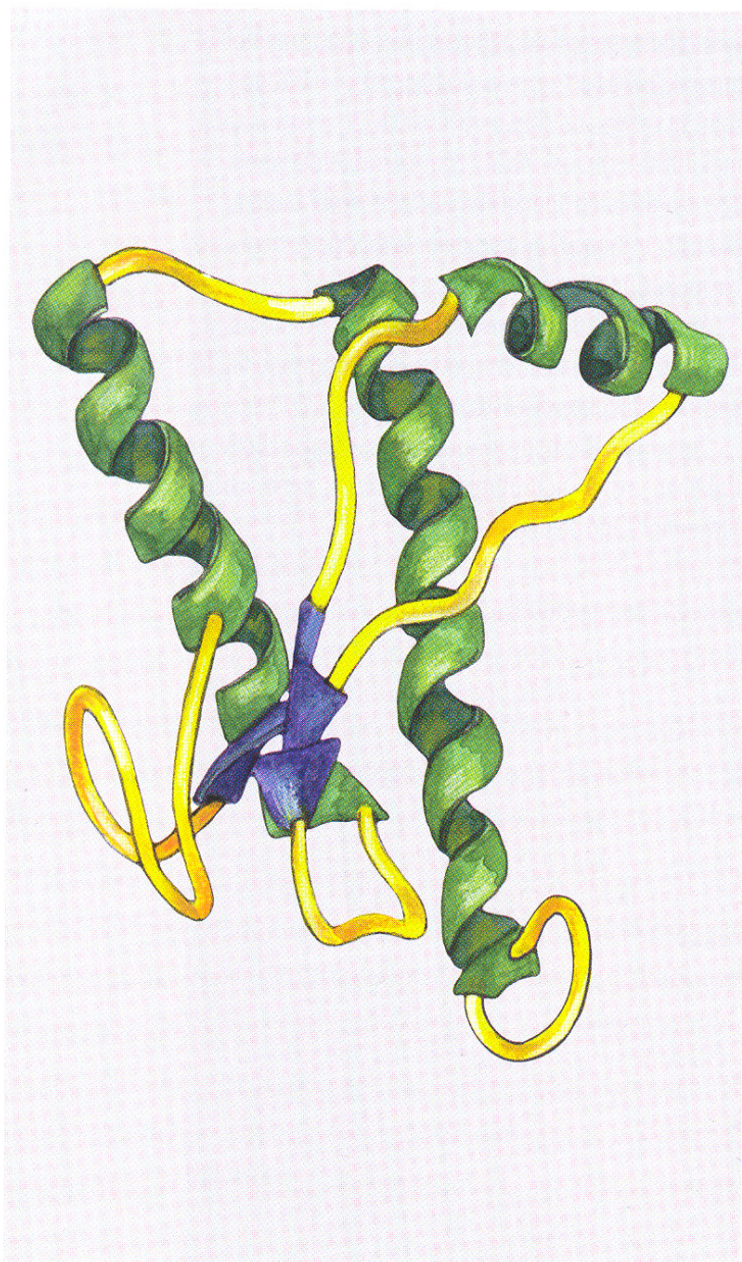


Illustration: Dave Ludwig

The risk of infection from contaminated surgical instruments is remote, but the lack of effective and reliable screening methods for patients with CJD has elevated the fear of an outbreak. Adding to the confusion of this disease's prognosis is the lack of well-defined protocols for addressing and resolving a potential CJD outbreak. The extremely low risk of CJD transmission during surgery ironically further complicates outbreak investigations.⁵

The hospital's root cause analysis involved sterilization and use of instruments, communication, competency of staff, and the interval between biopsy and pathology report. The hospital learned three important lessons³:

1. Instruments used during brain biopsy procedures should not be reused when the patient's diagnosis is uncertain at the time of the procedure.
2. CJD or prion disease patients do not always present with symptoms of CJD.
3. The time interval between the biopsy report and the pathology report should be closely monitored and reviewed to assure the shortest time from biopsy to results.

Other risk reduction strategies identified by Exempla Saint Joseph Hospital include³:

- Incinerate brain surgery instruments used on confirmed CJD patients.
- Quarantine neurosurgery instruments until physicians rule out CJD.
- Educate staff members, primary care physicians, and clinicians.
- Develop policies, procedures, and guidelines for suspected CJD cases in the operating room.

Recommendations

JCAHO recommends that organizations establish policies for 1) the disinfection or disposal of instruments used in neurosurgery in general and when CJD is suspected or confirmed and 2) the quarantine of such surgical instruments until an unclear diagnosis or biopsy is clarified. The World Health Organization's Infection Control

Guidelines for Transmissible Spongiform Encephalopathies also recommends the use of single-use surgical instruments and the destruction of reusable instruments that come in contact with highly infective tissues.³

Prions show considerable resistance to conventional chemical and physical sterilization methods such as ethylene oxide, boiling, dry heat, and autoclaving by conventional protocols.⁹ Many recommendations have been offered about instrument reprocessing. Some literature suggests discarding all instruments no matter what organ system they were used on.

New guidelines

Recently, two highly respected experts in health-care decontamination and sterilization science have challenged guidelines provided by the World Health Organization. William Rutala, PhD, and David Weber, MD, MPH, have challenged most of what has been previously published on processing instrumentation. Rutala and Weber suggest being proactive and not waiting until after the diagnosis to react.

Experts on CJD agree that not all tissue has the same level of risk of transmission. High-risk tissues include: eye tissue, dura mater, brain, and spinal cord. Significantly less infective tissues include: lymph nodes, lung, liver, kidney, spleen, and cerebral spinal fluid.⁶

Rutala and Weber suggest that the choice of sterilization methods for devices used on CJD patients depends on the type of device and the tissues to which it is exposed. The authors classify devices as: “critical,” devices that enter sterile tissue or the vascular system (eg, surgical instruments and implants), “semicritical,” devices that contact mucous membranes and broken skin (eg, endoscopes), and “noncritical,” items that touch intact skin but not mucous membranes (eg, blood pressure cuffs).⁷

A critical or semicritical device that has contact with high-risk tissue from a high-risk patient must be processed in a manner to ensure the elimination of prions. Critical or semicritical devices that have contact with low-risk or no-risk tissue can be treated by means of conven-

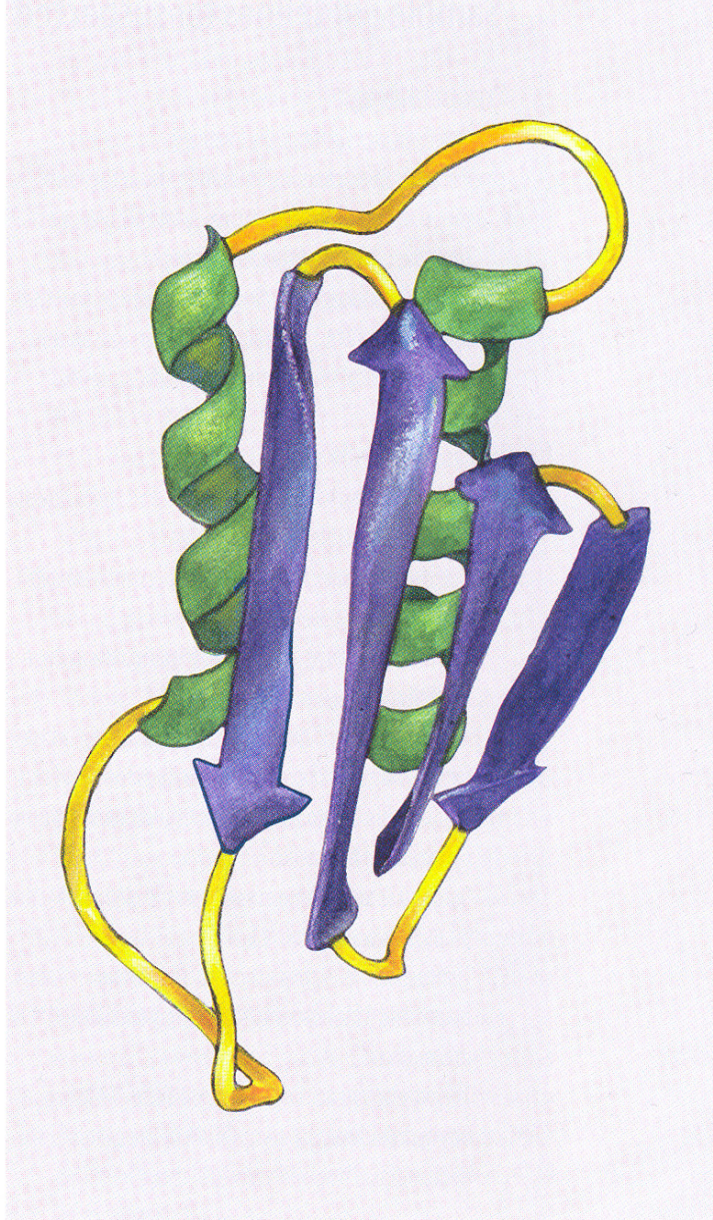


Illustration: Dave Ludwig

tional methods, because the devices have not resulted in the transmission of CJD.⁹

CDC guidelines

The Centers for Disease Control has worked on various guidelines relating to the processing of potentially CJD-contaminated instruments since 1985, and the CDC’s Healthcare Infection Control Practices Advisory Committee (HICPAC) is working on guidelines now. Rutala and another colleague, Martin Favero, PhD, recently presented the following two CDC draft guidelines⁷:

1. High-Risk Patient, High-Risk Tissue, Critical or Semicritical Device, a Modified Processing Protocol is recommended⁷:

FIGURE 2

Prions, infectious PrP^{sc}, are characterized by folded or accordion sections. Normal PrP is helical.

Sample guidelines for suspected CJD cases⁴

Preoperatively

- Notify all units potentially involved.
- Remove all extraneous equipment from the room (as much as possible) and move everything else as far from the operating table as possible.
- Cover all surfaces (including respiratory and anesthetic equipment) and OR table with impervious sheets.
- Cover electrical cords with sterile sleeves/plastic.

Intraoperatively

- Try to use disposable equipment and instruments whenever possible.
- Avoid using power instruments to prevent aerosolization of contaminants.
- Do not pass sharps from hand to hand. Always use a neutral zone to pass instruments.
- Attire: impervious gowns, hats, double gloves, masks, face shields, and knee-high impervious shoe covers.
- Clean spills of blood and body fluids with sodium hydroxide as they occur.
- Surgeon should change to new sterile gloves after the biopsy has been obtained.
- Tissue specimens are placed into a specimen container, placed into a biohazard specimen bag, and labeled "CJD precautions."
- The patient's head may be cleansed with 1 Molar sodium hydroxide at the completion of the case, per surgeon order.

Postoperatively

- Instrument handling: Place reusable instruments in an impervious container, red bag and label as "possible CJD."
- Body fluids/liquid waste: Should be collected, solidified, labeled and bagged as biohazardous and "possible CJD." Segregate waste from other red bag waste so that it can be incinerated.
- Other disposable supplies: All trash including surgical attire, drapes, Mayo covers, sponges, etc. should be placed in red bags and labeled as "possible CJD" and kept separate from other red bag trash, so that it can be incinerated. All disposable sharps should be placed in a sharps container and labeled as "possible CJD."
- Standard precautions should be used in the postoperative care of the patient's wound.

Environmental cleaning

- Decontaminate surfaces at the end of the procedure by continually wetting all exposed surfaces with 1 Molar sodium hydroxide for 60 minutes. Rinse thoroughly with water, then proceed with regular cleaning.
- Environmental surfaces contaminated with visible tissue should be decontaminated with 1:10 dilution of 5.25% sodium hypochlorite, followed by routine cleansing with hospital disinfectant.

- Steam autoclaving for previously cleaned instruments:
134° C (272° F) for 18 minutes or
121° C (250° F) for 1 hour
- For instruments that are difficult to clean:
Soak 1 hour in 5,000 parts per million hypochlorite or 1 molar (M) sodium hydroxide, Then rinse, clean, and autoclave as above.

2. Conventional Disinfection and Sterilization Protocols are Suitable for the Following Situations⁷:

- High-risk patient/medium-to-low-risk tissue/critical or semicritical device

- Low-risk patient/high-risk tissue/critical or semicritical device
- High-risk patient/high-risk tissue/noncritical device
- Medium-, low-, or no-risk tissue/high-risk patient/critical or semicritical device

Conclusion

Many questions still remain about Creutzfeldt-Jakob disease and controversy surrounds sterilization and disinfection guidelines recently issued by professional organizations. Written protocols are essential, and each healthcare organization is urged to review their policies and procedures for processing instrumentation used

on possible CJD patients. Guidelines should be prepared to include the following departments: nursing, pharmacy, central processing, infection control, environmental services, laboratory, and surgical services. Policies should be developed to include instrument handling, storage, cleaning, and decontamination or disposal. All staff members and physicians should be aware of the recommended precautions and policies. Health-care professionals should continue to seek the most current research materials and be prepared to update policies and procedures as new recommendations are developed.

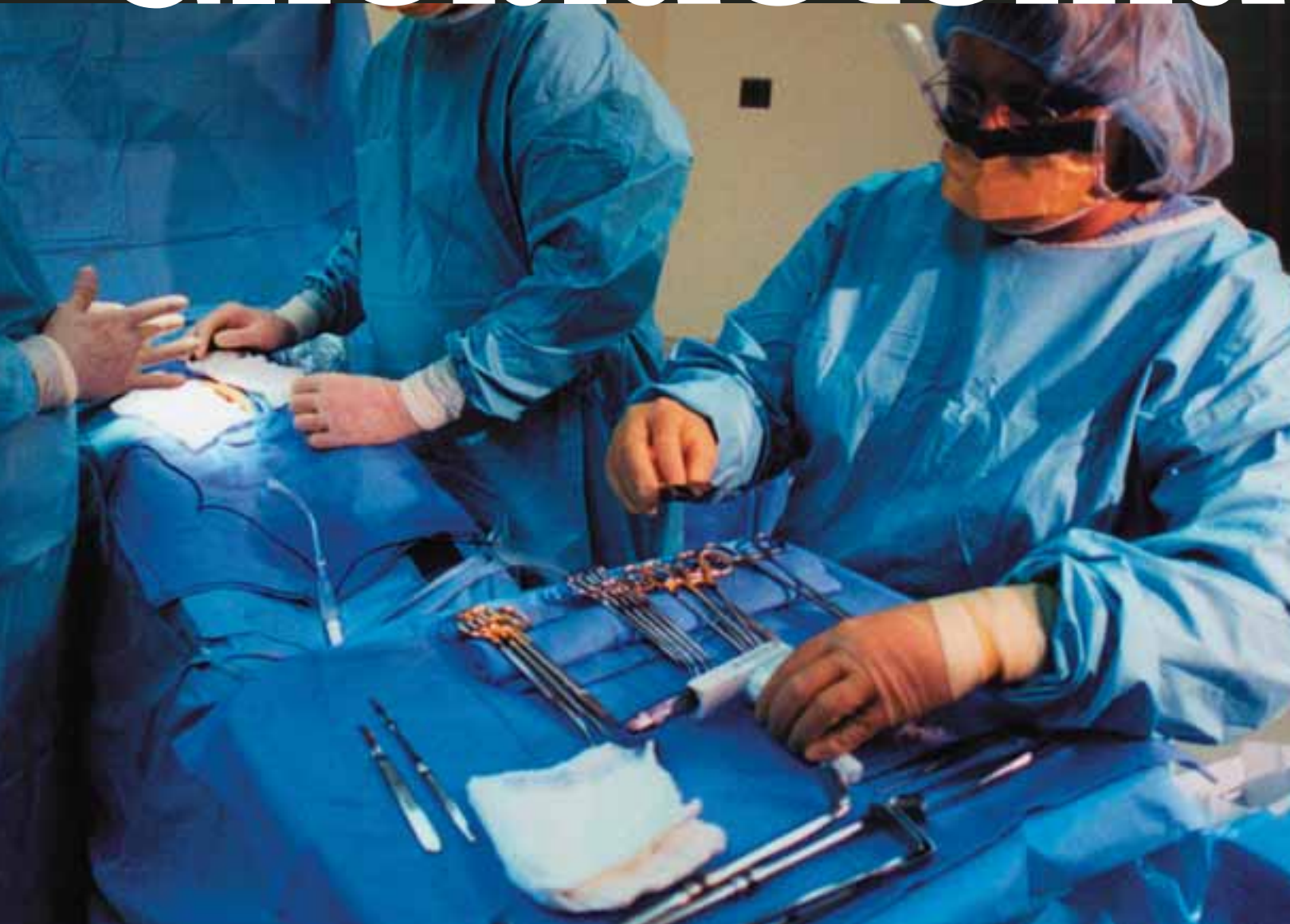About the author

Tracey A. Ross, CST, MEd, is currently the surgical services staff development instructor at Lancaster General Hospital in Lancaster, PA. She has worked both as a CST and as a surgical technology educator. Tracey is currently developing educational articles for the *Surgical Technologist* and the *AST Instructors' Newsletter*. She has served on the Core Curriculum Revision Committee and currently serves on the AST Education Committee.

References

- Centers for Disease Control. Questions and answers regarding Creutzfeldt-Jakob disease infection control practices. www.cdc.gov/ncidod/diseases/cjd/cjd_inf_ctrl_qa.htm
- Hansel P. Mad cow disease-the OR connection. *AORN Journal*. 1999;70(2):224-238.
- Joint Commission on Accreditation of Healthcare Organizations. Sentinel Event Alert. Issue 20. June 2001. Oakbrook Terrace, IL: Exposure to Creutzfeldt-Jakob Disease. www.jcaho.org/edu/pub/sealert/sea20.html
- Joint Commission on Accreditation of Healthcare Organizations. Inside the Joint Commission. Online [newsletter] August 6, 2001. Oakbrook Terrace, IL: CJD-Guidelines for Suspected CJD Cases in Operating Rooms.
- Muscarella L. "Assessing the risk of Creutzfeldt-Jakob disease." *Infection Control Today* [online]. August 28, 2001. www.infectioncontroltoday.com/articles/181feat1.html
- Reichert M, & Schultz J. CJD instrument processing. *OR Manager*. 2001;17(7):21-22.
- Roos R. "Overblown fears about CJD lead to over-the-top sterilization recommendation, expert says." *IcanPrevent*. [online] April 3, 2001. (subscription service, password required) www.icanprevent.com
- Rosenmann H, et al. "Detection of 14-3-3 protein in the CSF of genetic Creutzfeldt-Jakob disease." *Neurology*. 1997;49(2):593-595.
- Rutala W & Weber D. "Creutzfeldt-Jakob Disease: Recommendations for disinfection and Sterilization." *Clinical Infectious Diseases*. 2001;32:1348-1356.
- Steelman V. "Prion Diseases-An evidence-based protocol for infection control." *AORN Journal*. 1999;69(5):946-967.
- "Prion." Microsoft Encarta Encyclopedia 2000 [CD ROM]. Microsoft Corp. Redmond, WA.
- New Variant CJD (nvCJD) BSE Info Resource. March 2002. National Cattlemen's Beef Association and Cattlemen's Beef Board. www.bseinfo.org/resource/vcjd_fact.htm Accessed 1/4/02
- Pruisner SB. "The Prion Diseases." *Scientific American* [online]. August 1996. www.sciam.com/0896issue/prion/html Accessed 1/4/02
- Archer-Evans S, Boske A, Hodges C. Prions and Mad Cow Disease [web site]. University of Texas-Austin. www.esb.utexas.edu/palmer/bio303/group23/Prions%20and%20Mad%20Cow%20Disease.html Accessed 11/8/2001
- "CJD Info." Creutzfeldt-Jakob Disease Foundation Inc. cjd.foundation.org/CJDInfo.html Accessed 11/8/2001
- NINDS Transmissible Spongiform Encephalopathies Information Page. National Institute of Neurological Disorders and Stroke. www.ninds.nih.gov/health_and_medical/disorders/tse.htm Accessed 3/12/02
- "WHO Infection Control Guidelines for Transmissible Spongiform Encephalopathies: Report of a WHO Consultation, Geneva, Switzerland, 23-26 March 1999." National Center for Infectious Diseases. www.cdc.gov/ncidod/diseases/cjd/cjd_inf_ctrl_qa.htm#whoguidelines Accessed 3/13/02

Glioblastoma



JEFFREY J CORTESE, CST

Multiforme

FROM BIOLOGY TO TREATMENT

GLIOMASTOMA IS THE MOST COMMON PRIMARY BRAIN TUMOR IN ADULTS. NEARLY 12,000 CASES ARE DIAGNOSED ANNUALLY IN THE UNITED STATES.³ GLIOMASTOMA MULTIFORME (GBM) IS A MALIGNANT, RAPIDLY GROWING, PULPY OR CYSTIC TUMOR OF THE CEREBRUM OR THE SPINAL CORD.¹ IT IS ALSO CALLED ANAPLASTIC ASTROCYTOMA, GLIOMA MULTIFORME.²

GLIOMASTOMA IS BELIEVED TO ARISE FROM CELLS CALLED ASTROCYTES. GLIOMASTOMAS USUALLY PROGRESS AT THE SITE OF ORIGINAL GROWTH, BUT CAN TRAVEL TO OTHER PARTS OF THE BRAIN. THE LESION SPREADS WITH PSEUDO PROJECTIONS. IT IS COMPRISED OF A MIXTURE OF MONOCYTES, PYRIFORM CELLS, IMMATURE AND MATURE ASTROCYTES, AND NEURAL ECTODERMAL CELLS WITH FIBROUS OR PROTOPLASMIC PROCESSES.

In addition, glioblastomas, like other forms of brain tumors, can infiltrate normal brain tissue. This infiltration makes complete removal of glioblastomas virtually impossible, thereby necessitating other forms of therapy. Despite aggressive therapy, less than 5% of these patients are expected to live more than five years. Traditionally, treatment has consisted of maximal surgery followed by radiation therapy and chemotherapy. However, new advances in treatment have allowed for improvements in tumor control and in quality of life.

Causes of the disease

GBM, the extreme expression of anaplasia among the glial neoplasms, accounts for 40% of all primary intracranial tumors.⁵ Although no exact cause has been discovered for the disease, there are particular studies that have linked a cause with GBM. The charts of 100 patients with established diagnoses of GBM provided the data for a descriptive study of the patients' exposure to herbicides.⁹ The study focused on place of residence and occupation prior to GBM diagnosis. Although the subjects reported residence in 33 of the 75 counties in Arkansas, more than one-third of the sample came from just three counties in which rice, cotton, or wood products are produced.

These industries were reported as the occupations of almost one-third the sample from which occupations involved a risk of herbicide expo-

sure. Radiation-induced gliomas are uncommon, with only 73 cases on record to date. The disease that most frequently occasioned radiation therapy has been lymphoblastic leukemia. A case of transmission of a GBM from the donor to a kidney transplant recipient in the absence of a previous ventriculosystemic shunt is described.³

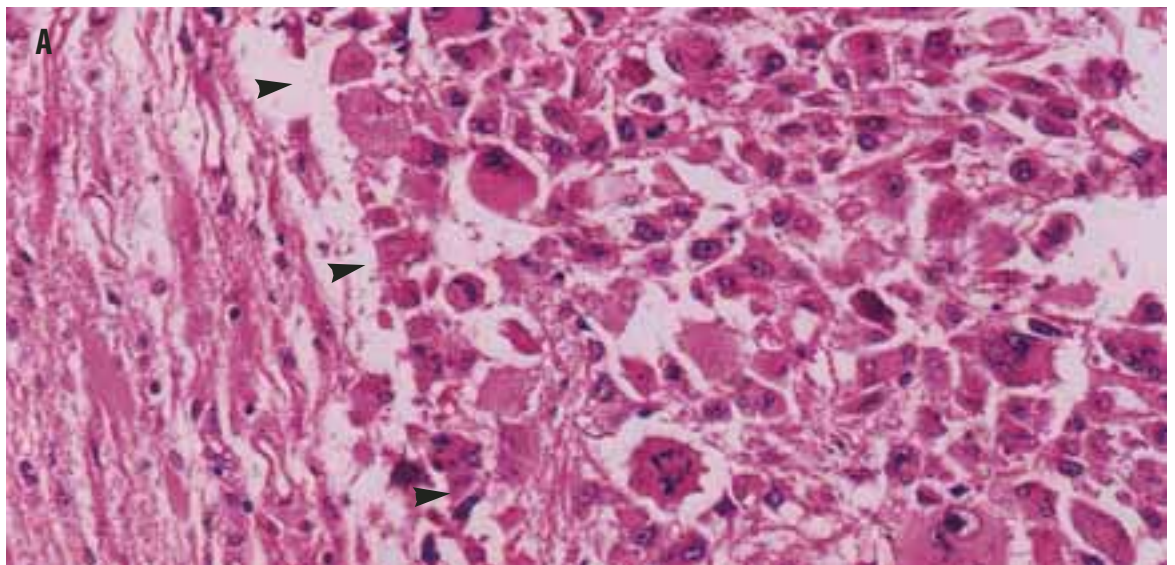
The recipient was a 48-year-old woman who developed a fever with no other associated symptoms 17 months post transplant. Physical examination revealed a large nonpulsatile mass on the upper pole of the donor kidney. Histopathological examination showed a highly cellular neoplasm with fusiform and globoid cells, a high grade of nuclear pleomorphism and mitosis, necrosis with pseudopalisading and vascular proliferation. Therefore, the risk of tumor transmission from donors with primary central nervous system tumors to kidney transplant recipients is real and should be considered when evaluating a graft mass in such patients.

Manifestations of the disease

Glioblastoma multiforme, beginning more often in the white matter, appears to be well demarcated because the surrounding brain is compressed, swollen, and edematous. The neoplasm is usually firmer than the adjacent tissue (Figure 1a-c). Its surface has a variegated gray, white, yellow (necrotic), and reddish brown (hemorrhagic) appearance. These colors are imported

FIGURE 1

- ⊕ Micrograph demonstrating the border of the tumor, which consists of a rapid transition (following the arrows) from a solid, cellular zone of pleomorphic infiltrate to a compressed and edematous white matter.



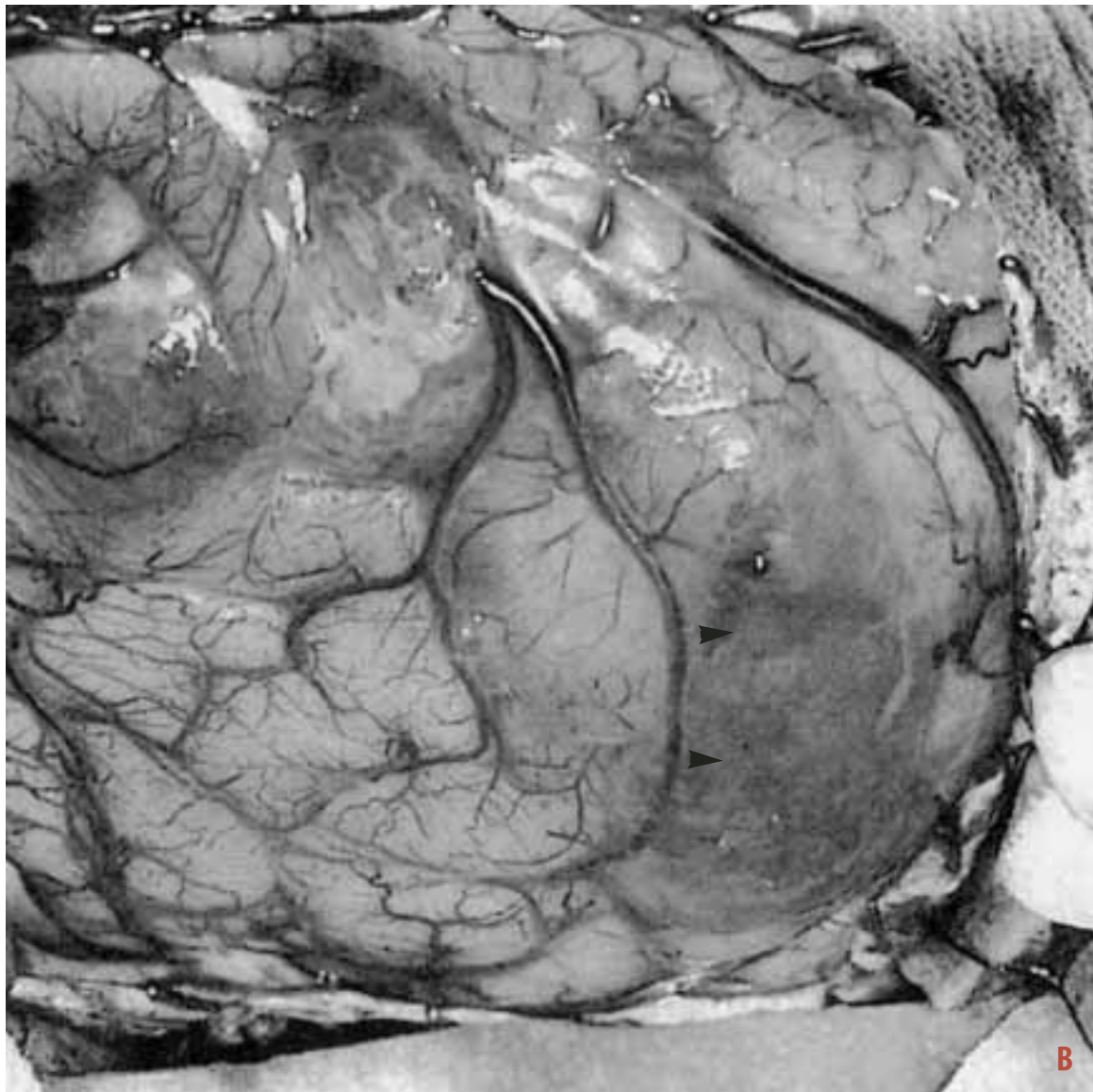


FIGURE 1

ⓐ Intraoperative photograph showing the cortical involvement of glioblastoma. The tumor produces irregular thickening and discoloration of the gyri. (See arrows.) Many glioblastomas are not apparent on gross external examination.

ⓑ Anatomic specimen showing the left middle temporal gyrus enlarged by the tumor (at arrow). The left temporal lobe is swollen.

by multiple areas of recent and remote hemorrhage and necrosis. The microscopic appearance of these lesions is characterized by profuse numbers of pleomorphic and frequently bizarre cells (Figure 2). Among these are many cells with enlarged and irregular nuclei (Figure 3). Some cells can be identified by their processes as being of astrocytic origin (Figure 4). Other cells may be small with oval, hyperchromatic nuclei resembling the undifferentiated small cells of a bronchogenic carcinoma² (Figure 5). In other areas, there may be large cells with irregular large, vesicular nuclei and with an abundant eosinophilic cytoplasm suggesting an origin from gemistocytic astrocytes.² In many areas

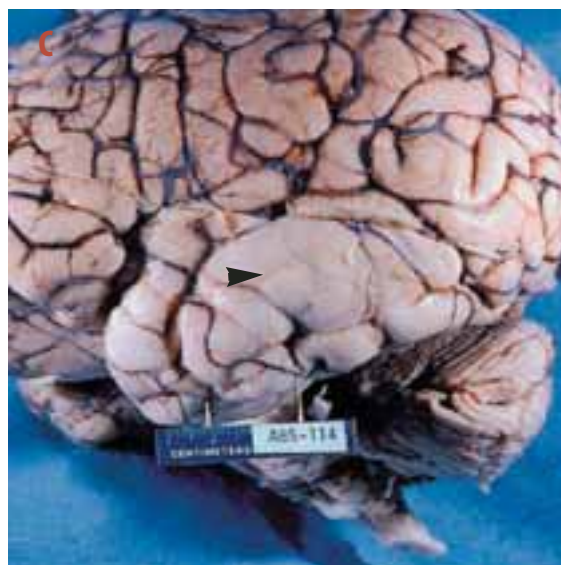

FIGURE 2

Micrograph showing pleomorphism, increased cellularity, vascular hypertrophy and endothelial proliferation.

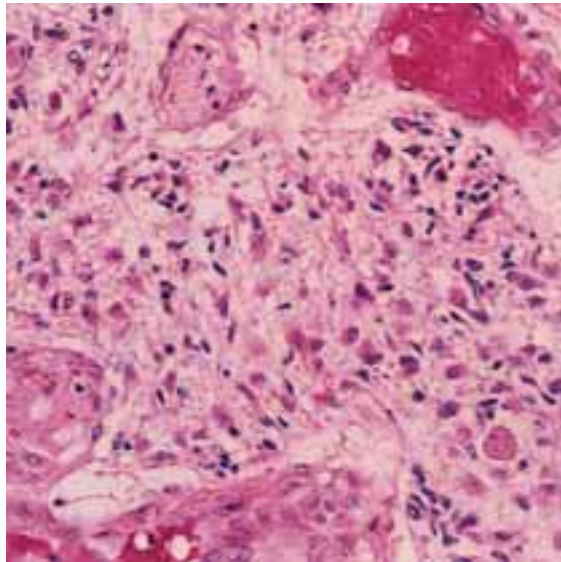


FIGURE 3

Micrograph of characteristic features of glioblastoma. Note the elongated nuclei and bipolar processes shown by the arrows.

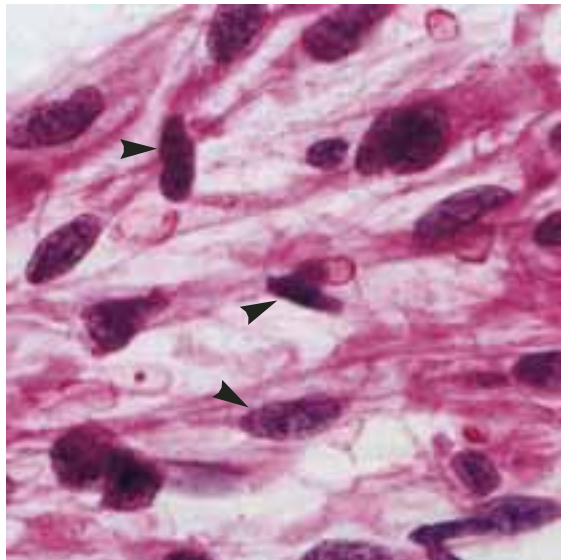
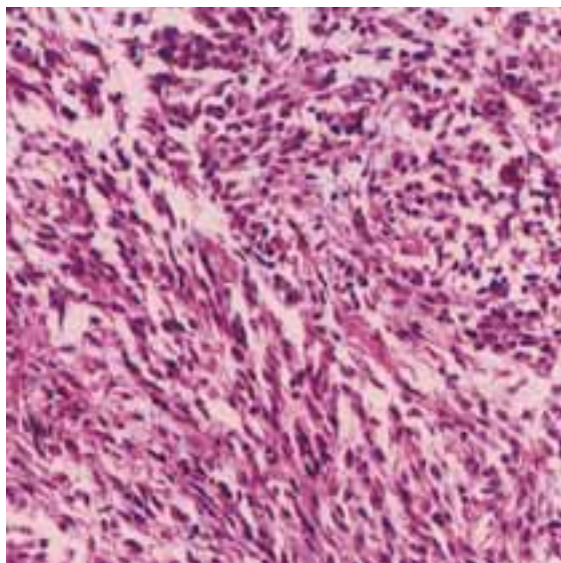


FIGURE 4

Micrograph showing bipolar cells characteristic of fibrillary astrocytes with prominent processes.



within the neoplasm, one may find bizarre, multinucleated cells with abundant cytoplasm resembling strap cells of rhabdomyosarcomas.

Mitoses, often abnormal, are usually easily found either in clusters or spread fairly regularly throughout the neoplasm. In many regions within the neoplasm are large and small areas of necrosis, often with a garland of small cell nuclei at the periphery. Blood vessels are greatly increased in the number and usually show endothelial adventitial hypertrophy and hyperplasia⁷ (Figure 6a-b). Occasionally, vessels with these changes are found well beyond the apparent microscopic limits of the neoplasm.

Signs and symptoms of the disease

The patient who is diagnosed with glioblastoma multiforme has several signs and symptoms associated with the neoplasm.⁶ In a general aspect, there is an increased intracranial pressure. The increase in ICP causes nausea, vomiting, headache, and papilledema. There are mental and behavioral changes associated with the disease. There are altered vital signs as follows: increased systolic pressure, widened pulse pressure, and respiratory changes. Speech and sensory disturbances are found with the disease. Children with GBM present with the above symptoms, plus the added symptoms of irritability and projectile vomiting.

On more of a locality aspect, a lesion on the midline of the brain would produce a headache, bifrontal or bioccipital, which is worse in the morning hours and manifests by coughing, straining, or sudden head movements. A growth in the temporal lobe would produce psychomotor seizures. Focal seizures are present in patients with a lesion in the central region of the brain. If the neoplasm is on the optic or oculomotor nerves, there are visual defects appreciated. Finally, a GBM lesion of the frontal lobe would cause abnormal reflexes and motor responses.

Course of the disease

Characteristically, GMB infiltrates extensively, frequently crossing the corpus collosum and producing a bilateral lesion likened to a butter-

fly in its gross configuration (Figure 7a-b). Although any glioma may “dedifferentiated” to the level of GMB, in practice, the majority of these lesions manifest some evidence of astrocytic differentiation.⁴

GMB may occur at any age but it is most common in the adult years, with a peak incidence during the fifth and sixth decades. Glioblastoma may arise anywhere along the neuraxis, but it is most common in the cerebral hemispheres. In contrast, a predilection for the brain stem is apparent in those arising in childhood.

Secondary diagnosis of the disease

Diagnostic procedures for brain tumors include physical and neurological examinations, visual field and fundoscopic examination, CT scans and MRI, skull X-rays, technetium brain scans, electroencephalography, and cerebral angiography.

Physical examination is used to assess motor and sensory function. Since the visual pathways travel through many areas of the cerebral lobes, detection of visual field defects can provide information about the location of the tumor. A fundoscopic examination is done to determine the presence of papilledema.

CT scans have become the screening procedure of choice for diagnosing and localizing brain tumors as well as other intracranial masses. MRI scans may be diagnostic when a CT scan does not detect a clinically suspected tumor (Figure 8). Skull X-rays are used to detect calcified areas within a neoplasm or erosion of skull structures due to tumors.

Brain tumors tend to disrupt the blood-brain barrier; as a result, the uptake of a radioactive isotope used in brain scans is increased within a tumor. About 70% of persons with a brain tumor have abnormal electroencephalograms; in some cases, the results of the test can be used to localize the tumor.⁴ Cerebral angiography can be used to locate a tumor and visualize its vascular supply.

Scintigraphy using Indium-111-labeled anti-EGRf-425 has become useful in diagnosing GBM. In a study, 28 patients with intracranial neoplasms were injected with an average dose of 2.2 mCi of EGRf-425.⁹ The immunoscintigra-

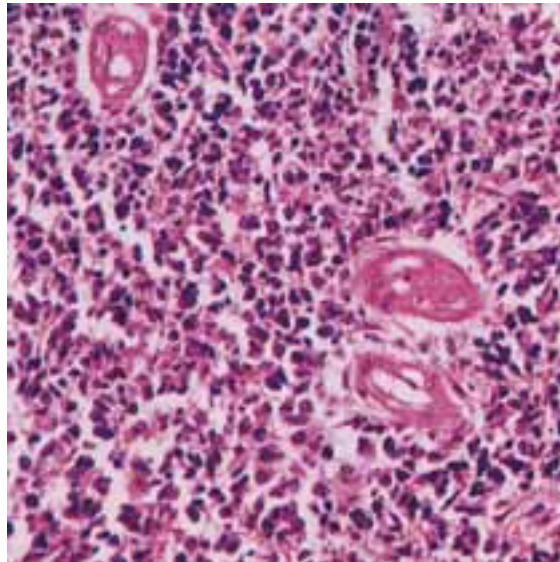


FIGURE 5

Micrograph showing the central zone of densely cellular small-cell glioblastoma with hyperchromatic nuclei and barely visible cytoplasm.

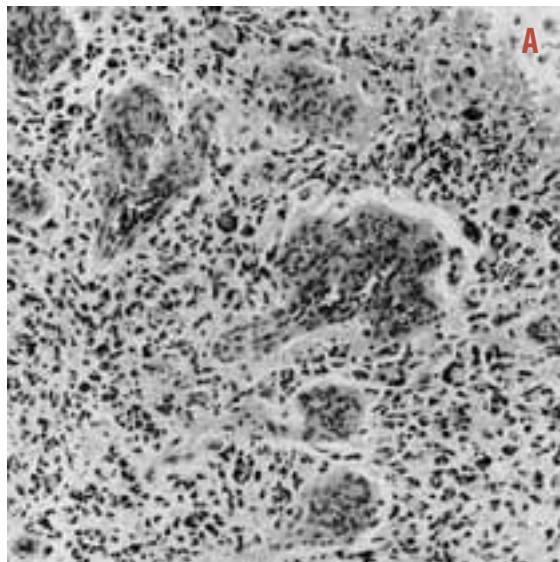


FIGURE 6

⊗ Micrograph showing bipolar cells characteristic of fibrillary astrocytes with prominent processes.

⊗ An unusual histologic pattern in glioblastoma is this gland-like configuration of the tumor cells in which there are large intercellular spaces.

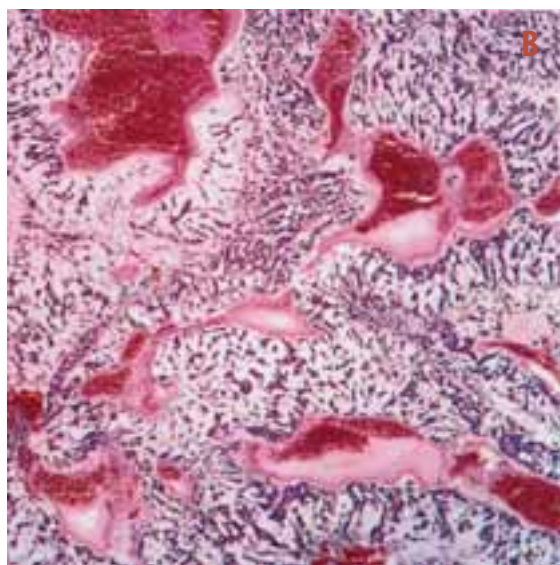


FIGURE 7

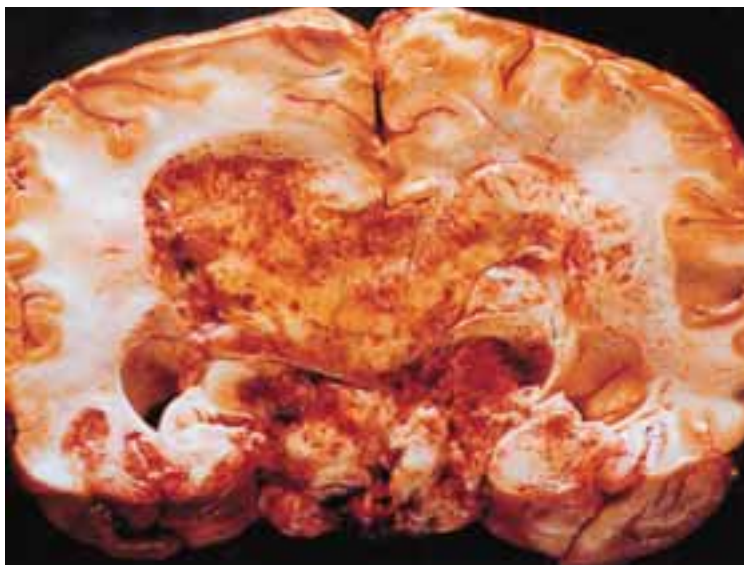
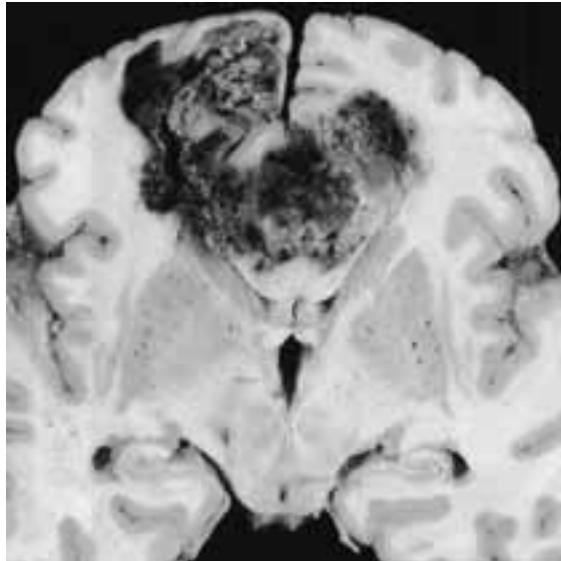
- Ⓐ Gross photograph of a typical untreated case of glioblastoma. The classic “butterfly” configuration, is necrotic hemorrhagic mass.
- Ⓑ Coronal section of a pathology specimen showing massive involvement of the splenium of the corpus callosum by a glioblastoma with bilateral white matter extension.

phy findings were generally in agreement with the CT findings. The definite diagnosis was established by biopsy findings.

Prognosis, survival rates, and treatments

The prognosis of patients with GBM is very poor. Although with recent advances in treatment of this neoplasm, the life expectancy of a patient with this disease without treatment is approximately 18 weeks. Radical surgery in conjunction with radical chemo and radiation therapy has increased the median survival rate to 62 to 72 weeks.

Surgery is part of the initial management of virtually all brain tumors. The development of microsurgical neuroanatomy, the operating



microscope, the fusion of imaging systems with resection techniques, advanced stereotactic and ultrasound technology, and intraoperative monitoring of evoked potentials have all served to improve the effectiveness of surgical resection. However, removal may be limited by the localization of the tumor and its invasiveness. Stereotactic surgery uses three-dimensional coordinates and CT and MRI to localize a brain lesion precisely.

Ultrasound technology has been used for localizing and removing tumors. The ultrasonic aspirator, which combines a vibrating head with suction, permits atraumatic removal of tumors from cranial nerves and important cortical structures. Intraoperative monitoring of evoked potentials is a prudent adjunct to some types of surgery.

Most malignant brain tumors respond to external radiation. Radiation can increase longevity and, at times, can allay symptoms when tumors recur. The treatment dose depends on the tumor's histologic type, radioresponsiveness and the anatomic site and level of tolerance of the surrounding tissue. Stereotactic radiosurgery, such as the Gamma Knife®, allows specific irradiation of the glioma. Narrow beams of radiation specifically target only the glioma. The normal brain is spared and does not receive significant exposure.

The use of chemotherapy for brain tumors is somewhat limited by the blood-brain barrier. Chemotherapeutic agents can be administered intravenously, intra-arterially, intrathecally, or intraventricularly. Improved delivery of chemotherapeutic agents through the use of a biodegradable anhydrous wafer impregnated with the drug polifeprosan 20 with carmustine implanted into the tumor bed at the time of surgery shows promise. However, new classes of antitumor drugs targeting cell motility and angiogenesis (most notably thalidomide) are either in development or in clinical trials.¹⁰

Acknowledgments

I wish to thank personally, John L Zinkel, MD, PhD, FACS, Suresh K Gehani, MD, Mark Nuytten, and Steve Wather, RT®, for their expert assistance in obtaining the images for this article.

About the author

Jeffrey J Cortese is a graduate of Baker College of Mount Clemens, Michigan, and has been certified since 1997. He works full time at Mount Clemens General Hospital, and part time at St. Joseph Mercy of Macomb Hospital. He is a member of AST's Neurosurgery Advisory Panel. Jeff was a speaker at AST's 33rd Annual National Conference in Las Vegas in May 2002.

References

1. Galnze WD, Anderson LE, Anderson K. *Mosby's Medical Nursing, and Allied Health Dictionary*. 4th ed. St Louis, Mo: Mosby-Year Book, Inc; 1994: 675.
2. Rubin R, Farber JL. *Pathology*. Baltimore, Md: Lippincott-Raven Publishers; 1988: 1470.
3. Smith-Rocker JL, Garrett A, Hodged LC, Shue V. Prevalence of glioblastoma multiforme subjects with prior herbicide exposure. *Journal of Neuroscience Nursing*. October 1992; 24(5):260-4.
4. Salvati M, Artico M, Caruso R, Rocchi G, Orlando ER, Nucci. A report of radiation-induced gliomas. *Cancer*. January 1991;67(2): 392-7.
5. Val-Bernal F, Ruiz JC, Cotorruelo JG, Arias M. Glioblastoma multiforme of donor origin after renal transplantation: report of a case. *Human Pathology*. November 1993; 24(1): 1256-1259.
6. Baldonado AA, Stahl DA. *Cancer Nursing—A Holistic Multidisciplinary Approach*. 2nd ed. Garden City, NJ: Medical Examination Publishing Company, Inc; 1980:232-235.
7. Hensen DE, Albores-Saavedra J. *Pathology of Incipient Neoplasia*. 2nd ed. Philadelphia, Pa: WB Saunders; 1993; 530-531.
8. Porth CM. *Pathophysiology*. 4th ed. Baltimore, Md: Lippincott-Raven Publishers; 1994: 1187-9.
9. Mahley MS, Mettlin C, Natarajan N, Laws ER, Peace BB. National survey of patterns of care for brain-tumor patients. *J Neurosurg*. 1989;71:826-836.

Images courtesy of Bon Secours Hospital, Grosse Pointe, Michigan.

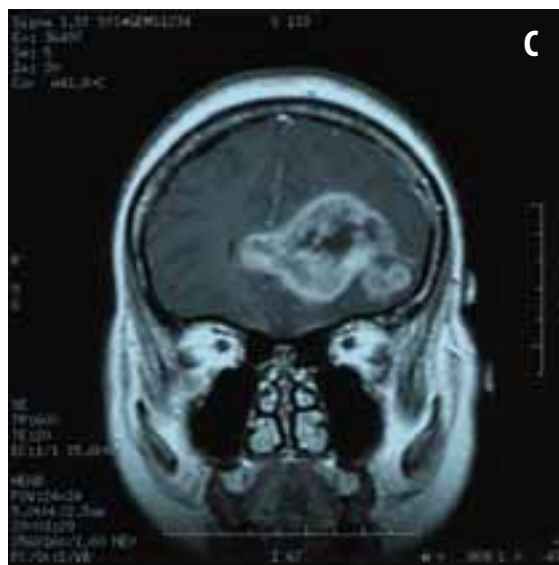
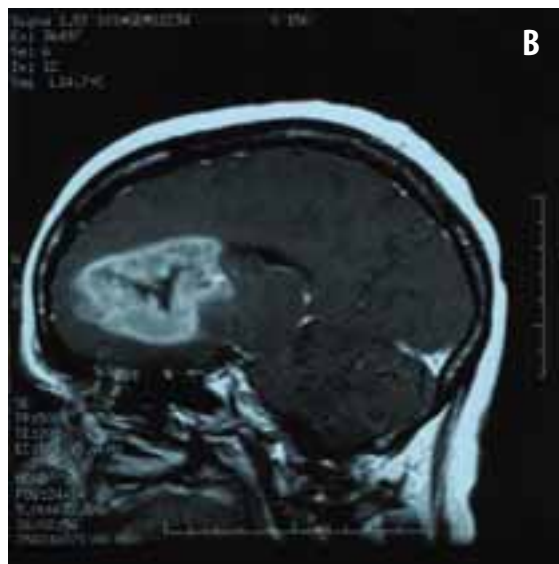
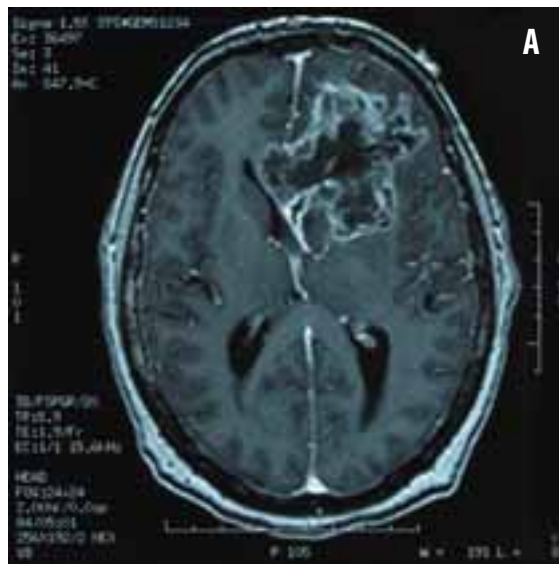
FIGURE 8

MRI appearance of glioblastoma as seen in the coronal, sagittal, and axial planes.

Microvascular decompression for control of typical trigeminal neuralgia

Jeffrey J Cortese, CSTC

TRIGEMINAL NEURALGIA (TN), TRIGEMINAL NEURALGIA IS
OR TIC DOULOUREUX, IS AMONG ORAL MEDICATION. FOR THOSE
THE MOST ACUTE PAIN KNOWN. PATIENTS WHO DO NOT RESPOND
TN AFFECTS APPROXIMATE- TO NONINVASIVE TREATMENTS,
LY 40,000 PEOPLE IN THE UNIT- SURGICAL TREATMENT IS ONE
ED STATES.¹ THE MOST COM- ALTERNATIVE TO DEAL WITH
MON FORM OF TREATMENT FOR THIS DEBILITATING CONDITION.

History of trigeminal nerve surgery

In 1934, Walter Dandy first pioneered the approach to the posterior fossa enroute to the trigeminal nerve complex.² Dandy also outlined the theory of vascular compression as a cause of the pain associated with the condition. The artery pinpointed as the source of compression was the anterior inferior cerebellar artery. This pathophysiology will be explained in further detail.

Peter Janetta was the first neurosurgeon to apply the surgical microscope to trigeminal nerve surgery, making it a relatively safe operation to perform.⁴ Along with this application, Janetta also devised a nondestructive technique to the decompression of the trigeminal nerve.

Anatomy involved

The trigeminal nerve, cranial nerve number V, exits from the pons at the base of the brain. The main function of this nerve is to transmit and receive facial sensations. The trigeminal ganglion is divided into three main divisions: the ophthalmic, the maxillary and the mandibular. The ophthalmic or V₁ branch controls sensation in the eyes, upper eyelids and forehead. The V₂ branch, or maxillary, acts upon the cheeks, lower eyelids, nostrils, upper lip and gums. Along with acting upon the jaw, lower lips and gums, the mandibular or V₃ branch also controls some of the chewing muscles (eg the masseters and buccinators).

Pathophysiology

Although the primary mechanism of TN is not known at the present time, doctors have

observed that an abnormality of the root entry zone into the pons is one source.¹ Vascular cross compression of the nerve is the most common source of the neuralgia. As a person ages, elongation of the vessels is observed. This elongation causes the vessel to adhere to the trigeminal nerve. The pulsation of the vessel, along with the mechanical “rubbing” of the nerve, causes demyelination of the axons, giving the nerve a “raw” spot that makes it susceptible to increased pain sensation.

In 1996, Janetta piloted a study of 1,204 patients that were treated with microvascular decompression of the trigeminal nerve.⁵ He observed that the superior cerebellar artery was the source of compression in 75.5% of patients (Table 1). Interestingly, a small unnamed artery, most likely a vascular anomaly, was the source of compression of 15.4% of the patients.⁵

Clinical presentation

The most common complaint of the TN patient is a sudden onset of lancinating pain that is severe. These electric shock-like pain surges are brief in duration (tics). Some of the triggers observed in the patient are, but are not limited to, light, moving the face while talking, eating and/or brushing the teeth.

Along with the pain associated with trigeminal neuralgia, the patient may have a mild sensory loss in the distribution of the trigeminal nerve. In V₁ neuralgia, the patient may have a decreased corneal reflex. Interestingly, trigeminal neuralgia affects mostly middle age or older women, due to their smaller posterior fossae. That, coupled with the vascular elongation secondary to aging, increases their risk.

Decreased estrogen production has been associated with trigeminal neuralgia in several patients.

Medical treatment

The first line of treatment for the TN patient is the administration of oral medications.³ The primary drug of choice is carbamazepine. Traditionally an anticonvulsant, the drug has proven itself as an effective means of drug treat-

TABLE 1 Sources of TN Compression

Superior cerebellar	75.5%
Anterior inferior cerebellar artery	9.6%
Posterior inferior cerebellar artery	0.7%
Vertebral artery	1.6%
Basilar artery	0.7%
Labyrinthine artery	0.2%
Unnamed small artery	15.4%

ment. Most recently, oxcarbazepine has been used without the side effects of carbamazepine (eg drowsiness, syncopal episodes and gait ataxia). Other drugs, like baclofen and gabapentin, have also been used in the treatment of trigeminal neuralgia, but with limited results.

Surgical treatment

For TN patients who do not respond to noninvasive therapy, surgery is the next course of treatment. There are two categories of surgical treatment for these patients: ablative and nonablative surgeries. The nonablative, microvascular decompression treatment will be discussed first.

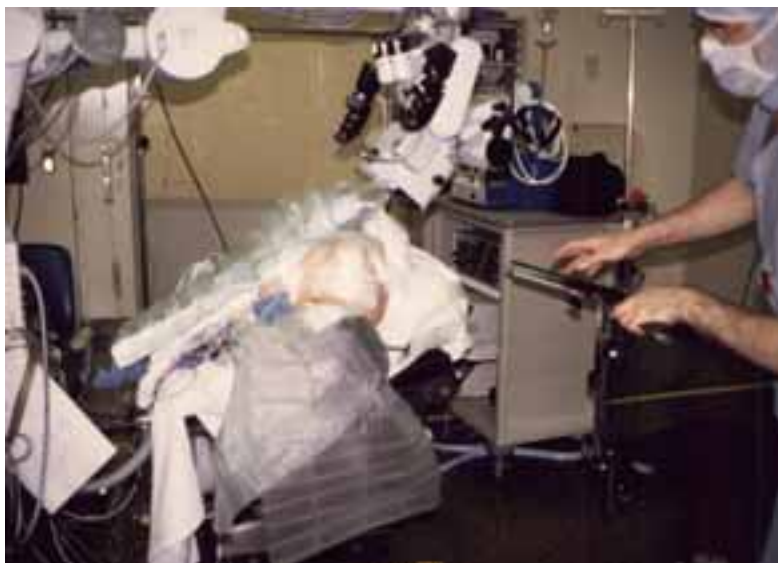The patient is administered general anesthesia and intubated with an endotracheal tube. A three or four-point head-fixation device (Mayfield, Sugita) is attached to the patient's skull. The patient is then rotated into a three-quarter lateral position on the operating table so that gravity aids in the retraction of the cerebellum enroute to the pons. Mannitol and Lasix are administered to help decrease brain bulk, thus eliminating excessive retraction of the cerebellum. Corticosteroids, along with prophylactic antibiotics, are also administered to the patient prior to the incision. The surgeon is seated at the patient's back with the surgical microscope directly across from the surgeon (Figure 1).

A standard craniotomy set-up is all that is needed for this surgery (Figure 2). A variety of microscissors, forceps, and Rhoton dissectors will facilitate the decompression portion of the procedure. Fibrin glue (Tisseal, Hemaseal®) should be mixed and ready prior to the closure of the incision.

After the surgical site is prepped and draped in the usual sterile fashion, the incision site can be infiltrated with lidocaine with epinephrine 1:200,000 to promote hemostasis. A lazy-s incision is made two fingerbreadths behind the hairline with the central third of the incision directly behind the mastoid process. The incision is carried further down to the bone with the monopolar electro-surgical unit. A self-retaining retractor is placed into the wound, while creating a 3 cm by 3 cm exposure via sub periosteal dissection.

A 7 mm round, acorn, or 14 mm craniotome is used to fashion a craniectomy into the posterior fossa. The inner table of the skull is rongeured away using a Beyer-Lempert, Leksell, or a Kerrison rongeur. The borders of the bone removal are determined by the inferior margin of the lateral sinus and the medial margin of the sigmoid sinus. Any bleeding is controlled by application of bone wax. If the sinuses are damaged during exposure, attention to the repair and reconstruction of these sinuses must be undertaken before proceeding with microvascular decompression.

Once a sufficient craniectomy has been performed, the surgical microscope is draped and brought into place. Any vessels on the dural



surface are coagulated with the bipolar unit prior to the opening of the dura. A durotomy is performed using a #11 blade. The durotomy is extended in a cruciate fashion using Metzenbaum or Jones scissors. The edges of the dura are tacked up using 4-0 silk or braided nylon and a TF needle or tagged with mosquito clamps, exposing the cerebellar hemisphere.

A self-retaining brain retractor (Leyla, Mayfield, Sugita) is attached to the head holder or operating table. A variety of retractor blades should be available to the surgeon, along with various sizes of nonadherent gauze (Adaptic™). The rationale for the gauze is that it is placed under the retractor blades to disperse the force

FIGURE 1
Patient positioned for microvascular decompression.

of the blades onto the gauze instead of on the surface of the brain. The cerebellum is retracted inferiorly and medially, exposing the bridging superior petrosal vein. This vein can be sacrificed with the bipolar unit and divided with microscissors without any side effects to the patient.

Cerebrospinal fluid is evacuated from the subarachnoid space using gentle suction, facilitating the brain retraction and exposure. Any arachnoid fibers are divided by sharp dissection using an arachnoid knife and microscissors. The retractors are further advanced on top of the cerebellum, exposing the lateral portions of the trigeminal and oculomotor nerves (Figure 3).

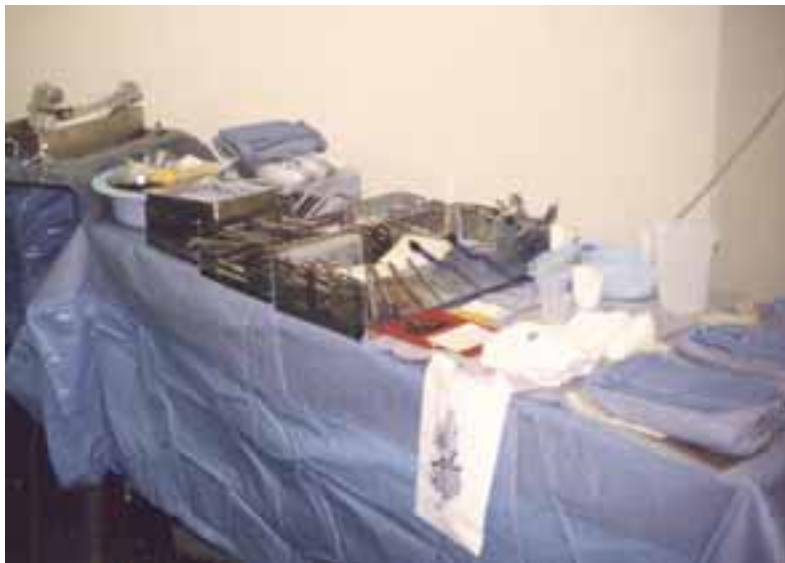

FIGURE 2 Further retraction exposes the root entry zone, along with sharp and blunt dissection.

Standard craniotomy setup. Final vessel and nerve exposure are achieved using sharp dissection. The offending vessels are identified and teased away into a horizontal position. This can be accomplished using a variety of microdissectors, microscissors, and microforceps. Extreme care must be taken not to manipulate the vessels too much, causing vasospasm. Alternatively, Gelfoam® soaked in papaverine can help prevent this from occurring.

Once the nerve has been satisfactorily decompressed, a small indentation can occasionally be seen where the vessel has been fixed to the nerve (Figure 4). A small piece of wad-

ded-up Teflon® pledget is placed where the vessel once resided, providing a physical padding between the artery and nerve. The padding is also placed at the root entry zone to prevent dislodging as it is wrapped around the nerve (Figure 5). Fibrin glue can be applied to the nerve and padding to coat and help keep the padding in place, but it is not mandatory. A Valsalva maneuver is performed by anesthesia to ensure that the padding is not going to migrate upon increased intracranial pressure.

The brain retractors are carefully removed, and the wound is copiously irrigated with saline containing a bacitracin antibiotic. The retention sutures are removed from the dura edges. The dura is approximated in a watertight fashion using a running locking suture of 4-0 silk or braided nylon and a TF needle. Fibrin glue is then sprayed onto the dura surface, thus decreasing the chance for a cerebrospinal fluid leak. A cranioplasty with methyl methacrylate or hydroxyapatite may be performed at this point, but it is not necessary. The wound retractors are removed, final hemostasis is achieved, and the wound is irrigated again with the antibiotic saline. The fascia is approximated using a CT-1 needle and 0-Vicryl® in an interrupted fashion. The subcutaneous tissue is approximated using an X-1 needle and 3-0 Vicryl®, and the skin can either be stapled or closed with a 5-0 plain gut. A sterile dressing is applied, and the patient is transferred to the stretcher and extubated.

Complications

Microvascular decompression surgery carries the same complications as any other neurosurgical procedure with the addition of brain stem infarct, hydrocephalus, facial paresis, hearing loss, and bacterial meningitis.⁵ Careful attention to detail and preoperative planning can help eliminate these complications.

Ablative procedures

Along with the microvascular decompression, other surgical options are available to the TN patient. These groups of procedures are aimed at destroying the trigeminal ganglion rather than

decompressing it. Although these procedures carry the decreased risks associated with conventional surgery, they are typically outpatient procedures and tend to have a less-than-optimal result.

The first of these ablative procedures is a percutaneous rhizotomy by injection of glycerol. This procedure, which is performed under local anesthesia, involves a 20-gauge spinal needle inserted under fluoroscopic control into the foramen ovale via the mouth. After a satisfactory position of the needle is achieved, glycerol is injected around the Gasserian ganglion. As stated, this is less invasive than a decompression procedure, but only provides temporary relief of symptoms.

The next ablative procedure performed involves the same approach, but it is performed under general anesthesia with a larger gauge needle. A balloon is introduced and inflated next to the ganglion, causing a compression injury to the nerve root. This ablative procedure is longer lasting than a glycerol injection, but it carries a risk of loss of corneal sensation and decreased action in the chewing muscles.

Radio frequency rhizotomies have become the most common ablative procedures in the treatment of trigeminal neuralgia. An electrode is inserted in the Gasserian via the same route as

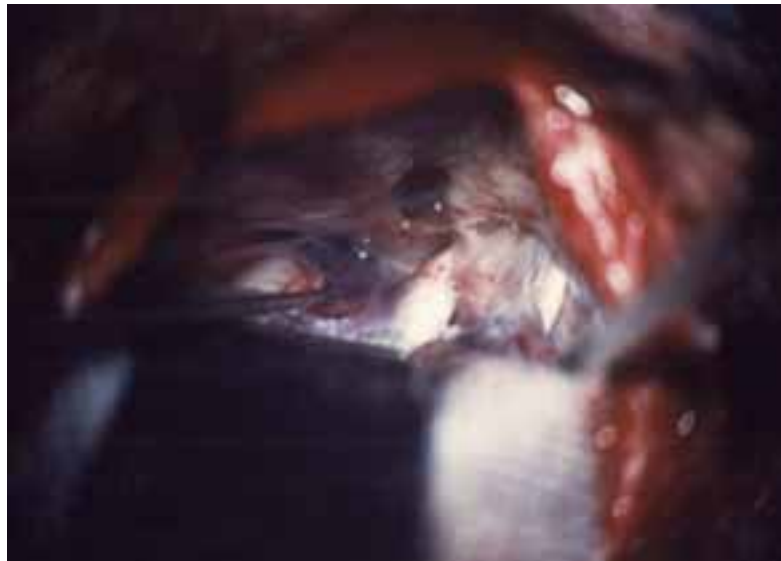


FIGURE 3
Exposure of the trigeminal and oculomotor nerves.

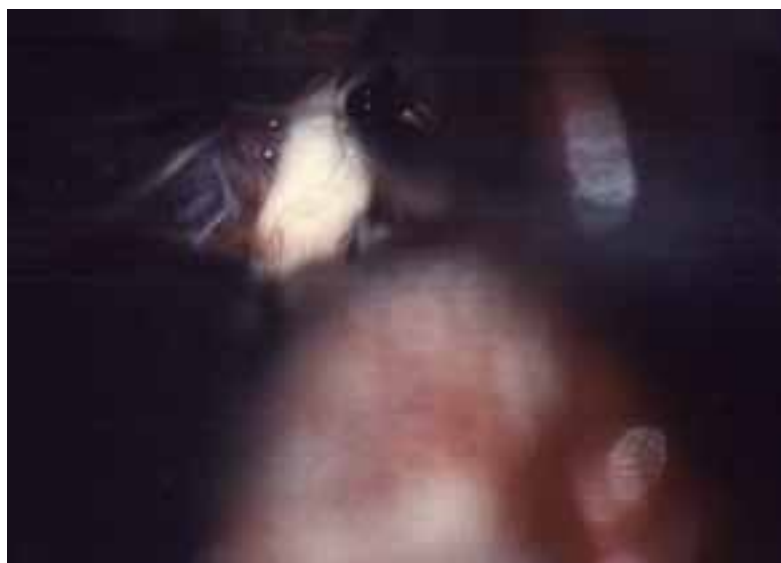

FIGURE 4
After decompression, an indentation in the nerve is still visible.

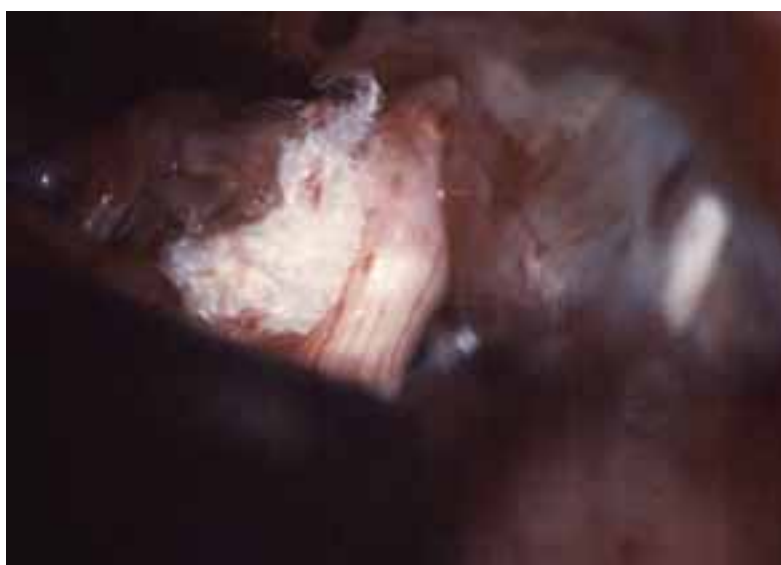


FIGURE 5
Padding at the root entry zone prevents dislodging.

the two previously procedures, and a lesion is burned into the nerve, causing the cessation of pain. This procedure, which is performed under local anesthesia with sedation, provides the best long-term results of the ablative procedures, but some facial parasthesia has been noted.

The latest noninvasive treatment available to TN patients is knifeless surgery. By utilizing specifically focused beams of radiation, the neurosurgeon is able to create a lesion at the root entry zone of the trigeminal nerve, thus ceasing the pain impulses. The two systems commercially available on the market for this type of procedure are the gamma probe and CyberKnife®.

Finally, surgeons have developed a minimally invasive treatment for microvascular decompression. By introducing an endoscope to the cerebellopontine angle via a dime-sized craniotomy in the posterior fossa, the same procedure is performed as conventional microvascular decompression, but without the brain retraction and with the enhanced visualization, lighting, and magnification of an endoscope. These patients are usually discharged within 24 to 48 hours of surgery.⁵

Conclusion

Trigeminal neuralgia is an extremely painful condition that has caused some patients to go as far as to commit suicide to alleviate the pain. TN patients often live for years with the pain before diagnosis. The disorder is commonly misdiagnosed by doctors as oral in etiology. These patients are then referred to the dentist or oral surgeon, who provides the patient with little to no relief. With the appropriate diagnosis, the physician is able to first provide the patient with various means of treatment. The least invasive of these is oral medications. When patients fail to respond, a more aggressive treatment must be employed. The next option for the patient is surgery. The surgical procedure that provides the most long-term pain relief without physically destroying the nerve itself, is microvascular decompression. This surgery, although it carries increased risks, promises the surgical patient with a better quality of life from this

painful and morbid condition. Microvascular decompression offers the best chance of long-term relief and improved quality of life of any of the available surgical procedures, and does so by providing pain relief without producing numbness, as is necessary with the destructive/ablative procedures.

About the author

Jeffrey J Cortese has been a certified surgical technologist in Michigan for eight years. He is employed at Mount Clemens General Hospital, and William Beaumont Hospital-Troy. Cortese, an adjunct instructor for the Surgical Technology Program at Baker College of Clinton Township, is also a full-time student at Baker College where he is attaining a bachelor's degree in health service administration. He plans to become a physician's assistant specializing in neurological surgery.

Acknowledgments

I dedicate this paper to the memory of my grandmother, Yolanda M McGuire, who suffered from trigeminal neuralgia. I also wish to thank Jennifer N Prigg, DO, and John L Zinkel, MD, PHD, FACS, for their continued support.

References

1. (Allen, Jr MB and Miller RH. *Essentials of Neurosurgery: A Guide to Clinical Practice*. New York: McGraw-Hill, Inc; 1995:484-488.
2. Dandy WE. Concerning the Cause of Trigeminal Neuralgia. *Am J Surg* 1934;24:447-455.
3. Drug treatment of trigeminal neuralgia. www.the-support.org (accessed 8/18/04)
4. Janetta PJ. Treatment of trigeminal neuralgia by micro-operative decompression. In: *Woman's Neurological Surgery*, 3d ed., Philadelphia: Saunders; 1988:3928-3942.
5. Pessanha Tavares M. Trigeminal Neuralgia-Microvascular Decompression. Medstudents. Medcenter Solutions of Brazil. www.medstudents.com.br/neuroc/neuroc2.htm (accessed 8/18/04)

Anterior Internal Fixation of Type II Odontoid Process Fractures

Jeffrey J Cortese, CST, BHSA

Overview of cervical spine injuries

Cervical spine injuries comprise approximately 10,000 new spinal cord injuries annually. Approximately 80% of the injured individuals are male and less than 40 years of age. The most common etiology of these injuries is motor vehicle accidents, and midcervical spine (C4-C6) injuries are most frequently involved. The occurrence of odontoid process fractures comprise 10% to 20% of all cervical spine fractures seen in patients.⁴

In addition to immobilization of the cervical spine through utilization of halo jackets and cervical collars, there are specific types of odontoid process fractures that require surgical intervention. This can be achieved either with fixation of the C1-2 articulation, via a posterior approach, or with the fixation of the odontoid process, via an anterior approach. The anterior approach will be discussed in this article.

Special anatomical considerations of C1 and C2

The atlas, C1, and the axis, C2, are two distinct cervical vertebrae. The most distinguishing feature of C1 is the absence of a vertebral body or a spinous process. However, it does have two lateral masses and two arches. The facets of C1 articulate with the occipital condyles superiorly and the facets of C2 inferiorly.

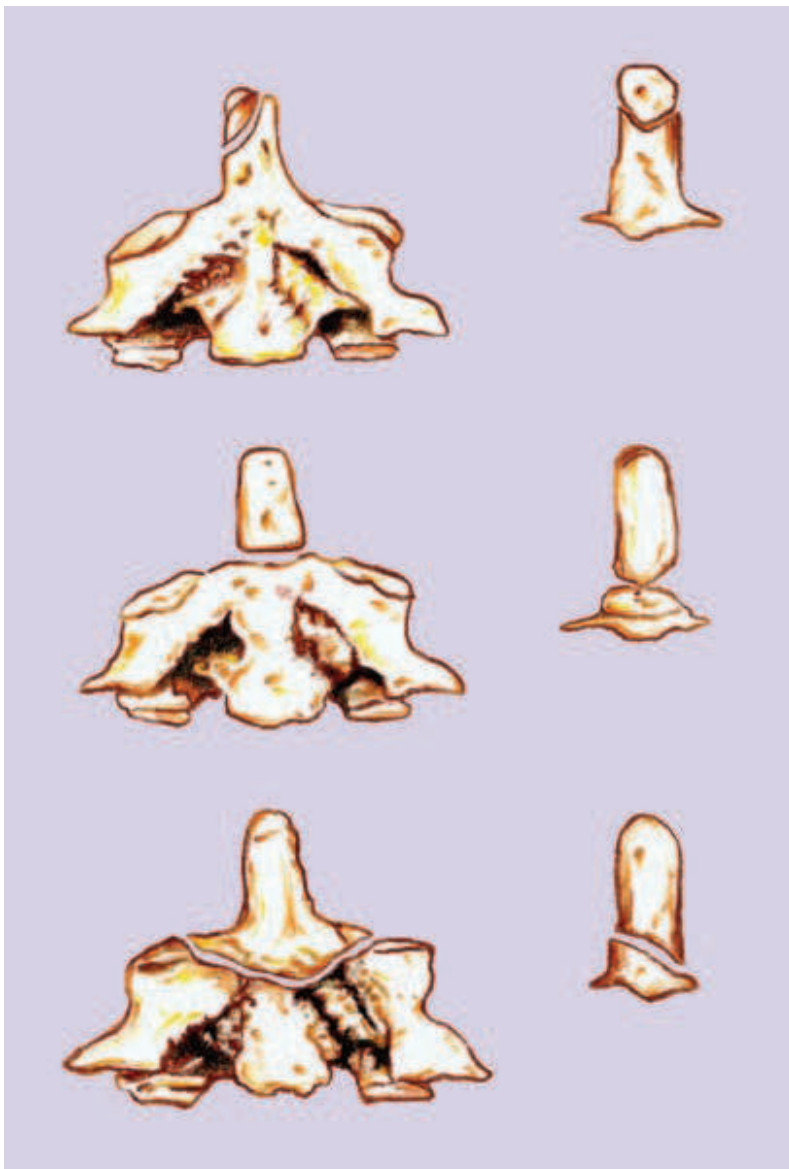


FIGURE 1: Anderson and D'Alonzo classification of odontoid process fractures. From top to bottom: Types I, II, and III.

The most distinguishing feature of C2 is the large odontoid process, the dens, which surfaces from the body of C2. The odontoid is prone to fracture by a traumatic injury and can be compromised by vascular insufficiency or a “watershed” zone at the base of C2.

Along with the bony characteristics of the C1-2 articulation, there are several key ligamentous attachments to consider when dealing with odontoid process fractures. The first is the cruciate ligament, which is shaped like a cross and helps stabilize the odontoid process. This ligament extends from the odontoid process rostrally to the basion, caudally to the body of the axis, and laterally to the lateral masses of the atlas.

Lateral extensions are called transverse ligaments, which help form a band or sling across the dorsal aspect of the odontoid. The alar ligaments are paired bands, which attach each side of the odontoid process to the medial aspect of the occipital condyle. The apical ligaments attach the tip of the odontoid to the basion. These ligaments help limit rotation and flexion of the head.

Classifications of fractures

Odontoid fractures were first described by Lambotte more than a century ago in 1894.³ Anderson and D'Alonzo developed a classification system of the various types of odontoid fractures that had been observed.¹ (Figure 1)

Type I fractures usually involve an avulsion of the tip of the odontoid process. This rarely seen condition is prone to significant ligamentous injury but can be treated with cervical collar immobilization.

Type II fractures involve a fracture at the base of the odontoid. These injuries are associated with ischemic necrosis of the process and are divided into three subtypes.¹ Subtype A includes transverse fractures. Subtype B involves fractures through the posterior superior to anterior inferior aspect of the dens. Finally, Subtype C involves fractures through the posterior inferior to anterior superior oblique aspects of the dens. Of these subtypes, the posterior inferior to anterior superior oblique is the most serious.

Type II fractures also involve anterior displacement of the dens and are more commonly seen than posterior displacement. These types of displacements can originate from flexion and extension injury, respectively.

The final classification factor of Type II fractures involves a nonunion of 20% to 80%.¹ This is frequently seen in injuries in patients older than 50 years of age. It is also seen in injuries that have more than 4 mm of displacement, including posterior displacement.

Type III odontoid fractures involve a fracture through the body of C2. These can be either non-displaced, requiring cervical outhouses or halo application, or displaced, requiring the application of a halo for three months.¹

Radiological examination of odontoid fractures

Suspect fractures of the odontoid process should be assessed by evaluating the initial preoperative lateral and anterior posterior (AP) plain X-ray films and/or unenhanced CT scans of the odontoid.⁴

Fracture type can be determined by the criteria delineated previously by Anderson and D'Alonzo. Fracture orientation should be classified according to the AP direction of the fracture line (anterior oblique, posterior oblique, or horizontal).¹ The degree of displacement is determined by the percentage of displacement of the fractured odontoid fragment, relative to the underlying body of C2.

Treatment of Type II odontoid fractures

In Type II odontoid fractures, there are several treatment options available to the surgeon.² The first option involves putting the patient in halo traction to reduce the fracture to less than 4 mm. The halo jacket should be worn for a period of 12 weeks, then a cervical collar should be worn for a period of six weeks to ensure proper healing of the fracture site.

If there is a delayed or nonunion of the fracture, the surgeon should initially consider placing the patient in a halo jacket before surgical intervention. In addition, the patients who are at a higher risk of nonunion—those who have more than 4 mm of displacement or older patients—should also be placed within a halo jacket.²

Treatment options for odontoid fractures associated with C1 ring fractures may utilize a halo application to allow C1 to heal; subsequently, a posterior C1-2 fusion is performed if nonunion occurs. In addition, the surgeon may choose to perform a posterior C1-2 fusion or an anterior odontoid screw fixation.⁴

Surgical technique

The patient is positioned supine on a well-padded operating room table and administered general anesthesia via endotracheal intubation. If not previously performed, the patient is placed in traction, either utilizing halo traction or Gardner-Wells tongs with 15 pounds of traction.

The head should be extended to help facilitate the trajectory of the screw(s). A small roll may be placed across the patient's scapulae to bring the anterior border of the sternocleidomastoid muscle into view.

After administering one gram of cefazolin, in combination with two grams of Solu-Medrol, the patient is prepped and draped in the proper sterile method. The surgical approach is identical to that of an anterior cervical discectomy, with fusion as described by Smith-Robinson.

A transverse skin incision is made at the C4-5 level. The reason for such depth is that the drill guide must be angled in, so that the guide itself is in total alignment with the central portion of the process. After using monopolar electrocautery to halt any bleeding in the subcutaneous tissue, a small Weitlaner retractor may be placed. The platysma muscle is split, either longitudinally or transversely with Metzenbaum scissors and monopolar electrocautery.

The pretracheal fascia is incised, using coagulation immediately anterior to the sternocleidomastoid muscle. Either blunt-finger dissection, or blunt dissection using a pusher, is employed to create a plane to the vertebral bodies. A handheld retractor, such as a Cloward retractor, is placed to retract the carotid sheath and the esophagus, trachea, and strap muscles medially. Care must be taken to avoid damaging the recurrent laryngeal nerve as it ascends in the neck between the trachea and esophagus on the left side. Any bleeding encountered is controlled by the use of bipolar electrocautery. The normal amount of bleeding encountered with this dissection should be less than a teaspoon. The dissection is carried superiorly to the base of C2. The longus colli muscles are stripped away from the vertebral body, leaving the anterior longitudinal ligament exposed.

A self-retaining retractor, such as an Apfelbaum, is employed to help maintain exposure of the body of C2. A draped fluoroscopic imaging unit is brought into place. An anterior posterior view is first obtained to confirm the correct level of the exposure and medial/lateral alignment. The C-arm is then positioned to obtain a lateral

image in preparation of the screw(s) placement. A biplane fluoroscopic unit is advantageous, because it is capable of producing several AP and lateral images in fast succession, in order to confirm the correct trajectory of the screw within the odontoid process.

The anterior longitudinal ligament is stripped away from the anterior-inferior portion of the vertebral body of C2 with monopolar electro-surgery, exposing the cortex. If the ligament is left intact, it will give a false measurement of the screw and will result in suboptimal purchase of the screw within the dens. A drill guide is inserted into the wound at the base of C2. The drill guide angulation is confirmed with AP and lateral fluoroscopic imaging. A guide wire is drilled into the vertebral body and the odontoid process. This placement is again confirmed with fluoroscopic imaging. Although not mandatory, but advantageous, a second guide wire may be advanced adjacent to the first for optimal fixation of purchase of the screw within the dens. The wire(s) should span the gap of the fracture and stop just before the inner cortex of the process. The wire(s) should be aimed 2 mm posterior to the apex of the odontoid process. Once satisfactory placement of the guide wire(s) has been confirmed, a cannulated depth gauge is inserted over the wire to determine the screw length needed. Partially threaded screws are preferred over fully threaded screws to act as a lag screw to compress the fractured dens into the body of C2. The partially threaded screws, however, can be changed out for fully threaded screws after optimal reduction is achieved in the two-screw technique.

Although the majority of the cannulated screws on the market for odontoid fixation are self-drilling and self-tapping, the surgeon may opt to drill and tap through the cortex of the body of C2 (Figure 2). This must be done with extreme care, and fluoroscopic confirmation must be used; because when the drill is advanced over the wire, the wire may also advance superiorly into the brainstem, thereby causing catastrophic results. The screw(s) are then inserted over the guide wire(s) with the same caution as mentioned above. The screw(s) are then tight-

ened down by hand until satisfactory fixation and purchase of the screw is felt (Figure 3).

The guide wire(s) are removed from the screw(s), and final images are then obtained to confirm placement and reduction of the odontoid process (Figure 4). The wound is adequately irrigated with saline containing bacitracin, polymyxin, and gentamicin. Any bleeding points are controlled with bipolar electro-surgery. The retractors are removed, and the platysma muscle is reapproximated with 3-0 Vicryl® (X-1 needle) in a simple, interrupted technique. An interrupted subcuticular suture of 3-0 Vicryl® (X-1 needle) is placed in the subcutaneous and subcuticular layer. Any skin irregularities can be corrected with 5-0 plain gut (PS-4 needle). Adhesive solution along with Steri-strips™ are placed on the wound and dressed according to aseptic technique. The patient can be placed in a cervical collar postoperatively.

Postoperative CT scanning should be employed to augment plain X-ray film studies, if needed. The presence of trabeculation across the fracture site, in combination with the absence of movement on lateral flexion and extension radiographs, along with the anatomical alignment of the fracture fragment, are indicators that the fusion of the fragment can be considered successful.

Complications

Although neurological- and respiratory-related complications are not commonly associated with odontoid fractures, Przybylski has discussed two articles in which the epidemiology of spinal cord injury in odontoid fractures was described.⁴

The fracture displacement and spinal canal size are identified as factors associated with risk of neurological injury. Whereas posteriorly displaced fractures have been more commonly associated with nonunion after external immobilization therapy, the risk of acute respiratory failure during surgical reduction of these fractures has only been described anecdotally.⁴ A frequent incidence of respiratory distress associated with possible death has been presented by

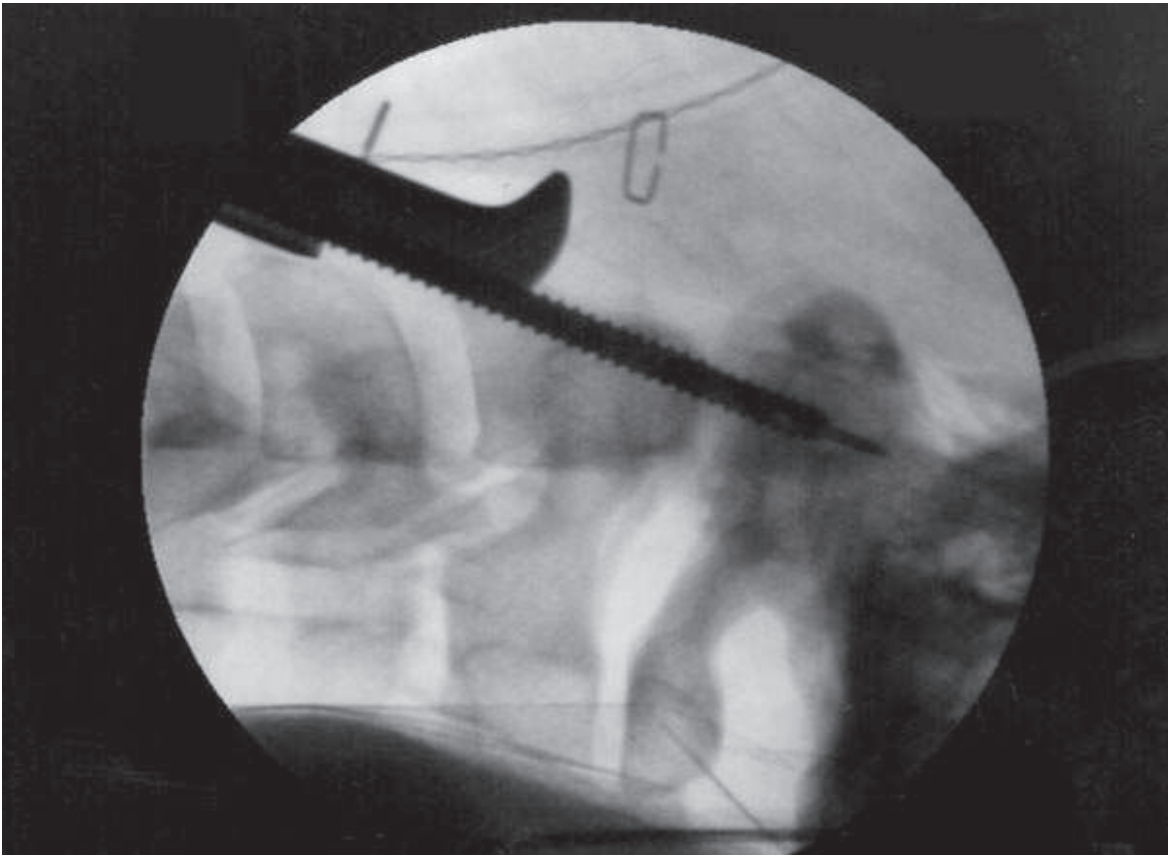


FIGURE 2: Lateral radiograph showing the guide wire in place, spanning the fracture line in the odontoid process with a cannulated tap being advanced along the wire.

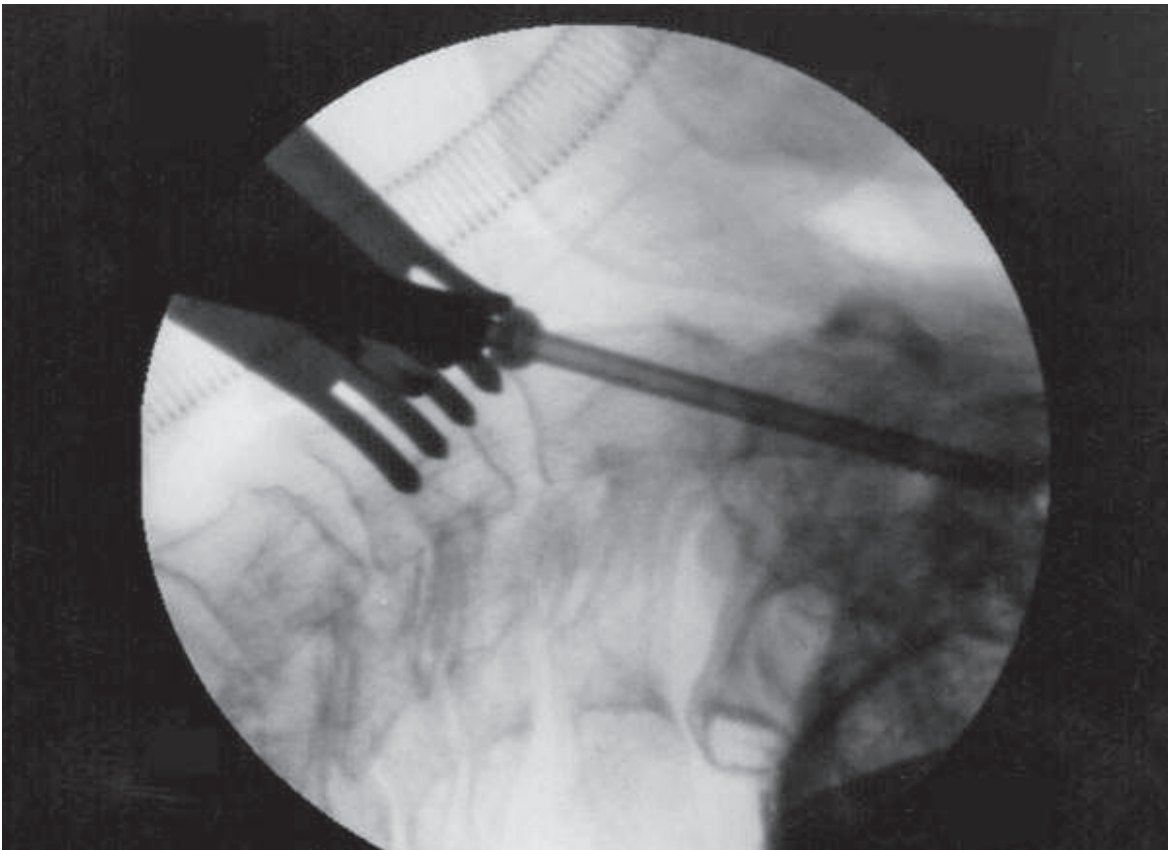


FIGURE 3: Lateral radiograph showing the final tightening of the cannulated, partially threaded, cancellous screw across the fracture site.