



*CE Credit Package 4A*

*10 Credits for \$15<sup>00</sup>*



*Please submit your completed Master Answer Sheet along with payment to*

*AST Member Services*

*6 W. Dry Creek Circle, Suite 200 Littleton, CO 80120*

*Table of Contents*  
*CE Credit Package 4A*



**From Bonesetter to Orthopaedic Surgeon: A History of the Specialty of Orthopaedics**  
**Osteoporosis Unveiled: Answers to Your Questions**

**IntraDiscal Electrothermal Therapy: A Novel Approach to Lumbar Disc Degeneration and  
Herniation**

**Posterior Spinal Surgery**

**The Ilizarov Technique**

**Fat Embolism: A Complication of Long Bone Fracture**

**Posterior Spinal Surgery: 20th Century Advances**

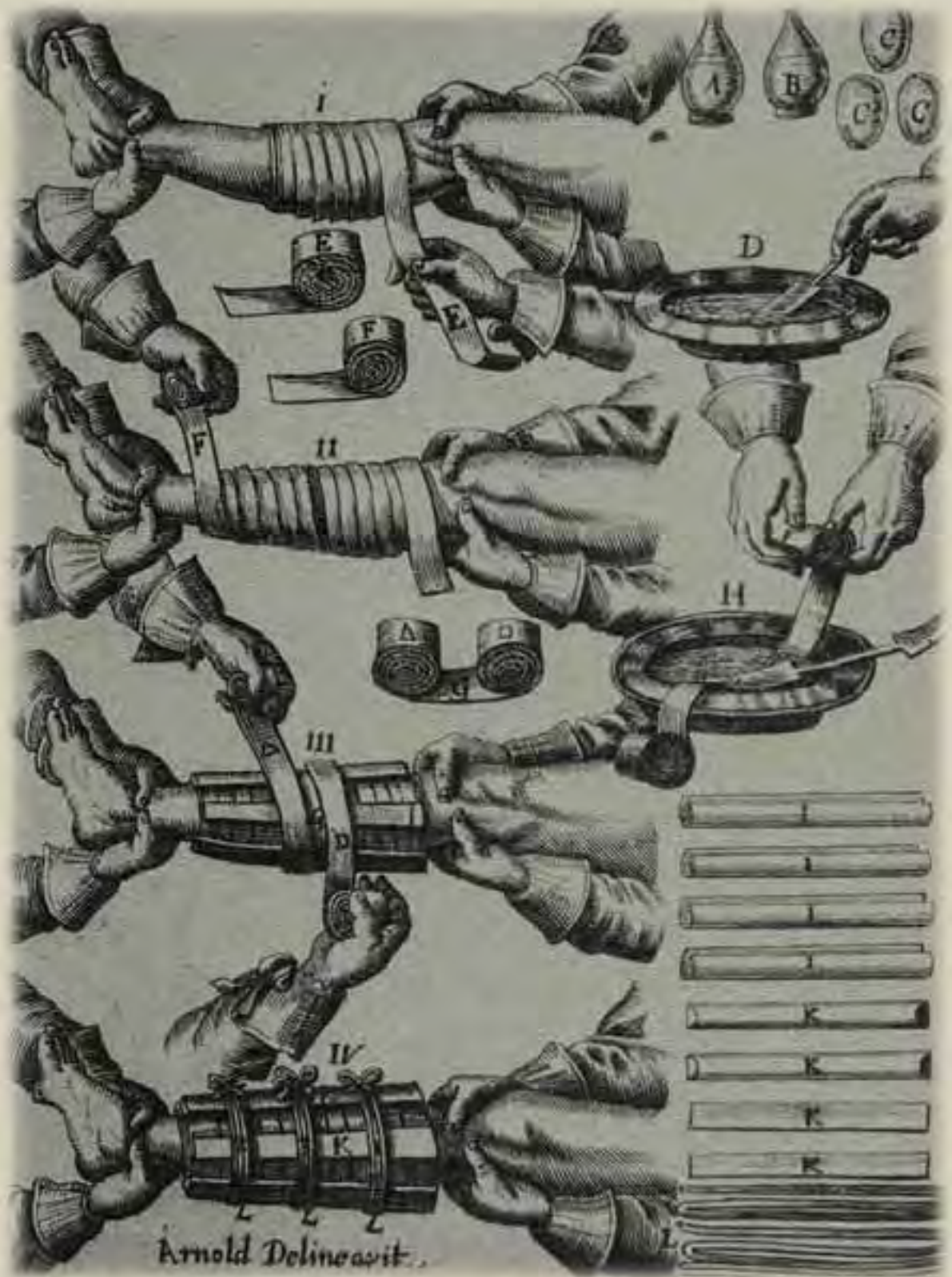
**Bone Healing**


**Anterior Cervical Fusion**

**Anterior Cervical Corpectomy: Fusion and Stabilization**

Procedures  
for  
bandaging  
and  
placing  
wooden  
splints

Simple Arm  
Fracture,  
by Arnold Delineavit  
1666





# From Bonesetters to Orthopaedic Surgeons: *A History of the Specialty of Orthopaedics*

**Deanna Beckett, BS, MSS**

Even before caveman Grogg picked up a club and began to hunt, humans have suffered from fractures. As humankind became more aware of injuries and how to treat them, certain people accepted the responsibility of keeping and using that knowledge to heal. In tribal cultures, that person was, and often still is, a medicine man or bonesetter.<sup>1</sup> In technologically advanced cultures, the best-trained healer for fractures is the orthopaedic surgeon.

The orthopaedic specialty has come a long way since Grogg's day. The transition over time hardly makes sense. From a purely linguistic standpoint, the name, orthopaedic, indicates a specialty with children, not bones and fractures.<sup>2,3</sup> The title of surgeon is equally odd. For hundreds of years, a surgeon was not an educated man, but a tradesman similar to a carpenter.<sup>4,5</sup> Today's orthopaedic surgeons have spent years acquiring specialized knowledge and experience in the field. They treat all age groups and conditions that range from musculoskeletal diseases to compound fractures and joint replacements. How could such a transition take place?

## **EARLY EVIDENCE**

Although there's no physical evidence remaining, skeletons from Grogg's day indicate that Neolithic people may have splinted fractures—probably with bark and sticks, secured with

bandages. Other primitive peoples also found creative ways to immobilize broken limbs. Tribes in South Australia made splints from clay, and the Shoshone Indians soaked strips of fresh rawhide in water and wrapped them around the limb. Rawhide and clay hardened as they dried, protecting the injured bone.<sup>4</sup> As human civilization advanced, specific people were designated as healers and bonesetters. Often the techniques were passed down from generation to generation. They used their skills to treat the injured or sick, and, when appropriate, cast spells and used incantations to encourage healing. These men often paid a price if their treatment failed. As early as 1900 BCE in Babylon, King Hammurabi organized a code of laws that regulated medical practice and set penalties for failure. That code mentions specifically the “Gallabu,” bonesetters who handled minor surgery, dentistry and slave branding.<sup>4</sup>

The first known written instructions for surgery and bone-setting date to 1600 BCE. The Edwin Smith Papyrus, named for an American Egyptologist, described the appropriate treatment of fractures. The papyrus describes treatment for a broken upper arm:

*“Thou shouldst place him prostrate on his back, with something folded between his two shoulders in order to stretch apart his upper arm until that break falls into place. Thou shouldst make for him two splints of linen, and shouldst apply for him one of them both on*



the inside of his arm, and the other of them both on the underside of his arm. Thou shouldst bind it with ymrw [an unidentified mineral substance], and treat it afterward with honey every day until he recovers.”<sup>4</sup>

For a fracture of a skull, the surgeon would apply a potion made from an ostrich egg to dry the wound, and recite an incantation to call for the help of Isis, the Egyptian goddess of fertility. The papyrus also describes conditions that would not be treated. If the surgeon took the treatment of a patient beyond what was described, and the patient died, the surgeon could be impaled.<sup>4</sup>

that sickness was a penalty for sin and called for prayer and fasting. They were suspicious of medicine’s pagan origin and its connection with the teachings of non-Christian Arabs and Greeks. The church’s moral code was equal to law, and any breach could lead to excommunication.<sup>5</sup> Instead of turning to healers and bonesetters, parishioners prayed to saints for healing.<sup>4</sup> When all else failed, they turned to priests for help.<sup>5</sup>

For almost 1,000 years, there were no medical schools or other form of medical training in Western Europe.<sup>4</sup> Priests studied Latin, making them the only ones able to read and use information from medical treatises. By 1100 ACE, the church



Woman  
being bled  
by a  
Barber-  
surgeon,  
a woodcut

by Hieronymus  
Brunschwig  
1500

By the 5<sup>th</sup> century ACE, the writings of Sutra in India offered instructions for limb amputation and constructing iron prosthetics. Hippocrates also wrote a treatise on fractures and dislocations, known for its accuracy of anatomy and physiology, which addressed compound fractures, reduction, dressing, and immobilization. He described a wooden rack to treat a dislocated femur and techniques for extension and counter-extension.<sup>4</sup>

#### THE ROLE OF THE CHURCH

After the fall of the Roman Empire, advances in medicine slowed. The Roman Catholic Church became the governing body for social and religious activity.<sup>4</sup> Church leaders believed

leaders became concerned about the clergy’s practice of healing. They worried that, if treatment went awry, the priests could have blood on their hands, and the church would have a scandal. The church enacted a series of laws that prevented priests and monks from attending public medical lectures and attempting surgery.<sup>5</sup> A later act extended the same rules to physicians. The priests’ servants, the barbers, were the only ones permitted to perform surgical operations.<sup>4,5</sup>

#### QUACKS AND TRADES

Because of their day-to-day interaction with people, barbers had the opportunity to perfect their techniques. Working with

the poor, they could observe and experiment without much fear of retribution. Fractures had to be set; aching teeth had to be pulled.<sup>6</sup> Qualifications for work as a barber had more to do with strength, physique, stamina, speed and dexterity rather than education. These early surgeons were tradesmen and were educated by apprenticeships, not in schools. Physicians, on the other hand, had no practical experience. They were trained in philosophy, but not basic science. Often they treated only the royals, nobles and others wealthy enough to afford their services. When physicians prescribed bloodletting or surgery, they would supervise the work of a barber or surgeon.<sup>5,6</sup>

money and bring hope to the sick.<sup>6</sup> These professions included “quacks, empirics, mountebanks and itinerant operators for the stone, for hernia, and for cataract.” Although they had neither the experience of a barber-surgeon or the education of a physician, and their dealings were technically illegal, these opportunists were generally ignored as long as they were transient.<sup>4</sup>

#### THE ORIGIN OF ORTHOPAEDICS

The 17<sup>th</sup> century brought a better understanding of anatomy, the discovery of the circulation of blood, and a new technique for amputation using a flap.<sup>4</sup> During that time, society’s view



National Library of Medicine, #A023196

## At the Village Barber- surgeons

by David Ryckaert

By the 15<sup>th</sup> century, a barbers’ guild had formed in England to help recruit, train and regulate its members. Other professions had also sprung up. The surgeons and their guild competed with the barbers to treat the same ailments. Physicians were only allowed to treat internal conditions. The druggist mixed medications, but had to purchase chemicals from apothecaries. By 1540, Thomas Vicary helped put an end to the fighting and confusion by securing the king’s permission to unify the guilds of the barbers and surgeons. The same act also outlined the duties of the barber-surgeon, versus that of the physician or the apothecary.<sup>4</sup>

In addition to those who had the legal right to practice, other kinds of healers did what they could to make a little

of the crippled became more sympathetic, due mainly to the Poor Relief Act of 1601 which provided for their care. Treatments for conditions such as club foot started gaining more attention.<sup>7</sup>

This environment set the stage for Nicholas André, a professor of medicine at the University of Paris. André published the first textbook on preventing and correcting musculoskeletal deformities in children. The name of his treatise, *L’Orthopedie*, was created by joining two greek words—*orthos* (meaning free from deformity) and *paideia* (meaning child).<sup>2,7</sup> The book, originally published in 1741, was translated into English, Belgian and German, spreading André’s techniques around the world.<sup>2</sup>

André used exercise, manipulation and splinting to treat deformities, and advised “remedies as are proper to relax tendons and muscles.” André compared his methods of treating limbs to those used to straighten young trees. That illustration became the icon for the specialty of orthopaedics.<sup>2,7</sup>

This newborn emphasis on treating children and bone deformities was financially beneficial to barbers, surgeons and other bonesetters. Some used “straps of sticking plaster” to hold deformed feet into place. Others wrapped the feet in rags soaked a mixture of egg whites and flour, forming a paper-mache-like cast.<sup>7</sup>

The 18<sup>th</sup> century also saw the development of the first orthopaedic hospital. The hospital’s creator, Jean André Veneal, developed the club-foot shoe and methods to treat curvature of the spine.<sup>7</sup>

### **BRINGING FRACTURES INTO THE FOLD**

Several factors from the 18<sup>th</sup> and 19<sup>th</sup> centuries influenced the transition from bonesetting to today’s orthopaedic surgeon. John Hunter’s research on tendon healing paved the way for tendon surgery.<sup>7</sup> Wilhelm Konrad Roentgen discovered X-rays and their ability to image bones. Antiseptic and anesthetic techniques made surgical procedures safer and easier to perform.<sup>1</sup> However, the specialty of orthopaedics remained focused on the deformities of children until the 1890s.

Evan Thomas had been a well-known bonesetter in Liverpool. In spite of his thriving practice, and well-known clients, Thomas wasn’t allowed a hospital position because he wasn’t a physician. Thomas insisted that his son, Hugh Owen Thomas, attend medical school. His son became interested in orthopaedics and joined his father’s practice specializing in children’s deformities. When Evan’s health began to decline, Hugh learned bonesetting techniques to continue his father’s work.<sup>1</sup> Thomas went on to become famous in his own right, developing the Thomas splint, which is still used today. His free, Sunday-morning clinics for the poor were known worldwide.<sup>1,8</sup>

Thomas convinced his nephew, Robert Jones, to attend medical school and join him in practice. After graduation, Jones became his apprentice and took over the practice when Thomas died of lung disease. Jones’ education, experience and location made him the perfect choice for the position of surgeon of the Manchester Ship Canal construction project.<sup>1,8</sup> The canal connected the port of Liverpool to the manufacturing capital of Manchester. Jones set up surgical centers along


the canal to handle injuries of the 20,000 workers. This project quickly made him an expert in treating fractures. Soon, physicians from around the world who docked in Liverpool would stop at Jones’ clinic to learn his techniques.<sup>1</sup>

When World War I began, Jones was the perfect candidate to organize the Army’s orthopaedic services. He was later knighted for those efforts. After the war, Jones helped establish a number of orthopaedic hospitals for children and founded the British Orthopaedic Association in 1918.<sup>1,8</sup>

### **ORTHOPAEDICS TODAY**

Andre gave the profession a name; Jones expanded the specialty to include fractures and the treatment of adults; and countless others developed surgical procedures to add to the breadth of the orthopaedic surgeon’s practice. Today’s surgeons treat the most complicated problems related to bones, cartilage, tendons, ligaments and nerves. They use surgical, medical, orthotic, prosthetic, and physical methods that have been perfected over hundreds, even thousands, of years.<sup>2</sup> Unlike the bonesetters or surgeons that spanned most of our civilization’s history, these specialists have the hands-on experience and years of education to give their patients high quality care.

What about the humble bonesetter? In many third-world countries where a majority do not have access to health insurance or government health care, treatment from a bonesetter is all they can afford. In South America and Africa, the shortage of qualified medical professionals is such a problem that the World Health Organization has funded better training for bonesetters and other medicine men.<sup>1</sup>

The tradition lives on. 

### **REFERENCES**

1. Green SA. Orthopaedic Surgeons: Inheritors of Tradition. *Clin Orthop.* 1999 Jun;(363):258-43.
2. *Turek’s Orthopaedics, principles and their application.* 5<sup>th</sup> ed. Weinstein SL, Buckwalter JA, et al. Philadelphia: JB Lippincott Co;1994:4-5.
3. Lyons AS, Petrucelli JR. *Medicine: An Illustrated History.* New York:Harry N Abrams Inc;1987:599-600
4. Bishop WJ. *Early History of Surgery.* London: Robert Hale Limited; 1960:11, 12, 16-18, 32-34, 48, 49, 58-66, 86-90.
5. Beck RT. *The Cutting Edge: Early History of the Surgeons of London.* London: Lund Humphries; 1974: 1, 79, 120, 121.
6. Santoni-Rugiu P, Mazzola R. Leonardo Fioravani (1517-1588): A Barber-Surgeon who influenced the development of reconstructive surgery. *Plast Reconstr Surg.* 1997 Feb;99(2):570-571.
7. Strach EH. Club-foot Through the Centuries. *Prog Pediatr Surg.* 1986;20:218-222.
8. Great Teachers of Surgery in the Past: Sir Robert Jones (1857-1933). *Br J Surg.* 1967 Feb;54(2):85-90.



# Osteoporosis Unveiled:







# Answers To Your Questions

**Teri Junge, CST/CFA**

**O**steoporosis is considered an invisible or silent disease affecting approximately 28 million Americans. Osteoporosis has no symptoms until the patient notices a loss of height, changes in posture (dowager's hump or kyphosis, Figure 1), or suffers a fracture. Although any bone is subject to osteoporotic fracture, vertebral body (Figure 2), distal radius, and proximal femur fractures are the most common. Almost all fractures in older adults are blamed at least in part to low bone density. Post fracture outcomes can vary from complete recovery to death with many patients suffering chronic pain and permanent disability.<sup>1</sup>

## **WHAT IS OSTEOPOROSIS?**

Osteoporosis is the condition of (sis) porous (poro) bone (osteo) and is *THE MOST COMMON* bone disease.<sup>1,4</sup> Osteoporotic rarefaction is considered a metabolic bone disease, which may be either idiopathic or secondary to another disease or condition. Osteoporosis has many forms that affect both children and adults. This article focuses on Type I—Postmenopausal Osteoporosis and will include a brief discussion of Type II—Senile Osteoporosis. With all types of osteo-

porosis, the patient experiences low bone mass and deterioration of the microscopic architecture of the bone tissue. Structural defects in the bone lead to fragility, causing an increased risk of fracture (Figures 3 A and B).

Simply put, osteoporosis occurs when there is a disruption in normal bone metabolism. Normally, osteoblastic and osteoclastic activity are equal, thereby maintaining the number and quality of osteocytes. The term remodeling is used to describe bone in its normal state of maintenance. A disruption that causes osteoclastic activity to be greater than osteoblastic activity results in a decrease in density (or mass) of the bone.

## **WHAT CAUSES OSTEOPOROSIS?**

The cause of osteoporosis varies according to the type that affects the patient. Type I osteoporosis is also referred to as “postmenopausal” osteoporosis. It is due to loss of estrogen and affects postmenopausal women. Type II osteoporosis is also referred to as “senile” osteoporosis. It is due to long-term calcium deficiency and affects persons (female and male) over the age of 75.

## HOW IS IT DIAGNOSED?

Bone loss due to osteoporosis is usually asymptomatic until a fracture occurs. Osteoporosis that results from hyperthyroidism is the only type of osteoporosis that is truly reversible. Therefore, hyperthyroidism should be ruled out during the process of diagnosis. In addition, blood levels of patients on thyroid hormone replacement therapy (for hypothyroidism) should be monitored to prevent over medication leading to bone loss similar to that associated with hyperthyroidism.<sup>4</sup>

The patient's level of bone mineral density (BMD) is key to diagnosis. Tests to quantify BMD offer several advantages to:

- Detect osteoporosis prior to fracture
- Determine rate of bone loss
- Predict the likelihood of future fracture
- Allow informed decisions about treatment
- Monitor the effect of treatment

BMD can be measured in several ways, all of which are noninvasive, safe, painless, and readily available.

- Dual Energy X-ray Absorptiometry (DEXA or DXA) is the most commonly used method for measuring bone mass. The patient lies flat on a padded X-ray table while the arm of the instrument passes over a selected area of the body. Specific anatomic sites for DEXA measurement include the pelvis, lumbar spine, proximal femur, forearm, and calcaneus. The exam takes approximately two minutes to complete and is very accurate. The patient is exposed to a very low dose of radiation. The exam is useful in determining the tensile strength of the bone to estimate the risk of fracture and assess treatment results.
- Single Energy X-ray Absorptiometry (SXA) is effective in measuring bone density at the calcaneus or distal radius.
- Peripheral Dual Energy X-ray Absorptiometry (PDXA) is also used to assess the extremities.
- Ultrasonic evaluation uses sound waves to measure bone density of the patella, tibia, or calcaneus without exposure to X-ray.



**FIGURE 1**—Dowager's hump—one of the first symptoms of osteoporosis in older adults.

Bone Mineral Density testing is recommended based on the individual's risk profile and is recommended for all postmenopausal women under the age of 65, who demonstrate one or more additional risk factors, and all women over the age of 65.<sup>1</sup>

**COULD I BE AT RISK?**

Theoretically, everyone is at risk for developing osteoporosis; certain factors may accelerate the process (Table 1). Although hereditary risk factors cannot be modified, others are related to lifestyle and can be changed to produce a life-enhancing or life-saving result.

**HOW CAN I PREVENT IT?**

There is no cure for osteoporosis. Although bone density can be increased, the bone can't be fully restored. Prevention is essential and can begin during childhood. The best preventive defenses for osteoporosis include the following:

**Table 1—Osteoporosis Risk Factors**

<b>Non-modifiable</b>	<b>Potentially Modifiable</b>
• Gender ( <i>*Female</i> )	• Cigarette Smoking
• Ethnicity <i>(*Caucasian and Asian closely followed by African-American and Hispanic)</i>	• Low Body Weight <i>(*Less than 127 pounds)</i>
• Advanced Age	• Low Levels of Sex Hormones <i>(Female—Estrogen, Male—Testosterone)</i>
• Personal and Family History of Fracture	• Alcoholism
• Dementia	• Poor Nutrition
• Other Medical Conditions—Non-treatable	• Other Medical Conditions—Treatable
• Body Size <i>(* Small framed individuals)</i>	• Inactivity

\* Indicates greatest risk

**Balanced Diet**

A general well-balanced diet using the food pyramid is recommended with special attention to adequate calcium intake (Table 2—Optimal Calcium Intake). Important sources of dietary calcium include low-fat dairy products, leafy dark-green vegetables, and foods fortified with calcium. Calcium supplements may be needed.

Vitamin D is necessary for absorption of calcium. Vitamin D is synthesized in the skin via exposure to sunlight. Sources of dietary Vitamin D include fortified milk and cereals, egg yolks, salt-water fish, and liver. Vitamin D production decreases with aging. Those at risk for deficiency (elderly or house-bound individuals) should consider a supplementary source. Recommended daily intake is 400-800 IU.<sup>1</sup>

**Exercise**

Weight-bearing and resistance exercises are beneficial to increasing muscle mass and bone mass and density. Bone is living tissue that responds to the demands of exercise by

**Table 2—Optimal Daily Calcium Intake (mg)**

<b>Infant—Child—Adolescent—Young Adult (Male/Female)</b>	
• Birth–6 Months	400
• 6–12 Months	600
• 1–5 Years	800
• 6–10 Years	800-1,200
• 11–24 Years	1,200-1,500
<b>Adult Female</b>	
• 25–50 Years	1,000
• Over 50 Years <i>(Postmenopausal— Without Estrogen Therapy)</i>	1,500
• Over 50 Years <i>(Postmenopausal— With Estrogen Therapy)</i>	1,000
• Over 65 Years	1,500
• Pregnant and Lactating	1,200-1,500
<b>Adult Male</b>	
• 25–65 Years	1,000
• Over 65 Years	1,500

\* Note: Calcium intake of up to 2,000 mg per day appears to be safe in most adults. Adapted from National Institutes of Health.<sup>2</sup>



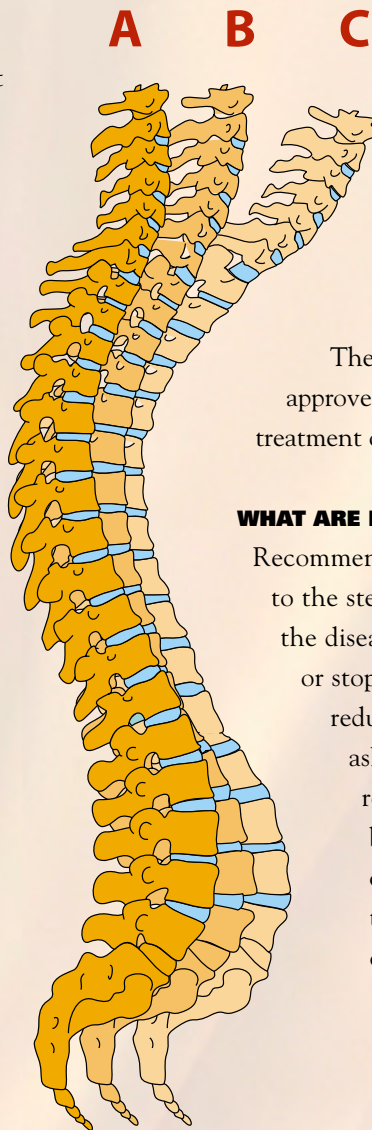becoming stronger and more dense. Exercises that combine the two types of exercise are ideal.

During weight-bearing exercise (eg walking, dancing, and tennis), the muscles and bones work against gravity. This kind of exercise has been shown to improve overall health, improve strength and balance (reducing the risk of falls), and modestly increase bone density.

Resistance exercises, such as weight lifting, swimming and bicycling, increase muscle mass and bone strength.

### Healthy lifestyle

Healthy lifestyle not only refers to a balanced diet and a healthy exercise program, but also to avoiding tobacco use and alcohol abuse. Smoking has been shown to speed the rate of bone absorption. Alcohol abuse has not been shown to affect bone density, but increases the propensity to fall.<sup>5</sup> Moderate alcohol use may actually be associated with higher bone density in postmenopausal women.<sup>1</sup>



### Bone Density Testing

BMD testing is the only way to diagnose osteoporosis. Early diagnosis is crucial to a positive treatment outcome.

### Medication

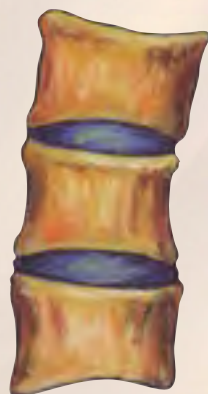The Food and Drug Administration (FDA) has approved four medications for the prevention and/or treatment of osteoporosis.

### WHAT ARE MY TREATMENT OPTIONS?

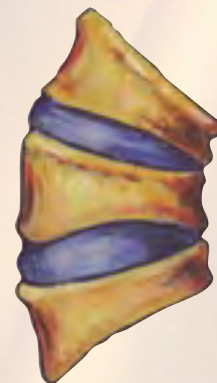Recommended treatments for osteoporosis are similar to the steps used in prevention. Early detection of the disease will allow for early intervention to slow or stop bone loss, increase bone density, and reduce the risk of fracture. Patients may be asked to improve their diets, stop smoking, reduce alcohol intake, and increase weight-bearing exercise. Additionally, four pharmacologic options are currently approved by the FDA for prevention and treatment of osteoporosis.



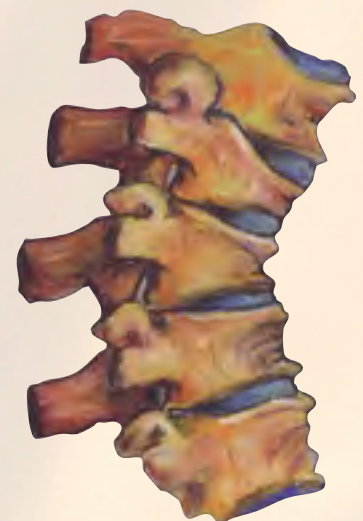**A**



**B**



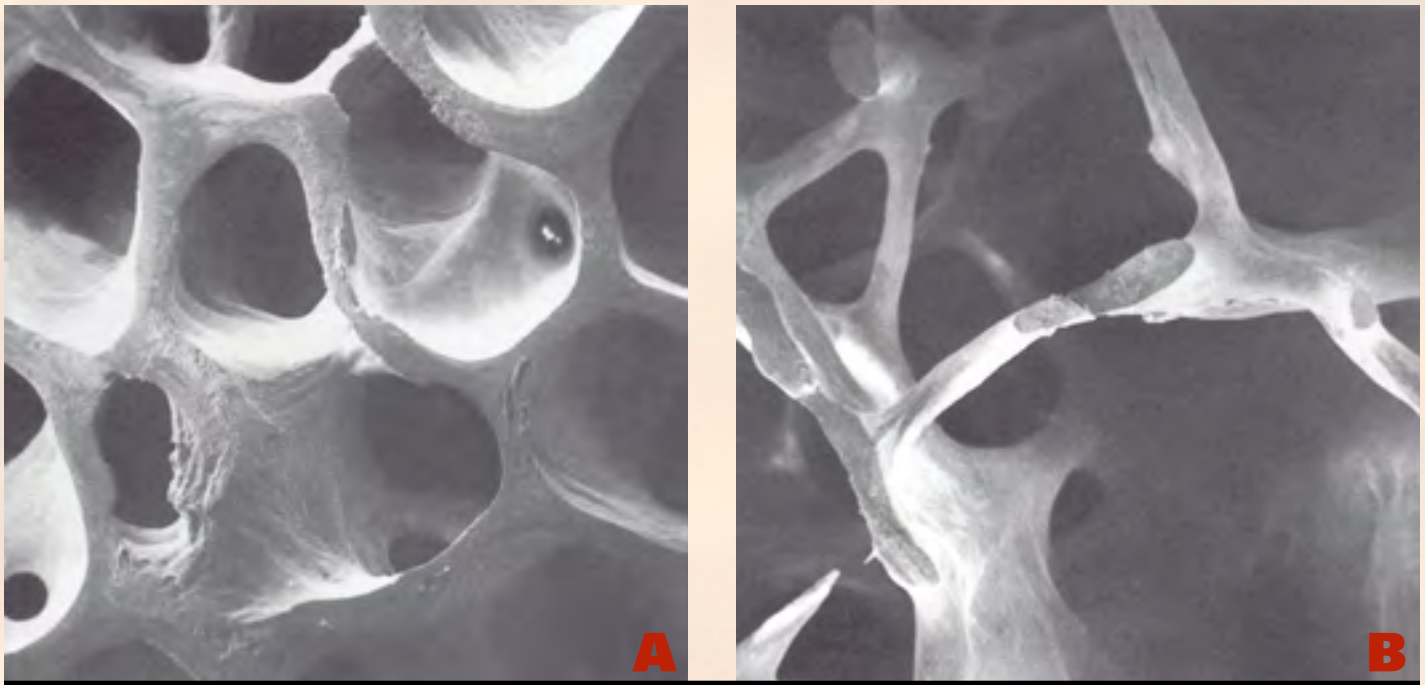
**C**



**Vertebral compression fracture**

**FIGURE 2**—Osteoporotic Changes Affecting the Spine. Normal spine (**A**), moderately osteoporotic spine (**B**), severely osteoporotic spine (**C**).





**FIGURE 3**—Micrographs of Normal **(A)** and Osteoporotic **(B)** Bone. Reproduced from *J Bone Miner Res* 1986; 1:15-21 with permission from the American Society for Bone and Mineral Research.

### **1. Estrogen Replacement Therapy (ERT) and Hormone Replacement Therapy (HRT)**

ERT is approved for both prevention and treatment of Type I osteoporosis. Evidence shows ERT effective in reducing bone loss and increasing bone density in both the spine and hip reducing the risk of fracture. ERT is taken orally or absorbed through the skin from a patch and is effective even if it is started after the age of 70. An increased risk of developing breast cancer and endometrial cancer has been demonstrated. Women with intact uteruses benefit from a combination of cyclic ERT and HRT (using progestin) to reduce that risk.

Additional benefits of ERT/HRT are relief of the symptoms of menopause and increased cardiovascular health. Side effects include bloating, breast tenderness, high blood pressure, and nausea.

ERT/HRT is not recommended for everyone. The risks and benefits of estrogen and hormone replacement therapy must be presented by the health care provider to allow the patient to make an informed decision.

### **2. Alendronate**

Alendronate is a bisphosphonate that is approved for both prevention and treatment of Type I osteoporosis. The preven-

tative dose is 5 mg; the treatment dose is 10 mg. Alendronate is effective in reducing bone loss and increasing bone density in both the spine and hip, reducing the risk of fracture. The drug is taken orally, and the manufacturer recommends that it be taken with a full glass of water on an empty stomach. The individual should then remain in an upright position for at least 30 minutes and wait at least 30 minutes before eating to reduce the side effects of nausea, heartburn, and irritation of the esophagus. Additional side effects include musculoskeletal and abdominal pain.

Alendronate has recently been approved for treatment of osteoporosis induced by long-term steroid use.

### **3. Calcitonin**

Calcitonin is a naturally occurring hormone that regulates calcium and bone metabolism. It is shown to slow bone loss and increase spinal bone density, while possibly relieving pain associated with fractures. Administration of the drug has been approved by the FDA for treatment (not prevention) of osteoporosis and does not show a reduction of non-vertebral fractures. Calcitonin is a protein; therefore, it cannot be taken orally and is available by injection or as a nasal spray. Injectable calcitonin may cause an allergic reaction, flushed

face and hands, skin rash, nausea, and urinary frequency. Runny nose is the only side effect that has been reported with nasal calcitonin.

#### **4. Raloxifene**

Raloxifene is from a new class of drugs called Selective Estrogen Receptor Modulators (SERMs) and is approved for prevention and treatment of osteoporosis. SERMs appear to prevent bone loss throughout the body and to actually increase bone mass. A 50 percent reduction in the risk of spine fractures has been demonstrated following three years of drug therapy. Raloxifene does not appear to negatively affect uterine or breast tissue and side effects, while few, include hot flashes and deep vein thrombosis.<sup>1</sup>

Other pharmaceuticals that are under investigation for use in preventing and treating osteoporosis are sodium fluoride,

vitamin D metabolites, estrogen receptor modulators, parathyroid hormone, and other forms of bisphosphonate and SERMs.

#### **NEED FOR AWARENESS**

For a disease that is highly preventable, osteoporosis has a huge impact on Americans and the American health system. Direct medical costs associated with osteoporosis and the ensuing fractures are currently \$38 million per day. For women in this country, the risk of a hip fracture is equal to the combined risk of breast, uterine and ovarian cancers.<sup>1</sup>

The month of May is National Osteoporosis Prevention Month. Take time this month to share this information with family, friends and co-workers who are at risk. For more information about Osteoporosis and the National Osteoporosis Prevention Month, check out the National Osteoporosis Foundation Web site at [www.nof.org](http://www.nof.org).

## **Osteoporosis in Men?**

- **More than 2 million American men are affected by osteoporosis.**
- **Another 3 million or more are at risk for the disease.**
- **80,000 men suffer osteoporotic hip fractures every year (figures on wrist and spine fractures have not been tracked).**
- **Nearly 27,000 (roughly 1/3) of the men suffering osteoporotic hip fractures will die within one year of the fracture.<sup>3</sup>**

Osteoporosis in men is believed to be under-diagnosed and underreported. Unfortunately, research has been focused on Type I postmenopausal osteoporosis. Therefore, information about the disease and treatment decisions for men affected by

osteoporosis have been based on information and treatments that have been developed for women, although the pathogenesis of the disease is thought to differ between the genders.

The limited osteoporosis research that has been done on men shows that the disease differs from osteoporosis in women in the following ways.

- **The bone loss seen in men is more gradual than in women.**
- **Both lose trabecular bone, but in males the loss is attributed to reduced formation, and in females the loss is attributed to increased resorption.**
- **Correlation of low testosterone levels to reduced bone mineral density (BMD)**


**has not yet been determined.<sup>6</sup>**

**Several risk factors have been associated with osteoporosis in men.**

- **Chronic disease (myeloma, alcoholism, adult onset celiac disease or hypogonadism)<sup>6</sup>**
- **Prolonged exposure to certain medications (steroids, anticonvulsants, chemotherapeutics, and antacids that contain aluminum)**
- **Low testosterone levels**
- **Lifestyle (alcohol use, smoking, poor nutrition, inadequate weight-bearing exercise)**
- **Age**
- **Heredity**
- **Race (osteoporosis is found in males of all ethnic backgrounds, but white males appear to be at greatest risk)<sup>1</sup>**



**QUESTIONS FOR FURTHER CONSIDERATION:**

1. Is there a difference between a disease and a condition?
2. Are you at risk for osteoporosis?
3. What steps will you take to protect your bone health? 

**REFERENCES**

1. National Osteoporosis Foundation, 1232 22nd Street NW, Washington, DC 20037-1292, (202) 223-2226, [www.nof.org](http://www.nof.org)
2. National Institutes of Health, Osteoporosis and Related Bone Diseases-National Resource Center, 1150 17th Street, NW, Suite 500, Washington, DC 20036, 202-223-0344 or 800-624-BONE, FAX (202) 223-2237, TTY (202) 466-4315, E-Mail: [orbd-nre@nof.org](mailto:orbd-nre@nof.org)
3. Osteoporosis Overview Revised 3/98 [www.osteoporosis.org/osteoporosis.html](http://www.osteoporosis.org/osteoporosis.html) Accessed 12/28/99
4. Wheelless' Textbook of Orthopaedics [medmedia.com](http://medmedia.com)
5. Osteoporosis [merck.com/disease/osteoporosis](http://merck.com/disease/osteoporosis) Accessed 5/28/99
6. Seeman, E MD, Osteoporosis in Men, Endocrine News, October Issue 1996 [endosociety.org/news\\_g/endonews/october/osteopor.htm](http://endosociety.org/news_g/endonews/october/osteopor.htm)
7. NOF Physician's Guide: Impact and Overview [www.nof.org/physguide/impact\\_and\\_overview.htm](http://www.nof.org/physguide/impact_and_overview.htm)

**ADDITIONAL SOURCES OF INFORMATION**

1. Auker, Lilley. 1999. *Pharmacology and the Nursing Process*. Chapter 31—Women's Health Agents. Mosby, Inc St Louis
2. Avioli, Louis V. 1993. *The Osteoporotic Syndrome Detection, Prevention, and Treatment*. Third Edition. Wiley-Liss. New York
3. Carmichael, Kim A. 1995. *Reservoir Osteoporosis—Prevention and Intervention*. [www.coolware.com/health/medical\\_reporter/osteoporosis.html](http://www.coolware.com/health/medical_reporter/osteoporosis.html) Accessed 1-22-00
4. Geusens, P. 1998. *Osteoporosis in Clinical Practice A Practical Guide for Diagnosis and Treatment*. Springer-Verlag. London.
5. Physiologic Overview. [www.fc.peachnet.edu/floyd/academics/healthsci/nursing/n2204/ortho/sld003.htm](http://www.fc.peachnet.edu/floyd/academics/healthsci/nursing/n2204/ortho/sld003.htm) Accessed 1-22-00
6. What is Osteoporosis? Mayo Clinic Health Oasis. [www.mayohealth.org/mayo/pted/html/osteopor.htm](http://www.mayohealth.org/mayo/pted/html/osteopor.htm) Accessed 1-22-00



**Lace Ribbon—A Symbol of the Fight for Bone Strength & Independence**

**“The lace symbol was designed by the National Osteoporosis Foundation to emphasize the importance of the fight against osteoporosis. The ivory color represents the outer appearance of the bones, while the lace symbolizes the intricate lattice-like inner architecture of the bone.”<sup>1</sup>**

**MAKE YOUR OWN!**

- Supplies
- Seven inch length of 1/2 inch wide ivory-colored lace
  - Straight pin
- Instructions
- Fashion a loop with the strip of lace
  - Fasten with straight pin, drop of glue, or stitch
  - Embellish if desired (suggestion: pearl or bead placed (glued or sewn)—at the point where lace crosses over itself)

Used with permission of National Osteoporosis Foundation, Washington, DC 20037

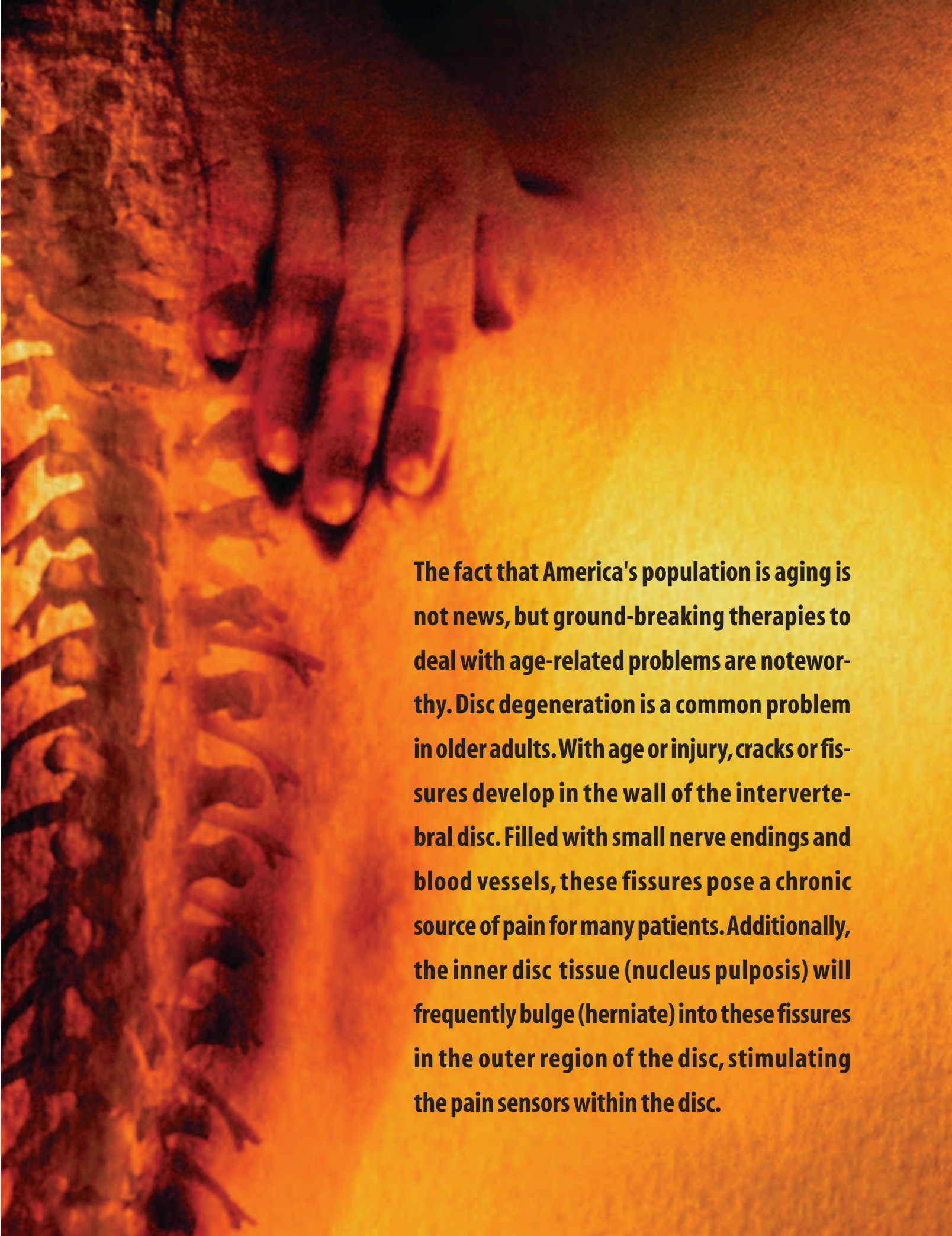


***IntraDiscal  
ElectroThermo  
Therapy™***

*a novel approach to lumbar disc  
degeneration and herniation*

**Jeffrey J Cortese, CST**





**The fact that America's population is aging is not news, but ground-breaking therapies to deal with age-related problems are noteworthy. Disc degeneration is a common problem in older adults. With age or injury, cracks or fissures develop in the wall of the intervertebral disc. Filled with small nerve endings and blood vessels, these fissures pose a chronic source of pain for many patients. Additionally, the inner disc tissue (nucleus pulposus) will frequently bulge (herniate) into these fissures in the outer region of the disc, stimulating the pain sensors within the disc.**

ntraDiscal ElectroThermo Therapy™ (IDET™) is a minimally invasive treatment in which the physician applies controlled levels of thermal energy (heat) to a broad section of the affected disc wall. This heat contracts and thickens the collagen of the disc wall and raises the temperature of the nerve endings. Therapy may result in contraction or closure of the disc wall fissures, a reduction in the bulge of the inner disc material, and desensitization of the pain sensors within the disc itself.

## Bone and ligament anatomy supporting the spinal cord

### Vertebral Column

The spinal column has 33 vertebrae joined by ligaments and cartilage. The cervical thoracic and lumbar vertebrae are mobile, but the sacral and coccygeal segments are fused to form the sacrum and coccyx.<sup>1</sup> There are seven cervical, twelve thoracic, five lumbar, five sacral, and four coccygeal (Coc1 to Coc4) vertebrae (Figure 2). Aging may cause sacralization (fusion of the sacrum and the L5 vertebra) or lumbarization (non-fusion between the sacrum and the S1 vertebra), and congenital spinal variations with partial or complete fusion. Identifying congenital abnormalities is important in the patient with a herniated lumbar disc, since the surgeon must identify the level of the ruptured disc. The level is determined by counting the vertebral bones on routine thoracic and lumbosacral X-rays and correlating the level with imaging studies. Additionally, the L5 and S1 vertebrae may be identified at the time of surgery by their mobility and resonant timbre, the L5 vertebra being mobile and having a sharply resonant sound upon tapping. If levels are questionable, intraoperative X-rays will provide positive identification.

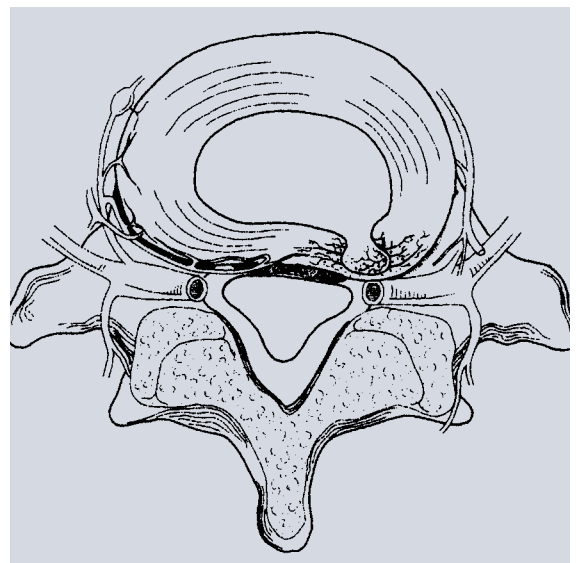
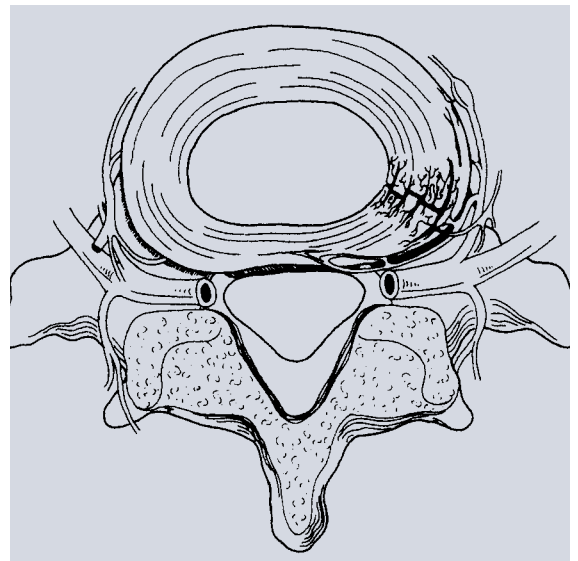
The vertebral column has an S-shaped curve when viewed laterally. The cervical and lumbar spine are lordotic and the thoracic spine is kyphotic. The term normal lordotic refers to ventral convexity. Kyphosis, or “hump back,” occurs with cervicothoracic tumors, trauma, osteomyelitis, degenerating spondylosis, and in

ankylosing spondylitis.<sup>2</sup> Straightening of the lumbosacral spine or abnormal lordosis can be seen in discogenic disease, trauma, tumors, stenosis, and paraspinal muscle spasm.

### Vertebrae and Lumbar Spine

Although the lumbar vertebrae are massive compared to other regions, traumatic fractures do occur regularly in the lumbar region, but neurologic injury is less common than in injuries at higher levels. The L1 vertebra is most prone to fracture as it lacks the rib cage support of its more rostral counterpart, the T12 vertebra.

Importantly, the lumbar spinal canal has an average AP diameter of 15 to 25 mm.<sup>1</sup> A diame-



## FIGURE 1

Disc degeneration and disc herniation.



ter of less than 12 to 13 mm is considered diagnostic of lumbar stenosis. Neurogenic claudication, a symptom of spinal stenosis, is a common and disabling disease that causes bilateral and posterolateral leg pain, cramping and weakness. Compromise of the AP diameter of over 50 percent is usually associated with neurologic deficit.<sup>2</sup>

Compression fractures require decompression and stabilization through anterior and posterior routes. One such treatment for this is interbody fusion. The article, "Operative Solutions to Axial Lumbar Pain" in the May 2000 issue of the *Journal*, details the anatomy of the vertebrae and lumbar spine, as well as procedures for anterior and posterior lumbar interbody fusions.

### *Intervertebral Disc*

Intervertebral discs are made up of a central core, the nucleus pulposus, surrounded by bands of fibrous tissue, the annulus fibrosis. In the annulus, the fibers are arranged in concentric rings so that each successive ring has a different slant than that of the preceding one (Figure 3). This criss-cross arrangement of the fibers gives elasticity to the annulus. Under normal tension, the fibers of two adjacent layers are lengthened and thinned, while with compression they are shortened and broadened. The most peripheral fibers of the annulus insert into the edge of the bone of the vertebral body. The remainder insert into the hyaline cartilage that lies superior and inferior to the disc, covering the cancellous bone of the vertebral body.

The chief component of the nucleus pulposus is a mucoid material containing embedded reticular and collagenous fibers. The nucleus contains 70 to 80 percent water, which gradually decreases from birth to old age. The nucleus is not quite centrally placed, positioned somewhat posterior to the center of the body of the vertebra. The posterior annulus fibrosus behind the nucleus pulposus is thinner than it is in front of the nucleus.

With its high water content, the nucleus pulposus itself is essentially incompressible. However, the pliability of the nucleus pulposus and the

compressibility and stretch of the annulus allow the shape of the disc as a whole to be changed, permitting the movement of one vertebra upon the next.<sup>4</sup>

The discs contribute about 25 percent of the length of the vertebral column above the sacrum. Their high water content means that they are subject to dehydration. As the structure of its polysaccharides undergoes change, the disc loses much of its hydrophilic property,<sup>3</sup> resulting in dehydration. In addition, fibers of the internal layers of the annulus fibrosis grow progressively into the nucleus pulposus.

The disc becomes amorphous, sometimes discolored, and increasingly fibrotic. It develops more tears, loses height, and frequently breaks through cartilaginous plates into the vertebral body, protruding or expelling fragments out of the intervertebral spaces into surrounding areas. This results in pressure on adjacent structures and contributes to the development of hypertrophy of the adjacent bone edges, producing osteophytes, a process that, in the extreme, results in traction spurs.<sup>4</sup>

As the spinal cord passes through the spinal canal, it gives off nerve roots which exit through the neural foramina into spaces maintained rostrally and caudally by pedicles, dorsally by the facets, and ventrally by the adjacent surfaces of the vertebral bodies and the intervertebral discs.

Degenerative changes of the intervertebral discs and the adjacent vertebral bodies, or of the bony facets, compromise the spinal canal and neural foramina. Discs protrude or herniate. Osteophytes develop at the edges of the



**FIGURE 2**

Image of  
entire  
spinal  
column.

vertebrae, or facets and bony misalignments occur.

### Mechanism of IDET

The idea of electrothermal annuloplasty was first conceived by Jeffrey A Saal, MD, and his brother, Joel S Saal, MD, in conjunction with Gary S Fanton, MD. These three doctors founded Oratec Interventions, Inc to develop techniques and instrumentation for the modification of collagen with the use of thermal energy. The doctors had first used human cadavers for a benchmark study of IntraDiscal ElectroThermal therapy. After several trials on cadaveric and animal models, the authors concluded that the whole nucleus pulposus was reduced by 7 percent and the focal point of contact between the disc and electrode was reduced by 20 percent.<sup>7</sup>

A pilot study was then initiated with 37 patients who had pain reproduction following discography. The patients were given the option of an interbody spinal fusion or IDET. All 37 patients chose the IDET procedure. After the study, 28 of the patients had reported reduction of their pain by 57 percent, improved sitting tolerance, and reduction of their pain medications.<sup>7</sup> None of the patients developed any neurological deficit or radicular pain as a result of the procedure.

The doctors had proven that thermal energy has profound changes in the collagenous and neurovascular annular structures of the degen-

erated discs. The collagen fiber molecules composing the annular wall are held in a triple helix structure by heat-sensitive hydrogen bonds. Precise levels of thermal energy break these bonds, contracting and thickening the molecules and, ultimately, the fibers.<sup>8</sup> An excellent analogy of this process is the reaction of a plastic wrap to a heat source. Within a certain period of time, the wrap will shrink.

### Room set-up

The IDET procedure can be performed in any setting that is capable of fluoroscopy. At Bon Secours Hospital, the team uses the operating room for the comfort of the patient, since some sedation is required for the procedure. An electric operating table capable of accommodating the fluoroscope is necessary to allow the surgeon to guide the needle(s) into the disc space(s) (Figure 4). Ideally, a bi-plane C-arm should be used for instantaneous images of the AP and lateral plane of the spine. However, a standard fluoroscopy unit will suffice. A small back table or the top of a case cart is adequate for the minimal amount of instrumentation and supplies needed to perform the procedure. The room is kept absolutely quiet during the procedure. Direct communication between the patient and the surgeon is very important to help guide the needle into the disc space and for the actual “heating” of the disc.

### FIGURE 3

The intervertebral disc.  
Note the concentric rings  
of the annulus fibrosis  
and the central nucleus  
pulposus.




Illustration © Michael Reinhold





**FIGURE 4**

The operating room set-up. The electric operating table is reversed to facilitate the use of the fluoroscopy unit and the case cart is utilized as the back table.

### Patient preparation

Prior to the IDET procedure, the patient undergoes a procedure called a discogram. Using the same approach described for IDET, the surgeon overinflates the disc with contrast media to recreate the patient's symptoms. This exam allows the surgeon to visualize the disc itself by looking at the X-ray films (Figure 5).

The patient is given 2 g of Cefazolin IV piggyback as a preoperative antibiotic. Muscle relaxation and anxiety reduction is achieved with 1 to 5 g of Midazolam (Versed) titrated based on patient need. If the patient becomes too sleepy during the procedure, Romazicon (.1 to .3 mg over 15 seconds) may be given to help reverse the Midazolam.

The patient is placed in a prone position on a well-padded table with blanket rolls and pillows to simulate a Wilson frame.

### Surgical preparation

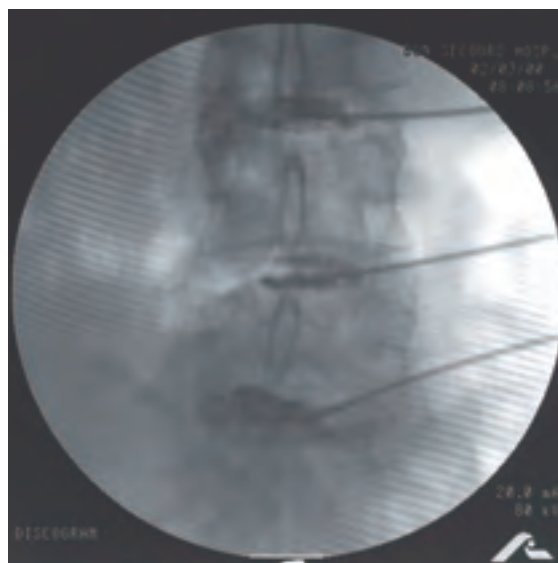
Preoperative scout fluoroscopy images are taken to align the vertebral bodies in the AP as well as lateral planes. The surgeon must line up both pedicles of the vertebral body to ensure that he or she is on the right trajectory into the disc space without entering the spinal nerve foramen. The C-arm is then moved away for the prep of the skin.

The skin prep consists of mechanically scrubbing the patients back for 10 minutes with a half-



**FIGURE 5**

The Discogram X-ray shows the disc spaces of L3-L4, L4-L5, and L5-S1. Note the annular degeneration of the L5-S1 inter space.



and-half mixture of Betadine scrub and solution. After blotting the mixture with a sterile towel, the assistant changes gloves and proceeds to paint the skin with Betadine solution.

The draping of the site only consists of four cloth towels secured with towel clips. This is strictly the surgeon's preference.

### Instrumentation

The same instrument set may be used for discography and IDET procedures (Figure 6). It consists of an instrument stringer, preferably one that has a swivel end, a long Kelly clamp, Crile hemostatic forcep, and a pair of straight Mayo scissors. Along with the basic instrumentation, introducer needles (17 g, 6"), an 18 g 6" spinal needle, and the SpineCATH™ are needed to complete the procedure.

### Operative procedure

The C-arm is brought back into the field. Using the instrument stringer as a pointer, images are taken to determine the entry point of the needle in the skin. The appropriate intervertebral levels are selected and marked with a sterile marking pen. These marks are then transferred 6 cm lateral to the midline for a far-lateral approach to the disc space (Figure 7). The skin is infiltrated with 0.5 percent Marcaine drawn up in a 10 cc slip-tip syringe mounted to a 30 g needle. The needle size is the surgeon's choice, but a 30 g nee-

dle works very well. The patient should feel no more pain than when having an IV line started.

Once the entry site(s) have been sufficiently anesthetized, the spinal needle is introduced through the skin and through the subcutaneous fat. X-ray images are used to confirm the trajectory of the needle in the AP as well as the lateral plane to confirm that the needle is not heading too far medially toward the foramen. Just before the thoracolumbar fascia is entered with the spinal needle, the stylet of the needle is removed, and the syringe containing Marcaine is attached to the needle to add a little more anesthetic to the site. Entrance without Marcaine is quite painful and should be avoided.

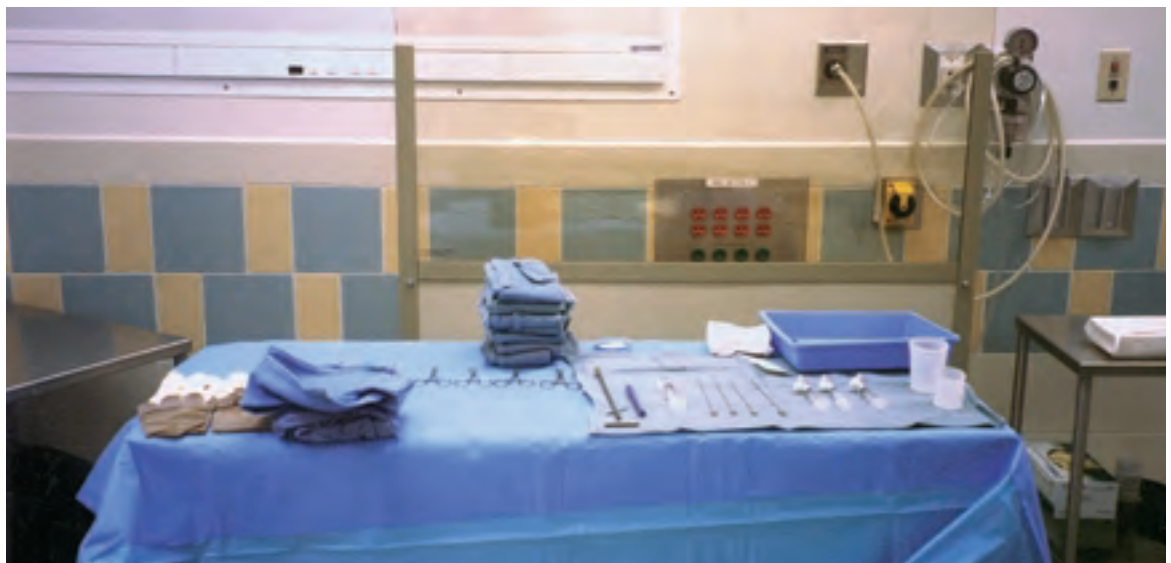Once the needle approaches the disc space, the surgeon will ask the patient to describe any pain in the back, hip, or leg. This is important because any type of radicular pain down the leg indicates that the needle may be brushing up on a nerve root. If this is the case, the surgeon has to withdraw the needle and reposition it. Once the disc space is entered, a slight amount of resistance is met, but very little is felt once the needle is placed. These steps are repeated for as many levels as are being treated.

### IDET

Once all the needles are in place, the surgeon may opt to distend the affected disc spaces with saline to confirm that the disc spaces are indeed

**FIGURE 6**

Very few instruments are required to perform the IDET procedure.



the ones causing the problem. Once this step is done, the SpineCATH™ is inserted through the spinal needle and into the disc space. In a staged fashion the flexible catheter is advanced along the inner annular margin until the resistive heating coil rests along the dorsal inner annular wall, ideally achieving full 360° penetration (Figures 8 and 9).

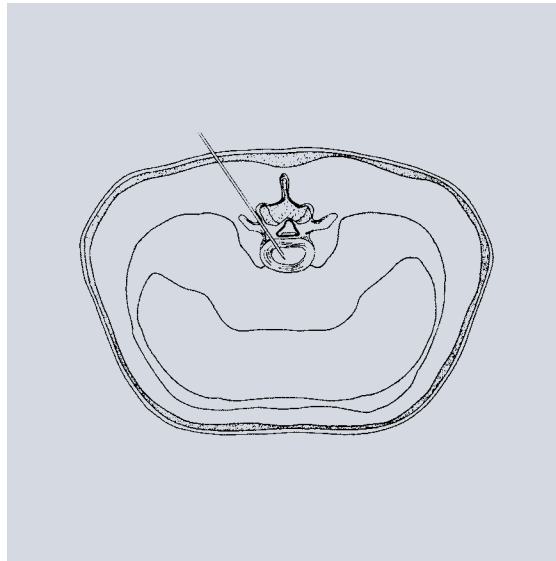
Electrothermal heat is generated in the heating section of the catheter starting at 65° C and increasing incrementally to 90° C, a process that can take 14 to 17 minutes. During this portion of the procedure, it is normal for the patient to feel some discomfort deep in the back. But, if the pain starts to radiate down the leg, the generator is stopped. If the generator is too close to the annular wall and the nerve root or spinal cord is being heated, the catheter is repositioned in the disc space.

In the catheter treatment, the surgeon heats a very large section of the disc, usually, from the three o'clock position to the eight o'clock position of the back wall of the disc.

Complete treatment of one disc takes about hour. Once the desired levels are treated, the SpineCATH™ is withdrawn, the spinal needles are withdrawn swiftly, the back is washed of the prep solution, and small dot-type adhesive bandages are applied to the skin. The patient typically recovers in the hospital anywhere from 40 to 60 minutes before going home.

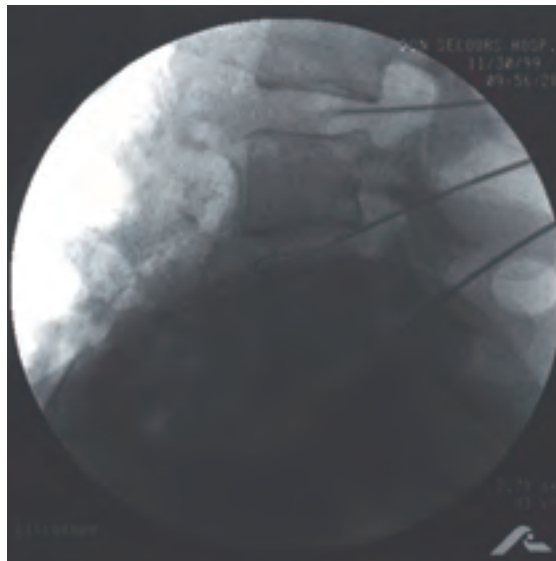
### Postoperative management

For most people there is a period of mildly increasing pain lasting a few days or weeks after the procedure. The normal treatments prescribed for this are rest, ice, pain medications, and anti-inflammatory medications. The patient is instructed not to exert him or herself for the first few weeks, including no housework, lifting or bending. Short walks are restricted to 15-20 minutes, but are not advised within the first postoperative week. Gradually over a month, patients may do light lifting, but they are still restricted from bending, twisting, or heavy lifting. Within the second, third, and fourth postoperative month, the patient is instructed to main-



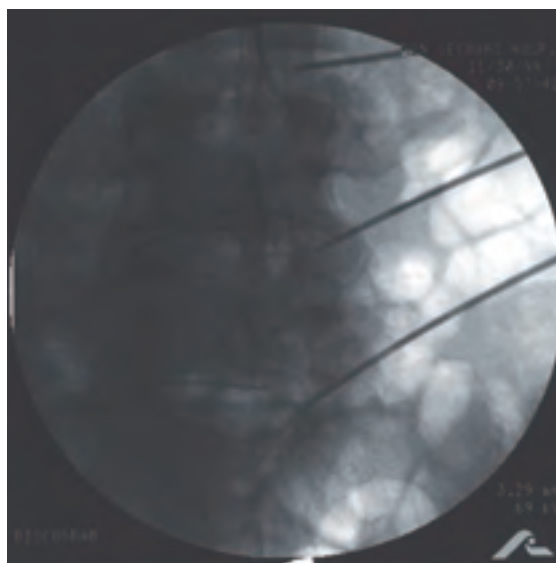
**FIGURE 7**

The trajectory of the spinal needle into the disc space.



**FIGURE 8**

SpineCATH™ electrodes in the discs of L4-L5 and L5-S1 are apparent on these X-rays. The electrode sits along the dorsal inner annular wall providing a full 360-degree penetration.





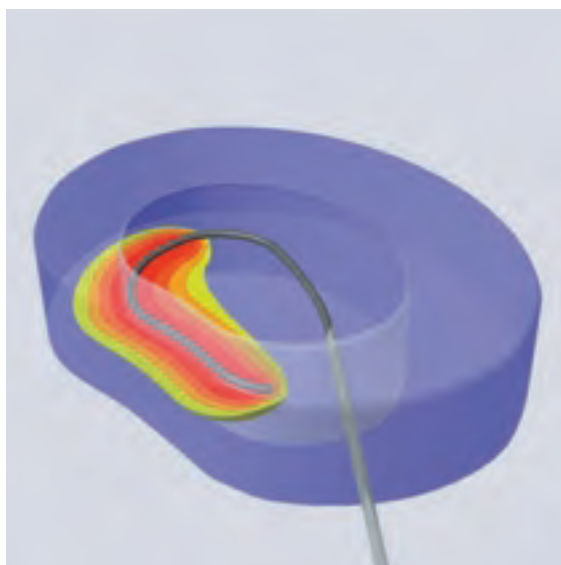
tain good body mechanics. If the patient chooses to do so, mild exercise may be resumed with specialized training. Under no circumstances is heavy work or aggressive physical activity allowed for at least six months following treatment.

### Conclusion

Stable articulations between the mobile vertebrae of the human spine control motion in three planes, flexion-extension, axial rotation, and lateral bending. Like any joint, the articulations may face large and varying loads and ultimately may degenerate and fail. As in the hip and knee,

**FIGURE 9**

Thermal heating of the annulus fibrosus.



degeneration of the spinal joints leads to pain, deformity, and altered function.

Ailments of the “overextended” spine are frequent, accounting for the fifth most common reason for time lost from work and physician office visits, just after the common cold.

The IDET procedure offers a less invasive outpatient procedure with a more convenient recovery. It costs a fraction of that of a comparable surgical fusion and is a less radical alteration in spinal anatomy. The hope is that carefully chosen patients will find this procedure as effective and more appealing than more invasive surgery. The long-term success of the IDET procedure remains to be proven but appears to be promising.

### About the author

Jeffrey J Cortese, CST, has worked at Bon Secours Hospital in Grosse Pointe, Michigan, for five years. He is also a biology/pre-medicine major at Wayne State University and works part-time as a research assistant for the school's department of neurological surgery.

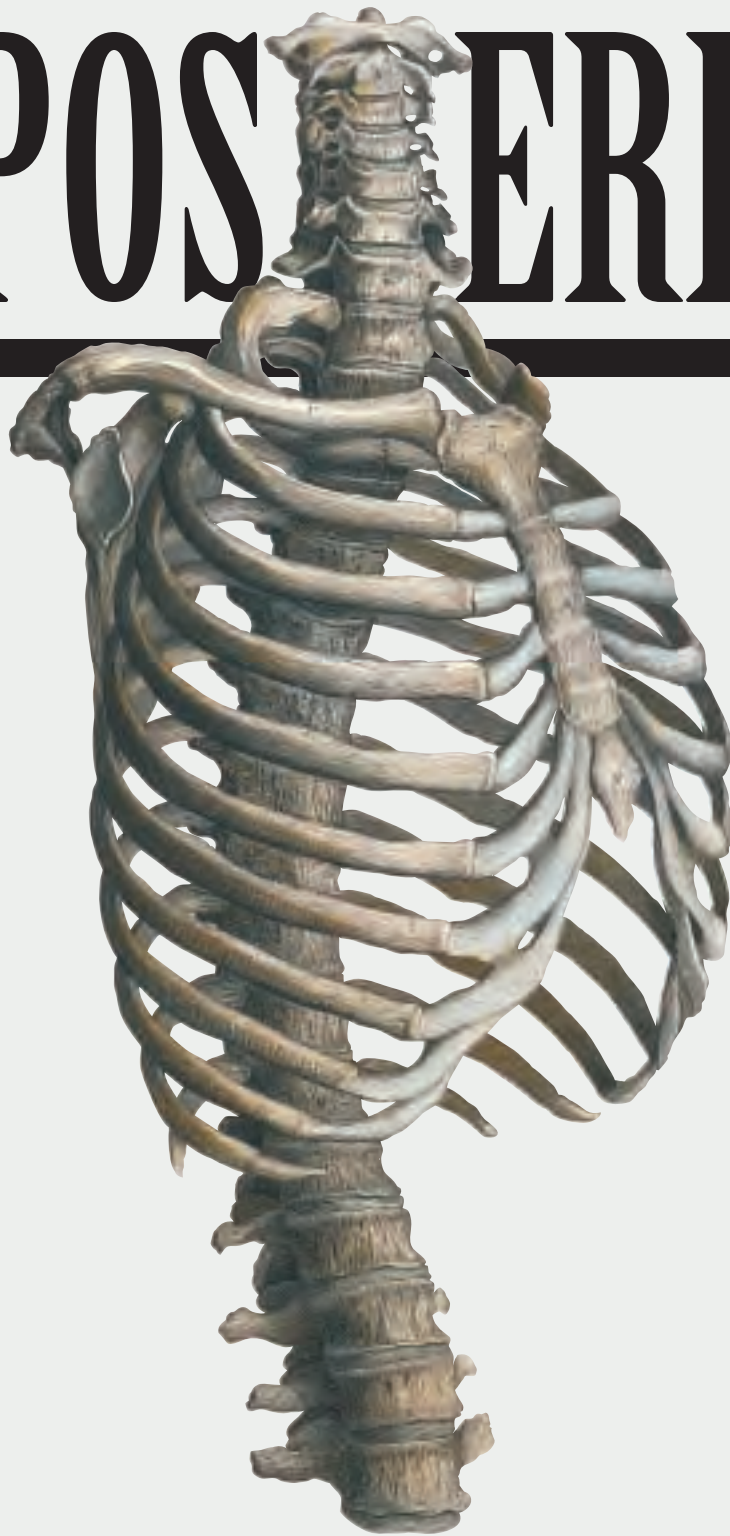*Illustrations courtesy of Oratec Interventions and Science and Medicine.*

### References

1. Truex RC, Carpenter MB: *Human Neuroanatomy*. Baltimore, Williams & Wilkins, 1973, pp 1-290
2. Youmans JR: *Neurological Surgery*, vols 1-6. Philadelphia, Saunders, 1982, pp 551-617.
3. Gower WE, Pedrini V: Age-related variations in proteinpolysaccharides from human nucleus pulposus, annulus fibrosus, and costal cartilage. *J Bone Jt Surg* 51A: 1154-1162, 1969.
4. Hendry NGC: The hydration of the nucleus pulposus and its relation to intervertebral disc derangement. *J Bone Jt Surg* 40B: 132-144, 1958.
5. Feinberg SB: The place of discography in radiology as based on 20 cases. *AJR* 92: 1275, 1964
6. SpineCATH™ IntraDiscal ElectroThermal™ Therapy (IDET™), *Procedure Information*. Brochure. Oratec Interventions, Inc. 1999
7. Saal JA, Saal JS, Ashley J: Thermal Characteristics of the Lumbar Disc: Evaluation of A Novel Approach to Targeted Intradiscal Thermal Therapy. NASS Thirteenth Meeting. San Francisco, California 1998
8. Derby R, Eek B, Ryan DP: Intradiscal Electrothermal Annuloplasty: NASS Thirteenth Meeting. San Francisco, California 1998
9. Rothman RH, Simeone FA: *The Spine*. Philadelphia, Saunders, 1982.
10. Frymoyer JW: *The Adult Spine*. New York, Raven, 1991.
11. Personal interview with John L Zinkel, MD, PhD, FACS, 2000.
12. Bao QB, Yuan HA: The Artificial Disc. *Science & Medicine* 5(1):7, 1998.

# POSTERIOR SP

---



*from ancient Egypt to the late 20th century*

# SPINAL SURGERY

Jeffrey Cortese, CST

**S**PINAL SURGERY HAS BEEN the domain of two specialties, neurosurgery and orthopaedics. Traditionally, neurosurgeons focus on problems inside the dura and bony abnormalities that result in compromise of the spinal cord or nerves, while orthopaedists are principally concerned with skeletal deformity. The role of each specialty in degenerative disc disease and spinal trauma has been less defined. The first article ever published on the herniated lumbar disc was coauthored by an orthopedist and a neurosurgeon. Consequently, both specialties have claimed the herniated disc and are actively involved in the evaluation and treatment of all forms of disc disease.

At one time, this situation was more clear-cut in spinal trauma. Neurosurgeons generally treated patients with neurological deficits, and orthopedists generally treated

patients without neurological deficits.

This article examines the history of all spinal fusion and will be presented in two parts. In this issue, the discussion begins with ancient approaches to spinal surgery and concludes with 20th Century posterior plating systems. In a subsequent issue of the *Journal*, a follow-up article will continue with several screw placement systems and discuss various modular and fixation systems.





## Ancient Egypt

The Edwin Smith papyrus was the earliest known document addressing surgical procedures of the spine.<sup>37</sup> In 1930, Professor James Henry Breasted, a renowned Egyptologist, translated the document, writing careful, detailed commentaries on each case. Breasted believed that, although written circa 1700 BCE, the papyrus itself was a copy of an original manuscript written between 3000 BCE and 2500 BCE.<sup>37</sup> The ancient Egyptian surgeons classified injuries into three categories:

1. *An ailment which I will treat. (Favorable cases.)*
2. *An ailment with which I will contest. (Cases that might be cured.)*
3. *An ailment not to be treated. (Hopeless cases.)*

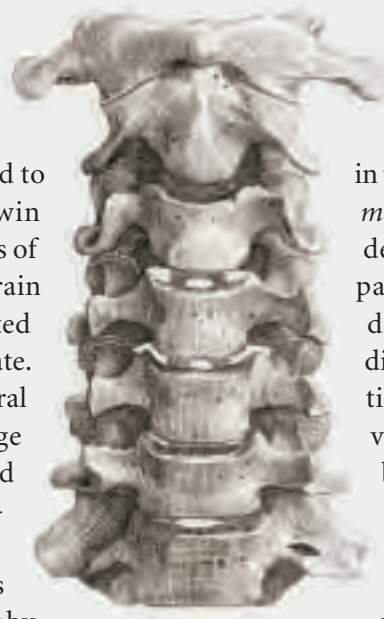
Spinal injuries were relegated to the hopeless category. The Edwin Smith papyrus describes six cases of injury to the spine including sprain in the spinal vertebrae, dislocated vertebrae, and crushed vertebrae. Its author recognized that vertebral injuries with spinal cord damage caused paralysis of the arms and legs, bowel and bladder incontinence, and loss of erection. The Egyptian surgeon treated patients with signs of spinal cord injury by application of meat and honey to the neck and through maintenance of the sitting position. The Breasted translation of case 32 from the Smith papyrus states: "Thou should bind it with meat the first day, thou shall lose his bandages and apply grease to his head as far as his neck, and thou shall bind it with ymrw (sic). Thou shouldst treat it afterward with honey every day and his relief of sitting until he recovers."<sup>37</sup>

## Ancient Greece

Hippocrates (460-377 BCE) discussed the nature of dislocation of the vertebrae and its relationship to paralysis of the limbs, but did not clearly appreciate the role of the spinal cord. He had

observed the results of traumatic spinal cord injury, but did not believe that anything could be done to correct spinal deformity in a living person. Oribasius of Pergamum (325-403 CE) illustrated a stretching-type traction frame for treating fractured spinal columns.

Aretaeus of Cappadocia (150 BCE) observed that in injuries involving the spinal cord, the resulting paralysis originated in some cases at the site of injury. Celsius (30 BCE) noted that death followed quickly when the spinal injury involved the cervical area. Galen (130-201 CE) proved experimentally that interruption of the spinal cord caused paralysis and loss of sensation below the level of injury.



## The Talmud and spinal surgery

Paraplegia, questionably of traumatic origin, was reported in the *Talmud*. An account in the *Talmud* reported by Joshua Leibowitz describes signs and symptoms of paraplegia as well as a differential diagnosis and verification of the diagnosis by postmortem examination. The case properly belongs in veterinary medical literature, because it deals with sheep. The reason for the discussion in the *Talmud* is that the case demanded a ritual decision, since consumption of meat of certain animals suffering from certain diseases, such as bony lesions, is not permitted according to Hebrew religious law. In addition to the case of the sheep, mention is also made of an animal sustaining similar injuries to the spine in a fall from a roof. In spite of the observations of these and other writers, progress was very slow toward an accurate and detailed knowledge of spinal cord function and treatment of injury.

Paul of Aegia (625-690), an outstanding seventh century figure, wrote about spinal injuries, "But if any of the processes of the vertebrae of the spine, as it is called, be broken off, it will readily be felt upon examination with the finger, the broken piece yielding and returning again to its

position, and therefore we must make an incision of the skin externally and extract it and having united the wounds with sutures, pursue the treatment for recent wounds.”

### High and late Middle Ages

Guido Lanfranc (1296) believed prognosis of dislocation of the spine was hopeless, but he was the first to report peripheral nerve structure. Guy de Chauliac (1300-1368) dismissed the matter by saying that one should not labor to cure paralysis from spinal injury. Called the father of modern surgery, de Chauliac’s great book on surgery was completed in 1363.<sup>37</sup>

Ambrose Pare advocated the cure of spinal dislocations by traction. Recognizing the seriousness of operating on spinal injuries he said, “You may make an incision so as to take forth the splinters of the broken vertebrate which driven in pressed the spinal marrow and the nerves thereof.” The diagnosis was made by palpation and evidence of crepitation.

### Elizabethan Age

Petrus L’Argelate (1531) described reduction of a cervical fracture dislocation by pressure applied to the point of angulation. Fabricius Hildanus (1646) noted treatment of fracture-dislocations of the cervical spine by grasping soft tissues of the neck with forceps and applying pressure. If this procedure of apparent reduction was unsuccessful, the surgeon was advised to explore the spinous processes and vertebral arch extricate fragments of bone.

### Age of Reason

In 1745, James advocated an operation intervention for fracture of the spine. Lorenz Heister, in 1768, advocated surgical removal of fragments in cases of fractured spines. Geraud described attempts to remove a musket ball from the body of the third lumbar vertebrae in a patient who

had paraplegia and bladder paralysis. He finally removed the missile on the fifth attempt, and the wound drained. The patient did recover some strength in his legs.

Gervase Markham described several other surgical procedures during this period including an operation by Louis during the war of 1762 in which a metallic fragment was removed from the lumbar spine and the patient made a complete, functional recovery.

### 19th century

F Chopart and Pierre Joseph Desault, writing in 1796, advocated removal of depressed fragments

of bone in spinal injury and suggested trephining the lamina. Henry

Cline, in 1814, resected fractured spines and lamina for a thoracic fracture-dislocation associated with signs of a complete transverse lesion of the spinal cord.

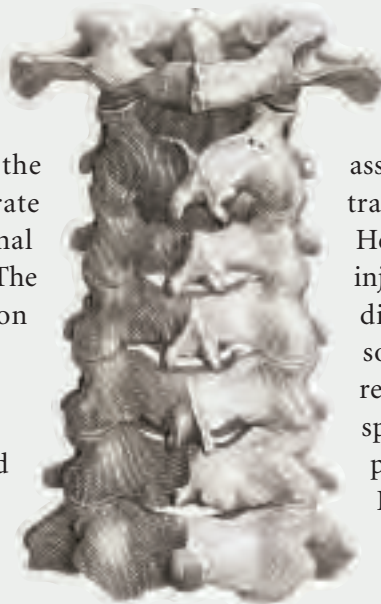He operated within 24 hours of the injury, but was unable to reduce the dislocation and the patient died soon afterward. In 1827, Tyrell reported several operative cases of spinal dislocation with cord compression, but all patients died.

Rogers, in 1835, also reported discouraging results. In 1828, Alban Smith of Kentucky operated on a man who had fallen from a horse

and suffered immediate paralysis of the legs. Smith removed the spinous processes and depressed the lamina, inspected the dura, and closed the incision. The patient survived and partially improved.

### 20th century

At the turn of the century, Hadra in Galveston, Texas, used wires to stabilize a fracture dislocation of the cervical spine; and George W Albee and Russel Hibbs reported a successful fusion in 1911.<sup>1</sup> However, it was not until the 1950s and 1960s that the Harrington rod for spinal instrumentation became available. In the early 1950s, in Houston, Texas, Paul R Harrington assumed



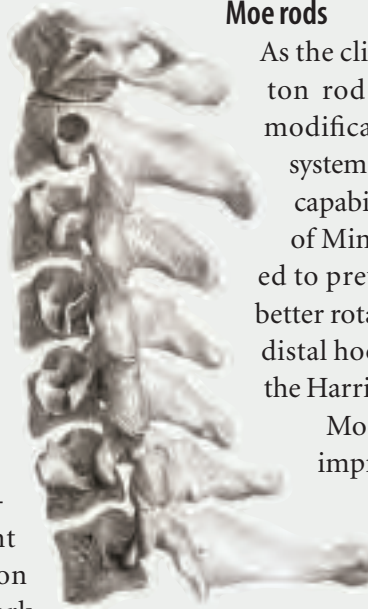
the care of children with progressive neuromuscular scoliosis secondary to polio. Poliomyelitis was epidemic at the time, and there were unacceptably high complication rates with stagnant casting and the major operative procedures of the day. Within this context, Harrington developed a spinal instrumentation system employing hooks and rods to effect spinal fusion as well as correction of the deformed spine. His initial operation required only 20 minutes and utilized facet screws through the vertebral bodies in the corrected position. Although the initial correction and results were satisfying, the results deteriorated postoperatively, leading to the abandonment of the facet-screw fixation concept.

The next step in the development of the modern Harrington rod was to use a treaded rod and hook system to effect correction. Employed in either compression or distraction mode the system was handmade on the night prior to surgery by the surgeon and an assistant. No bone grafting techniques or present-day fusion techniques were employed with these instrumentation systems. Applying knowledge gained from the failures of his earlier attempts, Harrington recognized two important concepts. First, dynamic correction without a good fusion could not work because of the high rate of hook disengagement and rod failure. These two complications produced a recurrence of deformity and failure of the rod. Second, instrumentation must be designed for greater durability, because there was an extremely high rate of instrumentation failure through breakage. Investigators concluded instrumentation would need to withstand seven million cycles of loading before fatigue failure.

Harrington arrived at this figure by doubling the estimated cycles for a one-year period, assuming 10,000 cycles per day. In the early stages of development, these changes were accomplished by doubling the hardness and

changing the fillet design of the ratchets in the rods.

When Harrington presented his modified design at the American Orthopedic Association Meeting in 1960, the widespread use of the current Harrington system began. The modern Harrington rod has gone through more than 47 changes since the original facet-screw system was developed in the early 1950s. Over the last 30 years, the Harrington rod system has been the standard for comparison of instrumentation systems used to effect spinal fusion in the treatment of scoliosis and the fractured spine, particularly at the thoracolumbar junction.



### Moe rods

As the clinical indications for Harrington rod instrumentation expanded, modifications of the basic Harrington system were made to improve stability, capability, and adaptability. John Moe of Minneapolis, Minnesota, attempted to prevent loss of lordosis and gain better rotational control by squaring the distal hook and distal end of the rod of the Harrington system.<sup>6</sup>

Moe believed a square hole would improve control of contouring and rotation better than Harrington's round tube in a round hole. He also employed this system for subcutaneous distraction, which was particularly helpful in young scoliosis patients with significant residual growth potential.

Modifications in hook design were initiated to prevent hook dislodgment. Other changes included a tongue to lock the sublaminar hook, as well as using two upper hooks in the proximal lamina. By distributing the stress between two hooks, scientists believed it would reduce stress on the individual hook site by 50 percent. Bifid facet hooks are now available to gain purchase around the pedicle.

CL Edwards of Baltimore had modified the Harrington system by altering the hook to match the anatomy of the lamina. He subsequently



improved modularity by employing universal rods, pedicle screws, and rod sleeves to effect forces in several directions in addition to distraction.<sup>9</sup> These hook and rod modifications were attempts to improve fixation attained by the original Harrington devices.

Harrington instrumentation revolutionized the surgical care of patients with spinal deformity and traumatic injuries of the spine. Most instrumentation systems available today are based on concepts derived from the development of Harrington instrumentation. All new instrumentation should be measured against Harrington instrumentation with regard to the biomechanical principles and the clinical results of that particular system.


The use of posterior instrumentation led to some significant advances in the care and treatment of spinal fractures and deformity. The Harrington system, though a revolutionary development in spinal surgery, has many deficiencies. Some of the major problems include: rod breakage due to the notches; hook pull-out; lack of rotational control with loss of sagittal plane alignment; and over distraction of the injured spine. These shortcomings encouraged the development of newer spinal implant systems.

The square-ended Moe system partially addressed rotational control. However, to ensure sagittal plane correction, this system requires precise determination of the hook placement and rod contouring. Supplemental sublaminar wiring to control hook pullouts resulted in higher risks of neurologic injury during insertion and removal of these wires. The use of pedicular fixation, which allows shorter fusion levels and preservation of more motion segments, is technically demanding and can cause neurologic injuries.

### Jacobs rodding

In 1979, Rea R Jacobs, collaborating with F Schlaepfer, R Mathys, and Alf Nachemson, designed a system to address these problems. A

rod with hooks controlled by nuts and washers permitted positioning of the hook axially along the rod, thus eliminating the need for deep notches in the rod and their weakening effect. Extra head 316-L stainless steel 5 mm by 7 mm rods were used to achieve maximum strength and increased fatigue life. The upper and lower hooks were in the anatomical configuration necessary to conform to the lamina to which they are applied. A sliding cover is placed over the cranial aspect of the upper lamina to lock the upper hook in place, thus avoiding the use of high distraction loads on the spine necessary for upper hook attachment. Both hooks are rotationally locked into the rod by meshing radial grooves in six-degree increments into the hook and a washer keyed to the rod. Superior and inferior nuts crimped to the flat end of the rod lock the hooks into position. The system was developed to permit maintenance of sagittal plane correction to facilitate implant



removal and allow for the possibility of fusion of only the injured motion segment. Implant removal would then allow restoration of motion of the infused segments after successful fusion and healing of the fractures.<sup>11</sup> In canine models, there is evidence that unfused motion segments undergo degeneration.

The Jacobs locking hook spinal rod helps the stabilization and reduction of the thoracolumbar spine. It provides adequate correction and maintenance of correction with little risk of complications. Attention to detail, especially during upper hook placement, is mandatory.

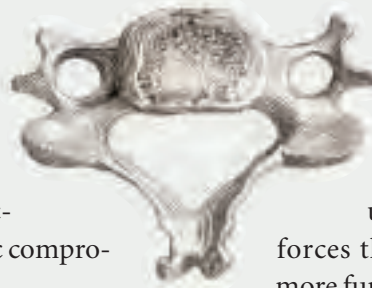### Luque sublaminar technique

The use of sublaminar wiring to achieve multiple points of fixation for spinal stabilization was developed by Eduardo Luque, MD, more than 20 years ago. Luque created his sublaminar wiring technique after observing the use of sublaminar wiring for fusion of a fracture and dislocation of C3 on C4.<sup>22</sup> The advantages of sublaminar wiring were immediately apparent: firm fixa-

tion at multiple points along the instrumented area of the spine and distribution of the corrective forces being applied to the spine, thereby diminishing the risk of osseous failure.

A large number of his scoliotic patients had poliomyelitis with associated osteoporotic bone. In this patient population, Luque found the use of conventional Harrington instrumentation was associated with a high failure rate due to cutting out the hooks. In addition, the socioeconomic situation of many patients made postoperative bracing difficult or impossible.

For the next several years, with increased clinical and laboratory experience, Luque modified the technique numerous times and reached several conclusions.<sup>22,23</sup> He found that the use of double L rods with segmental sublaminar wiring combined with good surgical technique led to a very high rate of arthrodesis. This construct provided excellent correction in both the frontal and sagittal planes. The multiple points of firm fixation allowed significant correction of the curves to occur. Luque cautioned against very aggressive attempts at correction that could lead to neurologic compromise.



### The arrival of segmental fixation

The concept of segmental fixation of the spine dates back to 1902.<sup>19</sup> Fritz Lange developed a technique for tuberculosis spondylitis designed to prevent progressive kyphosis. The technique involved placing buried steel rods in the back, which were fixed to the spinous processes with wires. His reception at the American Orthopedic Association was skeptical. He was thanked for, "...bringing before the members a method of securing fixation of the spinal column without restraint of the respiratory organs of the body, but it is questionable whether this method would be much of use."

In 1963, J Resina described a technique for the use of metal rods fixed to the spinous processes.<sup>28</sup> He felt that it was most effective biomechanically for the corrective forces to work at

right angles to the long axis of the rod. More recently, other methods of segmental fixation have been developed.

### Cotrel-Dubousset system

Since its introduction to the Scoliosis Research Society in 1984, Cotrel-Dubousset (C-D) instrumentation for the correction and stabilization of spinal deformity has generated tremendous excitement and various applications. Both the Harrington and Luque systems were popular. Their biomechanics, however, were confined to the application of unidirectional forces that achieved adequate correction, but often inadequate fixation.

The addition of sublaminar wires, while safe in most experienced surgeon's hands, offers the potential for catastrophic complications. Indeed, many teachers of spinal surgery had great difficulty conveying the fundamentals of sublaminar wiring technique without exposing patients to increased risk. The C-D device, with its ingenious rod design, has allowed for the unique utilization of multiple forces that attack spinal deformity on a more fundamental basis.<sup>5,7,8,13,29</sup>

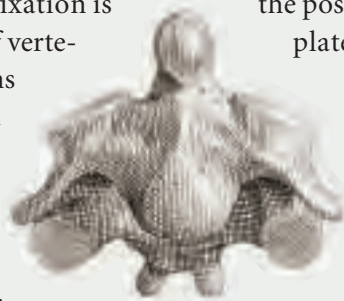The C-D device introduced a significant increase in the number of available surgical options for the patient with spinal deformities. The use of apical distraction or compression, the ability to distract and compress along the same rods, the advantages of rod coupling through the use of device for transverse traction (DTT), and the newer generation devices that offer exciting potential for fixation to the sacrum and pelvis are major milestones in the operative treatment of spinal deformity. Currently, the use of the device is expanding into the field of degenerative spinal disorders and spinal trauma. With tens of thousands of cases now performed worldwide, the Cotrel-Dubousset device has proved to be a safe and effective method in the treatment of scoliosis.

## Texas Scottish Rite Hospital spinal system

A truly universal spinal instrumentation system should be applicable to any area of the spine and to any spinal pathology for which stabilizing or corrective instrumentation is indicated. Such a system has been developed over the past five years at the Texas Scottish Rite Hospital (TSRH).<sup>16</sup>

Originally designed as an adjunctive implant for Luque sublaminar segmental instrumentation (SSI), the original Crosslink device has become a part of a complete, versatile system for correction of adolescent spinal deformity. It utilizes and expands the principles of the C-D system, while simultaneously improving certain technical aspects of implantation and, perhaps more importantly, improving the ease of removing and revising instrumentation already implanted.<sup>2</sup>

Anterior and transpedicular fixation is now possible with the addition of vertebral screws. This greatly broadens the uses of the instrumentation pathologies other than adolescent deformity, including all types of adult degenerative, traumatic, or neoplastic instabilities. With the addition of smaller, pediatric-sized hooks, deformity in very young or skeletally dysplastic patients can be instrumented safely, addressing certain cervical spine instabilities. Because of its ability to extend existing instrumentation cephalad or caudad by the axial cross-linking plates, the TSHR system has evolved into a truly universal system for instrumenting the spine.



## Posterior plating systems

### *Roy-Camille*

Devised over 25 years ago by R Roy-Camille, the posterior approach of the spine is relatively simple, and was later followed by a pedicular-screw plating system in the thoracolumbar spine.<sup>30</sup> He applied posterior fixation with plates and screws to the cervical, thoracic, and lumbar spine. The evolution of the instrumen-

tion has now solved almost all difficulties and technical problems of stabilization of the spine, whatever the pathology.

For thoracolumbar levels, the plates are 1 cm wide to fit into the posterior thoracolumbar vertebral grooves. The interface between the holes is 13 mm. This distance has been selected because the mean distance between two vertebral pedicles is approximately 26 mm with only slight differences along the entire length of the spine. To prevent plate breakage, the plates have reinforced holes. This reinforcement around the holes diminishes stress concentration at the holes so that the relative strength of the plate is the same along its length. When bending a long plate, the contour will be smooth and very regular along the entire plate without any abrupt bends at the screw holes. They are pre-contoured to adapt to the normal sagittal curvature of the posterior aspect of the spine. The same plate can be adapted for use in the thoracic and lumbar level.

The clearance of the screws in the hole plates produces a strong, flexible fixation that prevents screw breakage. This technique may be used at the lumbar spine and at the thoracic spine. The diam-

eter of the screws changes as the size of pedicles changes from thoracic to lumbar region. Using this instrumentation, the surgeon can solve any problem of instability of the spine and reconstruct in a stable manner.

### *Louis plates*

Following the works of Roy-Camille, published in 1969, on posterior vertebral osteosynthesis by pedicle screw plate, René Louis adopted this method to stabilize certain vertebral lesions. After two years, Louis decided to implement his own method with different material while maintaining the use of pedicle screws.<sup>21</sup> Transarticular screws did not seem practical and could be dangerous for the contents of the foramen. In addition, the screw holes were too far apart to regularly allow for exact positioning of the pedicular screws. To avoid a systematic second operation



with ablation of the material, Louis chose short and solid osteosynthesis accompanied by fusion of the posterior joints covered by osteosynthesis. He also modified the method for screw insertion in order to decrease the surgeon's exposure to X-rays. Ultimately, Louis's theory of vertical stability with three vertical columns, one anterior and two posterior, led him to perform anterior osteosynthesis or even combine posterior and anterior osteosynthesis to repair and stabilize each column with the same type of plate.

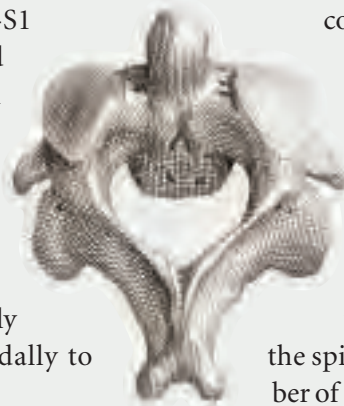Louis began to insert his own plate in 1972.<sup>21</sup> The first plates were made of vitallium, chosen for its excellent tolerance. However, the screws proved to be brittle, and in 1985, he selected stainless steel. The equipment included the plates, screws, and ancillary material, and he designed varied plates according to the vertebral region in question. For L5-S1 osteosynthesis, he created butterfly-shaped monoblock plates resembling the posterior arch and equipped with four holes. The two superior holes are oval shaped for the two L5 pedicular screws, and the two inferior holes are slanted obliquely at 45 degrees outward and caudally to allow for fixation in the sacral ala.

These plates are constructed in three sizes, according to the patient's interpedicular distance. Despite the model, the sacral foramina have been studied according to anatomical data so that the sacral screws can always be positioned away from the S1, S2 roots.

For osteosynthesis extending from L4 or L3 to the sacrum, Louis opted for a pair of symmetrical plates, each having a superior hole for sagittal screw placement into the L3 or L4 pedicles and for two inferior screws for oblique placement in the sacral ala. In the middle section, the plates are equipped with closely spaced holes, four of which are in the L4-S1 plate, allowing for precision screwing of the intermediate pedicles. Louis's system of screw plates for anterior and posterior vertebral osteosynthesis permits short and solid stabilization of the three stabilizing

columns of the spine. The association of a posterior interarticular or anterior intersomatic (interbody) arthrodesis is usually indispensable. An excellent fusion rate at a moderate cost is the principal advantage of this method.

There is much debate in the literature over the optimum spinal internal fixation device that affords the surgeon the benefit of rigid stabilization for fusion maturation while preserving the normal contouring and biomechanics of the spine. For years, the standard was the Harrington rod and hook system. This system allowed the surgeon to manipulate the spinal deformity in the coronal plane, but included excess motion segments in the fusion mass with the additional loss of optimum sagittal contouring. Today, there is great interest in utilizing the pedicle as a means of rigidly instrumenting all three columns of the spine, especially in the presence of posterior element deficiency.



#### ***Transpedicular fixation***

The addition of spinal plates attached to the pedicle screws allows the surgeon to perform wide, aggressive decompressions of the spine while stabilizing a limited number of spinal segments with preservation of the normal contours of the spine.

In 1944, D King first developed the concept of using the pedicle as a means of spinal fixation, and it was not until 1959 that Boucher reported on the actual success of obtaining a posterior fusion by passing screws through the lamina and pedicle into the vertebral body.<sup>17,3,34</sup> Since the early 1960s, numerous surgeons have developed spinal fixation systems using the pedicle as a major component of fixation.<sup>14</sup>

#### **Conclusion**

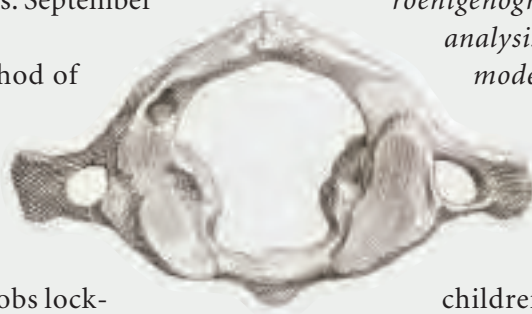
Through the practice and persistence of many medical professionals over the years, treatment of spinal injuries has progressed from untreatable to a condition with a variety of options. The second half of this article will continue to cover the considerable advancements in this field.

## About the author

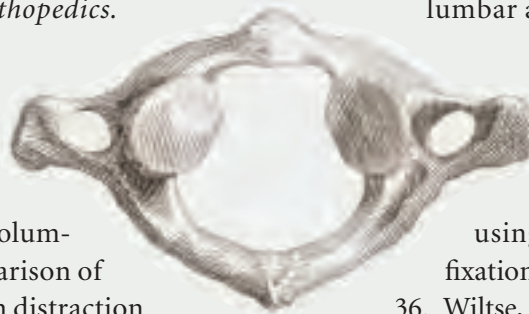Jeffrey J Cortese, CST, has been a certified surgical technologist for five years. He is employed at Bon Secours Hospital in Grosse Pointe, Michigan. He primarily works with the hospital's staff neurological surgeon, John L Zinkel, MD, PhD. With every case, he and Zinkel are constantly enhancing the hospital's neurological surgery service with minimally invasive procedures as well as new techniques and instrumentation.

## References

1. Albee FH. Transplantation of a portion of the tibia for Potts disease. *Journal of American Medical Association*. 1911; 57. 885-886.
2. Birch, Camp, Corin, et al. Rotational stability of various pedicle hook designs—an in-vitro analysis. Presented at the Annual Meeting of the Scoliosis Research Society. Amsterdam, The Netherlands. September 17-22, 1989.
3. Boucher HH. A method of spinal fusion. *Journal of Bone Joint Surgery*. 1959;41B. 248.
4. Boucher, Burkus, Sutherland, et al. Jacobs locking hook spinal rod and the AO fixator intern for fractures of the thoracic and lumbar spine. Submitted for publication. Unpublished data.
5. Cotrel, Dubousset, Guillaumat. New universal instrumentation in spinal surgery. *Clinical Orthopedics*. 1988; 227. 10-23.
6. Denis, Ruiz, Searls. Comparison between square ended distraction rods and standard round ended distraction rods in the treatment of thoracolumbar spinal injuries. A statistical analysis. *Clinical Orthopedics*. 1984; 189. 162- 167.
7. Denis F. Cotrel-Dubousset instrumentation in the treatment of idiopathic scoliosis. *Orthopedic Clinics of North America*. 1988;19. 291-311.
8. Ecker, Betz, Trent, et al. Computer tomography evaluation of Cotrel-Dubousset instrumentation in idiopathic scoliosis. *Spine*. 1988;13. 1141-1144.
9. Edwards CL, Levine AM. Early rod-sleeve stabilization of the injured thoracic and lumbar spine. *Orthopedic Clinics of North America*. 1986; 17. 121-145.
10. Edwards CC. Sacral fixation device—Design and preliminary results. *Scoliosis Research Society Annual Meeting*. Orlando, Florida. 1984.
11. Gertzbein, Jacobs, Stoll, et al. Results of a locking hook spinal rod for fractures of the thoracic and lumbar spine. *Spine*. 1990; 15. 275-280.
12. Gurr, McAfee, Shih. Biomechanical analysis of posterior instrumentation systems after decompressive laminectomy. *Journal of Bone Joint Surgery*. 1988; 70A. 680-691.
13. Gurr, McAfee, Warden, et al. *A roentgenographic and biomechanical analysis of spinal fusions; A canine model*. Baltimore: Scoliosis Research Society. 1988. 77-78.
14. Harrington PR, Tullos HS. Reduction of severe spondylolisthesis in children. *South Medical Journal*. 1969; 62. 1-7.
15. Herrmann HD. Transarticular metal plate fixation for stabilization of the lumbar and thoracic spine. *Acta Neurochir*. 1979; 48. 101-110.
16. Johnston, Ashman, Corrin. *Mechanical effects of crosslinking rods in Cotrel-Dubousset instrumentation*. Hamilton, Bermuda: Scoliosis Research Society. 1986. 77-78.
17. King D. Internal fixation for lumbo-sacral fusion. *American Journal of Surgery*. 1944;66. 357.
18. Krag, Weaver, Beynon, Haugh. Morphometry of the thoracic and lumbar spine related to transpedicular screw placement for surgical spinal fixation. *Spine*. 1988;13. 27-32.
19. Lange F. Support for the spondylolytic by means of buried steel bars attached to the



- vertebrate. *American Journal of Orthopedic Surgery*. 1910; 8. 344-361.
20. Lesion, Bouassakao, Cama, et al. Posttraumatic fixation of the thoracolumbar spine using Roy-Camille plates. *Neurosurgery*. 1982;18. 167-173
  21. Louis R, Maresca C. Lumbo-sacral fusion by internal fixation. *Clinical Orthopedic Research*. 1985;203. 18- 33.
  22. Luque E. The anatomic basis and development of segmental spinal instrumentation. *Spine*. 1982; 7. 256-259.
  23. MacEwen, Bennett, Guille. Autologous blood transfusions in children and young adults with low body weight undergoing spinal surgery. *Journal of Pediatric Orthopedics*. 1990; 10. 750-753.
  24. Magerl FP. Stabilization of the lower thoracic and lumbar spine with external skeletal fixation. *Clinical Orthopedics*. 1984; 189. 125-141.
  25. McAfee, Werner, Glisson. A biomechanical analysis of spinal instrumentation systems in thoracolumbar fractures—Comparison of traditional Harrington distraction instrumentation with segmental spinal instrumentation. *Spine*. 1985;10. 204-217.
  26. Muller, Allgower, Schneider, et al. *Manual of internal fixation*. 3rd ed. Berlin: Springer-Verlag. 1991. 627- 682.
  27. Ogilvie JW, Bradford DS. Lumbar and lumbosacral fusion with segmental fixation. Scoliosis Research Society Annual Meeting. Orlando, Florida. 1984.
  28. Resina J, Alves A. A technique for correction and internal fixation for scoliosis. *Journal of Bone Joint Surgery*. 1977; 59:2. 159-165.
  29. Richards, Birch, Herring, et al. Frontal plane and sagittal plane balance following Cotrel-Dubousset instrumentation for idiopathic scoliosis. *Spine*. 1989; 14. 733-737.
  30. Roy-Camille R, Demeulenaere C. Plating of thoracic, thoracolumbar and lumbar injuries. *Orthopedic Clinics of North America*. 1986; 17. 147-161.
  31. Sasso, Cotler, Reuben. Posterior fixation of thoracic and lumbar spine fractures using DC plates and pedicle screws. *Spine*. 1991;16. 5134-5139.
  32. Schlapfer, Worsdorfer, Magerl, et al. Stabilization of the lower thoracic and lumbar spine: comparative in-vitro investigation of an external skeletal and various internal fixation devices. In: Uhtoff HK, Stahl E, eds. *Current concepts of external fixation of fractures*. New York: Springer-Verlag. 1982. 367-380.
  33. Steffee AD, Sitkowski DJ. Posterior lumbar interbody fusion and plates. *Clinical Orthopedics*. 1988; 227. 99.
  34. Steffee, Biscup, Sitkowski. Segmented spine plate with pedicle screw fixation: A new internal fixation device for disorders of the lumbar and thoracolumbar spine. *Clinical Orthopedics*. 1986;203. 45.
  35. Thalgott, LaRocca, Aebi, et al. Reconstruction of the lumbar spine using AO DCP plate internal fixation. *Spine*. 1989;14. 91-95.
  36. Wiltse, Bateman, Hutchinson, et al. The paraspinous sacrospinalis-splitting approach to the lumbar spine. *Journal of Bone Joint Surgery*. 1968; 50A. 919.
  37. Yashon D. *Spinal Injury*. Appleton-Century-Crofts. 1978. 1-4.
  38. Zindrick, Wiltse, Widell, et al. A biomechanical study of intrapedicular screw fixation in the lumbosacral spine. *Clinical Orthopedics*. 1986; 203. 99.





# THE ILIZAROV TECHNIQUE

BY AMY M CROFT, CST/CFA, BGS

THE HUMAN BODY HAS AN AMAZING ABILITY TO HEAL ITSELF AND, GIVEN THE RIGHT ENVIRONMENT, TO CORRECT ITSELF. THE ILIZAROV TECHNIQUE PROVIDES A WAY TO HEAL BROKEN BONE— NOT THROUGH IMMOBILIZATION, OR ARTIFICIAL SCREWS, METALS OR COMPOUNDS— BUT THE BODY'S OWN PROCESS OF OSTEOGENESIS. DEVELOPED MORE THAN 50 YEARS AGO IN RUSSIA, THE ILIZAROV TECHNIQUE HAS ONLY BEEN USED IN THE UNITED STATES FOR THE PAST 20 YEARS. IT MAY BE USED FOR COMPLICATED FRACTURES, FRACTURE NONUNION OR TO ADDRESS CONGENITAL BIRTH DEFECTS THAT REQUIRE BONE LENGTHENING. IT IS COST EFFECTIVE AND LEAVES MINIMAL SCARRING.



## Configuration

The apparatus designed by Gavriil Ilizarov consists of a fixator frame and implements for attachment to the affected limb. Two external rings, placed proximal and distal to the fracture line, surround the limb and are connected via telescoping rods. These rods allow the osseous surfaces to be either distracted or compressed. Various connectors are also applied to the frame for attachment of pins and wires. Transosseous wires secure the rings to the limb, and half pins joined to the rings may be used for additional stabilization of bony fragments.<sup>1,3,4,7</sup>

The Ilizarov fixator has found multiple applications since its initial development five decades ago as an alternative to amputation. Complicated fractures and nonunion of fractures have been successfully treated with this system. The fixator has found further use to lengthen limbs, especially in cases of congenital birth defects or diseases that affect the bone. The development of hybrid systems allows the use of the fixator on virtually any bone that can be fractured. The patients suited for this method range from young children to 70-year-old adults.<sup>1,3,4,7</sup>

The versatility of this system allows the procedure to be done on a minimally invasive level. The application of the frame onto the limb is achieved with minimal scarring. The dynamics of the frame allow for early weight bearing and joint movement, which are key to the success of the procedure. Several days after application, the patient begins gradual corrections involving both distraction and compression techniques to accelerate osteogenesis.<sup>1,3,4,7</sup>

## Osteogenesis

The basis of the Ilizarov method is osteogenesis—the generation of both bony and soft tissues. Knowledge of basic bone structure and remodeling is important to understanding this approach. Essentially, tissue generation occurs between two separated osseous surfaces under gradual distraction. The surrounding muscle, nerve, and vessels regenerate in the direction of the distraction, a process known as distraction osteogenesis.<sup>1,4</sup>

## Bone structure

The macroscopic anatomy of a long bone is critical to understanding osteogenesis (Figure 1). The periosteum, which covers the diaphysis of a long bone, can be distinguished into two layers. The outer, fibrous layer contains the blood vessels, lymphatics, and nerves. The inner osteogenic layer of the periosteum contains structures such as blood vessels, elastic fibers, and osteoprogenitor cells. The periosteum is necessary for bone growth, repair, and nutrition. The endosteum lines the medullary canal and contains many bone forming cells, osteoblasts, and osteoclasts (cells that function in bone reabsorption).<sup>5</sup>

Histologically, bone consists of two different types of tissues, cortical and cancellous. The first, cortical tissue, is the outer portion of the bone. This hard and compact connective tissue provides support and protection. Microscopically, compact tissue appears to have hollow cylinders, known as Haversian canals, that run the axial length of a long bone. Surrounding the canals are concentric lamellae, which contain small spaces called lacunae that contain osteocytes. The canaliculi are able to provide a route for osteocyte nourishment by radiating out from the lacunae. The nourishment passes from the blood vessels in the periosteum through the Haversian canals. The blood vessels then connect with similar structures passing through the Volkmann's canals, which run transverse. This pattern repeats from the outer diameter of the bone to the inner, eventually meeting the red marrow in the medullary canal.<sup>5</sup>

The second osseous tissue type is cancellous or spongy bone. This tissue is surrounded by cortical bone. At the ends of long bones, the cancellous tissue is continuous. In the diaphysis of a long bone, it contains an abundance of red bone marrow. Microscopically, the tissue appears to resemble a honeycomb or scaffold. This type of structure is known as trabeculae. The blood and nerve supply for the spongy bone is derived from the vessels in the periosteum.<sup>5</sup>

## Bone remodeling

Bone remodeling is essentially the replacement of old bone tissue with new bone tissue. The increase in the diameter of a long bone and the creation of compact bone from cancellous bone are two good examples of bone remodeling. This process requires the use of two specialized osteocytes. Osteoblasts are responsible for the formation of bone tissue. They are derived from fibroblasts and form a matrix of bone. They are eventually encircled by this matrix and become osteocytes. Osteoclasts are believed to break down osseous tissue. The release of proteolytic enzymes and different types of acids digest and dissolve the osseous tissues. The activities of the osteoblasts and osteoclasts are kept in a state of homeostasis by the body.<sup>5</sup>

## Fracture repair

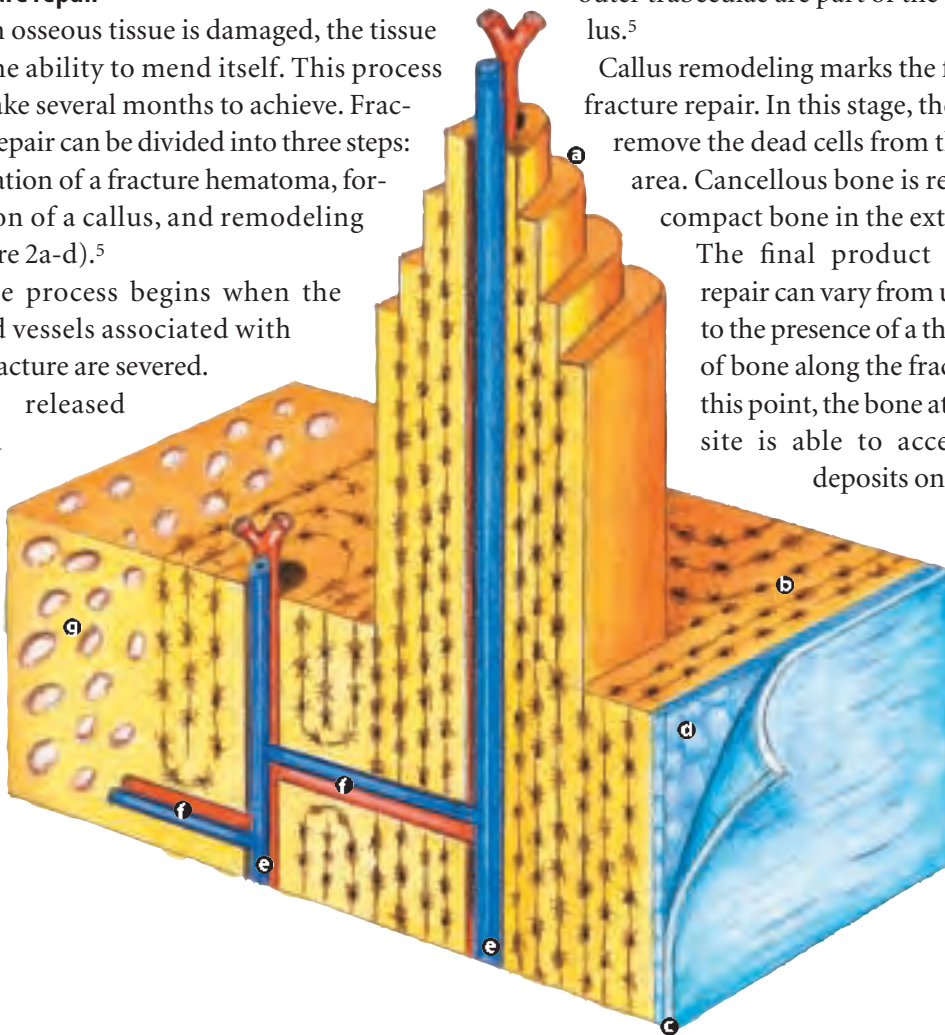
When osseous tissue is damaged, the tissue has the ability to mend itself. This process can take several months to achieve. Fracture repair can be divided into three steps: formation of a fracture hematoma, formation of a callus, and remodeling (Figure 2a-d).<sup>5</sup>

The process begins when the blood vessels associated with the fracture are severed. The released blood

forms a clot, called a fracture hematoma, at the site of the fracture. The hematoma forms within eight hours of the initial injury. The blood flow to the injured cells ceases, killing the cells along the fracture line.<sup>5</sup>

The next step involves the formation of a callus. A callus consists of the new osseous tissue along the fracture, which connects the severed ends of the bone. The callus can be divided into two regions, internal and external. The internal callus contains the osteoprogenitor cells from the endosteum. The external callus simply surrounds the internal callus. About two days after the initial injury, the osteoprogenitor cells from the osteogenic portion of the periosteum, endosteum, and bone marrow begin to divide. These cells then start to grow toward the fracture line. The osteoblasts initially form trabeculae. The outer trabeculae are part of the external callus.<sup>5</sup>

Callus remodeling marks the final stage of fracture repair. In this stage, the osteoclasts remove the dead cells from the fractured area. Cancellous bone is replaced with compact bone in the external callus. The final product of fracture repair can vary from undetectable to the presence of a thickened area of bone along the fracture line. At this point, the bone at the fracture site is able to accept mineral deposits once again.<sup>5</sup>



**FIGURE 1**

Histology of bone

- a** concentric lamellae
- b** cortical bone
- c** periosteum
- d** osteoprogenitor cells and osteoblasts
- e** Haversian canals
- f** Volkmann's canals
- g** cancellous bone



## Preoperative frame assembly

This method of fracture fixation begins with in-depth preoperative planning. The patient should have orthostatic films taken. The frame can then be templated from the X-ray. After the patient has been assessed, each frame is assembled specifically for that patient in a non-sterile fashion. The preoperative assembly reduces operating room time and increases efficiency. If possible, the completely assembled frame should be placed over the affected limb to ensure a proper fit. The frame is typically 2 to 3 cm larger in circumference than the limb. The frame can be placed off center to allow room for range of motion and swelling. Operating room personnel

### Technical insights

1. When a bilateral limb lengthening is scheduled, ensure that enough supplies are available.
2. If the procedure is scheduled to correct a primary fracture, the surgical technologist should have supplies ready for a fasciotomy.
3. Sterile supports can be premade from tightly rolled sheets secured with sterile tape.
4. Small washers can be used to prevent the olive wires from passing through the bone.

should sterilize the frame according to hospital and manufacturer's policies. Proper identification of the sterilized frame would include the patient's name, surgery date, and surgeon.<sup>3,7</sup>

The frame consists of a minimum of two rings, but four rings are more commonly used. The rings are manufactured as half circles and connected via nuts and bolts to form a full circle. Some frame styles may require the use of half rings for adequate range of motion. A variety of ring circumferences and curves have been developed to accommodate patient size and the intended application. Substances such as carbon fiber provide a lightweight yet strong material for ring composition.<sup>3,7</sup>

Once the rings have been assembled properly, they are connected with rods. The rods can be telescoping rods or simple threaded rods. The use of the rod depends on the ring placement. For a four-ring assembly, two rings are placed proximal to the fracture line and two rings distal to the fracture line. The rings farthest from the fracture line are called outer rings; the ones closest to the fracture line are termed inner rings. The inner rings would be connected with the telescoping rods to allow for distraction and compression techniques. The outer rings can be connected to the assembly through the threaded rods.<sup>3,7</sup>

## Operative preparation for lower limb fracture management

The patient is placed under general anesthesia, but regional anesthesia can be used as an alternative. Patient positioning depends on the fracture site. For tibial fractures, the patient is supine on a radiolucent bed. A rolled sheet can be placed under the hip of the affected leg for adequate positioning. Pressure points should be padded, and the safety strap applied appropriately.<sup>3,6,7</sup>

Skin preparation should follow a typical extremity prep. The prep should extend as far proximally on the extremity as possible. Fractured limbs may necessitate special steps in addition to the routine prep. As always, emphasis is given to carefully handle fractured limbs, and to ask for assistance, if necessary, to safely support the fracture site. Use appropriate solutions for open fractures.

After draping the patient, a sterile pneumatic tourniquet may be placed.<sup>6</sup> To allow for circumferential access to the limb, sterile supports, such as stacked towels, should be placed under the thigh and ankle. The fluoroscopy unit should be draped as well.

The sterile frame should be prepared for placement around the affected extremity. The frame should be opened (similar to a clamshell) by removing the nuts and bolts connecting the half rings on one side. The frame can now be safely placed around the extremity and the half rings reconnected.<sup>7</sup>

The frame is attached to the limb by transosseous wires. These wires range in diameter from 1.5 mm to 1.8 mm. Patient size and location of the frame determine the wire diameter. As a rule, the larger the wire's diameter, the stronger and more stiff the frame. Frame stiffness reduces fragment shifting and pain. Wires also appear in a variety of styles: plain or olive. Olive wires have an olive-shaped stop placed approximately one-third from an end. These wires hold fragments in place and increase stabilization.<sup>3,7</sup>

Several factors determine placement. Wires are placed perpendicular to the proximal and distal segments in relation to the fracture line. A 45- to 90-degree angle between each set of wires increases the frame's stability. Placement should avoid neurovascular structures, and the range of motion should not be impaired. The frame also determines wire placement. Ideally, two wires should be placed proximal and distal to the fracture line. Each set of wires should attach to the ring with one wire above and one wire below. Wires that do not touch the frame without bending should be repositioned.<sup>3,4,7</sup>

For reference, the goniometric system is used to indicate wire and pin placement. The range is from 0 to 360 degrees. In a caudal view of the extremity, the numbering begins directly anterior and increases clockwise for the left limb. It is mirrored for the right limb.<sup>7</sup>

The technique for wire insertion is simple. After determining the proper wire placement through fluoroscopy, a small skin incision is made with a number 15 blade. The wire is then gently pushed through the soft tissue from the more vulnerable side of the extremity. A mallet may be used to tap the wire slightly into the cortex. A pneumatic drill is then used to place the wire through the bone. A small skin incision should also be made as the wire exits the soft tissue. These wires do not require pre-drilling and can be placed with virtually any type of power drill. Room temperature irrigation can be used to avoid overheating of the drill and wire. The wires are then loosely attached to the frame with cannulated or slotted fixation bolts.<sup>7</sup>

## Setup for Ilizarov frame placement

### Equipment

- Radiolucent operating room table
- Rolled sheet for hip
- Suction set up
- Electrosurgical unit and appropriate grounding pad
- Fluoroscopy unit and protective attire
- Power source for powered instruments
- Pneumatic tourniquet

### Instrumentation

- Major orthopedic set
- Pneumatic wire tensioner and drill
- Osteotomes
- 2.0 mm pin cutter
- Berry needle holders
- Ilizarov instrumentation

### Supplies

- Extremity drape pack
- Basin set
- Extra towels for lower limb support
- Gowns
- Gloves
- Blades: 15
- Electrocautery pencil
- Suction tubing and tip
- Asepto
- C-arm drape
- Irrigation
- Dressing: according to surgeon's preference
- Suture: according to surgeon's preference
- Drains: according to surgeon's preference
- Pharmaceuticals: according to surgeon's preference

Half pins can be used to incorporate larger fragments into the fixation and should be placed with the same consideration as wires. The half pins range in diameters of 4.0, 5.0, and 6.0 mm. Insertion of the half pins begins after the proper placement has been determined. A small skin incision is made, and a trocar with drill sleeve is placed through the small tissue. A mallet can be used to gently tap the trocar into the cortex of the bone. The trocar is then removed, and the appropriate size of drill is used for the desired pin diameter. The length of the half pin is determined by passing the depth gauge through the drill sleeve. The half pin of proper length and diameter is placed through the sleeve and inserted using

with adapters to allow for tensioning where the wire joins with the ring. After all of the wires have been tensioned to approximately 100 to 130 kg of force, they can be cut. To avoid injury from the sharp edges of the wires, the ends should be turned in toward the frame.<sup>3,7</sup>

### Limb breakage for nonunion or limb lengthening

In the case of nonunion of a fracture or the need for limb lengthening, the affected bone must be broken. The bone can be fractured in several ways. The technique described by Ilizarov consists of a low energy osteotomy or corticotomy. This method of disrupting the continuity of the bone causes minimal damage to the blood supply,

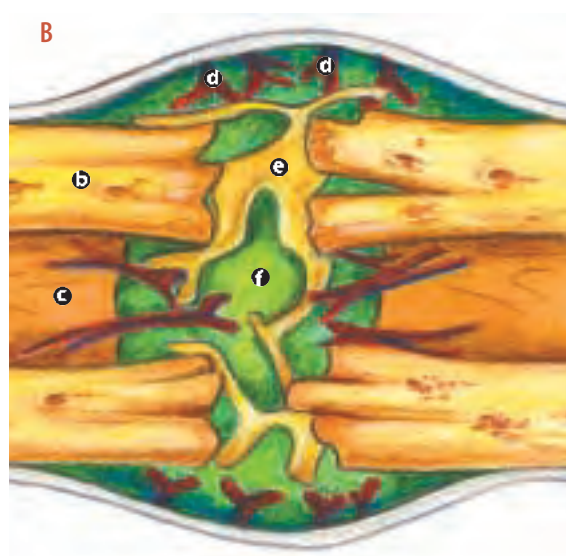
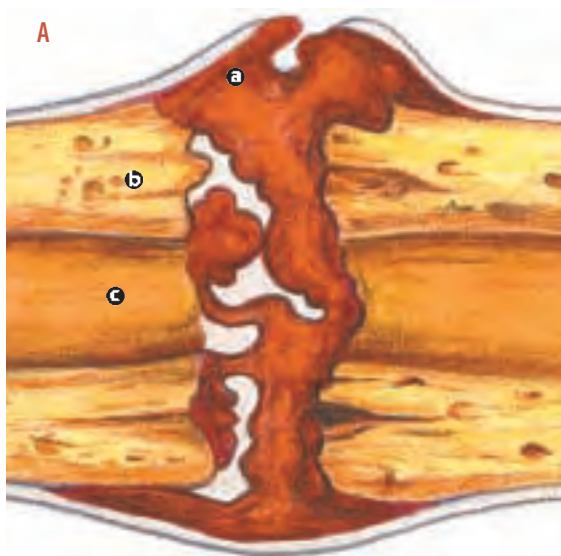
**FIGURE 2**

**A** Blood escapes from ruptured blood vessels and forms a hematoma

**B** Cancellous bone forms in regions close to developing blood vessels, and fibrous tissue forms in more distant regions

**C** Fibrous tissue is replaced by bony callus

**D** During remodeling, osteoclasts remove excess bony tissue, making new bone structure much like the original



the driver/extractor. Finally, the half pins are attached to the ring with Rancho Cubes.<sup>7</sup>

This process of inserting the wires and half pins is repeated until the frame is securely attached to the affected limb. Once this is accomplished, range of motion should be checked. Joint movement, flexion, and extension should not be affected by the placement of the frame. A final check of the fracture fixation should be accomplished using fluoroscopy.

The wires may be tensioned after ensuring the placement of the frame, wires, and half pins. Two types of wire tensioners are available. The dynamometric tensioner is hand operated to the desired tension. Pneumatic tensioners come

which is found in the periosteum and endosteum. Adequate nutrition at the fracture site is vital for osteogenesis, and this method indeed preserves the blood supply. Ilizarov accomplished a true corticotomy by cracking only the cortex of the bone.<sup>1</sup> Although ideal, surgeons have found this technique difficult to master. Other techniques for an osteotomy include the use of a Gigli saw or an oscillating saw. Also, pre-drilling several shallow holes in the cortex can be used to form an initial fracture line. The fracture would be then be extended with an osteotome and mallet.<sup>1,3,7</sup>

The corticotomy is achieved through a small incision at the intended site. The soft tissue is bluntly dissected to allow for insertion of a



periosteal elevator. The periosteum is then gently elevated, and the corticotomy is performed according to the surgeon's preference. The incision is closed after the frame is securely attached to the affected limb.

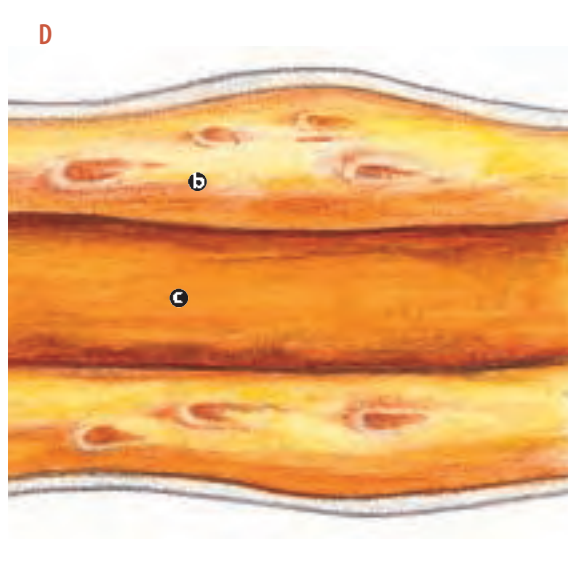
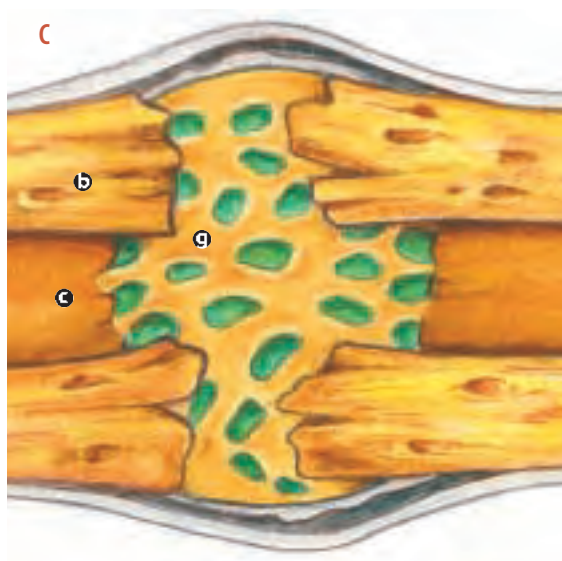
### Dressing

The application of a large device, such as the Ilizarov frame, necessitates a specialized dressing. Gauze impregnated with iodine can be cut and placed around the wire and pin sites. Gauze dressing can be placed around the pins. When a fasciotomy has been performed, the frame can be filled with ABDs and wrapped with a 6-inch ACE bandage.

Postoperative exams should include an inspection of the frame. Infection along pin sites should be immediately addressed. The tension of the wires should also be checked regularly. Loosening of the frame will extend healing time and cause undue pain. Neurological exams on the affected extremity are important to indicate any injury to associated neurovascular systems. Routine orthostatic X-rays monitor osteogenesis and indicate growth of the regenerate.<sup>3,7</sup>

### Osteogenesis and regenerate

Regenerate refers to the product of the osteogenesis. Distraction begins after a latent period of five to 10 days.<sup>4</sup> The patient simply turns the



### Postoperative procedures

A patient with an external fixator should be taught proper wound care. The most common complication with this type of device is infection of pin and wire tract sites.<sup>1,3,7</sup> The patient, using an antimicrobial solution, can daily cleanse the skin around the pins. The dressing around each pin should be changed daily as well.

Early weight bearing is instrumental for the success of the osteogenesis. Patients with lower limb frames should be instructed on proper limb positioning during rest and ambulation. Appropriate pain-relief medications should be supplied to aid in the healing process.<sup>1,3,7</sup>

telescoping rods to distract the osseous surfaces. The regenerate is procured at a distraction of 1.0 to 1.5 mm a day. Adults can attain a 15 percent increase in limb length. To further monitor the distraction between office visits, colored tape can be placed on the telescoping rods. After the desired length is achieved, the distraction continues until 7 to 10 additional millimeters of growth is seen. The regenerate is then compressed until the desired length is again achieved. This technique is referred to as "training the regenerate."<sup>7</sup>

Removal of the frame should be carefully considered. If in doubt, the frame should not be removed prematurely. Guidelines for frame

- Ⓐ hematoma
- Ⓑ cortical bone
- Ⓒ medullary canal
- Ⓓ new blood vessels
- Ⓔ cancellous bone
- Ⓕ fibrous tissue
- Ⓖ bony callus

removal include the presence of cortical ossifications and a stress test. Three of four ossifications at the regenerate site should be present on the X-ray prior to the stress test, which is performed prior to frame removal and can be used as an indicator for regenerate ossification. The test involves removing the rods connecting the rings, and the patient is asked to partially bear weight. If partial weight bearing is too painful, the rods and frame should be replaced.<sup>7</sup>

If the guidelines have been met, the patient can be taken to the operating room for frame removal. The removal should be carried out in a sterile fashion. The wires can be cut on one side with a heavy wire cutter. The pins are released from the Rancho Cubes and the frame is gently removed from the limb. Wire and pin removal can be quite painful. Make sure the patient remains comfortable during the procedure. Large holes left by pin removal should be closed and the sites dressed in a sterile fashion. The surgeon may opt for application of a splint according to the patient's general condition. The patient may be allowed partial weight-bearing status for several additional weeks to ensure adequate ossification at those sites.

### Advantages and disadvantages

The Ilizarov method to apply ring external fixators has enhanced orthopaedic medicine. The system is extremely versatile. The minimally invasive procedure incorporates early weight bearing with both distraction and compression techniques for osteogenesis.

However, it can require long assembly time, and the surgical technique can be involved and complicated. Postoperative management requires a well-informed and compliant patient. Examinations can be quite lengthy, requiring frequent visits and X-rays. The chance of infection at wire and pin sites is always a possibility.<sup>1,3,4,7</sup>

Recent advances in the Ilizarov method, such as hybrid systems, have minimized the disadvantages of this important technique for fracture repair. The ongoing research into the dynamics and methodology of osteogenesis will advance the success of this system. Education of the clin-

ician and patient in all aspects of care will ensure the continuing use of the Ilizarov method of external fixation.

### About the author

Amy Croft, CST/CFA, has been working in the OR for more than 10 years. She received her certification in surgical technology from Amarillo College in Amarillo, Texas, and obtained a BS degree in biochemistry from Texas Tech University in Lubbock, Texas. Croft is now a first-year student in the Physician Assistant Program at Wake Forest University in Winston-Salem, North Carolina. In addition, she was a contributing author to the recently released textbook, *Surgical Technology for the Surgical Technologist: A Positive Care Approach*.

### References

1. Aronson J. Limb-Lengthening, Skeletal Reconstruction, and Bone Transport with the Ilizarov Method. *Journal of Bone and Joint Surgery* 1997; 79-A(8):1243-1258.
2. Einhorn TA. One of Nature's Best Kept Secrets. *Journal of Bone & Mineral Research* 1998; 13(1):10-12.
3. Bianchi-Maiocchi A, Aronson J, Pous L Baral J. *Operative principals of Ilizarov*. Baltimore: Williams & Wilkins; 1991
4. Gugenheim JJ. The Ilizarov Method: Orthopedic and Soft Tissue Applications. *Clinics in Plastic Surgery* 1998; 25(4):567-578.
5. Wheelless C. *Wheelless' Textbook of Orthopaedics*. 2000.
6. Tortora GJ, Anagnostakos NP. *Principles of Anatomy and Physiology*. Philadelphia: Harper & Row, 1987.
7. Watson JT, Coufal C. Treatment of Complex Lateral Plateau Fractures Using Ilizarov Techniques. *Clinical Orthopaedics and Related Research* 1998;(353):97-106.

Picture courtesy of Smith & Nephew.





Teri Junge, CST/CFA

Fat embolism and the accompanying fat embolism syndrome (FES) are conditions that develop when droplets of fat act as emboli. The fat droplets become impacted in the microvasculature, especially of the lungs and brain. The multisystem disorder can also affect the heart, kidneys, eyes, and skin. Fat embolism presents at two different levels:

The microscopic form (subclinical) occurs in more than 90 percent of patients with long-bone fractures and in patients undergoing operative procedures performed on long bones without the use of a tourniquet. Microscopic fat embolism is detected by examination of the serum, urine, or sputum for evidence of fat.

Fat Embolism Syndrome, the most serious form, occurs in 2 percent to 23 percent of patients suffering blunt trauma and related fractures. The varying percentage relates to the severity of the injury. The Mangled Extremity Severity Score was developed to evaluate the potential viability of a limb following trauma and may be a valuable tool in predicting FES (Table 1).<sup>3</sup>

FES is a serious (potentially life-threatening) condition that usually develops after trauma, most frequently following fracture of a long bone (Figure 1). However, the syndrome has also been associated with blunt trauma, intramedullary procedures, prolonged corticosteroid therapy, osteomyelitis, childbirth, liposuction, fatty degeneration of the liver, pancreatitis, systemic lupus erythematosus (SLE), diabetes, sickle cell anemia, severe burns, coronary artery bypass surgery, massive infection, and conditions causing bone infarction.<sup>1,2,6</sup>

# FAT EMB a complication






# **BOLISM** of long bone fracture

Recent studies have also shown that FES is not simply a mechanical obstruction by the fat droplets of the small vessels, but that it also causes endothelial injury. The lipoprotein, lipase, causes fatty acids to be released from the impacted fat droplets allowing increased permeability of the microvasculature; fluid leakage into the interstitial spaces (edema) ensues.

### History

Experimentally, fat embolism was first observed in 1669 by Richard Lower of Oxford through his work with intravenous injections of various fatty substances, including milk. Lower's work was substantiated in 1842 by François Magendie, a



**FIGURE 1**  
Femoral shaft  
fracture

French physiologist, while investigating therapeutic intravenous therapy using olive oil. During Magendie's animal studies, the symptoms following the injection of fat were observed, and the changes preceding death were noted. He discovered that fat globules were trapped in the small vessels of the lungs (Figure 2).

Post-traumatic fat embolism was first described by FA von Zenker in 1862. His patient, a railway worker, received a severe thoracoabdominal crush injury that resulted in multiple rib fractures, and rupture of the liver and stomach. He attributed the embolism to aspiration of fatty gastric contents through the exposed hepatic veins.

Fat embolism was first related to bone fracture by Rudolph Wagner in 1862 when he reported lung emboli at necropsy (autopsy) in 48 patients who had suffered bone injury. His further experiments on dogs with bone injury verified the correlation.

The first diagnosis of fat embolism on a living patient was made by Ernst von Bergmann in 1873 on a patient with a fractured femur who subsequently died. It was also von Bergmann who, 10 years earlier through experiments on cats, discovered that the fat was usually trapped in the capillaries of the lungs (pulmonary embolism). In some cases, however, the fat could enter the general circulation (systemic embolism) and affect the liver and other organs, including the kidneys. He also noted that fat could escape into the urine for excretion.

Scriba, in 1880, first combined the experimental, clinical, and pathological observations to conclude that fat embolism occurred after every bone injury, especially fractures, via liberation of liquid bone marrow fat into venous circulation. The embolism could vary in importance from subclinical to the cause of death.<sup>6</sup>

### Clinical presentation

In 50 to 60 percent of patients, the onset of FES is gradual, becoming apparent within 24 hours; 90 percent of all cases will become apparent within 72 hours.<sup>7</sup> Patients with sudden onset of symptoms (usually within 12 hours of injury) with great intensity (referred to as a fulminant course) have a high mortality rate. The patient may first appear restless and complain of vague chest pain. The patient may become drowsy and show a decrease in urine secretion (oliguria). Unexplained fever greater than 101°F (38.3°C) and tachycardia may also be present. Clinical diagnosis is based on the presence of all three of the following criteria within 72 hours following injury.

*The three main clinical features of FES are:*

1. Respiratory failure manifested in one or more of the following ways: dyspnea, tachyp-

nea, cyanosis due to arterial hypoxemia, or radiograph showing diffuse alveolar infiltrates.

2. Petechiae covering the conjunctiva, retina, oral mucosa, or upper half of the body.
3. Cerebral dysfunction demonstrated by delirium, confusion, or coma.

### Incidence

Fat embolism is thought to occur in at least 90 percent of patients with a fracture. FES can occur in as many as 23 percent of the patients with fat embolism, with approximately 10 percent or fewer of those cases proving fatal.<sup>3</sup> Cerebral, renal, and cardiac complications are less

likely to cause death than respiratory failure. The risk of FES is decreased in young individuals with fractures and with a tourniquet during an operative procedure on a long bone. The risk of FES is increased when the fracture is closed, when the injury is severe and sustained at a high velocity, and in the presence of malignancy (either primary or metastasis, due to enlargement of venous sinuses related to the tumor).<sup>3</sup> Fat embolism and FES cannot be prevented, but several steps can be taken to lower the incidence:

- Immediate fracture reduction and stabilization

**Table 1 Mangled Extremity Severity Score (MESS)** *Adapted from Wheeler's Textbook of Orthopaedics*

**MESS value equal to or greater than seven is an accurate prediction that primary amputation is warranted.**

Criteria	Severity	Score
<b>1</b> Skeletal and/or soft tissue injury	• Low energy <i>(stab; simple fracture; pistol gunshot wound)</i>	• 1
	• Medium energy <i>(compound or comminuted fracture; dislocation)</i>	• 2
	• High energy <i>(high speed motor vehicle accident; rifle gunshot wound)</i>	• 3
	• Very high energy <i>(high speed trauma plus gross contamination)</i>	• 4
<b>2</b> Limb ischemia	• Pulse reduced or absent but perfusion normal	• 1*
	• Pulseless; paresthesia; diminished capillary refill	• 2*
	• Cool; paralyzed; insensate; numb	• 3*
<b>3</b> Shock	• Systolic blood pressure always greater than 90 mm Hg	• 0
	• Hypotensive transiently	• 1
	• Persistent hypotension	• 2
<b>4</b> Age (years)	• Less than 30	• 0
	• 30-50	• 1
	• Greater than 50	• 2

\* Indicates that the ischemia score is doubled if the time elapsed between injury and intervention is greater than six hours.



- Administration of low-dose corticosteroids
- Implementation of oxygen therapy.

### Pathophysiology

Fat embolism is classified into two pathological types: pulmonary embolism, which may occur as a separate entity, and systemic embolism, which is always associated with pulmonary embolism.

The genesis of both pathological types is the same. The fat originates at the site of the trauma, especially the injured marrow of a fractured bone. The fat cells rupture and, due to a difference in pressure between the marrow and the vessel, allow free fat globules to enter torn veins. Within seconds or minutes, the emboli are taken through the pulmonary artery to the lungs, where the fat globules become entrapped within the pulmonary arterioles and/or compressed within the pulmonary capillaries. The buildup of the fatty material may continue for several hours to a few days. New emboli may be introduced intermittently due to lack of mobilization at the fracture site or treatment of the fracture (closed reduction, surgical manipulation, or application of a fixation device: internal, intramedullary or external). The severity of the injury and the presence of multiple fractures dictate the degree of embolism. Histologically, minor to moderate degrees of pulmonary embolism is of little importance due to the enormous capillary bed

and the large functional reserves within the lungs. Severe embolism can be symptomatic and produce death.

Due to the liquid nature of the fat globules and capillary pressure, it is possible for the fat to continue to move forward in the blood stream through the lungs, enter the aortic circulation, and produce a systemic effect. All tissues and organs are involved with systemic embolism, with the brain (Figure 3) and kidneys the most heavily affected. As with pulmonary fat embolism, systemic embolism also varies considerably in its severity, depending on the degree of pulmonary embolism and the nature of the injury.

### Diagnosis

A criterion for diagnosis of FES was established by Fraser Newman Gurd in 1970 (Table 2).<sup>7</sup> Diagnosis of FES requires that the patient exhibit at least one sign from the major criteria category and at least three minor signs or two major and two minor signs.

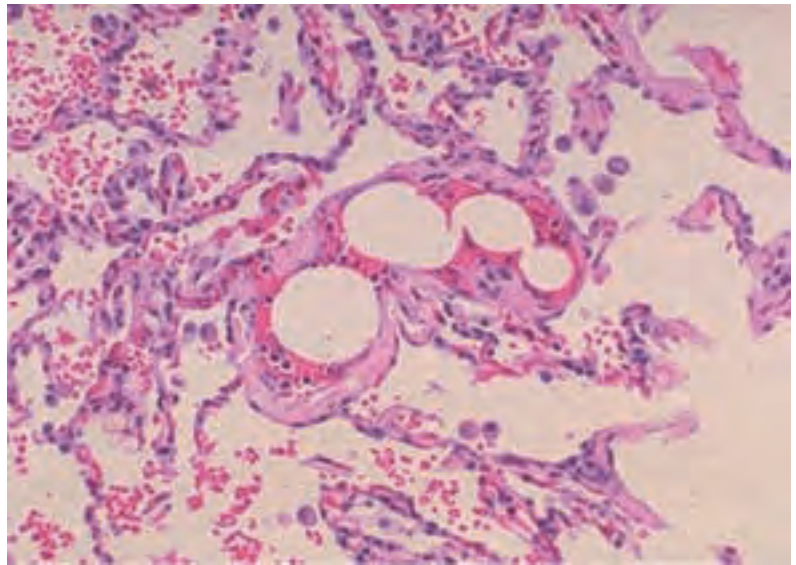
The clinician should be suspicious of the development of FES following any fracture, especially closed long bone, rib, and pelvic fractures. Open fractures, and fractures of the clavicle and sternum show lower incidence of FES.<sup>1</sup> The diagnosis is based on the clinical presentation of the syndrome, making diagnosis in an anesthetized patient difficult. No single specific

**Table 2** Gurd's diagnostic criteria for fat embolism syndrome *Adapted from Wheeler's Textbook of Orthopaedics*

Gurd's major criteria	Gurd's minor criteria	Miscellaneous
<ul style="list-style-type: none"> <li>• Hypoxemia</li> <li>• CNS depression that is disproportionate to hypoxemia, and pulmonary edema</li> <li>• Axillary or subconjunctival petechiae</li> <li>• Occurs within 4-6 hours of skeletal trauma</li> </ul>	<ul style="list-style-type: none"> <li>• Tachycardia (greater than 110 beats per minute)</li> <li>• Pyrexia (greater than 38.3 °C)</li> <li>• Retinal emboli upon fundoscopic examination</li> <li>• Fat present in urine</li> <li>• Fat present in sputum</li> <li>• Drop in hematocrit not related to blood loss</li> <li>• Drop in platelets (thrombocytopenia less than 150K)</li> <li>• Increased sed rate</li> </ul>	<ul style="list-style-type: none"> <li>• Occurs within 72 hours of skeletal trauma</li> <li>• Short of breath</li> <li>• Altered mental status</li> <li>• Long tract signs and posturing</li> <li>• Urinary incontinence</li> </ul>

diagnostic tool positively confirms the presence of FES; however, several exams provide useful information:<sup>1,3,5,7</sup>

1. Radiography shows evidence. Fat embolism is thought to have a similar appearance to pulmonary edema (snow storm appearance: fleck-like shadows that are evenly distributed) on chest X-ray.
2. Hematology
  - Platelet count is decreased (thrombocytopenia).
  - Coagulation times are increased (related to thrombocytopenia).
  - Hematocrit is decreased.
  - Hemoglobin is decreased.
  - Serum lipase level is increased.
  - Arterial blood gas (ABG), such as arterial hypoxemia or respiratory alkalosis, appears.
3. Urinalysis bears evidence of fat globules.
4. Neurological examination indicates decreased level of consciousness, convulsion, or personality changes.
5. ECG reveals tachycardia, ST depression, T wave flattening, AV block or bundle-branch block, evidence of right heart strain, or ischemic patterns.
6. Pulse oximetry shows decreased O<sub>2</sub> saturation.
7. Cerebrospinal fluid analysis contains fat globules.
8. Visual examination reveals cyanosis or the presence of petechial rash on the upper body, upper extremities, conjunctiva, and oral mucosa.
9. CT scan discloses evidence of cerebral edema.
10. Sputum analysis uncovers fat globules. A specimen may be obtained with the use of bronchioalveolar lavage (BAL).
11. Fundoscopic exam (ophthalmoscopy) reveals the following: retinal hemorrhage; presence of “cotton-wool” exudates, pallor, and edema in the macular region; or scotomata (area of decreased vision) in the central fields.



12. Transesophageal echocardiography may detect the emboli as they enter pulmonary circulation during a surgical procedure.

### Treatment

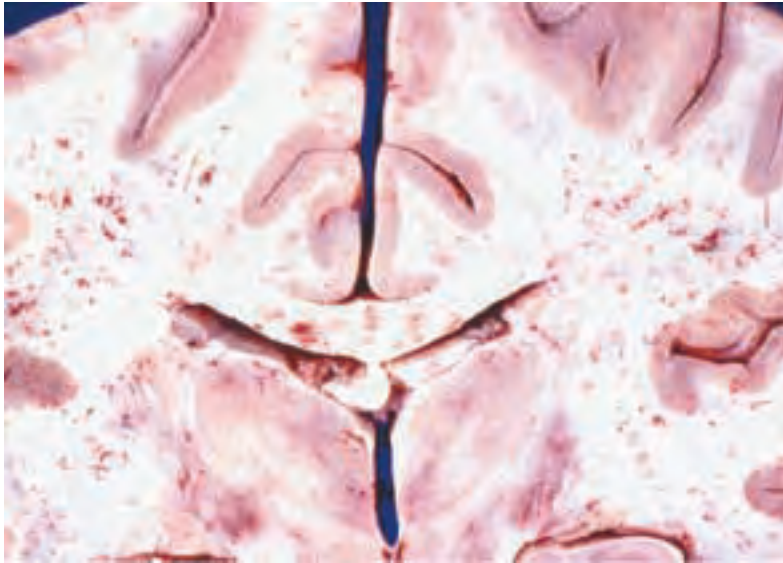
Treatments for fat embolism and FES vary according to the severity of the symptoms. This is a self-limiting condition; therefore, no “cure” for fat embolism or FES exists. The treatments are considered supportive until the patient spontaneously returns to a homeostatic state. Successful treatment depends on oxygenation to peripheral tissues. Several conventional treatment options are described below:<sup>1,3,5,7</sup>

1. Provide pulmonary support (according to need)
  - Supplemental oxygen by face mask
  - Mechanical ventilation (positive end-expiratory pressure [PEEP] may be helpful)
2. Optimize cardiac output to maintain perfusion
  - Maintain blood pressure (fluid administration; use of inotropic agents such as dobutamine, dopamine, epinephrine, isoproterenol, or norepinephrine)
  - Maintain hematocrit
3. Fluid management according to circulatory status (to decrease pulmonary edema)
  - Fluid restriction
  - Diuretic administration

### FIGURE 2

#### Lung pathology

Stained section of lung tissue showing arterial vacuoles that result from lipid removal during tissue processing



**FIGURE 3**

**Brain pathology**

“Purpura”  
petechial  
hemorrhages in the  
brain, prominently  
visible in the white  
matter

4. Early reduction and stabilization of fracture(s)
5. Administration of corticosteroids

Controversial treatment options include IV ethyl alcohol infusion to inhibit lipase and clofibrate (an antihyperlipidemic) to increase free fatty acid metabolism. Theoretically, use of lipase inhibitors is sound, as they increase the metabolism of intravascular lipids, but the formation of more free fatty acids may cause further damage to the pulmonary capillary endothelium. Administration of aspirin, heparin (also considered a lipase inhibitor), or dextran may be helpful in decreasing platelet adhesiveness; however, the benefits of the anticoagulants in treating FES may be outweighed by additional risk of hemorrhage from recent trauma.

**Conclusion**

Most individuals with FES recover fully within two to three weeks with appropriate supportive treatment. The overall prognosis is very good, with most patients suffering little to no residual effects of the event. Morbidity and mortality are related to the degree of pulmonary and central nervous system complications.<sup>7</sup>

The patient may suffer from multisystem trauma, making diagnosis and treatment difficult. Other conditions to be considered include pulmonary or cardiac contusion, pulmonary

embolism, shock (septic or hypovolemic), intracranial injury, aspiration pneumonitis, and other types of ARDS (acute respiratory distress syndrome).<sup>7</sup> FES may be accompanied by intravascular coagulation and osteonecrosis as part of a triad of pathological conditions.<sup>11</sup>

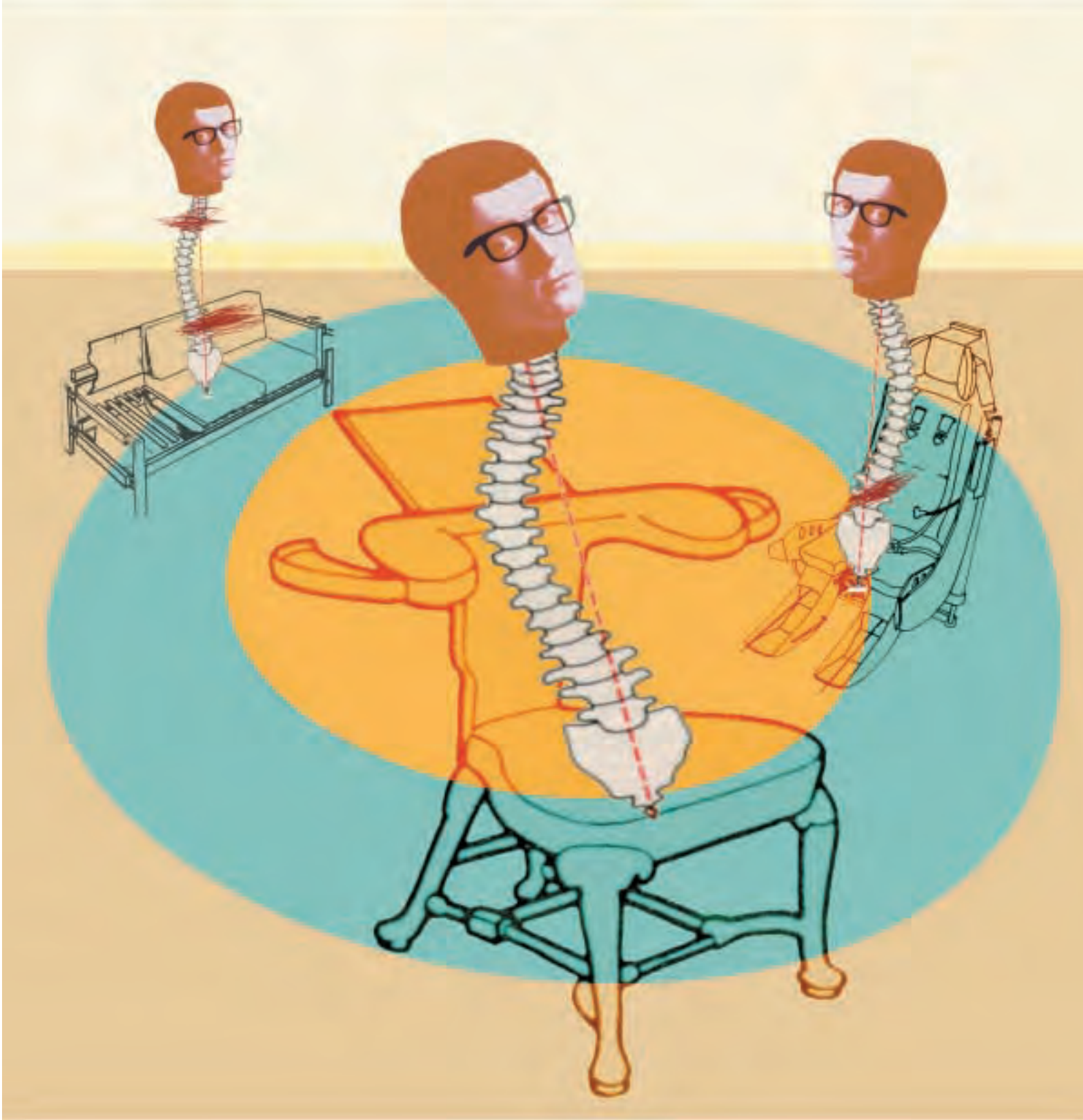
**References**

1. De Azevedo Prazeres, G. *Medstudents' Homepage Fat Embolism Syndrome* [www.medstudents.com.br/medint/medint2.htm](http://www.medstudents.com.br/medint/medint2.htm) Accessed 6-12-00
2. Fat Embolism (1996) [www.medhelp.org/glossary](http://www.medhelp.org/glossary) Accessed 4-25-00
3. Fat Embolism Cleveland Clinic Foundation Department of General Anesthesiology [www.anes.ccf.org:8080/pilot/ortho/fat.htm](http://www.anes.ccf.org:8080/pilot/ortho/fat.htm) Accessed 6-12-00
4. Fat Embolism Discussion [www.mamc.amedd.army.mil](http://www.mamc.amedd.army.mil) Accessed 4-25-00
5. Odegard, K. *Fat Embolism: Diagnosis and Treatment* [gasnet.med.yale.edu/gta/fat\\_embolism.html](http://gasnet.med.yale.edu/gta/fat_embolism.html) Accessed 6-12-00
6. Sevitt, S (1962) *Fat Embolism*. Butterworth & Co. (Publishers) Ltd London
7. Shergill, G; Parmar, H. *Fat Embolism And The Fat Embolism Syndrome* [www.fractures.com/institute/teaching/talks/fat\\_percent20embolism.htm](http://www.fractures.com/institute/teaching/talks/fat_percent20embolism.htm) Accessed 6-12-00
8. Tanaka, K; Shindo, M; Soma, K; Hirata, M; Ohwada, T. *Does Unreamed Nailing Prevent Pulmonary Embolism?* [pdm.medicine.wisc.edu/unreamed.htm](http://pdm.medicine.wisc.edu/unreamed.htm) Accessed 6-20-00
9. Todd, J. *Thrombosis, Embolism, and Infarction* [www.hsc.wvu.edu/som/pathology/thrombosis.htm](http://www.hsc.wvu.edu/som/pathology/thrombosis.htm) Accessed 6-20-00
10. Virtual Trauma Center TraumaNET Case #2 [www.trauma.orhs.org/htmls/02case/02case.html](http://www.trauma.orhs.org/htmls/02case/02case.html) Accessed 6-12-00
11. Wheelless, CR. (1996) *Wheelless' Textbook of Orthopaedics* [medmedia.com](http://medmedia.com) Accessed 6-12-00

*Images used with permission of Edward C Klatt, MD, Department of Pathology, University of Utah, and Wheelless Textbook of Orthopaedics.*



# Posterior



# spina

# SURGERY

## 20th century advances

By Jeff Cortese, CST

Although successful spinal fusion was reported as early as 1911, the procedure wasn't more fully developed until the 1950s when the Harrington rod became available. As Harrington's spinal instrumentation system was advanced (Figure 1), others—such as Moe, Edwards (Figure 2), Jacobs, and Luque—modified the technique to expand its clinical applications. Around the same time, segmental fixation was also being developed. The Cotrel-Debousset system, Texas Scottish Rite spinal system, and posterior plating systems added functionality. "Posterior Spinal Surgery: From Ancient Egypt to the Late 20th Century," published in the November 2000 issue of *The Surgical Technologist*, covered in detail these early developments of spinal fusion.

In 1944, D King began using the pedicle as a means of spinal fixation. By 1959, Boucher had achieved success in passing screws through the lamina and pedicle into the vertebral body. These two developments allowed the surgeon to perform aggressive decompressions of the spine, while stabilizing a limited number of spinal segments and preserving the normal contours of the spine. This article focuses on the considerable advances made through screw systems and documents recent developments in spinal fusion.

## Variable screw placement system

In 1986, Arthur D Steffee introduced the variable screw placement system (VSP) as a means of transpedicular fixation of the unstable spine. He described the efficacy of this system in patients suffering from spinal instability, severe back pain unresponsive to conservative treatment, and patients with back pain relieved by immobilization.<sup>34</sup> In his earliest article in VSP plating, he described the concept of the “force nucleus,” the junction of the pedicle, superior and inferior facets, the pars, transverse process and lamina, a channel where all forces posteriorly can be transmitted anteriorly through the pedicle to the anterior column of the spine. The functional importance of the pedicle’s anatomic location is further enforced by the proximity of the lumbar multifidus and longissimus attachments, both important to segmental movements of the spine.<sup>33</sup>

Steffee’s early attempt at fixation of the “force nucleus” consisted of an AO neutralization plate and cancellous bone screws, but he soon discovered the lack of flexibility between the fixed circular plate hole and the hex head of the cancellous screw.<sup>33</sup> This led to the development of the variable screw placement system.

The VSP system, marketed by DePuy Acromed, consists of two bilaterally placed plates with nested slots, allowing precise placement of specifically designed screws at any angle necessary for rigid fixation.<sup>34</sup> The screw consists of a long cancellous threaded portion that enters the pedicle and a machined-threaded portion on its shank with an integrated hex nut between both portions assisting in level placement of the slotted plates.

The screw lengths vary from 16 mm to 55 mm, with screw diameters of 4.75, 5.50, 6.25, 7.0, 7.75, and 8.50 mm. The material for the hardware can be manufactured from either stainless steel or lighter-weight titanium. Three different plate-spacer washers are used between the hex head of the cancellous portion of the screws to achieve level metal-to-metal contact between the plate and screw shank.

A VSP tapered nut is used to secure the plate to the pedicle screw, and a VSP lock nut is then used on all VSP screws to secure the entire fixation

device. The VSP instruments consist of a VSP T-handle screw wrench with a 3.18-mm hex socket for all VSP screws, a VSP T-handle nut wrench with a 9.5-mm hex socket for tapered nuts, and an 8-mm hex socket for locking nuts. The set also includes a VSP screw alignment bar and rod, a VSP pedicle probe, a VSP aluminum template set, a VSP sounding probe, and a VSP bone tap.

## Wiltse system

The initial use of the Wiltse system in humans started on May 24, 1984, at the Long Beach Memorial Hospital. Twenty other centers in the United States have since started using this system.<sup>36</sup> Pedicle screw fixation has provided the spinal surgeon with a powerful and versatile new tool. Rates of pseudoarthrosis in the lumbosacral spine continue to be high, particularly after the surgical removal of all or part of the facet joints. The Wiltse pedicle internal fixation system reestablishes the continuity of the facet joints. The fusion has been increased to 91.7% in the Phase II FDA study.<sup>38</sup>

The Wiltse pedicle system offers a reliable point of fixation to the vertebra. Pedicle screw fixation does not rely upon distraction, compression, or the presence of the posterior elements for fixation. By using some special instruments, pedicle screws allow the surgeon to exert distraction or compression forces as needed.

The pedicle screw system allows the surgeon to place the pedicle screws in the most appropriate position and then interconnect the screws by a malleable stainless-steel rod and a unique saddle-clamp assembly. In order to create a template, an aluminum, hand-malleable mastering rod is used to create a model. Using this mater, an exact stainless-steel duplicate can be fabricated. For this, a variety of bending instruments has been developed. In the case of particularly severe deformity over many levels, a major bending system is available that allows one to accurately contour the necessary rods.

These stainless steel rods are placed into the saddle-clamp assembly. A unique lock washer attached to the top saddle prevents loosening and allows the surgeon to use a single nut, thereby lowering the profile of the assembly (Figure 3 and 4).



## The Vermont spinal fixator

The use of the pedicle as a method for spinal implant attachment became a major advance in spine surgery. It provides a grip on the vertebra that resists loads of any type. Placement of a truly transpedicular screw was first reported by Harrington and Tullos in 1969, but was first developed as a practical method by Roy-Camille.<sup>14</sup> It was Martin Krag's experience with the Roy-Camille system in 1981 that led to the idea of the internal fixation device, later called the Vermont spinal fixator (VSF). This was further stimulated by a meeting in 1981 with Magerl and Schlapfer concerning their work on an external spinal fixator.<sup>24,32</sup>

At the time, there were no published descriptions of any other transpedicular system, not to mention the basic anatomic and biomechanical research. This prompted a series of anatomic and biomechanical studies that brought about the exact specifications for the VSF and clinical use in July 1986.

## AO fixation of the posterior spine

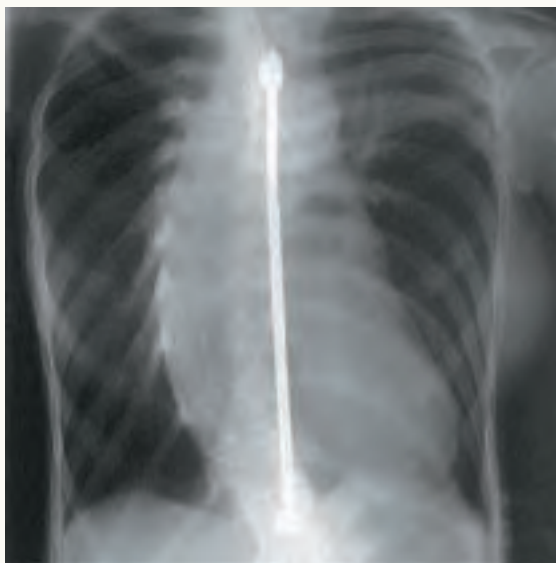
The use of the narrow, dynamic compression plate (DCP) in the treatment of thoracic and lumbar spine fractures was briefly described by the AO group in their *Manual of Internal Fixation*.<sup>26</sup> They cited the technique of Roy-Camille for performing internal fixation with pedicle screw plating.<sup>31</sup> Instead of using his round-hole plates, however, they advocated narrow DCPs, which allow the screws to be angled through the holes in any direction.

The DCP was developed by the AO group in 1965.<sup>35</sup> They touted the DCP as representing an improvement on the traditional round-hole plate because of the special geometry of the screw holes that allows for two unique advantages.<sup>31</sup> First, axial compression may be achieved without the use of a tension device if a special offset-drill guide is used. This is not applicable to the posterior transpedicular placement of these plates, but is useful for compression of the bone graft after an anterior corpectomy and instrumentation with the broad 4.5 mm DCP.

Second, it is possible to angle the screws through the holes in any direction desired. This is very significant for posterior plating since the

screws may be angled in an unlimited direction to properly enter the vertebral pedicles. The magnitude of the angulation is 25° longitudinally, in each direction parallel to the plate axis, and 7° laterally, perpendicular to the long axis.

In a round-hole configuration, the head is seated in the hole when the screw is perpendicular to the axis of the plate. If the screw is inserted obliquely, a torsional force occurs at the head in its perpendicular position. The torsional force is transmitted as a movement to the screw threads, causing asymmetric forces at the thread-bone interface. These asymmetric forces increase as the movement arm (screw length) increases and may lead to stress risers. The advantage of placing can-



**FIGURE 1**


A Harrington rod and bone graft are shown bridging the spine of a patient with thoracic scoliosis.

cellous screws oblique to the axis of the plate is important when the hole does not lie exactly over the center of the pedicle. In a fixed-hole system, this will occasionally occur. Oblique orientation of the screw through the plate hole into the pedicle, without a concomitant torsional movement experienced by the screw tip in the vertebral body, is optimal. The DCP's are named for the diameter of the outer thread of the cortical screw that corresponds to that particular plate. The 4.5 mm cortical screw has an 8.0 mm head that interfaces with the 4.5-mm DCP screw hole.

The 6.5-mm cancellous screw also has an 8.0 mm head and is used with the 4.5 mm DCP. The 4.5 mm DCP is made in broad and narrow fash-

ion. The broad 4.5 mm DCP has the holes staggered about the long axis of the plate to avoid placing the screws in the same plane. This is advantageous in a long bone and the anterior vertebral body because the chance of fracture occurring through the plane of the screws is decreased. The narrow DCP is characterized by all of the holes being in line with the long axis of the plate and is the type applicable to pedicle screw plating. The screws are named by the outside diameter of their thread. The 6.5 mm cancellous screw has a 3.0 mm core and a 2.75 mm pitch.

It is imperative when using the 6.5-mm cancellous screw, that the fully threaded modification is used. This provides thread fixation in



the pedicle, which is the strongest region for fixation of the vertebral complex.<sup>32</sup> These fully threaded cancellous screw modifications are generally not included in the standard large-fragment set and must be ordered separately.

A plate may be named by its anatomic and biomechanical characteristics. The anatomic properties of a plate are described by its material configuration, such as T, round hole, or a slotted plate. The biomechanical characteristics are determined by the functional manner in which the plate is operating, such as a compression, tension band, or neutralization plate.

The function of a specific plate is not necessarily governed by its anatomic configuration.<sup>4</sup>

For example, a round-hole plate can biomechanically function as a static compression, tension band, or neutralization plate, depending upon the manner in which it is employed.

Unfortunately, the DCP is named by one of its possible biomechanical functions rather than by its anatomic characteristics. It is thus sometimes confusing when describing the use of this plate. Even if the screw is placed centrally rather than eccentrically through the plate hole (thereby not utilizing the self-compressing function), the plate is called a dynamic compression plate. A more appropriate name would identify the plate by its semicylindrical screw holes for the others.<sup>4</sup>

The bending strength of a screw is proportional to the effective thread diameter. The effective thread diameter is equal to the outside thread diameter minus the core diameter.<sup>26</sup> The 4.5 mm cortical screw is fully threaded and has a core diameter of 3.0 mm and a 1.75 mm pitch. Both screws have a head diameter of 8.0 mm and uses the 3.5 mm hexagonal screwdriver.

The 3.2 mm drill bit corresponds to both the 4.5 mm cortical and the 6.5 mm cancellous screws, since the core diameters are equal. The two screws have equal bending strength, but the 6.5 mm cancellous has a stronger pullout strength.

The AO instrumentation described has proven to be a valuable adjunct in attaining fusion of the lumbar spine. The implants are readily available in all centers equipped with AO large-fragment sets. This is an extremely demanding procedure, however, and if used, must be limited to those surgeons who have specific training in transpedicular fixation and extensive experience in spinal surgery.

Although popular in Europe for many years, a wave of enthusiasm for transpedicular fixation of the spine swept through North America during the 1980s. While technically demanding, the advantages of pedicle screw fixation have become readily apparent to a growing number of surgeons.

It is a technique that allows the surgeon to thoroughly decompress the neural elements by the joints and pars interarticularis, if necessary. At the same time, immediate stability to the spine via transpedicular screw fixation is provided.<sup>12</sup> The

**FIGURE 2**  
Bilateral  
Edwards rods  
were used to  
bridge a spinal  
fracture.

earlier transpedicular fixation systems are primarily of the plate type and are satisfactory for some patients.<sup>15,20</sup> However, difficulty is encountered when contouring is required to accommodate both sagittal (lordosis) and coronal (scoliosis) curvatures. In addition, the transverse dimension of the available plates limits the space available for the application of a bone graft.

Transpedicular external fixation has been designed and used on fractures and for temporary fixation as a diagnostic test for lumbosacral instability.<sup>24</sup> However, its problems—protrusion of the device, pin-tract infection, and potential for accidental penetration of the screw through the anterior cortex of the vertebral body—make the device very unappealing.<sup>18</sup>

### **The Puno-Winter-Byrd system**

The problems described led, in 1984, to the development of a new pedicle screw system.<sup>27</sup> The Puno-Winter-Byrd (PWB) pedicle screw system is a rod-and-screw transpedicular fixation device designed to provide immediate mechanical stability to the instrumented spinal segments while bony fusion is taking place. Like any spinal instrumentation system, it is used as an adjunct to the surgical fusion technique. The primary goal of surgery is to produce a solid fusion, so the device should not be used as a substitute for meticulous technique in the arthrodesis procedure.

The purpose of all spinal fixation systems is to provide an optimum degree of stability to the instrumented spine in order to enhance the success rate for obtaining a solid fusion. However, there is no data available to prove the optimum degree of rigidity. Historically, spinal fixation systems have had total rigidity as their goal, with the thought that this would best enhance solid fusion. On the other hand, experience with long-bone fractures shows that rigidly fixed fractures often produce less-abundant calluses than those treated in a cast, which allow some degree of fracture motion. This would suggest that total rigid spinal fixation may not be necessary to provide the optimum milieu for a solid fusion.<sup>27</sup>

In addition, totally rigid pedicle-screw fixation of the lumbar spine can create potential prob-

lems, such as loosening at the bone-screw interface, especially in osteopenic bone, screw breakage, and stress shielding.<sup>25</sup> With these problems in mind, the PWB pedicle screw system was developed to allow for micro motion between the screw and rod via the use of a special coupling device. The micro motion produces a “shock absorber” effect to decrease the stress concentration at both the bone-screw interface and the screw-rod interface, which then enhances load sharing between the device and the bone.

Finally, the PWB pedicle screw system was designed to simplify implantation. The system has only six components and utilizes standard implantation techniques. As the PWB system evolved, several design changes were made to satisfy the aforementioned criteria. The final implant system resulted from five prototype designs. While there are several transpedicular systems available, they generally fall into two broad categories. They are either of the screw-and-plate design or the screw-and-rod design.

There are features of the PWB transpedicular spinal system that further enhances its function. Foremost of these is the fact that the screw and seat are two separate pieces, providing the micro motion necessary to decrease stress concentration at the screw-seat junction, thereby minimizing failure. In addition, the surgeon is able to compensate for the various small differences in pedicle direction from segment to segment without sacrificing seat alignment. This simplifies the ease of rod placement. The availability of four seat sizes allows careful tailoring of the instrumentation construct for each individual case despite the natural variations occurring from patient to patient. The PWB transpedicular system is easily implantable and provides the meticulous surgeon a new pedicle screw system that securely immobilizes the spine.

### **External spinal fixator**

The development of the “fixateur interne” has its origins in the developments by Friedrich P Magerl. Since 1977, Magerl has been working on the applications of external spinal skeletal fixator (ESSF).<sup>24</sup> The ESSF system consists of obtaining



segmental spine fixation through posteriorly placed pedicle screws held rigidly fixated by an external apparatus. He utilized 5 mm Schanz screws placed into the pedicles through either an open or closed technique.

Magerl and the Swiss Research Institute Laboratory for Experimental Surgery in Davos developed a connecting device to obtain rigid external fixation of the screws.<sup>24</sup> Magerl reported using the ESSF for fractures and infections. His results were very encouraging, but it was inconvenient for the patient to have an external fixation apparatus for weeks at a time.

With the ESSF, Magerl launched a new dimension in spinal instrumentation—reduction and restoration of anatomy while fusing only a limited number of segments—which has great potential. Also, he tried to achieve optimal stability for immediate mobilization with minimal external support. Based on these ideas, W Dick modified the ESSF. The *fixateur interne*, as developed by Dick, consists of long 5 mm Schanz screws that are inserted posteriorly through the pedicles into the vertebral bodies.

The connector is a 7 mm threaded longitudinal rod with flat sides and clamps that are mobile in every direction, and it is completely implanted using the posterior approach. The clamps hold the Schanz screw; the threaded rod permits distraction or compression. Through the long lever arm of the Schanz screws and moveable clamps, it is possible to apply lordotic or kyphotic forces. The configuration can then be fixed in the desired position with nuts.

### **The Edwards modular system**

The Edwards Modular System has evolved from a 12-year effort to sequentially overcome the problems and limitations faced by surgeons who seek to reconstruct the deformed or unstable spine.<sup>10</sup> It combines the contributions of Paul Harrington and Ramon Roy-Camille and adds the concept of adjustable transverse control in all dimensions. In the late 1970s, Charles Edwards, MD, concentrated on the surgical reconstruction of the injured spine.<sup>10</sup> From this experience, it became apparent that, for optimal results, a sur-

geon should first determine the primary vector(s) of injury from radiographs and then use instrumentation to directly counteract these deforming forces. Since most thoracolumbar fractures were caused by compression, flexion, and rotational forces, instrumentation was needed that could generate distraction and extension, and provide rotational control.

Harrington rods contributed the necessary distraction, but, even when contoured, provided only minimal extension and virtually no rotational control, resulting in frequent hook dislodgment. To provide the necessary active lordosis and rotational control, rod-sleeve spacers and the rod-sleeve method were developed to improve reduction and provide “indirect compression” of flexion-compression injuries.

The rod-sleeve method consistently yielded anatomic alignment, but laminar edge reabsorption with occasional hook dislodgment still occurred. These hook interface problems led to the design of an L-shaped anatomic hook in 1982. The L design increased hook-laminar contact area over C-shaped hooks to reduce laminar reabsorption and hook dislodgment.

The next problem was the inability to anchor rods directly to the sacrum to apply compression or distraction forces across the lumbosacral junction. The Sacral Fixation Device was developed in 1983 to overcome this limitation.<sup>10</sup> This device introduced two new capabilities: 1) the ability to attach spinal rods, which could be ratcheted in either compression or distraction, directly to the sacrum with screws; and 2) the ability to attach to proximal vertebrae with either laminar hooks or pedicle screws, designed for sacral alar or lumbar pedicle fixation.<sup>10</sup>

The capability of secure fixation in compression across the lumbosacral junction improved the in situ fusion rate and effectiveness in treating low lumbar nonunion. However, the systems still lacked the versatility needed to correct most lumbar deformities without anterior or trans-spinal releases and forced manipulation. In an effort to achieve more correction of deformity with less surgery, Edwards sought to incorporate intraoperative stress relaxation. However, this

required instrumentation with adjustability in all planes of motion. This requirement was fulfilled with the development of adjustable pedicle connectors in 1985. Connectors served as linkages between spinal screws and rods. They could be shortened or lengthened and positioned to translate individual vertebrae in any direction. Combining adjustable connectors with bi-directional ratcheting rods made it possible to gradually apply corrective forces and maintain stable fixation in all dimensions.

During the past five years, Edwards and his associates have focused on the development of surgical procedures that incorporate stress-relaxation to improve correction of kyphosis, spondylolisthesis, scoliosis, and other thoracic and lumbar deformities.<sup>10</sup> As the scope of surgery expanded, Edwards saw the need to enhance the overall stiffness of the final construct in selected cases. This need was met with the recent addition of adjustable-rod crosslinks.

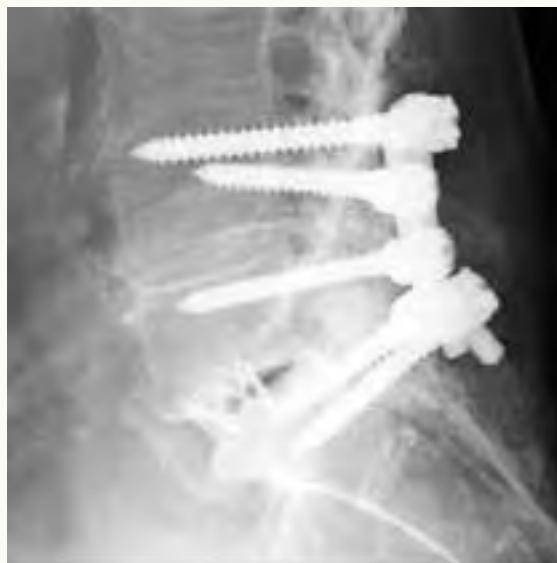Over the past decade, Edwards modular instrumentation has become a comprehensive posterior spinal system composed of six basic components:

1. Anatomic hooks for attachment to thoracic or lumbar lamina.
2. Screws for secure fixation to the sacrum or lumbar pedicles.
3. Bi-directional ratcheted universal rods for axial control.
4. Various-sized rod-sleeves as fixed transverse spacers.
5. Pedicle connectors for adjustable transverse control in all directions.
6. Adjustable-rod crosslinks for control of relative rod position and instrumentation stiffness.

These six components or “modules” can be assembled into a variety of constructs, depending on the biomechanical needs of each case. For example, the compression construct is designed to provide both stabilization and physiologic axial loading to promote bony union. Other constructs are designed to apply optimum corrective forces over time for greater reduction or deformity with

less invasive surgery than required in the past. These include the rod-sleeve construct for thoracolumbar fractures, the distraction-lordosis (D-L) construct for lower lumbar fractures and degenerative listhesis, the kyphoreduction construct, spondylo construct, and various scoliosis constructs. Extensive studies of these constructs have demonstrated improved clinical results.

Arthrodesis of long segments of the spine to a sacrum may be necessary for a variety of pathologic conditions and indications. The surgery may be necessary for patients who have had prior surgery, had failure of a fusion, or had degeneration above the area of prior fusion. Revision of prior surgeries, in which distraction instrumen-



**FIGURE 3**

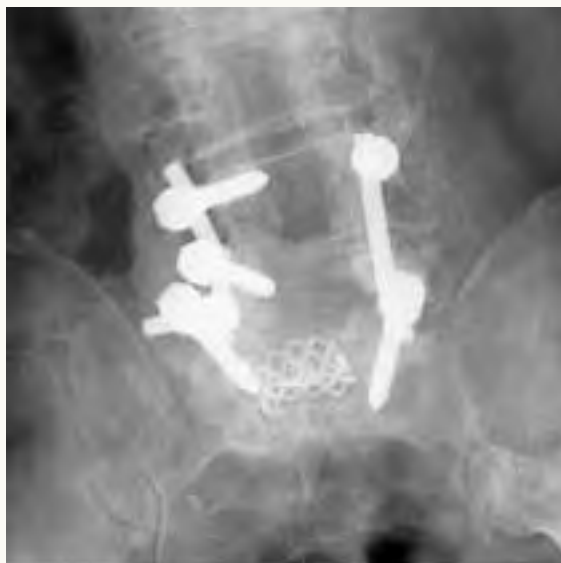In this patient with spinal stenosis, bilateral posterior spinal rods bridge L4, L5 and S1 (anteroposterior view following a laminectomy).

tation was used resulting in flat-back deformity, remains a problem. A better understanding of the biomechanical stresses placed on the fixation devices and the bone-implant interface has resulted in the development of improved techniques of fixation in the lower lumbar spine and the sacrum. This fixation always requires multiple levels of segmental spinal instrumentation. The type of instrumentation depends on the design of fixation, whether it is wire, hook, or screw, and the bone into which it is placed.

### Conclusion

The surgeon needs to understand the limitation of both the instrumentation and the bone prior to

proceeding with this demanding surgery. Why is so much emphasis placed on instrumentation? A tendency exists to not pay enough attention to the most important part of the operation. The surgery is always an arthrodesis and an attempt to place the spine in a stable and balanced position. Meticulous surgical techniques for arthrodesis are required, or failure is likely to occur. If the spine is placed in an unbalanced situation and the fusion area is placed under tension, failure of fusion and, subsequently, of the instrumentation will occur. The understanding of these concepts and principles is more critical to the success of this type of surgery than the specific instrumentation used. Instrumentation will continue to change using different met-



**FIGURE 4**

A lateral view of

the rods in

Figure 3. The

small metal cage

contains bone

graft material to

promote osseous

fusion at this

site.

allurgy and designs, but these principles and the goal of obtaining a solid arthrodesis and a balanced spine will never change.

### References

1. Albee FH. Transplantation of a portion of the tibia for Potts disease. *Journal of American Medical Association*. 1911; 57. 885-886.
2. Birch, Camp, Corin, et al. Rotational stability of various pedicle hook designs—an in-vitro analysis. Presented at the Annual Meeting of the Scoliosis Research Society. Amsterdam, The Netherlands. September 17-22, 1989.
3. Boucher, H.H. A method of spinal fusion. *Journal of Bone Joint Surgery*. 1959;41B. 248.

4. Boucher, Burkus, Sutherland, et al. Jacobs locking hook spinal rod and the AO fixator intern for fractures of the thoracic and lumbar spine. Submitted for publication. Unpublished data.
5. Cotrel, Dubousset, Guillaumat. New universal instrumentation in spinal surgery. *Clinical Orthopedics*. 1988; 227. 10-23.
6. Denis, Ruiz, Searls. Comparison between square ended distraction rods and standard round ended distraction rods in the treatment of thoracolumbar spinal injuries. A statistical analysis. *Clinical Orthopedics*. 1984; 189. 162-167.
7. Denis F. Cotrel-Dubousset instrumentation in the treatment of idiopathic scoliosis. *Orthopedic Clinic of North America*. 1988;19. 291-311.
8. Ecker, Betz, Trent, et al. Computer tomography evaluation of Cotrel-Dubousset instrumentation in idiopathic scoliosis. *Spine*. 1988;13. 1141-1144.
9. Edwards CL, Levine AM. Early rod-sleeve stabilization of the injured thoracic and lumbar spine. *Orthopedic Clinics of North America*. 1986; 17. 121-145.
10. Edwards CC. Sacral fixation device—Design and preliminary results. Scoliosis Research Society Annual Meeting. Orlando, Florida. 1984.
11. Gertzbein, Jacobs, Stoll, et al. Results of a locking hook spinal rod for fractures of the thoracic and lumbar spine. *Spine*. 1990; 15. 275-280.
12. Gurr, McAfee, Shih. Biomechanical analysis of posterior instrumentation systems after decompressive laminectomy. *Journal of Bone Joint Surgery*. 1988; 70A. 680-691.
13. Gurr, McAfee, Warden, et al. *A roentgenographic and biomechanical analysis of spinal fusions; A canine model*. Baltimore: Scoliosis Research Society. 1988. 77-78.
14. Harrington PR, Tullos HS. Reduction of severe spondylolisthesis in children. *South Medical Journal*. 1969; 62. 1-7.
15. Herrmann HD. Transarticular metal plate fixation for stabilization of the lumbar and

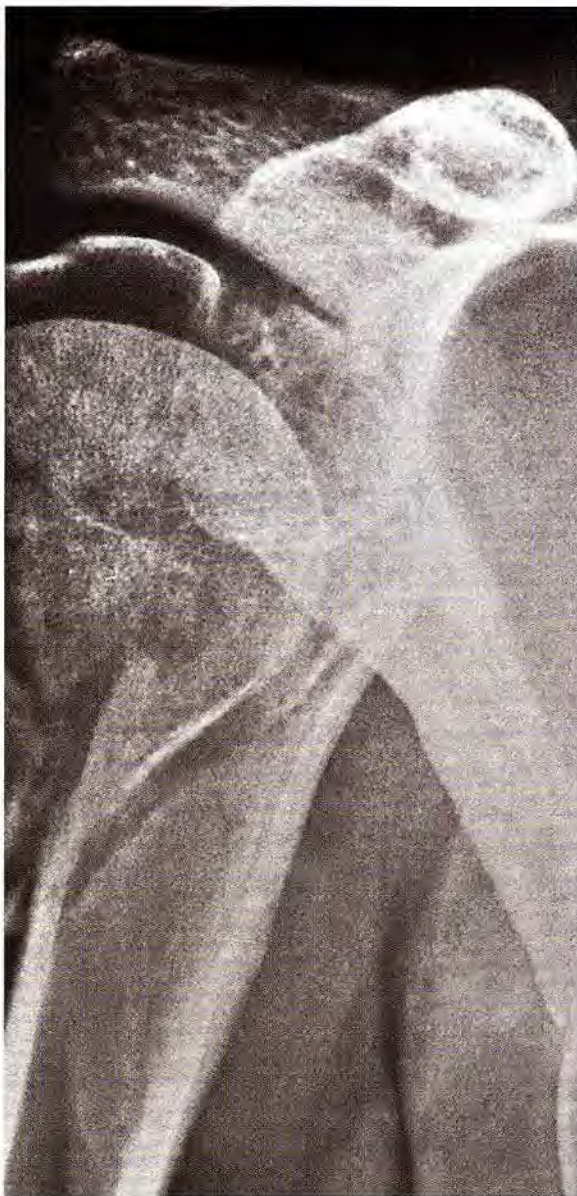

- thoracic spine. *Acta Neurochir.* 1979; 48. 101-110.
16. Johnston, Ashman, Corrin. *Mechanical effects of crosslinking rods in Cotrel-Dubousset instrumentation.* Hamilton, Bermuda: Scoliosis Research Society. 1986. 77-78.
  17. King D. Internal fixation for lumbo-sacral fusion. *American Journal of Surgery.* 1944;66. 357.
  18. Krag, Weaver, Beynon, Haugh. Morphometry of the thoracic and lumbar spine related to transpedicular screw placement for surgical spinal fixation. *Spine.* 1988;13. 27-32.
  19. Lange F. Support for the spondylitic by means of buried steel bars attached to the vertebrae. *American Journal of Orthopedic Surgery.* 1910; 8. 344-361.
  20. Lesion, Bouassakao, Cama, et al. Posttraumatic fixation of the thoracolumbar spine using Roy-Camille plates. *Neurosurgery.* 1982;18. 167-173.
  21. Louis R., Maresca C. Lumbo-sacral fusion by internal fixation. *Clinical Orthopedic Research.* 1985;203. 18-33.
  22. Luque E. The anatomic basis and development of segmental spinal instrumentation. *Spine.* 1982; 7. 256-259.
  23. MacEwen, Bennett, Guille. Autologous blood transfusions in children and young adults with low body weight undergoing spinal surgery. *Journal of Pediatric Orthopedics.* 1990; 10. 750-753.
  24. Magerl FP. Stabilization of the lower thoracic and lumbar spine with external skeletal fixation. *Clinical Orthopedics.* 1984; 189. 125-141.
  25. McAfee, Werner, Glisson. A biomechanical analysis of spinal instrumentation systems in thoracolumbar fractures—Comparison of traditional Harrington distraction instrumentation with segmental spinal instrumentation. *Spine.* 1985;10. 204-217.
  26. Muller, Allgower, Schneider, et al. *Manual of internal fixation.* 3rd ed. Berlin: Springer-Verlag. 1991. 627- 682.
  27. Ogilvie JW, Bradford DS. Lumbar and lumbosacral fusion with segmental fixation. Scoliosis Research Society Annual Meeting. Orlando, Florida. 1984.
  28. Resina J, Alves A. A technique for correction and internal fixation for scoliosis. *Journal of Bone Joint Surgery.* 1977; 59:2. 159-165.
  29. Richards, Birch, Herring, et al. Frontal plane and sagittal plane balance following Cotrel-Dubousset instrumentation for idiopathic scoliosis. *Spine.* 1989; 14. 733-737.
  30. Roy-Camille R, Demeulenare C. Plating of thoracic, thoracolumbar and lumbar injuries. *Orthopedic Clinic of North America.* 1986; 17. 147-161.
  31. Sasso, Cotler, Reuben. Posterior fixation of thoracic and lumbar spine fractures using DC plates and pedicle screws. *Spine.* 1991;16. 5134-5139.
  32. Schlapfer, Worsdorfer, Magerl, et al. Stabilization of the lower thoracic and lumbar spine: comparative in-vitro investigation of an external skeletal and various internal fixation devices. In: Uhtoff HK, Stahl E, eds. *Current concepts of external fixation of fractures.* New York: Springer-Verlag. 1982. 367-380.
  33. Steffee AD, Sitkowski DJ. Posterior lumbar interbody fusion and plates. *Clinical Orthopedics.* 1988; 227. 99.
  34. Steffee, Biscup, Sitkowski. Segmented spine plate with pedicle screw fixation: A new internal fixation device for disorders of the lumbar and thoracolumbar spine. *Clinical Orthopedics.* 1986;203. 45.
  35. Thalgott, LaRocca, Aebi, et al. Reconstruction of the lumbar spine using AO DCP plate internal fixation. *Spine.* 1989;14. 91-95.
  36. Wiltse, Bateman, Hutchinson, et al. The paraspinous sacrospinalis-splitting approach to the lumbar spine. *Journal of Bone Joint Surgery.* 1968; 50A. 919.
  37. Yashon D. *Spinal Injury.* Appleton-Century-Crofts. 1978. 1-4.
  38. Zindrick, Wiltse, Widell, et al. A biomechanical study of intrapedicular screw fixation in the lumbosacral spine. *Clinical Orthopedics.* 1986; 203. 99.

Images used courtesy of Michael L Richardson, MD, University of Washington, [www.rad.washington.edu](http://www.rad.washington.edu)

# Bone healing

Teri Junge, CST/CFA



**FIGURE 1**

Malunited 4-part fracture, five months after accident.

The first step in fracture healing is stabilization of the fracture site, mechanically. Healing cannot occur if the bone fragments are not reduced and held securely in position. As surgical technologists, we are aware of the surgical interventions that are used to reduce and stabilize a fracture. The procedure may be as simple as closed reduction and casting or may be more invasive. Many types of devices are available for surgical fracture stabilization, including the internal and external fixation devices with which we are all familiar. In the extreme case, partial or total joint replacement may be indicated.

If a fracture has been properly immobilized and aligned, the normal physiologic mechanisms of the human body should facilitate bone healing. Sometimes, however, that process gets disrupted. This article, the second part in a series, discusses disrupted bone healing and the factors that enhance proper bone healing. To review normal physiology, see "Bone Healing-Normal" in the March 2002 *Journal*.

## Disrupted bone healing

A disruption at any stage of bone healing or maintenance can be responsible for a variety of abnormal conditions.

Avascular necrosis occurs when the capillary network or collateral circulation cannot be reestablished following a traumatic injury of when the vascular system is disrupted by other



means. This can be pharmacologic (eg steroid use), pathologic (eg diabetes), or idiopathic. Decreased blood supply to the bone may lead to irreversible necrosis.

Osteomyelitis is an inflammation of the bone, marrow, and possibly the surrounding tissue commonly due to a *Staphylococcus aureus* infection. Prevention is the main issue; although, occasionally wound contamination cannot be avoided due to the type of injury sustained (especially in the case of a compound fracture). Chronic infection can result if the acute condition is not recognized or treated properly.

Compartment syndrome is an increase in pressure within a closed space. Excess pressure leads to neurovascular compromise. Tissue viability may be affected, increasing the risk for infection, and permanent nerve damage can occur.

Malunion is solid union of the fractured bone in a deformed position (Figure 1). This results from either inadequate reduction or immobilization. Patient noncompliance is often a factor.

Delayed union may have one or several determining causative factors including pathologic (eg osteoporosis), mechanical (eg distraction of the fracture site or inadequate immobilization), traumatic, referring to the type of injury sustained (eg comminuted fracture).

Nonunion is a failure of the bone fragments to calcify together. Often the space between the fragments is too large or soft tissue may be entrapped between the fragments. Improper immobilization and excess activity by the patient can disrupt an otherwise normal cycle of bone healing. Infection, nutrition, hormones, and circulation are also factors to be considered.

### Factors that enhance bone healing

Several options are available to the clinician and the patient to enhance fracture healing.

- Good nutrition and overall health are two very important influences on fracture healing. Calcium (RDA for the average, healthy adult is 800 mg) and Vitamin D (RDA for the

## Bone healing terminology

**Endosteum**—thin vascular membrane that lines the marrow cavity of long bones.

**Fibroblast**—immature, fiber producing, connective tissue cell proliferated at the site of inflammation. Fibroblasts are capable of differentiation into a chondroblast, a collagenoblast, or an osteoblast.

**Osteoblast**—cell associated with bone formation that arises from a fibroblast.

**Osteoclast**—cell associated with destruction and resorption of bone.

**Osteocyte**—mature, functional bone cell found in osteons.

**Osteomalacia**—softening of bone due to inadequate or delayed mineralization.

**Osteomyelitis**—inflammation of bone, marrow, and possibly the surrounding tissue usually due to infection.

**Osteon**—structural unit of mature compact bone.

**Periosteum**—dense fibrous membrane that covers the exterior surface of bone. Contains nerves, blood vessels, lymphatics, and osteoblasts. Responsible for nourishment and bone growth. Allows for attachment of tendons.

**Proliferate**—to reproduce or multiply.

**Calcitonin**—thyroid hormone that promotes the deposit of calcium in bone.

**Calcium**—chemical element responsible for hard bones and teeth, essential for normal heart, nerve, and muscle function, and is involved in normal blood coagulation (Factor IV).

**Parathyroid Hormone**—promotes movement of calcium from bone to blood.

**Vitamin D**—increases calcium in the body by allowing absorption from the GI tract.



average, healthy adult is 5 g) supplements are extremely helpful.

- Loading or placing stress on the bone is thought to produce a small electrical field that stimulates new bone formation.
- Treatment of osteoporosis (a gradual decrease in bone density begins in the late 30s in both men and women—osteoporosis does NOT only affect postmenopausal women).
- Grafting-bone may be taken from the patient (autograft), another human—most likely a cadaver (allograft), or a non-human source (xenograft). Xenograft materials include marine coral (coralline hydroxyapatite) and bovine collagen (collagraft). Xenografts are not actually bone replacements, but are considered scaffolds or structural foundations for natural bone regrowth. The graft must be capable of being included in the new growth and undergoing the remodeling process. The use of a fixation device may be necessary in addition to the graft to stabilize the fracture site.
- Injectable growth factor proteins are under investigational use. Additional amounts of the growth factor proteins, such as morphogenic protein and transforming growth factor-beta, which are normally found in the body, may be capable of encouraging faster and stronger bone healing.
- Bone filler paste is also being evaluated for fracture stabilization. The paste is injected at the fracture site and within 12 hours, the tensile strength of the bone is restored. The paste is reported to stabilize the fracture during healing and undergo the remodeling process.
- Electrical bone growth stimulators and ultrasonic devices stimulate the normal cellular processes at the fracture site. The stimulator may be noninvasive or implantable and may be used alone or in conjunction with open reduction internal fixation (ORIF), external fixation devices, and various grafting techniques. The external electrical stimulation is thought to reproduce the same type of electric force that is naturally created when the bone is loaded.

Many new therapies are on the horizon that will enhance fracture healing by improving the natural course of healing. Some of these techniques will require surgical expertise and others will encourage bone healing, thereby making the patient's post-injury course less painful and shorter in duration.

## References

1. Avascular Necrosis on Bone Scan. [www.mamc.amedd.army.mil/williams/NucMed](http://www.mamc.amedd.army.mil/williams/NucMed) Accessed 1-3-02
2. Becca Maddox Nursing 2204.Fall 1998. Orthopedics. [www.fc.peachnet.edu](http://www.fc.peachnet.edu) Accessed 1-3-02
3. Low-intensity Ultrasound Speeds Bone Fracture Healing. Academy of Orthopaedic Surgeons. AAOS On-Line Service. [www.aaos.org/wordhtml/press/sciwrit/ultra.htm](http://www.aaos.org/wordhtml/press/sciwrit/ultra.htm) Accessed 1-3-02
4. New Ways to Heal Broken Bones Directions in Health Care. [www.dentalcare.com/soap/archives/directhc/bones.htm](http://www.dentalcare.com/soap/archives/directhc/bones.htm) Accessed 1-3-02
5. Caruthers B, Price P, Junge T, Price B. *Surgical Technology for the Surgical Technologist: A Positive Care Approach*. Albany, NY: Delmar Thompson Learning; 2001.
6. The Normal Process of Bone Healing and Repair. [www.ebimedical.com/normal](http://www.ebimedical.com/normal) Accessed 1-3-02
7. Wheelless' Textbook of Orthopaedics. [medmedia.com](http://medmedia.com) Accessed 1-3-02

*Image used courtesy of  
AO Publishing ©2001.*



# CERVICAL FUSION

Roger Mullis, CST

In the normal aging process, the water content in the nucleus of the spinal disc commonly decreases with time, leading to disc degeneration. In a study by Gore and colleagues, researchers discovered that by 60 to 65 years of age, 95% of men and 70% of women had at least one disc level with degeneration on the cervical spine.<sup>1</sup>

Statistics for the number of spinal surgeries performed annually are already high. According to the American Association of Neurological Surgeons' 1999 Procedural Statistics, total number of spinal procedures topped a half million that year. Of those, more than 111,000 were functional arthrodeses, and almost 78,600 were anterior discotomies.<sup>2</sup> A majority of both of these procedures were performed on the cervical spine. As the Baby Boom population continues to age, the number of surgeries and need for this expertise will continue to increase.

# ANTERIOR

## Overview

Anterior cervical fusions (ACFs) have been routinely performed since the late 1950s when the procedure was first introduced. A small incision is made on the anterior neck just lateral of midline. After meticulous dissection, the operative level of the cervical spine is identified and exposed. The cervical disc is removed, relieving pressure on the spinal cord and nerve roots. The disc is then replaced with either the patient's own bone graft from the iliac wing (autograft) or bank bone (allograft). Artificial grafts can also be utilized; however, this article will not address artificial grafts since they account for less than 1% of cases.

## Anatomy

The cervical spine is composed of seven vertebral bodies, commonly referred to as C1 through C7. The cervical spine has a lordotic curve (a backward "C" shape). The major difference between the cervical spine and the rest of the spine are the transverse foramina, located in the vertebral bodies that allow passage of vertebral arteries and veins.

There are three distinct anatomic regions to the cervical spine: the atlas (C1), the axis (C2), and the remaining cervical vertebra (C3 through C7). The discs of the cervical spine are anatomically identical to the discs found in the rest of the spine. The disc is composed of the annulus fibrosis and the nucleus pulposus. The annulus is a fibrous ring-like structure, which serves to connect the vertebral bodies. In the center of the annulus is the nucleus. The nucleus, which has an almost "crab meat" type texture, acts along with the annulus as a shock absorber against loading on the spine. The annulus is weakest at the posterolateral margin. Ligaments provide less support in this area, making herniation of the nucleus much more common (Figure 1).

## Patient indications

In a study by Kelaey and colleagues, researchers found that acute cervical disc herniations affected people in their fourth decade more than any other age group.<sup>1</sup> The male to female ratio was

1.4 to 1, and the vast majority of those had involvement at the C5-C6 and C6-C7 levels. They also found that factors such as frequent heavy lifting at work and direct trauma to the neck (eg whiplash-type injury) can lead to ACFs. In the aforementioned study, doctors found that, of 205 patients that were followed for a minimum of 10 years after the onset of their pain, 79% had a decrease in pain, while 43% were now pain free. Persistent moderate-to-severe pain was seen in 32% of patients.

The vast majority of possible ACF patients present with complaints of moderate-to-severe neck pain. Symptoms include arm pain (either bilateral or unilateral), shoulder pain, loss of motion, weakness, paresthesia, severe headaches, even the legs can be affected. Surgery is not usually indicated unless the patient does not respond to six weeks of conservative treatment, has major neurologic deficit, or non-improving significant deficit.

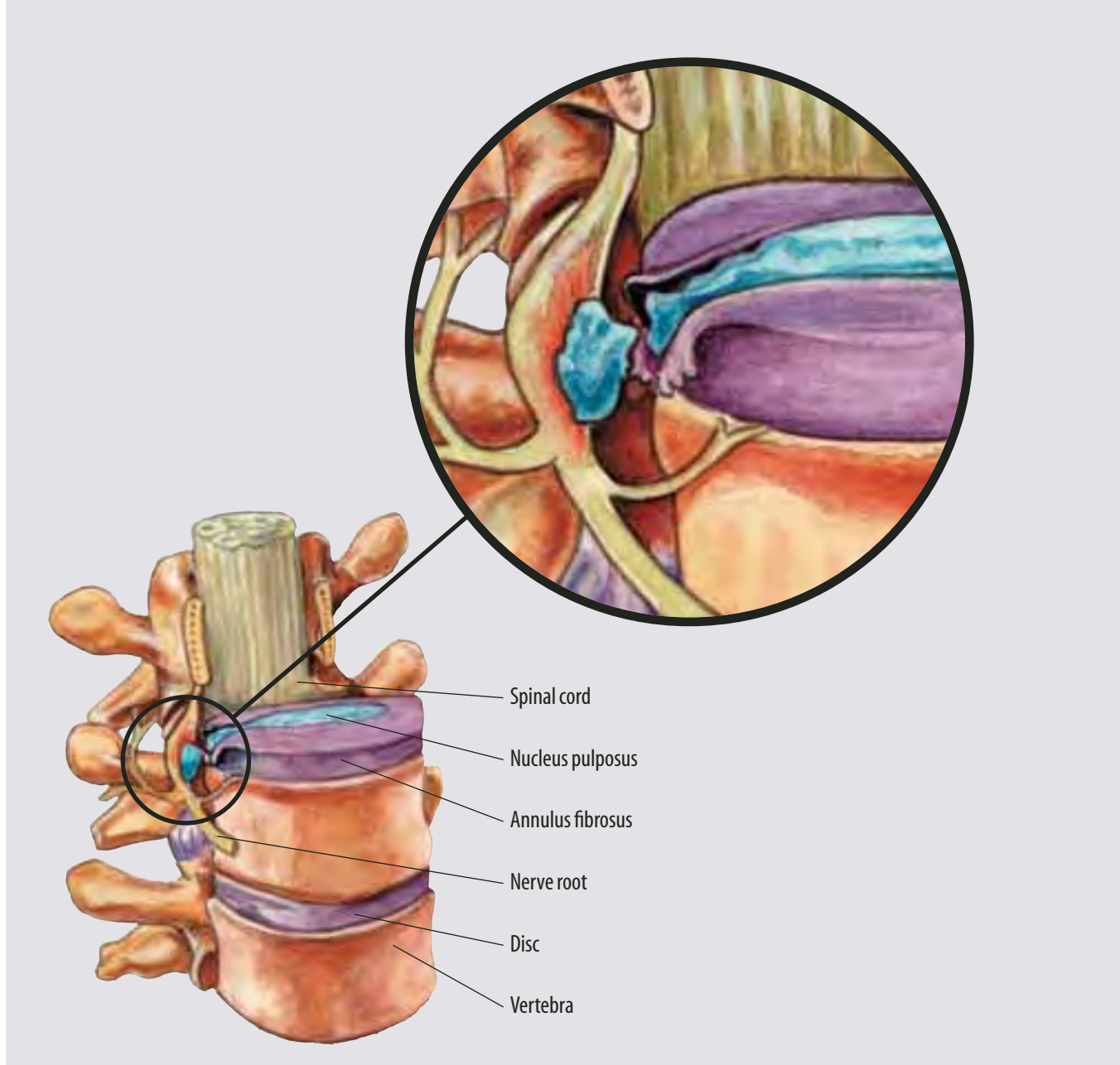
The symptoms that can lead to ACF are also associated with rotator cuff disease, shoulder pathology, impingement syndrome, or instability.

## Room set-up and instrumentation

Beyond instrumentation, pay particular consideration to patient positioning equipment. After the patient is put under general anesthesia, he/she should be placed in the supine position. Every effort should be made to keep the patient comfortable and well padded. This is accomplished with the aid of egg crate foam placed on the bed, along with foam heel padding and pillows or bolsters under the knees keeping them slightly bent. These efforts are important to prevent decubitus ulcers. Antiembolism sleeves or stockings should be placed on the legs as well. The placement of a Foley catheter is recommended for cases that are estimated to last four hours or longer.

It is important to keep access to the hip available if the surgeon has indicated that autograft will be used. Many surgeons prefer to place a padded bump (either a sandbag or an IV bag) under the hip that will be used for harvesting the autograft. A second roll towel will be placed





under the patient's shoulder to aid in extending the neck. After positioning, the patient's entire anterior neck surface is prepped in the usual manner. A second prep kit is necessary for graft harvesting.

Many surgeons will place a Gardner Wells Tongs to the patient's skull, often with the aid of fiber optic endotracheal equipment so as not to endanger an already unstable neck, and add anywhere from 5-10 pounds of weight on the device. This technique accomplishes cervical distraction and avoids the need for placement of distraction pins in the vertebral bodies. Other miscellaneous equipment may include a fluid warmer, surgical microscope or loops, neuro-monitoring equip-

ment, a patient warmer, or an AGF (autologous growth factor) blood machine.

### Procedure

After draping, a 4 cm incision is made just lateral of midline. The anterior approach is very versatile and, while the vast majority of incisions are made on the patient's right side, either side is acceptable. The side chosen for incision is mostly a matter of surgeon's preference. The left side may be preferred because of the anatomy of the recurrent laryngeal nerve. On the left side, the nerve is in the carotid sheath, then loops under the aortic arch and ascends in the neck, where it is protected by the esophagus and trachea. On

**FIGURE 1**

Herniated disc

## FIGURE 2

Disc material  
being removed

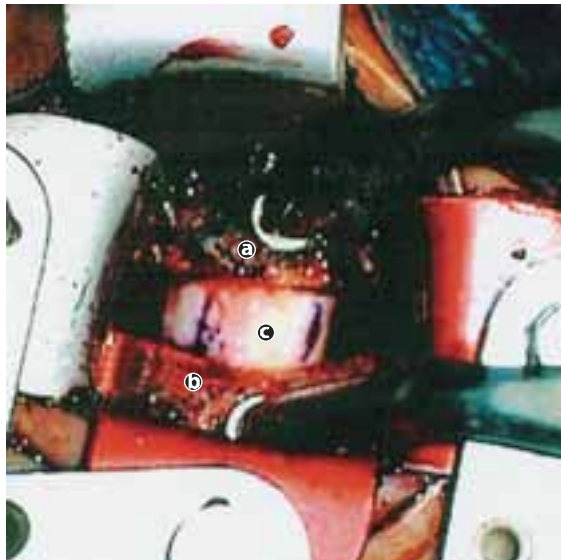- Ⓐ C4
- Ⓑ C5
- Ⓒ discspace



## FIGURE 3

Graft in place  
(single level ACF)

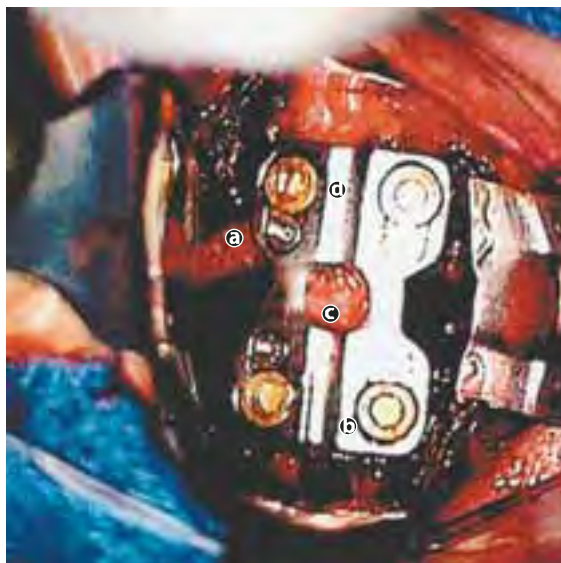- Ⓐ C4
- Ⓑ C5
- Ⓒ discspace



## FIGURE 4

Final plate on  
graft

- Ⓐ C4
- Ⓑ C5
- Ⓒ interbody graft
- Ⓓ Codman plate



the right side, the nerve will exit the carotid sheath at a higher level and cross the surgical field. The nerve is more susceptible to injury with a right-sided approach, but injury can occur on either side.

Meticulous dissection and identification is vital to avoid injury. Hemostasis is accomplished while the carotid sheath and sternocleidomastoid muscles are moved laterally. The esophagus is moved and held medially with hand-held Cloward retractors. At this point, it is important to identify the affected disc space with X-ray. An 18 gauge spinal needle, bent in a “stair-step” style is placed directly in the disc. After X-ray, the self-retaining retractor is placed. Our facility uses both the Shadowline and Trimline style of ACF retractors. While the blades for the retractor that are being placed both medially and laterally can have teeth; the superior and inferior blades should have no teeth to protect the carotid sheath and the esophagus.

Now that the proper cervical spine level has been identified and the retractor placed, removal of the disc can begin (Figure 2). A #15 blade is used to make a small stab wound in the annulus of the disc. The bulk of the disc is carefully removed with pituitary rongeurs. After removal, the surgeon may choose to place distraction pins into the vertebral bodies above and below the affected level. After the distracter is placed onto the pins and distraction is achieved, the disc space is opened approximately 1-2 mm more than its normal height. This will allow a more thorough removal of disc and easier placement of the replacement graft. After complete removal of the disc, any prominent bone spurs are removed to alleviate any impingement of either the nerve roots or the spinal cord itself. A caliper is then used to measure dimensions of the graft. After measurements are taken and recorded, the graft can be harvested from the patient’s iliac wing or the allograft can be shaped for placement.

If the surgeon and patient have agreed on the use of allograft, it is very important to follow the set guidelines for sterile handling. Soak the graft in antibiotic solution per the manufacturer’s instructions (usually 30 minutes). The graft can now be shaped precisely (following earlier measurements)

with a burr to fit the cleaned-out disc space. A precise fit is crucial, since a graft that is too large can lead to graft extrusion, and one too small can lead to intrusion. Intrusion of the graft could be disastrous, causing impingement of the spinal cord.

The graft size is consequential because a properly fitting graft will fuse with the adjoining vertebral bodies much sooner (Figure 3). The graft is then tapped into place using a precision bone tamp and small mallet. After placement, the graft is checked with a blunt nerve hook for impingement of the cord. If the surgeon is satisfied with the graft placement, the distraction pins can be removed and the screw holes sealed with bone wax to prevent bleeding. At this point, placement of a plate and screws would follow (Figure 4).

On a one-level fusion, the use of instrumentation is at the surgeon's discretion, as it is not always indicated. The use of plating on single-level fusions would depend on a number of factors: the patient has indicated the desire to return to work and a normal lifestyle quickly, or the patient wants to avoid wearing a cervical collar. On multiple-level ACFs, a cervical plating system is the standard of practice and is almost always indicated. These systems provide a higher fusion rate and better maintenance of cervical lordosis or curvature.

### Disadvantages of ACF

Beyond the usual possible complications that are found with any surgery (eg infection, rejection of the graft, scarring), there are usually few, if any, real problems with a one- or two-level fusion. Problems that may occur include temporary sore throat and loss of voice. The greatest risk, of course, is for spinal cord damage; however, this is a very rare event. In a study by Flynn, of 82,000 cases, spinal cord injury occurred in 0.1% of cases.<sup>1</sup>

As the number of levels increases, so do the complications. With any fusion, patients experience some loss of motion. With the single- or two-level fusion, this loss is often not noticeable by the patient. As more levels are fused, loss of motion increases.

Another long-term consideration is the increased axial loading that is placed on the

healthy disc spaces above and below the surgical site. As the number of levels increases, the axial loading on the adjacent healthy disc spaces is greatly increased, typically causing premature disc degeneration to occur over the next 15 to 20 years.

### Summary

Anterior cervical fusion is an important procedure to the many patients who require it. The patient's life has often been "put on hold" until this procedure can be performed. For many patients, this procedure is a life-altering event. The knowledge, continuing education and skill of the surgical team is paramount to positive outcomes for the patients. As the technology for plating systems improves and advances, surgical technologists should anticipate being able to serve an aging and growing population even better.

### About the author

Roger Mullis, CST, is co-coordinator for the neurosurgical team at Redding Medical Center in Redding, California. He received his training at the Academy of Health Sciences, Ft Sam Houston, Texas, and Walter Reed Medical Center, Washington, DC. He is also a site inspector for the Accreditation Review Committee on Education in Surgical Technology.

### Acknowledgments

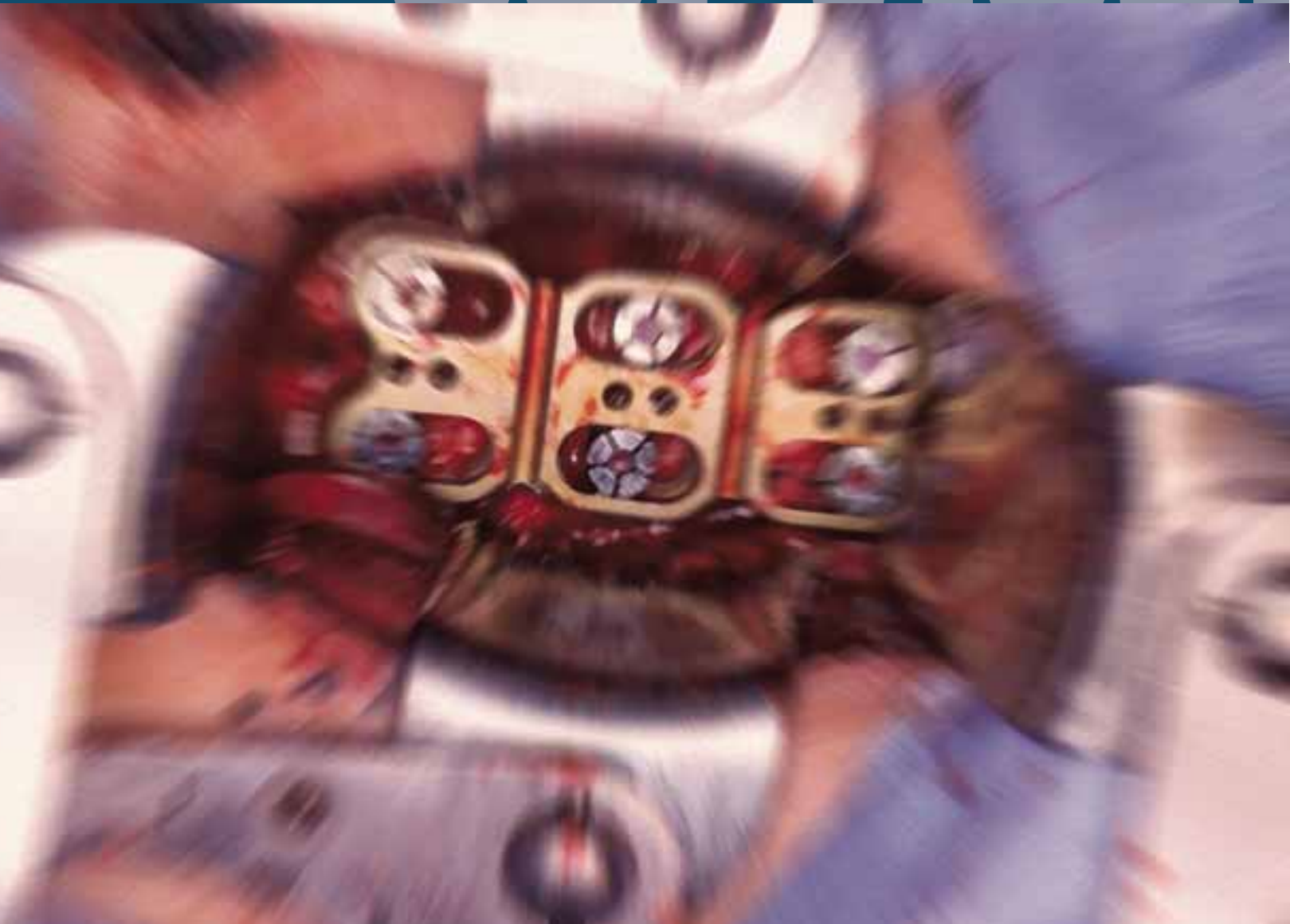The author would like to thank Lisa Often, RN, John Bennet, RN, the operating room team at Redding Medical Center, Dr Afra Guity, Dr Gary Lam and Dr Kevin Lawson.

### References

1. Rappoport and O'Leary, Cervical Disc Disease. *The textbook of Spinal Surgery*. 2nd edition. Philadelphia, Penn:Lippincott Raven; 1997.
2. National Neurosurgical Statistics, 1999 Procedural Statistics. Top Reported Spine Procedures Performed in 1999. American Association of Neurological Surgeons. [www.neurosurgery.org/aans/membership/stats/spine.html](http://www.neurosurgery.org/aans/membership/stats/spine.html) Accessed 5/9/02
3. Cervical Herniated Disc [spineuniverse.com/displayarticle.php/article265.htm](http://spineuniverse.com/displayarticle.php/article265.htm) Accessed 5/14/02



# Anterior Cervical



# CORPECTOMY, FUSION, AND STABILIZATION

JEFFREY J CORTESE, CST

**B**AILEY, BADGLEY, CLOWARD, SMITH, AND ROBINSON PIONEERED THE ANTERIOR SURGICAL APPROACH TO THE CERVICAL SPINE IN THE 1940S.

TODAY, IT IS THE MOST COMMONLY UTILIZED APPROACH FOR ADDRESSING DEGENERATIVE DISEASE OF THE CERVICAL SPINE. THE NUMEROUS ADVANTAGES OF THE ANTERIOR APPROACH ARE (1) DIRECT VISUALIZATION OF ANTERIOR PATHOLOGIC LESIONS, (2) SAFETY IN TERMS OF AVOIDING THE NEED FOR DIRECT MANIPULATION OF NEURAL ELEMENTS, AND (3) THE ABILITY TO

DIRECTLY DISTRACT ACROSS COLLAPSED DISK SPACES, THEREBY REDUCING BUCKLING OF THE LIGAMENTUM FLAVUM, INCREASING THE SIZE OF THE NEUROFORAMEN, AND ACHIEVING AN INDIRECT DECOMPRESSION OF NERVE ROOTS. OVER THE YEARS, TWO PRINCIPAL PROCEDURES HAVE EMERGED FOR ACCOMPLISHING THESE GOALS: ANTERIOR CERVICAL DISCECTOMY AND INTERBODY FUSION (ACDF), AND ANTERIOR CERVICAL CORPECTOMY WITH STRUT GRAFTING. THE ANTERIOR CORPECTOMY WITH STRUT GRAFTING WILL BE FURTHER STUDIED IN THIS ARTICLE.

## Anatomy of the cervical spine

In the cervical region, the C1 to C6 vertebrae contain transverse foramina that perforate each transverse process and also contain the vertebral artery en route to the cranium (Figure 1). The vertebral artery enters the cervical spine through the transverse foramen of the C6 vertebral body.

The atlas, or C1, and the axis, or C2, are distinctive cervical vertebrae. The C1 vertebrae has neither a body nor a spinous process but consists instead of two lateral masses and two arches, anterior and posterior. Its superior facets articulate with the occipital condyles, and its inferior facets with the axis, or C2 vertebrae.

The atlas is prone to an axial compression fracture by trauma, also known as a Jefferson fracture. It is also prone to ligamentous laxity and atlantoaxial subluxation. The atlas can be fused to the occiput, termed occipitalization, and is associated with a variety of craniovertebral junction anomalies, including basilar impression and invagination.

Dimensions of the spinal canal in the cervical regions are important. As one proceeds caudally the diameter of the canal narrows. At the foramen magnum, the normal diameter is 26 to 40 mm and is acceptable with an average diameter of 34 mm.<sup>1</sup> A diameter less than 19 mm often leads to neurologic deficits. At the C5-C6 cervical level, an anterior-posterior (AP) diameter less than 12 to 13 mm often is coupled with deficits and is indicative of spinal stenosis. The usual sagittal diameter at the C5-C6 level is 15 to 20 mm.

## Cervical disk disease

### *Epidemiology*

Cervical disk disease is usually seen in males between the ages of 30 and 50 who present with a protruded intervertebral disk.<sup>2</sup> However, cervical spondylosis is more common in older adult patients. Degenerative changes in the cervical spine are universal in the elderly age group, and clinical correlation is important.

### *Pathogenesis*

In the patient presenting with cervical disk disease, the disk degeneration leading to referred

pain has several causes that should be explored. In older adults, the aging process and water content change within the disk is one cause for pain. Lifestyle events and posture are other important factors when seeing the patient with pain. Another important factor is autoimmune phenomenon when ruling out causes for pain. Genetic factors and cigarette smoking are also very important.

In cervical spondylosis, there are several changes that can occur. Loss of intervertebral disk height results in cord or nerve root impingement. Osteophytes that form at the posterior zygapophyseal joints, neurocentral joints, and margins of the disk are another important cause of spondylosis in the cervical spine. If the spondylosis is left untreated, segmental instability or a kyphotic deformity may result.

## Associated symptoms and signs

The most commonly herniated disks in the neck are at the C5-C6 and C6-C7 levels.<sup>3</sup> Laterally herniated disks at the C5-C6 level usually compress the C6 nerve root and produce paresthesia and numbness in their distribution. Pain radiating down the lateral side of the arm and forearm, often into the thumb and index fingers, and numbness of the tip of the thumb or on the dorsum of the hand over the first dorsal interosseous muscle are often seen. There is frequently demonstrable weakness of the biceps muscle, and the biceps and radial reflexes may be diminished or absent.

Herniation of an intervertebral disk at the C6-C7 level usually irritates the C7 nerve root and may produce hyperalgesia down the medial aspect of the forearm to the ring and small finger and numbness of small and medial portion of the ring finger. The triceps muscle receives a large portion of its innervation through the C7 nerve root. It is often weak, a finding that is usually demonstrable if the reflex is depressed or absent.

A herniated disk at the C7-T1 level compresses the C8 nerve root and may be responsible for hyperalgesia in the hypothenar portion of the ring and the fifth digits. Sensory changes extend up the forearm to about the junction of the mid-



dle and distal thirds. Hyperalgesia in this distribution is helpful in distinguishing deficits resulting from compression of the C8 nerve root from those resulting from compression of the ulnar nerve at the elbow.

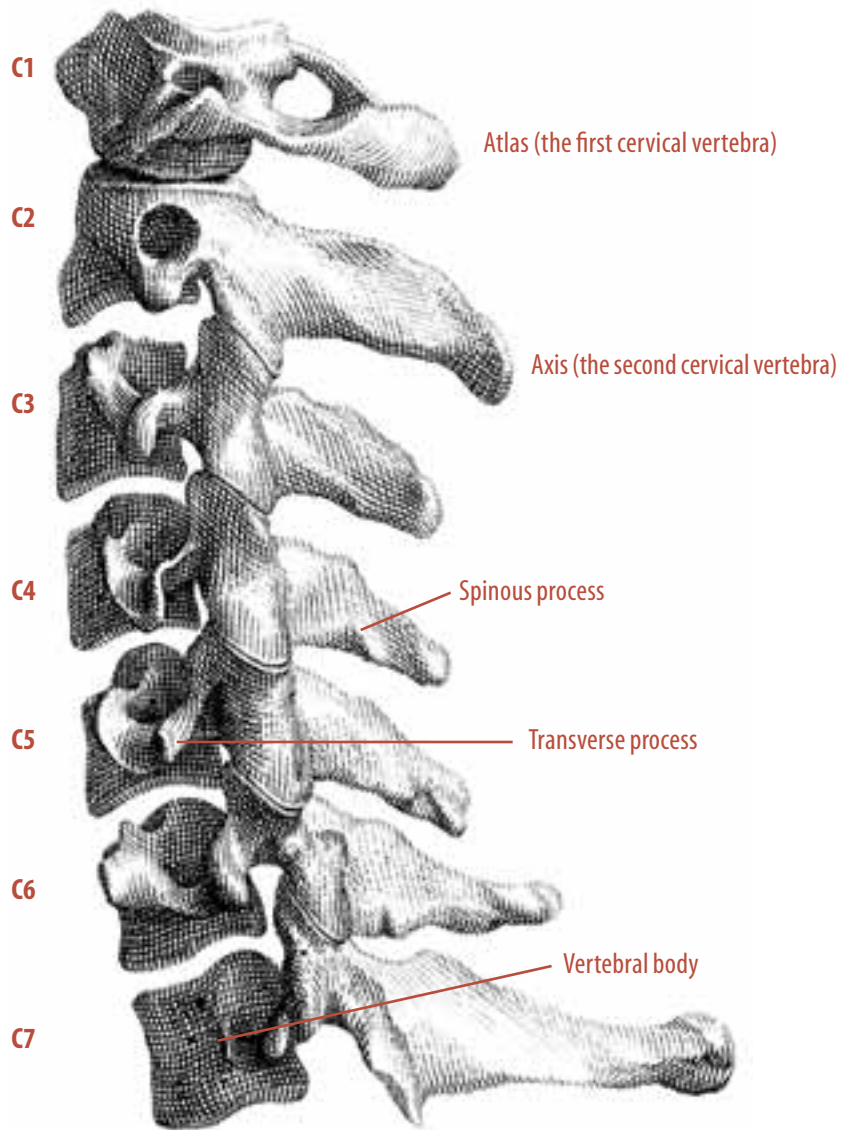
### Historical perspective

The anterior approach to the cervical spine dates back to 1928, when Stuckey attempted to remove a chordoma via an anterior approach.<sup>2</sup> Bailey and Badgley subsequently performed an anterior stabilization technique for the treatment of a lytic tumor involving the fourth and fifth cervical vertebrae. This was followed by Robinson and Smith,<sup>2</sup> who in 1955 described anterior discectomy and fusion with an onlay of iliac crest autograft for cervical spondylosis. This technique was similar to that described by Bailey and Badgley in that there was no direct decompression of the nerve root or spinal cord.

This approach was thought to minimize the risk of neurologic complications from manipulation of the nerve roots or spinal cord, decrease the risk of new osteophyte formation, stimulate osteophytes already present to regress because of the stability provided by the fusion, and reduce buckling of the ligamentum flavum and compression of the nerve root by distraction.

### Rationale of the anterior approach

Although many modifications in the Robinson-Smith graft technique have been developed, the approach to the cervical spine continues to provide easy access to the anterior spine today. Currently, the anterior approach is widely used for cervical spondylotic myelopathy involving three or fewer levels in patients with neutral or kyphotic sagittal alignment.<sup>4</sup> Variations in grafting and instrumentation are numerous, attempting to improve fusion rates, correct deformity, and reduce complications and morbidity at the operative and graft donor sites. These variations have led to the debate over discectomy with interbody fusion versus corpectomy and strut grafting, allograft versus autograft, and the use of supplemental internal fixation, which will be further explained in this article.



### Rationale of interbody fusion and plates

There is a majority in favor of an anterior cervical discectomy and interbody fusion (ACDF) in patients with cervical spondylotic myelopathy or myeloradiculopathy arising from either a soft disk herniation or osteophytes (hard disk) at a single level.<sup>5,6,7</sup> The addition of instrumentation as an adjunct to ACDF is increasingly being considered the treatment of choice for disease involving one to three cervical segments.<sup>6,8,9</sup>

This is partly because the pseudoarthrosis rate has been shown to be inversely related to the number of fused segments and may be due to increased contact stress at the graft-body inter-

**FIGURE 1**  
Anatomy  
of the cervical spine.

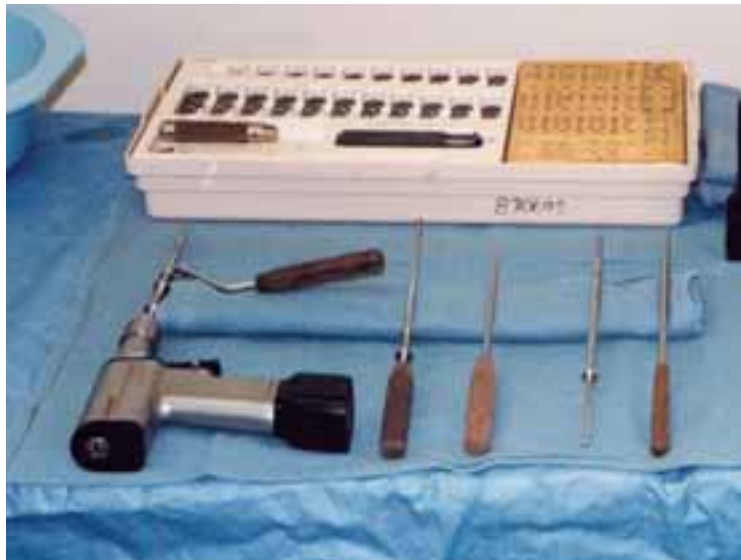**FIGURE 2**

Aesculap  
Caspar  
plating  
system.



**FIGURE 3**

Medtronic  
Sofamor  
Danek  
Orion plat-  
ing system.



face and the increased number of surfaces over which fusion is expected to occur.

### **Anterior corpectomy with strut grafting and instrumentation**

There are several situations in which anterior corpectomy and strut graft arthrodesis may provide a preferable alternative to ACDF. These include (1) single-level spondylotic myelopathy in which compression is occurring principally posterior to the vertebral body; (2) multilevel spondylosis involving three intervertebral levels or two vertebral bodies; (3) single-level or multilevel spondylosis with accompanying cervical stenosis; (4) multilevel spondylosis with kypho-

sis; (5) multilevel spondylosis with segmental instability; and (6) multilevel spondylosis with ossification of the posterior longitudinal ligament. The advantages of corpectomy and strut grafting are to provide more complete decompression, to decrease the risk of nonunion, and to restore a more normal cervical sagittal alignment.<sup>10</sup>

Indications for instrumentation are evolving in the setting of anterior corpectomy and strut grafting. As with ACDF, instrumentation may enhance fusion rates, particularly when three or more levels are involved. In certain instances, anterior plates may obviate the need for a posterior procedure or external immobilization in the early postoperative period. The addition of anterior plates, particularly at the inferior aspect of long strut grafts, may prevent graft extrusion.

The complication rate for anterior corpectomy and strut grafting increases as more corpectomy levels are incorporated into the procedure. The principal complications include pseudoarthrosis, graft displacement, and development of kyphosis. The choice between autograft and allograft balances the high complication rate associated with structural autograft harvest with the increased pseudoarthrosis rate reported with allograft.

### **Anterior cervical instrumentation specifics**

In the past several years, there has been an explosion in terms of the number of available hardware systems and techniques for anterior instrumentation of the cervical spine. Concerns have been raised about complications associated with anterior instrumentation in the cervical spine, including hardware failure and implant disloca-

tion leading to symptomatic dysphagia or esophageal perforation. The overall rate of hardware-associated complications with all types of anterior instrumentation has been estimated at approximately 5%, with some reports as high as 8%.<sup>11</sup> Plate length has been correlated positively with rates of hardware failure; pullout at the inferior end is the typical mode of failure.<sup>12</sup> Of particular concern are reports of increased rather than decreased pseudoarthrosis rates associated with anterior plating following ACDF. Some investigators have hypothesized that anterior plates may function to maintain distraction across disk spaces, preventing graft settling and thereby inhibiting fusion.<sup>13</sup> The debate continues as to which type of cervical plate is best suited for anterior cervical spinal fusion (Figures 2, 3, 4).

### Surgical preparation

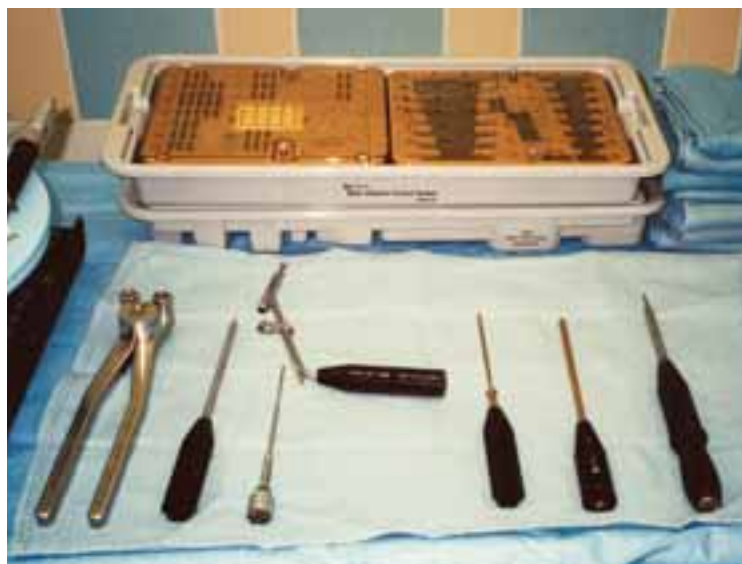The patient is moved to the operating table and administered general anesthesia via an endotracheal tube. Cefazolin antibiotic (1 gram) is administered along with 1 gram of Solumedrol steroid. If severe spinal cord compression is present, 250 cc of 20% Mannitol and 40 mg of Lasix is administered intravenously to decrease the volume of cerebral spinal fluid in the dura.

The patient's arms are padded and tucked at the sides to prevent injury to the ulnar nerves. A small roll or 1000 cc IV solution bag is placed horizontally along the patient's back, bringing into view the anterior border of the sternocleidomastoid muscle. Both shoulders are pulled caudally utilizing 2-inch silk tape and attached to the foot of the table. This maneuver is extremely helpful when trying to radiologically localize the lower cervical spine region, as the shoulders inhibit

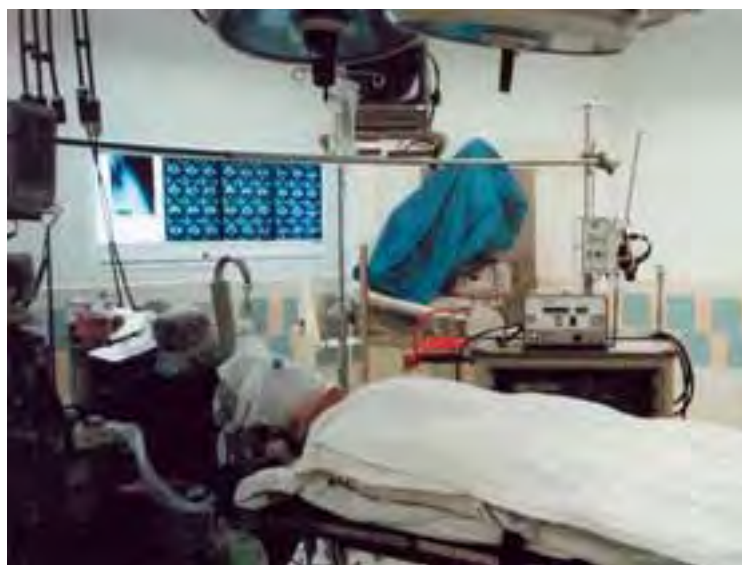the X-ray picture. If an autologous bone graft is to be harvested from the hip, a 10-pound sandbag is placed under the appropriate hip to bring the anterior iliac spine into view. The head is placed in a neutral position along the axial and sagittal planes. Gardner Wells traction tongs are then placed on the patient, and he or she is placed into 15 to 17 pounds of traction (Figure 5).

Fluoroscopic scout films are taken to identify the appropriate level. Once this is accomplished, the skin is scratched with a needle at the affected level. A marking pen is not used because the mark would wash off during the surgical skin prep.

The skin prep consists of mechanically scrubbing the skin for six minutes with a 1:1 mixture



**FIGURE 4**  
Surgical  
Dynamics  
Aline plat-  
ing system.



**FIGURE 5**  
Final  
patient  
position  
for anterior  
cervical  
fusion.



of iodine scrub and iodine solution. After blotting the site with a sterile towel, the circulator changes gloves and proceeds to paint the skin with the solution. If a hip graft will be harvested, the appropriate hip is also prepped in this manner. The draping technique varies from surgeon to surgeon.

### Surgical procedure

#### *Soft tissue dissection (Figures 6,7)*

Prior to making the incision, the scout X-ray films using fluoroscopy are checked again to confirm the correct levels. Using a #20 blade, a transverse anterolateral skin incision is made on

the left side of the neck from the medial border of the sternocleidomastoid muscle to the lateral edge of the trachea. Small surface bleeders are coagulated using a monopolar coagulator. The dissection is carried through the subcutaneous fat using the monopolar electro-surgical pencil. A small Gelpi retractor is then placed in the wound, and the dissection is further carried down until the platysma muscle is encountered. Using Metzenbaum scissors and Pott-Smith forceps with teeth, the platysma is divided parallel to the skin incision.

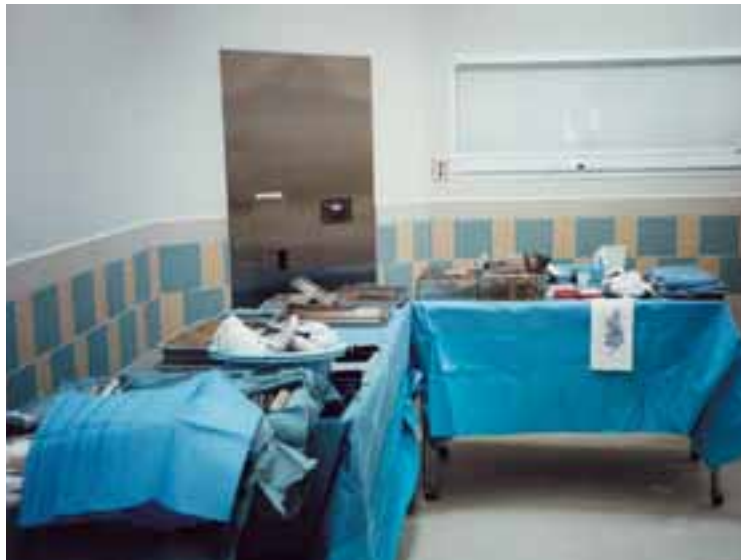Subplatysmal dissection is carried 2 to 3 cm in all directions to gain exposure of multiple levels (Figure 8). Any large venous structures encountered in the dissection are ligated with 2-0 silk ties and divided using the bipolar cautery and Metzenbaum scissors. Pushers mounted on a Beckman (Tonsil) clamp are used to separate the space between the anterior border sternocleidomastoid muscle and the pretracheal fascia and strap muscles. Again, this dissection is carried along the whole area that is to be fused. If the field is obscured by the omohyoid muscle, it can be divided electro-surgically.

The longus colli muscles are the next structures to be encountered. They are separated from the anterior longitudinal ligament and retracted laterally. Once sufficient exposure is achieved, an 18 mm hand-held Cloward retractor is placed in the wound, retracting the esophagus and the trachea medially while the surgeon is utilizing the pushers and suction to retract the carotid sheath laterally.

The underside of the trachea and esophagus are bluntly dissected away from the anterior longitudinal ligament using

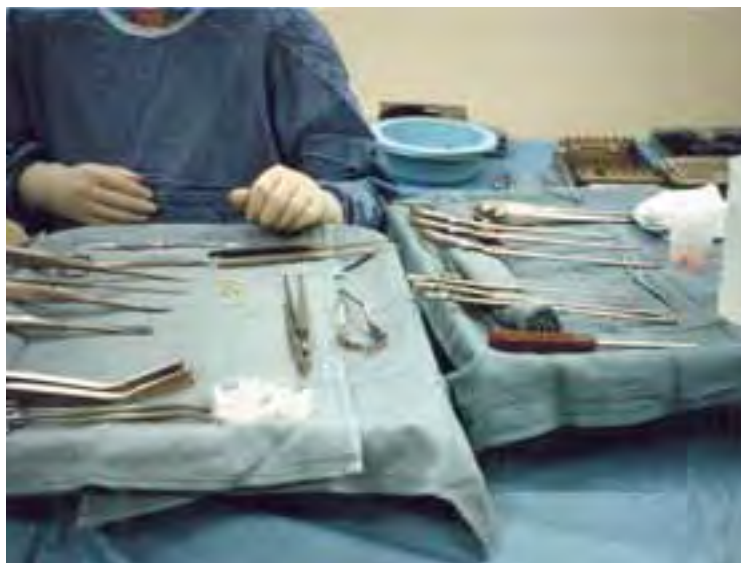**FIGURE 6**

Back  
table  
set-up.



**FIGURE 7**

Mayo  
stands  
set-up.



pushers. Any small venous bleeding points are controlled using bipolar electro-surgery.

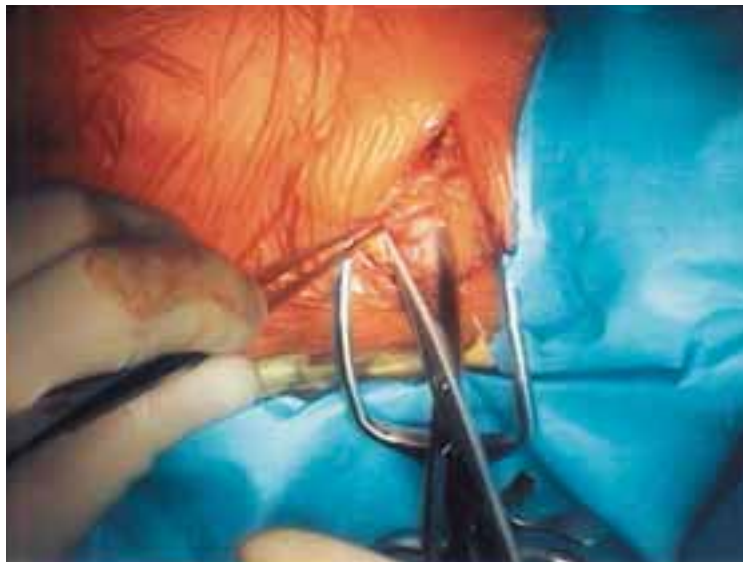
A needle is placed into the affected disk space and another X-ray image is used to confirm the correct levels. Once this is accomplished, a self-retaining retractor is placed into the wound. Many hospitals utilize the BlackBelt® retractor system. This system has a variety of widths and lengths of blades to choose from. This makes the surgeon able to maintain exposure of one level or several levels at once. The retractor is placed into the site in two directions, medially and laterally, and rostrally and caudally. This makes it simple for the surgeon to apply the plate without the aid of hand-held retraction. Extreme care must be taken not to distract the soft tissues too aggressively to avoid esophageal erosion.

#### ***Decompression of the bony elements***

The anterior longitudinal ligament is incised electro-surgically along the affected levels and dissected laterally away from the spine using a periosteal elevator. A vertebral distraction device that consists of 14 mm screws and a ratchet type distracter body is then placed into the vertebral bodies adjacent to the affected levels. This provides ample distraction of the posterior and anterior elements of the spine, thus decompressing the spinal cord and nerve roots.

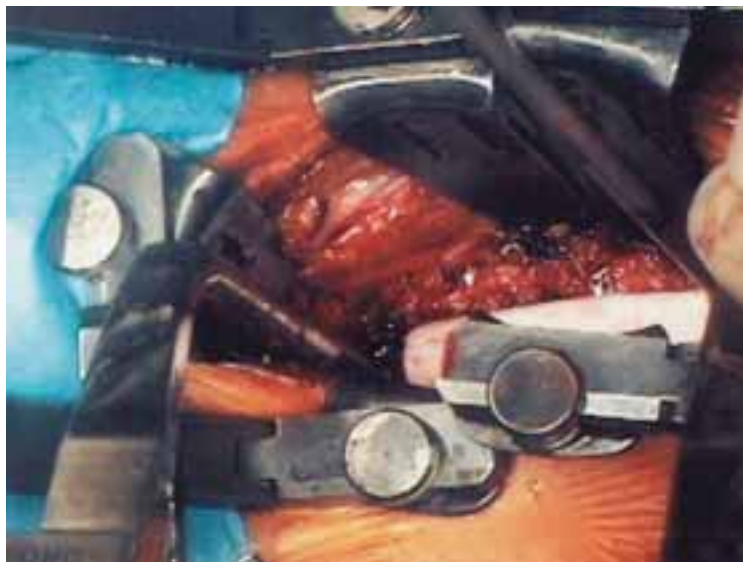
A corpectomy is performed utilizing a high-speed drill with a fairly large (9 mm) cutting burr. Once the major bony decompression of the anterior two-thirds of the vertebral body and disk is complete, the surgeon begins the finer decompression of the spinal cord.

A microscope may be brought into place; however, sufficient illumination and magnification



**FIGURE 8**

Operative photograph of initial dissection of the platysma muscle.



**FIGURE 9**

Operative photograph of a fibular strut implanted in a multi-level corpectomy site.

may be achieved using high-power loupes and a headlight. Using a #11 blade, the posterior longitudinal ligament is incised with attention paid not to damage the underlying dura. Bipolar electro-surgery may be used to stop any small bleeding points that may arise in the layers of the ligament.

A 2 mm Rhoton hook is then passed between the ligament and the dura to create a plane for the Kerrison rongeur to fit. A 2 or 3 mm 40° up-bite Kerrison rongeur is used to remove the ligament overlying the central portion of the dura. A Kerrison rongeur with a thinner foot-plate is advised for this part of the operation. The tighter, more lateral portions of the dura and the foramen are decompressed with a 2 mm Ker-

ri-son. The foramen are inspected closely with a 3 mm blunt nerve hook to ensure that there is no impingement of the nerve root by bony spurs and/or disk fragments. These are removed with Kerrison and pituitary rongeurs respectively.

Once the surgeon is satisfied with the decompression of the spinal cord, a high-speed drill with a 3 mm matchstick-type cutting burr is used to decorticate the rostral and caudal end plates of the adjacent vertebral bodies. Hemostasis of epidural bleeding is achieved with Gelfoam® and topical Thrombin®. The disk space is measured for height and depth using a Caspar caliper or other measuring tool. The wound is soaked in saline containing antibiotics; the self-

site. It must fit snugly enough to provide adequate load bearing to increase bony fusion, as well as be shallow enough not to compress the spinal cord behind the graft. If a fibular strut is used, bone taken from the corpectomy can be placed in the medullary canal of the fibular to provide a matrix for new bony growth to occur in the canal. The bone graft is then placed into the surgical site and tamped into place using a footed bone impactor and a small mallet, while gentle distraction is provided along the longitudinal axis of the neck (Figure 9). Once the surgeon is satisfied with the placement of the graft, the distraction pins are removed and the graft is probed to ensure firm seating and proper position-

ing. The holes created by the distraction pins are plugged with bone wax rolled into the shape of the hole.

#### *Plate preparation*

A cervical plate is chosen and compared to the X-ray to confirm that the superior and inferior screws of the plate will enter the adjacent vertebral body adequately (Figure 10). The plate should extend from near the top of the uppermost vertebral body incorporated in the fusion to near the bottom of the lowermost vertebral body, without

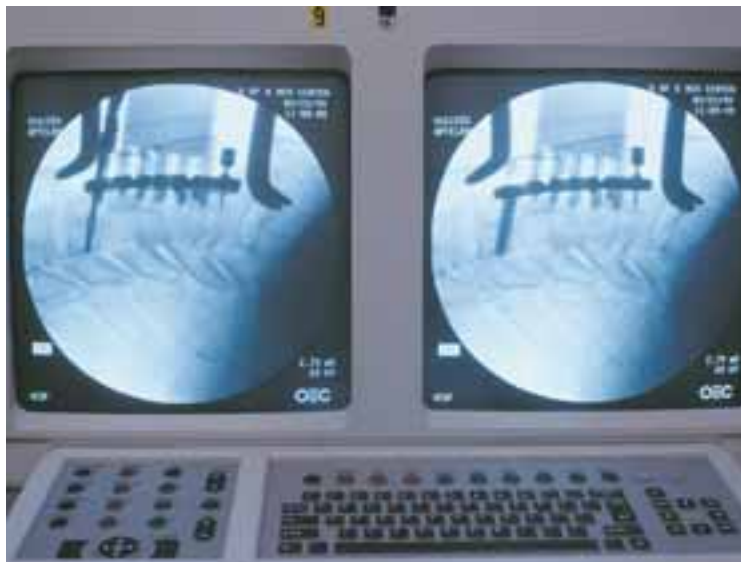
impinging upon the subjacent disk spaces.

Most plates are pre-bent to an optimal angle of cervical lordosis, but they should be further optimized to sit flush on the vertebrae without gaps and to not rock when digital pressure is alternately applied to either end or side-to-side. A bending tool is utilized to increase or decrease the lordotic curvature of the plate by making a series of corrections along the plate. Small sequential corrections should be made to avoid overcorrecting, since repeated bending and unbending can weaken any metallic device and should be avoided.

It may be helpful to mark the midline above and below the plate placement site to assist in

**FIGURE 10**

Photograph of fluoroscopic images showing the screw implantation procedure.



retaining retractor is relaxed, and attention is turned to preparation of the bone graft.

#### *Bone graft preparation*

There are two options of bone graft. Either harvest an autologous graft from the patient's hip or use allograft bone from a cadaver. With respect to pain, it has been reported that the hip graft site is much more painful than the neck site; therefore, the allograft is offered to the patient before the patient's own bone is offered. This has proved to be very reliable. Regardless of which bone graft is used, it must be fashioned to fit into the surgical site. Utilizing saws, drills, or rongeurs, the bone graft is tailored to fit in the fusion



vertical alignment. This can be easily done at the time of initial spine exposure. A temporary fixation pin is then inserted in the plate to ensure that unnecessary movement of the plate does not occur during the placement of the screws.

### **Drilling**

Normally, plate placement and drilling are done under fluoroscopic control to optimize selection of plate length and to optimize screw placement. Cranial and caudal screws are usually angled within the vertebrae, again increasing holding power. Their paths are carefully controlled to avoid entering the adjacent disk space.

By carefully aligning the fluoroscopic images of the facet joints of each vertebrae, the surgeon can be assured that a true lateral image is seen and precisely place bicortical screws by fully drilling the posterior cortex.

### **Tapping**

In the case of bicortical screws, the holes should be tapped after they are drilled. By tapping fully to the posterior cortex, the assurance of firm screw engagement is gained. This must be done under fluoroscopic control, as tactile feedback when tapping is inadequate to determine the depth safely. Again, care must be taken to use true lateral images.

### **Screw Placement**

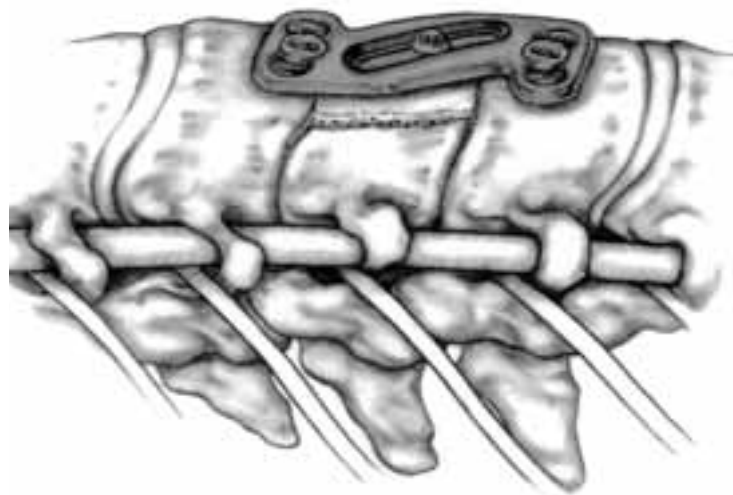
The correct screw length is selected based on the depth information obtained during drilling or by utilizing a depth gauge. The screws are tightened firmly but not to excess (Figure 11). It is recommended that each screw be fully or nearly fully tightened on insertion prior to placing the next screw. This is

repeated for as many screws as the surgeon wishes to place. Final tightening of the screws ensures that the heads are below the surface of the plate.

Many cervical plating systems on the market have a locking screw feature that helps prevent backing out of the screw. If this is the case, the locking screw is then engaged (Figure 12). After completing the bone screw placement at the ends of the plate and at any desired intermediate levels, as well as into any strut grafts, the temporary fixation pins are removed (Figure 13 a, b).

### **Closure**

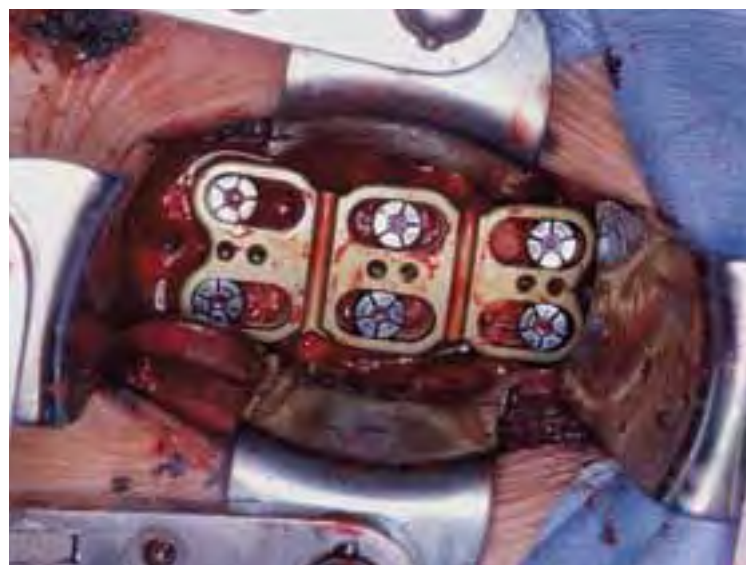The wound is irrigated copiously with saline containing antibiotics, and fine hemostasis is achieved



**FIGURE 11**

Artists representation of the final construct.

Illustration © 2001 Medtronic Sofamor Danek.



**FIGURE 12**

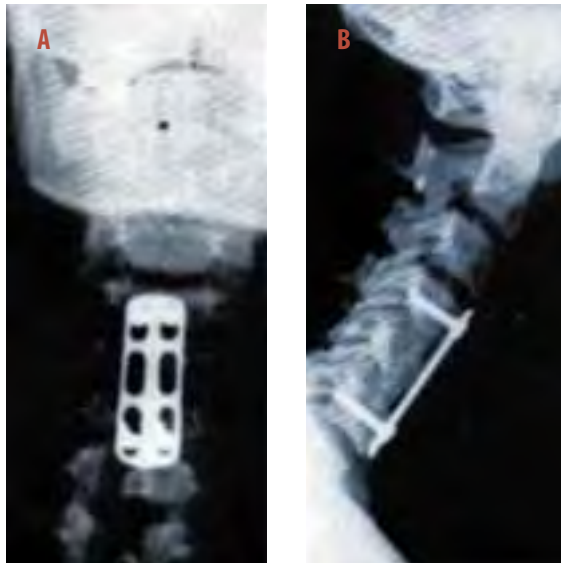
Operative photograph of a completed construct with locking mechanism engaged.

using the bipolar coagulation. After removal of the self-retaining retractor, inspection of the longus colli muscles and other soft tissues is performed. A small drain is placed in the wound, which is usually removed within 24 hours.

The platysma muscle is reapproximated using 0 Vicryl on a CT-2 (J 727D) needle in an interrupted fashion. The subcuticular layer is closed using interrupted 3-0 Vicryl suture on an X-1 (J 790D) needle. Any skin irregularities are corrected with 5-0 Plain Gut on a PS-4 (1632) needle. Mastisol, 0 Steri-Strips, a 1" x 3" Coverlet bandage, and a small Tegaderm bandage are placed on the wound. Betadine ointment on a 4" x 4" gauze sponge is placed around the drain site. The

**FIGURE 13**

AP and lateral radiographs of a multi-level corpectomy, fusion, and stabilization.



patient is moved back on the gurney and a cervical collar is applied. The anesthesia is reversed, and the patient is taken to the recovery room.

### Conclusion

Advances continue in the development and utilization of instrumentation for surgical treatment of cervical spine pathology and fusion. Strong evidence suggests that cervical spine instrumentation increases fusion rates, maintains cervical lordosis, and maintains or restores stability when appropriately employed. Such instrumentation may obviate the need for post-operative rigid external stabilization in many patients.

Clinical outcomes can be optimized and the potential for complications can be minimized, if the surgeon remains abreast of the continuously evolving indications, techniques, and instrumentation for treatment of the degenerative cervical spine.

### About the author

Jeffrey J Cortese, CST, has been a certified surgical technologist for six years. A graduate of Baker College, Mt Clemens Campus, Cortese is employed at Mt Clemens General and St Joseph's Mercy of Macomb Hospital in Clinton Township, Michigan. He is also a student at Oakland University where he is obtaining his bachelor's degree in biology with specialization in anatomy.

### Acknowledgments

I wish to thank my wife, Dawn, for her friendship and support in all of my endeavors. I also wish to thank John L Zinkel, MD, PhD, FACS, Medtronic Sofamor Danek, and Aesculap for their assistance in obtaining the images in this article.

### References

1. Gilman S, Newman SW. Manter and Gatzis *Essentials of Clinical Neuroanatomy and Neurophysiology*. Philadelphia: Davis; 1989:12-70.
2. Robinson RA, Walker AE, Ferlic DC, et al. The results of anterior interbody fusion of the cervical spine. *Journal of Bone and Joint Surgery*. 1962;44A:1569.
3. Frymoyer JW. *The Adult Spine*. New York: Raven; 1991.
4. Emery SE, Fisher JR, Bohlman HH. Three level anterior cervical discectomy and fusion: Radiographic and clinical results. *Spine*. 1997;22:2622-2625.
5. Heckmann JG, Lang C, Cobelein I, et al. Herniated cervical intervertebral discs with radiculopathy: An outcome study of conservatively or surgically treated patients. *Journal of Spinal Disorders*. 1999;12:396-401.
6. Caspar W, Geisler FH, Pitzen T, Johnson TA. Anterior cervical plate stabilization in one- and two-level degenerative disease: Over

- treatment or benefit? *Journal of Spinal Disorders*. 1998;11:1-11.
7. Epstein NE. Anterior cervical discectomy and fusion without plate instrumentation in 178 patients. *Spine*. 2000;13:1-8.
  8. Wang JC, McDonough PW, Endow BS, Delamarter RB. Increased fusion rates with cervical plating for two-level anterior cervical discectomy and fusion. *Spine*. 2000; 25(1):41.
  9. Epstein, NE. The value of anterior cervical plating in preventing vertebral fracture and graft extrusion after multilevel anterior cervical corpectomy with posterior wiring and fusion: indications, results, and complications. *Journal of Spinal Disorders*. 2000;13:9-15.
  10. Saunders RL, Pikus HJ, Ball P. Four-level cervical corpectomy. *Spine*. 1999; 23:2455-2461.
  11. Vanichkachorn JS, Vaccaro AR, Silveri CP, Albert TJ. The anterior junctional plate in the cervical spine. *Spine*. 1998;23:2462-2467.
  12. Paramore CG, Dickman CA, Sonntag VKH. Radiographic and clinical follow-up review of Caspar plates in 49 patients. *Journal of Neurosurgery*. 1989;25:491-502.
  13. Connolly PJ, Esses SI, Kostuik JP. Anterior cervical fusion: Outcome analysis of patients fused with and without anterior cervical plates. *Journal of Spinal Disorders*. 1996;9:202-206.

*Images used courtesy of Medtronic Sofamor Danek and Aesculap.*

## MARKET OUTLOOK Spinal Fixation and Instrumentation

Charlie Whelan

The market for products used in spinal surgery and rehabilitation is one of the fastest growing sectors of the US orthopedics industry, both in terms of revenues and in terms of technological innovation. In 2001, the US market for spinal implants alone was estimated to have accounted for approximately \$1.3 billion in revenues.

The spinal surgery patient base is expanding. Approximately 10 million Americans seek treatment for chronic back pain every year, and 10 percent of those people have surgery. Less invasive technologies, more spinal surgeons, and improved techniques and technologies that improve success rates and allow for greater numbers of patients to qualify for surgery have all lead to growth in the market.

Fixation instrumentation, the rods, screws, plates and other components used to fuse vertebral levels together, is the largest and most lucrative sector within the US spinal market.

The US market for spinal fixation instrumentation was estimated to have generated more than \$951 million in 2001 and is forecasted to grow to more than \$2 billion by 2008. Sales of constructs for use in the lumbar spine compose nearly half of all revenues for the market. The cervical market is growing rapidly, but the thoracic market is growing at a more modest rate.

Pedicle screws, rods and transverse connectors are the most important elements of most modern fixation constructs in the lumbar and thoracic spine, but lami-

nar hooks, plates and wire are also used to varying degrees depending on surgeon preference and the needs of the patient. While pedicle screws are popular, facet screw systems are also being used by some surgeons who desire a less stiff, lower profile construct. Use of laminar hooks is reported to be on the decline as improved designs of pedicle screws replace them. As these more expensive pedicle screws are used, market revenues have risen sharply.

*Charlie Whelan is a consultant for Frost & Sullivan, a San Jose, California-based growth consulting company. This information was excerpted from the report on US Spinal Surgery Markets, Frost & Sullivan, July 16, 2002.*