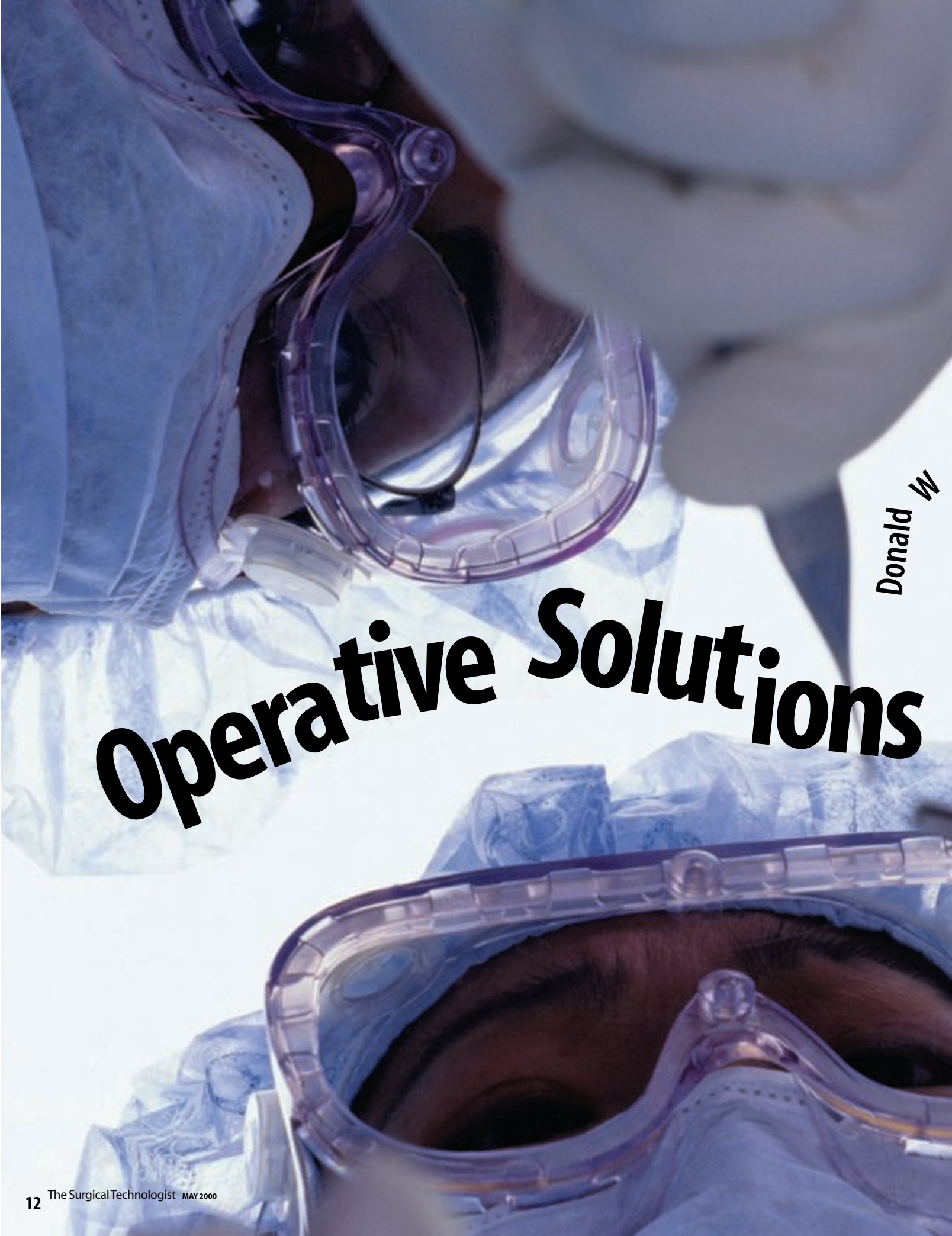



Operative *Solutions*

Donald W

Patrick, MD, and Ronald E Manicom, MD

For spinal surgery to be successful, the operating room professional must understand the indications for spinal surgery, the precise surgical approach, and the expected results. The surgical team must not only have a working knowledge of the anatomic structures being manipulated, but also the normal and pathologic physiology of these nervous, ligamentous, bony, and vascular tissues. From the preoperative administration of antibiotics to draping, to retracting and closing, the assistant has both a technical and a cognitive role in spinal surgery. Surgical assistants who have command of technical skill requisites, the rationale behind low back fusions, and the related information, will be uniquely situated in the spinal surgery environment.

to Axial Lumbar Pain

This article gives a brief overview of the history of spinal surgeons and discusses some of the cognitive skills required by those who perform spinal surgery for axial lumbar pain. This includes anatomy of the spine and its contents, pathophysiology of spinal pain, decision-making options and a step-by-step exposition of a surgical approach to posterior lumbar interbody fusion and posterior stabilization for axial lumbar pain.

Who are spinal surgeons?

For decades, neurosurgeons and orthopedists grudgingly shared surgical treatment of spinal conditions. Generally, neurosurgeons focused on nerve-root compression relieved by discectomy and laminectomy, and the orthopedists preferred fusions. Orthopedists performed surgery on lumbar spine problems and neurosurgeons operated on lumbar and cervical problems. Today, each of the two specialties has developed their own subspecialty of spinal surgery. Spinal neurosurgeons have learned lumbar fusion principles from orthopedists, and spinal orthopedists have added microsurgery and some cervical spine approaches to their repertoires. However, the first champion of lumbar interbody fusion was Ralph Cloward,¹ a neurosurgeon.

There are still considerable differences between the technical focus and training of the neurosurgeon and that of the orthopedist. The neurosurgeon is trained in meticulous hemostasis and handling of delicate neural structures, principles that are emphasized less in the orthopedic curriculum. The orthopedist is vitally concerned with spinal stability and configuration, issues that are appreciated only by neurosurgeons who subspecialize in spinal ailments.

Despite their disparate backgrounds, the subspecialties of spinal surgery in both orthopedics and neurosurgery have created an exponential increase in surgical brainpower. The clearest evidence of this is the booming trade in the application of technical advances to the solution of spinal dilemmas.

Spinal anatomy and physiology

The vertebral column is comprised of individual units of bone called vertebrae, which are made of an outer layer of cortical bone and an inner matrix of cancellous bone. This inner matrix is the site of the intracellular processes that produce the combination of cancellous and cortical bone to provide support and strength for the spine.

Each of the individual vertebral bodies continues with the paired pedicles, which connect to the transverse processes and inferior and superior articular processes. These processes blend into the lamina and the spinous process (Figure 1).

Only ligaments and cartilage connect all five lumbar vertebrae to one another. If one of these connections is damaged by repetitive trauma, inflammation, or the aging process, the spine becomes unstable to varying degrees. Figures 1 and 2 show the anterior longitudinal ligament, the posterior longitudinal ligament, the supraspinous ligament, the interspinous ligament, the ligamentum flavum, and the periarticular ligament. The anterior and posterior longitudinal ligaments secure the bodies of the vertebra in consonance with the disc. The periarticular ligament holds the facet joints in place, while the ligamentum flavum connects the laminae. The interspinous and supraspinous ligaments pass between the spinous processes. The facet joints are lined by glistening synovial membranes similar to those in the knuckle joints of the hand.

Secondarily, paraspinous muscles attach to the periosteum of the vertebrae and help stability, but their primary mission is movement of the spine.

An intervertebral disc sits between the bodies of each lumbar vertebra and between L5 and the sacrum (Figure 3). The disc is made of the annulus fibrosus, a tough outer fibrous envelope comprised of fibrocartilage that intimately attaches to the cortical bone of the vertebra. Inside the fibrocartilage is a mass of hyaline cartilage with the consistency of crabmeat, called the nucleus pulposus.

Columns

The spine is comprised of three columns; each must be competent for spinal stability. Figure 4 displays the bony elements of the three columns. The vertebral body–disc–ligament construction is considered the anterior column. The pedicles, facet joints and corresponding ligamentous investments compose the lateral columns on both sides. And the laminae and spinous processes with their ligamentous components complete the posterior column.

Therefore, spinal instability involves a combination of abnormalities in two or more of the columns. For example, when forward slippage of a vertebra occurs, a condition called spondylolisthesis, it must involve all three columns to varying degrees. One vertebra cannot slip forward if the annular fibers are not stretched, the articular ligaments are not degenerated allowing facet dislocation, and the posterior ligaments are not deprived of normal tension.

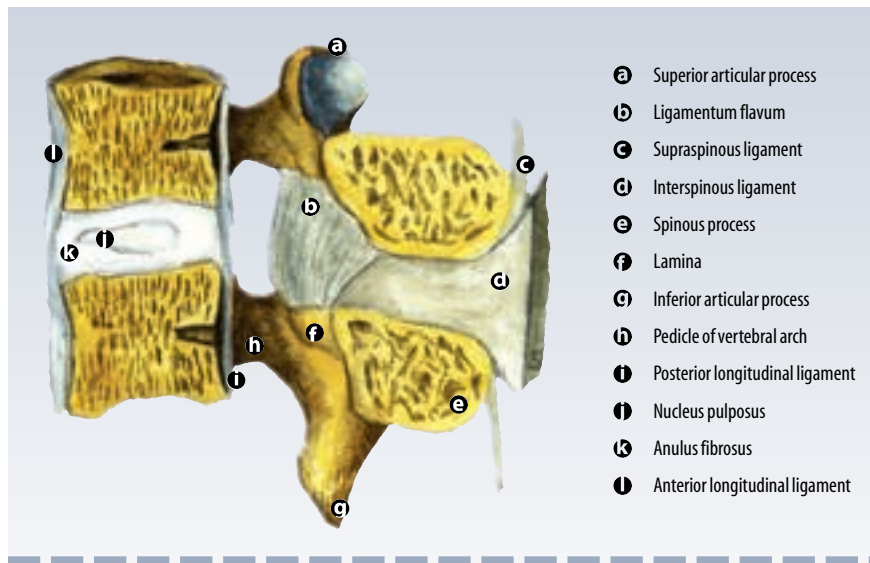
However, spinal instability producing back pain can occur without forward or backward slippage of one vertebra on the other. The back depends on the integrity of all its structural columns to produce a symphony of comfortable movement and vertical stability. Degenerative changes that affect this conformation appear in many forms, which singly or in combination will result in back and leg pain or back pain alone. Figure 5 shows the narrowing effect of degenerative changes on the disc and hypertrophy and spurring of the facet joints secondary to wear and tear or inflammatory changes in the joints' synovial membranes.

Anatomy of the cauda equina

The central and peripheral nervous system can be simplified into two divisions: motor power travels downward and sensation impulses travel upward. Muscle power in the legs is supplied by a pathway of motor impulses that originates in the cerebrum, passes downward through the brain stem and spinal cord and synapses with anterior horn cells (the cell bodies for motor nerve roots).

At L1-2, the nerves seem to explode out of the tapering terminal spinal cord, called the conus medullaris, into a bundle of fibers contained in the dural sac. At each vertebral level, fibers of neural tissue, or nerve roots, exit. The motor components of these nerve roots organize themselves into peripheral nerves, which supply specific muscle groups. For example, the femoral nerve, which receives its impulses from the L 2, 3, and 4 nerve roots, supplies motor control of the quadriceps muscle.

The spinal cord also contains the sensory components of the neural supply to the lower extremities and perineum. These, however, travel upward from the peripheral nerves through



nerve roots, spinal cord, brain stem, then to the cerebrum and cerebellum. Touch, pain, temperature, pressure, joint position, muscular tension, and sexual sensations are relayed to the brain by a variety of sensors through a complicated array of spinal cord tracts. In the brain, receptors relay these sensations to the cerebrum. Each peripheral nerve and nerve root have well-recognized areas of sensory reception. For example, sensations of touch, temperature, pain, pressure, and joint position in the big toe are relayed through the superficial peroneal nerve to the sciatic nerve, then the L5 nerve root to the spinal cord and through several complex pathways to the cerebrum. Similar pathways inform the cerebel-

FIGURE 1

A sagittal section of the vertebral column showing the midline structures.

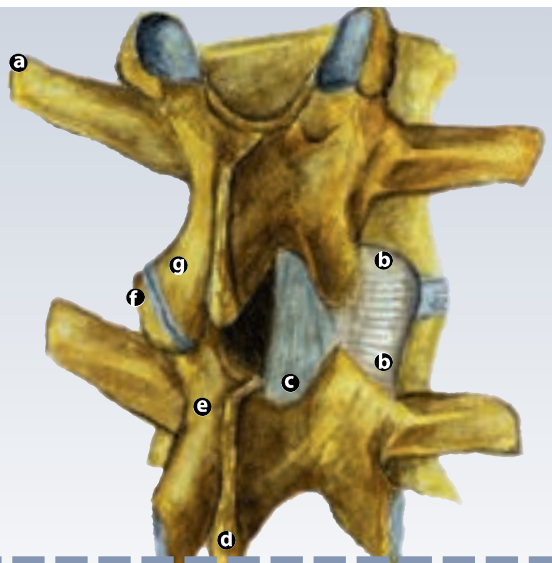
FIGURE 2

A right posterior oblique view of a section of the vertebral column.

lum of muscular tension, tendon position, and joint location so that it can coordinate motor commands issued by the cerebrum.

Relationship of nerve roots to discs and pedicles

At each lumbar level, a surgeon deals with two nerve roots bilaterally. In performing posterior interbody fusions, the surgeon and assistant must be aware that two nerves, called the exiting nerve and the crossing nerve, are present on both sides from cephalad to caudad. This configuration is most troublesome in the performance of posterior lumbar interbody fusions (PLIF). Since most PLIFs are done bilaterally, this situation causes the surgeon and the assistant to be



- a Transverse process
- b Articular capsule
- c Ligamentum flavum
- d Spinous process
- e Lamina of vertebral arch
- f Superior articular process
- g Inferior articular process

vigilant in finding and protecting all four nerves on a one-level fusion procedure.

Figure 6 shows how the inferior medial quadrant of the pedicle is especially sensitive to minor misplacements of pedicle screws. The nerve root, as it winds around the pedicle, is in intimate contact with the infero-medial pedicle wall. A screw that penetrates the wall of the pedicle in that area is in danger of entrapping and tearing the lining of the nerve and perhaps tearing the nerve fibers themselves.

Pathophysiology of axial low back pain

Any condition that stretches or tears the spinal ligamentous or annular structures,² deforms

TABLE 1 The causes of axial low back pain

1. Degenerative (Spondylosis)

- a. Disc
 - i. Central herniation
 - ii. Traction spurs
 - iii. Annular tears
 - iv. Internal disruption
 - v. Previous discectomy for herniation
- b. Facet

2. Inflammatory (Spondylitis)

- a. Various Arthritides (rheumatoid, osteo, lupus, etc.)
- b. Idiopathic

3. Vertebral slippage

- a. Spondylolisthesis
 - i. Without spondylolysis
 - ii. With spondylolysis
 - iii. Postoperative posterior decompression
- b. Retrolisthesis
 - i. Facet and disc degeneration
 - ii. Postoperative posterior decompression
 - iii. Postoperative discectomy
- c. Lateral translation
 - i. Facet and disc degeneration
 - ii. Postoperative posterior decompression

4. Others

and inflames the facet joint surfaces, or causes instability of one or more vertebrae in relation to one another can cause lumbar pain. Well-designed and executed decompressive procedures for spinal stenosis (laminotomy or laminectomy) can produce instability and lumbar pain by removing or altering the posterior column of the spine. Equally well-designed and executed discectomies alter the anterior support column of the spine and can produce chronic back pain. Many surgeons think that a disc that appears dark on the MRI, thus dehydrated and degenerated, can be the source of minor instability that creates back pain. One of the enigmas in this complex subject is that

many back-pain sufferers have no focal radiographically demonstrable cause for their problem.

Many individuals with back pain also have secondary gain issues and pending litigation. These issues can cloud the clinical picture.³

Discussion

Table 1 contains a thorough, but not exhaustive list of causes of axial lumbar pain. The terms spondylitis, spondylosis, spondylolisthesis, and spondylolysis require some explanation. The root word “spondylo” means “spine,” so, spondylitis means inflammation of the spine, such as rheumatoid spondylitis. Spondylosis is a non-specific term meaning “an ailment of the spine,” but it is commonly used to mean “degenerative ailment of the spine.” Spondylolisthesis is forward slippage of one vertebra on the other. Spondylolysis is a precise term referring to an actual fracture line in the bone, called the pars interarticularis, that connects the superior and inferior facets.

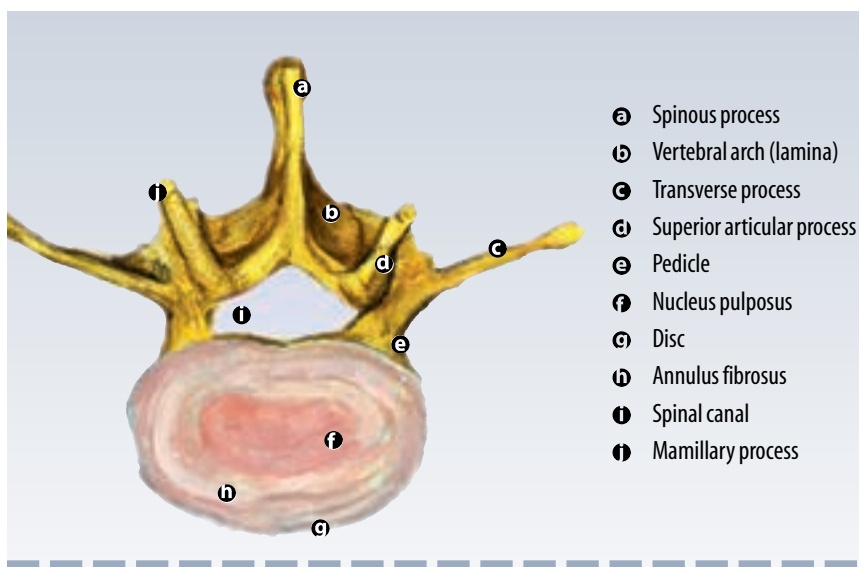
Unfortunately, some patients who endure disc or decompressive operations eventually need fusions. This realization among neurosurgical spinal specialists has given impetus to their drive to become competent in the performance of lumbar stabilizing procedures. However, most disc and decompressive operations successfully solve the patient’s complaints of pain and neurologic deficit without the necessity of a fusion.

Surgical treatment for axial low back pain

Principles of definitive management of axial low-back pain by invasive techniques are fairly well defined. If the problem is part of a general inflammatory process, such as rheumatoid arthritis, medical management is a more logical regimen than surgery. If focal abnormalities of the lumbar spine produce disc pathology, vertebral slippage, or facet joint deterioration, surgical treatment may be appropriate. Such treatment is almost exclusively aimed at immobilizing the painful vertebral unit with a bony fusion.

There are three exceptions to the rule of fusion for invasive treatment of the spine: extradural steroid injections, facet joint denervations and intradiscal electrothermal therapy (IDET). My experience with facet joint denervations and extradural steroid injections has been disappointing. Unfortunately, even if early results are favorable, most patients relapse into a painful state that resembles the pre-injection and predenervation status. Naturally, if any spinal pathology is present, other than that of the facet, the denervation per se will be unsuccessful.

IDET is a new technique for transcutaneous heating of the annulus being investigated by a variety of clinicians.



Discussion

Table 2 describes low-back fusion techniques. Most technical advances in the development of fusion devices have common elements³ including: 1. restoration of interbody height; 2. alignment in anatomic position as feasible; and 3. fusion of the weight-bearing anterior column. It is not necessary to go through the abdomen and do an ALIF to perform an anterior column fusion; a PLIF also fuses the anterior spinal column.

In addition to the three elements that must be satisfied to ensure success in the surgical management of axial back pain, many specialists think there should be posterior instrumentation creating stabilization as well. The FDA approval for

FIGURE 3

A vertebral disc shown in the horizontal section.

FIGURE 4

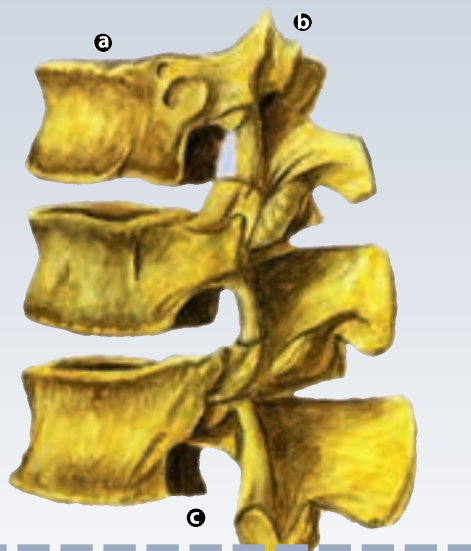Bony
elements of
the three
spinal
columns.

cuboidal carbon fiber cage construction designed by Brantigan includes the concomitant use of pedicle screws and rods or plates.³

The disagreement between specialists is not whether to do interbody fusions for axial back pain, but how it should be done.

Cages versus spacers

Almost all of these manufactured interbody devices are used in pairs—parallel to one another and on either side of the midline. These products can be divided into two large groups: cages and spacers. Cages are further divided into cylinders—some are screwed into position with the circular dimension facing anterior-posterior and



- Ⓐ Anterior column
- Ⓑ Posterior column
- Ⓒ Lateral column

some are inserted with the circular dimension of the cylinder placed in a superior-inferior orientation. These can be manufactured from titanium, stainless steel, or cadaver bone. Cages can be cuboidal: rectangular or square in their footprints in the spinal canal. One manufacturer employs carbon fiber. Spacers are, at present, made from cadaver bone and are primarily cuboidal.

Cages differ from spacers because they are hollow, with cancellous bone packed in the openings to provide the primary venue for the growth of interbody fusion. Spacers are solid and can provide eventual fusion, but their primary fusion medium is through the packed cancellous bone between and lateral to the spacers.

Anterior versus posterior

The surgeon chooses the anterior versus the posterior approach to lumbar interbody fusion on the basis of what conditions are most often treated. If surgeons mainly treat patients with posterior pathology—disc herniation, spinal stenosis, synovial cyst, and other causes of nerve root compression, their preferred approach is from the back. If they add posterior stabilization with screws and rods, the pedicles are already exposed.

Anterior lumbar interbody fusion (ALIF), useful when restoring the height of the disc space, can control compression of nerves in the spinal canal or foramina. If added stability is needed, however, combining a posterior pedicle screw fixation with ALIF is an additional and extensive procedure.

Anterior-approach surgeons depend on another surgeon, the vascular specialist, to expose the pathology without damaging adjacent structures. Intra-abdominal technical errors are horrendous, as are errors that affect the dura and the nerve roots that are exposed with the posterior method. However, medical reports detail dural and nerve root injuries from ALIFs as well.⁴ In situations where either an anterior or posterior approach will suffice, spinal surgeons must choose the technique with which they are the most comfortable.

BAKs™ and cylindrical screw-type allograft are frequently used for ALIFs⁵. Both allow minimal contact between the bone in the cages and the vertebral bodies, resulting in a high percentage of patients for whom bony fusion cannot be demonstrated postoperatively. Many of these cages seem to work well even in the absence of any objective evidence of fusion between the adjacent vertebra.⁶ The future will determine whether internal stabilization with cylindrical cages, without fusion and without pedicle screws and rods, is a life-long solution to axial back pain.

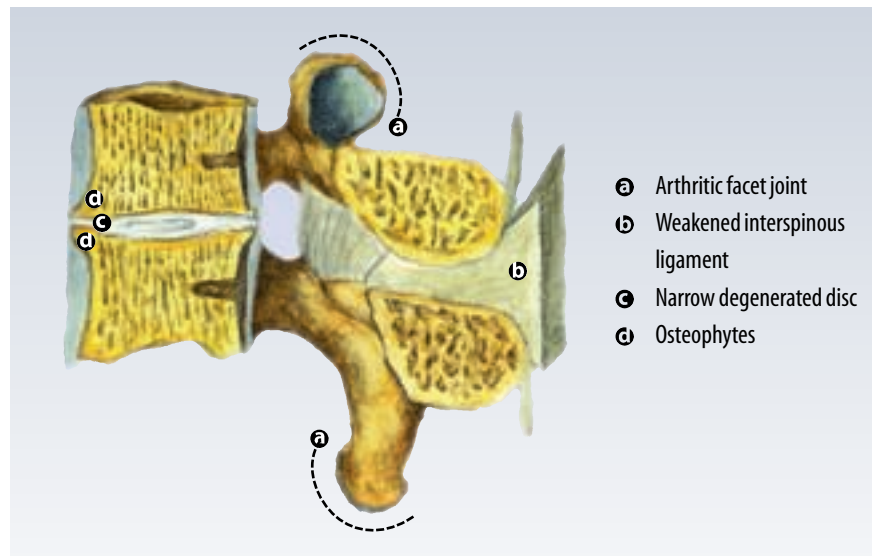
Most neurosurgeons are more comfortable working in the spinal canal and prefer the posterior technique. In patients who experience only axial back pain without spinal canal abnormalities, the laparoscopic ALIF approach is possible,⁷

TABLE 2 **Low back fusions**

1. **Anterior Lumbar Interbody Fusion (ALIF)**
 - a. Cages, retroperitoneal approach
 - i. Metal cylindrical screw-type
 - ii. Bony cylindrical allograft screw-type
 - iii. Bony allograft and metal, other
 - b. Cages, laparoscopic, metallic cylindrical screw type only
2. **Postero-lateral fusion**
3. **Posterior Lumbar Interbody Fusion (PLIF)**
 - a. Metallic cylindrical screw type cage
 - b. Bone cylindrical allograft screw type cage
 - c. Carbon fiber cuboidal cage
 - d. Metal cage, other
 - e. Bone spacers
4. **Posterior stabilization (Pedicle screws and rods/plates)**
 - a. Performed only in consonance with procedures 1, 2, or 3—never alone
 - b. When done with ALIF requires two operations, anterior and posterior
 - c. When done with PLIF requires only addition of hardware to standard posterior exposure
 - d. Posterior lateral fusion without hardware phasing out

square or rectangular design requires less nerve root retraction than the circular footprint cylindrical cages with the same relative height. The cuboidal cage can be inserted with less incursion into the vertebral body than the screw-type cage, saving more vertebral-body strength. This is important because vertebral-body collapses are much more common than device failures, leading doctors to prefer to remove less of the bony endplate when placing the cage. This fact favors the use of cuboidal cages and bone spacers.

We also favor posterior instrumentation, because studies have shown that there is motion instability, especially on axial rotation and extension in experiments using in vitro interbody



especially if the percentages of actual bony fusions were to be optimized.

PLIFs

Our approach has been to use the carbon fiber cuboidal cages for the interbody fusion and stabilize posteriorly using pedicle screws and rods. We prefer the posterior approach to that of the anterior, because most of our patients have leg pain and posterior pathology in addition to axial back pain. The posterior approach demands the smallest practical footprint of the intraspinally placed device to minimize nerve stretch, while having the vertical height to maximize annular tension on the interspace ligaments.⁸ The cuboidal cage's

constructs.⁹ The pedicle screw-plate/rod construction inhibits those instabilities.¹⁰

Care and skill in use of sterile technique, hemostasis, nerve protection, screw insertion, graft preparation, and other mandatory spinal surgical techniques are necessary for successful interbody fusions. Some keys to posterior interbody cage/spacer insertion merit special mention are shown on page 21.

Summary

In this day of rapid transformation of technical options for surgical management of axial back pain, one cannot predict what device or technique will ultimately prevail as the gold stan-

FIGURE 5
Degenerative changes on the disc and hypertrophy and spurring of the facet joints

FIGURE 6

A coronal section showing a posterior lumbar interbody fusion with the posterior elements cut away.

dard. Even the least invasive of all the present operative procedures is daunting to the patient, if not the surgeon. Perhaps a simple transcutaneous maneuver will be found that will solve the problem, though that possibility is quite unlikely in light of our present knowledge.

In the meantime, spinal surgeons will need skillful assistants who will apply themselves, not only to the technical side of the procedure, but to the cognitive aspect as well.

Considerations for the surgical first assistant

1 Preoperative considerations

Determine the location of the patient's pain and operative site by conferring with the

About the Authors

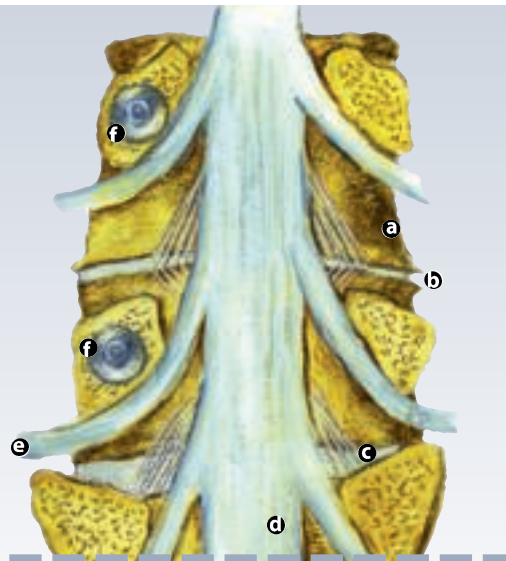
Ronald Manicom, MD, and Donald Patrick, MD, are in practice together at Round Rock Spinal Neurosurgery, located north of Austin, Texas, in the burgeoning computer industry corridor. They are both diplomates of the American Board of Neurological Surgery and have been friends for more than 40 years. They finished the Baylor College of Medicine Neurosurgery Residency Program together and served in Vietnam at the same time.

Donald Patrick, MD, will be speaking at the 31st Annual AST Conference on Saturday, May 27th. His presentation is titled "Posterior Lumbar Interbody Fusion."

References

- 1 Cloward RB. The treatment of ruptured lumbar intervertebral discs by vertebral body fusion. I. Indications, operative technique, after care. *J Neurosurg.* 1953;10:154-166.
- 2 Haughton VM, et al. Flexibility of lumbar spinal motion segments correlated to type of tears in the annulus fibrosus. *J Neurosurg.* 2000;92, Number 1:81-86
- 3 Agazzi S, et al. Posterior lumbar interbody fusion with cages: an independent review of 71 cases. *J Neurosurg.* 1999;91, Number 2: 188-189, 192.
- 4 Samadrala S, et al. Complications during anterior surgery of the lumbar spine: an anatomically based study and review. *Neurosurg Focus* 1999;7(6).
- 5 Nibu K, et al. Multidirectional stabilizing potential of BAK interbody spinal fusion system for anterior surgery. *J Spinal Disord.* 1997;10:357-362.
- 6 Ray, CD. Threaded titanium cages for lumbar intervertebral fusions. *Spine* 1997;22:667-80.
- 7 McLaughlin MR, et al. Laparoscopic ALIF. *Neurosurg Focus.* 1999;7(6).
- 8 Brantigan JW, et al. A carbon fiber implant to aid interbody lumbar fusion. Two-year clinical results in the first 26 patients. *Spine* 1993;18:2106-2107.
- 9 Kettler A, et al. Stabilizing effect of posterior lumbar interbody fusion cages before and after cyclic loading. *J Neurosurg.* 2000;92, Number 1:87-92.
- 10 Vaccaro AR. Internal fixation (pedicle screw fixation) for fusion of the lumbar spine. *Spine* 1995;20: 1575-1655.
- 11 Branch C Jr. Personal Communication. December 1999.
- 12 Sandhu HS. ALIF with osteoinductive growth factors. *Clin Orthop* 2000;371:56-60.

- Ⓐ PLL
- Ⓑ Narrow degenerated disc with spurring
- Ⓒ Normal disc
- Ⓓ Dura
- Ⓔ Nerve root winds around medial-inferior aspect of pedicle
- Ⓕ Cutaway of pedicle screws and pedicles



patient and physician and by looking at the chart and radiographs.

2 Operative preparation

Positioning devices (Andrews, Jackson, Wilson frames) and padding available, microscope draped, prophylactic antibiotics

3 Anatomical visualization

Dura, nerves (crossing and exiting), anterior annulus, pedicle, bleeding vessels

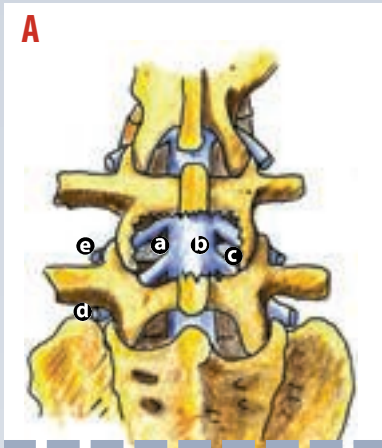
4 Instrumentation

Correct size screws and rods (verify placement radiographically)

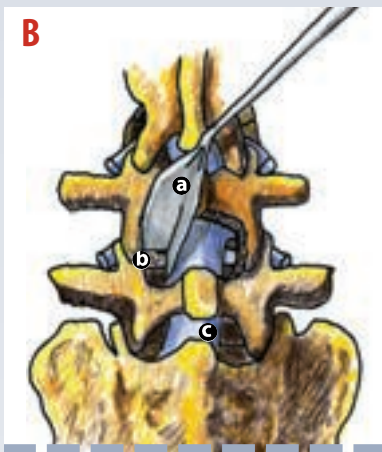
5 Post procedural

Closure, dressing, transfer, postop orders (H&H)

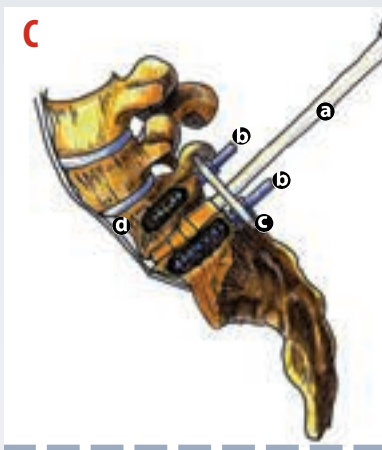
Medical illustrations rendered by Woody Patrick and Ryan Day.



a Discectomy d Crossing nerve root
 b Dura e Exiting nerve root
 c Intact disc



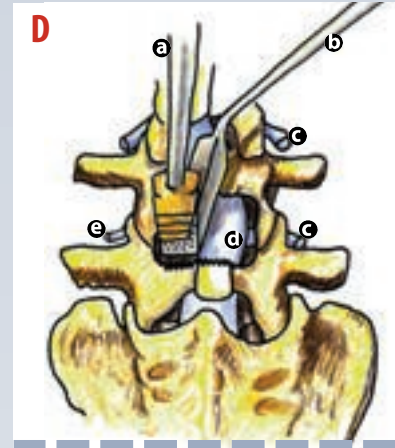
a Retractor c Dura
 b Disc space



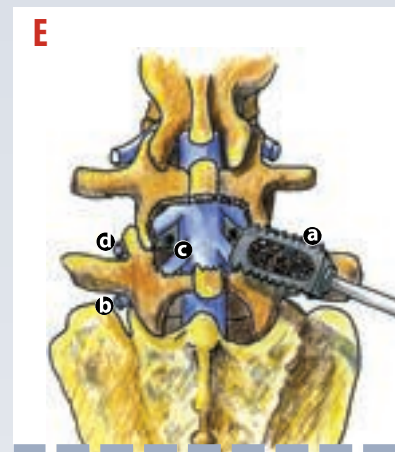
a Trial spacer c Plate
 b Pedicle screws d Spondylolisthesis

Cage/spacer insertion

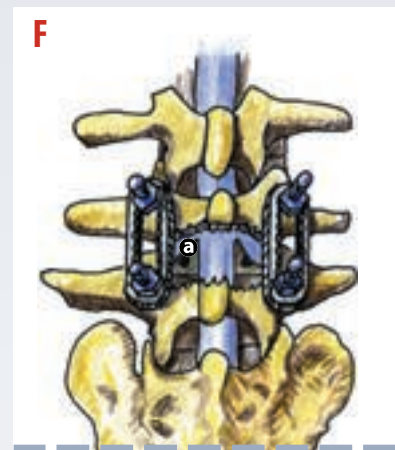
- 1 Patient selection—pay special attention to objective studies in individuals with secondary gain, drug habituation, exaggeration of physical limitations, and those who speak in hyperbole.
- 2 Avoid nerve-root stretch by an aggressive laminectomy and medial facetectomy (Figure A). If the patient has a narrow interpedicular distance, a complete facetectomy may be necessary to provide enough space to insert cages without stretching the exiting and crossing nerves.¹¹
- 3 Place screws after the laminectomy to visually evaluate pedicle integrity after passage of the gearshift pedicle locator, the tap, and the screw. Place the plates/rods and tighten the construction before preparing the interspace for cage insertion to ensure the interspace is at the correct height.
- 4 Use the thinnest nerve retractors available. Make sure the surgeon and assistant can both see that the exiting and crossing nerves and the dural sac are retracted beyond the reach of cutting or crushing tools. Figures B and D show a commercial one-piece design. Consider two Love type retractors to control pressure individually on the exiting and crossing nerve roots and dura.
- 5 Use a cage with adequate height. Place increasingly higher trial spacers until proper resistance of the annulus/ligaments is felt. Figure C shows a type of trial spacer application with pedicle screws in place, but the plate not locked into position.
- 6 Use autograft from the laminectomy or iliac crest through a trap-door incision. Studies suggest that commercially available, recombinant bone morphogenic protein (BM-2) graft extenders, which are added to the patient's cancellous bone, improves the rate of fusion.¹² Figure E shows the left cage in place and the right cage packed with bone and BMP prior to insertion. Note the relatively small space between neural structures.
- 7 Use a cell saver and have autologous blood drawn from patient a week or so before surgery.
- 8 At the conclusion of the interspace fusion, compressing the disc space with the pedicle screw-rod construct decreases chances of dislodgement and places cancellous graft in the closest possible proximity to vertebral endplates. Figure F depicts a typical appearance of the final construction as seen on a practice model.



a Broach d Dura
 b Retractor e Exiting nerve root
 c Nerve roots



a Carbon fiber cage c Cage in place
 b Crossing nerve d Exiting nerve



a Cage

Operative Solutions to Axial Lumbar Pain

Earn CE credit at home

You will be awarded one continuing education (CE) credit for recertification after reading the designated article and completing the exam with a score of 70% or better.

If you are a current AST member and are certified, credit earned through completion of the CE exam will automatically be recorded in your file—you do not have to submit a CE reporting form. A printout of all the CE credits you have earned, including Journal CE credits, will be mailed to you in the first quarter following the end of the calendar year. You may check the status of your CE record with AST at any time.

If you are not an AST member or not certified, you will be notified by mail when *Journal* credits are submitted, but your credits will not be recorded in AST's files.

Detach or photocopy the answer block, include your check or money order made payable to AST and send it to the Accounting Department, AST, 6 West Dry Creek Circle, Suite 200, Littleton, CO 80120-8031.

Members: \$6 per CE, nonmembers: \$10 per CE

- 1 The _____ ligaments hold the facet joints in place.
 - a supraspinous
 - b periarticular
 - c posterior longitudinal
 - d interspinous
- 2 Intervertebral disks are made of _____ that attaches to the cortical bone of the vertebra.
 - a fibrocartilage
 - b hyaline cartilage
 - c nucleus pulposus
 - d periosteum
- 3 Which elements comprise the anterior spinal column?
 - a pedicles, facet joints and ligamentous investments
 - b laminae and spinous processes
 - c ligamentous investments and their components
 - d vertebral body, disk, ligament construct
- 4 The _____ pose a problem for posterior lumbar interbody fusions.
 - a femoral nerves
 - b exiting and crossing nerves
 - c L2,3, and 4 nerve roots
 - d conus medullaris
- 5 Which is not a degenerative cause of axial low-back pain?
 - a traction spurs
 - b annular tears
 - c spondylolisthesis
 - d lateral disc herniation
- 6 Spondylolysis means _____.
 - a inflammation of the spine
 - b forward slippage of one vertebra on another
 - c an actual fracture line in the bone
 - d an ailment of the spine
- 7 Carbon fiber cuboidal cages and bone spacers are both typical of _____ low-back fusion.
 - a postero-lateral
 - b PLIF
 - c posterior stabilization
 - d ALIF
- 8 Which approach requires the use of vascular surgeon?
 - a postero-lateral
 - b PLIF
 - c ALIF
 - d none of the above
- 9 The laparoscopic ALIF is helpful for patients with _____.
 - a disk herniation, spinal stenosis or synovial cyst
 - b axial back pain, leg pain and posterior pathology
 - c previous discectomy for herniation
 - d axial back pain and no spinal canal abnormalities
- 10 An aggressive laminectomy and medial facetectomy helps avoid _____.
 - a nerve-root stretch
 - b dislodgement
 - c ligament stretch
 - d vertebral-body collapse

Operative Solutions to Axial Lumbar Pain

		a	b	c	d		a	b	c	d
<input type="checkbox"/> Certified Member	<input type="checkbox"/> Certified Nonmember	1	<input type="checkbox"/>	<input type="checkbox"/>	<input type="checkbox"/>	6	<input type="checkbox"/>	<input type="checkbox"/>	<input type="checkbox"/>	<input type="checkbox"/>
Certification No _____		2	<input type="checkbox"/>	<input type="checkbox"/>	<input type="checkbox"/>	7	<input type="checkbox"/>	<input type="checkbox"/>	<input type="checkbox"/>	<input type="checkbox"/>
Name _____		3	<input type="checkbox"/>	<input type="checkbox"/>	<input type="checkbox"/>	8	<input type="checkbox"/>	<input type="checkbox"/>	<input type="checkbox"/>	<input type="checkbox"/>
Address _____		4	<input type="checkbox"/>	<input type="checkbox"/>	<input type="checkbox"/>	9	<input type="checkbox"/>	<input type="checkbox"/>	<input type="checkbox"/>	<input type="checkbox"/>
City _____ State _____ ZIP _____		5	<input type="checkbox"/>	<input type="checkbox"/>	<input type="checkbox"/>	10	<input type="checkbox"/>	<input type="checkbox"/>	<input type="checkbox"/>	<input type="checkbox"/>
Telephone _____										

Mark one box next to each number. Only one correct or best answer can be selected for each question.