


Rhegmatol



genous RETINAL DETACHMENTS

PAMELA DALY, CST, SA-C

THE RETINA IS COMPRISED OF 1.2 MILLION PHOTORECEPTORS THAT ARE RESPONSIBLE FOR CHANGING LIGHT RAYS INTO ELECTRICAL IMPULSES THAT ARE CARRIED ALONG THE OPTIC NERVE TO THE BRAIN.²² THE RETINA MUST REMAIN FIRMLY ADHERED TO THE RETINAL PIGMENT EPITHELIUM (RPE) ON THE INSIDE WALL OF THE EYE IN ORDER TO FUNCTION PROPERLY. IN A RETINAL DETACHMENT, THE RETINA SEPARATES FROM THE RPE, CAUSING MALFUNCTION OF THE PHOTORECEPTORS AND DIMINISHED VISION

IN THE AREA OF DETACHMENT.^{16,22,2}

THE INCIDENCE OF PRIMARY RETINAL DETACHMENT IS APPROXIMATELY 12 CASES PER 100,000.¹¹ THEY OCCUR MORE OFTEN IN MEN, TYPICALLY BETWEEN AGES 40 AND 70.¹⁷

THIS ARTICLE WILL DESCRIBE THE PATHOGENESIS AND TREATMENT OF PRIMARY RHEGMATOGENOUS RETINAL DETACHMENT (RRD), AN UNCOMMON YET IMPORTANT CAUSE OF VISUAL LOSS THAT CAN BE TREATED MOST EFFECTIVELY BY EARLY RECOGNITION OF SYMPTOMS AND URGENT SURGICAL CORRECTION.

Anatomy

The posterior eye wall is formed by three juxtaposed layers: (1) the sclera, which is a tough, fibrous outer shell that serves to protect the internal ocular structures; (2) the choroid, a highly vascular layer that provides nutrients to the outer portion of the retina, (along with the RPE); and (3) the retina which contains the photoreceptors, neurosensory fibers and supporting cells that transmit visual information to the brain.^{21,22} (Figure 1)

The posterior segment of the eye receives light that passes through the anterior segment structures (the cornea, iris and lens) and converges that light on the retinal surface.²¹ (Figure 2) The central part of the retina, the macula, is the part of the retina that is aligned with the central visual axis; when it is diseased, central acuity is poor while peripheral vision is often spared. The vitreous cavity is the central portion of the globe, and is filled with a clear, collagenous gel, called the vitreous body. As the eye ages, the relationship between the vitreous gel and the peripheral retina forms the basis for understanding the pathogenesis of rhegmatogenous retinal detachments.^{1,2,5,7}

Pathogenesis and classification

Primary RRD are formed when a retinal tear or break occurs, allowing the vitreous fluid to seep through the retinal break and gain access to the subretinal space.⁴ This process occurs as a complication of a natural maturing of the vitreous gel.² In a younger person, the vitreous gel has a high concentration of collagen and relatively low water content. This makeup creates a vitreous body that is well formed, with the consistency of gelatin.

With age, the collagen content naturally diminishes and the water content increases, yielding vitreous that has the consistency of an egg white. As the vitreous breaks down and becomes much more fluid, the collagenous portion is still attached to the retinal surface as a broad sheet. This is called the posterior hyaloid or posterior vitreous face. The liquefaction of the central vitreous cavity causes a loss of support

for the posterior portion of the vitreous. The posterior hyaloid collapses inward toward the central vitreous cavity, peeling itself off of the retina. The more liquefied vitreous fluid leaks into the space created by the collapse of this posterior gel. This process is called a posterior vitreous detachment (PVD).^{1,2,3,6,7,10,16} PVDs occur in virtually all adults and the incidence increases with age.⁴ Myopia, aphakia, pseudophakia, inflammation and trauma can also increase the likelihood of PVD.⁷ Roughly 75% of all 75-year-old patients show evidence of PVD on a dilated eye examination.¹⁷

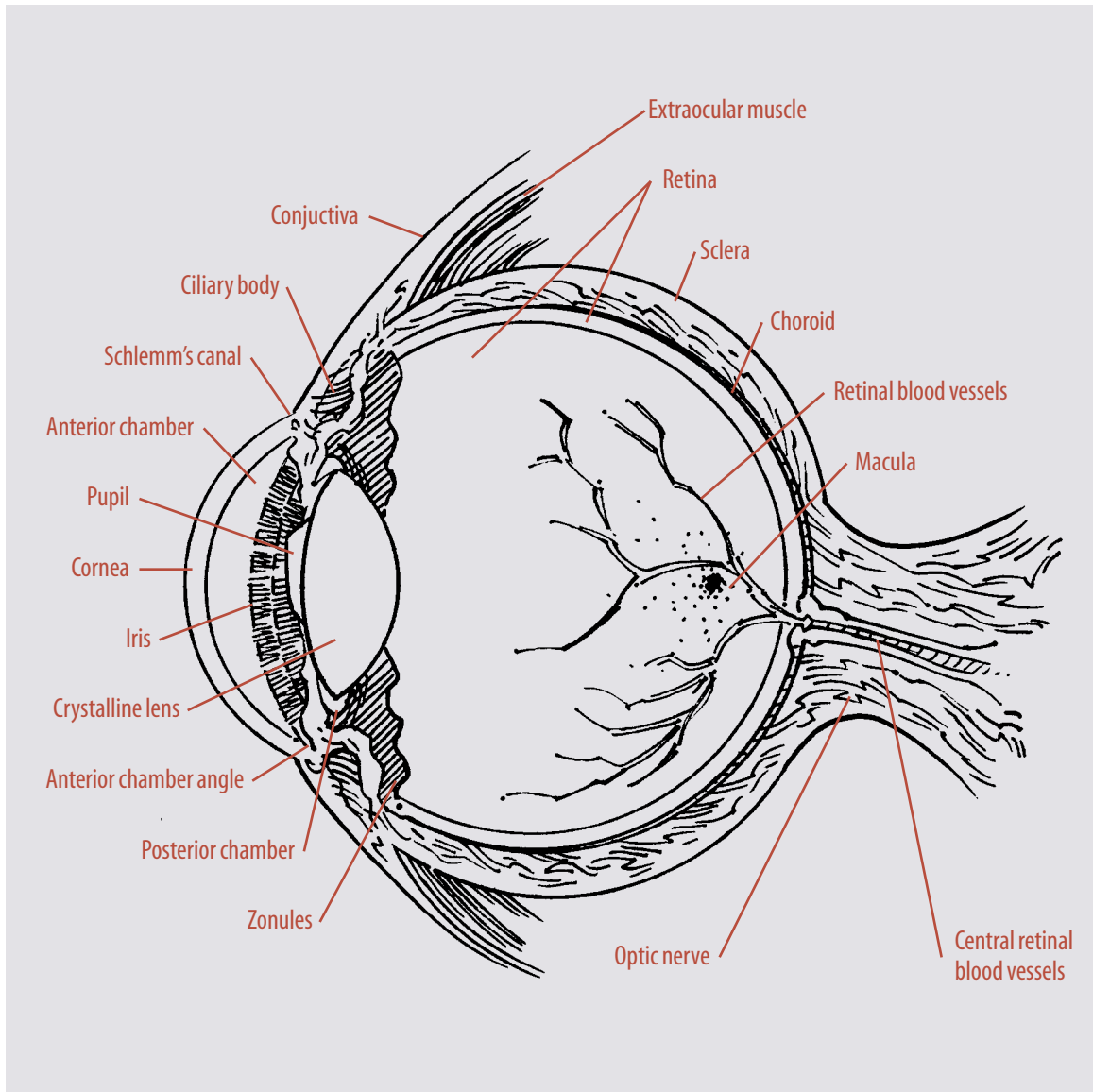
PVDs are usually asymptomatic, but patients may notice an abrupt increase in visual abnormalities (usually in the form of new floaters or peripheral flashes of light).^{6,8} Floaters occur for several reasons. The liquefied vitreous is now much more mobile because it has detached itself from the retinal surface. The differences in the viscosity of the more formed and less formed portions of the gel can cause visual aberrations.²³ As the gel detaches from the retina it can also pull fibrous, glial tissue off the optic nerve head (a Weiss ring) that can be seen as a circular floater in the central portion of vision.²²

Hemorrhage can also cause new floaters. This typically occurs when the retina becomes torn during a PVD.² As the gel peels away from the retina, any area of abnormally strong vitreoretinal adhesion (prior trauma, scars, lattice degeneration or other retinal disease) may place the patient at risk for a retinal tear.^{3,13,22} The gel will either break free (with no retinal damage) or will remain stuck. A flap of retina will be pulled toward the central part of the eye along with the vitreous body, creating a tear. Patients with evolving PVD often experience peripheral flashes caused by the traction and tugging on the retina by the vitreous.^{1,2,4,16} The resulting horseshoe tear usually progresses to a primary RRD—primary, since no other disease led to the detachment, and rhegmatogenous, since a retinal break led to the accumulation of subretinal fluid (*rhegma*=break).²³

Once fluid begins to enter the subretinal space and elevate the retina off of the choroids,

FIGURE 1

Anatomy
of the eye.



visual field anomalies can be seen in the area of detachment due to lack of nutrition of the photoreceptors.^{1,22} At this stage, patients may still have crisp central vision but a slowly enlarging field deficit. If repair is not performed at this stage, the visual darkening will progress across the eye, through the central part of vision. When this occurs, the vision usually drops to the “finger-counting” to “hand-motions” level. Prompt surgical intervention once the macula has detached will usually restore a significant amount of central acuity, but, in most cases, the best-corrected vision improves postoperatively only to the 20/50 level.²³ Prompt correction prior to macular

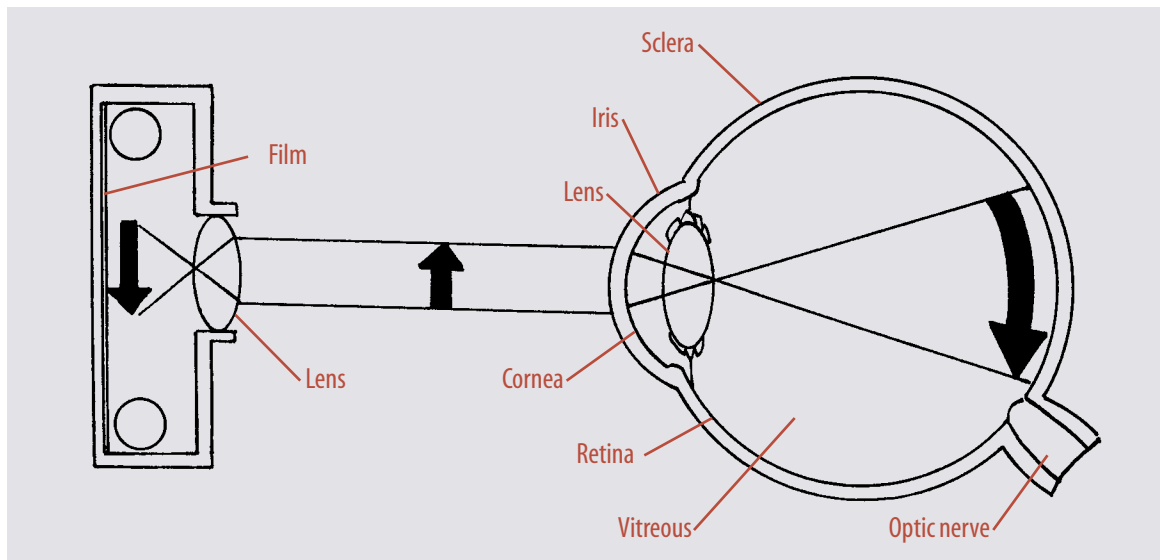
detachment usually can preserve sharp 20/20 acuity (with correction).²³

Other forms of retinal detachment include exudative and tractional. Exudative detachments occur as a result of extreme inflammation, abnormal blood vessel growth beneath the retina (choroidal neovascular membranes), or cancerous conditions (lymphoma, melanoma).²² The fluid that collects in the subretinal space does not come from the vitreous cavity as in primary rhegmatogenous detachments, but instead is proteinaceous serous fluid that leaks from abnormally permeable blood vessels.^{15,22}

Tractional detachments occur as a result of scar tissue that grows across the concave retinal

FIGURE 2

Light rays converge on to the retina like the film of a camera. If the film or retina is not good, the image won't be clear.



surface and then contracts, shortening the retina and elevating it off of the concave eye wall. Proliferative diabetic retinopathy and proliferative vitreoretinopathy are two examples of severe traction-producing diseases.^{12,15,22,23}

History of surgical correction

Hermann Von Helmholtz is credited with inventing the ophthalmoscope in 1851; this advance created the means to accurately describe and subsequently repair retinal detachments.^{17,23} Jules Gonin is considered to be the father of retinal detachment surgery. He believed, along with Theodor Leber, that liquid vitreous forced holes in the retina. Leber found retinal breaks in 70% of all retinal detachments and noted that there was usually a break in the area where the retinal detachment began.^{17,23} Both Gonin and Leber stressed that contraction of the vitreous body tore holes in the retina at sites of previous chorioretinitis (inflammation) or by chorioretinal degeneration.

Once Gonin realized that retinal breaks led to detachment, he concluded that a permanent cure depended on sealing them. In 1919, he performed the first operation designed to close retinal breaks.¹⁷ After localization of the break, he made a radial incision through the sclera to the choroids with a Graefe knife, then used the knife to incise the choroids and enter the subretinal space, draining the subretinal fluid. He then

placed cautery 2-3 mm into the wound. Using this technique, he achieved a 40-50% reattachment rate.²³

Others quickly improved upon Gonin's original operation. Gonin espoused two main principles that remain the basis for all successful retinal detachment surgery: (1) all breaks must be found, and (2) all breaks must be accurately localized (so they can be closed).²² Gonin recognized that a surgical failure meant that the retinal break was not properly closed or that another break existed.^{22,23}

Two significant advances in fundus examination were made in the late 1940s. Charles Schepens' electrically illuminated binocular indirect ophthalmoscope remains the most valuable instrument currently available for evaluation of a detached retina. The Goldman three-mirror lens permits stereoscopic slit lamp examination of almost the entire retina if the pupil can be widely dilated and if the ocular media (cornea, lens, vitreous) is clear.²² In 1938, Bengt Rosengren increased the rate of reattachment by injecting air into the vitreous to tamponade the retinal break after diathermy treatment and drainage of subretinal fluid. With this technique, Rosengren's reattachment rate improved to 76%.²³

In 1953, Ernst Custodis introduced scleral indentation, or "buckling," to help close retinal breaks. He called the procedure plombenauf-

nahung, literally, “the sewing on of a seal.” He first treated all breaks with surface diathermy and then closed all breaks with a polyviol explant (the “plombe”) sutured to the sclera overlying the retinal breaks.^{22,23} The indenting explant reduced vitreous traction on the retina and closed the break, allowing a firm chorioretinal scar to form.^{22,23} Custodis emphasized that the explant must be large enough to close the entire break, as he found that a misplaced explant could inhibit proper break closure. His success rate improved to 84%.²⁰

Schepens pioneered the use of implants in the scleral bed to reduce vitreous traction and to prevent posterior progression of the detachment.

Originally, he buried polyethylene tubing at the posterior end of the most posterior break and drained subretinal fluid. The implant was intended to act as a postoperative “dyke” of sorts, preventing posterior leakage of subretinal fluid from any open anterior break. He later used implants made of silicone to completely close all retinal breaks.²² Schepens also is credited with emphasizing the importance of encircling the eye with the buckling element to permanently reduce vitreous traction on the peripheral retina.^{17,22,23}

Surgical procedure for RRD

A patient who has been diagnosed with an RRD is given an explanation of the risks involved with

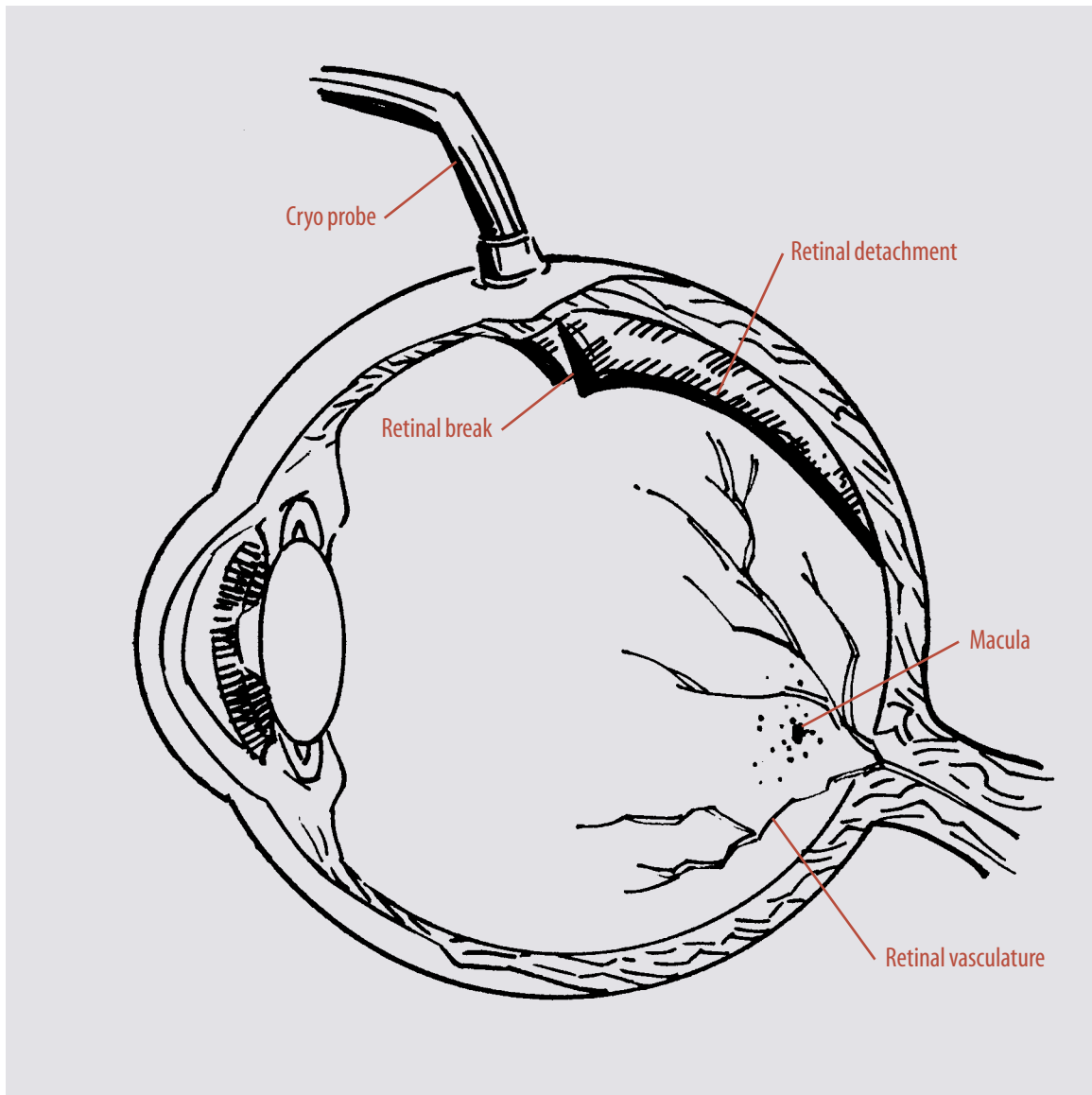


FIGURE 3

Cryoplexy of
retinal break.

FIGURE 4

Scleral buckling for treatment of retinal detachment.

- Ⓐ Preparation of sclera for buckle
- Ⓑ Scleral buckle sutured in place.

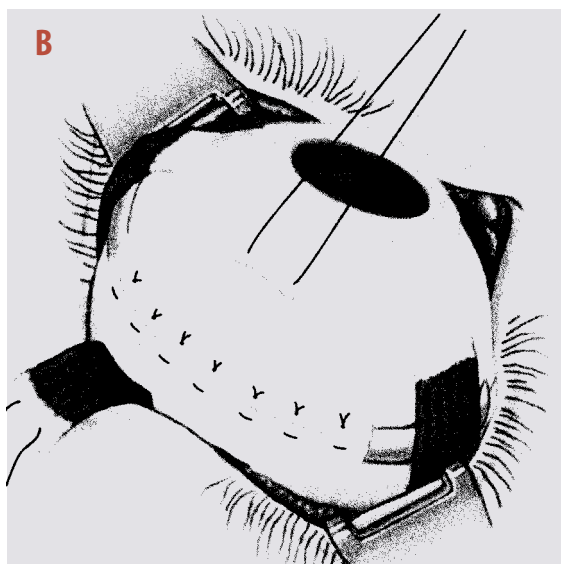
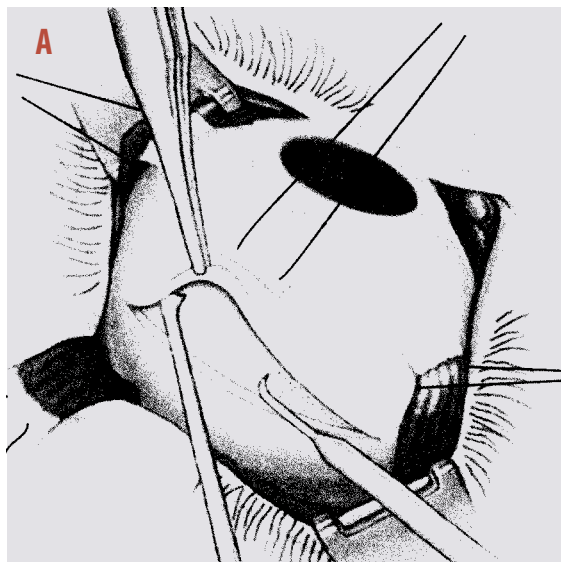


Illustration: From *Surgical Technology for the Surgical Technologist: A Positive Care Approach*, 1st edition by AST (© 2001). Reprinted with permission of Delmar Learning, a division of Thompson Learning, www.thompsonlearning.com. Fax: 800-730-2115.

the scleral buckle procedure. After going over any of the patient's questions, a consent form should be signed. The patient is brought to the operating room and placed in a supine position onto the operating bed. After anesthesia has been given (either general or a retrobulbar block), the patient's head is usually placed in some type of cradling device, such as a wedge shaped sponge, rendering it immobile during the procedure. At this time, some retina surgeons will verify the operative eye by looking into the dilated eye with an indirect ophthalmoscope before prepping the eye. Once this has been accomplished the circulator is given permission to proceed with the prep.

After the eye has been prepped, usually with a Betadine solution and water, the surgical technologist can then drape the eye with a non-fenestrated eye drape. After an opening has been made into the drape with a scissors, usually a Westcott scissors, a lid speculum is inserted into the eye so it remains open during the operation. It is typical for the surgeon to relax the conjunctiva and perform a peritomy around the limbus. At this point, a Curtis-Stevens tenotomy scissors can be used to clear the conjunctiva from the sclera.

A method for securing the buckle around the globe of the eye utilizes the four rectus muscles. One way of isolating the muscles is with the use of a muscle hook. The hook is placed under the muscle and then wiped clean with a sterile swab. A cannulated muscle hook loaded with a tying suture can then be placed under the muscle, and the suture pulled through and tied loosely. Typically, the surgeon inspects the detachment with the indirect ophthalmoscope and marks the area of detachment on the sclera with the use of a Connor depressor and a marking pen. It is common, at this point, to freeze the area of detachment with the use of cryotherapy to create scar tissue that will help the retina adhere to the back wall of the eye and remain flat. (Figure 3)

The silicone band can then be placed around the globe. Commonly, a mattress suture, usually with a 5-nylon, is placed onto the sclera between the four rectus muscles. The silicone band can then be tied onto the sclera, as well as secured under the four rectus muscles, to keep the buckle secure. (Figure 4) Before the buckle is permanently tied in place, it is sometimes necessary to drain the fluid that has accumulated under the retina. This can be accomplished by penetrating the globe with the use of a needle or beaver blade and allowing the fluid to escape, causing the retina to flatten. The surgeon then inspects the flattened retina with the indirect ophthalmoscope.

If the eye appears to be too firm, a paracentesis can be done into the anterior chamber of the eye. At this time, the mattress sutures can be permanently tied. The sutures that have been tied

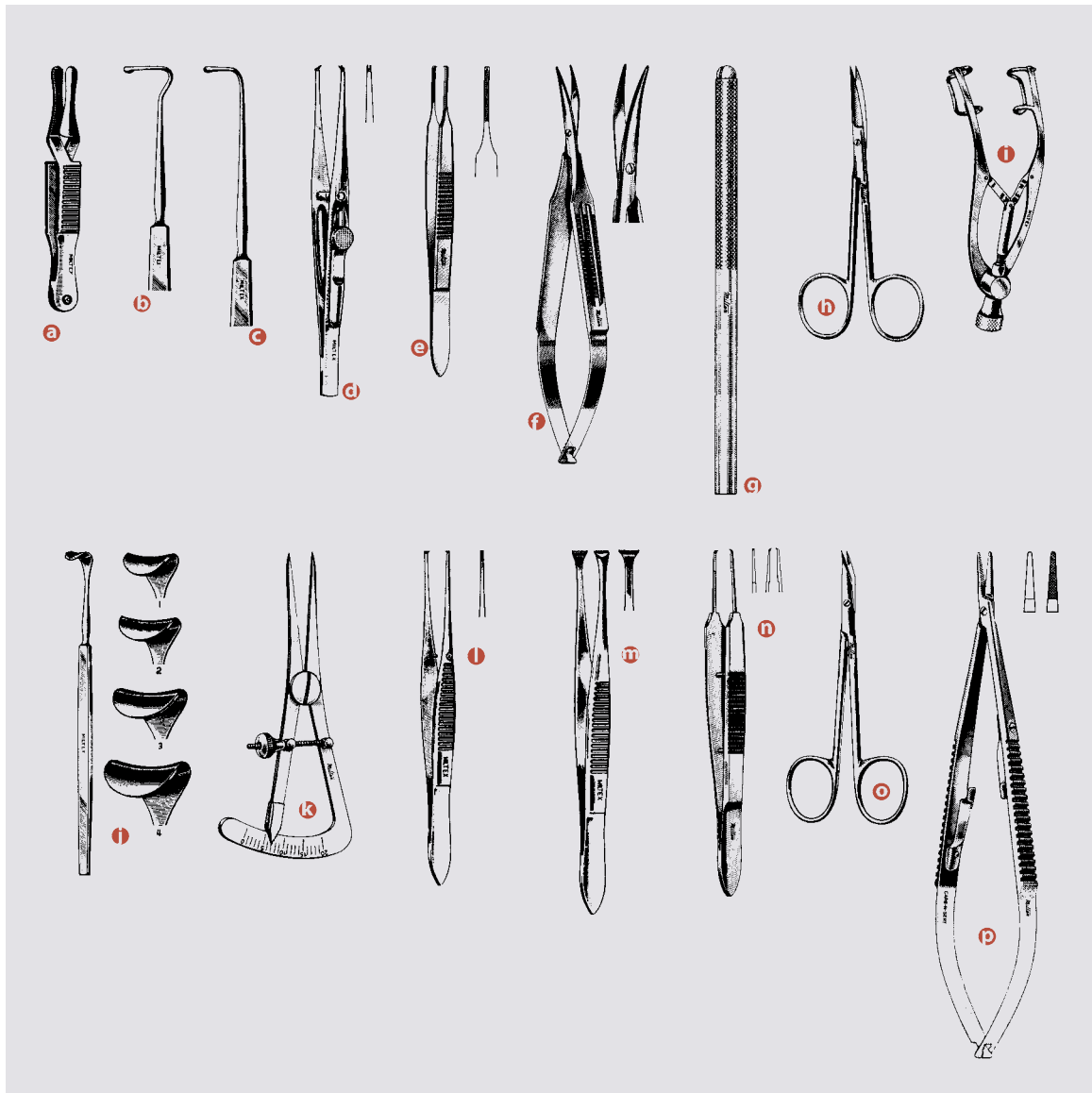


FIGURE 5

Select ophthalmic instrumentation.

- Ⓐ *Serrefine 1-1/2"*
- Ⓑ *Jameson strabismus hook 5"*
- Ⓒ *Von Graefe strabismus hook 5-1/2"*
- Ⓓ *Kirby fixation forceps 4"*
- Ⓔ *McCullough suturing forceps 4"*
- Ⓕ *Westcott tenotomy scissors 5-1/4"*
- Ⓖ *Miniature blade handle with chuck (fits Beaver blades)*
- Ⓗ *Iris scissors 4"*
- Ⓘ *Castroviejo eye speculum 3-3/4"*
- Ⓚ *Desmarres lid retractor 5-1/2"*
- Ⓛ *Castroviejo caliper 3-1/4"*
- Ⓜ *Iris tissue forceps 4"*
- Ⓝ *Graefe fixation forceps 4-3/8"*
- Ⓟ *Castroviejo suturing forceps 4"*
- Ⓠ *Eye suture scissors (Gradle) 3-3/4"*
- Ⓡ *Castroviejo needle holder 5-1/2" (with lock)*

www.CourtesyofMillers, Inc., Bellhouse, NY © 2002.

onto the muscles can be cut and removed. The conjunctiva can now be placed over the buckle and sutured together, making sure the buckle is completely covered. At the end of the operation antibiotics and steroids are commonly injected into the conjunctiva to promote healing. After being reversed from anesthesia, the patient can be brought to the recovery room and given instructions.

Postoperative notes

The patient is usually scheduled for an appointment with the surgeon the next day. It is customary to check visual acuity and intraocular pressure. Postoperative instructions are given

regarding the use of antibiotic and steroid drops. The patient is also informed of any restrictions on physical activity.

The success rate for scleral buckle surgery depends on the preoperative status of the macula. The anatomical success rate is 90 to 95%. Of the eyes that are successfully reattached, about 50% obtain a visual acuity of 20/50 or better if the macula was compromised. In eyes where the macula was attached prior to surgery, as many as 10% have some loss of vision despite successful surgery. In most cases, this decrease in vision is caused by cystoid macular edema and macular pucker. Without repair of the retinal detachment however, visual recovery is poor.

About the author

Pamela Daly has been a certified surgical technologist since 1984, and became certified with the American Board of Surgical Assistants in 2000. She attended Fox Valley Technical College in Appleton, Wisconsin. Pam is currently employed with Texas Retina Associates in Dallas, Texas. She has specialized in ophthalmology for the past six years.

Acknowledgements

I would like to thank David Callanan, MD, and Wayne Solley, MD, for their contributions and support in assisting me with writing this article. Thanks to Jim Daly for illustrating Figures 1-3 of this article.

References

1. Benson WE, Tasman W. Rhegmatogenous retinal detachments caused by paravascular vitreoretinal traction. *Arch Ophthalmol*. 1984; 102:669.
2. Bill A. Blood circulation and fluid dynamics in the eye. *Physiol Rev*. 1975; 55:383.
3. Boldrey EE. Risk of retinal tears in patients with vitreous floaters. *Am J Ophthalmol*. 1983; 96:783.
4. Davis MD. Natural history of retinal breaks. *Arch Ophthalmol*. 1974; 92:183.
5. Fatt I, Skhantinath K. Flow conductivity of retina and its role in retinal adhesion. *Exp Eye Res*. 1971; 12:218.
6. Haimann MH, Burton TC, Brown CK. Epidemiology of retinal detachments. *Arch Ophthalmol*. 1972; 56:700.
7. Jaffe NS. Vitreous detachments. In: *The Vitreous in Clinical Ophthalmology*. St. Louis: CV Mosby; 1969: 83-98.
8. Morse PH, Aminlari A, Scheie HG. Light flashes as a clue to retinal disease. *Arch Ophthalmol*. 1974; 92:297.
9. Paufigue L. The present status of the treatment of retinal detachment. *Trans Ophthalmol Soc UK*. 1959; 69:221.
10. Tasman WS. Posterior vitreous detachment and peripheral retinal breaks. *Trans Am Acad Ophthalmol Otolaryngol*. 1968; 72:217.
11. Wilkes ST, Beard CM, Kurland LT et al: The incidence of retinal detachment in Rochester, Minnesota, 1970-1978. *Am J Ophthalmol*. 1982; 94:670.
12. Felder DS, Brockhurst RJ. Retinal neovascularization complicating rhegmatogenous retinal detachment of long duration. *Am J Ophthalmol*. 1982; 93:773.
13. Laqua H, Machemer R. Glial cell proliferation in retinal detachment (massive periretinal proliferation). *Am J Ophthalmol*. 1975; 80:602.
14. Linner E. Intraocular pressure in retinal detachment. *Arch Ophthalmol (Suppl)*. 1966; 84:101.
15. The Retina Society Terminology Committee. The classification of retinal detachment with proliferative vitreoretinopathy. *Ophthalmology*. 1983; 990:121.
16. Sasaki K, Ideta H, Yonemoto J, et al. Epidemiologic characteristics of rhegmatogenous retinal detachment in Kumamoto, Japan. *Graefes Arch Clin Exp Ophthalmol*. 1995 Dec;233(12): 772-6(Medline).
17. Schepens CL, Marden D. Data on the natural history of retinal detachment. I. Age and sex relationships. *Arch ophthalmol* 1961; 66:631.
18. La Heij EC, Derhaag PF, Hendrikse F. Results of scleral buckling operations in primary rhegmatogenous retinal detachment. *Doc Ophthalmol*. 2000; 100(1): 17-25 (Medline).
19. Lincoff H, McLean JM, Nano H. Crkyosurgical treatment of retinal detachment. *Trans Am Acad Ophthalmol Otolaryngol*. 1964; 68:412-32.
20. Lincoff HA, Baras I, NcLean FM. Modification to the Custodis procedure for retinal detachment. *Arch Ophthalmol*. 1965; 73:160-3.
21. Texas Retina Associates, Dallas Texas Retinal Tears and Detachments. www.texasretina.com Accessed 5/2002.
22. Benson WE. *Retinal Detachment: Diagnosis and Management*, 2nd ed. Philadelphia: Lippincott; 1988: 1-13,53-65.
23. Wu L. Retinal Detachments. Ophthalmology Times [online journal]. June 27 2001, vol 2, No 6. www.opthalmologytimes.com/opthalmologytimes Accessed 5/2002

Rhegmatogenous retinal detachments

Earn CE credit at home

You will be awarded one continuing education (CE) credit for recertification after reading the designated article and completing the exam with a score of 70% or better.

If you are a current AST member and are certified, credit earned through completion of the CE exam will automatically be recorded in your file—you do not have to submit a CE reporting form. A printout of all the CE credits you have earned, including Journal CE credits, will be mailed to you in the first quarter following the end of the calendar year. You may check the status of your CE record with AST at any time.

If you are not an AST member or not certified, you will be notified by mail when *Journal* credits are submitted, but your credits will not be recorded in AST's files.

Detach or photocopy the answer block, include your check or money order made payable to AST and send it to the Accounting Department, AST, 6 West Dry Creek Circle, Suite 200, Littleton, CO 80120-8031.

Members: \$6 per CE, nonmembers: \$10 per CE

- Which layer of the posterior wall provides nutrients to the outer portion of the retina?
 - sclera
 - photoreceptors
 - choroid
 - macula
- Which of the following structures does not allow the passage of light focus light onto the retinal surface?
 - lens
 - photoreceptors
 - iris
 - cornea
- Which structure in the retina is aligned with the central visual axis?
 - sclera
 - macula
 - vitreous body
 - choroids
- Which is not a factor in the development of PVD?
 - age
 - trauma
 - myopia
 - presence of a cataract
- Which of the following are mismatched?
 - floaters: differences in gel viscosity
 - enlarging field of deficit: hemorrhage
 - circular floater: detached glial tissue
 - retinal break: accumulation of subretinal fluid
- Which form of retinal detachment may be caused by diabetic retinopathy?
 - tractional
 - rhegmatogenous
 - exudative
 - all of the above
- Which is mismatched?
 - Schepens: implant pioneer
 - Custodius: buckling
 - Von Helmholtz: father of retinal detachment surgery
 - Schepens: electrically illuminated binocular indirect ophthalmoscope
- A lid speculum is used to _____.
 - immobilize the head
 - drain fluid under the retina
 - mark the area of detachment
 - keep the eye open during surgery
- Which of the following may be used to secure the buckle around the globe?
 - rectus muscles
 - cannulated muscle hook
 - suture
 - a and c
- Cryotherapy may be used to _____.
 - help the retina adhere to the back wall of the eye
 - drain fluid from the retina
 - mark the area of detachment
 - close the wound

Rhegmatogenous retinal detachments

<input type="checkbox"/> Certified Member	<input type="checkbox"/> Certified Nonmember		a	b	c	d		a	b	c	d
Certification No _____		1	<input type="checkbox"/>	<input type="checkbox"/>	<input type="checkbox"/>	<input type="checkbox"/>	6	<input type="checkbox"/>	<input type="checkbox"/>	<input type="checkbox"/>	<input type="checkbox"/>
Name _____		2	<input type="checkbox"/>	<input type="checkbox"/>	<input type="checkbox"/>	<input type="checkbox"/>	7	<input type="checkbox"/>	<input type="checkbox"/>	<input type="checkbox"/>	<input type="checkbox"/>
Address _____		3	<input type="checkbox"/>	<input type="checkbox"/>	<input type="checkbox"/>	<input type="checkbox"/>	8	<input type="checkbox"/>	<input type="checkbox"/>	<input type="checkbox"/>	<input type="checkbox"/>
City _____ State _____ ZIP _____		4	<input type="checkbox"/>	<input type="checkbox"/>	<input type="checkbox"/>	<input type="checkbox"/>	9	<input type="checkbox"/>	<input type="checkbox"/>	<input type="checkbox"/>	<input type="checkbox"/>
Telephone _____		5	<input type="checkbox"/>	<input type="checkbox"/>	<input type="checkbox"/>	<input type="checkbox"/>	10	<input type="checkbox"/>	<input type="checkbox"/>	<input type="checkbox"/>	<input type="checkbox"/>

Mark one box next to each number. Only one correct or best answer can be selected for each question.