

Cervical Mediastinal



Exploration

SUSAN ALEXANDER

FOR STAGING OF LUNG CANCER

CERVICAL MEDIASTINAL EXPLORATION (CME), OR MEDIASTINOSCOPY, IS A SURGICAL PROCEDURE TO EXPLORE AND SAMPLE LYMPH NODES IN THE SPACE BETWEEN THE LUNGS, (THE MEDIASTINUM), WHEN DIAGNOSTIC IMAGING STUDIES (X-RAY, CT SCAN, ETC) SUGGEST A GROWTH IN THE LUNGS OR MEDIASTINAL REGION. THE MOST COMMON PURPOSE OF THE CME IS TO DIAGNOSE BRONCHOGENIC LUNG CANCER BY SAMPLING SELECTED LYMPH NODES IN AND AROUND THE TRACHEA, ITS MAJOR BIFURCATION AND THE GREAT VESSELS. LYMPH NODES ARE REMOVED AND SENT TO PATHOLOGY FOR TISSUE DIAGNOSIS TO DETERMINE THE HISTOLOGY OF THE TUMOR. CME IS PERFORMED PRIMARILY TO STAGE LUNG CANCER AND DETERMINE THE EXTENT OF THE DISEASE AND ESTABLISH TREATMENT OPTIONS.

If cancer exists in the lymph nodes, the cell type (histology) identifies the type of cancer and extent of the lymph nodes involved. If tumor involvement in the mediastinal area is demonstrated in the pathology review of the specimen(s) (lymph nodes), the patient may be spared an unnecessary thoracotomy; however, this means that the tumor is inoperable.⁵

History

CME was originally described by Harken and associates (1954).¹ The procedure is done to sample lymph nodes in the paratracheal area and the superior mediastinum for the tissue diagnosis of mediastinal disease with the use of a modified laryngoscope. The original technique was an extension of scalene node biopsy that had been developed by Daniels (1949).² This procedure was further refined by E Carlens (1959)¹ and FG Pearson (1965)², who reported on an anterior cervical mediastinoscopy using a midline approach, the technique currently used today.

TM McNeil and JM Chamberlain (1966)³ described the technique in which lymph nodes not accessible by the CME in the aortopulmonary window could be sampled by an anterior mediastinotomy. This is referred to as the Chamberlain procedure. RJ Ginsberg and associates (1987),² “extended” the technique as an alternative to left anterior mediastinoscopy. The Chamberlain procedure may also be used to stage lung cancer.

Incidence and histology

American Cancer Society reports figures on patients with thoracic neoplasms. In 2001, there were 169,400 new cases of lung and bronchus cancers for both genders in the United States. Estimated total deaths from lung cancer were 154,900.⁴ Different types (histology) of lung and bronchogenic cancers are diagnosed as: squamous cell (also known as epidermoid), small cell (also called oat cell), adenocarcinoma and large cell. The type indicates the rate of growth and prognosis.

Patients with tumors involving the left hilum or left upper lobe present a special problem, in that these tumors frequently spread to lymph

nodes that are not accessible through CME. In one series of 100 patients with tumors in this area, 22 were found to be inoperable despite having a negative mediastinoscopy.⁵ Left anterior mediastinotomy through the second intercostal space is the preferred method to assess the operability of these patients, as suggested by Pearson and coworkers.⁵

Less than 50% of patients undergoing curative resection for bronchogenic carcinoma survive five years. Most deaths are due to local recurrence or disseminated disease. Analysis of the causes of death within a year of surgery suggests that a third of patients have metastases. Likely sites of metastases include bone, brain, liver, and adrenal glands.

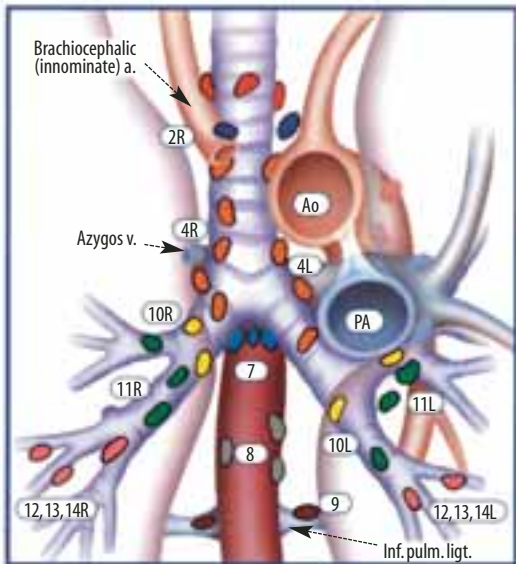
Metastases is less frequent for squamous cell carcinoma, than for adenocarcinoma. In resected patients with Stage I squamous cell cancers, metastases occurred in 15% versus 27% with adenocarcinomas.

Hillers et al performed a literature review (1966-1991) to determine the proportion of patients with potentially operable non-small cell lung cancer that could be spared thoracotomy by a search for extrathoracic metastases. Although only 17 studies were suitable for analysis, the frequency of metastases was as follows:

- Liver Imaging 2.3% (0.9–3.3%)
- Head CT 3.3% (2.1–4.4%)
- CT adrenal 4.7% (3.0–6.4%)
- Bone Scan 9.3% (6.7–12%)

Staging

Having a common way to describe a patient's cancer enables doctors everywhere to share information about cancers and their treatments. The international system used is the TNM system. The letters TNM are used for describing the cancer: T indicates the size of the tumor; N indicates if the cancer has spread to lymph nodes; and M indicates whether the cancer has spread to other parts of the body (metastasis). A number is then added to each letter to indicate the degree of size and spread. For example, a cancer could be described as T1 N2 M0.⁶ This



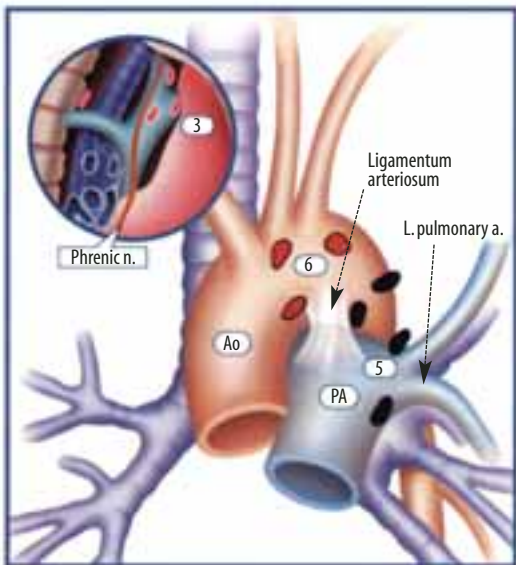
Superior mediastinal nodes

- 1 Highest mediastinal
- 2 Upper paratracheal
- 3 Pre-vascular and retrotracheal
- 4 Lower paratracheal (including Azygos Nodes)

N₁ = singledigit, ipsilateral
N₂ = single digit, contralateral or superclavicular

Aortic nodes

- 5 Subaortic (A-P window)
- 6 Para-aortic (ascending aorta or phrenic)



Inferior mediastinal nodes

- 7 Subcarinal
- 8 Paraesophageal (below carina)
- 9 Pulmonary ligament

N₁ nodes

- 10 Hilar
- 11 Interlobar
- 12 Lobar
- 13 Segmental
- 14 Subsegmental

FIGURE 1

Regional nodal stations for lung cancer staging.

means the tumor is under 3 cm in size, nodes are involved (ipsilateral mediastinal and/or subcarinal), and no evidence exists of distant metastases to target organs. Target organs are those organs that lung cancer is known to metastasize to. The probability of metastases depends on the TNM stage and the histology type.⁶ The higher the stage, the more frequent the metastases. For example, there is a 12-fold increase in cerebral metastases in patients with stage T2N1 tumors compared those with stage T1N0 (Table 1).⁷

Grading

Grading is another way of describing a cancer. In grading, tumor cells are examined under a

microscope to see how much they resemble normal cells. A pathologist can make a prediction about whether tumor cells are likely to grow slowly or rapidly. Like staging, the lower the grade, the better the chance the tumor will respond to therapy. Usually, grading is done on a scale of one to three, or one to four.

Surgical anatomy

The anatomic basis for developing this procedure rests on the lymphatic drainage of the lungs that proceeds from the hilar nodes to the subcarinal, paratracheal, and finally supraclavicular lymph nodes. Exploration of the peritracheal superior mediastinum with identification and

biopsy of lymph nodes in and around the trachea and its major bifurcation can be accomplished (Figure 1).

Harken and associates¹ method was to sample the lymph nodes in the peritracheal area through a lateral supraclavicular incision. Note these lymph nodes are unavailable for biopsy by the standard mediastinoscopy: anterior mediastinal, subaortic, and posterior subcarinal. To safely biopsy these nodes, the Chamberlain approach is needed.

The McNeil and Chamberlain³ approach involved a vertical incision on either the right or left side of the chest over the lateral sternal border through which the mediastinum can be entered. The disadvantage for this technique is that it only allows for unilateral exploration. If bilateral exploration is necessary, the procedure has to be repeated on the contralateral side. The incision on the left side allows for biopsies of subaortic and para-aortic nodes as well as the hilar, interlobar, lobar, segmental, and subsegmental nodes (also referred to as N1 nodes) (Table 2). The incision on the right side allows for biopsies of just the N1 nodes. Carlen's midline CME approach via a suprasternal incision allows for a safe bilateral exploration and biopsy.¹

Thoracic neoplasms

Mediastinoscopy is also a valuable tool in diagnosing other tumors such as thymic, tracheal, and bronchial cysts, thymic lymphomas or hyperplasia, nervous system tumors, thyroid masses, or ascending aortic aneurysms, as well as enlarged lymph nodes associated with sarcoidosis.^{1,2} The major indications for a cervical mediastinal exploration are evaluation of lymph node involvement in patients with lung cancer, and tissue biopsy of suspected tumors.

Mediastinoscopy and mediastinotomy are used primarily for staging of lung cancer, to evaluate the lymph nodes in patients with potential cancer of the lung. The tumors identified during mediastinoscopy include primary malignant tumors such as bronchogenic lung cancer, lymphoma, as well as bone, vascular, or connective tissue tumors. The staging of lung cancer due to

the result of this procedure determines the course of treatment, or whether further evaluation needs to be done.

Diagnosis and preoperative preparation

A complete history and physical examination are carried out with emphasis on any respiratory symptoms, wheezing, coughing, dyspnea, and orthopnea. On occasion, a patient may have a chest X-ray or CT-scan of the chest for evaluation of another problem and a mass in the chest is discovered. The preoperative work up should include chest X-rays, CT scans of the chest and neck, and a pulmonary function test. If the evaluation reveals a potential serious obstruction due to a mediastinal mass, a preoperative course of chemotherapy, or radiation is suggested to reduce the size of the tumor and decrease the risk of respiratory compromise during induction and maintenance of anesthesia.

It is also important to determine whether any respiratory symptoms are exacerbated by exercise or by assuming the supine position. Presence of these changes should raise the question of a major airway obstruction secondary to the mediastinal mass. Dysphagia as a preoperative finding may indicate the presence of a mediastinal mass impinging on both the trachea and esophagus. If tracheal deviation is suspected, then specific studies should be obtained to evaluate the location and extent of the mass as well as the degree of airway compromise.

Procedure

CME is a sterile procedure performed under general endotracheal anesthesia. The patient is placed in the supine position with a bolster under the shoulders and the neck fully extended. If necessary, the patient is shaved and the entire chest is prepped (in case an emergency median sternotomy or thoracotomy becomes necessary) and draped. A small, short transverse incision is made through the skin and soft tissue, just above the suprasternal notch, about one fingerbreadth above the manubrium. The lymph nodes that may be biopsied are the hilar, subcarinal, paratracheal (including the Azygos node), and the

Table 1 The TNM staging system for lung cancer

TUMOR Stages: (T)	NODE Stages: (N)	METASTASIS Stages: (M)
T(X): Primary tumor cannot be assessed, or tumor proven by presence of malignant cells in sputum or bronchial washings but not visualized by imaging or bronchoscopy	N(X): Regional lymph nodes cannot be assessed	M(X): Presence of distant metastasis cannot be assessed
T(0): No evidence of primary tumor	N(0): No regional lymph node metastasis	M(0): No distant metastasis
Tis: Carcinoma in situ		
T(1): Tumor 3 cm or less in greatest dimension, surrounded by lung or visceral pleura, without bronchoscopic evidence of invasion more proximal than the lobar bronchus (ie not in main bronchus)	N(1): Metastasis in ipsilateral peribronchial and/or ipsilateral hilar lymph nodes, including direct extension	M(1): Distant metastasis
T(2): Tumor with any of the following features of size or extent: More than 3 cm in greatest dimension. Involves main bronchus, 2 cm or more distal to the carina. Invades the visceral pleura. Associated with atelectasis or obstructive pneumonitis which extends to the hilar region but does not involve the entire lung	N(2): Metastasis in ipsilateral mediastinal and/or subcarinal lymph node(s)	
T(3): Tumor of any size that directly invades any of the following: chest wall (including superior sulcus tumors), diaphragm, mediastinal pleura, parietal pericardium; or tumor in the main bronchus less than 2 cm distal to the carina but without involvement of the carina; or associated atelectasis or obstructive pneumonitis of the entire lung	N(3): Metastasis in contralateral mediastinal, contralateral hilar, ipsilateral or contralateral scalene or supraclavicular lymph node(s)	
T(4): Tumor of any size that invades any of the following: mediastinum, heart, great vessels, trachea, esophagus, vertebral body, carina; or tumor with a malignant pleural effusion		

FIGURE 2

Mediastinoscope.

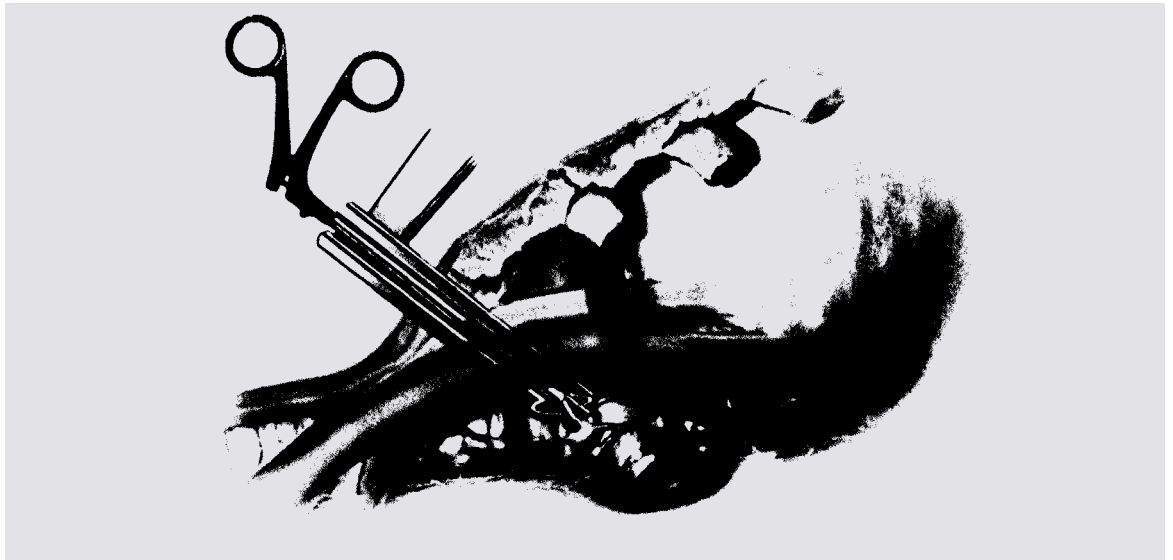


ILLUSTRATION From *Surgical Technology for the Surgical Technologist: A Positive Care Approach*, 1st edition by AST (c)2001. Reprinted with permission of Delmar Learning, a division of Thomson Learning: www.thomsonrights.com. Fax 800-730-2215.

upper paratracheal nodes. If the visual examination by the surgeon indicates that these nodes look normal, the Chamberlain procedure may be performed allowing the surgeon to obtain the subaortic, para-aortic, as well as any N1 lymph nodes, which are not accessible through the cervical mediastinoscopy.

A mediastinoscope with light source is introduced into the area between the lungs (Figure 2). The surgeon then examines the mediastinum through the viewing instrument and removes tissue samples from any suspicious areas. This procedure is often performed in combination with bronchoscopy.

A muscle retracting exposure of the trachea then allows for finger dissection into the mediastinum. The fascia is divided, allowing entry into the pretracheal space. During this dissection, the surgeon palpates for any abnormalities, including enlarged lymph nodes. It is extremely important to open the fascia below the level of the innominate artery. The right paratracheal and pretracheal nodes will be more easily accessible if this fascia is opened prior to insertion of the mediastinoscope.

Specimen labels are prepared in advance to avoid errors in labeling the potentially large number of specimens. Some surgeons assign the node its anatomical number to identify the location of the node. An anatomical chart should always be available in the operating room.

If there is any question as to the vascular nature of a structure, a spinal needle mounted on a small syringe to aspirate the structure in question is used. Any small bleeding vessels are coagulated electrosurgically. The incidence of complications is relatively low when the procedure is performed by experienced surgeons, and the mortality rate is about 0.5%.⁵

Intraoperative risks

Major complications during mediastinoscopy are most commonly encountered at either tracheobronchial angle. On the right side, the azygos vein and anterior pulmonary arterial branch to the right upper lobe are at risk of injury. The azygos vein is easily mistaken for the anthracotic lymph node and inadvertently biopsied. Experience and the liberal use of a long aspirating needle prior to biopsy will prevent this complication. Lymph nodes in this area are often directly adherent to branches of the pulmonary artery, which are therefore at risk if deep biopsies are taken or if excessive traction is applied. The apical arterial branch can also be injured if the mediastinoscope is “levered” anteriorly, resulting in a traction injury to the artery. At the left tracheobronchial angle, the recurrent laryngeal nerve is in close proximity to regional lymph nodes and can be easily traumatized. The entire lymph node should not be sampled since the recurrent laryngeal nerve is usually directly

adherent to nodes in the area. Bleeding is best handled with packing placed through the mediastinoscope rather than electrosurgically, which may cause permanent damage to the recurrent nerve.

In the event of massive bleeding, mediastinal packing will usually control the hemorrhage while blood is obtained and preparations are made for a possible thoracotomy or median sternotomy. Following 10 minutes of gauze tamponade, with the operating room prepared for a major procedure; the gauze packing is gently removed. In many cases the hemorrhage will have subsided or decreased so that the bleeding site can be identified. In the face of persistent uncontrollable hemorrhage, the mediastinum should be repacked and a decision made as to whether thoracotomy or median sternotomy offers the best approach to control the hemorrhage.

Median sternotomy is a most versatile incision and allows most injuries to be easily identified and controlled. It also allows the surgeon to expeditiously institute cardiopulmonary bypass to gain control of major vessel injuries. A disadvantage of sternotomy is the difficulty in carrying out a definitive pulmonary resection once the hemorrhage is controlled.

Injuries to the esophagus are extremely rare. As the esophagus lies directly posterior to the subcarinal space, most injuries occur during the exploration of this space and the biopsy of subcarinal lymph nodes. This injury is often not recognized at the time of surgery and often is only diagnosed postoperatively when the patient develops mediastinitis and an esophagogram is obtained.²

Conclusion

Mediastinoscopy is a valuable technique to obtain biopsies of benign or malignant lymph node diseases involving the nodes in the visceral compartment of the mediastinum. The value of mediastinal staging in the management of cancer of the lung cannot be underestimated. The detection of early stages of cancer only increases the survival rate. Knowledge of the anatomy of

Table 2 Lymph nodes and their locations

Superior Mediastinal Nodes

1. Highest Mediastinal
2. Upper Paratracheal
3. Pre-vascular and Retrotracheal
4. Lower Paratracheal (including Azygos Nodes)
N2=single digit, ipsilateral
N3=single digit, contralateral or supraclavicular

Aortic Nodes

1. Subaortic (A-P window)
2. Para-aortic (ascending aorta or phrenic)

Inferior Mediastinal Nodes

1. Subcarinal
2. Paraesophageal (below carina)
3. Pulmonary Ligament

N1 Nodes

1. Hilar
2. Interlobar
3. Lobar
4. Segmental
5. Subsegmental

the mediastinal area and the potential for bleeding in this area are crucial for the surgical technologist to appreciate. CME requires a relatively short amount of surgical time, but is not without the potential for serious intraoperative bleeding. The surgical technologist is key in being prepared for “going open” if the case should warrant it.

About the author

Susan Alexander graduated in May 2002 from Springfield Technical Community College, School of Health Science, with an AS degree in surgical technology. She currently works as a surgical technologist at Baystate Medical Center

Instruments, supplies and medications

CME instrument set

mediastinoscope
light carrier
light cord
1 Mayo scissors
1 Metzenbaum scissors
2 curved mosquito
4 Coller
2 Kelly
2 Allis
2 regular right angle
2 short needleholder
2 French-eye needleholder
2 short alligator forceps
2 medium DeBakey tissue forceps
2 short single toothed forceps
2 Adson with teeth
2 Army-Navy
2 Weitlaner
1 small and large straight biopsy punch
1 small and large, angled upward biopsy punch
1 biopsy punch, angled left
1 biopsy punch, angled right
2 mediastinal clip applier
2 short medium litigating clip applier
2 small clip applier
2 Schnid
1 metal suction catheter (Frazier)

Supplies

drapes
basins
pack
prep set
double lumen endotracheal tube
bolster for positioning
22 gauge needle (to remove specimens from biopsy punch)
litigating clips
Lukens traps
ties (Vicryl 3-0)
aspirating needle (spinal)
Surgicel
Gelfoam
Formalin/specimen containers
dressings
light source
suction apparatus
electrosurgical unit

Medications

Marcaine 0.5% with epinephrine

in Springfield, Mass. She is married and has three children, all of whom are in college.

Acknowledgments

I would like to thank professor Kathleen Flynn, who is not only a dedicated educator but also a good friend, and Springfield Technical Community College for having such an outstanding program for Surgical Technology. My sincere thanks to the surgical technologists, doctors, and nurses at Baystate Medical Center and Mercy Medical Center of Springfield, Mass.

References

1. Kaplan JA. *Thoracic Anesthesia*. 2nd edition. New York, Edinburgh, London, Melbourne, Tokyo: Churchill Livingstone; 1991: 337-340.
2. Deslauriers J, Ginsberg RJ, Hiebert CA, McKeenally MF, and Urschel HC. *Thoracic Surgery*. New York, Edinburgh, London, Melbourne, Tokyo: Churchill Livingstone; 1995: 837-840.
3. Shields TW. *Mediastinal Surgery*. Philadelphia, London: Lea & Febiger; 1991: 77-80.
4. *CA A Cancer Journal for Clinicians*. Jan/Feb 2002, Vol. 52/No.1-27.
5. George RB, Light RW, Matthay MA, Matthay RA. *Chest Medicine—Essentials of Pulmonary and Critical Care Medicine*. 2nd edition. New York: Churchill Livingstone; 1990 155-156, 368-369.
6. The Staging of Cancer. www.bmsconcology.com
Accessed 3/25/02
7. Texas Cancer Online. www.jasper-web.com/texas-canceronline/staging.htm Accessed 4/14/02

Editor's note

Interested readers may wish to consult the March 1999 *Surgical Technologist* for a related article, "Bronchoscopy: Diagnosis of Tumors in the Lung."

Cervical mediastinal exploration staging of lung cancer

Earn CE credit at home

You will be awarded one continuing education (CE) credit for recertification after reading the designated article and completing the exam with a score of 70% or better.

If you are a current AST member and are certified, credit earned through completion of the CE exam will automatically be recorded in your file—you do not have to submit a CE reporting form. A printout of all the CE credits you have earned, including Journal CE credits, will be mailed to you in the first quarter following the end of the calendar year. You may check the status of your CE record with AST at any time.

If you are not an AST member or not certified, you will be notified by mail when *Journal* credits are submitted, but your credits will not be recorded in AST's files.

Detach or photocopy the answer block, include your check or money order made payable to AST and send it to the Accounting Department, AST, 6 West Dry Creek Circle, Suite 200, Littleton, CO 80120-8031.

Members: \$6 per CE, nonmembers: \$10 per CE

- Another name for epidermoid bronchogenic cancer is _____.
 - oat cell
 - squamous cell
 - adenocarcinoma
 - large cell
- Frequency of metastasis is less for which type of cancer?
 - oat cell
 - epidermoid
 - adenocarcinoma
 - large cell
- Which stage is mismatched?
 - M = metastases
 - T = size
 - T = target organ
 - N = lymph node
- Grading a tumor involves:
 - scraping it away from normal tissue
 - describing how quickly a tumor multiplies
 - comparing tumor cells to normal cells
 - none of the above
- Which of the following lymph nodes can be accessed by standard mediastinoscopy?
 - subaortic
 - posterior subcardinal
 - anterior mediastinal
 - none of the above
- Which exploration approaches are mismatched?
 - left: interlobar nodes
 - right: N1 nodes
 - left: para-aortic nodes
 - right: subaortic nodes
- A preoperative course of chemotherapy may serve to _____.
 - reduce tumor size
 - decrease risk of respiratory compromise
 - improve maintenance of anesthesia
 - all of the above
- Which position is utilized for CME?
 - Trendelenburg
 - Supine
 - Fowler's
 - lithotomy
- Which intraoperative risk is mismatched?
 - recurrent laryngeal nerve: electrosurgery
 - lymph nodes: excessive traction
 - azygos vein: electrosurgery
 - apical arterial branch: anterior movement of mediastinoscope
- What is a disadvantage of sternotomy upon injury?
 - difficult transition to cardiopulmonary bypass
 - difficulty with definitive pulmonary resection
 - potential esophageal injury
 - all of the above

Cervical mediastinal exploration staging of lung cancer

<input type="checkbox"/> Certified Member	<input type="checkbox"/> Certified Nonmember										
Certification No _____		1	<input type="checkbox"/>	<input type="checkbox"/>	<input type="checkbox"/>	<input type="checkbox"/>	6	<input type="checkbox"/>	<input type="checkbox"/>	<input type="checkbox"/>	<input type="checkbox"/>
Name _____		2	<input type="checkbox"/>	<input type="checkbox"/>	<input type="checkbox"/>	<input type="checkbox"/>	7	<input type="checkbox"/>	<input type="checkbox"/>	<input type="checkbox"/>	<input type="checkbox"/>
Address _____		3	<input type="checkbox"/>	<input type="checkbox"/>	<input type="checkbox"/>	<input type="checkbox"/>	8	<input type="checkbox"/>	<input type="checkbox"/>	<input type="checkbox"/>	<input type="checkbox"/>
City _____ State _____ ZIP _____		4	<input type="checkbox"/>	<input type="checkbox"/>	<input type="checkbox"/>	<input type="checkbox"/>	9	<input type="checkbox"/>	<input type="checkbox"/>	<input type="checkbox"/>	<input type="checkbox"/>
Telephone _____		5	<input type="checkbox"/>	<input type="checkbox"/>	<input type="checkbox"/>	<input type="checkbox"/>	10	<input type="checkbox"/>	<input type="checkbox"/>	<input type="checkbox"/>	<input type="checkbox"/>

Mark one box next to each number. Only one correct or best answer can be selected for each question.