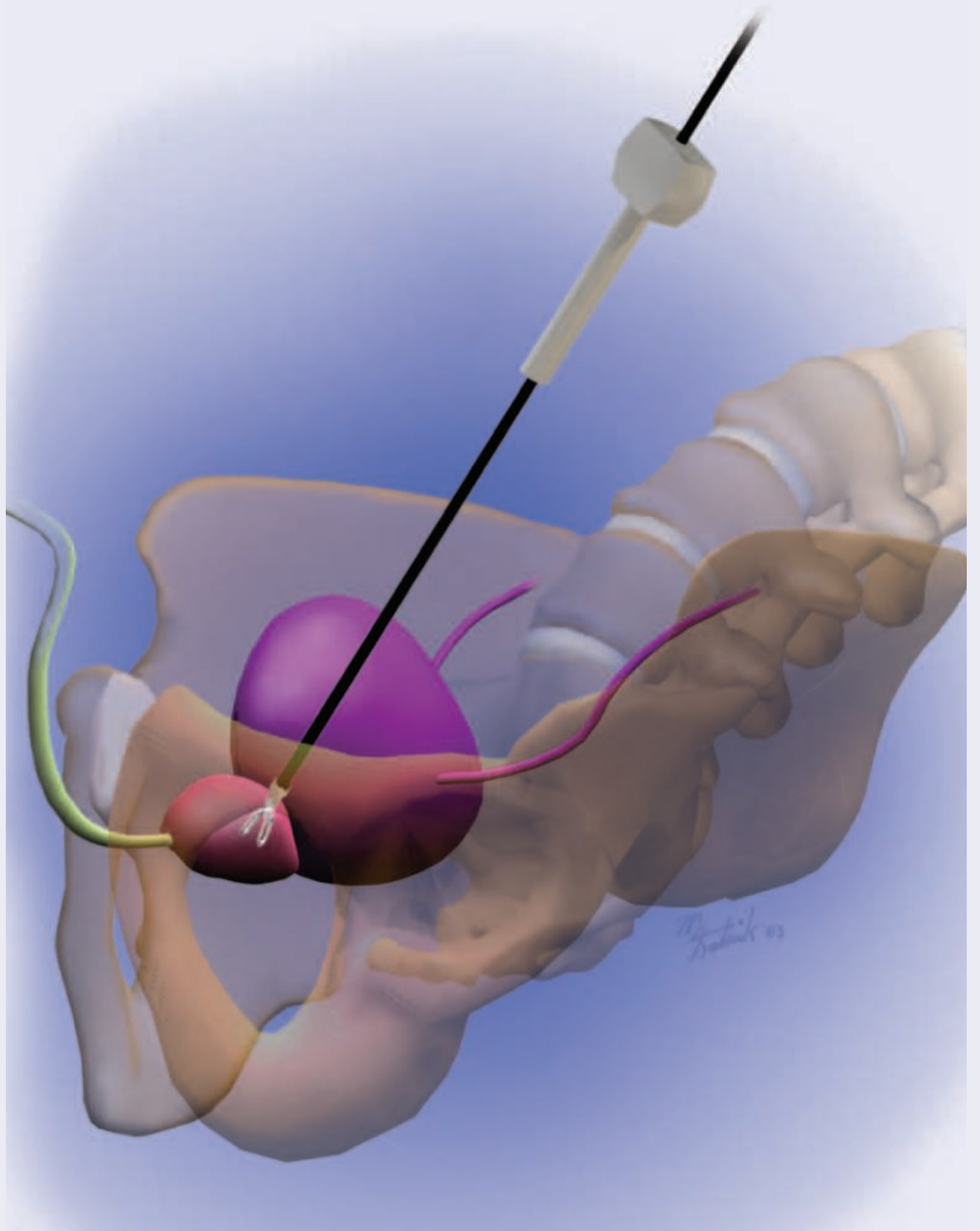

# A ROBOT'S VIEW OF THE PROSTATE

Rebecca Pieknik, CST, BHS

**M**edia coverage, national fund raising efforts and pink ribbons have brought much-needed attention to the fight against breast cancer, raising awareness among women. The male counterpart, prostate cancer, is far more prevalent than the public realizes and doesn't get the same amount of media attention. How prevalent? Prostate cancer accounts for more than 40% of all cancers diagnosed in men, and is considered the number two killer in men second only to skin cancer. One out of every eight men will be diagnosed with prostate cancer in their lifetime. Nearly 350,000 men are diagnosed with prostate cancer each year; approximately 45,000 die annually (one every 13 minutes) of prostate cancer.<sup>5</sup>

Until laparoscopic technologies were available, a standard open radical prostatectomy was often performed, which had many possible com-

plications. Laparoscopic surgery refined the technique for better patient outcomes. Robotic technology has brought additional advantages to the operating table. Laparoscopic instruments were still controlled by hand, and sensitive to the surgeon's hand tremor. Additionally, laparoscopic instruments were less flexible allowing the standard 4 degrees of freedom. Robotic technology eliminates hand tremor and allows a full 6 degrees of freedom, which is less traumatic for tissue and allows greater access for removal of cancerous tissue.

The most apparent difference between a standard open procedure and a computer-controlled laparoscopic procedure involves port incisions instead of abdominal incision.<sup>4</sup> From a patient's standpoint, the most noticeable outcome is the lack of abdominal pain. Patients are fully awake, alert, physically active and eating solid food within four hours of the operation.<sup>4</sup>

## Anatomy

The prostate is a walnut-sized gland that is located below the urinary bladder (Figure 1). It surrounds the urethra and the vas deferens, which conducts sperm to the urethra and passes through the prostate. The glandular cells of the prostate gland add nutrients and fluid to the sperm. The anterior wall of the rectum lies only millimeters behind the prostate gland. The veins of the prostate drain toward the heart via connections that lie alongside the spine, which also lies in close proximity to the prostate gland. Lymph, the watery fluid that is in all tissues, flows away from the prostate through small channels called lymphatic channels to lymph nodes along the wall of the pelvis. Lymph nodes act to filter out bacteria and cancer cells before the fluid flows further upstream toward the veins that eventually empty into the heart.<sup>6</sup>

The cavernous nerves of the male reproduction system control erection and are contained within the neurovascular bundle. This bundle passes across the prostate and adheres fully to it (Figure 1). Any damage to the cavernous nerves could result in impotence and/or incontinence. To preserve the neurovascular bundle, dissecting around the lateral aspect of the seminal vesicles by cold cutting may eliminate damage to the neurovascular bundle. The other method used to preserve the bundle is to transect the lateral pedicle and completely exclude the neurovascular bundle.<sup>3</sup>

## Pathology

Prostatic cancer is a malignant growth of the glandular cells of the prostate gland. Prostate cancer usually grows slowly but may grow rapidly and spread outside the prostate gland. Testosterone, which is produced in the testes, will stimulate the growth of prostate cancer. As the cancer grows, it eventually spreads outside the capsule of the gland and may spread locally to the bladder and seminal vesicles. It also spreads distally to the lymph nodes of the pelvis and to the spine.

Prostate cancer accounts for more than 40% of all cancers diagnosed in men and is the number two killer, second only to skin cancer.<sup>5</sup>

## Unpreventable risk factors of prostate cancer

One of the biggest risk factors of prostate cancer is related to a man's age. Almost 80% of men diagnosed with prostate cancer are 65 years of age or older. Although a few men in their 20s are diagnosed with prostate cancer, 10% to 20% of men in their 30s develop the disease, but by age 50, nearly one out of every three men will have prostate cancer.<sup>5</sup> Family history plays a role in the prostate cancer risk factors. In the United States, the average man's risk for developing prostate cancer ranges from 10% to 15% and the average risk for dying from the disease is 3%. Conversely, if a family member had the disease, the risk of developing prostate cancer doubles.<sup>5</sup> Where you reside can affect your probability of dying from advanced prostate cancer. In the United States, 25% of the men who develop advanced prostate cancer will die from the disease, while in Switzerland the risk jumps to 40%. In Japan, there is a smaller risk of developing prostate cancer, but of those who develop the disease, 33% will die from it.<sup>5</sup> Studies show that testosterone is associated with an increased risk of prostate cancer and a high level of testosterone is thought to accelerate the growth of prostate cancer.

## Preventable risk factors

Men between the ages of 50 to 70 should be screened for prostate cancer. The Digital Rectal Exam (DRE) is done annually during a physical. The physician is looking for irregularities or enlargement of the gland. The prostate specific antigen (PSA) is a blood test that measures the level of an enzyme located in the prostate. Normal levels of PSA are 0 to 4.

The environment also plays a role in prostate cancer. For example, when a man moves from one country to another, he will develop the risk of his adopted nation.<sup>5</sup> A diet high in saturated fat and low in fiber could increase the risk of prostate cancer. Studies link the fast growth of prostate tumors to diets of high fat.<sup>5</sup> Jobs in certain fields, such as water treatment, aircraft manufacturing, railway transport, utilities, farming, fishing and forestry are associated with an increased risk of prostate cancer.

## Gleason Grading System

Prostate cancer is commonly evaluated using the Gleason Grading System (Figure 2).<sup>5</sup> This system is a method of describing the cancer based on how the cells look and how they are arranged from a biopsy. With this tissue sample, the pathologist will use Gleason's System to determine how fast the cancer is growing. The surgeon will take samples of the cancer tissue and assign a score of 1-5 to the two largest samples.<sup>5,6</sup> The sum of these two numbers is used for prognosis.

### Grade 1-2

- Least aggressive

### Grade 3

- Seldom has metastases

### Grade 4-5

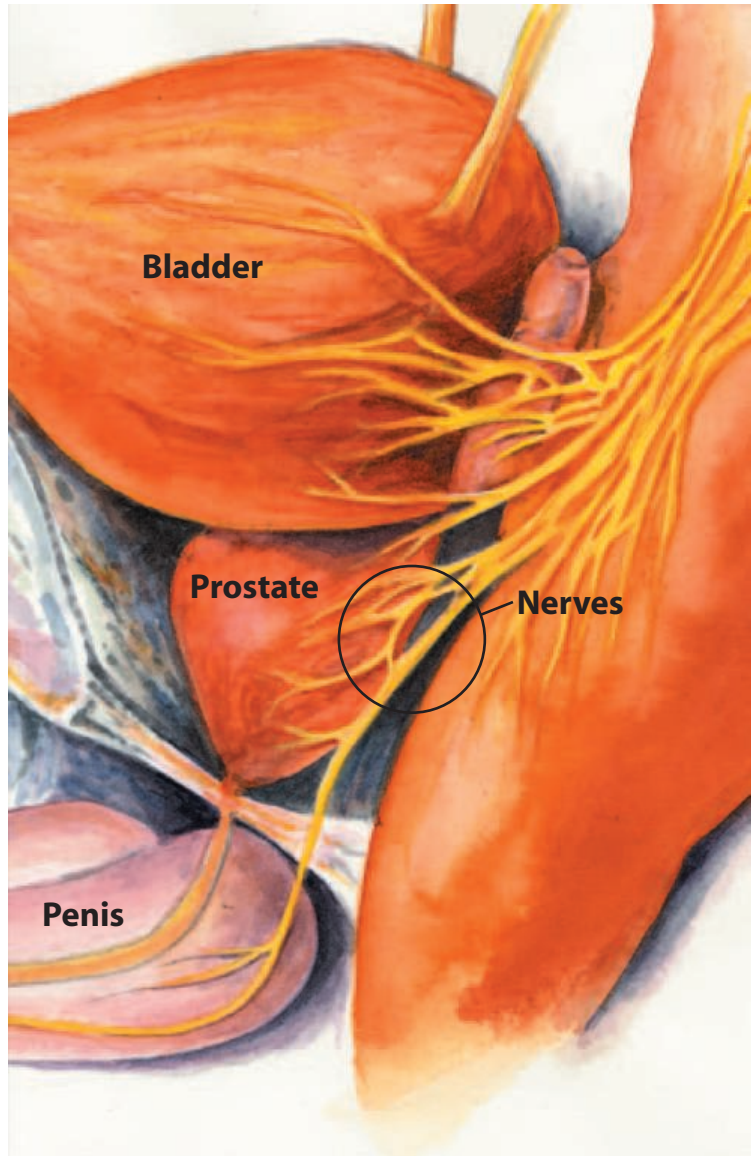
- Commonly has metastases

### Scores:

- 2-4 low-grade tumor
- 5-7 intermediate-grade tumor
- 8-10 high-grade tumor

A low-grade tumor (Gleason sum of 2-4) has normal looking cells and grows slower, whereas a high-grade tumor (sum of 8-10) has very abnormal cells and is more likely to spread outside the prostate. The treatment options vary and are based on age, tumor grade and the degree of metastasis. Several other tests will be performed to determine the spread of the disease.<sup>6</sup>

- *Bone Scan.* A small amount of radioisotope is injected into the bloodstream and absorbed into the bones in the areas affected by the cancer. The spine is the most common site outside of the pelvis for the cancer to metastasize.
- *CAT (computerized axial tomography) scan.* This test examines the inside of the body through the creation of computerized X-ray images. A CAT scan of the pelvis may demonstrate enlargement of the prostate gland or pelvic nodes.



- *MRI (magnetic resonance imaging) scan.* This test will create a detailed computerized image of the internal organs and bones by identifying the changes in the tissue molecules when subjected to a strong magnetic field.

### Staging cancer

Once the cancer is graded, it will be staged to determine how far it has spread. The Jewett-Whitmore staging system uses the letters ABCD to describe the different stages.<sup>5,6</sup>

- A The tumor is localized and is usually found during a procedure unrelated to cancer.  
A1 = Cancer is small and low grade

## FIGURE 1

The neurovascular bundle passes across the prostate. Damage leads to impotence and incontinence.

A2 = Cancer is high grade or throughout the specimen.

**B** The tumor is still localized but was found by DRE, elevated PSA or other method used to detect cancer.

B1 = Cancer is limited to one side of the prostate.

B2 = Cancer is on both sides.

**C** The tumor has spread beyond the prostate and could be in other structures near the prostate.

**D** The tumor has spread far beyond the prostate to lymph nodes, bone, lungs or other organs.

D1 = Cancer is spread to only pelvic lymph nodes.

D2 = Cancer has spread to bones.

The TNM (tumor, nodes, metastasis) staging system has been adopted by the American Joint Committee on Cancer and the International Union against Cancer.<sup>6</sup>

Primary tumor (T)

- TX = Primary tumor cannot be assessed.
- T0 = No evidence of primary tumor.
- T1 = Clinically not apparent tumor, not palpable on rectal exam or visible by imaging.
  - T1a. Tumor is incidental finding in 5% or less of tissue resected for benign enlargement of the prostate.
  - T1b. Tumor incidental finding in more than 5% of resected tissue.
  - T1c. Tumor identified by needle biopsy (elevated PSA).
- T2 = Tumor confined in prostate.
  - T2a. Tumor involves one lobe of prostate.
  - T2b. Tumor involves both lobes.
- T3 = Tumor extends through the prostatic capsule.
  - T3a. Extension through capsule on one or both sides.
  - T3b. Tumor invades adjacent seminal vesicle(s).
- T4 = Tumor is fixed or invades adjacent structures other than seminal vesicles such as

the bladder neck, rectum, pelvic muscles or pelvic wall.

Regional lymph nodes (N).

- NX = Regional lymph nodes cannot be assessed.
- N0 = No regional lymph node metastasis.
- N1 = Metastasis present in regional lymph nodes(s).

Distant Metastasis

- MX = Distant metastasis cannot be assessed.
- M0 = No distant metastasis.
- M1 = Distant Metastasis
  - M1a. Beyond regional lymph nodes.
  - M1b. To bone(s).
  - M1c. To other site(s).

### Surgical treatment options

The standard open radical prostatectomy is indicated for patients where the cancer is confined to the gland.<sup>4</sup> Once the cancer has spread outside the prostate gland, the chance of totally removing the tumor is reduced. There are many disadvantages to the standard radical prostatectomy. The average length of surgery for the radical prostatectomy is three hours. Over 85% of patients required blood transfusions due to loss of blood during the procedure. 24% of the patients had positive margins. This percentage is indicative of the possibility of the cancer reoccurring because the removal of the entire cancer was not achieved. The goal of surgery would be to have this percentage as low as possible. Two percent of patients were totally incontinent due to the surgery and only one-third regained potency or returned to baseline.<sup>6</sup>

There are several possible complications to the radical prostate surgery.<sup>4</sup>

- Excessive hemorrhage. The prostate is surrounded with many blood vessels that easily bleed during surgery. Extensive blood loss is the reason for blood transfusion.
- Impotence. Because of the involvement of the nerves surrounding the prostate, the patient may not be able to have an erection.

## Table 1 Instrumentation and Equipment

### Urology instruments

- Urology extras
- Standard laparotomy retractors
- Laparoscopic nephrectomy Set
- Dull towels clips—nonpiercing
- Warming thermos
- Male urethral sounds
- Da Vinci™ system-camera, insufflator, monitor(s)
- Allen-style stirrups
- Lenses
- Light table

### Supplies

- Abdominal tray
- Skin marker
- 1000 cc pitcher
- Urinary drainage bag
- Sterile specimen cup
- 10 cc syringe
- 20 cc syringe
- Intuitive EndoWrist® Prograsp
- Intuitive large needle driver
- Intuitive Debakey forceps
- Intuitive Cautery Hook
- Intuitive Cadiere Forceps
- Intuitive Ultrasonic Shears
- Da Vinci™ Accessory Sets 1 & 2
- #400077 single use cannula seal x 2
- #400016 da Vinci™ Instrument Arm drape x 2
- #500027 da Vinci™ camera drape
- Steri drape w/long drape
- 22 Fr. 30cc Foley Catheter x 2
- Hem-o-lok® clips (green & purple)
- OneSeal Reducer Cap x 2
- Applied Medical scope warmer seal
- Hem-o-lok® applier
- Catheter plug
- Suction irrigator tubing
- Insufflator tubing
- SGT 5 & 10 mm suction irrigator tip
- SGT Verres needle
- LIGACLIPS®
- Endoscopic knitters

- 5 mm VersaPort® x 2
- ENDOPATH® trocars/cannulas
- ENDOPOUCH® specimen retrieval bag
- 10 mm Laparoscopic Babcock
- Bougie

### Suture

- 2-0 VICRYL® CT1 x 4
- 2-0 VICRYL® CT2 x
- 0 VICRYL® CT1 x 4
- 4-0 MONOCRYL® x 2
- 2-0 VICRYL® UR6 x 2
- 2-0 VICRYL® RB1 x 5 (needed for anastomosis)
- 2-0 VICRYL® RB1 9-inch double armed

### Blades

- #15, #10 and #11

### Prep

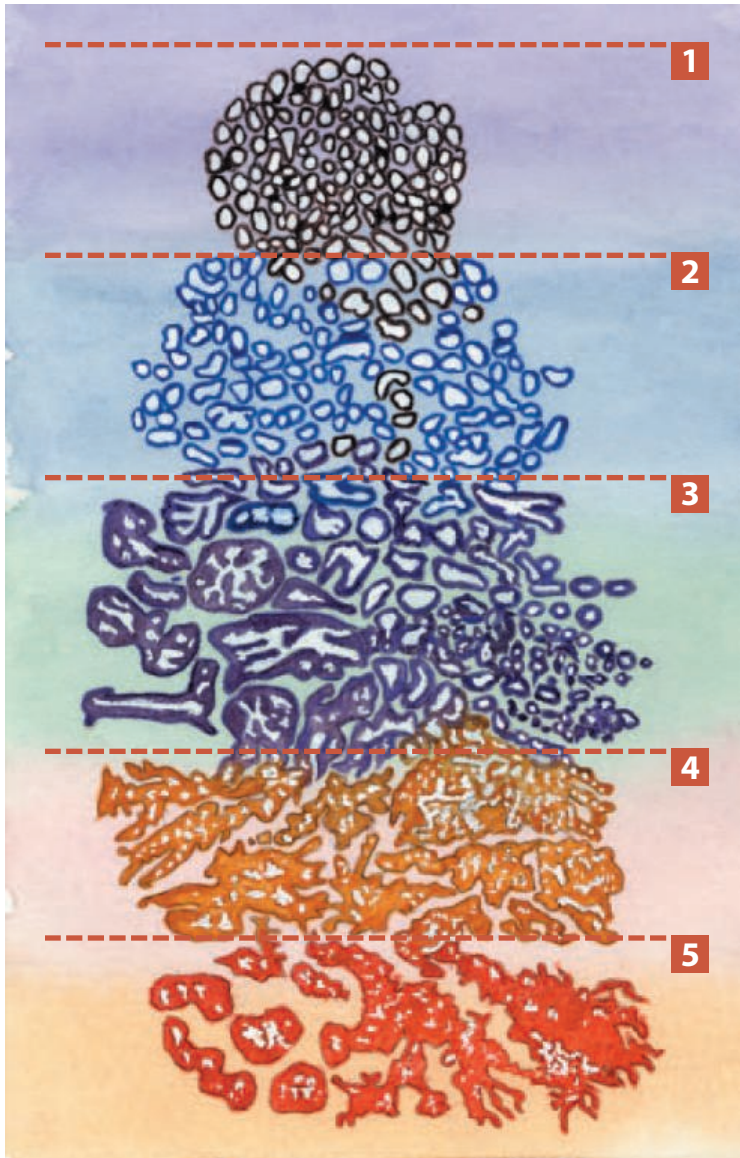
- Scrub prep solution
- Betadine® soap & prep

### ESU Setting

- 30/30

### Medications

- Surgilube®



**FIGURE 2**  
 Histologic grades  
 of prostatic adeno-  
 carcinoma shown  
 by the Gleason  
 Grading System.

- Incontinence. Damage to the neurovascular bundle during surgery can lead to injury of the nerves.
- Bladder Neck Contracture. This may occur due to the scar tissue when the urethral stump is sutured to the bladder.
- Infection. The increase chance of infection is due to the close proximity of the prostate to the rectum.
- Tear into the rectum. This occurs from the close proximity of the rectum to the prostate gland. If this occurs, the patient will require a colostomy during the healing process.
- Deep vein thrombosis (DVT). Blood clots may develop in the legs or deep pelvic veins.

This can be dangerous because the clot may break loose and travel to the lung.

The first laparoscopic prostatectomy was performed in 1992.<sup>2</sup> The laparoscopic edge to the prostatectomy is the fact that the doctors can more easily view the prostate through a camera that will magnify the organ.<sup>2</sup> Robotics have refined this surgery. Where laparoscopic instruments were controlled by hand, and sensitive to the surgeon's hand tremor, robotic instruments eliminate the hand tremor. Where laparoscopic instruments allowed only 4 degrees of freedom, robotic instruments allow a full 6 degrees of freedom.

The da Vinci™ surgical system is the first totally "intuitive" laparoscopic surgical robot in existence.<sup>6</sup> It is the first operative robot endorsed by the United States Food and Drug Administration (FDA). Da Vinci has been cleared by the FDA for several different surgical specialties, such as GYN, cardiovascular as well as urology. Over 115 surgical systems are currently in use throughout the United States, Europe and Japan. Frederic Moll, MD, Robert Younge, and John Freund, MD, built Intuitive Surgical in 1995. The system is based on foundational robotic surgery technology developed at SRI International (Stanford Research Institute).<sup>7</sup>

Michigan has three hospitals that currently use the da Vinci Robotic System: the University of Michigan Health Center in Ann Arbor, William Beaumont Hospital in Royal Oak and the Henry Ford Health System in Detroit, Michigan. The Henry Ford Health System, in conjunction with the Vattikuti Institute at Henry Ford has become a world leader in the treatment of prostate cancer. The American Medical Group Association (AMGA) recently awarded the Henry Ford Medical Group the top quality prize for its innovative prostate cancer program. The Prostate Cancer Options Program (PCOP) at Henry Ford is intended to enable patients to be more active in the decision making process of their treatment options concerning prostate cancer. According to Mani Menon, MD, Director of the Vattikuti Urological Institute, more than

40% of his patients that undergo a prostatectomy are requesting the da Vinci surgical system.<sup>1</sup>

Menon spent two years in France fine tuning his skills. Since then, Dr Bertrand Guillonnet, one of the team leaders at the Institut Montsouris in Paris, has traveled to Detroit to oversee Menon's first cases of the computer-assisted prostatectomy.<sup>2</sup>

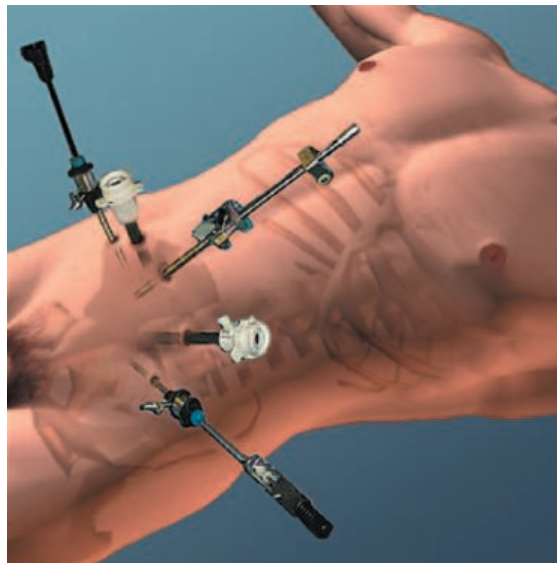
### Operative procedure

The da Vinci Robotic System is set up prior to the patient being brought into the room. The instrument arms are draped and then covered with a 3/4 sheet to prevent contamination. The patient is brought into the room and transferred from the stretcher to the operating table. The patient is placed in a supine position with arms tucked at the sides. The legs are placed in stirrups and spread apart to provide access to the urethra and anus area. The abdomen is shaved from the costal margins to the pubic bone. The abdomen, penis, scrotum, upper thighs and perianal region are prepped with Betadine® scrub and draped for a laparoscopic procedure with the legs draped separately. A 22 Fr Foley catheter and rectal bougie are inserted.

Three ports are needed for the da Vinci Surgical System, two assistive ports and a port in the umbilicus. Pneumoperitoneum is created with the use of a Veress needle and CO<sub>2</sub> is introduced to a pressure of 15mm Hg. Six puncture incisions are made with a #11 blade on a #3 knife handle. A 12 mm port is inserted in the umbilicus for placement of the binocular scope. Two eight mm ports are inserted for the da Vinci instrument arms approximately 10-12 cm from the midline just below the camera port; two 5 mm ports for assistive instrumentation and one 10 mm port for removal of the prostate are placed under direct vision with a 30 degree lens. The left instrument arm cannula is inserted between the left anterior superior iliac spine and the endoscopic port along the mid-clavicular line. The right instrument arm cannula is placed between the umbilicus and the anterior inferior iliac spine along the mid-clavicular line. Care should be taken to avoid injury to the inferior

epigastric vessels. To prevent external instrument interferences there should be a minimum distance of 8 cm between the endoscopic cannula for each of the da Vinci instruments' arms. Once the ports are all placed, the surgeon will break scrub and sit at the stereoscopic console to direct and guide the robotic arms.

The patient should be placed in a 20° Trendelenburg before the da Vinci surgical cart is rolled into place. The surgical cart should be positioned so that the surgical cart column, the endoscopic arm and the endoscopic port are aligned in a straight line. The surgical cart column will be placed between the legs of the patient. The base of the surgical cart will straddle



the base of the operating table. Once the cannulas are in place and the patient is in the Trendelenburg position, the colon and small bowel should be retracted and repositioned away from the pelvis using laparoscopic instruments.<sup>4</sup>

The extra peritoneal space is entered through a transverse peritoneal incision that is made from the left and extended to the right medial umbilical ligament. This incision is extended through an inverted U to the level of the vasa on either side. This will expose the vasa, which is then transected. The seminal vesicles are identified and freed from their attachments and vasculature. The seminal vesicles are retracted anteriorly and Denonviller's fascia is tented and

### FIGURE 3

Port placement for laparoscopic prostatectomy. An extra port is utilized with the da Vinci system.

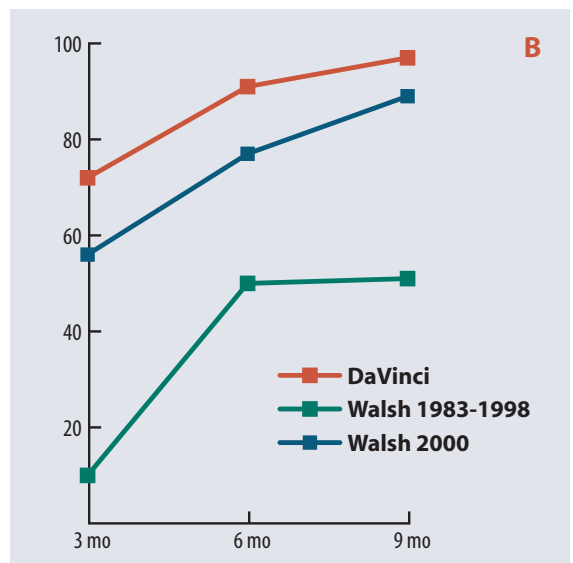
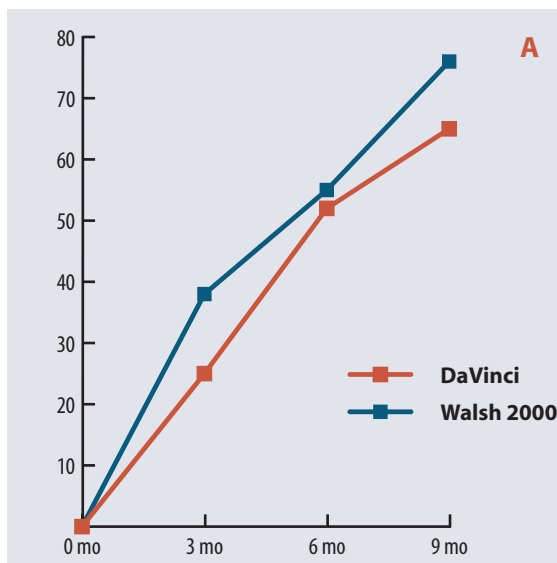


incised. This will expose the plane directly behind the prostate, which will allow the tissue plane to be extended inferiorly. The instrument arms will move to the retropubic space of Retzius to continue the operation. The bladder is distended with normal saline, so its contours can be easily identified and the peritoneum is incised. The areolar tissue around the bladder is then easily dissected, causing the bladder to drop posteriorly. The bladder is then emptied. The Foley catheter remains inserted.<sup>4</sup>

Once all superficial and dorsal prostatic veins are coagulated; the fat over the Fascia of Zuckerkandl covering the prostate is resected or swept aside. The endopelvic fascia is incised, exposing

margin for subsequent urethrovisceral anastomosis. The Foley catheter is removed, and the posterior face of the bladder neck is exposed with a bladder mucosal incision.<sup>4</sup>

The surgeon will then need to expose the prostatic pedicles. The vas deferens and seminal vesicle are grasped through the space between the prostate and the posterior bladder neck and pulled up to expose the pedicle to be incised. Once the pedicles are transected, the surgeon will identify the neurovascular bundle. In order to preserve the bundle, a lateral incision is made in the visceral fascia that covers the peri-bundle fat. Caутery should not be used near the neurovascular bundle, as thermal damage to the



**FIGURE 4**

- Ⓐ Return of potency
- Ⓑ Return of continence

the levator ani muscles. The puboprostatic ligaments may be incised. The dorsal complex can then be ligated with a 2-0 absorbable suture passed with a curved needle from one side to the other.<sup>4</sup>

To identify the bladder neck, the anterior prevesical fat is retracted superiorly that causes an outline of the prostatovesical plane. The plane is acknowledged through sharp and blunt dissection. The urethra is identified, and the anterior wall is incised to expose the Foley catheter. The catheter balloon is then deflated and the catheter is pulled up and into the abdomen to expose the lateral and posterior bladder neck, which is incised precisely maintaining a clean detrusor

neurovascular bundle may cause impotence or incontinence. The neurovascular bundle is transected from the base of the prostate to their entrance in the pelvic muscular floor that is posterolateral to the urethra. The dorsal vein is ligated with 2-0 absorbable suture and retracted anteriorly to expose the anterior urethral wall that is also incised. The back wall of the urethra is incised with a laparoscopic cold knife. Gentle traction is applied to the prostate, positioning it superiorly. The rectourethralis is divided.<sup>4</sup>

The anastomosis is completed with interrupted sutures. The anastomosis is accomplished with a 2-0 RB1 9-inch double-armed absorbable suture on a curved needle. The first two sutures

are placed at the 5 and 7 o'clock positions going from the inside out of the urethra and outside in on the bladder neck. The two sutures are tied inside the urethral lumen. Four other sutures are symmetrically placed at 4 and 8, then 2 and 10 o'clock and tied outside the lumen. The final stitches are placed at 1 and 11 o'clock and tagged. The Foley catheter is inserted and the correct position is checked. The final two sutures are tied without compromising the catheter.<sup>4</sup>

An ENDO CATCH™ is passed through the 10 mm port. The specimen is placed in the sac and removed. The abdominal pressure is lowered to 5 mm Hg to check for bleeding. A Jackson-Pratt drain is passed to the pelvis and sutured to the skin. The remaining trocars are removed and the incisions are closed with a 4-0 Monocryl and dressed.

## Conclusion

With consent of the laparoscopic procedure, the patient should understand there is a risk of converting to an open procedure. It will become necessary to convert in the event of major bleeding, rectal or ureteral injury, or problems with the urethrovesical anastomosis.<sup>5</sup>

Complications of the daVinci prostatectomy are minimal compared to the standard open radical prostatectomy. Perioperative complications include a port-side hernia, hematomas, constipation or DVT.

The major advantage of the robotic laparoscopic prostatectomy is the postoperative recovery for the patient.<sup>4</sup> With the elimination of an abdominal incision, parenteral analgesics and/or epidural analgesia are not needed.<sup>5</sup> The means the patient is more alert and able to function more quickly (Figure 4). The patient will usually go home within 24 hours excluding any complications without any restrictions.

International studies of more than 800 patients confirm that a laparoscopic prostatectomy is as effective as the standard radical prostatectomy for treating prostate cancer.<sup>5</sup> The radical prostatectomy is considered one of the most successful therapies, as 85% of men will still cancer free after 10 years.<sup>1</sup>

## About the author

Rebecca Pieknik, CST, BHS, is the program director for the Surgical Technology Program at Oakland Community College, William Beaumont Hospital, Royal Oak, MI. In addition, she is pursuing a master's of science degree in bioethics from Albany Medical College/The Graduate University of Union College.

## References

1. Anstett, Patricia. Computer-driven tools do operation. Detroit Free Press. July 17, 2001. [www.freep.com/news/health/robot17\\_20010717.htm](http://www.freep.com/news/health/robot17_20010717.htm) Accessed 11/17/03.
2. Ansett, Patricia. Computer-age prostate surgery: High-tech procedure is less invasive and less painful. Detroit Free Press. July 17, 2001. [www.freep.com/news/health/pros17\\_20010717.htm](http://www.freep.com/news/health/pros17_20010717.htm) Accessed 11/17/03.
3. Gill IS and Zippe CD. Laparoscopic Radical Prostatectomy Now Mirrors Open Techniques. Urology News. The Cleveland Clinic. May 7, 2003. [www.clevelandclinic.org/urology/news/laparo/vol8b.htm](http://www.clevelandclinic.org/urology/news/laparo/vol8b.htm) Accessed 11/17/03.
4. Krongrad A. January 27, 2003. *Laparoscopic Radical Prostatectomy*. Krongrad Urology. [www.krongrad-urology.com/review.htm](http://www.krongrad-urology.com/review.htm) Accessed 11/17/03.
5. Moyad MA and Pienta KJ. *The ABC's of Advanced Prostate Cancer*. Chelsea, MI: Sleeping Bear Press; 2000.
6. Prostatectomy. Yoursurgery.com. [www.yoursurgery.com?ProcedureDetails.cfm?BR=7&Proc=41](http://www.yoursurgery.com?ProcedureDetails.cfm?BR=7&Proc=41) Accessed 1/27/03.
7. Intuitive Surgical. [www.intuitivesurgical.com/products/da\\_vinci.html](http://www.intuitivesurgical.com/products/da_vinci.html) Accessed 11/17/03.

*DaVinci Robotic Surgical System™ is a trademark of Intuitive Surgical. LIGACLIP®, ENDOPOUCH® and ENDOPATH® are registered trademarks of Ethicon Endo-Surgery. VICRYL® and MONOCRYL® are registered trademarks of ETHICON, Inc. VersaPort® is a registered trademark of US Surgical.*

# A robot's view of the prostate

### Earn CE credit at home

You will be awarded one continuing education (CE) credit for recertification after reading the designated article and completing the exam with a score of 70% or better.

If you are a current AST member and are certified, credit earned through completion of the CE exam will automatically be recorded in your file—you do not have to submit a CE reporting form. A printout of all the CE credits you have earned, including Journal CE credits, will be mailed to you in the first quarter following the end of the calendar year. You may check the status of your CE record with AST at any time.

If you are not an AST member or not certified, you will be notified by mail when *Journal* credits are submitted, but your credits will not be recorded in AST's files.

Detach or photocopy the answer block, include your check or money order (\$6 for members or \$10 for nonmembers) made payable to AST and send it to the Accounting Department, AST, 7108-C South Alton Way, Centennial, CO 80112-2106.

- Which of the following risk factors doubles a man's risk of developing prostate cancer?
  - age over 65 years
  - family member with the disease
  - place of residence
  - frequent intercourse
- Which is not a screening test for prostate cancer?
  - DRE
  - PSA
  - EPT
  - None are screening tests
- Which is not a preventable risk factor for prostate cancer?
  - area of residence
  - diet
  - type of employment
  - age
- Which is mismatched?
  - Gleason Grade 5:metastasis
  - Gleason sum 3:low-grade tumor
  - Gleason sum 6:least aggressive
  - Gleason sum 9:high-grade tumor
- Which is mismatched?
  - Stage A:localized tumor
  - Stage B2:cancer is limited to one side of prostate
  - Stage C:Tumor spread to structures near the prostate
  - Stage D2:Cancer spread to bones
- Complications of radical prostate surgery include:
  - excessive hemorrhage
  - incontinence
  - impotence
  - all of the above
- Robotics provide an advancement over laparoscopic surgery because:
  - reduces hand tremor
  - allows greater degrees of freedom
  - allows greater flexibility of movement
  - all of the above
- How many ports are needed for this robotic surgery?
  - 3
  - 2
  - 4
  - 6
- Cautery should not be used near the \_\_\_\_\_.
  - areolar tissue and bladder
  - neurovascular bundle
  - pedicles
  - fascia of Zuckerkindl
- With robotic surgery, the patient will be hospitalized approximately \_\_\_\_\_.
  - 72 hours
  - 48 hours
  - 36 hours
  - 24 hours

## A robot's view of the prostate

		a	b	c	d		a	b	c	d
<input type="checkbox"/> Certified Member	<input type="checkbox"/> Certified Nonmember	1	<input type="checkbox"/>	<input type="checkbox"/>	<input type="checkbox"/>	6	<input type="checkbox"/>	<input type="checkbox"/>	<input type="checkbox"/>	<input type="checkbox"/>
Certification No _____		2	<input type="checkbox"/>	<input type="checkbox"/>	<input type="checkbox"/>	7	<input type="checkbox"/>	<input type="checkbox"/>	<input type="checkbox"/>	<input type="checkbox"/>
Name _____		3	<input type="checkbox"/>	<input type="checkbox"/>	<input type="checkbox"/>	8	<input type="checkbox"/>	<input type="checkbox"/>	<input type="checkbox"/>	<input type="checkbox"/>
Address _____		4	<input type="checkbox"/>	<input type="checkbox"/>	<input type="checkbox"/>	9	<input type="checkbox"/>	<input type="checkbox"/>	<input type="checkbox"/>	<input type="checkbox"/>
City _____ State _____ ZIP _____		5	<input type="checkbox"/>	<input type="checkbox"/>	<input type="checkbox"/>	10	<input type="checkbox"/>	<input type="checkbox"/>	<input type="checkbox"/>	<input type="checkbox"/>
Telephone _____										

Mark one box next to each number. Only one correct or best answer can be selected for each question.