

Avascular Necrosis of Femoral Head:

DIAGNOSIS TO TREATMENT

ROBERT DOHENY, CST

Avascular necrosis (AVN) is a disease resulting from a temporary or permanent loss of blood supply to the bones. It generally affects people between the ages of 30 and 50 years of age. This disease is also known as osteonecrosis, aseptic necrosis and ischemic bone necrosis. Avascular necrosis is the death of the bone marrow cells due to ischemia. In some cases, the bone will collapse. It affects the epiphysis of the long bones and is most commonly seen in the femur.

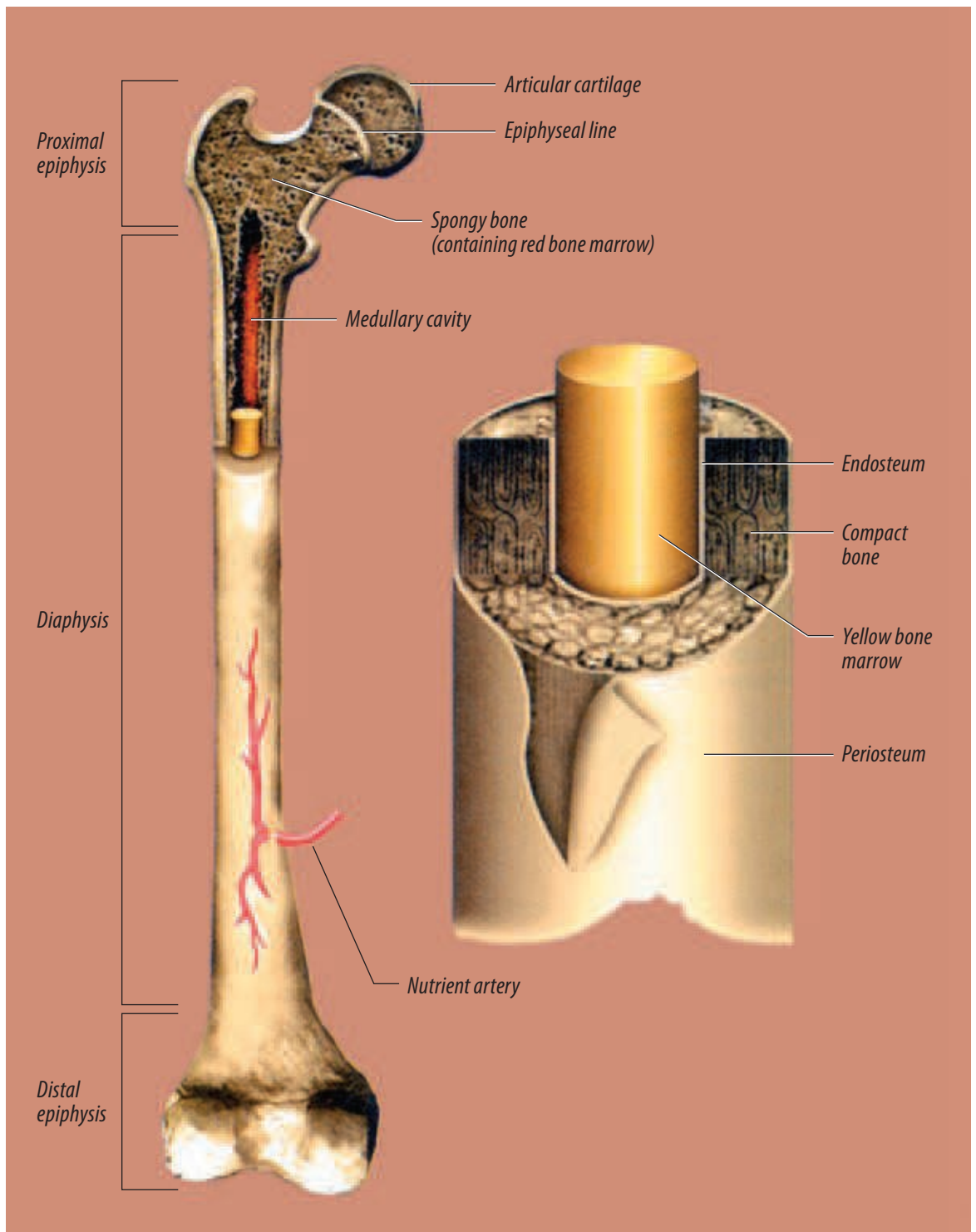
SYMPTOMS

Avascular necrosis of the femoral head presents with groin pain that radiates down the anteromedial thigh. Some patients may demonstrate a limp and/or limited range of motion in flexion, abduction and internal rotation. Pain is sometimes induced by standing, walking, moving or other mechanical stress. It's usually relieved by rest.

CAUSES

Avascular necrosis has several causes. Trauma is the most common cause of AVN. It can occur within eight hours after a traumatic injury. Types of trauma associated or leading to AVN include:

- Fracture of the femoral neck
- Slipped capital femoral epiphysis
- Proximal femoral epiphysiolysis
- Dislocated femoral head
- Epiphyseal compression
- Vascular trauma
- Radiation exposure
- Chronic renal failure



Reprinted from *Surgical Technology for the Surgical Technologist: A Positive Care Approach*, Thomson-Delmar Learning, ©2004

FIGURE 1:
Structure of long bones.

The two most common etiologies of atraumatic avascular necrosis are alcohol consumption and long-term use of corticosteroids. Excessive alcohol consumption may have a toxic effect on osteogenic cells. Alcohol intake increases the risk of AVN more than 11 times, because alcohol causes an increase in the amount of fat within bones. The extra fat may squeeze the surrounding blood vessels, which causes reduction of blood flow to the bones. This eventually leads to the death of the bone.

Corticosteroids, such as prednisone, are commonly used to manage diseases that cause inflammation, including lupus, rheumatoid arthritis and irritable bowel disease. Possible side effects of long-term use include osteoporosis and AVN. Supplements of calcium and vitamin D may be prescribed to counteract these side effects. The estimated incidence of necrosis among long-term users is 3–4%.

The use of long-term steroids is associated with 35% of all cases of atraumatic avascular necrosis. Corticosteroid-related avascular necrosis is more severe and more likely to affect both hips than noncorticosteroid-related AVN. The use of alcohol and corticosteroids can also lead to increased levels of fat in the blood, called hyperlipidemia.

AVN is also a side effect of other conditions, including Gaucher's disease (a lipid storage disease characterized by an accumulation of fatty material in the liver, spleen, kidneys, lungs, brain and bone marrow), pancreatitis, chemotherapy, hemodialysis, and blood disorders, such as sickle cell anemia.

DIAGNOSIS

A complete physical exam by a physician, including blood work, family history, history of alcohol and/or long-term steroid use, as well as AP and lateral X-rays of the affected bone, is the first step in identifying AVN. The necessary blood work should include a CBC with differential. This test would identify any abnormalities, such as inflammation, acute or chronic infection, and autoimmune disease. A cholesterol work-up may also be necessary to check on the amount of lipids in the blood. If the films show the presence of AVN, a series of additional imaging exams may

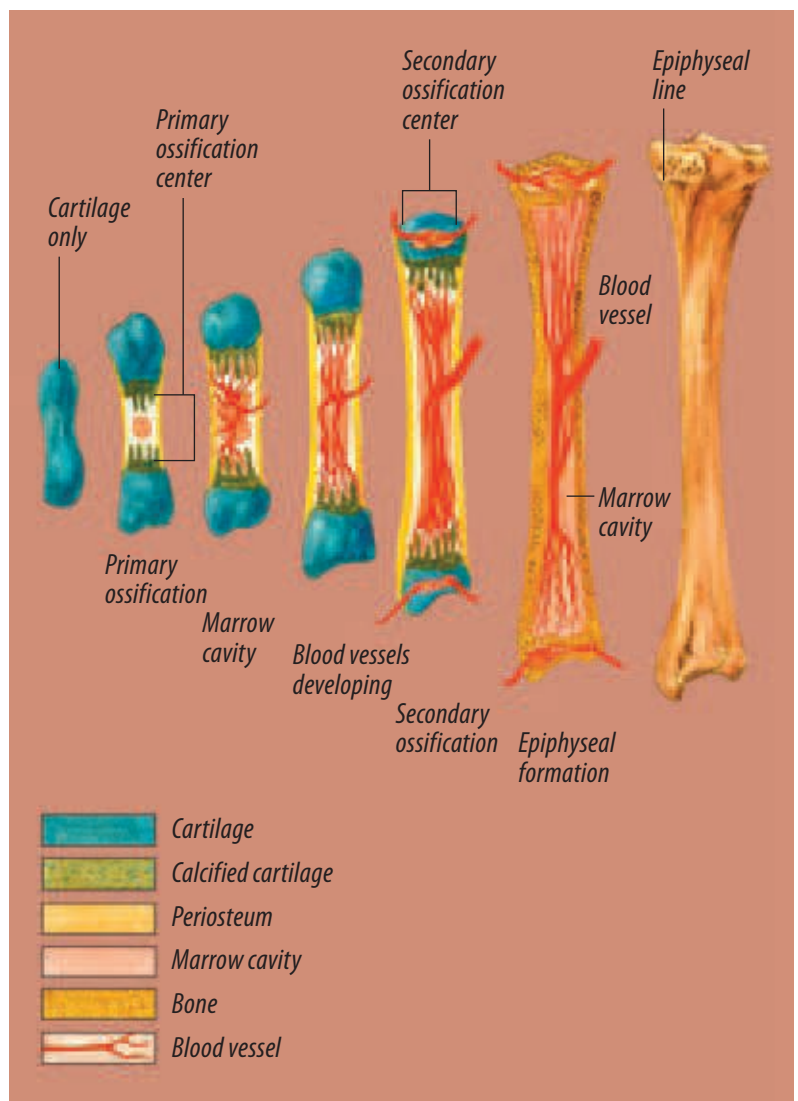


FIGURE 2: Progression of bone growth.

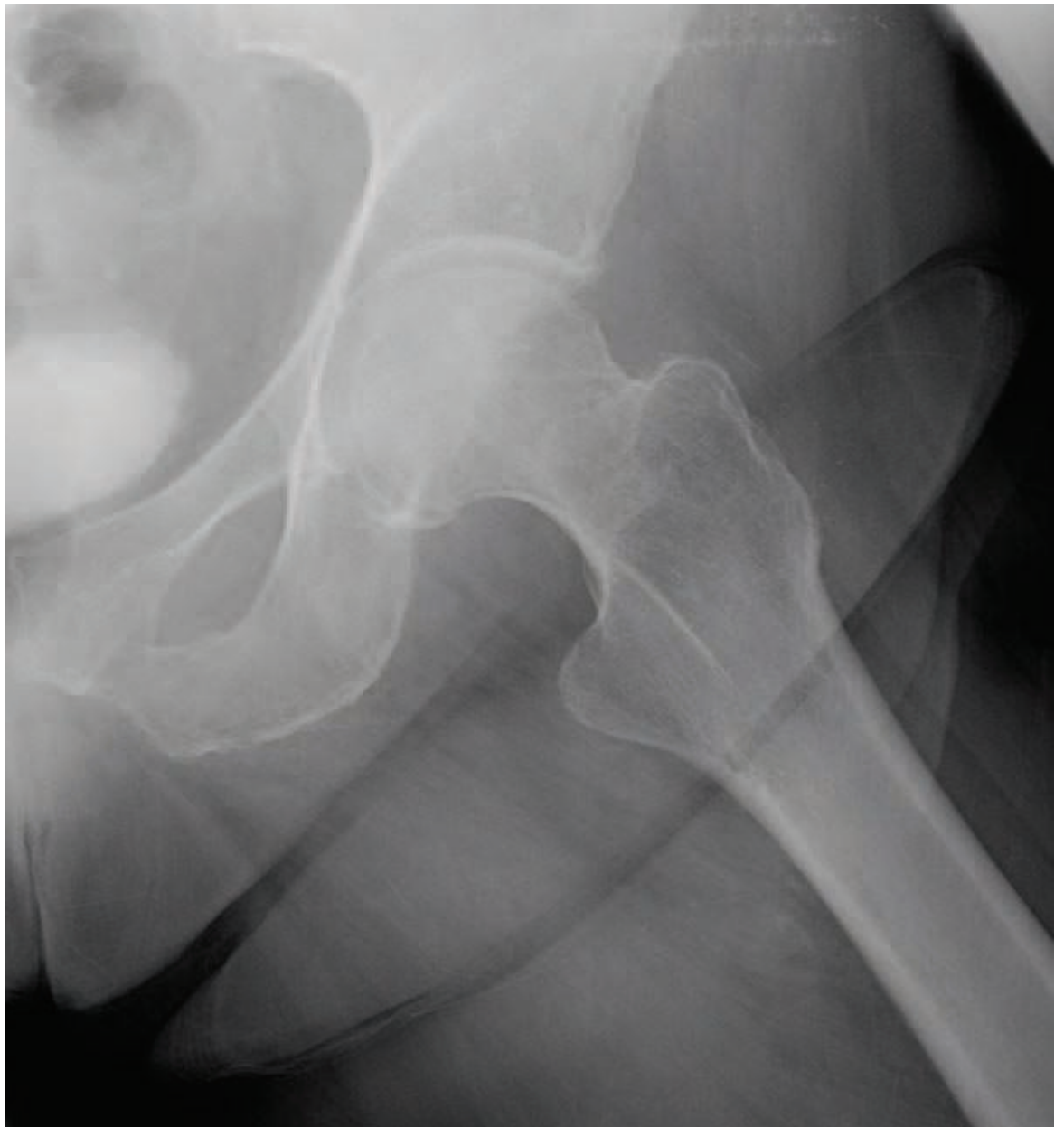be performed. The tests listed here can be used to determine the amount of bone affected, as well as the progression of the disease.

- X-ray (See Figure 3.)
- Magnetic resonance imaging (MRI) (See Figure 4.)
- Bone scan (also known as scintigraphy)
- CT scan

AVN is classified by five stages through the use of normal radiological clinical findings. This specific staging system was developed by Marvin Steinberg, MD, and remains the most comprehensive and practical classification system for AVN.

FIGURE 3:

X-ray shows left hip with avascular necrosis.



Each stage identifies and explains the pathological progress and the severity of the disease.

- **Stage 1:** Cell death; undetectable by plain films
- **Stage 2:** Cell modulation; characterized by localized osteoporosis
- **Stage 3:** Development of the margin of dead bone; appears sclerotic
- **Stage 4:** Margin increases; takes on a crescent shape
- **Stage 5:** Total destruction and possible collapse of the bone

NONINVASIVE TREATMENT

During the early stages of AVN, a physician may begin treatment by having patients limit the amount of weight they place on the affected joint. Limited activity or crutches will likely be recommended to slow the damage caused by AVN. Range-of-motion exercises may be done by a physical therapist or by the patients themselves. This can improve and maintain the joint's range of motion. The reduction of weight, together with prescribed medications, can be an effective way to avoid or delay surgery for some patients.

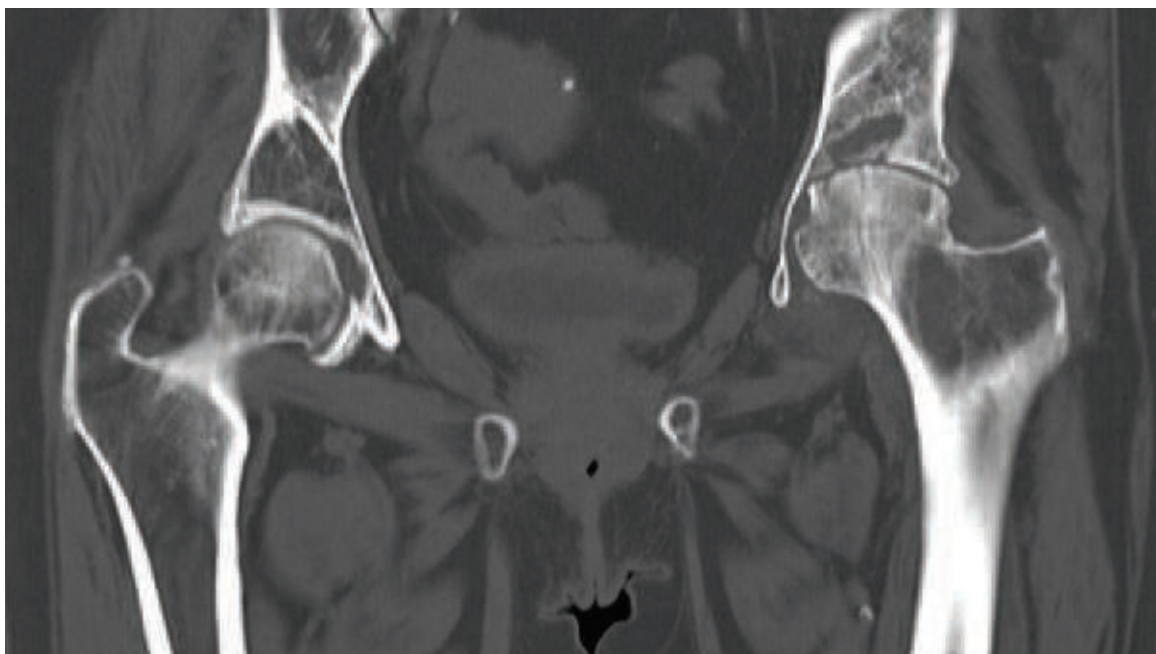


FIGURE 4: Magnetic resonance imaging shows AVN and collapse of left hip and arthritis in right hip.

When surgery is indicated, one of two procedures is typically performed—either a core decompression or a total hip arthroplasty.

SURGICAL OPTION 1— CORE DECOMPRESSION

The first and least invasive is a core decompression. During this procedure, a section of the diseased cancellous bone is removed from the femoral head. This relieves pressure from within the bone and increases blood flow to the bone, possibly allowing new blood vessels to form. Core decompression is most successful during the early stages of the disease and prior to collapse of the joint.

Instrumentation and supplies needed for a core decompression include:

- Basic bone instruments
- Orthopedic soft tissue set
- Stryker® drill and battery
- Synthes® DHS instrumentation (See Figure 5.)
- Ioban™ drape
- Major basin (lap sponges, electro-surgical pencil, suction tubing, Yankauer suction, #10 blade, bulb syringe)
- Fracture table
- Lead gowns
- C-arm




Photo courtesy of Synthes, USA.

FIGURE 5: Instrumentation.

Mayo stand set-up should include:

- #10 blade
- Hemostat
- Small elevators (1/2–3/4 in)
- One pair of small skin rakes
- Curved Mayo scissors
- Guide pin (Synthes DHS set)
- Lag drill (Synthes DHS set, drill depth set to 0)

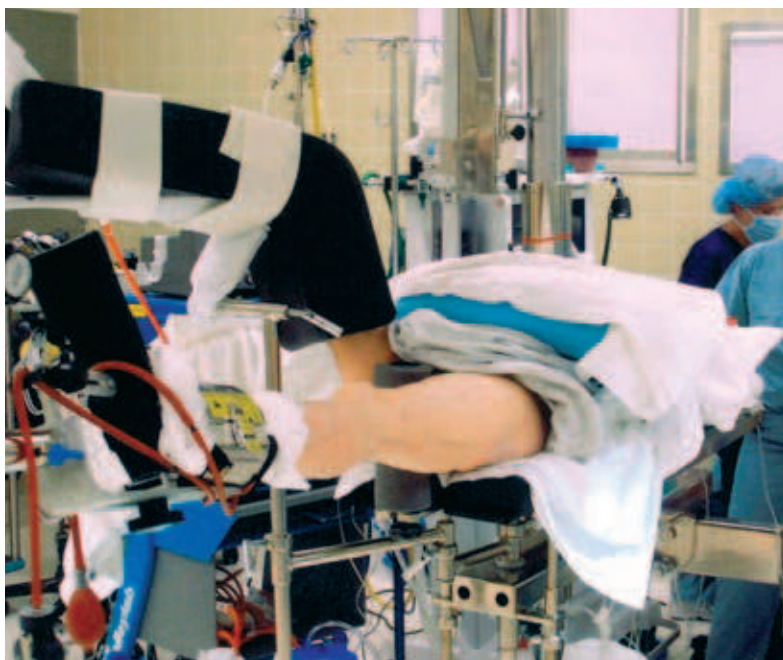
FIGURE 6:
Positioning on
fracture table.

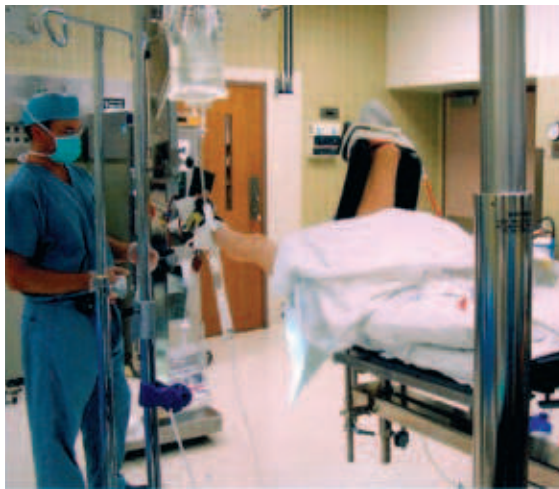

FIGURE 7:
Positioning on
fracture table.

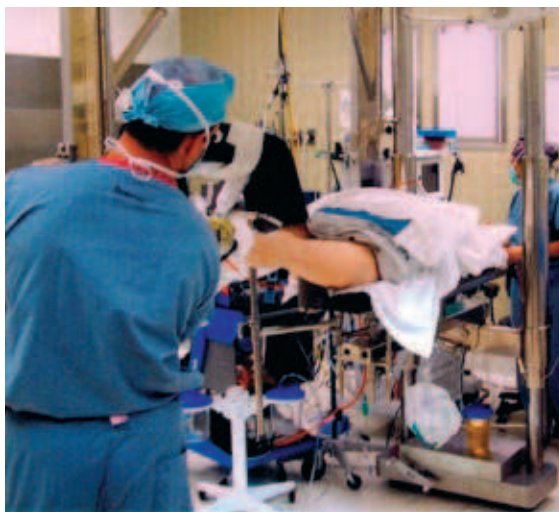

FIGURE 8:
Final position for
core decompression.



ANESTHESIA AND POSITIONING

The patient is brought into the operating room, and general or spinal anesthesia is administered. The patient is then placed on a fracture table with the affected leg placed in an ankle cuff. A C-arm is then used to create an X-ray image of the affected hip. The C-arm is then locked in place to hold the proper position for additional X-rays. (See Figures 6, 7, and 8.)

The patient is then prepped with either beta-dine scrub and paint or 4% chlorhexidene, depending on whether the patient is allergic to iodine. Once the preparation solution is dry, four sterile towels are used to determine the sterile area. A large Ioban drape is used to drape the patient. A time out is then done to verify the patient's name, surgery performed, correct site, and surgeon's name. The date consent form is also checked to verify that the patient has signed it.

PROCEDURE

A #10 blade is used to make a 3- to 5-inch, lateral incision. Hemostasis is achieved with the use of an electrocautery pencil. Underlying tissue is incised with a #10 blade, followed by curved Mayo scissors. A ½-inch periosteal elevator is used to expose the underlying bone. The femur is then exposed, and proper retraction is used. A 2.5-mm guide pin is placed against the cortex of the femur, and the X-ray film is checked to determine proper placement.

The pin is placed on the drill, and the surgeon drills to the proper depth, according to the X-ray. Once the correct position is confirmed on X-ray, a reamer is used. The reamer is placed on the guide pin and is drilled down to the proper depth until the devascularised bone is reached.

The drill is then reversed, and the bone is left on the drill. The removed bone is submitted to pathology as a specimen. A final X-ray is taken as a hard film for the patient's chart. The incision is irrigated, checked for hemostasis and closed. The fascia is closed with 0-Vicryl® suture, and 2-0 Vicryl is used to close the subcutaneous tissues. Either 4-0 Vicryl or staples are used to close the wound on the skin surface. The incision is then cleaned, and the dressing is applied.

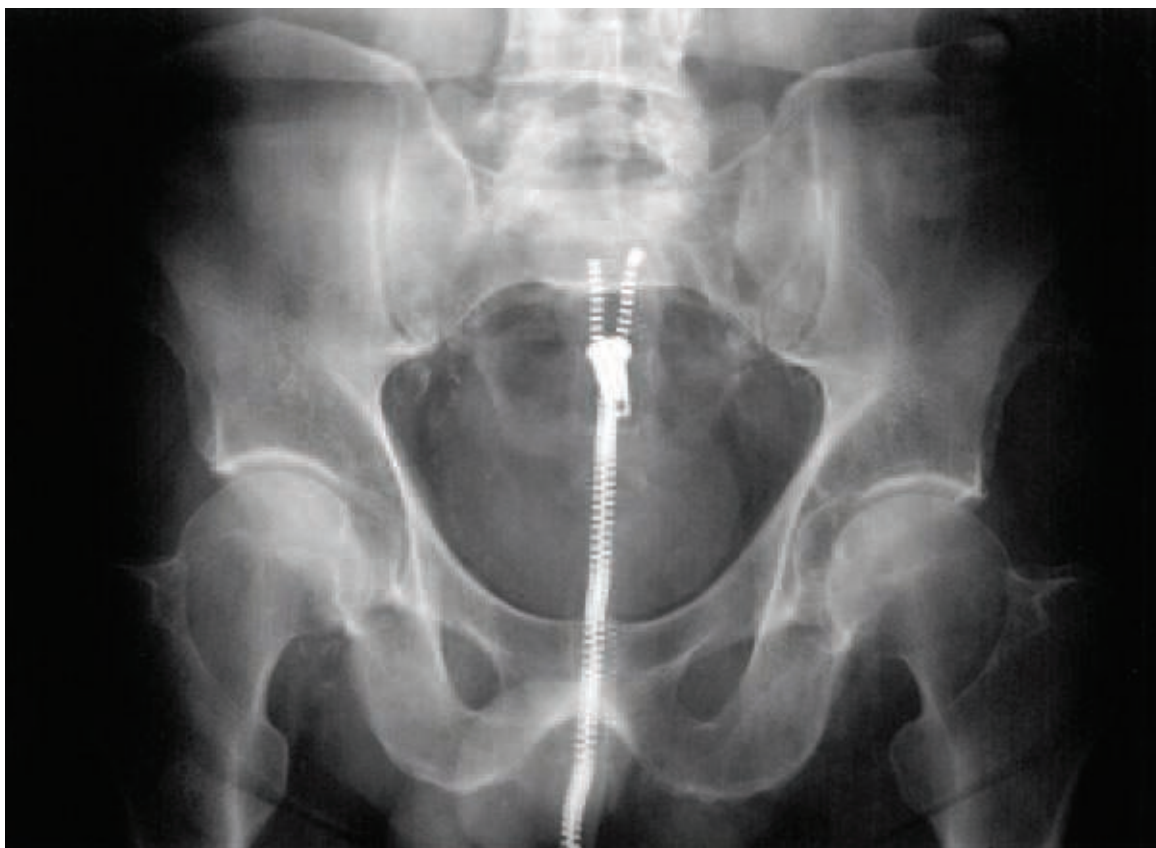

FIGURE 9:
AP of pelvis pre-core
decompression.

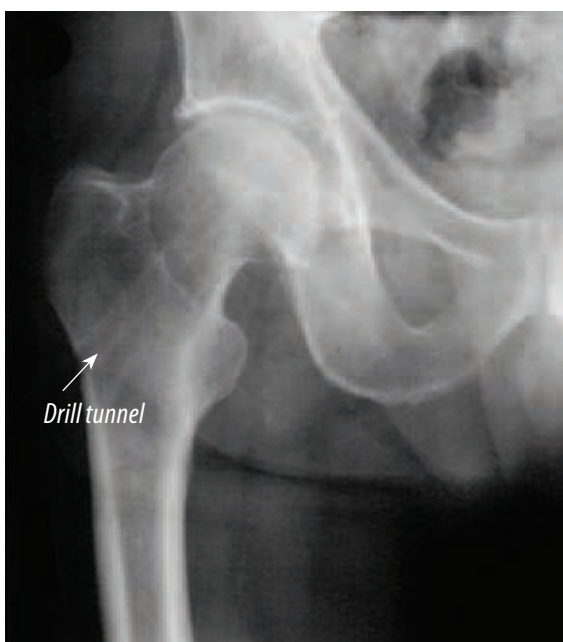

FIGURE 10:
After core
decompression.
Right hip.

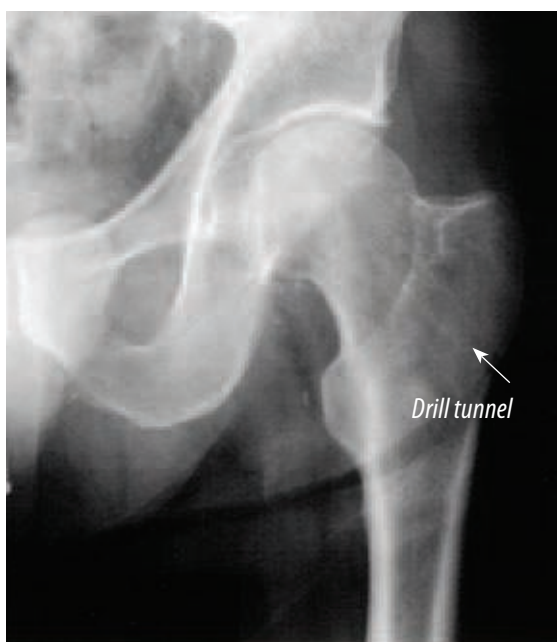

FIGURE 11:
After core
decompression.
Left hip.

SURGICAL OPTION 2 — TOTAL HIP ARTHROPLASTY

The second surgical option is a total hip arthroplasty, typically used in the last stage of AVN when the joint is destroyed. A total hip arthroplasty is also indicated for patients who are not good candidates for any other treatments.

Instruments and supplies needed for a total hip arthroplasty include:

- Total hip pack (lap sponges, electrosurgical pencil, scratch pad, Ioban drapes, needle box, #10/20 blades, medication cups, medication labels, skin marker, basins, asepto syringe, impervious stockinette, Coban™, Eshmark, and Mayo stand cover)
- Cement, cement mixer, cement gun
- Osteotomes (straight and curved)
- Charnley retractor
- Power saw, blades and batteries
- Total hip instruments (Varies by institution)
- Six to 15 pans
- Flexible reamers
- Suture
- Abduction pillow

ANESTHESIA , POSITIONING AND DRAPING

Depending on the patient's health and medical history, either general or spinal anesthesia will be administered. Once the patient is anesthetized, he or she is placed in a lateral position, surgical side up—using either a bean bag or another hip positioning device. The nonsurgical leg is padded with egg crate pads, and a compression stocking is applied to reduce the risk of deep vein thrombosis.

A nonsterile u-drape is applied to the unaffected hip, covering the unaffected leg and keeping it clean. This also creates a prepping margin on the operative leg, which is raised up in a leg holder. Skin preparation is performed from the level of the umbilicus to the ankle or foot and bilaterally as far as possible. Once this is finished, two sterile medium sheets are placed under the affected hip, which is being held by the surgeon with a stockinette. Sterile towels are then placed to define the intended incision site.

A u-drape is applied over the towels, followed by a large total hip extremity drape. The leg is placed

at 60 degrees of flexion, and the landmarks are drawn with a sterile marking pen. An Ioban drape is applied. This drape is an iodine-impregnated drape used to reduce the risk of infection. A time out is then done to verify the patient's name, surgery performed, and correct location. The consent form is then checked for the patient's signature and date.

PROCEDURE

A #20 blade is used to make the skin incision. The surgeon begins the incision proximally at the anterosuperior iliac spine parallel to the posterior edge of the greater trochanter. The surgeon then extends the incision along the femoral shaft about 10 cm distal to the greater trochanter. Using a 3/4-inch elevator, the subcutaneous tissues are dissected from the fascia. Once the fascia is exposed and proper retraction is in place, a marking pen is used to draw out the incision through the fascia. A #10 blade is used to nick the fascia, and a curved Mayo scissors are used to extend the incision. The gluteus maximus is then split proximally with an electrosurgical pencil, and a Charnley retractor is used to further the exposure. A medium Richardson or Meyerding retractor may be used as well.

The capsule is incised and removed with an electrosurgical pencil or a #10 blade on a #3 knife handle. Once the capsule is excised, the femoral head is visualized.

The assistant dislocates the femoral head by gently applying traction and externally rotating the leg. At the same time, the surgeon uses a bone hook placed around the femoral neck to pull up gently, assisting with the dislocation. Once the hip is out of the acetabulum, a blunt Hohmann retractor is placed under the femoral neck, and a Meyerding retractor is placed distally along the femoral neck. The knee must remain flexed to stabilize the leg.

The soft tissue is removed by using an electrosurgical pencil and a rat tooth pick up and is dissected from the femoral neck and the medial side of the greater trochanter. The osteotomy guide is used to mark the area of the proposed osteotomy of the femoral neck. The planned cut is marked with either an electrosurgical pencil or a sterile marking pen.

The oscillating saw is used to cut the head off the femur. The femoral head is measured with a

caliper, and the measurement is relayed to the surgeon. A self-retaining retractor or blunt Hohmann is used to retract tissue from the acetabular opening. The acetabulum is checked to ensure that any bony overgrowth or tissue is removed.

A long, heavy hip curette is used to scrape any remaining cartilage from the acetabulum and expose the inner table. The patient's position is verified prior to reaming to ensure proper placement of the implant. The femur is retracted anteriorly to allow passage of the reamers.

Acetabular reamers are used to remove cartilage and bone to the predetermined size. The smallest reamer is used first, followed by progressively larger ones. Save any bone shavings in the event that a bone graft is needed. Reaming is complete when there's complete contact between the reamer and the acetabular rim. Bone shavings are used to fill any voids in the acetabulum; then the last reamer used is reapplied and operated in reverse to help compact the bone graft.

An acetabulum trial is inserted and impacted with the proper degree of anteversion, using the patient's shoulder as the reference. If it is not a good fit, the next size trial shell will be used. Once the final cup size has been established and impacted, the larger or smaller acetabular liner is inserted, according to the patient's size.

To expose the proximal end of the femur, the patient's foot is lowered toward the floor, internally rotating the hip. Two Bennett retractors are used to stabilize the femur during preparation of the femoral canal.

Any remaining soft tissue is removed from the distal femur, and a box osteotome is used to provide a straight entry into the femoral canal. The intramedullary canal reamer is inserted to expose the opening, followed by the use of additional flexible reamers, the sizes of which are determined by the width of the canal. Reaming should stop once the cortex is reached.

Once the canal is opened, the smallest broach is inserted into the femur to enlarge the posterior entry point. Several broach sizes are used to determine the correct stem fit. Once the proper stem is inserted, a calcar reamer is placed on the proximal end of the trial. This reamer removes

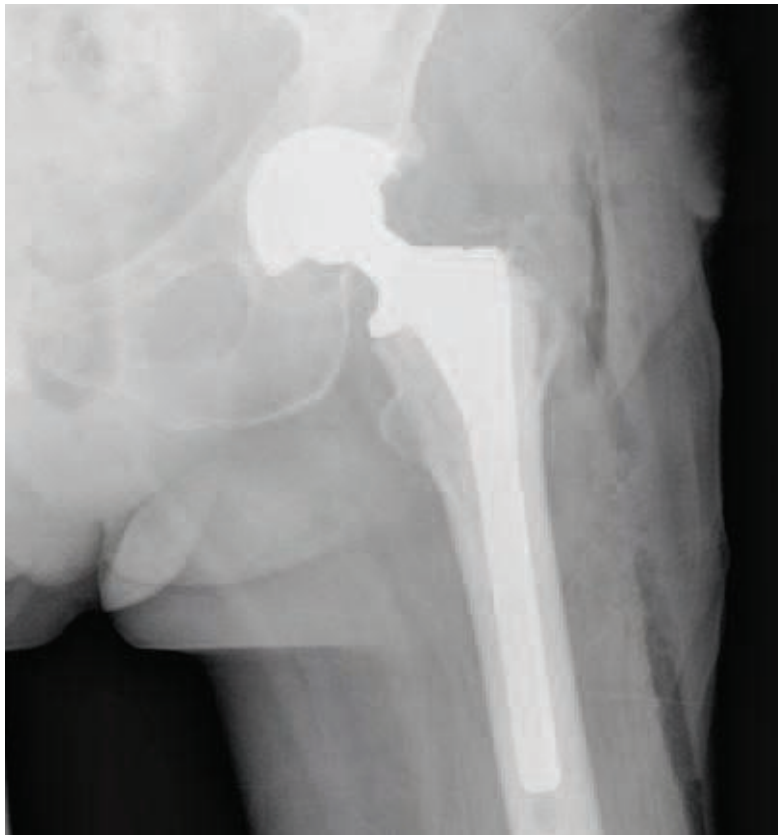

FIGURE 12: X-ray of patient's left hip following total hip arthroplasty.

any excess bone around the implant. Head and neck components of the anticipated size are assembled and inserted into the femur.

The hip is reduced and brought into flexion, extension, adduction, and internal and external rotation. The leg is measured to determine accuracy of the size of the implants. The hip is then dislocated, and the trial implants are removed. The wound is irrigated with either antibiotic irrigation or plain saline.

If cement is to be used, a cement restrictor will be placed into the distal femoral canal to prevent the cement from migrating distally. The necessary implants will be opened, assembled on the inserters and placed in a safe area until the time of insertion. The final acetabular cup is inserted into the acetabulum and impacted.

The femoral component is impacted into the femoral canal either with or without the use of cement. If cement is used, notify the anesthesia provider when the cement is inserted, because the patient may experience a negative reaction to the cement.

Next, the femoral head is impacted onto the

femoral stem. The hip is reduced slowly to prevent fracture of the greater trochanter. Range-of-motion and stability are tested. The wound is irrigated, and hemostasis is verified. The hip is closed and dressed, and a hip adduction splint is placed between the patient's legs. Compression stockings will be placed on the operative leg to reduce the risk of deep vein thrombosis.

POST-OP OF A TOTAL HIP PROCEDURE

RECOVERY

The patient is placed in his or her bed and transported to the postanesthesia care unit, where vital signs will be monitored for approximately one and a half hours. Pain management techniques will be implemented.

Once the patient is released to the orthopedic ward, rehabilitation will begin within two days. The dressing is changed as needed, and the drain is removed on the first or second postoperative day. The average hospital stay for this procedure is three to five days.

After being discharged, the patient may be transferred to a rehabilitation facility for additional physical therapy. Once the patient is mobile, he or she may be sent home. Regular outpatient physical therapy visits will continue until full range of motion and strength are achieved.

POSSIBLE COMPLICATIONS

As with any surgical intervention, complications may occur. The following is a list of potential complications associated with total hip arthroplasty:

- Deep vein thrombosis
- Infection
- Death
- Dislocation of the prosthesis
- Loosening of the prosthesis
- Femur fracture
- Change in leg length
- Bleeding
- Nerve injury
- Pain and stiffness
- Anesthesia complications
- Allergy to metal implants, medications, tape
- Skin rashes
- Reactions to blood transfusions

Avascular necrosis is a serious disease, but most people with AVN can lead normal productive lives with proper treatment and patient education. If caught during the early stages, treatment may be as minimal as medication or as invasive as a total joint replacement. With today's advanced diagnostic testing, patients are diagnosed earlier and are taking steps to manage their health and lifestyle to minimize the effects of AVN.

ABOUT THE AUTHOR

Robert Doheny, CST, has been a surgical technologist for seven years. He was trained on the job at St Joseph Hospital, Clinton Township, Michigan, and graduated from Macomb County Community College in Clinton Township, Michigan, in 2002 with an Associate degree in surgical technology and general studies. He was certified in 2002 and was the primary contributor to the orthopedic chapter in the fourth edition of *Surgical Technology: Principles and Practice* (Elsevier Saunders, 2005). He has been employed at William Beaumont Hospital in Troy, Michigan, since 2002.

Acknowledgments

I would like to thank my family for their patience and support during writing and furthering my education. Also a special thank you to Donald Knapke, MD, Laurence Ulrey, MD, Marty Gross, MD, for the X-rays in this article. Additional thanks to the following orthopedic surgeons at William Beaumont Hospital, Troy, Michigan, for their knowledge, great teaching skills and advanced use of technology in surgery: Charles Stroud, MD, Melissa Mozden, PA-C, John Schmpike MD, Russel Miller, MD, Christopher Nicholas, MD., and Matthew Kopera, MD.

References

1. Bently G, Duthie RB. Mercer's *Orthopaedic Surgery*, 9th ed. Oxford, England: Oxford University Press; 1996.
2. Epps Jr CH. *Complications in Orthopaedic Surgery*. Philadelphia, Pa: Lippincott Williams & Wilkins; 1994.
3. Fuller JK. *Surgical Technology: Principles and Practice*, 4th ed. Philadelphia, Pa: Elsevier Saunders; 2005.
4. Hoppenfeld S, deBoer P. *Surgical Exposures in Orthopaedics, The Anatomical Approach*, 3rd ed. Philadelphia, Pa: Lippincott, Williams & Wilkins; 2003.
5. Canale ST. *Campbell's Operative Orthopaedics*. Vol 1-4, 10th ed. Philadelphia, Pa: Mosby; 2003.

Synthes® is a registered trademark of Synthes, Inc. Stryker® is a registered trademark of Stryker Corp. Ioban™ and Coban™ are trademarks of 3M Corp.

Avascular necrosis

Earn CE credits at home

You will be awarded continuing education (CE) credit(s) for recertification after reading the designated article and completing the exam with a score of 70% or better.

If you are a current AST member and are certified, credit earned through completion of the CE exam will automatically be recorded in your file—you do not have to submit a CE reporting form. A printout of all the CE credits you have earned, including Journal CE credits, will be mailed to you in the first quarter following the end of the calendar year. You may check the status of your CE record with AST at any time.

If you are not an AST member or are not certified, you will be notified by mail when Journal credits are submitted, but your credits will not be recorded in AST's files.

Detach or photocopy the answer block, include your check or money order made payable to AST, and send it to the Accounting Department, AST, 6 West Dry Creek Circle, Suite 200, Littleton, CO 80120-8031.

Members: \$6 per CE, nonmembers: \$10 per CE

- Which supplements are used to counteract the effects of corticosteroids on the bones?
 - Iron
 - Potassium
 - Vitamin D
 - Chondroitin
- AVN is best diagnosed by...
 - MRI
 - Complete blood cell count
 - Physical exam
 - Ultrasound
- Steinberg's Stages identify ...
 - Osteoblasts formation
 - Arthritis
 - Proper treatment
 - Pathological progress
- Total hip arthroplasty is indicated in which stage of AVN?
 - 2
 - 5
 - 4
 - 3
- Alcohol in the blood causes lipids within the bones to ...
 - Increase
 - Decrease
 - Neutralize
 - Stabilize
- Which of the following is not true about core decompressions?
 - Increase blood flow to the bone
 - Decrease pressure in the bone to stimulate bone growth
 - Performed in the early stages of the disease
 - Increase and improve range of motion
- Avascular necrosis affects what percentage of long-term corticosteroid users?
 - 20
 - 25
 - 35
 - 50
- Which of the following is not associated with AVN of the femoral head?
 - Overexposure of radiation
 - Dislocation of the femoral head
 - Femoral neck fracture
 - Distal femoral epiphysiolyis
- When should physical therapy start after a total hip arthroplasty?
 - 48 hrs after surgery
 - When patient goes home
 - When patient is transferred to rehabilitation center
 - 24 hrs after surgery
- Which of the following is true about avascular necrosis?
 - Limits a patient's physical activity
 - Affects people 30-50 years old
 - Causes ischemia in the cancellous bone
 - All of the above

Avascular necrosis

Certified Member Certified Nonmember

Certification No. _____

Name _____

Address _____

City _____ State _____ ZIP _____

Telephone _____

	a	b	c	d		a	b	c	d
1	<input type="checkbox"/>	<input type="checkbox"/>	<input type="checkbox"/>	<input type="checkbox"/>	6	<input type="checkbox"/>	<input type="checkbox"/>	<input type="checkbox"/>	<input type="checkbox"/>
2	<input type="checkbox"/>	<input type="checkbox"/>	<input type="checkbox"/>	<input type="checkbox"/>	7	<input type="checkbox"/>	<input type="checkbox"/>	<input type="checkbox"/>	<input type="checkbox"/>
3	<input type="checkbox"/>	<input type="checkbox"/>	<input type="checkbox"/>	<input type="checkbox"/>	8	<input type="checkbox"/>	<input type="checkbox"/>	<input type="checkbox"/>	<input type="checkbox"/>
4	<input type="checkbox"/>	<input type="checkbox"/>	<input type="checkbox"/>	<input type="checkbox"/>	9	<input type="checkbox"/>	<input type="checkbox"/>	<input type="checkbox"/>	<input type="checkbox"/>
5	<input type="checkbox"/>	<input type="checkbox"/>	<input type="checkbox"/>	<input type="checkbox"/>	10	<input type="checkbox"/>	<input type="checkbox"/>	<input type="checkbox"/>	<input type="checkbox"/>

Mark one box next to each number. Only one correct or best answer can be selected for each question.