

Pectus Carinatum:

Pigeon Chest

Tracy Cheek

Pectus carinatum is a deformity of the chest wall distinguished by a protuberant sternum and rib cage. It is caused by congenital and genetic abnormalities found in pediatric patients. This unusual deformity can have both physiological consequences and significant psychological impacts on the untreated patient.

PATIENT CASE STUDY

The patient is a 13-year old Caucasian male who presented with a protuberant sternum and characteristic *pectus carinatum*. The chest wall deformity has slowly been increasing in prominence and distortion over time as the patient has grown, causing discomfort and pain on occasion. The patient was experiencing bouts of fatigue and dyspnea (shortness of breath) during physical activity, which became more frequent in the last year. The young man recently expressed concerns to his parents that he felt his chest deformity was hindering him from normal physical activities at school, and that he felt self-conscious of his appearance, particularly around his peers. The patient's parents noted that he was beginning to isolate himself from both friends and family and showing signs of depression. They articulated that, at this point, the primary concern with their son was his emotional state of mind, and that it was directly related to the cosmetic appearance of his chest wall deformity. The patient has a past history of psychological issues and problems with socialization. The parents felt that the next logical step would be surgical intervention to repair the *pectus carinatum*.

LEARNING OBJECTIVES

- ▲ Review the relevant anatomy for this procedure
- ▲ Examine the set-up and surgical positioning for this procedure
- ▲ Compare and contrast the various genetic disorders that may cause *pectus carinatum*
- ▲ Evaluate the step-by-step procedure for surgical correction of *pectus carinatum*
- ▲ Assess the postoperative precautions and recovery time for this procedure

THE DISEASE

Pectus carinatum is an uncommon deformity of the anterior chest wall that is typically characterized by a protruding breast bone (sternum) and ribs caused by an overgrowth of the costal cartilages. It is a pediatric disease that can present solely as a congenital abnormality or in conjunction with other genetic disorders. It frequently goes unrecognized until adolescence, where it is predominantly seen in males, and typically increases in severity with age, particularly during growth spurts. It is sometimes referred to as “pigeon chest,” as it causes the patient’s chest to have the appearance of a bowed bird’s chest.¹

Treatment for *pectus carinatum* includes both surgical and nonsurgical options. Children with mild forms of *pectus carinatum* will often only require nonsurgical treatments, which can include being fitted with an external pressure brace or no treatment at all. Similar in theory to how orthodontic braces work on the teeth, a pressure brace applies a constant, gentle pressure against the bone (in this case the sternum), which over time pushes the bone back into normal anatomical position. The number of days, as well as the amount of time per day that a child wears the brace until desired results are accomplished will be dependent on the amount of severity in disproportion of the child’s chest. Although this treatment option has been shown to provide positive results over time, some parents have found that it is difficult to keep their child from taking off the brace due to it being uncomfortable to wear, which reduces the overall therapeutic process.¹

Patients with moderate to severe *pectus carinatum* will require surgical intervention. Surgical treatment involves removing the cartilages that project the sternum forward

and suturing them into normal, anatomical position. As the patient heals, the cartilage regenerates and forms in the new position. Surgical treatment can take anywhere from two to six hours, depending on the amount of cartilage to be removed, and a postoperative hospital stay can be anywhere from three to seven days, depending on complications and pain management.¹


The most common method of surgical treatment for *pectus carinatum* is the Ravitch procedure. It involves cutting the costal cartilage away from each side of the sternum and making the sternum lie flat. In this procedure, the surgeon may choose to utilize stabilization bars that can be inserted into the sternum to help maintain its new shape. These bars remain in place permanently. Drains are placed on each side of the chest to evacuate fluids from the wound and are sutured in place. The Ravitch procedure has a 97 percent satisfaction rate among patients.²

Pectus carinatum is mainly an asymptomatic disease with little or no interference with the patient’s cardiopulmonary function. However, as studies have suggested, there can be decreased lung capacity and mitral valve prolapse associated with the disorder. The outward projecting and rigidity of the sternum can impair the gas exchange process of the cardiopulmonary system, which in turn can decrease a patient’s physical stamina. Additionally, connective tissue disorders affecting major blood vessels and heart valves are being seen along with emphysema, respiratory tract infections and dyspnea. Many patients experience pain and tenderness in the chest area. Yet among all of these symptoms, it appears the primary concern for patients suffering from *pectus carinatum* and their families revolves around the significant cosmetic concerns this disorder can present.³

EPIDEMIOLOGY

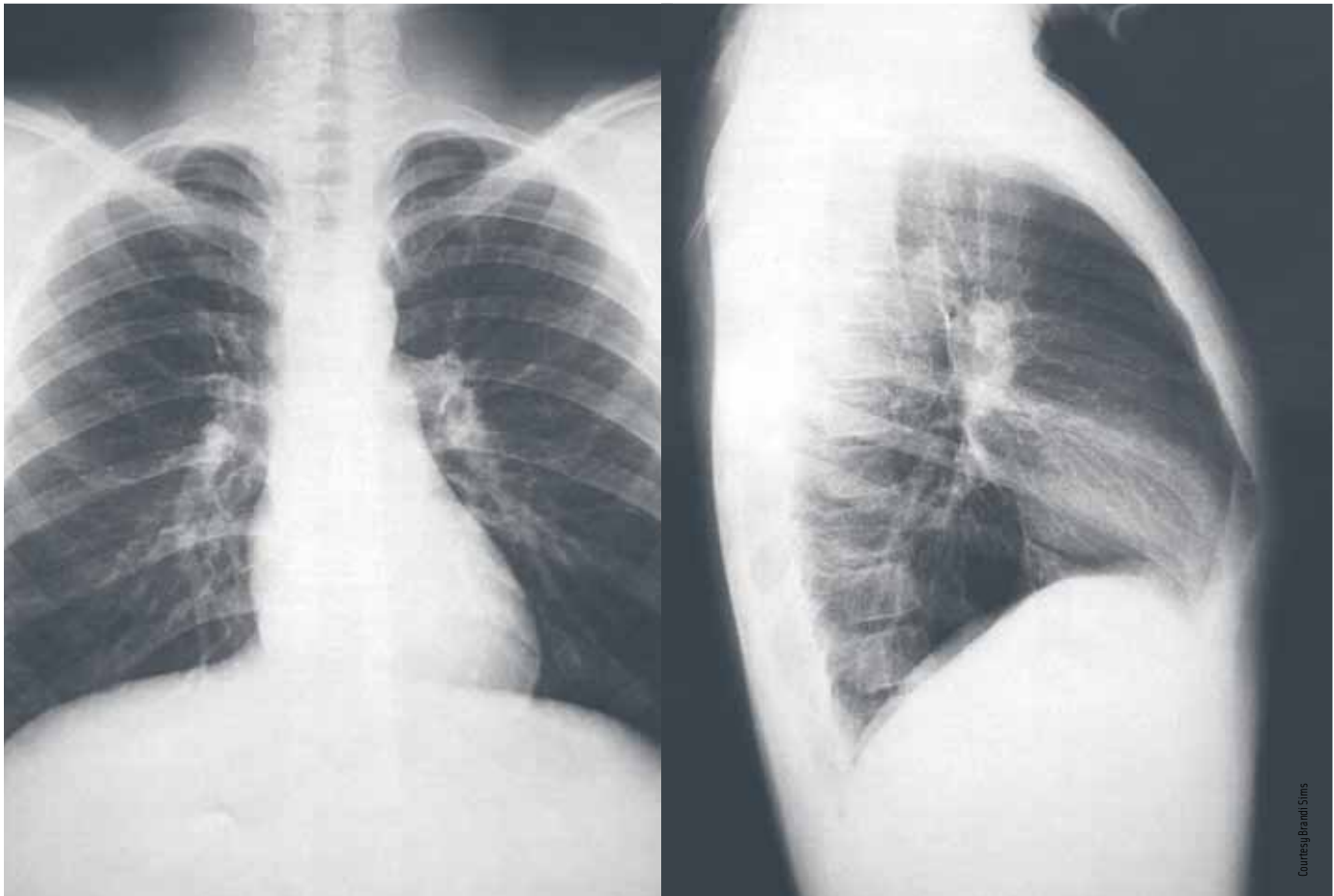
According to the Seattle Children’s Research Foundation, *pectus carinatum* occurs in approximately one out of every 1,500 children. It is five times more likely to occur in males than in females.¹

Pectus excavatum is another chest deformity that is similar to *pectus carinatum*, but has the reverse effect on the patient’s sternum. This disorder presents as an inverted, or “funnel chest,” as opposed to *pectus carinatum*’s protruding chest. *Pectus excavatum* generally affects the lower half of the sternum and is much more common than *pectus carinatum*, affecting one in every 500-1,000 children. Like *pectus carinatum*, *pectus excavatum* is also believed to be caused from genetic factors passed down familial lines.⁴



An external pressure brace.

Courtesy Westcoast Brace & Limb*



Front and lateral X-rays of an adolescent male with *pectus carinatum*.

ANATOMY AND PHYSIOLOGY

The thorax (chest) is a conical-shaped, airtight, protective compartment made up of an osseo-cartilaginous cage. The primary purpose of the thorax is to protect the principal organs of respiration and circulation (the lungs and heart).⁵

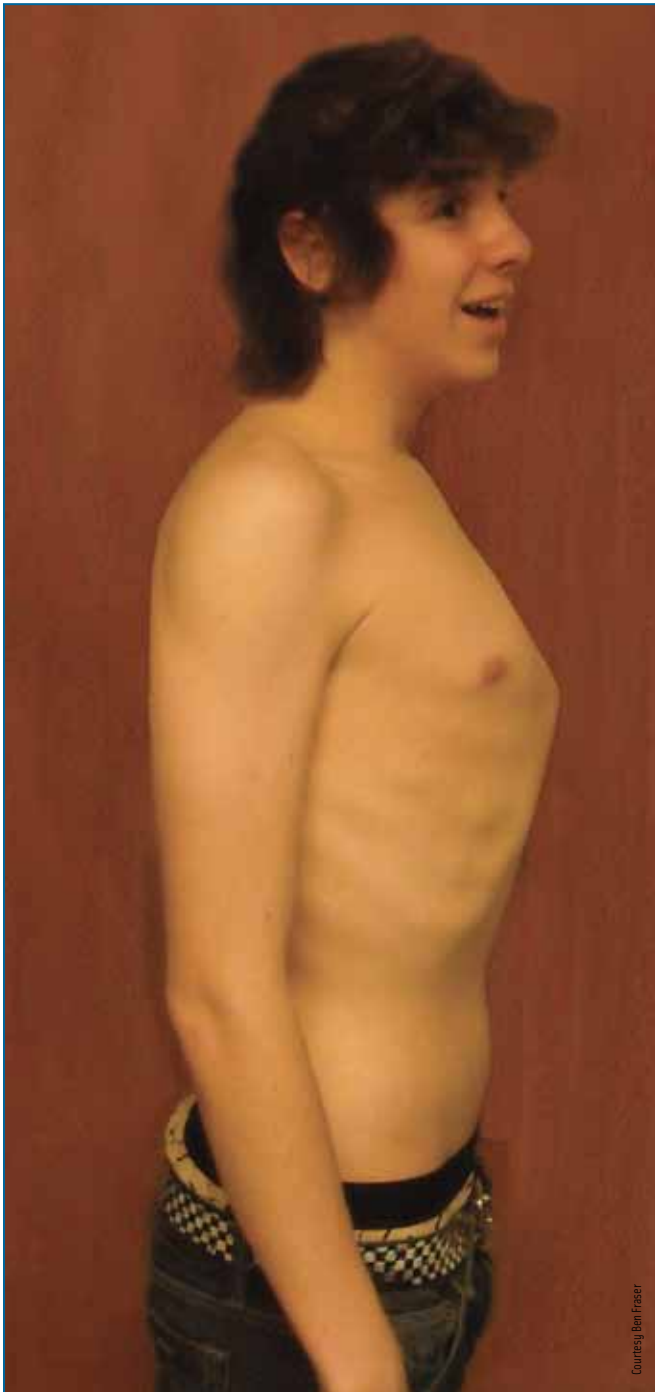The thorax is narrow at the superior end and wide at the inferior end. Its anatomical boundaries include the 12 thoracic vertebrae (T-1 through T-12), which form the posterior boundary; the sternum and costal cartilages, which form the anterior boundary; and the ribs, which are at each of the lateral margins.⁵

The human body contains 24 ribs, the first seven superior ribs are considered the “true ribs,” and they are attached to the sternum by the costal cartilages. The purpose of the costal cartilages is to allow the ribs to stretch forward and back during respirations. The eighth, ninth, and tenth ribs are considered the “false ribs.” These ribs adjoin with the costal cartilages of the superior ribs. The eleventh and twelfth ribs are also known as false ribs. These ribs are not

joined with the sternum by the costal cartilages. The false ribs are also known as the “floating ribs.”⁵

The superior opening of the thorax is wide from side to side. It is formed by the first thoracic vertebrae (T-1) posteriorly, the superior portion of the sternum anteriorly, and the first rib laterally. The inferior opening of the thorax is formed by the twelfth thoracic vertebrae (T-12) posteriorly, the eleventh and twelfth ribs laterally, and the seventh, eighth, ninth, and tenth rib cartilages (costal cartilages) anteriorly. The costal cartilages form the subcostal angle at the xiphoid process. The diaphragm, a large sheet of muscle, extends across the bottom of the thoracic compartment and separates the thoracic cavity from the abdominal cavity.⁵

The spaces between the ribs, known as the intercostal spaces, are occupied by muscles known as the intercostal muscles, which assist in the mechanics of respiration. There are 11 external intercostal muscles that aid in inhalation and 11 internal intercostal muscles that aid in exhalation. Each of these muscles has its own blood supply and inner-



Courtesy Ben Fraser

Adolescent male presenting with severe *pectus carinatum*.

vation. The intercostal arteries supply blood to the muscles and branch from the internal thoracic artery and the aorta. The intercostal veins connect with the mammary veins and the azygos and hemiazygos veins. The intercostal nerves, branch from the thoracic spinal nerves and the ventral rami nerves, innervate the intercostal muscles.⁵

The pectoralis major is a large muscle group that is located on the sides of the chest, superiorly and contralaterally. This group of muscles branch from the sternum, the superior ribs, and the clavicle area. They are innervated by the lateral and medial pectoral nerves.⁶

The male thorax is different from the female thorax. In the male, the thorax has a larger capacity than that of the female. The level of the upper sternum is at the second thoracic vertebrae (T-2), whereas in the female the level of the upper sternum is at the third thoracic vertebrae (T-3). Additionally, the upper ribs in the male thorax are less mobile than the female thorax.⁵

DISEASE PRESENTATION

There are several possible causes for *pectus carinatum*, all of which can present in three separate situations: at birth, during growth spurts and post-surgically. Generally, post-surgical presentations of the disease are due to the sternum's malunion during healing. This is seen in cases where a patient has undergone cardiac surgery, but it is fairly uncommon. Patients who develop *pectus carinatum* from surgery will require additional future surgical intervention to correct the sternal protrusion.⁷

Congenital presentations are the second most likely presentation of *pectus carinatum*. The newborn will have a circular chest, which develops into a protrusion at around three years of age. Often in these cases, surgical intervention to correct the deformity will take place once the child reaches puberty.

The most frequent presentation of *pectus carinatum* is in adolescent males undergoing growth spurts. This kind of presentation can come on rapidly and can be the cause of much emotional turmoil for the child and the parents. Surgical intervention in these cases is generally more for the cosmetic effects than symptomatic reasons.⁷

PATHOPHYSIOLOGY

Pectus carinatum can be caused by either sole congenital abnormalities or from genetic abnormalities. One type of genetic disorder associated with the development of *pectus carinatum* is Edward's syndrome, or Trisomy 18. Trisomy 18 is a genetic disorder that involves a person having extra genetic material from chromosome 18. This genetic syndrome is fairly common and occurs in females more often than males. Symptoms of Trisomy 18 include low birth weight, mental deficiency, micrognathia, microcephaly, low-set ears, clenched hands, crossed legs, round-bottomed

feet, undescended testicles, underdeveloped fingernails, and *pectus carinatum*.⁸

Trisomy 21 is another genetic abnormality that is commonly associated with Down syndrome and another possible contributor to the development of *pectus carinatum*.⁹

Marfan syndrome is another genetic disorder that has been associated with *pectus carinatum*. Marfan syndrome is a connective tissue disorder that affects the eyes, skin, heart, blood vessels, lymphatic vessels and bones. In this disorder, a genetic defect involving the gene fibrillin-1 interferes with the body's tissue-building properties and, in turn, causes an excessive growth in the long bones of the body. Symptoms of Marfan syndrome include arachnodactyly, flat feet, loose joints, learning disabilities, nearsightedness, eye problems, scoliosis, and *pectus excavatum* or *pectus carinatum*.¹⁰ Although Marfan syndrome is considered an inherited genetic disease, approximately 30 percent of the children presenting with this defect have no known family history of the disorder.¹⁰

It appears the primary concern for patients suffering from *pectus carinatum* and their families revolves around the significant cosmetic concerns this disorder can present.

Homocystinuria is another genetic disorder associated with the development of *pectus carinatum*. This genetic disorder involves the inability of the body to correctly metabolize methionine, an amino acid. Similar to Marfan syndrome, homocystinuria affects the tissue building properties of the body, particularly the joints. Marfan syndrome causes the body joints to become loose, whereas homocystinuria affects the joints by causing them to be stiff and tight. Common symptoms of homocystinuria include flushed cheeks, knocked knees, long limbs, mental retardation, psychiatric disorders, highly-arched feet and chest deformities such as *pectus excavatum* and *pectus carinatum*.¹¹

Morquio syndrome is a genetically inherited disease that affects the metabolism. The body lacks the proper enzymes to breakdown glycosaminoglycan, a specific type of sugar molecule. Morquio is associated with a group of diseases known as mucopolysaccharidoses, or MPS. The common symptoms

of Morquio syndrome include knock knees, widely-spaced teeth, macrocephaly, loose joints and an abnormal development of bones including those of the thorax.¹²

Multiple lentiginos syndrome is a genetic disorder that is tied to *pectus excavatum* and *pectus carinatum*. Symptoms of this syndrome include dark skin spots on the neck and chest area, delayed puberty, pulmonic stenosis, cryptorchidism, hypogonadism, *pectus excavatum* or *pectus carinatum*.¹³ Generally, patients diagnosed with multiple lentiginos have a strong family history of the disorder.

A congenital disorder called *osteogenesis imperfecta* (brittle bone disease) is another potential cause for the development of *pectus carinatum*. This disorder is caused by a defective gene that is responsible for the production of collagen. Type I collagen is an important component of bone building. Common symptoms of *osteogenesis imperfecta* include multiple bone fractures, deafness, eye discolorations, loose joints, flat feet, bowed limbs, scoliosis, kyphosis and *pectus carinatum*.¹⁴

DIAGNOSTIC TESTING

The patient in the case study has been given several preoperative diagnostic tests to confirm the diagnosis of *pectus carinatum*. The physician treating the patient performed a thorough physical examination and review of his complete medical history. The patient's medical history reveals that the 13-year old has a history of emotional disorder, specifically attention deficit hyperactivity disorder (ADHD), for which he is being treated with the drug methylphenidate. Additionally, it is found that when the patient was seven-years old, he underwent a right-side inguinal hernia repair with no noted postoperative complications. No other medical interventions or diagnoses are found in the patient's history and physical exam.¹⁵

Diagnostic testing continues with an X-ray exam to view the patient's chest abnormalities and verify any signs of scoliosis. Results of the X-ray are conclusive, revealing that the patient has a moderate protrusion of the thoracic wall with an over growth of five of the costal cartilages, contralaterally. No scoliosis is noted. A computed tomography (CT) scan is performed to review the patient's chest anatomy. His lungs and heart appear normal in size for the patient's age and build.¹⁵

A pulmonary function test (spirometry) is performed to identify any lung abnormalities and to verify lung function. The physician also performs an electrocardiogram (ECG) to observe the electrical conductivity of the patient's heart

and an echocardiogram to confirm the patient's heart structure is sufficient and functioning properly. The spirometry, electrocardiogram and echocardiogram show normal heart and lung function.¹⁵

Several blood tests are performed, including a complete CBC, metabolic, enzyme and chromosomal study panels. These blood tests are performed to confirm and rule out genetic disorders associated with pectus carinatum. No genetic disorder is identified.

Finally, the patient has a urine analysis conducted to verify kidney function and rule out diabetes.¹⁵

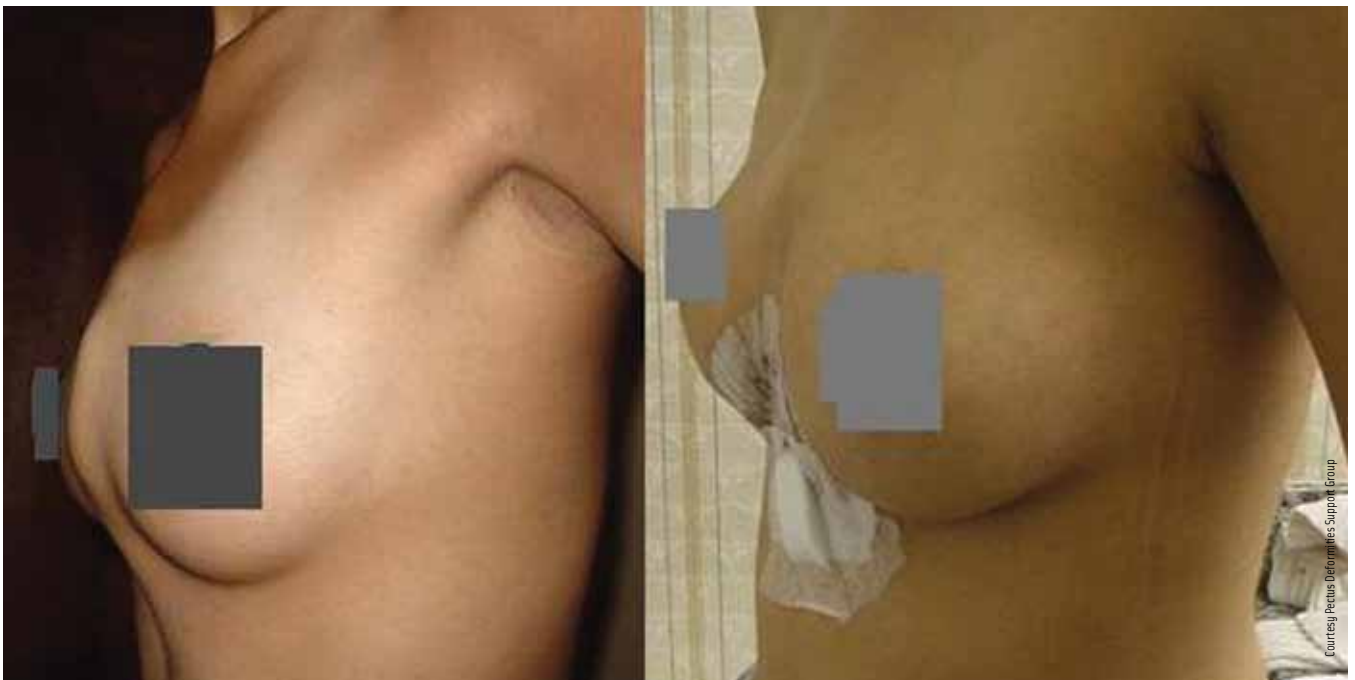PREOPERATIVE PREPARATION

The patient is scheduled for surgery at 13:30 hours. The surgical technologist (ST) and the circulator begin preparing the operating room for the procedure at approximately 12:50 hours. Per the surgeon's preference card, the pediatric instrumentation trays pulled for the case consist of a plastics set, a minor orthopedic set, and several specialty items that are requested by the surgeon for this procedure, including Lane bone holding forceps, a Shaw scalpel, additional Freer elevators (Freer elevators are included in the minor orthopedic set, however, the surgeon uses several during this particular procedure as they become dull, and requested to have extra on hand), and two Davol drain systems.

A major laparotomy module is pulled, which includes the basic items needed for setting up the sterile field, including:

- A back-table cover
- 77 x 108 pediatric drape
- Mayo stand cover
- 32-oz plastic basin
- Lap sponges
- X-ray-detectable sponges
- Bulb syringe
- Large basin
- Specimen cups
- Rigid light handle covers
- Towels
- Emesis basin
- Sterile marking pen
- #15 blades
- Electrosurgical-tip-cleaner pad
- Electrosurgical pencil with needle tip and holster
- Suture garbage bag
- Magnetic needle holder/counter
- Three sterile surgical gowns

Additional sterile items pulled for the procedure include bone wax, adhesive skin closure strips, suction tubing, cord



A lateral view of a 20-year old female before and after having her pectus carinatum surgically repaired.

and blade for Shaw scalpel, and several sutures including 2-0, 3-0, and 4-0 polyglactin 910 RB-1 and 4-0 polyglicaprone 25 CT-1.

At approximately 13:10 the ST began establishing the sterile field, starting by arranging the operating room furniture into place for the procedure and ensuring all items had been pulled for the case prior to opening. The ST opens the major laparotomy pack on the back table and places the instrumentation sets on a prep stand. Once the items are placed, the ST and the circulator don sterile face masks and begin opening the items to establish the sterile field. During this time, the circulator adjusts the room temperature and confirms with the ST what local anesthetic will be used for the procedure, (one percent lidocaine with epinephrine, 1:200,000). Once the back table (laparotomy pack) and the instrumentation sets are opened, the ST proceeds to the scrub sink to perform a surgical scrub, according to facility policy. After the scrub, the ST returns to the operating room and dons his or her gown and gloves. The circulator assists the ST as needed.

Once the ST is gowned and gloved he or she organizes the back table and performs an initial sponges, sharps, and instrument count, according to facility policy, with the circulator. At the conclusion of the initial count, the circulator pours sterile water and normal saline solutions in labeled bowls on the back table and prepares the local anesthetic. At this time, the circulator exits the operating room to get the patient. The ST continues setting up the Mayo stand and back table for the procedure. The anesthesia provider is now present in the room and advises that the patient had been given an epidural of morphine sulfate at 13:00 hours.

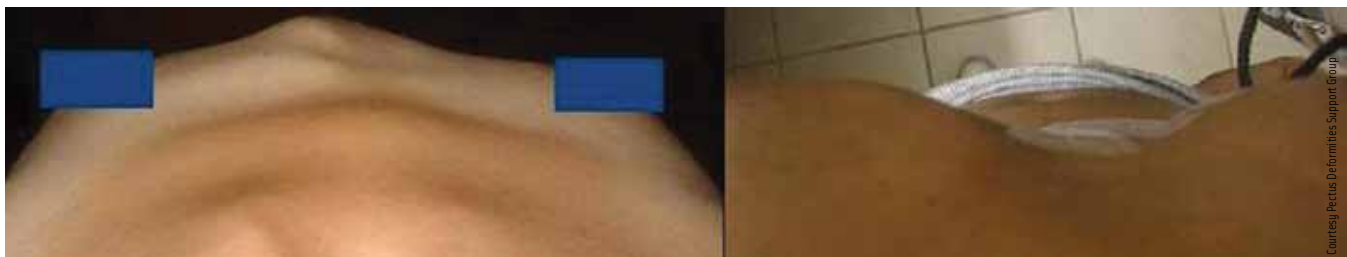At approximately 13:15 the circulator returns to the operating room with the 13-year old male patient, who is conscious and alert. He has been given a preoperative sedative of midazolam (1 mg) to reduce anxiety. Shortly afterward, the surgeon and a resident surgeon enter the oper-

For some patients, additional surgical intervention will be required in the future due to inadequate contracture of the chest wall that resulted in an undesirable cosmetic look. It is for this reason that it is desirable to wait for a child's skeletal system to reach maturity prior to surgical intervention.

ating room and talk briefly with the patient. The surgeon confirms with the ST his or her suture preference and that two Davol drains are available for the procedure.

At 13:25 the patient is moved to the operating table, anesthetized, and intubated by the anesthesia provider. The circulator and the anesthesia provider assist in positioning the patient in supine position with his chest slightly hyperextended with a rolled towel. The patient's head is placed on a foam donut pad with his arms tucked at the sides with a sheet. A small pillow is placed under his knees, and a safety strap is applied. The circulator applies a dispersive electrode pad to the patient's posterior near the sacrum. The anesthesia provider adjusts the operating table height to an optimal level and at a slight reverse Trendelenburg position, as requested by the surgeon.

Once the patient is positioned, the circulator performs a skin prep on the patient's chest, beginning at the incision site and extending out to each side contralaterally, from chin to umbilicus, down to the table sides. Povidone-iodine solution is used as the skin prep agent. During this time, the surgeon and resident proceed out of the operating room to perform a surgical scrub, after which the ST assists them



Superior view of a 20-year old female before and after having her pectus carinatum surgically repaired.

with drying, gowning and gloving.

With the skin prep completed, the ST assists the surgeon with draping the patient. Draping consists of four folded towel drapes secured with Backhaus towel clips and a fenestrated, pediatric chest drape.

At approximately 13:30 hours, the surgeon performs a “time out” according to facility policy. The “time out” procedure verifies the patient’s name, identification number, operative procedure and site (correct surgical site is marked on the patient’s chest with a sterile surgical marking pen). Additionally, it is confirmed that the patient has no known allergies,¹⁵ preoperative medications have been given, and consent has been signed. The ST, circulator, anesthesia provider, and resident acknowledge this information.

The ST moves the Mayo stand and back table into position and begins laying out the electrosurgical pencil, suction, Shaw scalpel and accessory light handles on the operative field and prepares for the intraoperative portion of the procedure.

INTRAOPERATIVE PROCEDURE

The ST places two X-ray-detectable sponges at the operative sight and hands the surgeon the Shaw scalpel. The surgeon begins by making a transverse inframammary incision on the left side of the patient’s chest with the scalpel. The incision is carried down through the dermis, epidermis, and subcutaneous tissues. Hemostasis is achieved with periodic use of the electrosurgical pencil; however, minimal hemorrhaging is seen due to the surgeon’s use of the Shaw scalpel and its cutting and coagulating properties.

As the surgeon continues incising downward through the layers of tissue, the ST prepares the Cobb elevator. Utilizing the Cobb elevator, the surgeon makes a skin flap and elevates it from the pectoral muscles superiorly and inferiorly. The pectoral muscles are then lifted off the costal cartilage on both sides. The surgeon observes that there appear to be five abnormal cartilages on each side of the patient’s rib cage.

The ST retrieves the Cobb elevator and hands the surgeon the Freer elevator and the Lane bone holding forceps. Using the Freer elevator and the Lane bone forceps intermittently, the surgeon proceeds to remove each cartilage by incising the perichondrium, stripping it off of the cartilage, and then removing the cartilage, leaving behind the perichondrial bed.¹⁵ The ST provides the surgeon with the electrosurgical pencil and suction as needed. As pieces of cartilage are removed, they are placed in a sterile specimen

cup. All pieces of cartilage are placed in one sterile specimen cup per the surgeon’s request.

The surgeon removes all 10 of the abnormal costal cartilages and then proceeds to pull the sternum down into a more anatomical position. The ST hands the surgeon a prepared 2-0 polyglactin 910 RB-1 suture on an 8” Crile-Wood needle holder. The surgeon takes the suture and begins to imbricate the costal beds. This method of overlapping the cartilages and retracting the pectoral muscles pulls the sternum downward and contracts the thoracic wall. The ST provides the electrosurgical pencil, irrigation, suction and suture scissors as requested throughout this process. Care is taken to change out soiled X-ray-detectable sponges as necessary.

Once the surgeon completes pulling the sternum downward with the suturing technique, the ST prepares two Davol evacuating drainage systems, one 1/4 inch and one 3/16 inch, for use, along with additional 2-0 polyglactin 910 suture to secure the drains. The surgeon takes the 1/4-inch Davol drain and places it under the pectoral muscle. It is then re-approximated and affixed to the periosteum of the sternum using the 2-0 polyglactin 910. The surgeon then takes the 3/16-inch Davol drain and places it in the subcutaneous space. Once the drains are in place, the surgeon closes the skin using 3-0 and 4-0 polyglactin 910 in the subcutaneous tissue, and 4-0 polyglucaprone 25 in the skin (dermis and epidermis). He or she administers local anesthetic (one percent lidocaine with epinephrine, 1:200,000) at the operative site to provide additional postoperative pain management and hemostasis.

The ST initiates a final count of sharps and sponges with the circulator during the skin closure and prepares the postoperative dressings. A wet and dry sponge is also readied in anticipation of cleaning the operative site once the skin closure is complete.

While the surgeon finishes up the skin closure, the ST ensures all pieces of the cartilage are in the specimen cup securely. The cup is labeled appropriately, according to facility policy, with the patient’s name, identification number, and the name of the specimen contents. This information is verified with the patient’s chart. The cup is then handed off to the circulator, who transports it to pathology in a dry state.

POSTOPERATIVE PROCEDURE

At the completion of the skin closure the surgeon requests a wet and dry X-ray-detectable sponge to clean off the patient’s

operative wound site and to remove any remaining skin prep solution. The ST assists the surgeon with this task. Once the wound has been cleaned, the ST hands the surgeon bacitracin antibiotic ointment (placed on the back of a tissue forceps handle), which the surgeon applies liberally onto the closed suture line. Using smooth Adson tissue forceps, pre-cut adhesive skin closure strips (the strips are cut into thirds per the surgeon's request) are then applied to the site followed by folded, sterile 4x4 dressings and padded tape.

Once the dressings are in place the ST carefully pulls back the Mayo stand and, in keeping with proper sterile technique, pushes the back table several feet away from the operative table as to allow for adequate room to remove drapes, disposable suction tubing and electrical cords from the field and provide space to move the patient to the gurney. After removing the disposable items, the ST removes his or her outer gloves and provides assistance in moving the patient off the operating table to the gurney. Once the patient is securely on the gurney and out of the operating room, the ST begins the postoperative clean up procedure.

All sharps (blades, hypodermic needles, suture needles and electrosurgical pencil tips) are verified with the count board and disposed of properly, according to facility policy, in the sharps container. Dirty instrumentation is separated from clean instrumentation. Dirty, sharp instrumentation is placed in a separated basin with sterile water while non-sharp, dirty instrumentation is placed in another basin with sterile water. Each of the basins is marked, according to facility policy, with the operating room number, the ST's initials, the time of the surgical procedure and the date. Clean instrumentation is returned to its set container with the lid on. All instrumentation is then placed in the dirty case cart. All sponges, disposable towels and items are rolled up in the back table cover and discarded. The facility's postoperative surgical team member (PST) removes the used suction canisters, takes out the waste containers and cleans and mops the operating room to prepare it for the next case. The ST doffs his or her gown and gloves, washes his or her hands and dons new nonsterile gloves. After ensuring all instrumentation is in placed in the case cart, the ST proceeds to the dirty dumb waiter and transfers the items to the facility's sterile processing and distribution center (SPD) for decontamination and sterilization. Upon return, the ST removes the gloves and washes his or her hands again. All unused core supplies are acquired from the operating room and returned to their specified locations in the sterile core.

PATIENT POSTOPERATIVE

At 15:37 hours, the patient arrives at PACU for recovery and stays for approximately one hour. He is in a semi-conscious state upon his arrival, where he is given 10 milligrams of hydrocodone for postoperative pain management. At approximately 16:40, the patient is transferred to his hospital room.¹⁵

The first night post-operatively, the patient reports several episodes of moderate to severe postoperative pain in the chest area. On a scale of one to 10, the patient advises that he is experiencing an eight. Consequently, the patient is given additional hydrocodone the following night to ease his symptoms and help him sleep. On the second postoperative day, the patient's pain has lessened and he is more comfortable than he had been the night before. On day three, the patient has his Davol drains removed and is discharged from the hospital. A two-week postoperative appointment is made for the patient.¹⁵

The patient and his parents are instructed on postsurgical at-home care. They are advised to keep the incision site clean and dry, and dressings are to be changed daily. Any signs of redness, swelling or puckering around the incision site are indications of infection and the parents are directed to contact the doctor immediately if this is the case. The patient is given a breathing treatment machine (spirometer) to improve lung function while healing.

The patient is directed to limit his physical activity level, particularly any twisting movements or rapid elevation of arms over his head for the next four months. The patient is given a list of lower extremity exercises that he is to perform for the next two weeks prior to his next postoperative checkup. He is told that light weights are beneficial for his upper extremities, but was to avoid lifting or carrying anything weighing more than 25 pounds. The patient will not be able to participate in any athletic activities for the next five months. Pain will be managed with ibuprofen and acetaminophen.

SPECIAL CONSIDERATIONS AND COMPLICATIONS

Postoperative complications for a repair of a *pectus carinatum* include hemorrhage, infection, pleural effusion, pneumothorax, keloid scarring and pain. Generally, a patient's hospital stay will be based on postoperative complications and pain management. An average hospital stay for this procedure is anywhere from three to seven days.¹

Although pain was a significant complication in the first night post-op, the patient in this case study showed marked

improvement in tolerance within 24 hours, and therefore his postoperative hospital stay was only three days. At the time of this report, the patient is healing as expected and no complications have been reported as of his last postoperative check up.¹⁵

For some patients, additional surgical intervention will be required in the future due to inadequate contracture of the chest wall that resulted in an undesirable cosmetic look. It is for this reason that it is desirable to wait for a child's skeletal system to reach maturity prior to surgical intervention.⁹

CONCLUSION

Aside from the apparent physiological problems resulting from a pectus abnormality, pediatric patients can have considerable emotional issues that affect their daily lives. As with the patient in the case study, although he did suffer occasional pain and discomfort related to the pectus carinatum, and consequently physical activities were cut short due to dyspnea, there was clearly a negative social impact that the deformity was having on his life. His self image and confidence were causing him to isolate from his peers and family members, and he was beginning to show progressive signs of clinical depression. Already having a past medical history of psychiatric behavioral issues, it was apparent that this physical abnormality was causing additional emotional stress on the child that could possibly have devastating consequences in the future if surgical intervention was not taken.

ABOUT THE AUTHOR



Tracy Cheek is a surgical technology student at San Joaquin Valley College in Fresno, California. Prior to going back to school to pursue this career, she spent 21 years in the fire service, working for the California Department of Forestry and Fire Protection. She is currently in her clinical externship at Children's Hospital of Central California and Community Regional Medical Center in Fresno, California.

References


1. Seattle Children's Hospital Research and Foundation (July 2010), *Pectus carinatum*. Retrieved on July 30, 2010 from <http://www.seattlechildrens.org/medical-conditions/bone-joint-muscle-conditions/pectus-carinatum/>.
2. UK Pectus Excavatum and Pectus Carinatum Information (2010), *Surgical treatment*. Retrieved on July 30, 2010 from <http://www.pectus.org/surgical.htm>.
3. Cataletto, M. (August 25, 2008). Pectus carinatum. Retrieved June 30, 2010 from <http://emedicine.medscape.com/article>.
4. Family Practice Notebook (2010), *Pectus carinatum*. Retrieved July 30, 2010 from <http://www.fpnotebook.com/lung/Exam/>.
5. Rothrock, J. (2007). *Alexander's care of the patient in surgery*, 13 ed, St. Louis, MI: Mosbey, Elsevier.
6. Cohen, B. (2009). *Memmler's the human body in health and disease*, 11th ed, USA: Lippincott, Williams, and Wilkins.
7. Wisegeek, (2010), What is pectus carinatum. Retrieved July 30, 2010 from <http://www.wisegeek.com/what-is-pectus-carinatum.htm>.
8. US National Library of Medicine. 2010. "Trisomy 18." Medline Plus. Accessed: August 18, 2010. Available at: <http://www.nlm.nih.gov/medlineplus/ency/article/001661.htm>.
9. Medline Plus (June 25, 2010), Pectus carinatum. Retrieved on July 2, 2010 from <http://www.nlm.nih.gov/medlineplus/ency/article/003321.htm>.
10. US National Library of Medicine. 2010. "Marfan syndrome." Medline Plus. Accessed: August 18, 2010. Available at: <http://www.nlm.nih.gov/medlineplus/ency/article/000418.htm>.
11. US National Library of Medicine. 2010. "Homocystinuria." Medline Plus. Accessed: August 18, 2010. Available at: <http://www.nlm.nih.gov/medlineplus/ency/article/001199.htm>.
12. US National Library of Medicine. 2010. "Morquio syndrome." Medline Plus. Accessed: August 18, 2010. Available at: <http://www.nlm.nih.gov/medlineplus/ency/article/001206.htm>.
13. US National Library of Medicine. 2010. "Multiple lentiginos syndrome." Medline Plus. Accessed: August 18, 2010. Available at: <http://www.nlm.nih.gov/medlineplus/ency/article/001473.htm>.
14. US National Library of Medicine. 2010. "Osteogenesis Imperfecta." Medline Plus. Accessed: August 18, 2010. Available at: <http://www.nlm.nih.gov/medlineplus/osteogenesisimperfecta.html>.
15. Children's Hospital of Central California. Patient Chart. 2010. Unpublished patient chart. Cincinnati Children's (2010), Chest/lungs diagnoses and conditions. Retrieved July 30, 2010. Available at: <http://www.cincinnatichildrens.org/health/info/chest/diagnose/pectus-carinatum.htm>.

Additional Resources

- Frey, K. (2008). *Surgical technology for the surgical technologist: a positive care approach*, 3rd ed, USA: Delmar Cengage Learning.
- Goldman, M. (2000). *Pocket guide to the operating room*, 3rd ed, Philadelphia, PA: F.A. Davis Company.

*Westcoast Brace & Limb, 5311 E Fletcher Ave, Tampa, FL 33617, 813-985-5000

CE EXAM



Earn CE Credits at Home

You will be awarded continuing education (CE) credits toward your recertification after reading the designated article and completing the test with a score of 70% or better. If you do not pass the test, it will be returned along with your payment.

Send the original answer sheet from the journal and make a copy for your records. If possible use a credit card (debit or credit) for payment. It is a faster option for processing of credits and offers more flexibility for correct payment. When submitting multiple tests, you do not need to submit a separate check for each journal test. You may submit multiple journal tests with one check or money order.

Members this test is also available online at www.ast.org. No stamps or checks and post to your record automatically!

Members: \$6 per credit

(per credit not per test)

Nonmembers: \$10 per credit

(per credit not per test plus the \$400 nonmember fee per submission)

After your credits are processed, AST will send you a letter acknowledging the number of credits that were accepted. Members can also check your CE credit status online with your login information at www.ast.org.

3 WAYS TO SUBMIT YOUR CE CREDITS

Mail to: AST, Member Services, 6 West Dry Creek Circle Ste 200 Littleton, CO 80120-8031

Fax CE credits to: 303-694-9169

E-mail scanned CE credits in PDF format to: memserv@ast.org

For questions please contact Member Services - memserv@ast.org or 800-637-7433, option 3. Business hours: Mon-Fri, 8:00a.m. - 4:30 p.m., mountain time

Pectus Carinatum: Pigeon Chest

323 NOVEMBER 2010 2 CE credit

- 1. Pectus Carinatum is characterized by a/an ___ of the sternum.**
 - a. Protrusion
 - b. Indentation
 - c. Fracture
 - d. A & C
- 2. Effects of pigeon chest include ___.**
 - a. Fatigue
 - b. Dyspnea
 - c. Psychological issues
 - d. All of the above
- 3. The surgical procedure can take anywhere from ___.**
 - a. 2-4 hours
 - b. 2-6 hours
 - c. 4-6 hours
 - d. None of the above
- 4. The Ravitch procedure has a ___ percent satisfaction rate among patients.**
 - a. 97
 - b. 87
 - c. 79
 - d. 92
- 5. Patients' cardiopulmonary function can be affected by ___.**
 - a. Mitral valve prolapsed
 - b. Decreased lung capacity
 - c. Impaired gas exchange in cardiopulmonary system
 - d. All of the above
- 6. The Ravitch procedure does not involve ___.**
 - a. Cutting the costal cartilage
 - b. Using a stabilization bar
 - c. External pressure brace
 - d. Removal of some costal cartilage
- 7. The ratio of males to females that develop pectus carinatum is ___.**
 - a. 3:1
 - b. 7:2
 - c. 6:2
 - d. 5:1
- 8. The principal organs of respiration and circulation are protected by the ___.**
 - a. Thorax
 - b. Pectoral muscles
 - c. Sternum
 - d. Thoracic vertebrae
- 9. The human body has ___ false ribs.**
 - a. Ten
 - b. Six
 - c. Three
 - d. Two
- 10. A chest deformity characterized by an inverted sternum is ___.**
 - a. Pectus carinatum
 - b. Pigeon chest
 - c. Pectus excavatum
 - d. All of the above
- 11. The intercostal spaces are located between the ___.**
 - a. Lungs
 - b. Ribs
 - c. Vertebral bodies
 - d. Costal cartilages
- 12. Pectus carinatum can present at which phase of a patient's life?**
 - a. At birth
 - b. Post surgically
 - c. During growth spurts
 - d. All of the above

13. Which genetic disorder is not considered a possible cause of pectus carinatum?

- a. Trisomy 21
- b. Morquio syndrome
- c. Brittle bone disease
- d. Scoliosis

14. One percent lidocaine with epinephrine, 1:200,000 describes ____.

- a. Sterile solution
- b. General anesthetic
- c. Local anesthetic
- d. Anxiety medication

15. In the case presented, the patient is in the ____ position for surgery.

- a. Reverse Trendelenburg
- b. Supine
- c. Trendelenburg
- d. None of the above

16. ____ is/are performed preoperatively to rule out genetic disorders.

- a. Blood tests
- b. Urine analysis
- c. X-ray
- d. ECG

17. The average hospital stay for this procedure is ____.

- a. 1-5 days
- b. 3-5 days
- c. 3-7 days
- d. 5-9 days

18. Preoperative diagnostic tests include ____.

- a. Pulmonary function
- b. CT scan
- c. Urine analysis
- d. All of the above

19. ____ is a genetic disorder in which the body cannot metabolize methionine.

- a. Homocystinuria
- b. Morquio syndrome
- c. Trisomy 18
- d. Marfan syndrome

20. Twisting movement or rapid elevation of the arms is restricted for ____.

- a. Two months
- b. Four months
- c. Six weeks
- d. Until postoperative checkup

PECTUS CARINATUM: PIGEON CHEST 323 NOVEMBER 2010 2 CE credit

NBSTSA Certification No. _____

AST Member No. _____

My address has changed. The address below is the new address.

Name _____

Address _____

City _____ State _____ Zip _____

Telephone _____

	a	b	c	d		a	b	c	d
1	<input type="checkbox"/>	<input type="checkbox"/>	<input type="checkbox"/>	<input type="checkbox"/>	11	<input type="checkbox"/>	<input type="checkbox"/>	<input type="checkbox"/>	<input type="checkbox"/>
2	<input type="checkbox"/>	<input type="checkbox"/>	<input type="checkbox"/>	<input type="checkbox"/>	12	<input type="checkbox"/>	<input type="checkbox"/>	<input type="checkbox"/>	<input type="checkbox"/>
3	<input type="checkbox"/>	<input type="checkbox"/>	<input type="checkbox"/>	<input type="checkbox"/>	13	<input type="checkbox"/>	<input type="checkbox"/>	<input type="checkbox"/>	<input type="checkbox"/>
4	<input type="checkbox"/>	<input type="checkbox"/>	<input type="checkbox"/>	<input type="checkbox"/>	14	<input type="checkbox"/>	<input type="checkbox"/>	<input type="checkbox"/>	<input type="checkbox"/>
5	<input type="checkbox"/>	<input type="checkbox"/>	<input type="checkbox"/>	<input type="checkbox"/>	15	<input type="checkbox"/>	<input type="checkbox"/>	<input type="checkbox"/>	<input type="checkbox"/>
6	<input type="checkbox"/>	<input type="checkbox"/>	<input type="checkbox"/>	<input type="checkbox"/>	16	<input type="checkbox"/>	<input type="checkbox"/>	<input type="checkbox"/>	<input type="checkbox"/>
7	<input type="checkbox"/>	<input type="checkbox"/>	<input type="checkbox"/>	<input type="checkbox"/>	17	<input type="checkbox"/>	<input type="checkbox"/>	<input type="checkbox"/>	<input type="checkbox"/>
8	<input type="checkbox"/>	<input type="checkbox"/>	<input type="checkbox"/>	<input type="checkbox"/>	18	<input type="checkbox"/>	<input type="checkbox"/>	<input type="checkbox"/>	<input type="checkbox"/>
9	<input type="checkbox"/>	<input type="checkbox"/>	<input type="checkbox"/>	<input type="checkbox"/>	19	<input type="checkbox"/>	<input type="checkbox"/>	<input type="checkbox"/>	<input type="checkbox"/>
10	<input type="checkbox"/>	<input type="checkbox"/>	<input type="checkbox"/>	<input type="checkbox"/>	20	<input type="checkbox"/>	<input type="checkbox"/>	<input type="checkbox"/>	<input type="checkbox"/>

Mark one box next to each number.
Only one correct or best answer can be selected for each question.