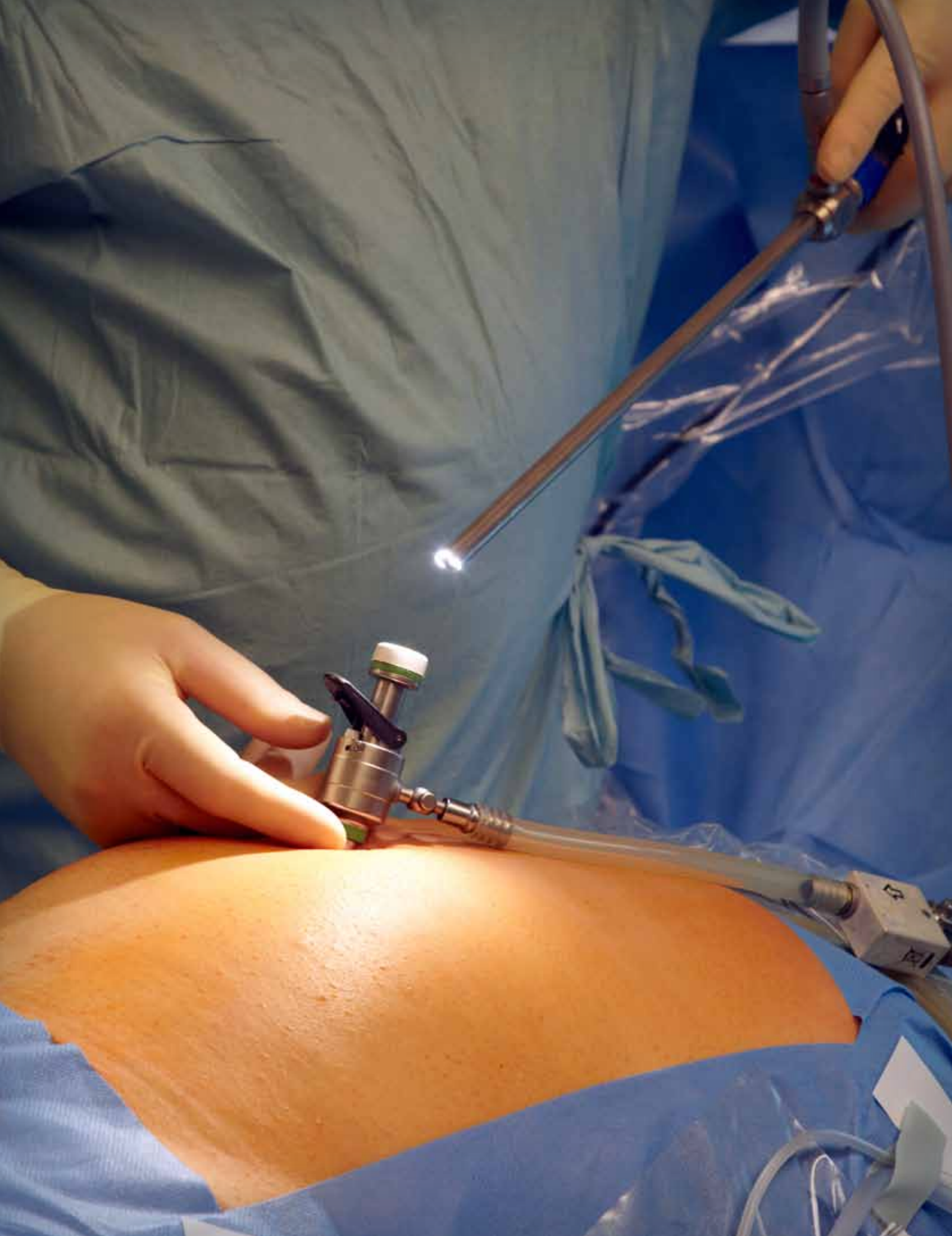



# Single-site Laparoscopic Total Hysterectomy

FREDERICO JOSÉ SILVA CORRÊA, MD

The latest advancement of laparoscopic minimally invasive surgery in the last couple years is the single port (SPL), also known as a single-incision laparoscopic surgery (SILS) or laparoendoscopy single site surgery (LESS surgery).<sup>9</sup> The LESS technique is laparoscopic surgery performed by only one incision, usually in the umbilical region. The laparoscope and tweezers are introduced through this single incision to perform the procedure. Initial studies have shown that the technique is reliable and applies to the areas of general surgery and urology.<sup>14,23</sup> The use of LESS in gynecologic surgeries is recent and the number of cases reported in the literature remains low, respectively. Still, pioneering groups have observed promising results with LESS in both, simpler procedures such as salpingectomy and oophorectomy, and more complex such as hysterectomies and pelvic lymphadenectomy.<sup>4,20</sup>

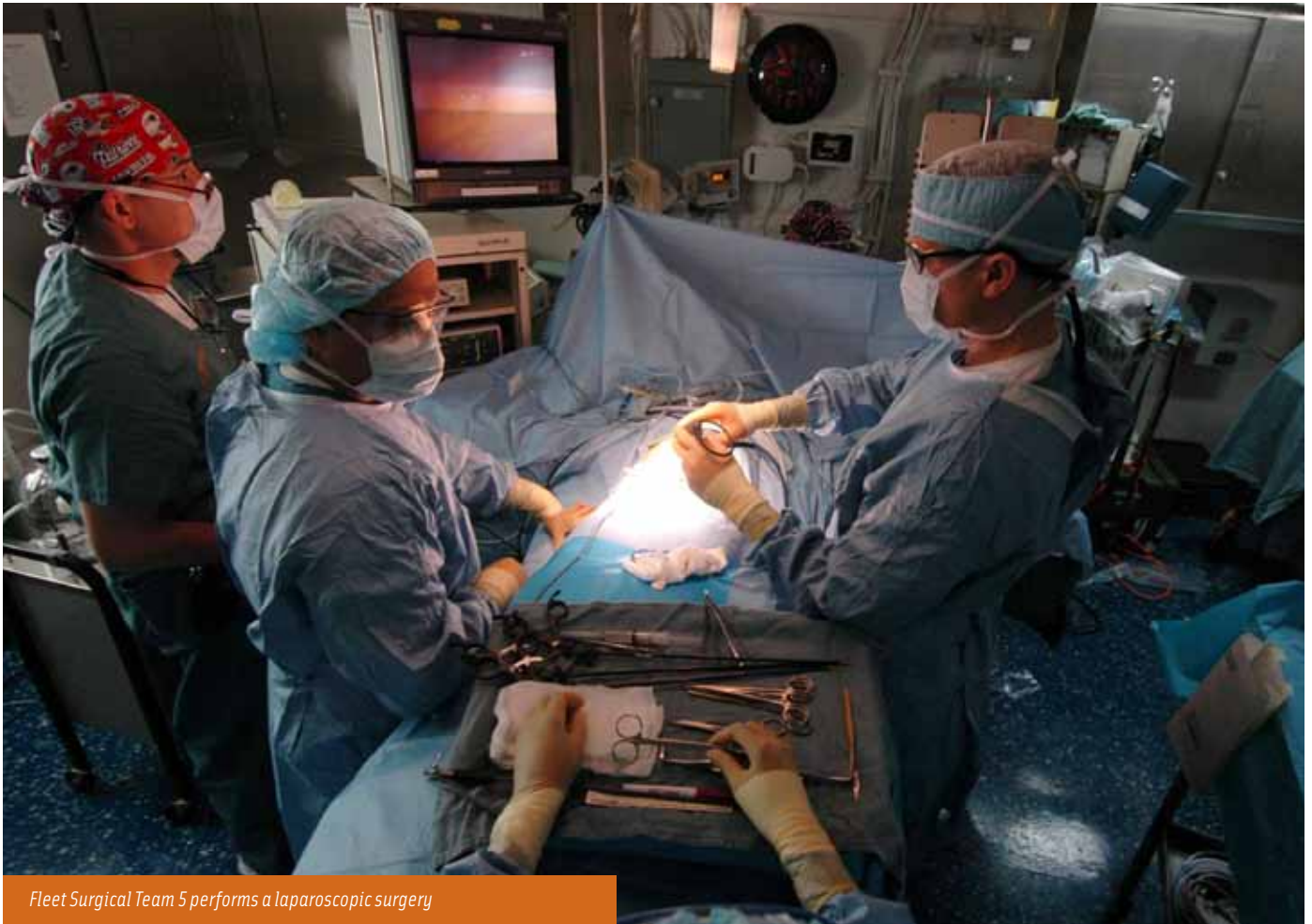## CASE DESCRIPTION

**P**atient, 44 years old, married, complaining of dysmenorrhea and chronic pelvic pain for about two years with progressive worsening. She presents hypermenorrhea and menorrhagia for one year. She was referred for hysterectomy with the diagnosis of diffuse adenomyosis. She had two normal pregnancies and two natural births. Her personal history includes a laparoscopy 11 years ago to treat fibroids and ovarian endometriosis. Her pap smear was negative for neoplastic cells.

On physical examination the patient was in good general condition, with body mass index of 29.6 kg/m<sup>2</sup>. Genital examination showed a normal vulva and vagina. The bimanual digital pelvic examination showed an anteversoflexion uterus (AVF), increased in size, mobile and with painful mobilization. The ovaries were normal in size and location without pain in mobilization. The pouch of Douglas exam was painful but without palpable nodules. The patient underwent a transvaginal ultra-

## LEARNING OBJECTIVES

- ▲ Determine what equipment is necessary when performing a laparoendoscopy single site total hysterectomy
- ▲ Identify the appropriate instruments needed for this operation
- ▲ Note the postoperative considerations and possible complications
- ▲ Discuss the history and timeline of LESS procedures
- ▲ Access the benefits of laparoendoscopic surgeries



*Fleet Surgical Team 5 performs a laparoscopic surgery*

Courtesy US Navy

sound examination that showed an AVF uterus, heterogeneous myometrium with echogenic areas, diffuse and isolated cystic areas in the anterior wall that is thickened. Uterine volume is 142cm<sup>3</sup>. Endometrium was echogenic, regular with 11mm thick. Normal ovaries. After the diagnosis of diffuse adenomyosis, clinical treatment introduced. It was done using continuous combined estrogen and progesterone contraceptive pills, continuous oral progesterone or anti-inflammatory drugs. However, no significant improvement of clinical symptoms was observed and side effects hormone therapy forced discontinuation of treatment. It was then indicated a total hysterectomy. After orientation, the patient opted for laparoscopic hysterectomy. The patient was offered the possibility of LESS surgery that was accepted by patient. Prior to the appointment and the procedure, the patient signed an informed consent form (ICF) for surgery and another ICF allowing the publication of the case.

The laparoscope 10 mm with flexible tip was introduced through the channel port and then a 5mm curved forceps and an ultrasonic scalpel was introduced into the other two channels.

#### OPERATIVE PROCEDURE

The patient went under general anesthesia with endotracheal intubation and was placed in a supine position with legs parted. After antisepsis, a vesical catheterization was performed. A disposable intrauterine manipulator was

introduced and a scalpel was used to perform a 2.5 cm longitudinal incision to open the peritoneal cavity. A LESS port disposable model was introduced and carried through the CO<sub>2</sub> infusion to formation of pneumoperitoneum. After establishing the pneumoperitoneum pressure of 14mmHg, the patient was placed in lithotomy with Trendelenburg to displace and protect the rectum and bowel. The laparoscope 10 mm with flexible tip was introduced through the channel port and then a 5mm curved forceps and an ultrasonic scalpel was introduced into the other two channels.

With the entire abdominal cavity in view, the hysterectomy procedure begins. An ultrasonic scalpel is used to perform the ligation and section of the adnexal pedicles and round ligaments. The broad ligaments and peritoneum fold of the bladder are held as the bladder is lowered. The uterine arteries are identified, ligated and divided with an ultrasonic scalpel, followed by the opening of the vagina and removing the uterus. The vagina is anchored to the uterosacral and cardinal ligaments with a laparoscopic needle holder and an absorbable suture. Once this step is complete, the uterus and adnexa are removed and the closing of the vagina begins. Trocars remain in place and the abdomen is re-sufflated with CO<sub>2</sub> and the surgeon checks for hemostasis. The pelvis is irrigated and suctioned and the pneumoperitoneum is released. The trocars are released and the umbilical incision was closed with stitches in the aponeurosis with polyglactin 910 and 4-0 suture.

## POST-OP

This surgery was uneventful, and the patient recovered well after surgery with no complaints of significant pain and showed no immediate complications. The patient was discharged in good condition within 40 hours postoperatively.

## OTHER POSTOPERATIVE CONSIDERATIONS

Patients are transferred to the PACU and monitored for fluid maintenance and pain. A liquid diet is recommended for 12 to 24 hours following the operation to assist with limiting nausea and slowing of gastrointestinal activity. The bladder may be drained if spontaneous voiding does not occur. After the patient is given a good prognosis, he or she may return to normal activities within a week.

Complications from this procedure can include hemorrhaging, failed LAVH and conversion to laparotomy, injury to major blood vessels, bowel injury, ureteral injury, bladder

## VAGINAL AND LAPAROSCOPICALLY ASSISTED VAGINAL HYSTERECTOMY (LAVH)

### Equipment

Allen stirrups  
Electrosurgical unit  
SCD pump  
Video system  
Laparoscopic irrigator/suction  
Bipolar generator

### Instruments

GYN laparoscopy set  
Laparotomy instrument set  
Abdominal hysterectomy set  
D&C set  
Camera

### Supplies

LAVH supplies including any disposable or nondisposable laparoscopic supplies such as trocars, Veress needle, acorn cannula, endoscopic scissors, graspers, dissectors  
Gloves  
Surgeon-specific sutures  
Blades  
Basin set  
Dressing material according to surgeon preference  
LAVH drape

### Operative Preparation

#### **Anesthesia**

- General anesthetic

#### **Position**

- Low lithotomy position  
with Allen stirrups

#### **Prep**

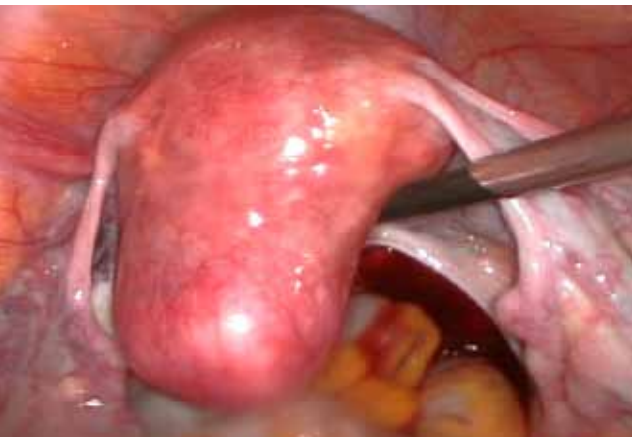
- Abdominal and vaginal prep  
- Patient is catheterized

#### **Draping**

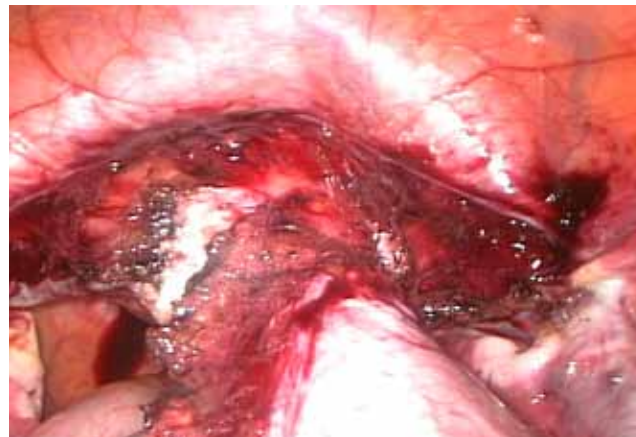- Drape sheet under the buttocks  
- Leggings  
- LAVH Laparoscopic drape sheet (may have attached leggings)

#### **Practical Considerations for Surgical Technologist**

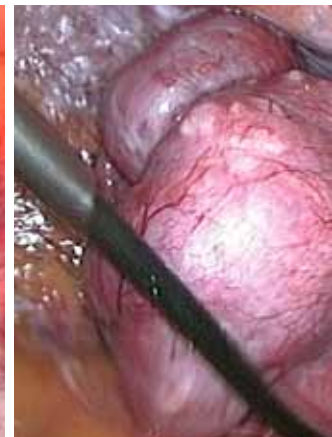
Check all equipment and supplies prior to patient's arrival



Uterus before hysterectomy



During laparoscopic hysterectomy



Total Lap Hysterectomy

## PATIENT SAFETY – LITHOTOMY POSITION

### Potential Hazards

### Precautionary Action(s)

Crushing or shearing injury to the head

- Place arms on armboards
- If arms are positioned at the patient's sides, the hands must be observed during movement of the operating table.

Pressure injury to skin, blood vessels and nerves

- Pad feet and ankles
- Be sure restraining devices are not restrictive
- Avoid excessive torsion, flexion or extension of any part of the patient's body
- The legs may not come in direct contact with the stirrups
- Adjust stirrups to an equal height and length
- Raise and lower legs slowly and simultaneously by two individuals

Back, knee and hip pain

- Buttocks should rest completely on the operating table
- Adjust stirrups to an equal height and length
- Raise and lower legs slowly and simultaneously by two individuals

Blood pressure changes

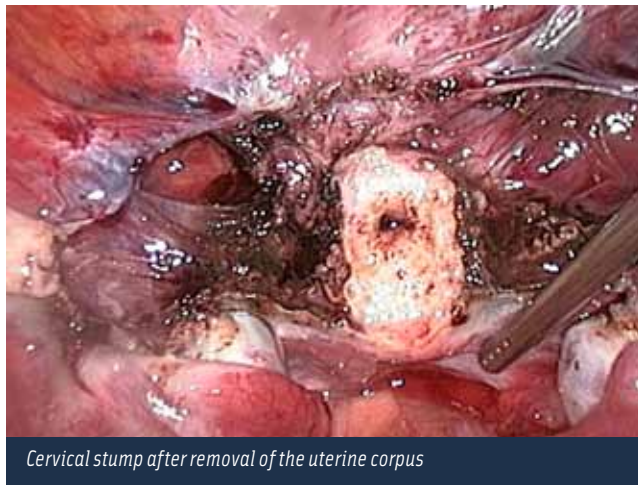
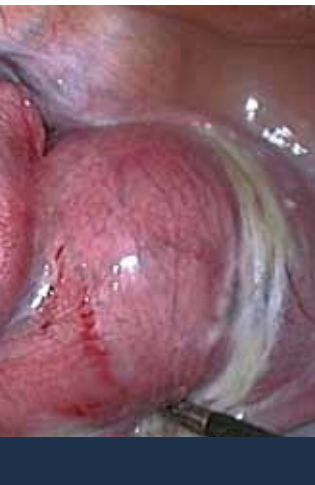- Raise and lower legs slowly and simultaneously by two individuals

Venous stasis

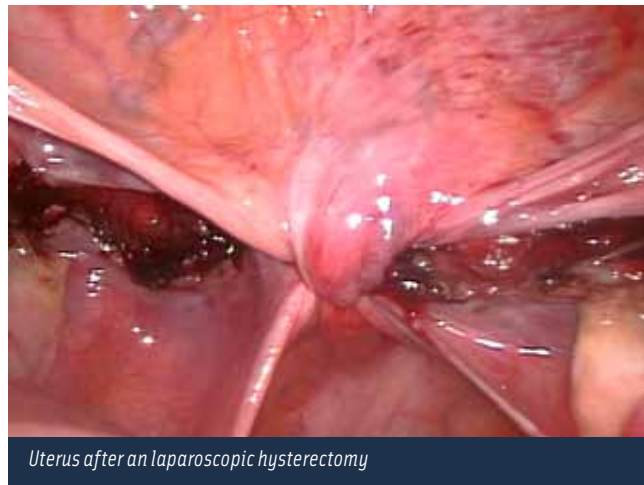
- Use antiembolic devices

Cardiovascular and respiratory compromise

- Restrict accompanying use of Trendelenburg's position
- Decrease leg height and hip flexion
- Return patient to the supine position as soon as possible



Cervical stump after removal of the uterine corpus



Uterus after a laparoscopic hysterectomy

injury, wound infection and hernias at trocar sites. A long-term complication from this surgery can include developing vesicovaginal or enterovaginal fistulas.

#### AN OVERVIEW OF LESS

The first laparoscopic surgeries were performed by single port. Wheeler reported more than 4,000 cases of rapid and effective surgical sterilization by laparoscopy with only a single trocar incision<sup>28,29</sup> about 20 years after the first complex procedure by a single trocar that resulted in a supracervical hysterectomy in four patients.<sup>22</sup> However, the technique did not become a standard procedure at that time. The initial difficulties related to a lack of appropriate instrumentation, which evolved into the LESS stagnation.

In recent years there has been an increase in the interest of surgeons for the surgery by single port. The development of specific instruments and equipment for the LESS has contributed in the evolution of the technique. Reproducibility and safety of new materials has allowed the improvement of skill and performance of procedures of greater complexity.<sup>26</sup> LESS surgery has been used in several procedures such as cholecystectomy, appendectomy, nephrectomy, colectomy, adrenalectomy, liver resection and bariatric surgery among others. Although, overall, fewer gynecological surgeries have been carried out by LESS.

Kosumi *et al*, in 2001, carried out laparoscopic ovar-

ian cystectomy for a single incision.<sup>15</sup> Then, Ghezzi *et al*, reported a successful single port surgery for the surgical treatment of ectopic pregnancy in 10 patients.<sup>8</sup> Lim *et al*, in 2009, reported the use of LESS in the treatment of 12 patients with benign adnexal tumor and had no complications.<sup>19</sup> Also in 2009, Kim *et al*, also reported 24 cases of surgery with the LESS approach in adnexal tumors without intraoperative complications.<sup>13</sup>

In 2009, Lee *et al*, reported performing 24 laparoscopically assisted vaginal hysterectomies with LESS. Langebrekke *et al*, in the same year reported the first case of laparoscopic total hysterectomy through single incision.<sup>16</sup> A camera and a multiple port device was used at the time. The suture of the vaginal vault was performed laparoscopi-

LESS surgery has been used in several procedures such as cholecystectomy, appendectomy, nephrectomy, colectomy, adrenalectomy, liver resection and bariatric surgery among others.

cally. In the following year, Yoon *et al*, reported performing supracervical hysterectomy by LESS with transcervical morcellation of the uterus.<sup>31</sup>

Kim *et al*, recently published a comparative study between LESS and conventional laparoscopy in cases of assisted vaginal laparoscopic hysterectomy.<sup>12</sup> The patients who underwent LESS surgery had a lower score on the visual analog scale of pain post-surgery at 24 and 36 hours.<sup>12</sup>

Yim *et al*, published a study comparing hysterectomy for LESS (52 patients) and conventional laparoscopic hysterectomy (105 patients).<sup>30</sup> The LESS group showed less intraoperative blood loss, shorter hospital stays and earlier introductions of solid diets. However, complications rates did not vary from each study. Chen *et al*. in 2011, published a randomized trial comparing LESS (50 cases) and conventional laparoscopic cases of laparoscopic assisted vaginal hysterectomy (50 cases).<sup>3</sup> The authors concluded that there was no difference in operative time, blood loss, length of hospital stay and complication rate between the groups. However, the LESS group had less postoperative pain than the other group.

Jung *et al*, in a prospective randomized study of 68 patients who underwent conventional laparoscopy surgery or LESS, observed no significant difference in pain

for more auxiliary incisions in conventional laparoscopy in theory reduces the inherent risks in such punctures (bleeding, perforation of viscera or vessel and infection). Other advantages are the least reported postoperative pain, faster recovery times and shorter hospitalizations. However, these advantages still require confirmation with more studies,<sup>6</sup> but this specific case confirms that the surgical technique for single portal is feasible, safe and reproducible and opens new perspectives in the treatment of gynecological diseases with minimally invasive surgical procedures.

## ABOUT THE AUTHOR

Frederico José Silva Corrêa, MD, is medical graduate from the Federal University of Goiás. His surgical specialities include gynecology and laparoscopic procedures.

... the surgical technique for single portal is feasible, safe and reproducible and opens new perspectives in the treatment of gynecological diseases with minimally invasive surgical procedures.

scores between groups. However, the LESS group used more analgesics than the laparoscopic conventional group.<sup>11</sup>

A recent study by Escobar *et al*, demonstrated the use of LESS surgery in gynecological oncology surgeries.<sup>5</sup> Twenty-one patients underwent pelvic and para-aortic lymphadenectomy staging for endometrial cancer and ovarian cancer. The authors concluded that the technique was feasible for such cases and that further studies should be conducted to assess the possible benefits of the new technique.


## THE FUTURE

The possible advantages of using LESS surgery are related to reducing the number of auxiliary punctures. The effect of cosmetic (aesthetic) is a reality but can be quite questionable. The performance of only one umbilical incision of 20mm in LESS against the need

## REFERENCES

1. Bucher P, Pugin F, Morel P. Single-port access laparoscopic radical left colectomy in humans. *Dis Colon Rectum*. 2009;52:1797-1801.
2. Bucher P, Pugin F, Morel P. Single port access laparoscopic right hemicolectomy. *Int J Colorectal Dis*. 2008;23:1013-1016.
3. Chen YJ, Wang PH, Ocampo EJ, Twu NF, Yen MS, Chao KC. Single-port compared with conventional laparoscopic-assisted vaginal hysterectomy: a randomized controlled trial. *Obstet Gynecol*. 2011;117(4):906-912.
4. Escobar PF, Bedaiwy MA, Fader AN, Falcone T. Laparoendoscopic single-site (LESS) surgery in patients with benign adnexal disease. *Fertil Steril*. 2010;93:2074e7-2074e10.
5. Escobar PF, Fader AN, Rasool N, Espalliat LR. Single-Port Laparoscopic Pelvic and Para-Aortic Lymph Node Sampling or Lymphadenectomy Development of a Technique and Instrumentation. *Int J Gynecol Cancer*. 2010;20:1268-1273.
6. Escobar PF, Starks D, Fader AN, Catenacci M, Falcone T. Laparoendoscopic single-site and natural orifice surgery in gynecology. *Fertil Steril*. 2010;94:2497-2502.
7. Frumovitz M, Ramirez PT, Greer M, et al. Laparoscopic training and practice in gynecologic oncology among Society of Gynecologic Oncologists members and fellows-in-training. *Gynecol Oncol*. 2004;94:746-753.
8. Ghezzi F, Cromi A, Fasola M, Bolis P. One-trocar salpingectomy for the treatment of tubal pregnancy: a "marionette-like" technique. *BJOG*. 2005;112:1417-1419.
9. Gill IS, Advincula AP, Aron M, et al. Consensus statement of the consortium for laparoendoscopic single-site surgery. *Surg Endosc*. 2010;24:762-768.
10. Hernandez JM, Morton CA, Ross S, Albrink M, Rosemurgy AS. Laparoendoscopic single site cholecystectomy: the first 100 patients. *Am Surg*. 2009;75:681-686.
11. Jung YW, Lee M, Yim GW, Lee SH, Paek JH, Kwon HY, Nam EJ, Kim SW, Kim YT. A randomized prospective study of single-port and four-port approaches for hysterectomy in terms of postoperative pain. *Surg Endosc*. 2011.
12. Kim TJ, Lee YY, Cha HH, et al. Single-port-access laparoscopic-assisted vaginal hysterectomy versus conventional laparoscopic-assisted vaginal hysterectomy: a comparison of perioperative outcomes. *Surg Endosc*. 2010.
13. Kim TJ, Lee YY, Kim MJ, et al. Single port access laparoscopic adnexal surgery. *J Minim Invasive Gynecol*. 2009;16:612-615.

14. Kommu SS, Kaouk JH, Rane A. Laparo-endoscopic single-site surgery: preliminary advances in renal surgery. *BJU Int.* 2009;103:1034-1037.
15. Kosumi T, Kubota A, Usui N, Yamauchi K, Yamasaki M, Oyanagi H. Laparoscopic ovarian cystectomy using a single umbilical puncture method. *Surg Laparosc Endosc Percutan Tech.* 2001;11:63-65.
16. Langebrekke A, Qvigstad E. Total laparoscopic hysterectomy with single-port access without vaginal surgery. *J Minim Invasive Gynecol.* 2009;16:609-611.
17. Langwieler TE, Nimmesgern T, Back M. Single-port access in laparoscopic cholecystectomy. *Surg Endosc.* 2009;23:1138-1141.
18. Lee YY, Kim TJ, Kim CJ, et al. Single-port access laparoscopic-assisted vaginal hysterectomy: a novel method with a wound retractor and a glove. *J Minim Invasive Gynecol.* 2009;16:450-453.
19. Lim MC, Kim TJ, Kang S, Bae DS, Park SY, Seo SS. Embryonic natural orifice transumbilical endoscopic surgery (E-NOTES) for adnexal tumors. *Surg Endosc.* 2009;23:2445-2449.
20. Mereu L, Angioni S, Melis GB, Mencaglia L. Single access laparoscopy for adnexal pathologies using a novel reusable port and curved instruments. *Int J Gynaecol Obstet.* 2010;109:78-80.
21. Nieboer TE, Johnson N, Lethaby A, et al. Surgical approach to hysterectomy for benign gynaecological disease. Cochrane Database System Review. 2009;CD003677.
22. Pelosi MA, Pelosi MA. Laparoscopic supracervical hysterectomy using a single-umbilical puncture (mini-laparoscopy). *J Reprod Med.* 1992;37:777-784.
23. Podolsky ER, Rottman SJ, Poblete H, King SA, Curcillo PG. Single port access (SPA) cholecystectomy: a completely transumbilical approach. *J Laparoendosc Adv Surg Tech.* 2009;19:219-22.
24. Raman JD, Bagrodia A, Cadeddu JA. Single-incision, umbilical laparoscopic versus conventional laparoscopic nephrectomy: a comparison of perioperative outcomes and short-term measures of convalescence. *Eur Urol.* 2009;55:1198-1204.
25. Tacchino RM, Greco F, Matera D, Diflumeri G. Single-incision laparoscopic gastric bypass for morbid obesity. *Obes Surg.* 2010;20:1154-1160.
26. Uppal S, Frumovitz M, Escobar P, Ramirez PT. Laparoendoscopic single-site surgery in gynecology: review of literature and available technology. *J Minimally Invasive Gynecol.* 2011;18:12-23.
27. Walz MK, Groeben H, Alesina PF. Single-access retroperitoneoscopic adrenalectomy (SARA) versus conventional retroperitoneoscopic adrenalectomy (CORA): a case-control study. *World J Surg.* 2010;34:1386-1390.
28. Wheelless CR. A rapid, inexpensive and effective method of surgical sterilization by laparoscopy. *J Reprod Med.* 1969;3:65-69.
29. Wheelless Jr CR, Thompson BH. Laparoscopic sterilization. Review of 3600 cases. *Obstet Gynecol* 1973;42:751-758.
30. Yim GW, Jung YW, Paek J, et al. Transumbilical single-port access versus conventional total laparoscopic hysterectomy: surgical outcomes. *Am J Obstet Gynecol.* 2010;203:26e1-26e6.
31. Yoon G, Kim TJ, Lee YY, et al. Single-port access subtotal hysterectomy with transcervical morcellation: a pilot study. *J Minim Invasive Gynecol.* 2010;17:78-81.



### Earn CE Credits at Home

You will be awarded continuing education (CE) credits toward your recertification after reading the designated article and completing the test with a score of 70% or better. If you do not pass the test, it will be returned along with your payment.

Send the original answer sheet from the journal and make a copy for your records. If possible use a credit card (debit or credit) for payment. It is a faster option for processing of credits and offers more flexibility for correct payment. When submitting multiple tests, you do not need to submit a separate check for each journal test. You may submit multiple journal tests with one check or money order.

**Members this test is also available online** at [www.ast.org](http://www.ast.org). No stamps or checks and it posts to your record automatically!

**Members: \$6 per credit**  
(per credit not per test)

**Nonmembers: \$10 per credit**  
(per credit not per test plus the \$400 nonmember fee per submission)

After your credits are processed, AST will send you a letter acknowledging the number of credits that were accepted. Members can also check your CE credit status online with your login information at [www.ast.org](http://www.ast.org).

### 3 WAYS TO SUBMIT YOUR CE CREDITS

**Mail to:** AST, Member Services, 6 West Dry Creek Circle Ste 200, Littleton, CO 80120-8031

**Fax CE credits to:** 303-694-9169

**E-mail scanned CE credits in PDF format to:**  
[memserv@ast.org](mailto:memserv@ast.org)

For questions please contact Member Services - [memserv@ast.org](mailto:memserv@ast.org) or 800-637-7433, option 3.  
Business hours: Mon-Fri, 8:00a.m. - 4:30 p.m., MT



# SINGLE-SITE LAPAROSCOPIC TOTAL HYSTERECTOMY

343 July 2012 1 CE credit - \$6

1. **Advantages of laparoscopic surgeries include \_\_\_\_\_.**
  - a. Shorter hospital stays
  - b. Shorter recovery time
  - c. Fewer complications
  - d. All of the above
2. **The patient needs to be placed in the \_\_\_\_\_ position for a single-site laparoscopic hysterectomy.**
  - a. Supine
  - b. Lithotomy
  - c. Reverse Trendelenburg
  - d. Kraske
3. **A \_\_\_\_\_ is used to perform ligation of the round ligaments.**
  - a. Electrosurgical pencil
  - b. Scissors
  - c. Ultrasonic scalpel
  - d. Curved Forceps
4. **Trocars remain in place as the surgeon checks for \_\_\_\_\_.**
  - a. Hemostasis
  - b. Instruments
  - c. Blood pressure
  - d. Hemolysis
5. **Complications from this procedure can include \_\_\_\_\_.**
  - a. Bowel injury
  - b. Loss of appetite
  - c. Nausea
  - d. Loss of vision
6. **With some of the studies that have been conducted, one of the biggest benefits for patients undergoing LESS procedures is \_\_\_\_\_.**
  - a. Less operation time
  - b. Less blood loss
  - c. Less prep time
  - d. Less postoperative pain
7. **Following the procedure, the patient is monitored for \_\_\_\_\_.**
  - a. Fluid maintenance
  - b. Pain
  - c. Nausea
  - d. All of the above
8. **If spontaneous voiding does not occur following the operation, the \_\_\_\_\_ may be drained.**
  - a. Wound site
  - b. Bladder
  - c. Bowels
  - d. Stomach
9. **During the procedure, a \_\_\_\_\_ incision is performed to open the peritoneal cavity.**
  - a. Lateral
  - b. Distal
  - c. Longitudinal
  - d. Inferior
10. **The pneumoperitoneum is released after the pelvis is \_\_\_\_\_ and suctioned.**
  - a. Washed
  - b. Irrigated
  - c. Suctioned
  - d. Scrubbed

## SINGLE-SITE LAPAROSCOPIC TOTAL HYSTERECTOMY 343 July 2012 1 CE credit - \$6

NBSTSA Certification No. \_\_\_\_\_

AST Member No. \_\_\_\_\_

My address has changed. The address below is the new address.

Name \_\_\_\_\_

Address \_\_\_\_\_

City \_\_\_\_\_ State \_\_\_\_\_ Zip \_\_\_\_\_

Telephone \_\_\_\_\_

Check enclosed  Check Number \_\_\_\_\_

Visa  MasterCard  American Express

Credit Card Number \_\_\_\_\_

Expiration Date \_\_\_\_\_

	a	b	c	d
1	<input type="checkbox"/>	<input type="checkbox"/>	<input type="checkbox"/>	<input type="checkbox"/>
2	<input type="checkbox"/>	<input type="checkbox"/>	<input type="checkbox"/>	<input type="checkbox"/>
3	<input type="checkbox"/>	<input type="checkbox"/>	<input type="checkbox"/>	<input type="checkbox"/>
4	<input type="checkbox"/>	<input type="checkbox"/>	<input type="checkbox"/>	<input type="checkbox"/>
5	<input type="checkbox"/>	<input type="checkbox"/>	<input type="checkbox"/>	<input type="checkbox"/>
6	<input type="checkbox"/>	<input type="checkbox"/>	<input type="checkbox"/>	<input type="checkbox"/>
7	<input type="checkbox"/>	<input type="checkbox"/>	<input type="checkbox"/>	<input type="checkbox"/>
8	<input type="checkbox"/>	<input type="checkbox"/>	<input type="checkbox"/>	<input type="checkbox"/>
9	<input type="checkbox"/>	<input type="checkbox"/>	<input type="checkbox"/>	<input type="checkbox"/>
10	<input type="checkbox"/>	<input type="checkbox"/>	<input type="checkbox"/>	<input type="checkbox"/>

Take CE exams online and have credits post automatically to your file! You just need a credit card. No more waiting and checking your file to see if credits have posted. Just log on to your account on our home page, [www.ast.org](http://www.ast.org), to take advantage of this option!

Mark one box next to each number.  
Only one correct or best answer can be selected for each question.