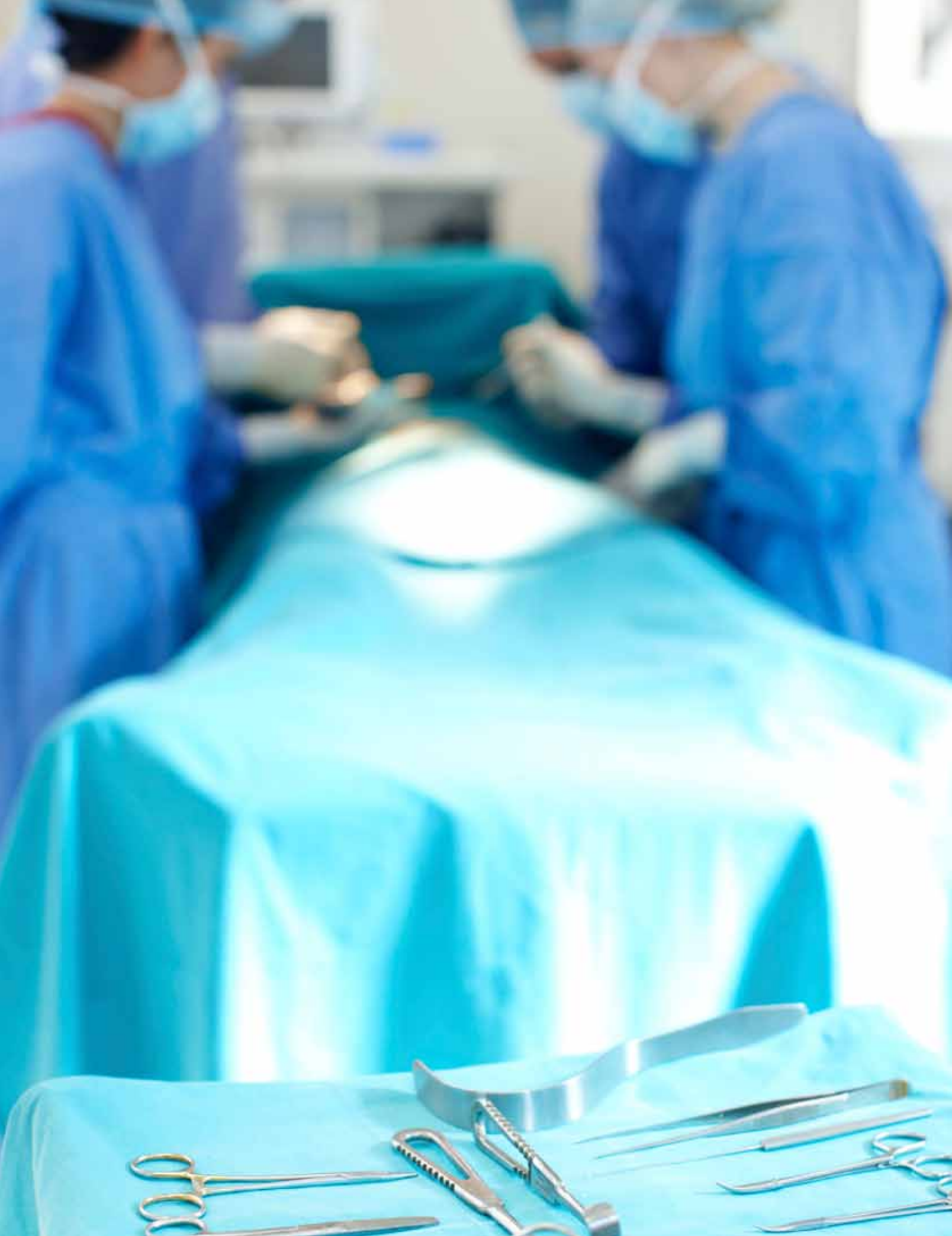



Hepatectomy to Treat Hepatocellular Cancer

Mary Graham, CST

A hepatectomy is the surgical removal of a segment of the liver, or the liver in its entirety. Hepatectomies are performed to surgically remove tumors that are hepatocellular carcinoma or malignant hepatoma. Any part of the liver – an entire lobe or the whole liver – which contains a tumor, will be removed. If a partial hepatectomy is performed, healthy margins of liver tissue will be saved to maintain the normal functions of the liver. When a total hepatectomy is performed, a liver transplant will be needed in order for the patient to survive.⁹

INDICATIONS FOR A HEPATECTOMY

Indications for a hepatectomy include trauma, cysts and tumors that are benign, or that present as liver cancer. Trauma to the liver may be caused by many different ways and are categorized by open or closed traumatic injury to the liver. Most often seen are open injuries to the liver which include stab wounds and gunshot wounds. Closed traumatic injuries to the liver include blunt abdominal trauma, mainly due to impact. Motor vehicle accidents, collapsed buildings, falls from extreme heights, sports injuries and assault can all contribute to closed traumatic injuries to the liver.⁸

Cysts on the liver are usually presented as fluid-filled cavities that are located sporadically. There usually are rare signs and symptoms eliminating the need for treatment or surgical removal. Cysts may enlarge and cause discomfort and pain causing a need for an incision and drainage or surgical removal. There are currently no known causes for liver cysts. Most cysts found on the liver are congenital. Liver cysts seldom indicate serious underlying conditions such as polycystic liver disease, a parasitic

LEARNING OBJECTIVES

- ▲ Review the role of the surgical technologist in this procedure
- ▲ List instruments and equipment needed for a hepatectomy
- ▲ Evaluate the indications calling for a hepatectomy to be performed
- ▲ Learn the steps of a hepatectomy procedure as it relates to hepatocellular cancer
- ▲ Identify the post-op protocol and possible complications for such an operation

infection called Echinococcus or liver cancer.¹⁰ Tumors of the liver can be benign or malignant. There are two broad categories of malignant liver tumors. Primary tumors are tumors that originate in the liver. The most common primary tumor of the liver is hepatocellular carcinoma, which also may be known as hepatoma. Patients who suffer from cirrhosis, chronic hepatitis or long-term alcohol abuse may be at risk for hepatocellular carcinoma. Secondary liver tumors are tumors that have been spread to the liver from other surrounding organs or tissues that were affected with cancer. Many of these tumors may be treated with systemic chemotherapy. When systemic chemotherapy is not successful, a hepatectomy is advised.¹

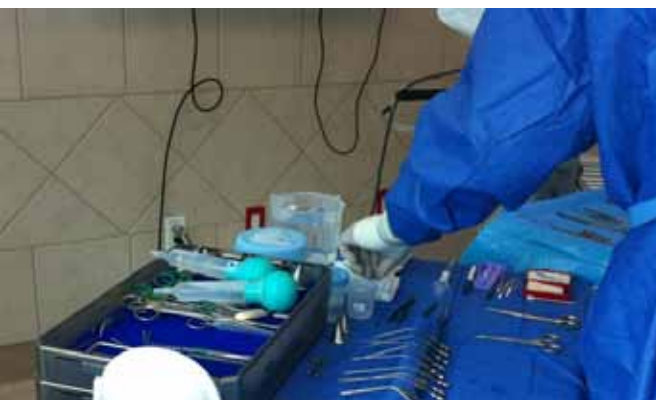The following article will describe a hepatectomy procedure detailing the role of the surgical technologist.

SETTING UP THE STERILE FIELD

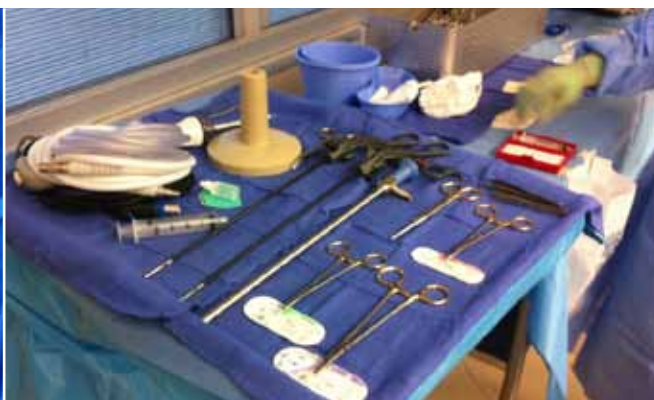For this particular case, the surgical technologist started setting up the sterile field by donning a face mask with attached eye protection and announcing that she was “opening” to the other surgical team members that were currently in the OR. The rest of the surgical team members also donned a face mask with eye protection. All of the needed supplies were opened starting with the draping of the back table, as well as the extra back table and double ring stand.

Mayo stand was draped and covered with two blue towels. The fluid warmer was carefully draped and filled with 0.9% saline for irrigation by the circulating nurse while verbalizing along with the surgical technologist the name, concentration strength and expiration date. All other supplies including the drapes, gowns, etc, were organized. The instruments were opened by the surgical technologist while the circulating nurse checked the wrapping for any tears. This procedure was repeated for each instrument tray that was opened. After establishing that the instruments were sterile, they were placed on the back table and organized for efficient use during the procedure. All sharps were arranged in the right lower corner of the main back table. The circulating nurse poured 0.25% bupivacaine hydrochloride and epinephrine solution into a medicine cup to use for a local anesthetic that would be injected into the incision site. The medication’s name, concentration strength and expiration date was verbally verified by the circulating nurse and the surgical technologist. The surgical technologist wrote out a label for the medicine cup and the 12 cc controlled release syringe stating the name, concentration strength, expiration date and the surgical technologists initial’s. The medication was drawn up and set aside by the sharps for easy accessibility. After all the instruments were organized, an instrument count was performed. After the count was complete,

the circulating nurse wrote on a dry erase board how many sponges, sharps, vessel loops and umbilical loops were counted so that it could be easily seen throughout



Back table setup



Back table setup

After all needed supplies were opened onto the back tables, the surgical technologist went outside of the OR to the sink area to perform a surgical hand scrub. A 10-stroke surgical hand scrub was performed and the surgical technologist proceeded back into the OR carefully so not to contaminate herself, dried her arms and donned the surgical gown and gloves. The surgical technologist approached one of the back tables and began to organize the sterile field. Two sterile sheets were draped over both of the back tables. The

the procedure, as well as noted if any additions were added. The sterile field was ready for the patient to enter the OR.

PREOPERATIVE PREPARATION

The circulating nurse and anesthesia provider transported the patient from the pre-op holding area into the OR. While the patient was being wheeled in, the circulating nurse introduced the patient to the surgical technologist and explained what her role would be during the procedure. The

patient was assisted while being transferred from the gurney to the operating table by the circulating nurse and anesthesia provider. The patient was placed in supine position with both of her arms extended on armboards. The ulnar nerve plexus was padded and protected with a foam ulnar pad, on both arms. A safety strap was applied at about two inches above the wrist to prevent the arms from falling off of the boards. Both legs were extended straight on the operating bed with both ankles padded with foam ankle pads. A pillow was placed under both knees. A safety strap was placed at about two inches above the knees to prevent the patient from sliding off the operating table when it was moved. A sequential compression device was applied to the patient's legs to aid in the prevention of intraoperative thrombosis. A full-body warming blanket was applied to maintain the patient's optimal body temperature. A pulse oximeter was applied to the patient's left index finger to measure intraoperative arterial blood gases. The anesthesia provider began the induction of general anesthesia by applying a face mask to the patient's nose and mouth.

About 10 minutes after the induction of general anesthesia, the circulator inserted a Foley catheter so that the patient's bladder could be controlled through the procedure as well as to measure intraoperative urine amounts. After the Foley catheter was inserted, the circulating nurse began to perform a surgical skin preparation to the abdomen. An alcoholic skin prep was used to cleanse the surgical site starting by cleaning out the umbilicus with a three Q-tips, and a wand was used to spread out the skin preparation from the middle of the abdomen to the patient's clavicle, the mid-thighs and bilaterally to the sides of the operating table. After the skin prep was completed, the patient was draped.

A three-quarter sheet was placed at the edge of the pubis and extended over the patient's legs. Four blue surgical towels were used to square off the abdomen to make for a surgical site. Two side drapes were applied to each side of the patient. A laparotomy drape was then centered over the surgical site and extended over the head, clamped and secured to an IV pole on the right and left sides by the anesthesia provider. The remaining part of the laparotomy drape was draped over the lower portion of the patient's body. The Mayo stand was brought up over the knees of the patient to be closely accessible to the surgical technologist. Sterile light handles were screwed into each overhead OR light. The ESU cord, suction tubing, scalpel cord and a cautery cord were all secured to the drape, organized under the Mayo stand and the bottoms of the cords were handed to the circulating nurse to be hooked up to the cords corresponding machine.

INTRAOPERATIVE PROCEDURE

The operating surgeon asked for a report from the surgical technologist, circulating nurse and anesthesia provider to confirm all preoperational measures were taken and asked for any questions or concerns. A "time out" was then performed. The patient's name, medical number, gender, date of birth, condition and the type of surgical procedure being performed was confirmed by the surgeon and all other surgical team members. The surgeon and the surgeon's assistant then proceeded outside of the OR to the sink area and performed a surgical hand scrub. The surgeon and assistant proceeded back into the OR careful not to contaminate themselves. The surgical technologist handed both the surgeon and the assistant a dry sterile towel and assisted both of them in gowning and gloving. The surgeon approached the left

Instruments Needed

Gloves
Gowns
Two packs of sterile sheets
¾ sheet and a universal drape that included two sides, a bottom and a top
Incise drapes
8-pack of sterile towels
Solution warmer drape
Five bundles of lap sponges
Two bundles of sponges
Pack of peanut sponges
A large adhesive trash bag
Surgical absorbable hemostat 3x4
Red maxi vessel loops
Catheter - 18
30-count needle holder and counter x 3
32 oz sterile bowl
14/16 Foley catheter tray
Suction tubing x 2
50 ml syringe x 2
Drain
ESU with teflon long tip extender
30-inch umbilical tape
2-0, 3-0 30" Silk ties
2-0, 3-0, 4-0, 5-0, 6-0 absorbable sutures
Stapler
Dressings

Equipment Needed
An extra back table
ERBE machine
Headlights for the surgeon and the assistant
Sealing system
Staple cart with assorted staplers and loads as well as assorted clip applicators
Warming blanket
Compression device
Major procedures tray one and two
Vascular trauma tray
Retractor tray

side of the patient while the assistant approached the right side of the patient. The surgical technologist approached the left side of patient and stood behind the Mayo stand. The surgical team was then ready to begin the procedure.

HEPATECTOMY PROCEDURE

An indelible marking pen was used to map out the incision over the right upper quadrant of the abdomen where the tumor of the liver was located. A 12 cc controlled release syringe with an 18-gauge needle was used to inject 0.25% bupivacaine hydrochloride and epinephrine solution into the incision site. A #15 blade on a #3 handle was used to make an elliptical incision from the xyphoid process along the right side of the end of the rib cage. The incision measured about six inches in length. The ESU pencil was used to control hemorrhage as the incision was opened. The skin was incised through each layer down to the peritoneum to expose the liver. The surgeon applied the Thompson retractor to fully expose the liver and surrounding organs. Two bed posts were applied and secured to each side of the operating table. A support bar was applied and secured to the bed posts. Another bar with the same length with bars on each side, was applied and secured to the first bar to make for an irregular circular shape to hold retractors. Four ratcheting arms were secured to the two bars, two on the top and two on the bottom. Different types of retractor blades such as a large body wall, medium body wall and malleable retractors were applied and secured to the ratchet

arms. Full exposure of the liver and surrounding organs was accomplished.

The liver was fully examined by the surgeon and assistant, and the tumor was located. Margins were mapped out around the tumor with the ESU pencil to make a template of where the resection would take place. The hepatic artery was located and isolated by dissection with the ESU pencil and a DeBakey forceps. A right-angle clamp was used underneath the hepatic artery while a DeBakey forceps was used to grasp a red vessel loop to pull under and around to ligate the artery. A Kelly clamp was used to tag the vessel loop to relocate it later. The same steps were followed to find the portal vein and the common bile duct. Hemostasis was constantly controlled by the ESU pencil or a 6-0 absorbable suture was used with a needle holder. Once the triad of vessels were located and isolated, the surgeon proceeded to dissect the liver.

The tumor took about three-quarters of the light upper lobe of the liver. Following the previous outline marks that were made with the ESU pencil, resection began. The ESU pencil was first used to cut through the parenchyma. Constant ligation of major vascular and biliary channels was accomplished throughout dissection with a combination of 3-0 and 2-0 silk ties, and 4-0, 5-0 and 6-0 absorbable sutures and a needle holder.

As dissection continued, a combination of the scalpel and a cautery cord was used to free the section of the liver. Care was taken when dissection was close to the posterior surface of the liver close to where the hepatic veins enter the inferior vena cava. The section of the liver with the tumor was freed from the rest of the remaining liver and passed to the surgical technologist to place on the back table while the team waited for the pathologist. The pathologist retrieved the specimen that was sent fresh to make sure enough of the tissue was resected and reasonable margins were taken. While waiting for the pathologist, wet lap sponges were placed over the surgical site to keep the abdominal contents from drying out. The pathologist returned and confirmed the tumor was indeed hepatocellular cancer and that there were good margins of the resected tumor.

The moist sponges were removed and all ligating vessel loops were removed. Three graduated pitchers of 0.9% saline was used to irrigate the wound site. A pool suction tip was used to suction the irrigation fluid. A mixture of 3% hydrogen peroxide and 0.9% saline, a 1:1 ratio, was applied to the resected area to check for bile leaks.

Complete hemostasis was achieved and no bile leaks were present. The surgeon began to close the abdominal cavity. This particular surgeon closed the abdominal layers peritoneum and fascia together with a 1-0 polydioxanone stitch with a Mayo-Haggard needle holder and a Ferris-Smith forceps. At this time the first count was completed by counting all sponges, sharps, and instruments. A 3-0 absorbable suture was used to close the last layer of skin with a Mayo-Haggard needle holder and an Adson tissue forceps. At this time a final count was performed. All sharps, sponges were counted and verbalized to the surgeon that the count was correct. A drain was inserted into the peritoneal cavity and secured with a 3-0 nylon suture.

The wound was cleansed with a wet lap sponge and dried with a dry lap sponge. A balsamic resin was applied to the wound. Bandage rolls were applied along the wound and secured with an abdominal pad and perforated tape. The Mayo stand was removed from the field. The back table was pushed away from the field. All of the cords were pulled off of the drape and the drapes were removed and the patient's gown was lowered over her body.

POST-OP

After the drapes were removed and the gown was returned to normal position, the patient was awoken by the anesthesia provider. The sequential compression device and warming blanket were removed and the patient was then transferred to a gurney and transported to the PACU. After such an operation, a patient may stay in the hospital for a week, possibly two, depending on the patient's condition. The patient may experience uncomfortable pain that can be controlled with pain medication. If the patient is a transplant recipient, close monitoring will be needed for possible organ rejection.

POSSIBLE COMPLICATIONS

Intraoperatively the patient is at risk for complications that include, but are not limited to, hemorrhaging, blood clots or a pulmonary embolism, injuries to nearby structures such as the gallbladder or the intestines and death. Postoperatively the patient may experience hemorrhage, pain, infection, reoccurrence of cancer, liver failure and death.




ABOUT THE AUTHOR

Mary Graham, CST, is a student at San Joaquin Valley College, Fresno, California.

REFERENCES

1. About liver tumors. 2012. Retrieved from http://www.aboutliver tumors.com/liver_tumor.aspx
2. Cohen, B J. Memmler's the human body in health and disease. 2009. Baltimore, MD: Lippincott Williams & Wilkins
3. Cho, S C.; Fong, Y; Park, J. Hepatic resection. 2007. Retrieved from <http://www.acssurgery.com/acs/chapters/ch0523.htm>
4. CRMC. Patient chart. Unpublished patient chart, patient name excluded due to HIPPA regulations. 2012.
5. Logan, MD. Hepatectomy Preference Card. Unpublished surgical preference card, CRMC, California. 2012.
6. Frey, K, et al. Surgical Technology for the Surgical Technologist, A Positive Care Approach, 3rd edition. Delmar Publishing. 2008.
7. Goldman, A M. Pocket Guide to the Operating Room, 3rd edition. Philadelphia, PA: F.A. Davis Company. 2008.
8. Hepatic injury causes. 2012. Retrieved from <http://www.ahealthstudy.com/diseases/hepatic-injury-causes>
9. Loberge, M. 2012. Hepatectomy. Retrieved from <http://www.encyclopedia.com/topic/Hepatectomy.aspx>
10. Picco, F M. 2012. *Liver problems*. Retrieved from <http://www.mayoclinic.com/health/liver-cysts/AN00148>
11. Stuart, E K. 2012. *Hepatocellular carcinoma*. Retrieved from http://www.medicinenet.com/liver_cancer/article.htm

CE EXAM



Earn CE Credits at Home

You will be awarded continuing education (CE) credits toward your recertification after reading the designated article and completing the test with a score of 70% or better. If you do not pass the test, it will be returned along with your payment.

Send the original answer sheet from the journal and make a copy for your records. If possible use a credit card (debit or credit) for payment. It is a faster option for processing of credits and offers more flexibility for correct payment. When submitting multiple tests, you do not need to submit a separate check for each journal test. You may submit multiple journal tests with one check or money order.

Members this test is also available online at www.ast.org. No stamps or checks and it posts to your record automatically!

Members: \$6 per credit

(per credit not per test)

Nonmembers: \$10 per credit

(per credit not per test plus the \$400 nonmember fee per submission)

After your credits are processed, AST will send you a letter acknowledging the number of credits that were accepted. Members can also check your CE credit status online with your login information at www.ast.org.

3 WAYS TO SUBMIT YOUR CE CREDITS

Mail to: AST, Member Services, 6 West Dry Creek Circle Ste 200, Littleton, CO 80120-8031

Fax CE credits to: 303-694-9169

E-mail scanned CE credits in PDF format to:
memserv@ast.org

For questions please contact Member Services - memserv@ast.org or 800-637-7433, option 3.
Business hours: Mon-Fri, 8:00a.m. - 4:30 p.m., MT

Hepatectomy to Treat Hepatocellular Cancer

349 January 2013 1.5 CE credits - \$9

- 1. A hepatectomy is the surgical removal of the _____.**
 - a. Colon
 - b. Abdomen
 - c. Liver
 - d. Small intestines
- 2. Hepatocellular carcinoma may result from _____.**
 - a. Long-term alcohol abuse
 - b. Chronic hepatitis
 - c. Cirrhosis
 - d. All of the above
- 3. An alcoholic skin prep is used to cleanse the surgical site starting by cleaning out the _____.**
 - a. Clavicle
 - b. Mid-thighs
 - c. Umbilicus
 - d. Abdomen
- 4. The patient is placed in the _____ position prior to this operation.**
 - a. Supine
 - b. Supine with pillow underneath legs
 - c. Supine with arms extended on armboards
 - d. Supine with pillow underneath knees
- 5. A marking pen is used to map out the incision over the _____ of the abdomen where the tumor was located.**
 - a. Left lower quadrant
 - b. Right upper quadrant
 - c. Right lower quadrant
 - d. Left upper quadrant
- 6. A #15 blade on #3 handle was used to make a(n) _____ incision from the xyphoid process to the end of the rib cage.**
 - a. Elliptical
 - b. Square
 - c. Diagonal
 - d. Straight
- 7. A _____ was used underneath the hepatic artery.**
 - a. DeBakey Forceps
 - b. ESU pencil
 - c. Retractor
 - d. Right-angle clamp
- 8. The _____ retrieves the dissected organ to make sure enough tissue was resected.**
 - a. Surgical technologist
 - b. Pathologist
 - c. Surgeon
 - d. Circulating Nurse
- 9. Wet lap sponges were placed over the surgical site to keep the _____ from drying out.**
 - a. Abdomen
 - b. Liver
 - c. Parenchyma
 - d. Inferior vena cava
- 10. A mixture of hydrogen peroxide and saline was applied to the resected area at what ratio?**
 - a. 2:1
 - b. 2:2
 - c. 1:1
 - d. 3:1

11. Possible complications from this procedure include _____.

- a. Hemorrhage
- b. Blood clots
- c. Pulmonary embolism
- d. All of the above

12. A three-quarter sheet was placed at the edge of the _____ and extended over the patient's legs.

- a. Pubis
- b. Clavicle
- c. Abdomen
- d. Mid-thighs

13. How many back tables were used during this specific operation?

- a. 3
- b. 2
- c. 1
- d. 0

14. The most common primary tumor of the liver is _____?

- a. Echinococcus
- b. Hepatocellular carcinoma
- c. Malignant hepatoma
- d. Cysts

15. A sequential compression device is applied to the patient's legs in order to prevent _____.

- a. Thrombosis
- b. Embolism
- c. Swollen feet
- d. Hemorrhaging

Take CE exams online and have credits post automatically to your file! You just need a credit card. No more waiting and checking your file to see if credits have posted. Just log on to your account on our home page, www.ast.org, to take advantage of this option!

HEPATECTOMY TO TREAT HEPATOCELLULAR CANCER 349 January 2013 1.5 CE credits - \$9

NBSTSA Certification No. _____

AST Member No. _____

My address has changed. The address below is the new address.

Name _____

Address _____

City _____ State _____ Zip _____

Telephone _____

Check enclosed Check Number _____

Visa MasterCard American Express

Credit Card Number _____

Expiration Date _____

	a	b	c	d		a	b	c	d
1	<input type="checkbox"/>	<input type="checkbox"/>	<input type="checkbox"/>	<input type="checkbox"/>	11	<input type="checkbox"/>	<input type="checkbox"/>	<input type="checkbox"/>	<input type="checkbox"/>
2	<input type="checkbox"/>	<input type="checkbox"/>	<input type="checkbox"/>	<input type="checkbox"/>	12	<input type="checkbox"/>	<input type="checkbox"/>	<input type="checkbox"/>	<input type="checkbox"/>
3	<input type="checkbox"/>	<input type="checkbox"/>	<input type="checkbox"/>	<input type="checkbox"/>	13	<input type="checkbox"/>	<input type="checkbox"/>	<input type="checkbox"/>	<input type="checkbox"/>
4	<input type="checkbox"/>	<input type="checkbox"/>	<input type="checkbox"/>	<input type="checkbox"/>	14	<input type="checkbox"/>	<input type="checkbox"/>	<input type="checkbox"/>	<input type="checkbox"/>
5	<input type="checkbox"/>	<input type="checkbox"/>	<input type="checkbox"/>	<input type="checkbox"/>	15	<input type="checkbox"/>	<input type="checkbox"/>	<input type="checkbox"/>	<input type="checkbox"/>
6	<input type="checkbox"/>	<input type="checkbox"/>	<input type="checkbox"/>	<input type="checkbox"/>					
7	<input type="checkbox"/>	<input type="checkbox"/>	<input type="checkbox"/>	<input type="checkbox"/>					
8	<input type="checkbox"/>	<input type="checkbox"/>	<input type="checkbox"/>	<input type="checkbox"/>					
9	<input type="checkbox"/>	<input type="checkbox"/>	<input type="checkbox"/>	<input type="checkbox"/>					
10	<input type="checkbox"/>	<input type="checkbox"/>	<input type="checkbox"/>	<input type="checkbox"/>					

Mark one box next to each number.
Only one correct or best answer can be selected for each question.