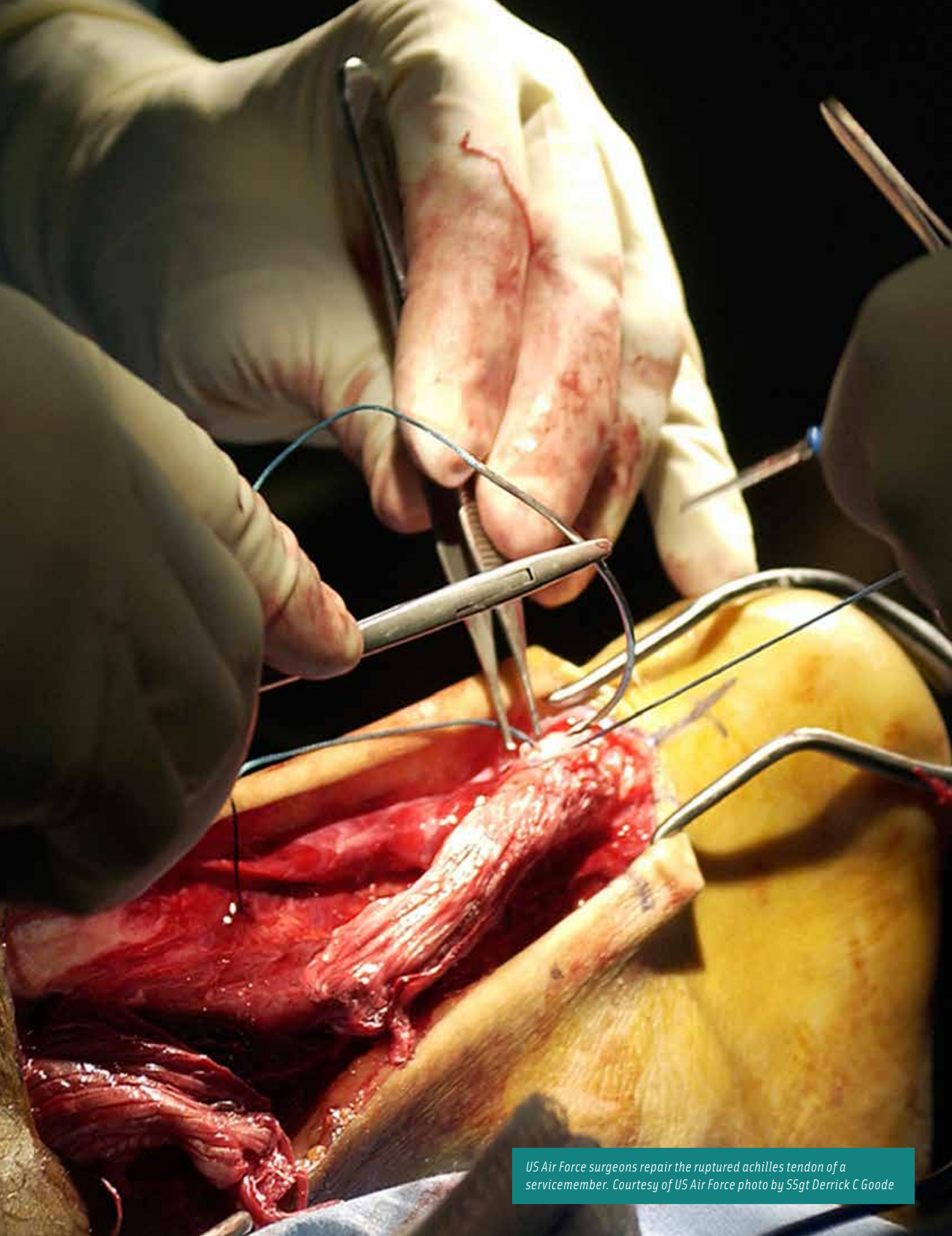

US Air Force surgeons repair the ruptured achilles tendon of a servicemember. Courtesy of US Air Force photo by SSgt Derrick C Goode

Achilles Tendon Repair with Graft Jacket

MARIHA BRANDT

The Achilles tendons are the largest and strongest tendons in the body. However, they are some of the most susceptible to injury. Achilles tendonitis and rupture are extremely common among athletes due to the amount of use and strain put on the tendon during training. But one doesn't have to be an athlete to suffer from these conditions.

An Achilles tendon injury, whether it's a tear or complete rupture, can be caused by a direct trauma, a laceration or severe force stress such as jumping. It also can be caused by multiple lesser stresses throughout an extended period of time. Generally, these stresses go untreated, which causes weakness in the tendon. At some point, the tendon no longer can endure sudden stress or overload from an extension of the ankle or knee, and a partial or complete rupture of the tendon occurs.¹

This article will explore the anatomy of the Achilles tendon and surrounding areas, and the procedure for a full rupture of the Achilles tendon of the right ankle, along with a tear in the peroneus brevis tendon, also in the right ankle. The goal of this procedure will be to reattach the tendon, which will be reinforced by a graft jacket, and repair the peroneus brevis tendon tear.

LEARNING OBJECTIVES

- ▲ Explore the anatomy affected by the surgical repair of an Achilles tendon rupture
- ▲ Recall the procedural steps for this procedure
- ▲ State the post-operative recovery plan including physical therapy
- ▲ List the instruments and equipment needed for this operation
- ▲ Review the pre-op steps and special considerations

ANATOMY

“The Achilles tendon is a fibrous cord of connective tissue that is located at the posterior aspect of the heel. Its purpose is to attach the gastrocnemius and soleus muscles in the calf to the tuberosity of the calcaneus or the heel bone, which is the largest bone of the foot. The proper function of this fibrous cord allows a person to walk, run, jump, dance or stand. Traumatic injuries most commonly occur to the Achilles tendon when the subject is pushing off (as in any number of sporting events) or as the result of a direct blow.”⁹ “The tiny plantaris muscle also connects to the Achilles tendon. Additional names for the Achilles tendon include: heel cord, heel tendon and calcanean tendon. Unlike most tendons, the Achilles tendon does not have an actual tendon sheath, but is encircled by a paratenon of soft tissue that protects, nourishes and helps facilitate the blood supply to the tendon.”¹

Compared with the other tendons of the body, the Achilles tendons have a relatively poor blood supply. The Achilles tendon receives its blood from two sources. The proximal end of the tendon receives its blood from the two calf muscles that it extends from, the gastrocnemius and

An Achilles tendon injury, whether it's a tear or complete rupture, can be caused by a direct trauma, a laceration or severe force stress such as jumping. It also can be caused by multiple lesser stresses throughout an extended period of time. Generally, these stresses go untreated, which causes weakness in the tendon. At some point, the tendon no longer can endure sudden stress or overload from an extension of the ankle or knee, and a partial or complete rupture of the tendon occurs.¹

the soleus muscle. The distal portion derives its blood supply from the tendon-bone connection. Both of these areas are supplied blood in part by the mesotenon portion of the paratenon.¹ The paratenon receives its blood supply largely from the posterior tibial artery.⁸

“The Achilles tendon is supplied by sensory nerves from the contributing muscles and via small branches from neighboring cutaneous nerves, notable the sural nerve. The paratenon is more richly innervated than the tendon itself.”⁸

The peroneus brevis originates at the distal two-thirds of the lateral surface of the fibula and inserts on the tuberosity on the lateral side of the proximal end of the fifth metatarsal. It's responsible for the plantar flexion and eversion of the foot at the ankle and gives lateral stability to the ankle. Tears and damage in the peroneus brevis are commonly associated with or referred to as a sprained ankle. The peroneus brevis nerve innervation is derived from the peroneal, S1, L5 and L4 nerves.¹⁴

Diagnostic tests will be performed to determine the extent of injury and to assist the surgeon when deciding upon the course of treatment. Tests may include a physical examination, a podiatric examination, MRI, CT scans and X-rays.

SPECIAL CONSIDERATIONS

Special considerations for this case will include:

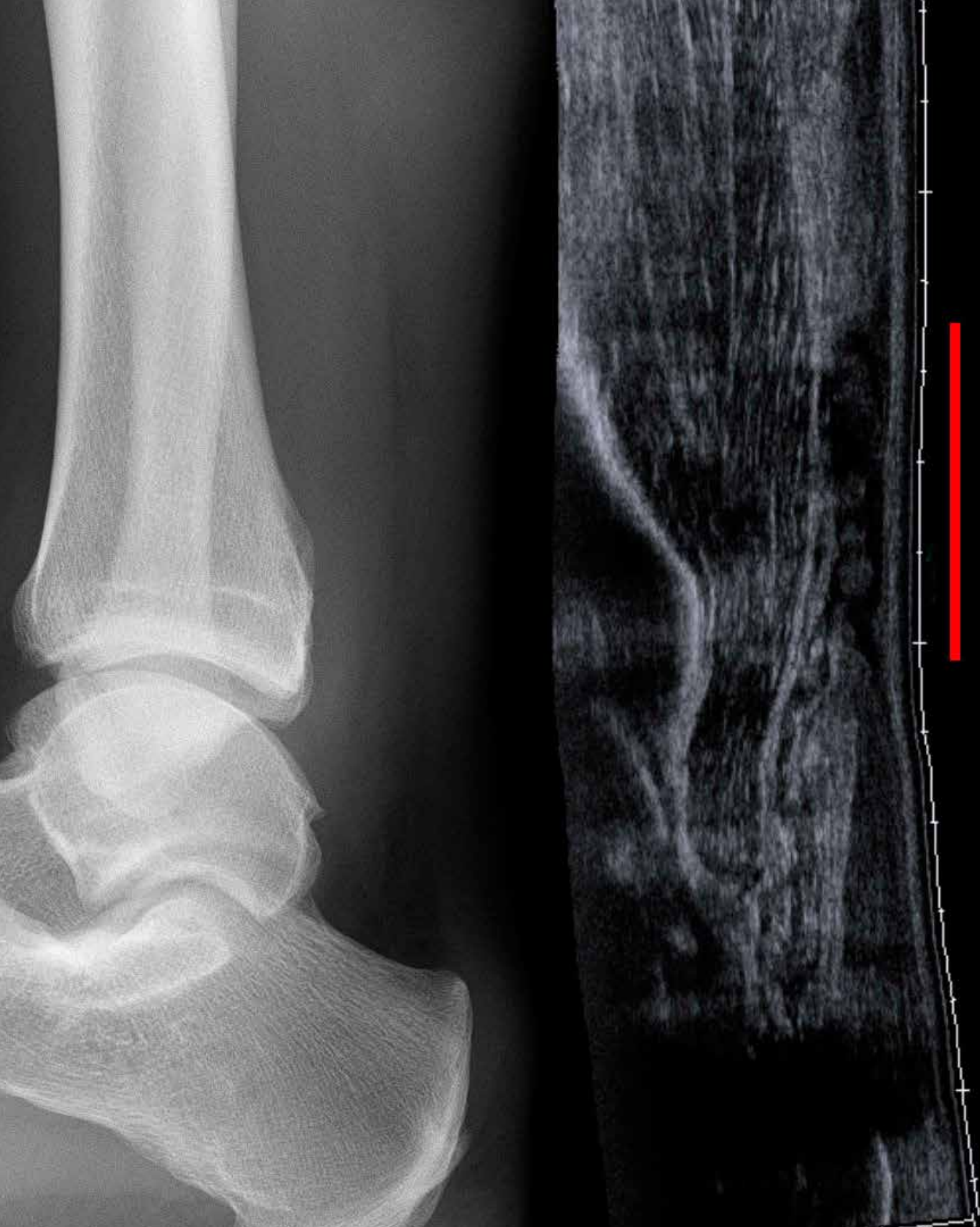- Ensuring all diagnostic films are in the room before the case begins.
- Ensuring proper preferred graft material is available in the room.
- Ensuring additional graft is available in the room.
- Ensuring all consents are signed and in the room.

PATIENT POSITION

The patient will be placed in the supine position with his or her arms tucked in at the sides for the induction of anesthesia. The patient will be turned to the prone position after anesthesia has been administered. Multiple people may be required to turn and place the patient.⁹

Positioning Aids

The head of the bed will need to be changed to a horse-shoe-shaped headrest. Care will need to be taken to avoid disturbing the patient's artificial airway. The patient's arms will be extended and flexed at the elbow and placed on the arms boards. Proper padding must be applied to the



Courtesy of Hellerhoff
Achilles tendon rupture seen at sonography: discontinuity over several centimeters.

ulnar and axillary areas of the arm to protect the ulnar nerves and the brachial plexus. The unaffected leg will need to be flexed on a pillow to ensure that the patient's toes will not rest on bed, avoiding unnecessary pressure.⁹

Special Positioning Considerations⁹

- A gurney needs to be kept immediately outside the OR in case the patient needs to be returned to supine position quickly due to an emergency situation.
- Chest rolls need to be placed prior moving the patient to the OR to allow for proper ventilation.
- A bolster may be needed in order for the affected leg to avoid improper position of the foot and ankle.

The foot will be placed in a plantar flexion position in order to approximate the two ends of the ruptured Achilles tendon. The ends will be trimmed with Metzenbaum scissors to ensure reconnection. After they are brought back together, they will be reconnected using the polyethylene braided suture, achieving the original tendon length.

PATIENT PREP

The patient's hair will be removed from the ankle's posterior up to the lower calf. This will allow the surgeon to extend the incision if needed. The patient's skin will be prepped with an iodine and alcohol gel prep. The affected leg will be bent at the knee and be placed on an elevated leg rest so it will be kept off of the unsterile bed. The prep will begin at the toes, and the patient's nails and in between the toes will be cleaned. The prep will extend circumferentially from the patient's toes to his or her knee of the affected leg.⁶

Draping

A half sheet will be placed underneath the affected leg and over the unaffected leg and will extend down each side of the OR table. The affected leg will be placed into an impervious stockinette and it will be extended over the calf. The affected leg will be passed through a fenestrated extremity

sheet, which will be aligned to the lower part of the calf. A $\frac{3}{4}$ -sheet will be used to additionally cover the patient to create a tent for anesthesia.⁶

Tourniquet

A tourniquet will be placed at the lower thigh above the knee. A stretchable cotton material will be wrapped around the thigh prior to tourniquet placement to add a layer of protection for the skin. The tourniquet will not be inflated until after the patient is draped. Prior to the inflation, the surgeon or surgical technologist will raise the leg by bending at the knee to facilitate the blood drainage beyond the knee. The foot and ankle will be exsanguinated with an Esmarch bandage to allow for a "bloodless" bandage. The tourniquet will be inflated to 375 mm, and the patient's ankle will be placed on a bolster to allow for the proper of the ankle and reduce tension. The end of the stockinette will be cut off and peeled back to expose the surgical site.

Graft

The graft jacket will reinforce the repair and will allow for the growth of new tissue. The new tissue will grow through the graft material, which will allow for the tendon to grow stronger and more durable.

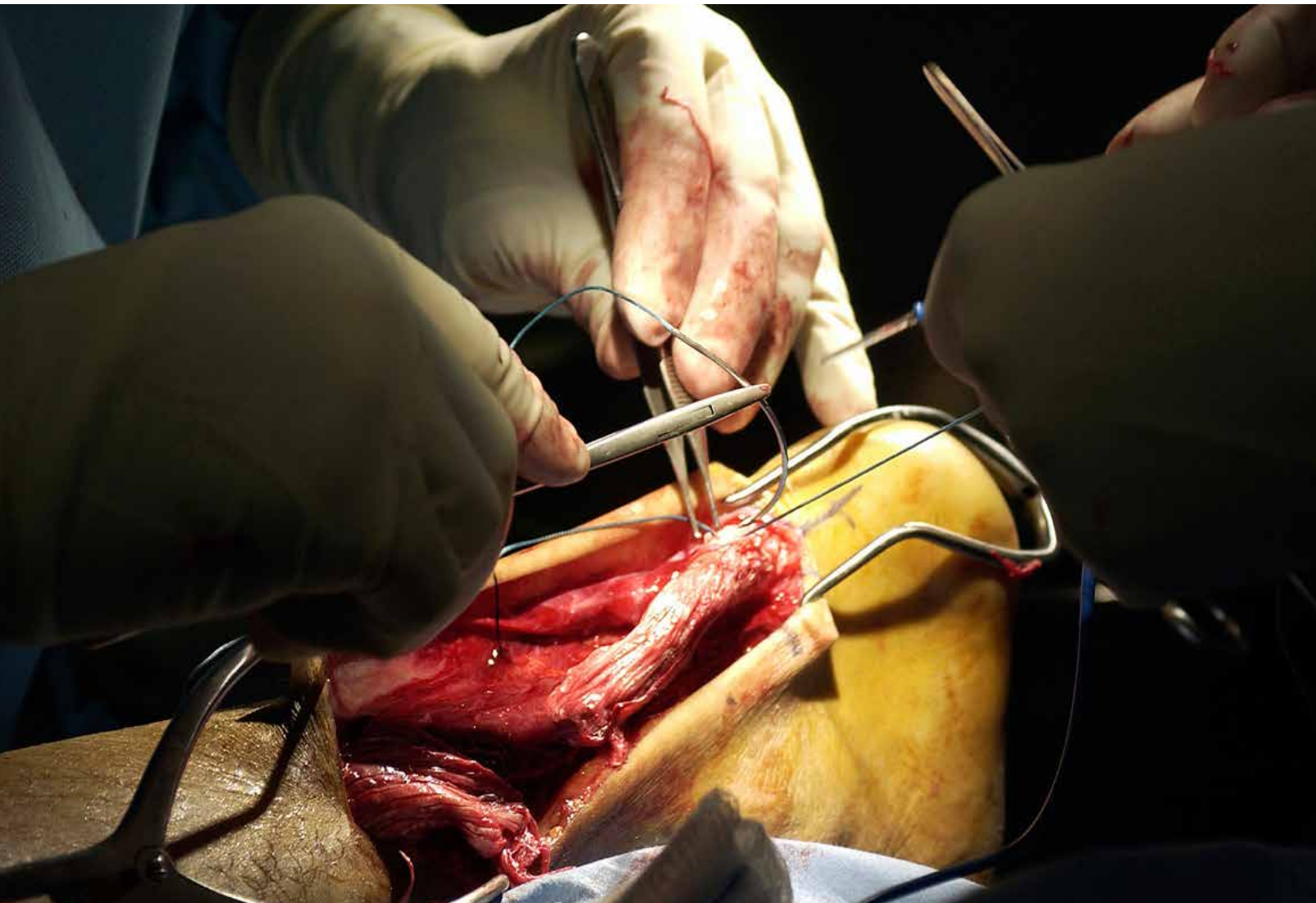
Incision

A marking pen will be used to draw approximation lines denoting the incision site. The skin will be incised with a #15 blade on a #3 knife handle. The incision will extend approximately five to six inches, and will end a bit superior to the calcaneus bone. (The incision will be extended if needed during the procedure. The skin knife will need to be set aside on the back table for this purpose.)

PROCEDURE

After the initial count is completed and the time out performed, the surgical site will be injected with a lidocaine solution. The incision will be made using a #15 blade on a #3 knife handle as the surgical technologist will provide surgical sponges and a Bovie as needed for hemostasis. The skin will be retracted using the Senn retractors. Sharp and blunt dissection will be performed to expose the Achilles tendon. The surgical technologist will need to have a #3 handle and a curved Metzenbaum scissors as well as the Bovie and/or suction as needed.

The surgeon will identify the two ends of the Achilles



tendon and will use a 3-0 polyglactin 910 suture as a Crile clamp will be used to secure the ends of each traction suture. Further dissection will be performed to expose the peroneus brevis tendon. Care will be taken to protect both the sural and lateral dorsal cutaneous nerves. Any damaged tissue will be removed.

The peroneus brevis tendon rupture will be identified and approximated. The rupture will be repaired using a 2-0 polyethylene braided suture with a half-inch taper needle used for interrupted sutures. The polyethylene suture will be cut as needed using Mayo scissors. The foot will be placed in a plantar flexion position in order to approximate the two ends of the ruptured Achilles tendon. The ends will be trimmed with Metzenbaum scissors to ensure

reconnection. After they are brought back together, they will be reconnected using the polyethylene braided suture, achieving the original tendon length. Once the tendon is secured, the surgeon will reconstruct the paratenon.³

The surgical technologist will request and retrieve the graft from the circulator. An area on the Mayo stand or back table needs to be open to allow for the surgeon to custom cut the graft. It will be critical to record the implant information in the patient chart. The surgical technologist will need to have scissors for the surgeon as needed to allow for a custom cut of the graft jacket so it properly fits the patient. The surgeon will suture the graft both to itself and to the tendon using the polyethylene sutures. The surgical will need to continue to assist with retraction and cutting

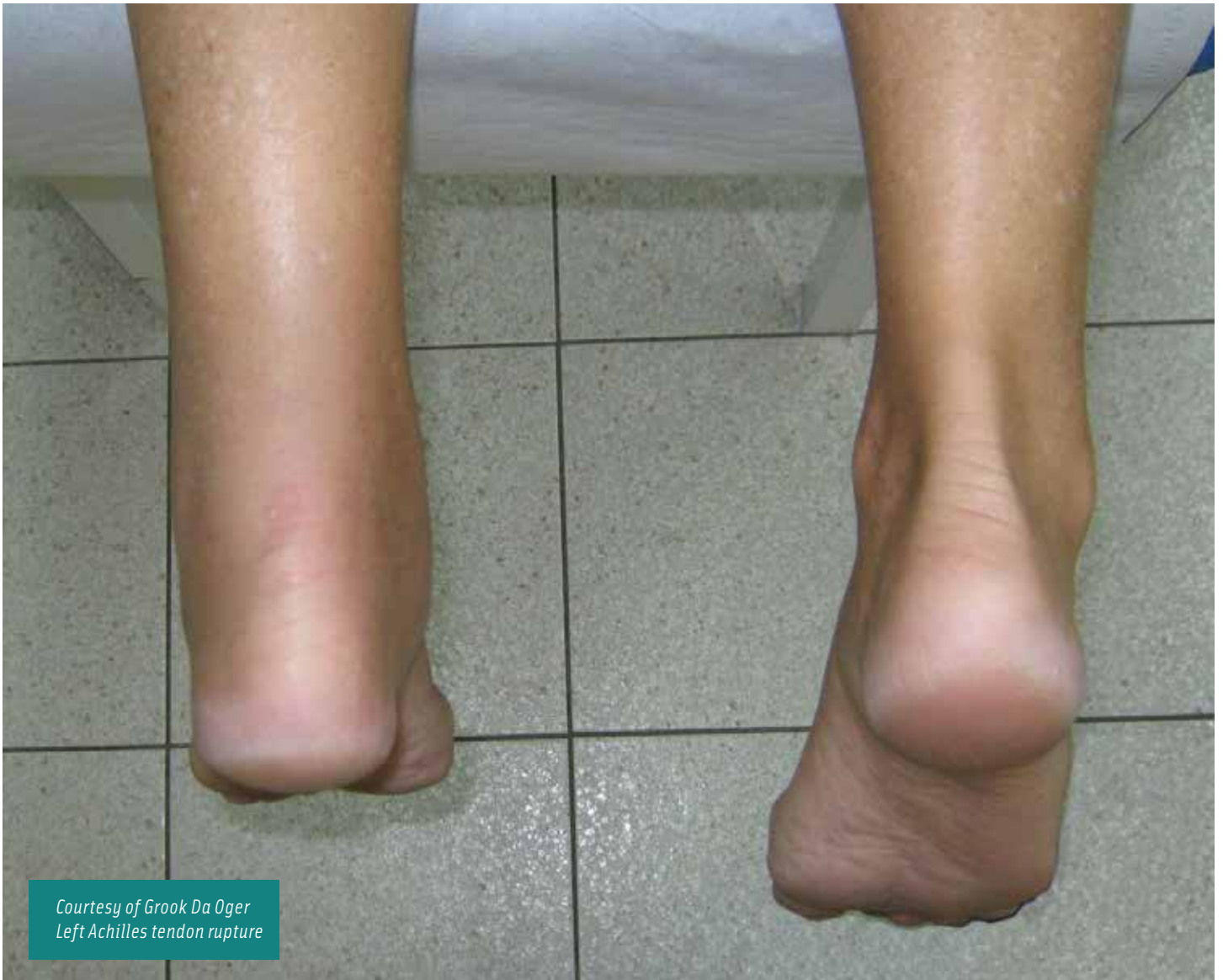Equipment
Leg holder
Hip tourniquet: general-mid thigh
Tourniquet insufflator
Suction apparatus
Electrosurgical Unit
Power source for drill (available)
Pulsed lavage suction irrigator and tip (available)
Casting Cart
Supplies
Antiemboletic hose (for unaffected leg)
Cotton padding
Tube Stockinette
½ sheet drape
Custom foot pack
Custom basin set
¾ sheet drape (available)
Fenestrated extremity drape
Esmarch bandage
Bed pad
ESU pad with cord
ESU pencil, button switch
Guarded and needle Bovie tips
2-4 additional #15 blades available
2-#64 brush cutter blades
2% lidocaine hydrochloride plain: pre-op and intra-op local
0.5% bupivacaine hydrochloride plain: post-op pain
0.9% sodium chloride for irrigation
Bulb syringe for irrigation
Sodium chloride mixture for irrigation
20 cc syringe with 22 gauge 1 ½ inch needle
30 cc syringe with 22 gauge 1 ½ inch needle
Suture

of the suture ends. Once complete, the wound will be irrigated with a sodium chloride mixture, with a basin placed underneath the foot to catch the fluid. Suction will occur as needed.⁴

Once the wound is cleaned, closure will begin as will the final count. The fascia and subcutaneous tissue will be closed using subcutaneous interrupted

Instruments
The following instruments will be necessary for the procedure:
1. Hand and foot tray
2. Basic orthopedic tray (available)
3. Mc Glamory elevator set (available)
4. Beaver knife handle
5. Sims suction tip
6. Micro Sagital Saw with fine blade
On The Mayo Stand
2-#15 blades on #3 knife handles
Bandage scissors
Straight Mayo scissors
2- Senn retractors
Curved Metzenbaum scissors
Freer elevator
2- Mosquitos
3- Criles (one to secure cords on drape)
2- Adson Brown forceps
Adson with teeth forceps
Marking pen
Raytech sponges

The graft jacket will reinforce the repair and allows for the growth of new tissue. The new tissue will grow through the graft material, which will allow for the tendon to grow stronger and more durable.



Courtesy of Groom Da Oger
Left Achilles tendon rupture

sutures and a 4-0 polyglactin 910 suture passed on a needle driver. The ends will be cut with Mayo scissors. The skin will be closed using vertical mattress retention sutures. A bupivacaine solution will be injected in and around the wound to help with post-operative pain. The area will be cleaned and the dressings will be applied. The foot will be held in a plantar flexion position to avoid unnecessary strain on the newly repaired Achilles tendon. A light pressure dressing will be applied to the incision site and the ankle will be wrapped with cotton padding from superior to the incision to the toes. A splinting material will be moistened with warm saline and placed on the posterior aspect of the lower calf, ankle heel and foot. It will be formed to the natural shape of the leg and foot and allowed to harden

and partially dry. The entire splint will be wrapped with a three-inch elastic bandage and secured. The splint will remain in place until the post-operative visit.

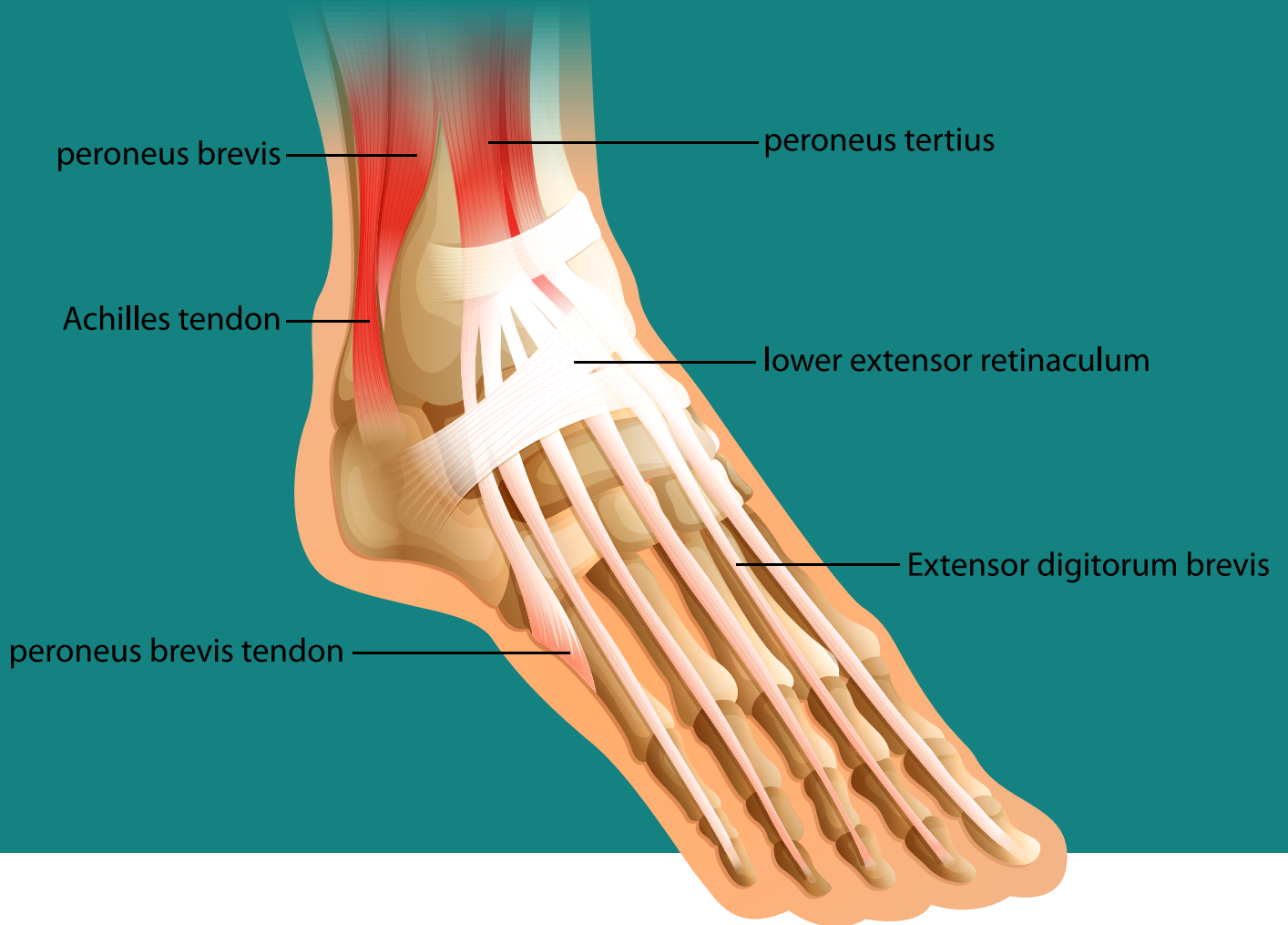COMPLICATIONS

Complications are rare with this procedure, but occasionally occur.

Intraoperative Complications:

- Damage to surrounding tendons, ligaments and soft tissue
- Nerve damage
- Hemorrhage
- Shortened tendon: This can occur when too much dam-

Foot Muscles and Tendons



The patient will return for a post-operative appointment two days after surgery. The splint will be removed, the dressings changed and the patient will be fitted with a pneumatic walking boot. The walking boot will be set and secured to keep the foot in a slight plantar flexion position. All dorsal flexion will be restricted at this time and the patient will remain in the boot and on crutches. Physical therapy will be scheduled.

age is done to the ends of the ruptured tendon. This can be improved over time with physical therapy, but may require permanent orthotics to compensate.

Postoperative Complications

- Infection
- Wound dehiscence
- Suture granulomas
- Rupture reoccurrence
- Graft rejection
- Hypertrophic scars
- Nerve entrapment
- Tightness or pain in tendon
- Limited range of motion
- Inflammation

POSTOPERATIVE CARE

The patient will be transported to the PACU via a gurney after extubation. The patient will be monitored until he or she is conscious enough to be moved to the step-down phase. Pain medications may be given and the patient is usually released to go home within 45 to 60 minutes.

Patients will not be allowed to place any pressure on the affected leg and will need to use crutches to move around. To avoid excessive swelling, the patient will need to elevate the affected leg. Light bleeding from the surgical site will be expected within the first few hours of the surgical procedure or when the dressings are changed.

FOLLOW-UP CARE

The patient will return for a post-operative appointment two days after surgery. The splint will be removed, the dressings changed and the patient will be fitted with a pneumatic walking boot. The walking boot will be set and secured to keep the foot in a slight plantar flexion position. All dorsal flexion will be restricted at this time and the patient will remain in the boot and on crutches. Physical therapy will be scheduled.

PHYSICAL THERAPY

Physical therapy is a vital part of the recovery phase of an Achilles tendon rupture repair.

The only way to strengthen, lengthen and gain full range of motion of the newly repaired tendon is to exercise it regularly. The physical therapist will place the patient

on a personalized schedule of exercises based on his or her age and ability and the extent of his or her injury and repair. Recovery time will be based on these factors and is generally at least 12 weeks.

REFERENCES

1. AchillesTendon.com. (2006). *Everything about achilles tendon*. Retrieved from <http://www.AchillesTendon.com/Footwear.html>
2. Cohen, B. (2009). *Memmler's: the human body in health and disease*. (Eleventh Edition). Philadelphia, PA: Wolters Kluwer | Lippincott Williams & Wilkins.
3. Cook, J; Frey, K. (2008). *Surgical technology for the surgical technologist: a positive care approach*. Clifton Park, NY: Delmar Cengage Learning.
4. Goldman, M. (2008). *Pocket guide to the operating room*. (Third Edition). Philadelphia, PA: FA Davis Company.
5. Gottschlich, L. (2010). *Achilles tendonitis*. Retrieved from <http://emedicine.medscape.com/article/85115-overview>.
6. Grandt, V. (2012). *Achilles tendon repair preference card*. Unpublished surgical preference card, Sequoia Surgical Center, California.
7. Massagetoday.com. (2007). *Achilles tendon disorders*. Retrieved from <http://www.message today.com/mpacms/mt/article.php?id=13684>
8. Maffulli, N. (2007). *The achilles tendon*. New York, NY: Springer.
9. Medcomrn.com. (2012). *Achilles tendon repair*. Retrieved from http://ww5.medcomrn.com/cgi-bin/commedctr/process?mv_session_id=9ZmRA2kx&mv_nextpage=edu/courseframes&mv_todo=return&mv_arg=OR0952-T&v_test_number=
10. Orthogate.org. (2006). *Peroneal tendon problems*. Retrieved from <http://www.orthogate.org/patient-education/ankle/peroneal-tendon-problems.html>
11. Physicaltherapynetwork.wordpress.com. (2011). *Achilles tendon rupture needs physical therapy*. Retrieved from <http://physicaltherapynetwork.wordpress.com/2011/08/09/achilles-tendon-rupture-needs-physical-therapy/>
12. Sequoia Surgical Center. (2012). *Patient chart*. Unpublished patient chart, patient name excluded due to HIPPA regulations.
13. Sportsinjuryclinic.net. (2012). *Achilles tendonitis*. Retrieved from <http://www.sportsinjuryclinic.net/sport-injuries/ankle-achilles-shin-pain/achilles-tendonitis>
14. Wheelessonline.com. (2012). *Peroneus Brevis*. Retrieved from http://www.wheelessonline.com/ortho/peroneus_brevis

Achilles Tendon Repair with Graft Jacket

370 OCTOBER 2014

1 CE credit - \$6

1. The Achilles tendon is a _____ of connective tissue that is located at the posterior aspect of the heel.
 - a. Fibrous cord
 - b. Tendon
 - c. Muscle
 - d. Ligament
2. After the patient has been given anesthesia, the patient will be moved to the _____ position.
 - a. Supine
 - b. Lateral
 - c. Prone
 - d. Trendelenburg
3. The head of the bed will need to be changed to a _____-shaped headrest.
 - a. Donut
 - b. Circle
 - c. Horseshoe
 - d. Vertical
4. Patient prep will extend from the ankle's posterior to the _____.
 - a. Mid-thigh
 - b. Lower calf
 - c. Knee
 - d. Hip
5. A tourniquet will be placed at the _____.
 - a. Knee
 - b. Mid-calf
 - c. Toes
 - d. Lower thigh
6. The ends of the ruptured Achilles tendon will be trimmed using _____ scissors.
 - a. Metzenbaum
 - b. Iris
 - c. Mayo
 - d. Knight
7. Intraoperative complications for this procedure does not include:
 - a. Nerve damage
 - b. Shortened tendon
 - c. Hypertrophic scars
 - d. Hemorrhage
8. Physical therapy is a vital part of the recovery phase for an Achilles tendon rupture repair. How long is general recovery?
 - a. 10 weeks
 - b. 12 weeks
 - c. 16 weeks
 - d. 4 months
9. Initially, the incision will extend approximately _____ inches.
 - a. 4-5
 - b. 5-6
 - c. 6-7
 - d. 7-8
10. The affected leg will be passed through a fenestrated extremity sheet, which will be aligned to the _____.
 - a. Lower part of the thigh
 - b. Lower part of the leg
 - c. Mid-part of the calf
 - d. Lower part of the calf

ACHILLES TENDON REPAIR WITH GRAFT JACKET 370 OCTOBER 2014 1 CE CREDIT - \$6

NBSTSA Certification No. _____

AST Member No. _____

My address has changed. The address below is the new address.

Name _____

Address _____

City _____ State _____ Zip _____

Telephone _____

Check enclosed Check Number _____

Visa MasterCard American Express

Credit Card Number _____


Expiration Date _____

	a	b	c	d
1	<input type="checkbox"/>	<input type="checkbox"/>	<input type="checkbox"/>	<input type="checkbox"/>
2	<input type="checkbox"/>	<input type="checkbox"/>	<input type="checkbox"/>	<input type="checkbox"/>
3	<input type="checkbox"/>	<input type="checkbox"/>	<input type="checkbox"/>	<input type="checkbox"/>
4	<input type="checkbox"/>	<input type="checkbox"/>	<input type="checkbox"/>	<input type="checkbox"/>
5	<input type="checkbox"/>	<input type="checkbox"/>	<input type="checkbox"/>	<input type="checkbox"/>
6	<input type="checkbox"/>	<input type="checkbox"/>	<input type="checkbox"/>	<input type="checkbox"/>
7	<input type="checkbox"/>	<input type="checkbox"/>	<input type="checkbox"/>	<input type="checkbox"/>
8	<input type="checkbox"/>	<input type="checkbox"/>	<input type="checkbox"/>	<input type="checkbox"/>
9	<input type="checkbox"/>	<input type="checkbox"/>	<input type="checkbox"/>	<input type="checkbox"/>
10	<input type="checkbox"/>	<input type="checkbox"/>	<input type="checkbox"/>	<input type="checkbox"/>

Make It Easy - Take CE Exams Online

You must have a credit card to purchase test online. We accept Visa, MasterCard and American Express. Your credit card will only be charged once you pass the test and then your credits will be automatically recorded to your account.

Log on to your account on the AST homepage to take advantage of this benefit.



Earn CE Credits at Home

You will be awarded continuing education (CE) credits toward your recertification after reading the designated article and completing the test with a score of 70% or better. If you do not pass the test, it will be returned along with your payment.

Send the original answer sheet from the journal and make a copy for your records. If possible use a credit card (debit or credit) for payment. It is a faster option for processing of credits and offers more flexibility for correct payment. When submitting multiple tests, you do not need to submit a separate check for each journal test. You may submit multiple journal tests with one check or money order.

Members this test is also available online at www.ast.org. No stamps or checks and it posts to your record automatically!

Members: \$6 per credit

(per credit not per test)

Nonmembers: \$10 per credit

(per credit not per test plus the \$400 nonmember fee per submission)

After your credits are processed, AST will send you a letter acknowledging the number of credits that were accepted. Members can also check your CE credit status online with your login information at www.ast.org.

3 WAYS TO SUBMIT YOUR CE CREDITS

Mail to: AST, Member Services, 6 West Dry Creek Circle Ste 200, Littleton, CO 80120-8031

Fax CE credits to: 303-694-9169

E-mail scanned CE credits in PDF format to:
memserv@ast.org

For questions please contact Member Services - memserv@ast.org or 800-637-7433, option 3. Business hours: Mon-Fri, 8:00a.m. - 4:30 p.m., MT

Studying for the CST Exam? There's an App for That

The only AST-authored study guide with more than 1,400 questions has gone mobile! AST recently published its first app – AST Study Guide – and it's available in the iTunes Store and Google Play.

The app includes six tests to review and utilize while preparing for the CST examination sponsored by the National Board of Surgical Technology and Surgical Assisting. Now, all the study tips are conveniently in the palm of your hand.

Study with confidence whenever and wherever you are!

