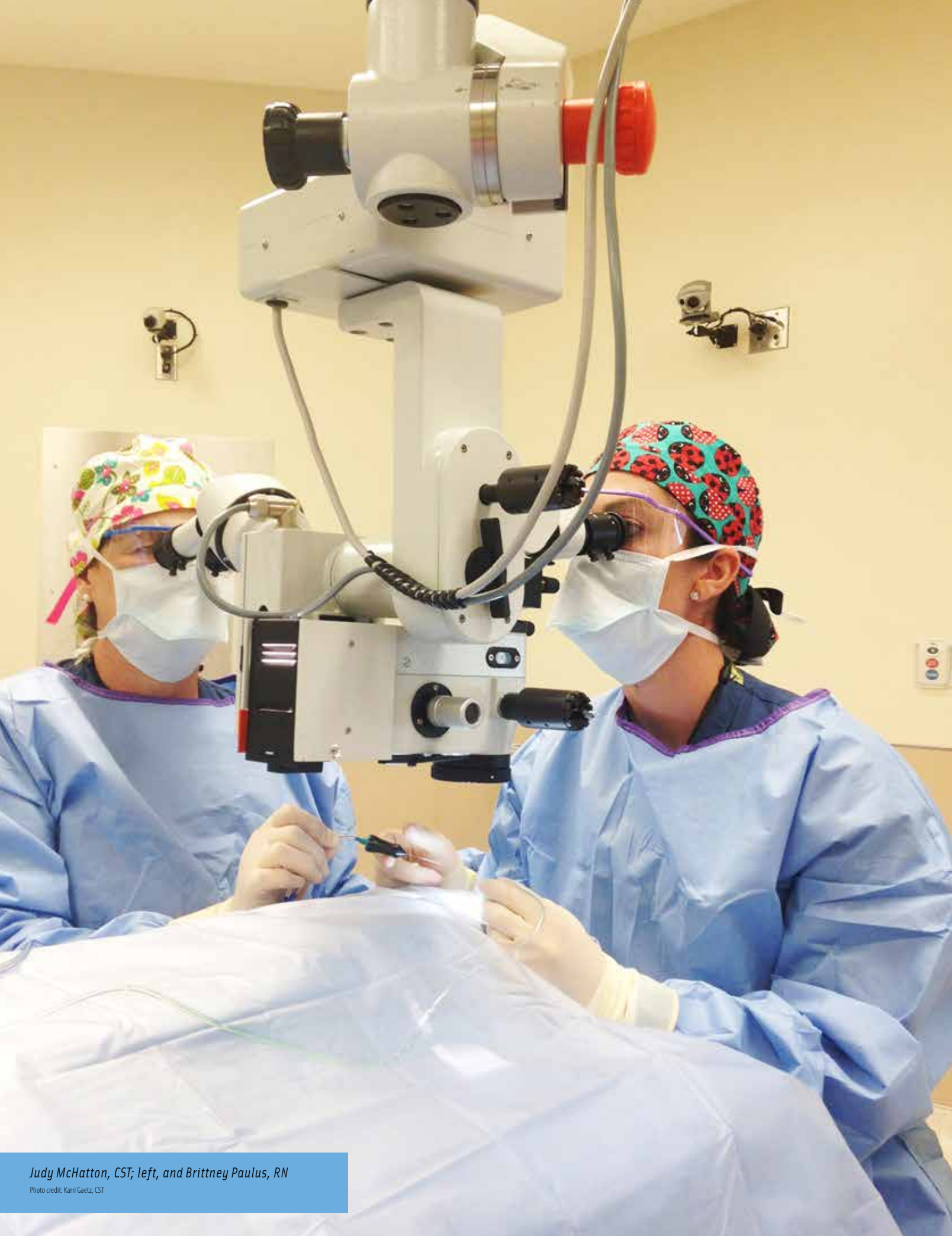



Judy McHatton, CST; left, and Brittney Paulus, RN

Photo credit: Karri Gaetz, CST

Pediatric Cataract Surgery

KARRI GAETZ, CST

The term cataract is used to describe opacification of the crystalline lens of the eye.¹ Often, when people hear about cataract surgery, they picture the procedure being performed on an adult. The lens in the eye continues to form new lens fiber cells throughout our lives. After many years all the new cells forming near the peripheral edge of the lens start to compress the older cells in the nucleus. It is this compression that causes the lens to harden and turn opaque which causes reduced vision.

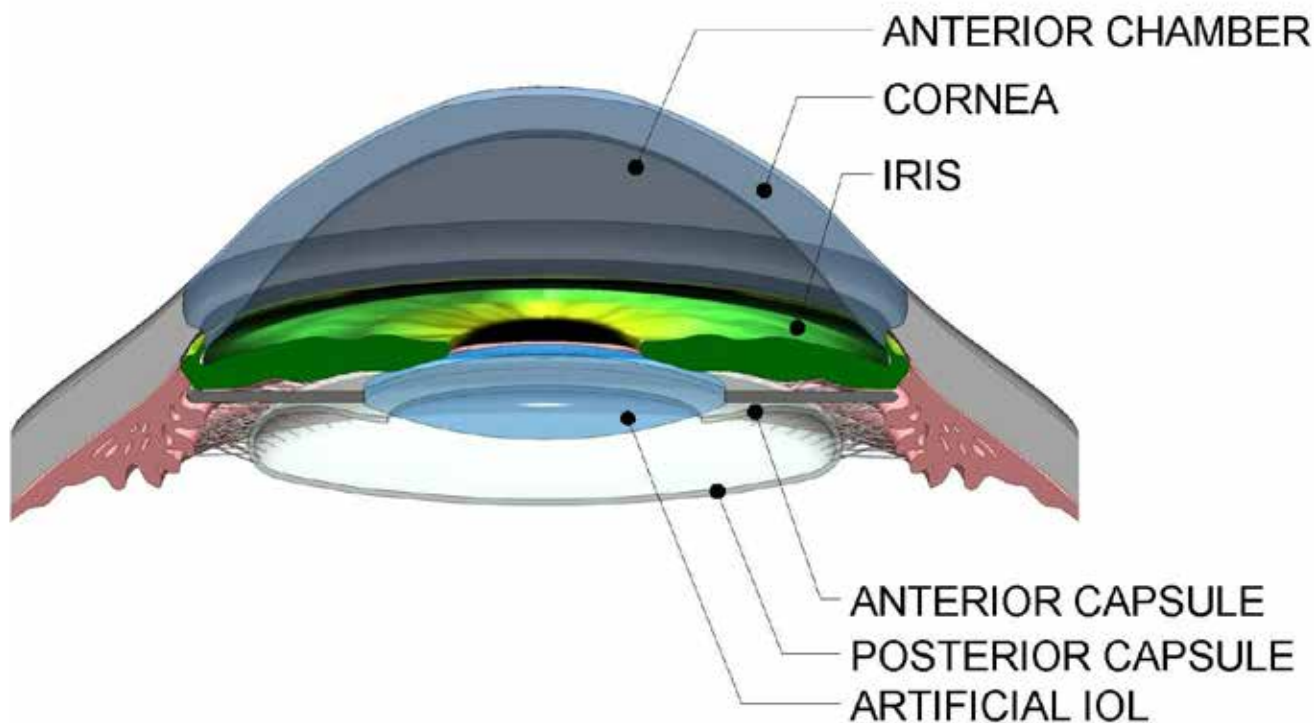
Patients undergo a short operation, usually under local anesthesia, to remove this lens, so the surgeon may implant a new clear artificial lens. However, most people do not realize that infants who have barely used their lenses also can develop cataracts. The occurrence rate of congenital cataracts in infants is 1 to 6 per 10,000 live births, depending on the ascertainment method.²

ANATOMICAL DIFFERENCES

Pediatric eyes are anatomically different than adult eyes. Eyes continue to grow and change until adolescence. In infant eyes, the sclera is thinner, more vascular and more elastic. This results in a greater tendency for hemorrhage or a collapse leading to higher vitreous pressure during surgery.³ The crystalline lens is smaller in children than adults – leading to an important decision about whether or not to implant an artificial lens, and, if so, what size and power. In adults,

LEARNING OBJECTIVES

- ▲ Define the term cataract
- ▲ Learn the anatomical differences between adult and pediatric eyes
- ▲ Review the various types of pediatric cataracts
- ▲ Recall the procedural steps taken for the different types of procedures regarding this condition
- ▲ Identify the actions needed for successful post-operative care



IOL IMPLANTATION IN THE SULCUS

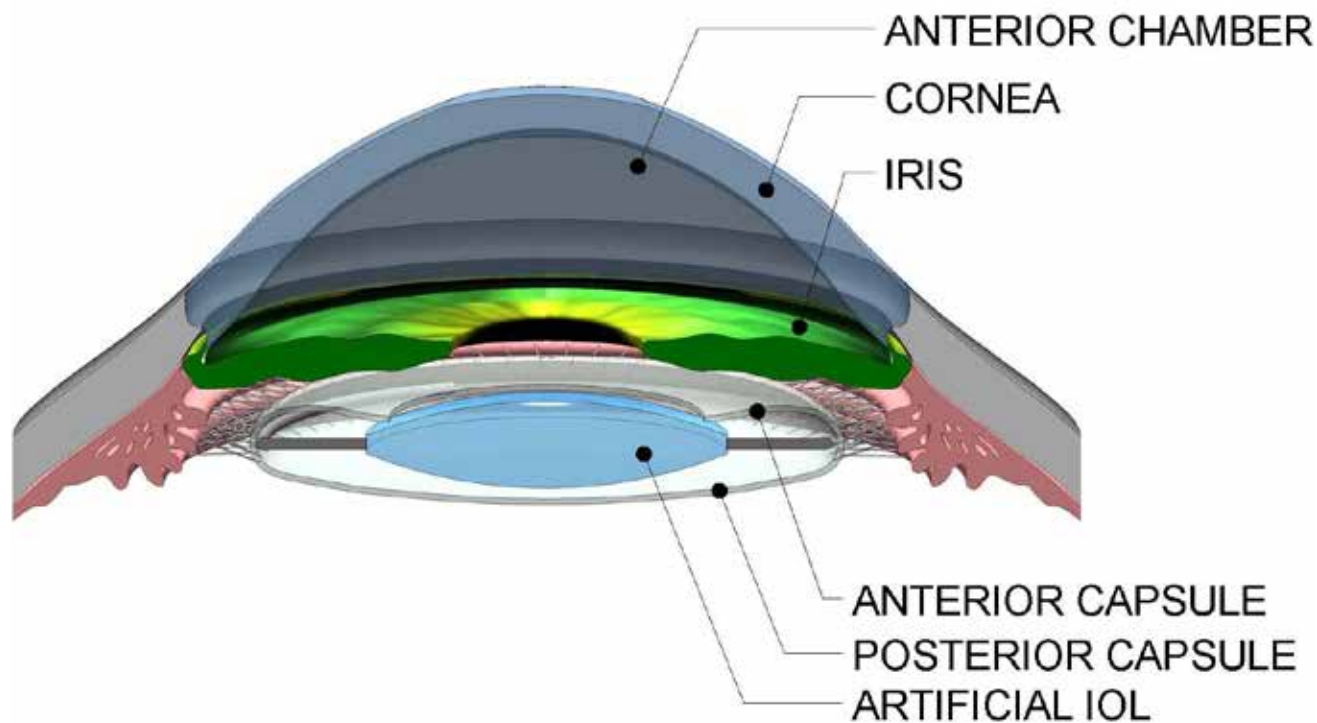
Illustrations created by Jonathan Rose, CDT

the lens being removed is hard and requires phacoemulsification (ultrasound energy) to break it up before it can be aspirated. In pediatric eyes, the lens material is soft and viscid, which requires an irrigation-aspiration technique or a vitrectomy hand piece in order to be removed. The anterior capsule also is thinner and more elastic. This combined with higher vitreous pressure makes the capsulorrhexis more difficult.³ The iris is thicker and more vascular leading to a higher incidence of post-operative inflammation.⁴ The posterior capsule opacifies quickly after surgery, which may make an opening in the posterior capsule necessary at the time of surgery. Remnants of the anterior vitreous in children can serve as a scaffold for fibrous membrane overgrowth, which requires a second procedure to remove.³ Care also must be taken to prevent

macular and retinal phototoxic injury due to intense illumination from the microscope.⁵

TYPES OF PEDIATRIC CATARACTS

Pediatric cataracts can be unilateral or bilateral. Both are most often congenital, but can develop later during childhood. Unilateral congenital cataracts are most often idiopathic. Abnormalities occur in the formation of proteins essential for maintaining the transparency of the lens, but the cause of these abnormalities is unknown.³ Unilateral cataracts also can be caused by trauma. A traumatic cataract results from either a blunt or penetrating force that damages the lens. The cataract can form shortly after the trauma or months to years following the injury. Bilateral congenital cataracts may be caused by intrauterine infec-

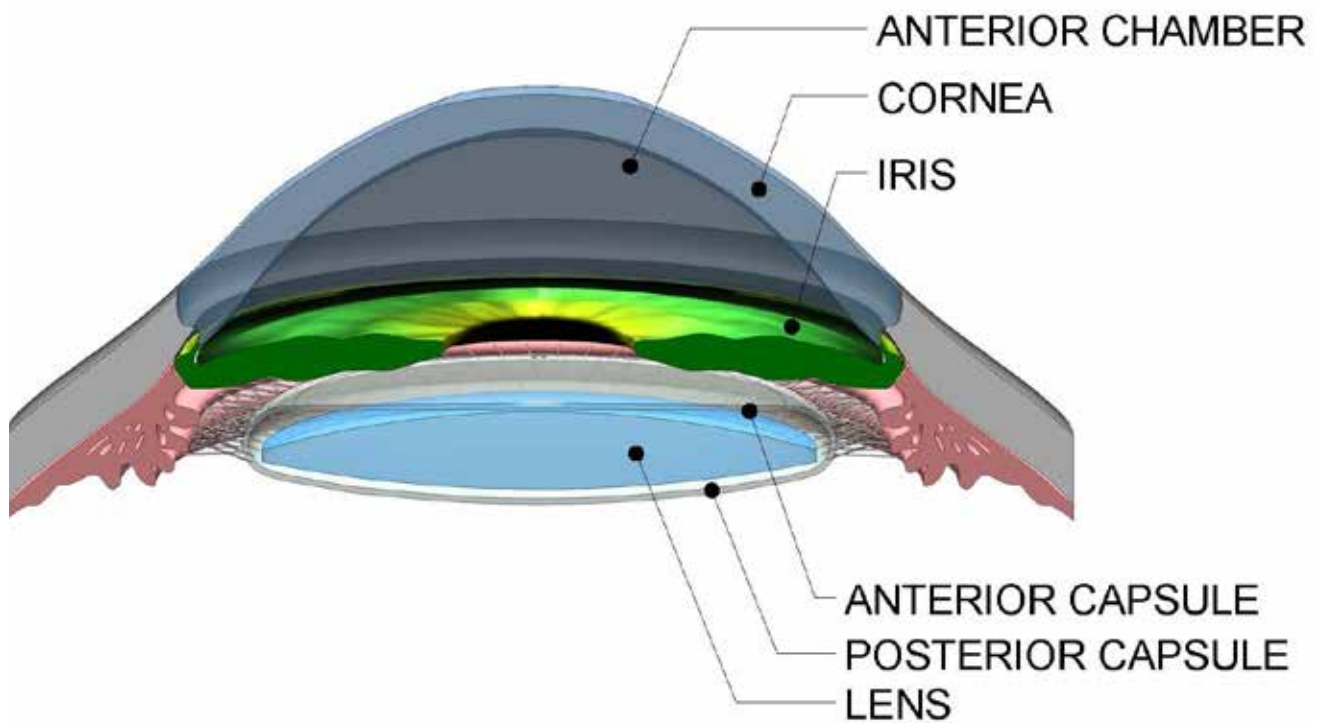


"IN THE BAG" CAPSULAR IOL IMPLANTATION

tions, inflammation, drug reactions, metabolic or genetic disorders or they can be idiopathic. Fetal infection is most common when the mother is infected during the first trimester. Congenital cataracts have been documented after neonatal infection with varicella, toxoplasmosis, rubella and syphilis. The use of steroids while in utero has been shown to cause congenital cataracts.⁶ Metabolic deficiencies are associated with bilateral congenital cataract formation. Examples include galactosemia, Lowe's syndrome, Down syndrome and Type 1 diabetes.⁷ Both unilateral and bilateral congenital cataracts can be hereditary with autosomal dominant inheritance being the most common.⁶

INDICATION FOR SURGERY

Cataracts can form in different areas in the lens of the eye. Surgical intervention to remove congenital cataracts is only needed when the cataract forms in the child's visual axis and impairs his or her vision. A unilateral cataract that affects vision and has been diagnosed at birth should be surgically removed between four to six weeks of age.⁷ Bilateral cataracts that affect vision and have been diagnosed at birth should be surgically removed one at a time, with the first removed between four to six weeks of age and the second, two weeks following the first procedure.⁷ Performing surgery at this age decreases anesthesia-related complications and lowers the incidence of glaucoma after surgery. Postponing, however, can adversely affect the visual outcome.^{8,9} A delay in cataract removal can interfere with the normal



NATURAL LENS POSITION

development of the vision centers in the brain. If the child has no visual input from the eye with the cataract, the brain will not receive necessary information to form neurological pathways for sight in that eye. If this happens, the child may never form useful vision in that eye, even if the cataract is removed later in life.

INSTRUMENTS, EQUIPMENT AND SUPPLIES

Pediatric cataract surgery requires the Certified Surgical Technologist (CST) to have a basic knowledge of micro surgery and ophthalmic instrumentation. As with most surgical procedures, each ophthalmic surgeon has his or her own preferences for instrumentation. Table 1 shows a general list of instruments, equipment and supplies needed to perform

a pediatric cataract removal surgery and intraocular lens implantation, if planned.

PROCEDURE OVERVIEW

General anesthesia is administered by the anesthesiologist, and the patient is positioned supine on a specialized eye cart with an articulating head piece. After the time out, the patient's operative eye is prepped by the circulating registered nurse (RN) with a 5% povidone-iodine solution diluted with balanced salt solution and the eye is draped by the CST. A 4-0 silk suture is placed by the surgeon to hold traction and keep the eye from rolling upward. A superior circumlimbal incision is made by the surgeon with a micro vitreoretinal (MVR) blade just outside the cornea. The eyelid and superior orbital rim provide protection in a trauma-

prone pediatric patient when the incision is placed here. The surgeon then makes a paracentesis temporally. A bipolar cautery is used by the surgeon to control bleeding. Then, the surgeon makes an opening into the anterior chamber with a keratome blade, and injects a viscoelastic material into the anterior chamber of the eye to maintain the chamber space and prevent collapse.

Capsulotomy

The lens of the eye has a thin capsule around it, so an opening must be made anteriorly to access the lens material. This opening is called an anterior capsulotomy and is achieved by the surgeon using capsulorrhexis forceps to make a continuous curvilinear capsulorrhexis (CCC) in which the surgeon manually makes a curvilinear tear that makes a round circular opening. A capsulotomy also can be made by vitrectorrrhexis which achieves an anterior capsulotomy using the vitrector probe.

Lensectomy

The next step in cataract surgery is to remove the opaque cataractous lens material. The vitrector-aspirator probe and a blunt irrigation cannula are placed in the incisions by the surgeon and are used to remove the lens material. Pediatric eyes are less rigid than adult eyes so the constant flow of irrigation from the cannula helps to prevent the anterior chamber from collapsing during the lensectomy. The irrigation also breaks up the viscid lens material making it easier to aspirate, which is performed with the vitrector-aspirator hand piece. If the lens material is too thick to aspirate alone, the vitrector hand piece has a cutting feature. The lens material is aspirated into the vitrector port, and a rapid guillotine-like blade removes that portion and aspirates it.

IOL insertion

When the lens material is removed from inside the capsule that surrounds it an empty capsular bag remains. When a new artificial intraocular lens (IOL) is placed inside this structure it is referred to as an in-the-bag IOL fixation. The capsular bag is the best location for IOL implantation because it is the most stable and the most physiologic position.¹⁰ However, there are many factors in pediatric eyes that make it difficult to keep the capsular bag open, stable and intact. If the IOL cannot be implanted in the capsular bag, it is implanted by the surgeon into the ciliary sulcus.¹¹ Figure 1 illustrates a normal lens in its natural position: an IOL placed in the capsular bag and an IOL placed in the ciliary sulcus.

TABLE 1

INSTRUMENTATION

Cataract tray to include:

- Eye speculum
- Catsroviejo suturing forceps with teeth x2
- McPherson tying forceps smooth x2
- Kuglen iris hook and lens manipulator
- Sinsky lens manipulating hook
- Castroviejo caliper
- Capsulorhexis forceps
- Hartmann mosquito forceps
- Vannas capsulotomy scissors
- Westcott tenotomy scissors
- Castroviejo needle holder

EQUIPMENT

- Vitrectomy system
- Eye bed for patient with wrist rest
- Eye chair for surgeon with back and arm rests
- General ophthalmic microscope
- Indirect ophthalmoscope

SUPPLIES

- Custom cataract pack
- Gloves
- Blades: MVR blade 23 gauge
 - Crescent knife 2.5mm 55o bevel up
 - Keratome blade 2.5mm angled
- Drapes: Split sheet drape
 - 1061 steri drape
- Suture: 4-0 silk on a BB taper needle for traction
 - 10-0 vicryl on a CS140-6 spatula needle to close corneal incision
- Specialty: Bipolar cautery pencil
 - Anterior chamber cannula
 - Automated vitrector-aspirator probe pack
- If implanting intraocular lens (IOL):
 - Intraocular lens cartridge
 - Intraocular lens-size will depend on patient
 - Intraocular lens injector
 - Lens inserting forceps
- Intraoperative medications:
 - Balanced salt solution (BSS)-topical to moisten cornea
 - BSS Plus with epinephrine -intraocular irrigation
 - Sodium hyaluronate ophthalmic filler
 - to keep the eye from collapsing
 - Carbachol to constrict iris after lens implantation
 - Dexamethasone 4ml/ml - anti-inflammatory
 - Cefazolin 1G - antibiotic
- Dressings: Eye pad
 - Eye shield

The insertion of an IOL is a routine part of cataract surgery in adults. However, there is discussion among pediatric ophthalmic surgeons as to whether or not an IOL should be implanted in an infant at the time of surgery. The other option is to leave the child aphakic or without a lens until the child is older and the eye is larger. The IOL then could be implanted during a separate procedure. If this is the case, the child would have to wear a contact lens or glasses until then. Some ophthalmic surgeons feel that implanting an IOL at the time of surgery is important in encouraging normal visual development and preventing amblyopia commonly known as lazy eye. Others feel it is more appropriate to correct the vision of an aphakic eye with glasses or contact lenses until the child is older. This option reduces the risk of a severe inflammatory response brought on by placing a large IOL into a small capsular bag.¹¹

Closure

While a sutureless cataract surgery is appropriate in adults, it may not be the best closure for pediatric patients. Greater physical activity and less attention to and protection of the incision are associated with an increased risk of complications postoperatively.¹² The surgeon repairs the surgical wound with 10-0 monofilament sutures. The circulating nurse then places ophthalmic antibiotic and steroid medication in the operative eye, and an eye pad is taped over the eye by the CST, followed by an eye shield.

Cataracts can form in different areas in the lens of the eye. Surgical intervention to remove congenital cataracts is only needed when the cataract forms in the child's visual axis and impairs his or her vision.

POST-OPERATIVE COMPLICATIONS

Post-operative complications occur more commonly after pediatric cataract surgery than adult cataract surgery and many of these complications do not develop for years following the operation. As a result, it is critical that children be monitored closely on a long-term basis by their surgeon after cataract surgery.³ Some possible complications following cataract surgery include anesthetic reactions, glaucoma,

amblyopia with eye wiggling (nystagmus), retinal detachment, infection, hemorrhage or secondary membrane growth. Frequently, a second surgery is required to treat these complications. In rare cases, some complications can be permanent and lead to blindness.

POST-OPERATIVE CARE

Children will need to be monitored closely after surgery due to the growth and changes of their eyes. Following surgery, a child's vision will need to be corrected with contact lenses or glasses. If an IOL is implanted by the surgeon, the child still will need glasses to correct vision because the IOL cannot focus like a natural lens does. As the eye grows, eye-wear prescriptions will continually change. If an IOL is not implanted and the child is left aphakic, the child will need a strong prescription of glasses or contacts immediately following the procedure.

The frequent application of topical antibiotics, steroids and sometimes cycloplegic medication postoperatively is extremely important to the success of the surgery and the prevention of complications. This burden falls on the parents or caregivers and compliance is often an issue.

Occlusion therapy often is started in unilateral cases as soon as vision is corrected with glasses or contacts.⁶ Occlusion therapy or "patching" is used to try to prevent amblyopia. This is done by occluding the vision in the child's non-operative eye by covering it with a patch. This allows the eye – that was previously occluded with the cataract – time to form the required neurological pathways it missed in the first weeks of life. By covering the non-operative eye, the operative eye is the only source of visual information the brain has, and, in turn, will be utilized more than if both eyes were un-occluded.

ADDITIONAL PROCEDURES

As the child matures there may be a need for additional procedures and operations. If the child is uncooperative during routine post-operative exams, an exam under anesthesia (EUA) may be required to be performed in an operating room. Once the child is anesthetized, the surgeon can see into the back of the eye to monitor the retina, test the pressure in the eye to ensure the child is not developing glaucoma and can test for the ever-changing prescription strength for glasses or contacts. More EUAs may be required as the child grows until they are old enough to be awake and remain in a still position.

Opacification of the posterior capsule or anterior vitreous face is a common complication after pediatric cataract

surgery, particularly in children who have surgery under the age of one.¹² As mentioned earlier, remnants of these structures can serve as a scaffold for fibrous membrane overgrowth. The lens epithelial cells on the vitreous surface or on the back of the optic can be found many months after surgery.⁶ One way to remove this overgrowth is a second surgery. The surgeon uses a vitrectomy hand piece to remove the fibrous membrane. Another way to remove this membrane is with a Nd:YAG laser procedure in an office setting.¹² However, the child must be cooperative and be able to remain still.

Secondary glaucoma is a relatively common but serious complication of pediatric cataract surgery. Glaucoma is a condition of increased pressure within the eye, causing gradual loss of vision. Some eyes with secondary glaucoma can be controlled with topical medication, but many will need a trabeculectomy surgery or a glaucoma shunt placement surgery to control the pressure.⁶

Strabismus is a common effect of visual deprivation or amblyopia. Strabismus is the abnormal alignment of the eyes caused by the loss of vision associated with a pediatric cataract. If patching is not successful in helping the operative eye “catch up” to the non-operative eye, strabismus can develop. Eye muscle surgery may be required to align the two eyes.

LONG-TERM SUCCESS

Visual outcome following pediatric cataract surgery depends on many factors: the age of onset, the time between the onset and surgery, whether the cataract is bilateral or unilateral, the type of cataract, the density of the cataract, pre-existing ocular abnormalities, complications following surgery and the outcome of amblyopia treatment.

Surgery is only the first step in treating a pediatric cataract. Since the post-operative care is a lifelong process, the child's family must be committed to the occlusion therapy schedule and optical correction for the best outcome. With prompt diagnosis and meticulous attention to detail in the surgical management, post-op care, and rehabilitation of pediatric cataracts, most children can enjoy a lifetime of excellent vision.

AUTHOR ACKNOWLEDGEMENTS

I would like to thank Amy A Leverant, MD, for her medical content contribution; and Richard Cotugno, MHSM; and Cheryl Gallaga, MSNEd, RN, CPON; for their literary mentorship.



AUTHOR BIOGRAPHY

Karri Gaetz has been a Certified Surgical Technologist since 2009. She worked for Fairview Red Wing Medical Center in Minnesota before moving to Arizona in 2011. She is currently working at Phoenix Children's Hospital as a CST in multiple specialties such as ENT, general, orthopedics, plastics, neurology and ophthalmology.

REFERENCES

1. Francis PJ, Berry V, Bhattacharya B, Moore AT. The genetics of childhood cataracts. *J Med Genet.* 2000;37:481-488.
2. Haddrill M, Slonim C, MD. Congenital Cataracts. <http://www.all-aboutvision.com/conditions/congenital-cataracts.htm>
3. Lambert SR, Drack AV. Infantile Cataracts. *Surv Ophthalmol.* 1996;40:427-458
4. Vasavada AR, Trivedi RH, Singh R. Necessity of vitrectomy when optic capture is performed in children older than 5 years. *J Cataract Refract Surg.* 2000;27:1185-1193
5. Long VW, Woodruff GH. Bilateral retinal phototoxic injury during cataract surgery in a child. *J AAPOS.* 2004;8:278-279
6. Zetterstrom C, Kugelberg M. Pediatric Cataract Surgery. *Acta Ophthalmol Scand.* 2007;85:698-710
7. Trivedi RH, Wilson ME Jr. Pediatric Cataract Surgery. *J Ophthalmic Surgery.* 2008;20(4): 397-407
8. Birch EE, Stager DR. The critical period for surgical treatment of dense congenital unilateral cataract. *Invest Ophthalmol Vis Sci.* 1996;37(8):1532-1538.
9. Wilson ME, Jr., Trivedi RH, Hoxie JP, Bartholomew LR. Treatment outcomes of congenital monocular cataracts: the effects of surgical timing and patching compliance. *Journal of Pediatric Ophthalmology & Strabismus.* 2003;40(6):323-329.
10. Fallaha N, Lambert SR. Pediatric cataract. *Ophthalmol Clin North Am.* 2001;14:493-499
11. Wilson ME, Jr., Trivedi RH, The Latest in Pediatric Cataract Surgery. *Cataract and Refractive Surgery Today.* June 2013:43-61
12. Karimian F, Javadi MA, Jafarinasab MR. Pediatric Cataract Surgery. *Iranian Journal of Ophthalmic Research.* 2007;2(2):146-153

Pediatric Cataract Surgery

375 MARCH 2015

1 CE credit

\$6

1. **The occurrence rate of pediatric cataracts is _____.**
 - a. 1 to 3 per 10,000 live births
 - b. 1 per 10,000 live births
 - c. 1 to 6 per 10,000 live births
 - d. 1 to 4 per 10,000 live births

2. **Unilateral congenital cataracts are most often _____.**
 - a. Idiopathic
 - b. Traumatic
 - c. Caused by infection
 - d. Caused by metabolic deficiencies

3. **A cataract diagnosed at birth affecting vision should be removed _____.**
 - a. Never
 - b. As soon as possible
 - c. Between four to six weeks of age
 - d. Between two to six weeks of age

4. **All of the following instruments are needed during a cataract surgery except:**
 - a. Vannas capsulotomy scissors
 - b. Skin hook retractor
 - c. Eye lid speculum
 - d. Castroviejo needle holder

5. **The _____ is the best location for lens implantation.**
 - a. Ciliary sulcus
 - b. Capsular bag
 - c. Anterior chamber
 - d. Posterior chamber

6. **Aphakic means:**
 - a. Artificial lens
 - b. Cataractous lens
 - c. Without a lens
 - d. Damaged lens

7. **The surgical wound is closed with _____.**
 - a. 9-0 braided suture
 - b. 10-0 braided suture
 - c. 9-0 monofilament suture
 - d. 10-0 monofilament suture

8. **During the procedure, the surgeon makes an opening into the anterior chamber with a _____.**
 - a. Keratome blade
 - b. Mirco vitreoretinal blade
 - c. Capsulorhexis forceps
 - d. Vitrector-aspirator hand piece

9. **Increased pressure in the eyeball can be controlled by _____**
 - a. Glaucoma shunt placement
 - b. Topical medication
 - c. Trabeculectomy surgery
 - d. All of the above

10. **Pediatric eyes are anatomically different than adult eyes, which makes for a difficult decision when deciding:**
 - a. To perform surgery
 - b. To implant an artificial lens
 - c. To allow the child to wear glasses
 - d. To wait until adolescence to operate

PEDIATRIC CATARACT SURGERY 375 MARCH 2015 1 CE CREDIT \$6

NBSTSA Certification No. _____

AST Member No. _____

My address has changed. The address below is the new address.

Name _____

Address _____

City _____ State _____ Zip _____

Telephone _____

Check enclosed Check Number _____

Visa MasterCard American Express

Credit Card Number _____

Expiration Date _____


	a	b	c	d
1	<input type="checkbox"/>	<input type="checkbox"/>	<input type="checkbox"/>	<input type="checkbox"/>
2	<input type="checkbox"/>	<input type="checkbox"/>	<input type="checkbox"/>	<input type="checkbox"/>
3	<input type="checkbox"/>	<input type="checkbox"/>	<input type="checkbox"/>	<input type="checkbox"/>
4	<input type="checkbox"/>	<input type="checkbox"/>	<input type="checkbox"/>	<input type="checkbox"/>
5	<input type="checkbox"/>	<input type="checkbox"/>	<input type="checkbox"/>	<input type="checkbox"/>
6	<input type="checkbox"/>	<input type="checkbox"/>	<input type="checkbox"/>	<input type="checkbox"/>
7	<input type="checkbox"/>	<input type="checkbox"/>	<input type="checkbox"/>	<input type="checkbox"/>
8	<input type="checkbox"/>	<input type="checkbox"/>	<input type="checkbox"/>	<input type="checkbox"/>
9	<input type="checkbox"/>	<input type="checkbox"/>	<input type="checkbox"/>	<input type="checkbox"/>
10	<input type="checkbox"/>	<input type="checkbox"/>	<input type="checkbox"/>	<input type="checkbox"/>

Make It Easy - Take CE Exams Online

You must have a credit card to purchase test online. We accept Visa, MasterCard and American Express. Your credit card will only be charged once you pass the test and then your credits will be automatically recorded to your account.

Log on to your account on the AST homepage to take advantage of this benefit.

CE EXAM



Earn CE Credits at Home

You will be awarded continuing education (CE) credits toward your recertification after reading the designated article and completing the test with a score of 70% or better. If you do not pass the test, it will be returned along with your payment.

Send the original answer sheet from the journal and make a copy for your records. If possible use a credit card (debit or credit) for payment. It is a faster option for processing of credits and offers more flexibility for correct payment. When submitting multiple tests, you do not need to submit a separate check for each journal test. You may submit multiple journal tests with one check or money order.

Members this test is also available online at www.ast.org. No stamps or checks and it posts to your record automatically!

Members: \$6 per credit

(per credit not per test)

Nonmembers: \$10 per credit

(per credit not per test plus the \$400 nonmember fee per submission)

After your credits are processed, AST will send you a letter acknowledging the number of credits that were accepted. Members can also check your CE credit status online with your login information at www.ast.org.

3 WAYS TO SUBMIT YOUR CE CREDITS

Mail to: AST, Member Services, 6 West Dry Creek Circle Ste 200, Littleton, CO 80120-8031

Fax CE credits to: 303-694-9169

E-mail scanned CE credits in PDF format to: memserv@ast.org

For questions please contact Member Services - memserv@ast.org or 800-637-7433, option 3. Business hours: Mon-Fri, 8:00a.m. - 4:30 p.m., MT

WRITE A CE



We are always looking for CE authors and surgical procedures that haven't been written about or the latest advancements on a commonplace surgery. You don't have to be a writer to contribute to the *Journal*. We'll help you every step of the way, AND you'll earn CE credits by writing a CE article that gets published!

Here are some guidelines to kick start your way on becoming an author:

1. An article submitted for a CE must have a unique thesis or angle and be relevant to the surgical technology profession.
2. The article must have a clear message and be accurate, thorough and concise.
3. It must be in a format that maintains the *Journal's* integrity of style.
4. It must be an original topic (one that hasn't been published in the *Journal* recently.)

How to Get Started

The process for writing a CE can be painless. We are here to assist you every step of the way and make sure that you are proud of your article.

- Write to publications@ast.org, and state your interest in writing, and what topic you would like to author.
- Submit an outline of your proposed topic for review. Once the outline is returned to you for approval, begin writing your manuscript. Getting your outline approved will save you time and effort of writing a manuscript that may be rejected.
- Submit manuscript, as well as any art to illustrate your authored topic. You will be notified upon receipt of receiving the manuscript and as well as any changes, additions or concerns.

Things to remember:

- **Length:** Continuing education articles should run a minimum of 2,000 words and a maximum of 5,000 words.
- **References:** Every article concludes with a list of ALL references cited in the text. All articles that include facts, history, anatomy or other specific or scientific information must cite sources.
- **Copyright:** When in doubt about copyright, ask the AST Editor for clarification.
- **Author's Responsibility:** All articles submitted for publication should be free from plagiarism, should properly document sources and should have attained written documentation of copyright release when necessary. *AST may refuse to publish material that they believe is unauthorized use of copyrighted material or a manuscript without complete documentation.*

Don't delay! Become an author today. Write to us at publications@ast.org