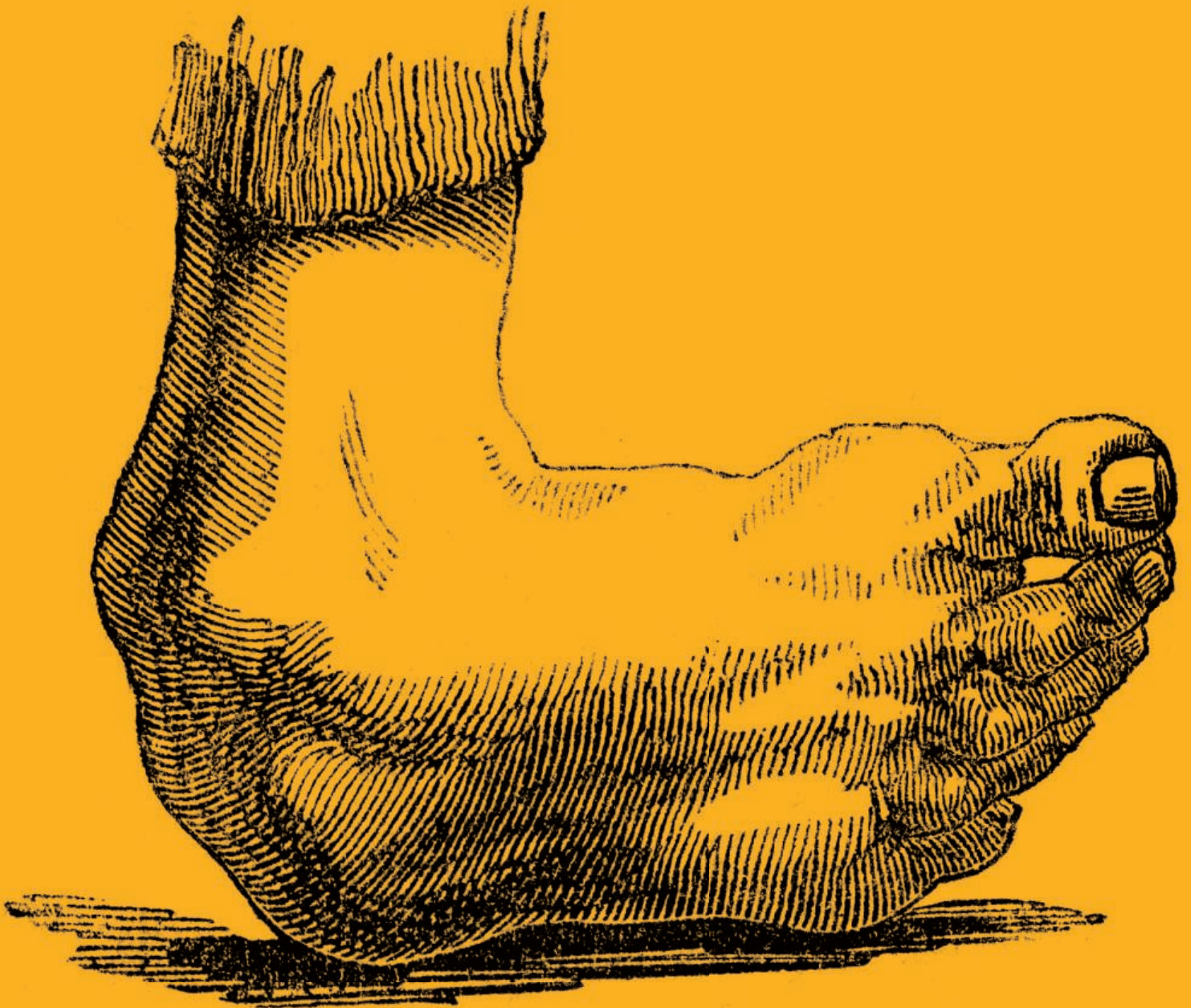

# Posteromedial Release of a Clubfoot

JENNIFER HOPKINS, CST

Clubfoot, also called congenital talipes equinovarus (CTEV), is a congenital defect involving the foot. The defect may be unilateral or bilateral, and the most notable animal to have the defect is horses, hence equin/o in the name. Typically, doctors can fix the defect using different nonsurgical methods, but occasionally, surgery is needed if the deformity is severe.

Statistically speaking, every 1 in 1,000 infants are born with clubfoot annually. In the United States, the incidence rate is roughly 1 in every 68,000 births, which means about 4,000 people each year are born in the United States with a clubfoot. The Office of Rare Diseases (ORD) has classified clubfoot as a rare disease due to the fact that numbers have to be above 200,000 to be considered more common.<sup>2</sup> Luckily for those who have the congenital defect, clubfoot is a non life-threatening condition.

A clubfoot is twisted into a position similar to a golf club, which is essentially where the name came from.<sup>4</sup> The inner tendons of the affected foot are short and tight, while on the opposite side, the tendons are long and loose, causing the sole of the foot to twist inward and give the foot an appearance of a club. The tarsal bones suffer the most changes, resulting in misshapen and poorly positioned bones. The affected leg also will be visibly smaller, due to the gastrocnemius having fewer muscle fibers. The calf will appear higher and thinner than a normal leg, and the clubfoot may be as much as a half inch shorter than the normal foot.<sup>5</sup>

## LEARNING OBJECTIVES

- ▲ Learn how World Clubfoot Day came about
- ▲ Review the anatomy related to repairing a clubfoot
- ▲ Describe the "Z" technique
- ▲ List the procedural steps of a posteromedial release of a clubfoot
- ▲ Review the types of clubfoot

## TYPES OF CLUBFOOT

<b>Equinovarus</b>	<ul style="list-style-type: none"><li>• Most severe type</li><li>• The foot is twisted inward and downward</li><li>• The child does not have a flat sole and must walk on the ball, the side, or top of the foot</li></ul>
<b>Calcaneus valgus</b>	<ul style="list-style-type: none"><li>• Moderately severe form</li><li>• The foot is angled upward and outward</li><li>• The child walks on their heel or inner side of the foot</li></ul>
<b>Metatarsus varus or adductus</b>	<ul style="list-style-type: none"><li>• Mildest form of the defect</li><li>• Doesn't involve the ankle, but instead the bones and connective tissues of the foot</li><li>• The front part of the foot turns inward</li></ul>

### WHY CLUBFOOT OCCURS

There are speculations as to why clubfeet develop, but doctors have yet to completely understand why the congenital deformity happens. The only study that doctors conclude to be widespread is that clubfeet occur twice as much in boys as they do in girls. Other studies suggest that there could be problems during the fetus' developmental fibular stage, anomalous tendon insertions, defective cartilage and possibly even seasonal variations.<sup>7</sup> There also have been theories that clubfoot occurs due to a polio-like condition in prenatal children. There could be a family history, or other neurological disorders in the infant, such as Spina Bifida. But, even with these speculations, essentially more than 90% of patients with clubfoot have an unknown cause.<sup>5</sup>

### DIAGNOSTIC INTERVENTION

Diagnostic intervention is fairly easy, to the point that the doctor most likely knows that their patient has a clubfoot or clubfeet as soon as the infant is born. Sometimes when the mother has an ultrasound, the doctor may notice the deformity on the unborn child. Once the child is born, the doctor may examine the bones with an X-ray, and usually compares the clubfoot with the unaffected foot if the infant does not have bilateral clubfeet.<sup>4</sup> Essentially, the diagnosis will be evident, and the infant will require treatment before it becomes a toddler. If left untreated, the child will be hindered in attempts to learn to walk. The ultimate goal is to avoid surgery if possible, and the Ponseti method is usually set in motion right after birth. The Ponseti method is a series of castings for roughly six to eight weeks to

manipulate the foot into correct alignment. If this treatment fails, however, surgery is usually necessary, with one procedure being the posteromedial release.<sup>4</sup>

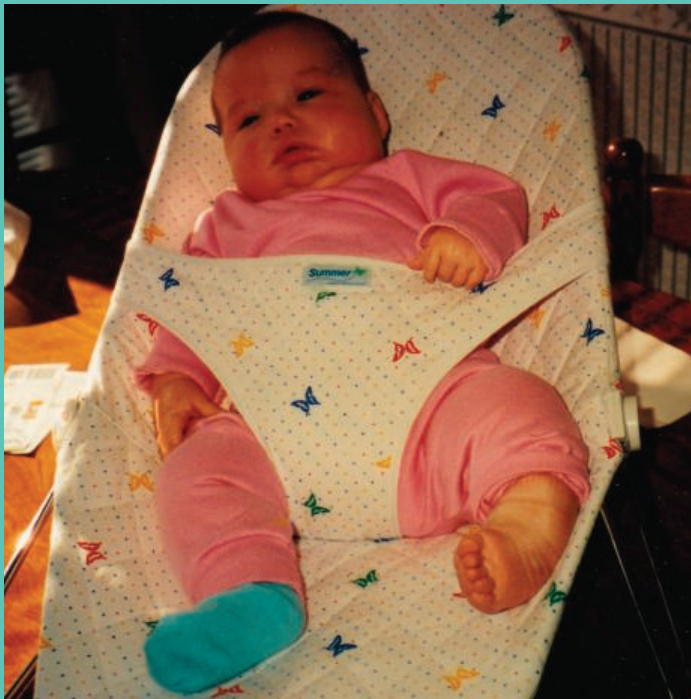
### SURGICAL PROCEDURE

The instrumentation and supplies for this procedure are fairly minimal. A basic orthopedic tray is used, 4-0 non-absorbable and 4-0 absorbable suture, a tourniquet, Kirschner wires, pins, local, intravenous antibiotics, two #10 blades, X-ray detectable sponges, antibacterial skin prep solution, gowns, gloves, towels and irrigation. The patient is placed in the supine position, and a tourniquet is applied to the leg to restrict the blood flow once anesthesia is administered.<sup>6</sup> General anesthesia is given to the patient and the foot and leg are prepped with a skin prep solution. An Esmarch is used to restrict the blood flow to the extremity, and the tourniquet is used to keep the blood flow restricted through the procedure. A half sheet is placed under the leg and a fenestrated sheet is placed around the leg, along with several towels. The knee needs to remain visible during draping so the foot is realigned properly.<sup>6</sup> The surgical technologist and circulator will perform the first sharps and sponge count, and a time out is taken.

Using a #10 blade, an incision will be made along the side of the foot from the Achilles tendon at the ankle to the end of the foot before the hallux begins. A Bovie may be used to assist the opening cut.<sup>6</sup> The surgeon will proceed to cut through fatty tissue and any other layers involved with curved Mayo scissors while using Adson pickups to manipu-

There are speculations as to why clubfeet develop, but doctors have yet to completely understand why the congenital deformity happens. The only study that doctors conclude to be widespread is that clubfeet occur twice as much in boys as they do in girls.

late tissue and retract when necessary. Once the surgeon has cut through the fatty tissue and any other tissues, the flexor digitorum longus will be located and dissected using the curved Mayo scissors and Adsons with teeth. If necessary, the smooth end of a rake may be used to retract the skin.



*Jennifer Hopkins, CST, was born with a clubfoot. She had surgery to fix the condition when she was five months old.*

The surgeon then will proceed to locate and free the tibialis posterior tendon, continuing the use of Adsons and curved Mayo scissors.<sup>6</sup> The process is continued with the posterior talofibular ligament, the calcaneofibular ligament, the posterior third deep deltoid ligament, the talocalcaneal interosseous ligament, the superficial deltoid ligament, the Y ligament and the spring ligament. They are all divided using the “Z-technique.”<sup>6</sup> The surgeon cuts the tendon or ligament into a z shape. When he or she reattaches the two halves, they will be longer than original. The ligaments may be tagged with hemostats so the proper halves will be stitched back together.

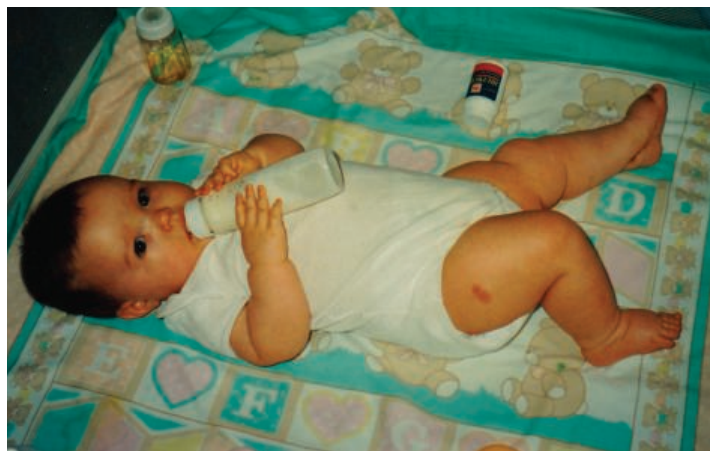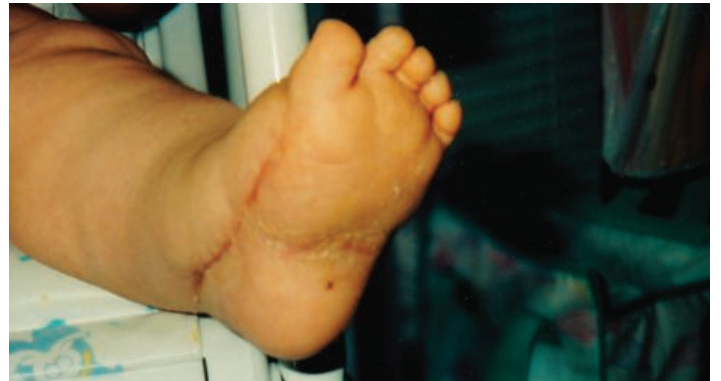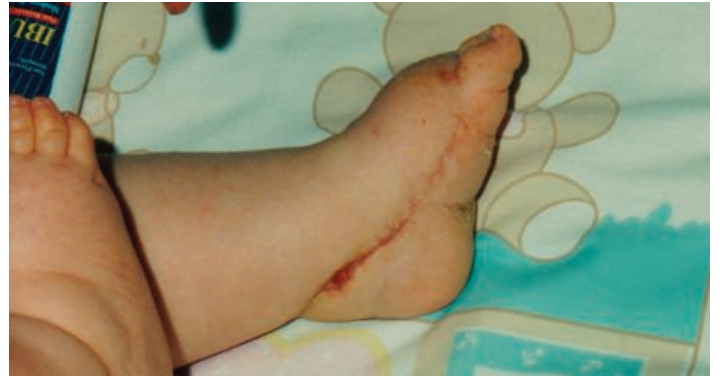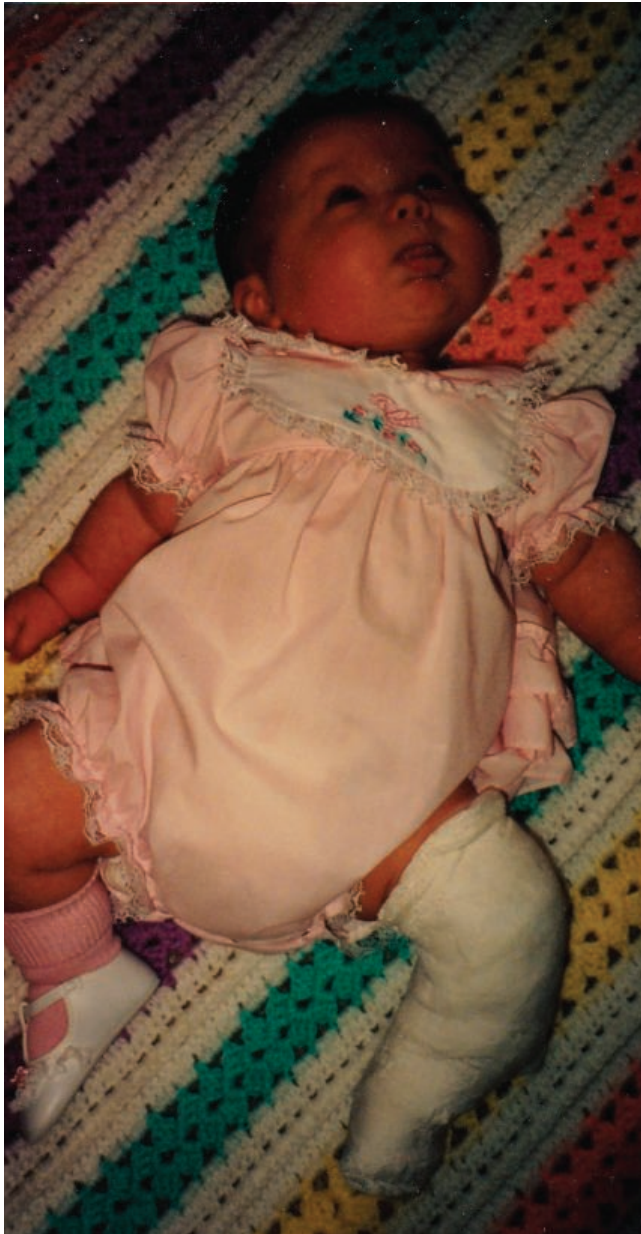The next step will be to align and reposition the bones. The anterior portion of the calcaneus will be moved laterally, the navicular will be moved anteriorly and the head of the talus will be moved medially. To ensure that the foot remains steady, the foot should remain in this position, and a Kirschner wire will be placed through the talus to the first metatarsal to steady the talonavicular joint.<sup>9</sup>

At this point of the surgery, the surgeon will check that the knee and the foot will be in alignment before the tendons are sewn back together.<sup>6</sup> A misalignment would render the procedure null. Once they are confirmed to be aligned, the ligated tendons and ligaments will be stitched together in a loose fashion with non-absorbable suture. As mentioned, the Z-technique will allow the halves to come back together in

a proper but longer manner, which will prevent the ankle from returning to the club position.<sup>6</sup> During this time, the surgical technologist and the circulator will perform a sponge and sharps count. The tourniquet will be released so that the foot may be checked for proper circulation. Typically, the surgeon will feel for a pedal pulse, and may use Adson forceps to check if the patient’s blood flows properly. If there is any excessive bleeding, the surgeon may need to cauterize the blood source. The incision will be closed with an absorbable and/or non-absorbable suture depending on the surgeon’s preference. The patient also will have an antibiotic administered.<sup>6</sup> The final sharps and sponges count will be performed by the surgical technologist and circulator while the incision is being closed, and a cast will be applied. There will not be a specimen.

#### POST-OP

Postoperatively, the child will be in the hospital for about one to three nights following the surgery. Pain medication may be given, and the foot will need to be elevated. If the child is older, then he or she may opt to use crutches to attempt to walk, or they may use a wheelchair. The cast will remain on the foot for roughly four weeks. This allows the stitches to heal and stabilizes the foot so the joint may reform to the new position. After four weeks, the Kirschner



## World Clubfoot Day

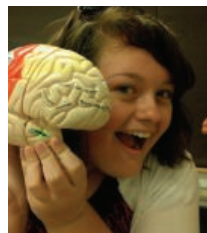Ponseti International Association (PIA) designated June 3 as World Clubfoot Day in honor of Dr Ignacio Ponseti, the man who created the Ponseti Method to treat clubfoot with casts before resorting to surgery. The day is used to spread global awareness about the congenital deformity and the options there are for treatment.<sup>8</sup> For most children, the Ponseti Method works, and even though other children may require surgery, World Clubfoot Day is a day for all children with clubfeet to spread their story and honor Dr Ponseti for all of the work that he dedicated to finding an alternative treatment for children with CTEV.

wires will be removed, and another cast will be applied for two more weeks.<sup>6</sup> Once the casting process is complete, the child will start physical therapy to return flexibility and muscle strength, and a brace usually will be prescribed. The child more than likely will not regain full motion in the affected ankle due to oddly shaped bones and slightly tight tendons and ligaments.

Once the incision sites have healed and physical therapy sessions have been complete, the child should be able to walk normally and play sports. The foot and calf may be noticeably smaller than the unaffected foot, and there may be future complications that require another surgery.<sup>3</sup>

### POTENTIAL COMPLICATIONS

Complications are fairly minimal for this procedure. General complications are similar to those of any other operation. One of the biggest concerns unique to this treatment is that the foot may return to the club position due to puberty. Another concern is that the patient's blood supply may not return to the foot after the tourniquet is released during the procedure. There also is the possibility of extensive scarring, which typically occurs if the stitches dissolve too early and are not replaced.



### ABOUT THE AUTHOR

Jennifer Hopkins became a Certified Surgical Technologist and graduated from her program in 2014. She will have her associates degree in science by the end of the 2015 fall semester, and plans to transfer to a university to

major in biology in January. Jennifer was born with a clubfoot and had the procedure at five months old. She loves science, golfing and corny jokes.

### REFERENCES

1. Clubfoot Club. "What is Clubfoot?" *The Clubfoot Club*. Accessed June 22, 2014. <http://clubfootclub.org/about/>
2. Healthgrades. "Statistics About Clubfoot." *Right Diagnosis*. Accessed June 22, 2014. <http://www.rightdiagnosis.com/c/clubfoot/stats.htm>
3. Kaneshiro, Neil. "Clubfoot repair." *MedlinePlus*. Accessed February 28, 2014. <http://www.nlm.nih.gov/medlineplus/ency/article/002964.htm>
4. Mayo Clinic Staff. "Diseases and Conditions: Clubfoot." Mayo Clinic. Accessed February 28, 2014. <http://www.mayoclinic.org/diseases-conditions/clubfoot/basics/riskfactors/con20027211>
5. Miller, B. *The Parents Guide to Clubfoot*. Berkeley, CA: Publishers Group West. (2012).

In the United States, the incidence rate is roughly 1 in every 68,000 births, which means about 4,000 people each year are born in the United States with a clubfoot.

6. Nitin, J. Childortho.co.in- Postero medial release for resistant CTEV. (2009). Accessed February 28, 2014. <http://www.youtube.com/watch?v=vP3kuS9OFKc>
7. Patel, M. "Clubfoot." Medscape. Accessed February 28, 2014. <http://emedicine.medscape.com/article/1237077-overview#a0104>.
8. Ponseti International Association. "World Clubfoot Day Celebrations." Ponseti International. Accessed June 22, 2014. <http://www.ponseti.info/site/publisher/files/World%20Clubfoot%20Day%20Global%20Celebrations.pdf>
9. Yamamoto, Haruyasu. "Posteromedial Release of Congenital Club Foot in Children Over Five Years of Age." *The J of Bone and Joint Surg.* (1993). Accessed February 28, 2014. [http://boneandjoint.org.uk/highwire/filestream/15292/field\\_highwire\\_article\\_pdf/0/555.full-text.pdf](http://boneandjoint.org.uk/highwire/filestream/15292/field_highwire_article_pdf/0/555.full-text.pdf)

# Posteromedial Release of a Clubfoot

378 June 2015 1 CE credit \$6

1. The Y ligament is one of the ligaments that is divided by using the \_\_\_\_ technique.
  - a. W
  - b. Y
  - c. Z
  - d. X
  
2. In the United States, there are about \_\_\_\_\_ people each year born with a clubfoot.
  - a. 2,000
  - b. 4,000
  - c. 6,000
  - d. 8,000
  
3. The calf of the affected leg appears \_\_\_\_\_ than a normal leg.
  - a. Higher and deeper
  - b. Lower and thinner
  - c. Higher and thinner
  - d. Deeper and lower
  
4. The clubfoot may be as much as \_\_\_\_\_ shorter than the normal foot.
  - a. One inch
  - b. A half inch
  - c. 2 cm
  - d. 4 mm
  
5. Using a #10 blade, an incision will be made along the side of the foot from the Achilles tendon at the \_\_\_\_\_ to the end of the foot.
  - a. Toes
  - b. Arch of the foot
  - c. Calf
  - d. Ankle
  
6. When aligning the bones, the anterior portion of the calcaneus will be moved \_\_\_\_\_.
  - a. Anteriorly
  - b. Laterally
  - c. Medially
  - d. Posteriorly
  
7. The clubfoot's inner tendons are \_\_\_\_\_.
  - a. Short and tight
  - b. Short and loose
  - c. Loose and long
  - d. None of the above
  
8. After \_\_\_\_\_ weeks, the Kirschner wires will be removed, and then another cast will be applied.
  - a. 2
  - b. 5
  - c. 4
  - d. 8
  
9. The Ponseti method is a series of \_\_\_\_\_ for roughly six to eight weeks to manipulate the foot into correct alignment.
  - a. Surgeries
  - b. Physical therapy
  - c. Stitches
  - d. Castings
  
10. The patient is placed in the supine position, and a \_\_\_\_\_ is applied to the leg.
  - a. Tourniquet
  - b. Calf compression
  - c. Warming blanket
  - d. Drape

## POSTEROMEDIAL RELEASE OF A CLUBFOOT 378 JUNE 2015 1 CE CREDIT \$6

NBSTSA Certification No. \_\_\_\_\_

AST Member No. \_\_\_\_\_

My address has changed. The address below is the new address.

Name \_\_\_\_\_

Address \_\_\_\_\_

City \_\_\_\_\_ State \_\_\_\_\_ Zip \_\_\_\_\_

Telephone \_\_\_\_\_

Check enclosed  Check Number \_\_\_\_\_

Visa  MasterCard  American Express

Credit Card Number \_\_\_\_\_

Expiration Date \_\_\_\_\_

	a	b	c	d
1	<input type="checkbox"/>	<input type="checkbox"/>	<input type="checkbox"/>	<input type="checkbox"/>
2	<input type="checkbox"/>	<input type="checkbox"/>	<input type="checkbox"/>	<input type="checkbox"/>
3	<input type="checkbox"/>	<input type="checkbox"/>	<input type="checkbox"/>	<input type="checkbox"/>
4	<input type="checkbox"/>	<input type="checkbox"/>	<input type="checkbox"/>	<input type="checkbox"/>
5	<input type="checkbox"/>	<input type="checkbox"/>	<input type="checkbox"/>	<input type="checkbox"/>
6	<input type="checkbox"/>	<input type="checkbox"/>	<input type="checkbox"/>	<input type="checkbox"/>
7	<input type="checkbox"/>	<input type="checkbox"/>	<input type="checkbox"/>	<input type="checkbox"/>
8	<input type="checkbox"/>	<input type="checkbox"/>	<input type="checkbox"/>	<input type="checkbox"/>
9	<input type="checkbox"/>	<input type="checkbox"/>	<input type="checkbox"/>	<input type="checkbox"/>
10	<input type="checkbox"/>	<input type="checkbox"/>	<input type="checkbox"/>	<input type="checkbox"/>

### Make It Easy - Take CE Exams Online


You must have a credit card to purchase test online. We accept Visa, MasterCard and American Express. Your credit card will only be charged once you pass the test and then your credits will be automatically recorded to your account.

Log on to your account on the AST homepage to take advantage of this benefit.



# WRITE A CE

## CE EXAM



### Earn CE Credits at Home

You will be awarded continuing education (CE) credits toward your recertification after reading the designated article and completing the test with a score of 70% or better. If you do not pass the test, it will be returned along with your payment.

Send the original answer sheet from the journal and make a copy for your records. If possible use a credit card (debit or credit) for payment. It is a faster option for processing of credits and offers more flexibility for correct payment. When submitting multiple tests, you do not need to submit a separate check for each journal test. You may submit multiple journal tests with one check or money order.

**Members this test is also available online at [www.ast.org](http://www.ast.org).** No stamps or checks and it posts to your record automatically!

### Members: \$6 per credit

(per credit not per test)

### Nonmembers: \$10 per credit

(per credit not per test plus the \$400 nonmember fee per submission)

After your credits are processed, AST will send you a letter acknowledging the number of credits that were accepted. Members can also check your CE credit status online with your login information at [www.ast.org](http://www.ast.org).

### 3 WAYS TO SUBMIT YOUR CE CREDITS

**Mail to:** AST, Member Services, 6 West Dry Creek Circle Ste 200, Littleton, CO 80120-8031

**Fax CE credits to:** 303-694-9169

**E-mail scanned CE credits in PDF format to:** [memserv@ast.org](mailto:memserv@ast.org)

For questions please contact Member Services - [memserv@ast.org](mailto:memserv@ast.org) or 800-637-7433, option 3. Business hours: Mon-Fri, 8:00a.m. - 4:30 p.m., MT

We are always looking for CE authors and surgical procedures that haven't been written about or the latest advancements on a commonplace surgery. You don't have to be a writer to contribute to the *Journal*. We'll help you every step of the way, AND you'll earn CE credits by writing a CE article that gets published!

Here are some guidelines to kick start your way on becoming an author:

1. An article submitted for a CE must have a unique thesis or angle and be relevant to the surgical technology profession.
2. The article must have a clear message and be accurate, thorough and concise.
3. It must be in a format that maintains the *Journal's* integrity of style.
4. It must be an original topic (one that hasn't been published in the *Journal* recently.)

## How to Get Started

The process for writing a CE can be painless. We are here to assist you every step of the way and make sure that you are proud of your article.

- Write to [publications@ast.org](mailto:publications@ast.org), and state your interest in writing, and what topic you would like to author.
- Submit an outline of your proposed topic for review. Once the outline is returned to you for approval, begin writing your manuscript. Getting your outline approved will save you time and effort of writing a manuscript that may be rejected.
- Submit manuscript, as well as any art to illustrate your authored topic. You will be notified upon receipt of receiving the manuscript and as well as any changes, additions or concerns.

## Things to remember:

- **Length:** Continuing education articles should run a minimum of 2,000 words and a maximum of 5,000 words.
- **References:** Every article concludes with a list of ALL references cited in the text. All articles that include facts, history, anatomy or other specific or scientific information must cite sources.
- **Copyright:** When in doubt about copyright, ask the AST Editor for clarification.
- **Author's Responsibility:** All articles submitted for publication should be free from plagiarism, should properly document sources and should have attained written documentation of copyright release when necessary. *AST may refuse to publish material that they believe is unauthorized use of copyrighted material or a manuscript without complete documentation.*

**Don't delay! Become an author today.  
Write to us at [publications@ast.org](mailto:publications@ast.org)**