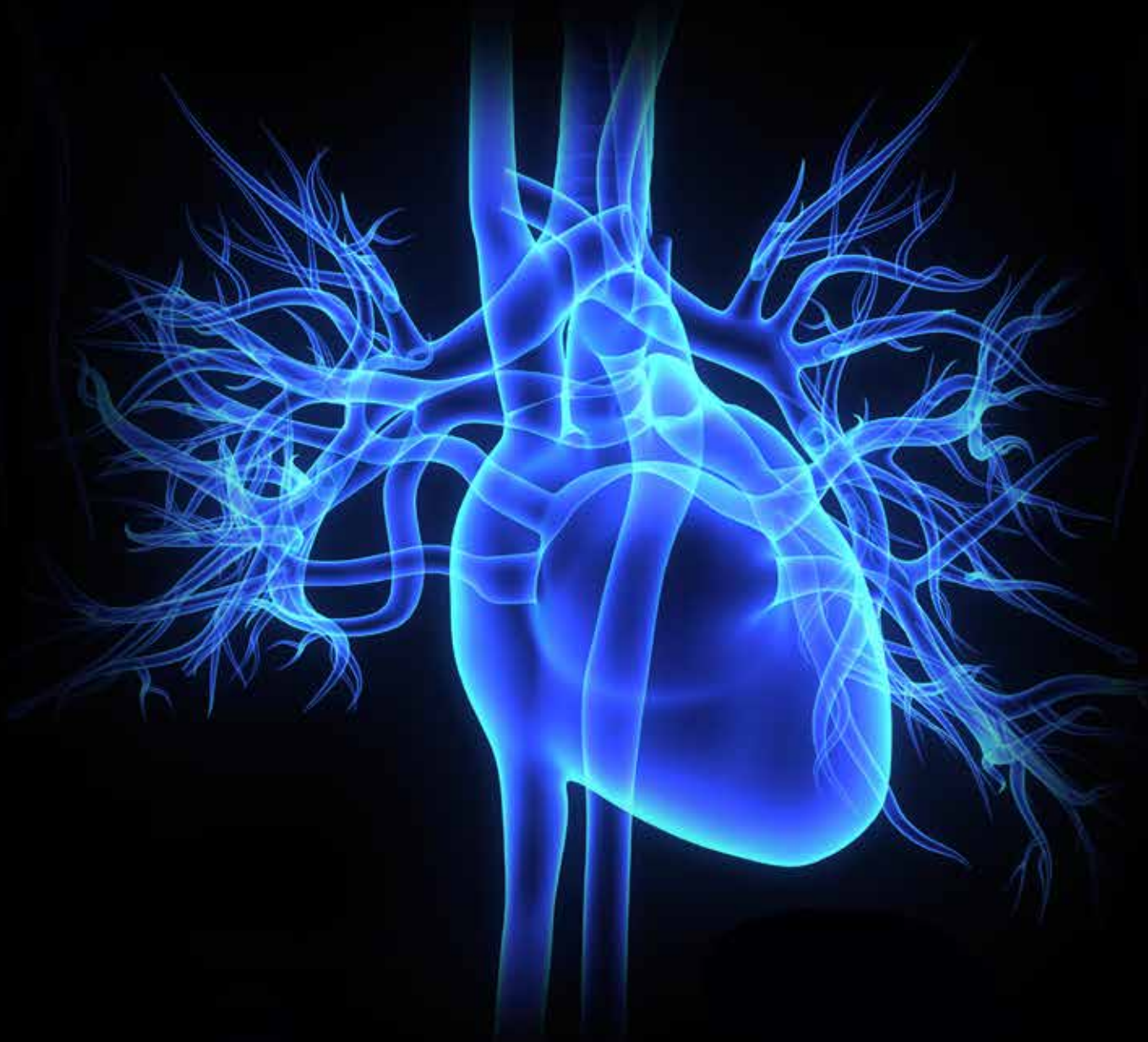



Transcatheter Aortic Valve Replacement (TAVR)

RYAN PARKER, CST, CSFA

Without intervention, 50% of patients suffering from symptomatic aortic valve stenosis will die within two years after the onset of symptoms. However, transcatheter aortic valve replacement procedures are giving patients renewed hope as the procedure allows for a cure for their aortic valve stenosis.

Transcatheter aortic valve replacement procedures are typically for patients who are considered non-operable through traditional sternotomy because of preexisting comorbidities, which prevent them from being candidates, or for cases where open heart surgery has been deemed too risky. The advancements in technology surrounding transcatheter aortic valve replacements have advanced greatly in recent years. New versions of the valves and deployment systems have begun to surface, offering lower profile valves, more valve sizes and smaller sheaths (offering completely percutaneous surgery without a cut down). In the future, this technology may be a less invasive option for any patient suffering with aortic valve stenosis.⁴

PATHOPHYSIOLOGY

The heart is the center of the body's circulatory system. The heart is made up of four chambers. The left and right ventricles dispatch blood and the left and right atriums receive blood. The heart contains four valves. These valves consist of tissue-paper-like leaflets which regu-

LEARNING OBJECTIVES

- ▲ Review the pathophysiology of the heart
- ▲ Explain the condition that is aortic valve stenosis
- ▲ List the advantages of transcatheter aortic valve replacement
- ▲ Recall the procedural steps of a TAVR
- ▲ Identify the complications of this procedure

late unidirectional blood flow. The tricuspid valve allows deoxygenated blood to flow from the right atrium into the right ventricle. The deoxygenated blood will then flow from the right ventricle to the pulmonary artery through the pulmonary valve. At this point the blood will flow to the lungs to become oxygenated and back to the heart via the pulmonary veins (the only veins in the body that carry oxygenated blood), which will then empty into the left atrium. The mitral valve then opens to allow the oxygenated blood to leave the left atrium and enter the left ventricle. The fourth and final valve within the heart is the aortic valve. The aortic valve sits between the left ventricle and the ascending aorta, the largest artery in the body. The ascending aorta is the starting point of the large network of arteries that carry oxygenated blood from the heart to the rest of the body and the veins that return deoxygenated blood back to the heart. The aorta consists of three portions: ascending (portion that arises from the left ventricle), arch (transverse portion that curves up and down into the left chest) and descending segment (includes thoracic and abdominal portion). The abdominal portion of

“Gradual, chronic obstruction to the left ventricular outflow creates an increasing pressure load on the left ventricle. The ventricle must work harder to generate a pressure higher than the aortic pressure in order to propel blood through the narrowed orifice into the systemic circulation. The ventricle cannot compensate indefinitely. Although cardiac output can be maintained for a considerable period, left ventricular dilation occurs, which predisposes the heart to left sided failure and left atrial enlargement. If the ventricle is dilated and LV function is more significantly impaired, preoperative risk increases.”²

Syncope, angina pectoris and dyspnea all can be symptoms of aortic valve stenosis. These symptoms are caused by insufficient blood flow to the brain and the heart and to impaired left ventricular function.³ Traditionally, a patient suffering from severe aortic stenosis would undergo open heart surgery to replace the calcified valve.

Transcatheter aortic valve replacement procedures are typically for patients who are considered non-operable through traditional sternotomy because of preexisting comorbidities, which prevent them from being candidates, or for cases where open heart surgery has been deemed too risky.

TAVR ADVANTAGES

There are several advantages to transcatheter aortic valve replacement, the foremost being recovery time. Patients typically are discharged from the hospital within a few days of their procedure.⁴ TAVR procedures preclude the need for a sternotomy, which is necessary for traditional aortic valve replacement surgery. Also aiding in recovery time is the use of a small

the aorta is where the aorta bifurcates into the common iliac arteries. The femoral arteries are a continuation of the external iliac arteries and are the main arteries of the lower limbs.

AORTIC VALVE STENOSIS

Aortic valve stenosis is a narrowing after the outflow tract from the left ventricle to the ascending aorta. The most common causes of this condition are rheumatic fever, birth defect and radiation therapy with the number one cause being age-related calcification.¹ When calcium deposits that flow through the blood stream begin to accumulate on the annulus and leaflets of the aortic valve, the leaflets become rigid and unable to open freely, resulting in stenosis.

incision at the groin and a few small punctures where the sheaths are placed. This decreases the incidence of infection as well as pain. In most cases, there is no need to utilize the cardiopulmonary bypass machine, which puts less stress on the organs of the body.

There are three main approaches currently being utilized for the TAVR procedures. Most commonly used is the transfemoral approach, where access is gained through the femoral artery. The transapical approach is when access is gained through the apex of the heart and is accomplished through a small left thoracotomy. The transaortic approach, is where access is gained by making a sideline mini-sternotomy directly over the ascending aorta. Two less commonly known TAVR approach options are the carotid and subclavian routes, used for patients with unusual circumstances.

PREOPERATIVE EVALUATION AND TESTING

Preoperative patient selection for a TAVR procedure is extensive. Initial steps include a cardiology consult as well as a cardiothoracic surgery consult. The patient will need to be considered high risk and deemed inoperable by two cardiothoracic surgeons. If, after these two consultations, the patient is still deemed a candidate, the patient will undergo lab work and preoperative testing. These tests include transesophageal and transthoracic echocardiograms (TEE & TTE), ankle-brachial index (ABI), carotid ultrasounds, pulmonary function test (PFT) and computed tomography angiography (CTA), which are part of the TAVR protocol. Many different tools are utilized to predict the risks of the surgical procedure, such as the Euroscore (I and II) and the Society of Thoracic Surgery (STS) Score.

ROOM SET-UP AND PREPARATION

The surgical technologist will need to organize all equipment necessary for the procedure. The team will review wires and sheaths making sure all are readily available. Two back tables will be set up with instruments and sterile supplies. The first table will be used for valve preparation and equipment. The second table will be for the surgical cut down procedure and potential emergent conversion for cardiopulmonary bypass. The surgical technologist will perform a count with the circulating nurse once all instruments and supplies are set up. While this is happening, a team member from the catheterization lab will scrub in.

PREPPING AND DRAPING

An anesthesiologist or certified nurse anesthetist will place a central arterial line, intravenous line and a Swan-Ganz catheter. The patient's head will be placed on a gel headrest, intubated and the Foley catheter and transesophageal echocardiogram probe will be inserted. The apex of the heart will be marked utilizing the transthoracic ultrasound. The patient will be placed in a supine position on a vascular table with his or her arms secured at his or her sides. The patient will be prepped with multiple chlorhexidine prep sticks from chin to knees. A towel will be triple-folded lengthwise and placed at the groin, followed by a peri groin drape, which will be placed atop the patient's legs. Towels will be placed at both sides of the patient's chest so the apex is clearly visible. A fold will be made in the left corner of the towel on the patient's right side to ensure access to the aorta and great vessels. A half sheet will be placed across the patients' head. A back

Supplies and Equipment

Hybrid room with c-arm
Cardiac table pack and basin pack
Heart valve
Valve sheath
Delivery catheter
Valvuloplasty balloon
Dilator set
Lead wall and lead aprons
Radiolucent EKG leads
TEE machine and probe
Mayfield cardiac table
Sternal saw (traditional vs repeat sternotomy)
I-STAT machine and cartridges
Cell saver suction
Cardiopulmonary bypass machine
Arterial and venous cannulas (femoral & traditional)
Multiple back tables
Underbody bair hugger and bair hugger machine
Ultrasound machine and cover
Pacing box
Defibrillator and radiolucent R2 pads
Level 1 (rapid infuser)
Contrast power injector
C-arm cover
Sheaths, wires and catheters
Iopamidol (contrast medium)
Heparin
Bags of injectable NaCl
Basins
Cardiac instrument tray
Valve instrument tray
Suture
Electrocautery unit, pad and pencil
Large antimicrobial incise drapes
Foley catheter
Chlorhexidine sticks
Dressings and liquid adhesive

table cover will be placed lengthwise at the end of the bed in order to accommodate the length of the vascular table. A large antimicrobial incise drape will be placed across the patients' chest to the groin, followed by a cardiac split drape. At this point, sterile light handles will be placed, and suction and the cautery pencil will be thrown off the field to the circulating nurse and plugged in. In some cases, the right arm from the elbow to the hand will be circumferentially prepped and draped in order to leave access to the right radial artery for the cardiologist in the event that coronary stenting becomes necessary.

PROCEDURAL STEPS FOR THE TRANSFEMORAL APPROACH

After the time out is performed, the cardiothoracic surgeon will make a skin incision using a 15 blade on a #7 handle. The surgical technologist will hand the surgeon DeBakey forceps and the cautery pencil. A medium Weitlaner will be placed and the assistant will use an Army/Navy retractor to

There are several advantages to transcatheter aortic valve replacement, the foremost being recovery time. Patients typically are discharged from the hospital within a few days of their procedure.⁴ TAVR procedures preclude the need for a sternotomy, which is necessary for traditional aortic valve replacement surgery.

help with visualization. Metzenbaum scissors will replace the cautery pencil while the surgeon dissects the tissue to expose the femoral artery. Medium and small hemoclips may be used to ligate vessels as the tissue is dissected.

The femoral artery will be isolated using a right angle followed by Dacron tapes and tourniquets or vessel loops. Access will be gained into the femoral artery using an introducer kit (21 gauge needle, .018-inch wire, 5 French sheath). The introducer wire will be replaced with a larger .035-inch exchange wire and a 6 French sheath is inserted into the vessel. Once this is done, the cardiologist and the interventional technologist will take over by placing an extra stiff .035-inch wire over the aortic arch and across the aortic valve. A pigtail catheter will be placed into the ascending aorta through a second 6 French sheath in order to perform an angiogram. A third 6 French sheath will be utilized for an internal pacing wire, which will remain throughout the operation. A super stiff .035-inch wire will be placed into

the external iliac vein through the fourth and final 6 French sheath for the potential of a cardiopulmonary bypass.

A diagnostic angiogram will be performed using a contrast power injector while the surgical technologist and the valve rep inspect the valve, valve equipment and prepare the valve for insertion. Once the valve has been prepped, the surgical technologist will present the dilators for introduction of the valve sheath. The valvuloplasty balloon will be de-aired and the insufflator will be filled with the pre-measured amount of contrast medium/NaCl, ensuring it is in locked position. The surgical technologist will hand the balloon and the insufflator to the interventional technologist communicating the size of the balloon, the pre-measured amount of contrast medium/ NaCl in the insufflator and its locked position. The interventional technologist or surgical technologist will assist the cardiologist/cardiothoracic surgeon by placing and removing the increasing sizes of dilators on the extra stiff wire to dilate the femoral artery

and the valve sheath, and prepare to advance the valvuloplasty balloon. Once the balloon is advanced and in place within the aortic valve another time out will be performed and the balloon will be inflated under rapid heart pacing.

While the valvuloplasty is performed, the surgical technologist and the valve rep will finalize the preparation and position of the new valve on

the delivery catheter. The primary cardiothoracic surgeon or cardiologist will check the position and orientation of the valve on the delivery catheter. Once the placement is confirmed, the valve will be crimped the rest of the way into its final position.

The valvuloplasty then will be complete and the cardiologist will be ready for the valve. The surgical technologist will bring the prepared delivery catheter containing the valve and the insufflator to the operative field and it will be given to the interventional technologist. The surgical technologist will communicate the size of the valve, the amount of contrast medium/NaCl in the insufflator and its locked position. The cardiologist will advance the delivery catheter into the aortic arch and delicately advance it into place within the aortic valve. Before deploying the valve, rapid pacing is induced so that aortic valve will be in the open position and the native leaflets will be out of the way. If the placement of the prosthetic valve is agreed upon by

the cardiothoracic surgeons, cardiologists and echo cardiologist, the valve will be deployed using an insufflation device with a pre-measured amount of contrast medium/NaCl. Once the valve is deployed, the contrast medium/NaCl will be aspirated from the balloon using the same insufflation device and the rapid pacing is stopped. The delivery catheter will be removed from the aorta, and the valve placement will be evaluated by angiogram and TEE.

A collaborative reading will be performed by the cardiothoracic surgeon, cardiologist and an echo cardiologist to determine adequate placement and possible valvular or paravalvular leaks. At this time, the cardiothoracic surgeon will remove the delivery catheter and place an angled DeBakey vascular clamp across the femoral artery. The femoral arteriotomy will be closed using Stille forceps and multiple 5-0 polypropylene sutures. The incision will be irrigated with antibiotic irrigation, and the surgical technologist and the circulating nurse will perform the final count. The first fascial layer is closed with interrupted 0 polyglactin sutures. The second fascial layer will be closed with a running 2-0 polyglactin suture and the skin will be closed with a running 3-0 poliglecaprone 25 suture. The incision site will be covered with a layer of liquid adhesive and a transparent dressing with chlorhexidine gluconate. The pigtail catheter and internal pacing wire will be removed by the cardiologist as well as the 6 French sheaths. The cardiothoracic surgeon will remove the 6 French sheath and extra stiff .035-inch wire that was placed as an access point in case cardiopulmonary bypass was needed. For vessels not closed with suture, the manual pressure or closure device will be utilized. The patient is usually extubated and transported to the cardiac intensive care unit. However, there are times when a patient might need to remain intubated and then will be transported to the cardiac intensive care unit to be extubated at a later time.

COMPLICATIONS

As with any surgical procedure there are always risks. Immediate complications include aortic rupture and tamponade, a valve issue such as malposition or leakage, stroke, myocardial infarct from coronary ostium interference and access route trauma such as iliac artery tear. Some of these can be lethal and necessitate the insertion of an intraaortic pump counterpulsation and even prompt a sternotomy and extracorporeal bypass. Other postoperative complications include respiratory failure, renal failure and infections.

RECOVERY

The average hospital stay is two to three days and patients are encouraged to start walking the day following the procedure. Pain medication will be prescribed as necessary. A follow-up appointment will be made to make sure wound site is healing properly, which generally takes as long as two weeks to heal. Cardiac rehabilitation will be scheduled and most patients return to normal activities within one to two months after surgery.



ABOUT THE AUTHOR

Ryan Parker, CST, CSFA, has been a Certified Surgical Technologist for eight years and recently achieved the credentials of Certified Surgical First Assistant. She resides in New Boston, New Hampshire, and currently works as part of the

CVOR team at Catholic Medical Center in Manchester. She would like to extend a special thanks to Yvon Baribeau, MD; Benjamin Westbrook, MD; as well as her colleagues for their continued support and encouragement, and to all who had input for this article.

REFERENCES

1. www.newheartvalve.com 2014, Edwards Lifesciences Corporation.
2. Seifert, PC. Cardiac surgery perioperative patient care. St Louis, Missouri. Mosby 2002.
3. Rosenhek R., et al. Predictors of outcome in severe, asymptomatic aortic stenosis. *N Engl J Med* 343(9):611 2000.
4. Otto CM. Timing of aortic valve surgery. *Heart* 2000; 84: 211-218.

Transcatheter Aortic Valve Replacement (TAVR)

380 August 2015

1.5 CE credits

\$9

1. When calcium deposits that flow through the blood stream begin to accumulate on the annulus and leaflets of the aortic valve, the leaflets become rigid and unable to open freely, which results in _____.
 - a. Syncope
 - b. Rheumatic fever
 - c. Birth defect
 - d. Aortic valve stenosis
2. Which of the following is not one of the three main approaches being utilized for TAVR procedures?
 - a. Transfemoral approach
 - b. Carotid approach
 - c. Transapical approach
 - d. Transaortic approach
3. The valvuloplasty balloon will be advanced and placed within the _____.
 - a. Left ventricle
 - b. Right ventricle
 - c. Aortic valve
 - d. Right atrium
4. Which of the following tests may be used to qualify a patient for TAVR?
 - a. PFT
 - b. CTA
 - c. TTE
 - d. All of the above
5. The patient is placed in which position for this procedure?
 - a. Lithotomy
 - b. Supine with head tilted back
 - c. Supine
 - d. Lateral
6. A large antimicrobial incise drape will be placed across the patient's chest to his or her _____.
 - a. Knees
 - b. Belly button
 - c. Groin
 - d. Thighs
7. The _____ allows deoxygenated blood to flow from the right atrium into the right ventricle.
 - a. Tricuspid valve
 - b. Mitral valve
 - c. Aortic valve
 - d. Pulmonary artery
8. In some cases, the right arm from the elbow to the hand will be circumferentially prepped and draped in order to leave access to the _____ for the cardiologist in the event that coronary stenting becomes necessary.
 - a. Right radial artery
 - b. Left radial artery
 - c. Right lateral nerve
 - d. Right cephalic vein
9. Most patients recovering from TAVR return to normal activities within:
 - a. 1-2 weeks
 - b. 2-4 weeks
 - c. 1-2 months
 - d. 2-3 months
10. The cardiothoracic surgeon will make a skin incision using a 15 blade on a _____.
 - a. #3 handle
 - b. #10 handle
 - c. #6 handle
 - d. #7 handle

TRANSCATHETER AORTIC VALVE REPLACEMENT (TAVR) #380 AUGUST 2015 1.5 CE CREDITS \$9

NBSTSA Certification No. _____

AST Member No. _____

My address has changed. The address below is the new address.

Name _____

Address _____

City _____ State _____ Zip _____

Telephone _____

Check enclosed Check Number _____

Visa MasterCard American Express

Credit Card Number _____

Expiration Date _____

	a	b	c	d		a	b	c	d
1	<input type="checkbox"/>	<input type="checkbox"/>	<input type="checkbox"/>	<input type="checkbox"/>	11	<input type="checkbox"/>	<input type="checkbox"/>	<input type="checkbox"/>	<input type="checkbox"/>
2	<input type="checkbox"/>	<input type="checkbox"/>	<input type="checkbox"/>	<input type="checkbox"/>	12	<input type="checkbox"/>	<input type="checkbox"/>	<input type="checkbox"/>	<input type="checkbox"/>
3	<input type="checkbox"/>	<input type="checkbox"/>	<input type="checkbox"/>	<input type="checkbox"/>	13	<input type="checkbox"/>	<input type="checkbox"/>	<input type="checkbox"/>	<input type="checkbox"/>
4	<input type="checkbox"/>	<input type="checkbox"/>	<input type="checkbox"/>	<input type="checkbox"/>	14	<input type="checkbox"/>	<input type="checkbox"/>	<input type="checkbox"/>	<input type="checkbox"/>
5	<input type="checkbox"/>	<input type="checkbox"/>	<input type="checkbox"/>	<input type="checkbox"/>	15	<input type="checkbox"/>	<input type="checkbox"/>	<input type="checkbox"/>	<input type="checkbox"/>
6	<input type="checkbox"/>	<input type="checkbox"/>	<input type="checkbox"/>	<input type="checkbox"/>					
7	<input type="checkbox"/>	<input type="checkbox"/>	<input type="checkbox"/>	<input type="checkbox"/>					
8	<input type="checkbox"/>	<input type="checkbox"/>	<input type="checkbox"/>	<input type="checkbox"/>					
9	<input type="checkbox"/>	<input type="checkbox"/>	<input type="checkbox"/>	<input type="checkbox"/>					
10	<input type="checkbox"/>	<input type="checkbox"/>	<input type="checkbox"/>	<input type="checkbox"/>					

11. During the procedure, a _____ retractor is used to help with visualization.

- a. Weitlaner
- b. Army/Navy
- c. Davis
- d. Kelly

12. The cardiologist advances the delivery catheter into the _____.

- a. Aortic arch
- b. Aortic valve
- c. Native leaflets
- d. Femoral artery

13. After a collaborative reading is performed by the cardiothoracic surgeon, cardiologist and an echo cardiologist to determine adequate placement, the cardiothoracic surgeon will remove the delivery catheter and place an angled _____ across the femoral artery.

- a. Weitlaner retractor
- b. Debakey clamp
- c. Stille forceps
- d. French sheath

14. Aortic valve stenosis is a narrowing after the outflow tract from the left ventricle to the _____.

- a. Right ventricle
- b. Abdominal aorta
- c. Arch aorta
- d. Ascending aorta


15. Symptoms of aortic valve stenosis include:

- a. Syncope
- b. Angina pectoris
- c. Dyspnea
- d. All of the above

Make It Easy - Take CE Exams Online

You must have a credit card to purchase test online. We accept Visa, MasterCard and American Express. Your credit card will only be charged once you pass the test and then your credits will be automatically recorded to your account.

Log on to your account on the AST homepage to take advantage of this benefit.



Earn CE Credits at Home

You will be awarded continuing education (CE) credits toward your recertification after reading the designated article and completing the test with a score of 70% or better. If you do not pass the test, it will be returned along with your payment.

Send the original answer sheet from the journal and make a copy for your records. If possible use a credit card (debit or credit) for payment. It is a faster option for processing of credits and offers more flexibility for correct payment. When submitting multiple tests, you do not need to submit a separate check for each journal test. You may submit multiple journal tests with one check or money order.

Members this test is also available online at www.ast.org. No stamps or checks and it posts to your record automatically!

Members: \$6 per credit

(per credit not per test)

Nonmembers: \$10 per credit

(per credit not per test plus the \$400 nonmember fee per submission)

After your credits are processed, AST will send you a letter acknowledging the number of credits that were accepted. Members can also check your CE credit status online with your login information at www.ast.org.

3 WAYS TO SUBMIT YOUR CE CREDITS

Mail to: AST, Member Services, 6 West Dry Creek Circle Ste 200, Littleton, CO 80120-8031

Fax CE credits to: 303-694-9169

E-mail scanned CE credits in PDF format to:

memserv@ast.org

For questions please contact Member Services - memserv@ast.org or 800-637-7433, option 3. Business hours: Mon-Fri, 8:00a.m. - 4:30 p.m., MT