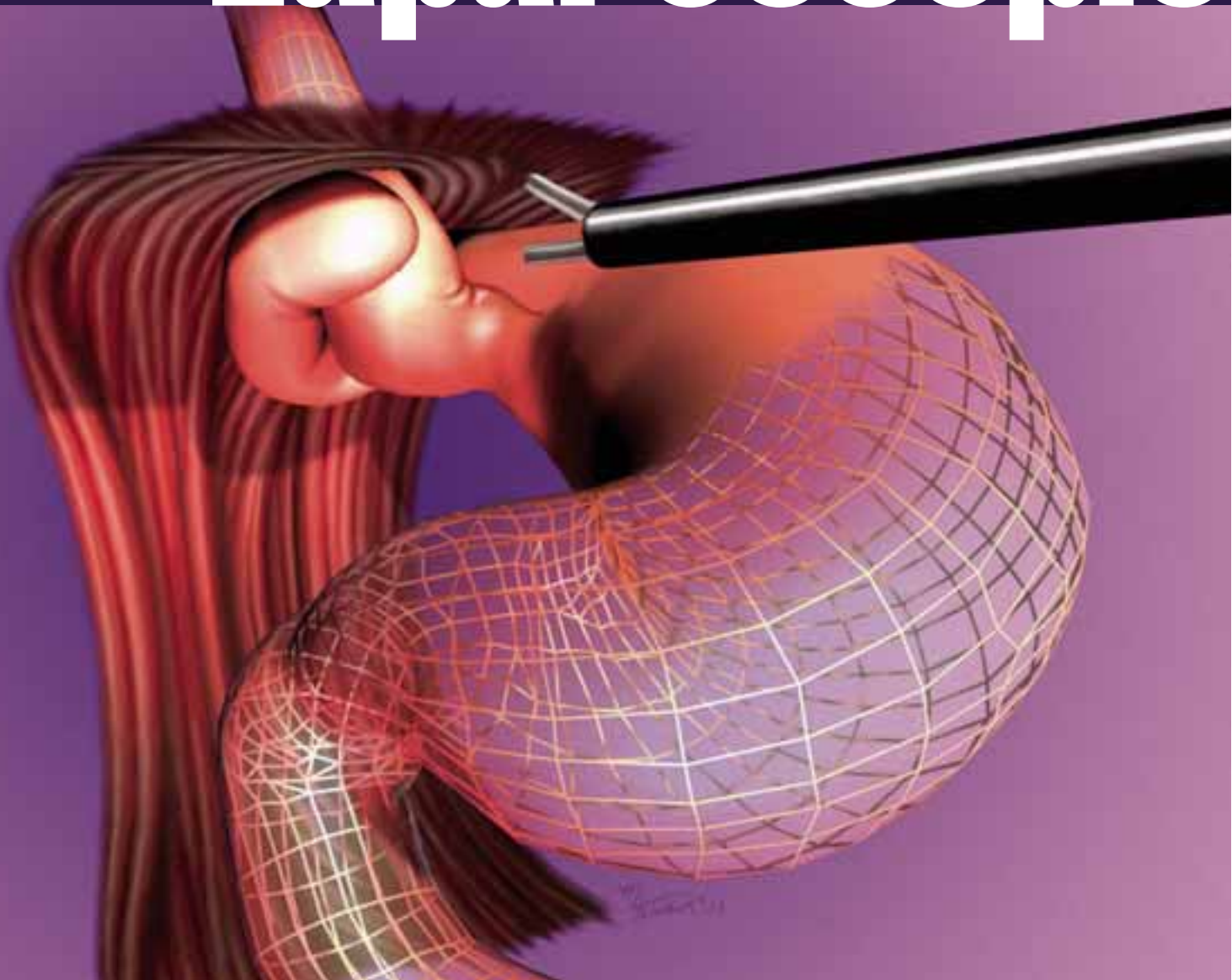


Laparoscopic



antireflux surgery

Edward T Chory, MD
Tracey A Ross, CST, MEd

GASTROESOPHAGEAL REFLUX DISEASE (GERD) IS A COMMON CONDITION WITH A HEAVY ECONOMIC IMPACT. IN A STUDY PUBLISHED IN THE MAY 2002 ISSUE OF *GASTROENTEROLOGY*, RESEARCHERS CALCULATED THAT GERD IS ONE OF THE MOST PREVALENT DIGESTIVE DISEASES IN AMERICA WITH 19 MILLION DIAGNOSED CASES.¹

THE NUMBER OF UNDIAGNOSED CASES PROMISES TO BE MUCH HIGHER BASED ON THE MILLIONS OF HEARTBURN SUFFERERS WHO TAKE OVER-THE-COUNTER MEDICATIONS TO TREAT THEIR SYMPTOMS. GERD IS ALSO THE MOST EXPENSIVE OF THE DIGESTIVE CONDITIONS WITH ANNUAL DIRECT COSTS AT \$9.3 BILLION.¹

et costs, such as missed work and lower productivity, would be almost impossible to measure accurately. However, companies and individuals are likely to feel the financial impact of increased insurance premiums. For example, in 2002, the *Wall Street Journal* reported that the use of proton pump inhibitors (PPIs) increased General Motors' health care budget for employed retirees more than \$55 million.²

With increasing experience in laparoscopic reflux surgery over the last 10 years, morbidity has decreased, outcomes have improved and more patients are undergoing operative procedures to treat GERD. This article will discuss the development of antireflux surgery, patient selection including the evolving indications, important aspects of operative technique, complications and outcomes.

History

Allison described the first successful operation to correct reflux esophagitis in 1951.³ In 1956, Nissen described his method of antireflux surgery that has become the most popular operation for treating GERD.⁴ Reports of results with open Nissen funduplications just before the advent of the laparoscopic surgery documented good to excellent reports in 87-93% with follow up as long as 20 years.^{5,6,7}

In 1991, several groups reported the earliest use of laparoscopic techniques to perform Nissen fundoplication for the treatment of GERD.^{8,9} There has been explosive growth in the application of this new procedure. Experience, though increasing rapidly, allows only short-term follow up. Health care professionals are still ascending the learning curve, indications are expanding, and techniques are evolving, including use of a partial (270°) wrap and esophageal lengthening procedures combined with fundoplication.

Patient selection/preoperative assessment

Clinical symptoms of reflux disease are divided into three categories. (Table 1)¹⁰ The most common symptoms are heartburn and reflux of gastric contents. Secondary symptoms include dysphagia (difficulty swallowing), odynophagia

(painful swallowing), esophageal spasm, and more rarely GI bleeding (hematemesis or melena). Tertiary symptoms are unrelated to the esophagus, such as reflux-induced asthma, hoarseness and pharyngitis. Tertiary symptoms have increasingly been considered indications for antireflux surgery, and recent reports have documented excellent results, particularly for reflux-induced asthma.¹¹

Traditionally, antireflux surgery was reserved for patients who did not respond to medical therapy. Many experts, however, have reported that results with surgery can be predicted by their experience with medical therapy.¹² Patients intractable to medical therapy tend to have less satisfactory postoperative outcomes. Others have reported that patients with typical symptoms have higher "good" and "excellent" outcome scores compared to patients with secondary symptoms.¹³ With increasing experience, improving outcomes, decreased morbidity and shortened length of stay (some centers performing laparoscopic antireflux surgery on an outpatient basis), indications have been expanded to include patients that simply choose surgery over long-term medical therapy.

Fernando et al from the University of Pittsburgh utilized an objective, formal measurement of quality of life scores to compare surgery to medical management.¹⁴ They found superior scores in the surgically treated patients. Cost analysis studies comparing medical and surgical treatment of GERD have found surgical treatment is less expensive, adding an economic indication for antireflux surgery. Patients unable to afford antireflux medications, as well as those unable to tolerate medications because of side effects, are now considered candidates for antireflux surgery. (Table 2)

There was increased interest in surgical treatment of GERD after recent reports of increasing incidence of adenocarcinoma of the esophagus. Barrett's esophagus, metaplasia of the distal esophagus secondary to chronic reflux has long been associated with an increased incidence of adenocarcinoma of the distal esophagus. Most experts consider Barrett's esophagus an indica-

tion for antireflux surgery, although data documenting reversal in the metaplastic changes in the esophagus after surgery is lacking.

Preoperative evaluation of patients considering surgical intervention for GERD is controversial and varies from center to center. Esophageal manometry is absolutely essential. Preoperative manometry is performed to evaluate esophageal peristalsis and rule out motility disorders such as achalasia. Other commonly performed procedures included upper endoscopy, 24-hour pH testing and barium upper gastrointestinal series. Nuclear medicine gastric emptying studies are utilized in patients with suspected gastric emptying difficulties such as diabetic gastroparesis. Many surgeons also utilize abdominal ultrasound to rule out cholelithiasis prior to laparoscopic Nissen fundoplication. (Table 3)

The evaluation of esophageal peristalsis with manometry is used to decide whether a partial 270° wrap (Toupet procedure) is preferable to a full 360° Nissen fundoplication to reduce the incidence of postoperative dysphagia. Most surgeons perform a Toupet procedure in patients with typical symptoms, diminished esophageal peristalsis and documented reflux on 24-hour pH testing. More centers are performing barium upper GI studies to document whether esophageal shortening is present and needs to be corrected, usually with a Collis procedure, combined with fundoplication.

Technique

Patients are admitted the morning of the planned procedure. Acid reducing medications (H₂ blockers or proton pump inhibitors, PPIs) are continued prior to surgery to minimize esophagitis present at the time of surgery.

Preoperative medical and physiologic evaluation and operating room preparation is performed for either a laparoscopic or an open procedure. Informed consent must include the discussion of expected outcomes, common complications and the possible need to convert from laparoscopic to open surgery. The most common problems necessitating laparotomy are adhesions, usually from prior upper abdominal

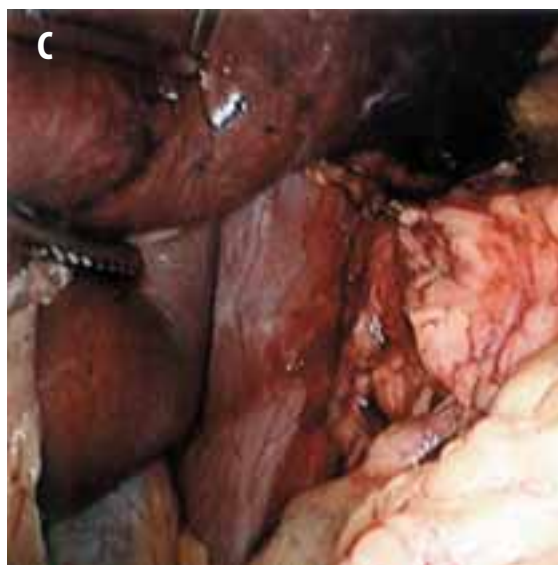
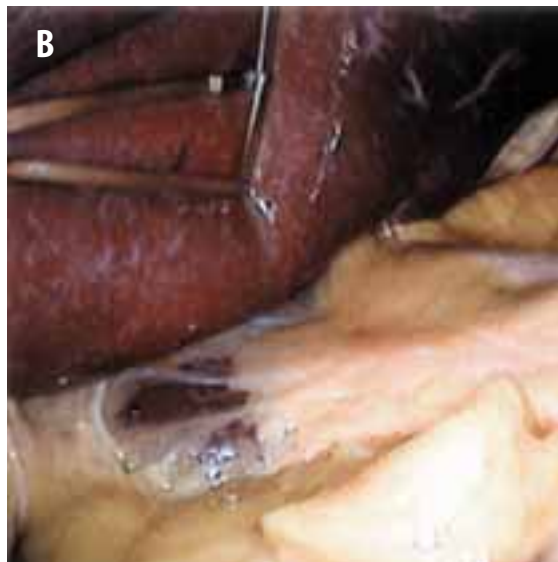
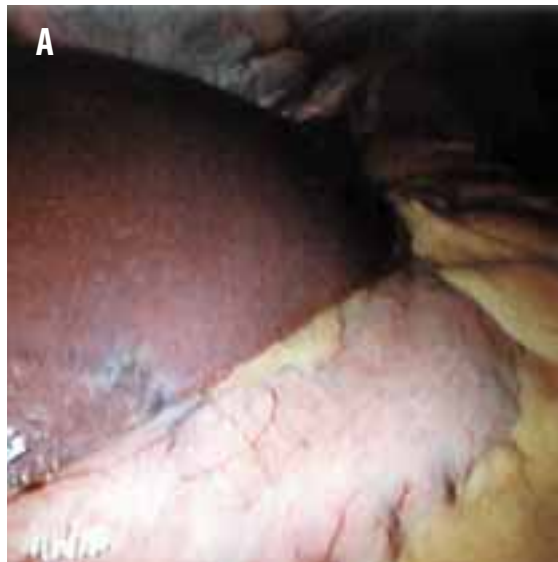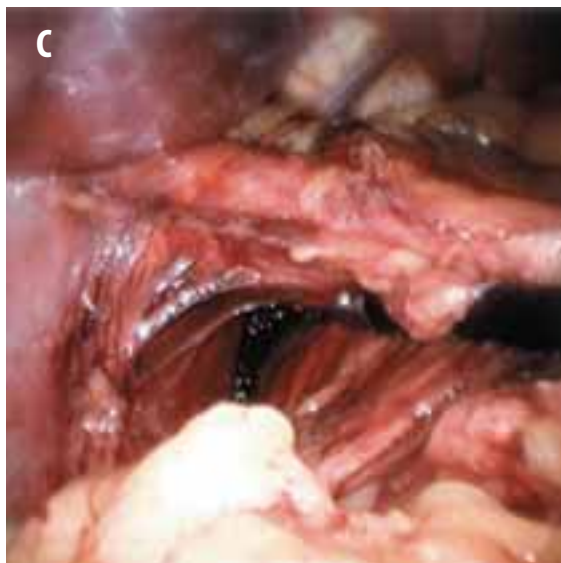
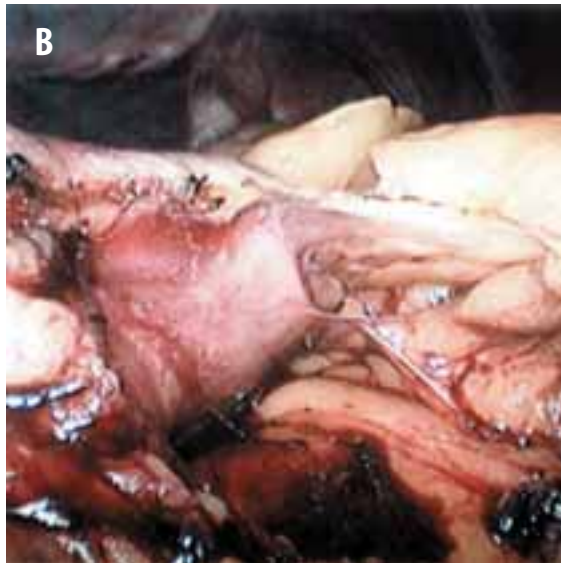

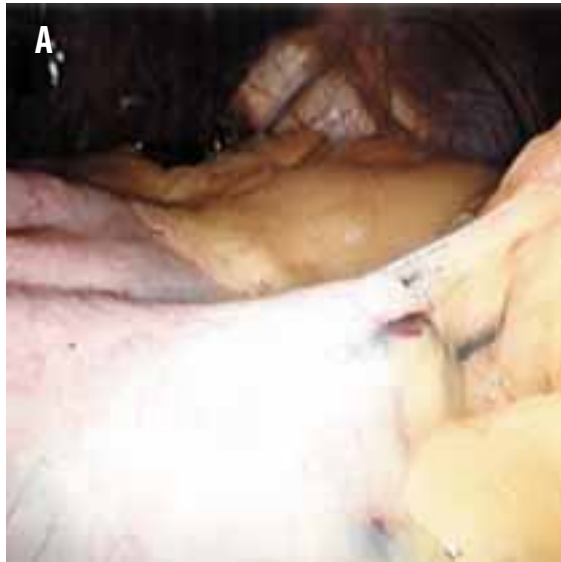
FIGURE 1

- a The liver and stomach are exposed.
- b The liver is retracted with fan. The stomach is retracted with atraumatic grasper, pulled laterally to expose the gastrohepatic ligament.
- c The right crus of the diaphragm is exposed.

FIGURE 2

- a The gastrosplenic omentum is retracted to start division of short gastric vessels with harmonic scalpel.
- b Proximal dissection of short gastric vessels allows for full immobilization of fundus.
- c A view of the retroesophageal window dissection.



surgical procedures including prior antireflux surgery, large left lobe of the liver or morbid obesity preventing visualization of the esophageal hiatus, and intraoperative bleeding.

General endotracheal anesthesia is essential with adequate relaxation to allow for a CO₂ pneumoperitoneum of 14-15 mm Hg pressure and good visualization of the esophageal hiatus. An orogastric or nasogastric tube and Foley catheter are inserted after the induction of anesthesia. Two video monitors are placed on either side of the head of the operating room table. The patient is placed in lithotomy position to allow the operating surgeon to stand between the patient's legs and face the operative field and video monitors at the same time. The thighs should not be flexed more than 20° to 25° so that they will not hinder the mobility of the instruments.

The team at Lancaster General performs open laparoscopy routinely and starts the procedure by inserting a Hassan cannula in the midline several centimeters cranial to the umbilicus. A 10 mm, zero-degree scope is utilized and four trocars are inserted under laparoscopic observation. All trocar sites are transilluminated and infiltrated with long-acting local anesthetic (.25% Marcaine with epinephrine 1:200,000) as the trocars are inserted. 5 mm trocars are inserted near each anterior axillary line, right and left, near the costal margin. The right-sided trocar allows passage of a flexible "snake" retractor to elevate the left lobe of the liver. The left-sided trocar is used to pass an atraumatic grasper to retract the fundus of the stomach and gastrosplenic omentum, as well as dissecting instruments to fully mobilize the fundus, dividing the short gastric vessels and posterior attachments of the fundus.

Two primary operating trocars are passed in the midabdomen. The positions of these trocars vary from patient to patient and are dictated primarily by the patient's habitus, the size of the left lobe of the liver and the position of the falciform ligament. An 11 mm trocar is the primary suturing trocar and is typically inserted in the left midclavicular line, near the costal margin. A

5 mm trocar is passed in the epigastric area near the costal margin, usually just to the right of the midline, entering the peritoneal cavity to the left of the falciform ligament. It is important this trocar allows easy access to the esophageal hiatus without restriction and “crossing swords” with the scope.

The harmonic scalpel is an essential instrument to perform adequate dissection and mobilization of the fundus. Many authors have reported decreased incidence of postoperative dysphagia with full mobilization of the fundus that includes division of the short gastric vessels in the gastrosplenic omentum between the upper pole of the spleen and the greater curvature of the fundus.¹⁵

Once all the trocars have been inserted, a 30° lens is used, and the patient is placed in the reverse Trendelenburg position. This allows the best visualization of the esophageal hiatus. Dissection is typically begun along the proximal lesser curvature of the stomach. The gastrohepatic omentum is divided with the harmonic scalpel. Exposure is optimized and gentle traction on the gastrohepatic omentum maintained by using an atraumatic grasper passed through the left anterior axillary line trocar to retract the stomach laterally and caudally.

The hepatic branch of the vagus nerve, and less commonly the left gastric artery, is seen during this dissection, and care taken to leave these structures undisturbed. An aberrant left hepatic artery can also be located in this area. The right crus of the esophageal hiatus is identified and the peritoneum overlying the anterior esophagus elevated and divided (Figures 1 a-c). Blunt dissection along the right of and posterior to the esophagus can usually allow visualization of the left crus of the diaphragm posteriorly.

The anesthesiologist must be alert for changes in airway pressure or oxygenation when dissection begins along the right crus and into the mediastinum. A tension pneumothorax can be life threatening if not recognized and treated with a thoracostomy. The patient should be prepped in such a way to allow sterile access for this simple procedure, and a small caliber (20

Table 1 Symptoms of gastroesophageal reflux

Typical/Primary Symptoms

Heartburn
Reflux

Secondary Symptoms

Dysphagia
Odynophagia
Hematochezia
Melena
Esophageal ulcer
Esophageal stricture
Barrett’s esophagus

Tertiary symptoms

Reflux induced asthma
Pharyngitis
Hoarseness
Halitosis
Acid taste in mouth

Table 2 Indications for antireflux surgery

Primary symptoms unresponsive to medical therapy/Intractable GERD
Unable to tolerate medications (side effects)
Patient choice (quality of life)/does not want to take life-long medication
Patient unable to afford medication/economic
Barrett’s esophagus
Reflux induced asthma/pharyngitis

French) chest tube should be available in the operating room.

The focus of the dissection is switched to the greater curvature of the stomach and the gastrosplenic omentum, and short gastric vessels are divided with the harmonic scalpel. This dissection should begin approximately 5 cm distal to the GE junction and work proximally. It is often helpful to switch the position of the scope to the 11 mm trocar in the left midclavicular line to allow better visualization to the proximal greater curvature and posterior gastric attachments.

Table 3 Preoperative assessment

Esophageal manometry*
Barium UGI series
24 hour pH testing
Fiberoptic upper endoscopy
Nuclear gastric emptying study
Abdominal ultrasound

* essential preoperative test

Table 4 Complications/morbidity

Intraoperative or postoperative hemorrhage
Intraabdominal organ injury
 Secondary to dissection
 Splenic injury
 Hepatic injury
 Perforation of esophagus or stomach
 Secondary to laparoscopy
 Solid or hollow visceral injury
Acute paraesophageal herniation
Dysphagia
Gas Bloat syndrome/Inability to vomit
Prolonged gastric emptying
Recurrence of reflux
Postop complications not specific to laparoscopic surgery
 Pneumonia
 DVT

As the left lateral and posterior dissection is completed, the left crus dissection is completed (Figures 2 a-c). A 3-inch Penrose drain is used to encircle the distal esophagus. Retraction with the Penrose allows mobilization of the distal esophagus, as well as easier passage of the fundus to create the wrap. The fundus is brought behind the esophagus to be sure the retrogastric space dissection and mobilization of the fundus is adequate to allow the wrap to lie in position without tension or distortion (Figures 3 a-c).

The fundus is then returned to its normal position to allow for crural approximation. Interrupted 0 Ethibond sutures are used to close

the hiatus posterior to esophagus. Typically two or three sutures are required. Do not use pledgets. Once the crural sutures are placed the fundus is again brought behind the esophagus in preparation for the creation of the wrap. The gastric tube is removed, and the anesthesiologist carefully advances a 60 French bougie while laparoscopically observing the GE junction (Figures 4 a-c).

The fundoplication is created using interrupted 0 Ethibond sutures. The suture is passed through the 11 mm trocar in the left midclavicular line and incorporates the fundus to the left of the esophagus, the anterior wall of the esophagus and the fundus to the right of the esophagus. Three or four interrupted, simple sutures are placed without pledgets with the bougie in place. The knots are tied extracorporeally using a knot pusher. The length of the wrap is approximately 2.5 cm (Figures 5 a-c). Care is taken not to suture too closely to the left/anterior vagus nerve on the anterior esophagus.

If a partial wrap (270° Toupet fundoplication) is performed, the right lateral wrap is sutured to the esophagus at 10 or 11 o'clock. The most proximal suture also incorporates the right crus of the diaphragm. The left lateral wrap sutures approximate the fundus to the left lateral esophagus at approximately 1 or 2 o'clock. Interrupted, simple 0 Ethibond sutures, tied extracorporeally are used for the Toupet procedure as for the Nissen fundoplication. Typically six interrupted sutures are placed, three on each side.

After completion of the fundoplication the bougie is removed and the operative field is thoroughly inspected for hemostasis. More recently, the team at Lancaster General has applied 10-20 ml of local anesthesia (.25% Marcaine with epinephrine 1:200,000) to the hiatal area before removing the trocars and releasing the pneumoperitoneum. This technique was described by Milford et al at Kaiser Foundation Medical Foundation in San Diego as a way of allowing outpatient laparoscopic antireflux surgery in selected patients.¹⁶

A portable chest X-ray is obtained in the recovery room on all patients. A Gastrografin/

barium swallow is performed in the early morning on postoperative (PO) day one before starting PO intake. If the swallow excludes a leak, PO fluids are begun and the patient's diet advanced to a soft diet as tolerated. Some surgeons maintain their patients on a liquid diet for as long as two weeks, because they feel solid intake prolongs the resolution of PO swelling and dysphagia.¹⁷ Most patients are discharged on the second postoperative day because inadequate oral intake, and the need for parenteral analgesia prevents discharge on the first postoperative day. The Lancaster General team is able to discharge more motivated patients on the first postoperative day with the use of perioperative Toradol, as well as morphine PCA and topical local anesthetic applied at the completion of surgery.

Morbidity/complications

Conversion from laparoscopic approach to a laparotomy is necessary in less than 2% of patients and should not be considered a complication. Intraoperative bleeding from the spleen, short gastric vessels or liver is a complication that may require transfusion, conversion to an open procedure or both.

The most serious intraoperative complication is perforation of the esophagus or stomach. This complication occurs infrequently (less than 1% in large series) but can be life threatening, particularly if not recognized early, either intraoperatively or within 24 hours after surgery. A UGI contrast study the morning after surgery (before starting oral intake) will exclude this complication.

Dysphagia, difficulty swallowing, is the most common complication of antireflux surgery. It is also normal. The severity and longevity of this problem determines whether dysphagia is significant. Many surgeons discuss dysphagia and weight loss (10-20 lbs) as a normal part of the postoperative course. At least 25% of patients undergoing laparoscopic Nissen fundoplication experience early postoperative dysphagia. Less than 5% of patients suffer dysphagia longer than eight weeks. Early comparisons of open and laparoscopic fundoplication noted higher

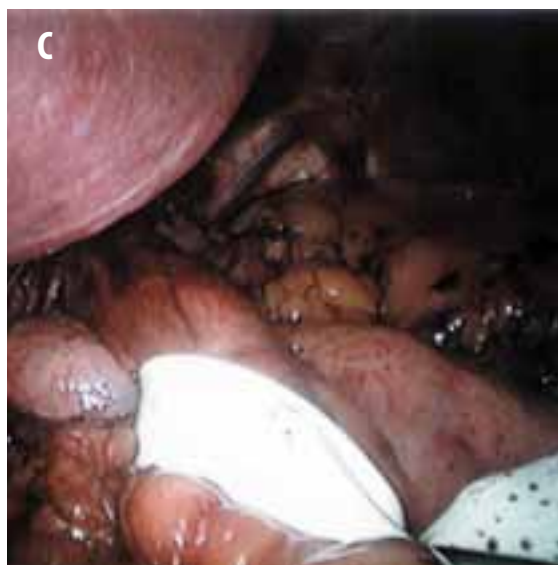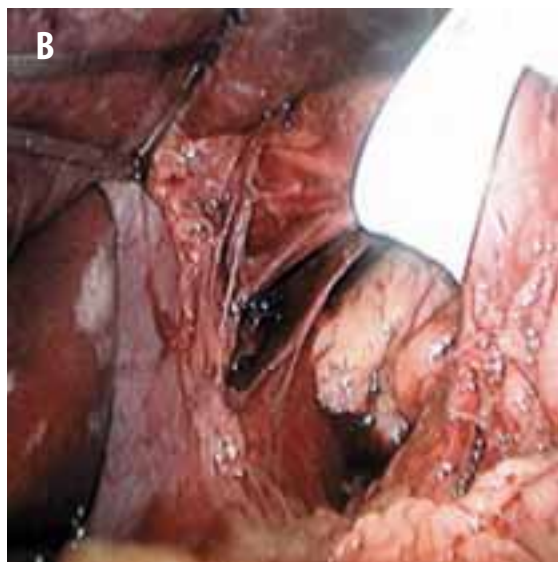
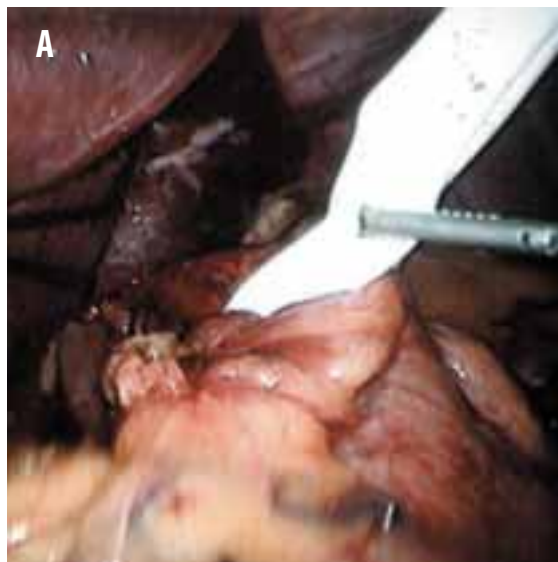
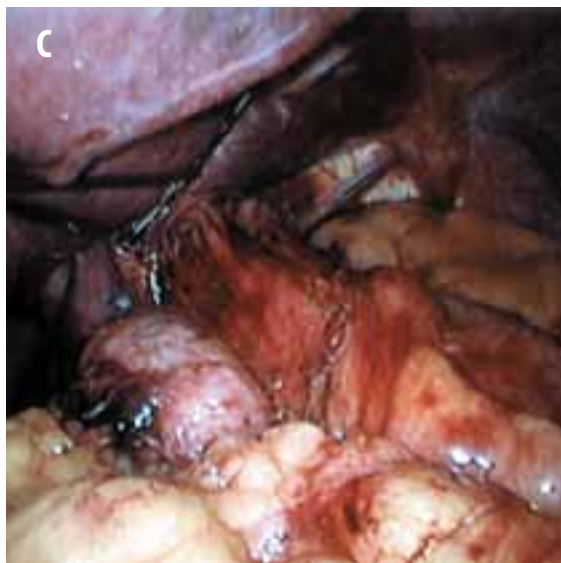
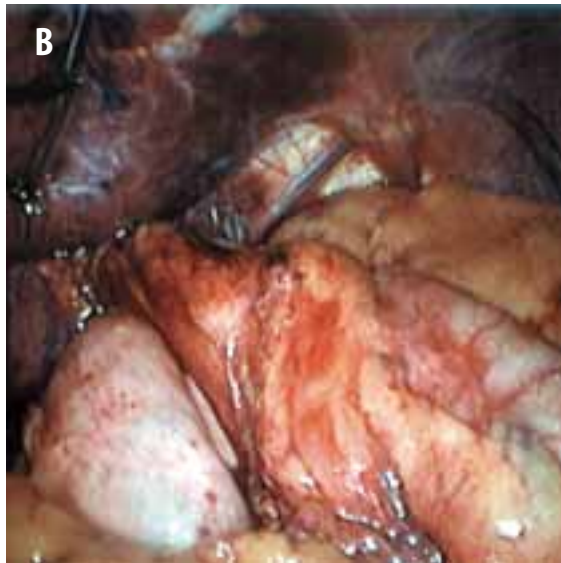
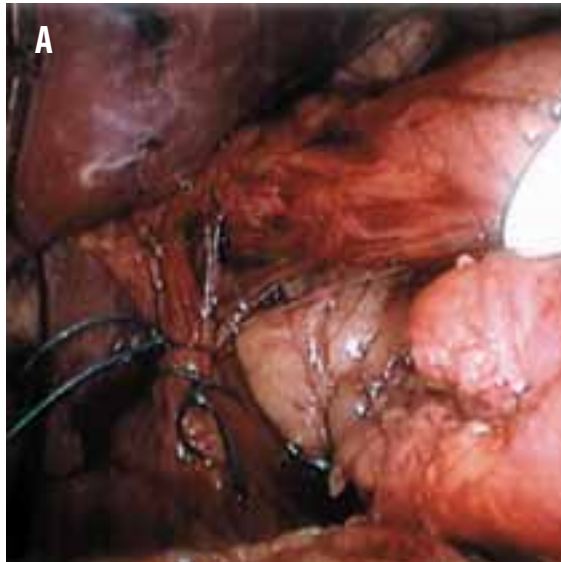


FIGURE 3

- a A 1/2" Penrose drain encircles esophagus for retraction.
- b The esophageal hiatus is exposed.
- c Mobility of the fundus is checked to assure the wrap will lie without tension.

FIGURE 4

- a The hiatus is closed with interrupted 0 Ethibond sutures.
- b A view of the wrap when ready for suture.
- c A wider view of the prepared wrap.



rates of postoperative dysphagia in laparoscopic patients. As mentioned above, most authorities report a lower rate of dysphagia with more extensive dissection and mobilization of the fundus.¹⁵

If dysphagia persists longer than six to eight weeks postoperatively and results in a weight loss of more than 10% of a patient's preoperative weight, it is significant and should be evaluated. Evaluation of postoperative dysphagia often starts with a barium UGI series but almost always includes upper endoscopy, which may prove therapeutic, dilating a tight fundoplication. Endoscopy earlier than six weeks post op should be cautioned against for two reasons, to allow for spontaneous resolution of postoperative swelling and dysphagia and, more importantly, to prevent disruption of the fundoplication.

Acute paraesophageal herniation is an uncommon early postoperative complication that usually requires early reoperation. Postoperative vomiting or retching may be responsible for this complication. Violent retching or vomiting may also cause disruption of the fundoplication and should be aggressively treated with antiemetic medication.

Gas bloat syndrome and an inability to vomit are complications that have become increasingly less common with the routine use of a large bougie (54-60 French) during creation of the fundoplication.

Complications secondary to laparoscopy may also occur and include injuries to intraabdominal organs, perforation of hollow viscus, trocar site bleeding and hernias.

Outcomes

Outcomes have been traditionally categorized as excellent, good, fair or poor. Prior to the advent of laparoscopic surgery, success rates for open antireflux surgery (good and excellent results) were 87-93%. In his text *Surgical Laparoscopy*, Dr Karl Zucker reviewed more than 25 reports of laparoscopic antireflux surgery all with more than 30 patients (35-300 patients).¹⁷ Success rates varied between 84% and 100%.

The reported GERD recurrence rates ranged between 0 and 5.4%. In a more recently published series, Quality of Life scores have replaced the VISCIK grade for evaluation of reflux symptoms.¹⁴ As mentioned above, these series documenting an advantage for surgically treated patients have led to an expansion of indications for antireflux surgery. The subsequent change in experience, performing more surgery on patients with typical symptoms responsive to medical therapy, and therefore a smaller percentage on patients intractable to medical therapy, should result in even further improvement in success rates.

Technical modifications and advancements, such as more extensive dissection of the attachments of the fundus and the harmonic scalpel to allow this dissection to be performed more quickly, should also contribute to improving outcomes. Slippage of the fundoplication has been identified as contributing to both recurrence and dysphagia. This knowledge has also led surgeons to modify their technique to assure mobilization of the esophagus and assure fixation of the wrap to the esophagus, another factor that should lead to further improvement in success rates.

Conclusion

Laparoscopic antireflux surgery has been performed for more than 10 years. It is a safe, effective treatment modality for GERD, a very common condition. Indications are expanding and techniques being improved that should lead to ongoing improvement in outcomes.

Acknowledgments

The authors would like to thank Jane Rossetti, PhD, RN, for her research assistance on this article.

About the authors

Edward T Chory, MD, practices laparoscopic general surgery at the Lancaster Surgical Group in Lancaster, PA. He graduated from The Johns Hopkins University before attending medical school at the University of Medicine and Dentistry of New Jersey. Chory did his surgical resi-

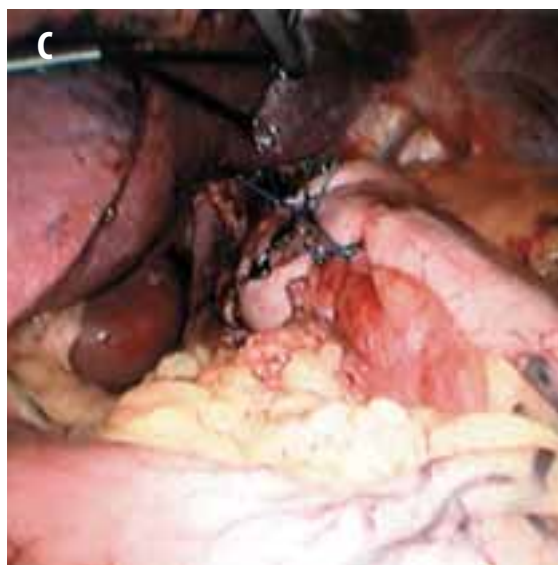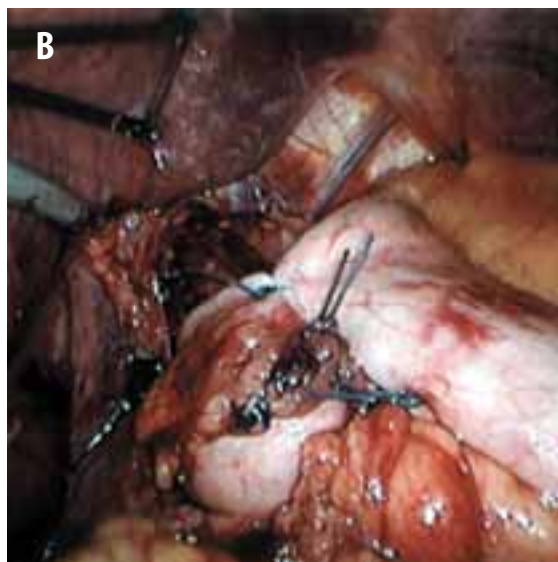
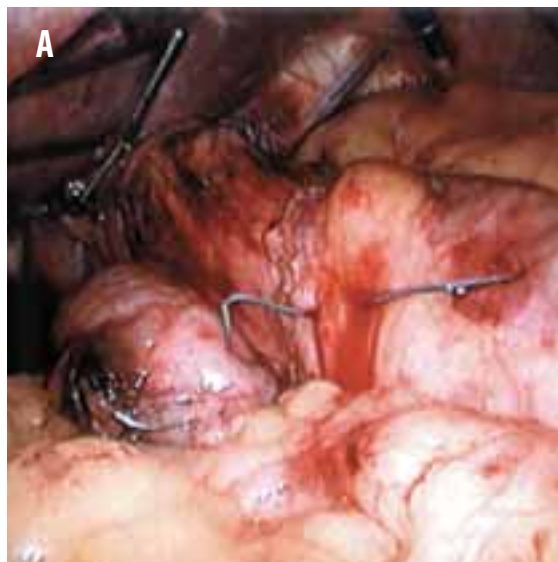


FIGURE 5

- a The first suture is passed to create the wrap.
- b A view of the completed fundoplication.
- c A wider view of the completed fundoplication.

dency training at Saint Vincent's Hospital in Manhattan, New York. He is board certified in general surgery and a fellow of the American College of Surgeons.

Tracey A Ross, MEd, CST, is currently the Surgical Services staff educator at Lancaster General Hospital in Lancaster, PA. Prior to this position, she had several years' experience as a CST and a surgical technology educator. Ross has written articles for *The Surgical Technologist*, the AST Education Committee and the AST *Instructors' Newsletter*. She has served on the Core Curriculum Revision Committee and currently serves on the AST Education and Professional Standards Committee.

References

1. Sandler RS, Everhart JE, Donowitz M, et al. The burden of selected digestive diseases in the United States. *Gastroenterology*. May 2002;122(5):1500-1511.
2. Burton TM. Backlash Rises Against Flashy Ads for Prescription Pharmaceuticals. *Wall Street Journal* [online]. March 13, 2002. Available at online.wsj.com/article_email/0,,SB1015968026351450840,00.html Accessed 3/7/03
3. Allison PR. Reflux esophagitis, sliding hiatal hernia and the anatomy of repair. *Surg Gynecol Obstet* 1951;92:419.
4. Nissen R. Gastropexy as the lone procedure in the surgical repair of hiatus hernia. *Am J Surg* 1956;92:389-392.
5. Stein HJ, DeMeester TR, Hinder RA. Outpatient physiologic testing and surgical management of foregut disorders. *Curr Prob Surg* 1992;29:415-555.
6. DeMeester TR, Bonavina L, Albertucci. Nissen fundoplication for gastroesophageal reflux disease: evaluation of primary repair in 100 consecutive patients. *Ann Surg* 1986;204:9-20.
7. Grande L, Toledo-Pimental V, Manterola C, et al. Value of Nissen fundoplication in patients with gastroesophageal reflux judged by long-term symptom control. *Br J Surg* 1994;81:548-550.
8. Dallemagne B, Weerts JM, Jehas C. Laparoscopic Nissen Fundoplication: preliminary report. *Surg Laparosc Endosc* 1991;1:138-143.
9. Hinder RA, Fillipi, CJ. The technique of laparoscopic Nissen fundoplication. *Surg Laparosc Endosc* 1992;2:265-272.
10. Todd S, Corsnitz D, Ray S et al. Outpatient Laparoscopic Nissen Fundoplication. *AORN Journal* 2002;75:956-979.
11. Spivak H, Smith CD, Phichith A et al. Asthma and gastroesophageal reflux: fundoplication decreases need for systemic corticosteroids. *J Gastroint Surg* 1999;3:477-482.
12. Hinder RA. Surgical therapy for GERD: selection of procedures, short- and long-term results. *J Clin Gastroenterol* 2000;30(3suppl): S48-50.
13. Ritter MP, Peters JH, DeMeester TR et al. Outcome after laparoscopic fundoplication is not dependent on a structurally defective lower esophageal sphincter. *J Gastrointest Surg* 1998;2:567-572.
14. Fernando HC, Schauer PR, Rosenblatt M et al. Quality of life after antireflux surgery compared with nonoperative management for severe gastroesophageal reflux disease. *J Am Coll Surg* 2002 Jan;194(1):23-7.
15. Hunter JG, Trus TL, Branum GD et al. A physiologic approach to laparoscopic fundoplication for gastroesophageal reflux disease. *Ann Surg* 1996;223:673-687.
16. Milford MA, Paluch TA. Ambulatory laparoscopic fundoplication. *Surg Endosc* 1997;11:1150-1152.
17. Laparoscopic Nissen Fundoplication. In: *Surgical Laparoscopy*. 2nd edition. Zucker KA, ed. Philadelphia: Lippincott Williams & Wilkins; 2001:375-400.