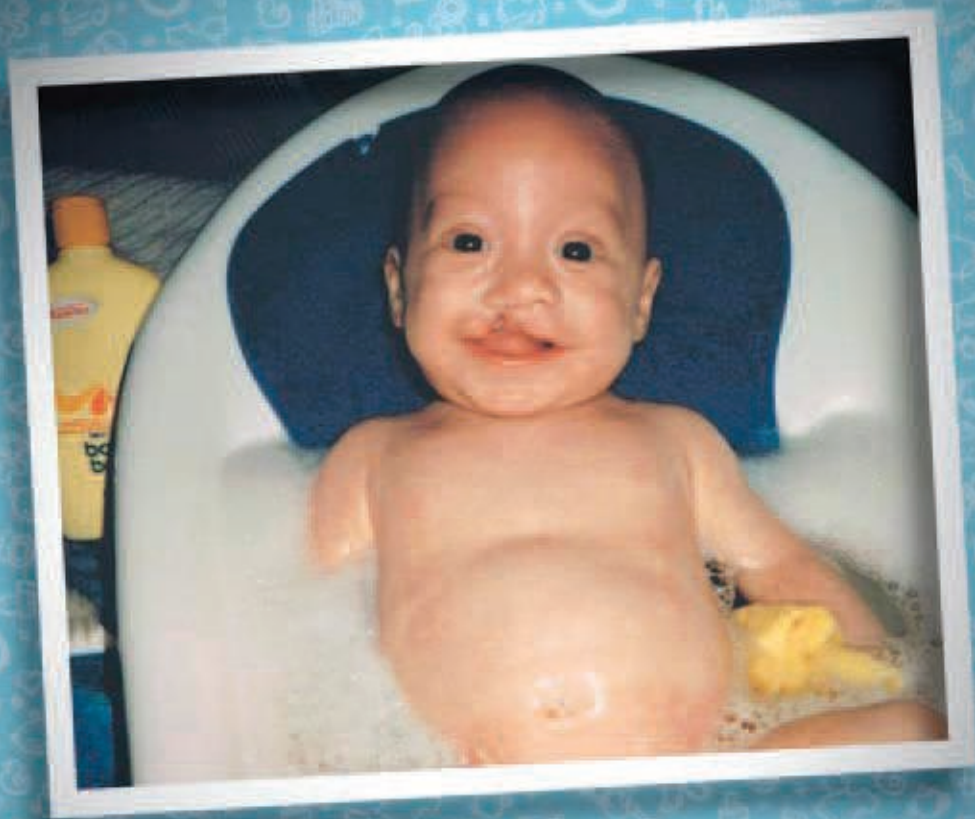



# Palatoplasty—

## ONE PATIENT'S JOURNEY FROM A NINE-MONTH-OLD TO A TEENAGER

PAT MANCILLA

**A**round the fifth week of human embryonic development, facial features begin to form. When proper development is disrupted, a cleft—a fissure or elongated opening—can occur in the lip, palate or both. A cleft in the palate is the result of a lack of fusion of the palatal shelves, which typically occurs between weeks five and 12.

### PREVALENCE OF CLEFT PALATE

This condition tends to be more prevalent in boys. The cleft can be unilateral or bilateral and often appears on the left side of the patient's face.

Currently, cleft lip and palate occur in approximately 1 in 800 births. Exact causes have not been determined, although there appears to be a genetic link in some cases. Maternal age, environmental factors, drug and alcohol abuse, infection and vitamin deficiencies may play a role in cases where there is no apparent genetic link.<sup>5</sup>

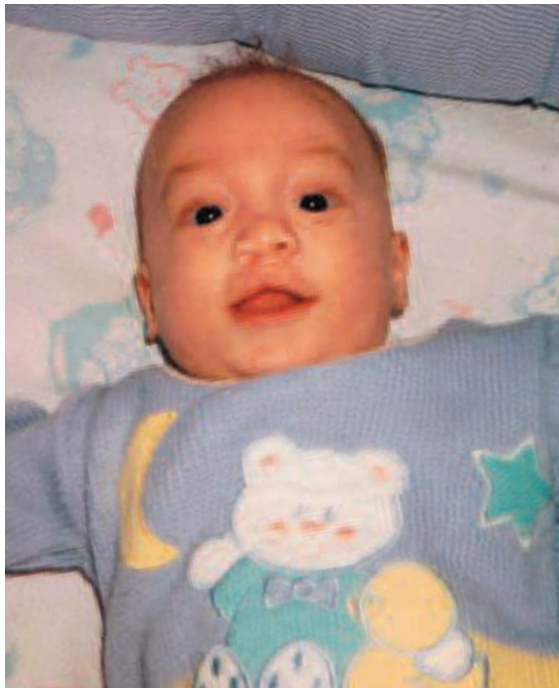If immediate surgical intervention is not necessary and the newborn is able to feed successfully and thus gain weight properly, surgical repair of a cleft lip or palate may be delayed until the child is between seven and 18 months of age.<sup>5</sup>

A palatoplasty may be performed separately or in conjunction with a cheiloplasty. Additional corrective procedures may include rhinoplasty, orthodontic treatment, speech therapy, ear tubes and dental extractions.

#### CASE STUDY: DIAGNOSIS AND INDICATIONS FOR SURGERY

The patient was a nine-month-old male who was diagnosed immediately after birth with right unilateral cleft lip and palate with nasal deformity. The patient's medical history included a prior cheilorrhaphy performed when the patient was three months old.

The patient as an infant.



Courtesy Pat Mancilla

#### PHYSICAL CONDITION

The patient underwent the following preoperative tests: complete blood count, urinalysis and hematocrit. All test results were normal. A series of facial X-rays was performed to determine the extent of the palate defect.

Vital signs were normal and stable, and the patient was in good health. The normal range for vital signs of a nine-month-old are:

Weight:	15 lbs
Heart rate:	120–130 bpm
Respirations:	20–40 breaths per minute
Blood pressure (Systolic):	80–100 mmHg
O <sub>2</sub> saturation:	100%
Temperature:	99.6°F

#### POSITIONING, SKIN PREPARATION AND DRAPING

Upon arrival in the O.R., the patient was placed in the supine position with the operating table turned so that it was at a 90-degree angle to the anesthesiologist.

General anesthesia was induced, followed by endotracheal intubation. The patient's eyes were lubricated and then covered with Tegaderm™ to protect the corneas.

Skin preparation was accomplished with 0.5% Betadine® applied from the hairline to the chin area with careful attention paid to ensuring the solution did not come in contact with the eyes and did not pool in the ears.

The patient's head was then draped turban-style for full facial exposure. A small, fenestrated sheet was used to expose the right hip (the donor site).

#### PROCEDURAL OVERVIEW

The lip border was tattooed with methylene blue using cotton swabs, lining the vermillion and cutaneous border of the lip. The lip was then injected with 0.5% bupivacaine with epinephrine.

A diamond-shaped excision was made after marking the vermillion cutaneous junction. The skin was then undermined with a #15 blade.

Two 5-0 silk sutures were used to gather the deep dermal layer and to take tension off the skin. The skin was then closed using 6-0 polydioxanone suture in buried and interrupted intracuticular fashion.

The mucosa of the lip was closed with the dry vermillion being closed with 6-0 chromic gut sutures in interrupted fashion.

Attention was then directed to the nose, where a marginal incision was made. Then, using tenotomy scissors, the skin was undermined in subcutaneous fashion immediately over the cartilage onto the dorsum and over the normal left lower lateral cartilage, as well as laterally over the right lower lateral cartilage.

The auricular cartilage graft could be seen. The jagged edges of the graft from the prior cheilorrhaphy were trimmed but left in place. A 4-0 polydioxanone suture on a free needle was then passed from the tip-defining point on the patient's left side just lateral to the genu of the right lower lateral cartilage. This was stitched into place, bringing the right lower lateral cartilage up to a nearly symmetrical position.

A Z-plasty was then performed on the internal surface of the nose to rid the patient of his nostril stenosis. Closure of these internasal incisions was made with 4-0 chromic gut suture in interrupted fashion.

Several mattressing sutures of 5-0 polydioxanone were used—beginning intranasally, coming out through the alar nasal groove, then back through the same suture hole and back into the nose, and then tied. A total of three of these sutures were placed to pexy the cephalic margin of the lower lateral cartilage into good position.

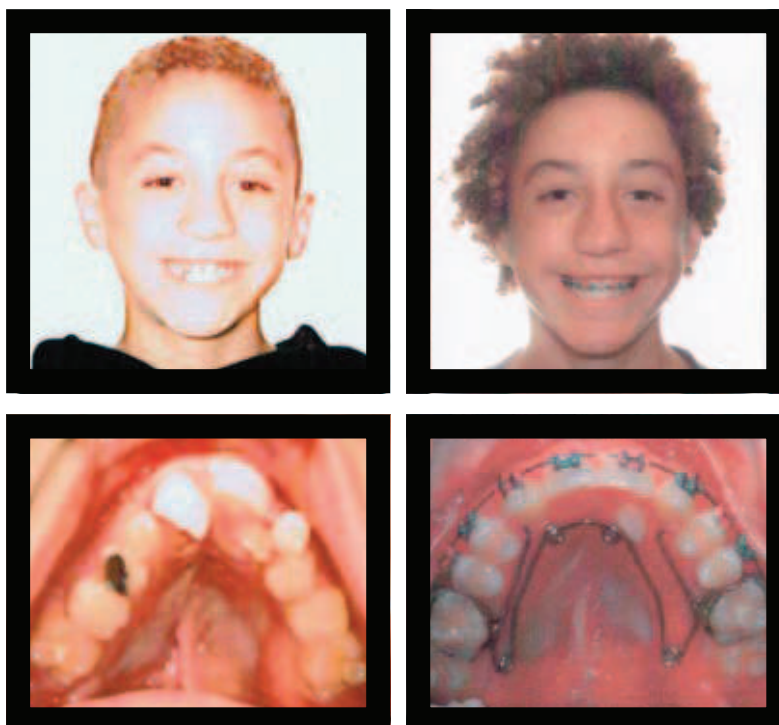
Attention was then directed to the nasal ala, where a considerable groove was seen in the patient's nasal floor. This was excised using a #15 blade, and the nasal sill was undermined down to the piriform aperture to free it completely. Closure was achieved with 5-0 polydioxanone sutures in interrupted and buried fashion.

The skin was then closed using 6-0 plain gut suture in interrupted fashion. A solution of 0.5% bupivacaine with 1:200,000 epinephrine was injected into the infraorbital nerves bilaterally. These nerves innervate the maxilla and anterior area of the cleft palate repair.

The nose was then dressed using Mastisol® and Steri-Strips™ in rhinoplasty-type fashion. The oropharyngeal pack was placed in the posterior oral pharynx, and approximately 3 cc of 1% lidocaine with 1:100,000 epinephrine was injected

in an infiltration and block fashion, in order to achieve adequate hemostasis and postoperative local anesthesia.

Next, using a #15 blade, a sulcular incision was made in the right maxillary anterior region. The periosteal elevators were used to elevate the periosteal flap proximal and distal to the cleft site.



Courtesy Pat Mancilla

A similar flap was elevated on the palatal aspect proximal and distal to the cleft.

Care was taken to dissect the nasal floor from the mucoperiosteal flaps. The supernumerary tooth was identified and atraumatically removed. Once the nasal floor had been developed, closure of the nasal floor was achieved using 4-0 Vicryl™ suture.

#### EXCISING THE BONE GRAFT

At this point, a pack was placed in the oral cavity, and attention was directed toward harvesting the bone graft from the right iliac crest.

The surgical team then rescrubbed and regowned, and a second sterile set-up was used. The anterior iliac crest was identified, and approximately 2 cc of 1% lidocaine with epinephrine was injected along the planned incision site.

The photos show how orthodontic treatment shaped the patient's mouth between the ages of 10 (at left) and almost 13 (at right).

Using a #15 surgical blade, an incision was made just lateral to the crest of the ridge. Hemostasis was achieved electrosurgically.

Sharp dissection to the iliac crest ridge was performed using a surgical blade and electrocautery. The crest of the ilium was then identified.

The lateral periosteum was released, and the bone graft was harvested from the lateral aspect of the right anterior iliac crest. Once the graft was harvested, the wound was irrigated with copious amounts of normal saline, and attention was directed toward hemostasis.

Avitene® sheets were placed in the wound to

aid in hemostasis. Once meticulous hemostasis had been achieved, the wound was closed using 3-0 and 4-0 Vicryl sutures for primary re-approximation, followed by 5-0 nylon suture for the skin.

Triple antibiotic ointment was placed over the wound, followed by Steri-Strips.

#### PLACING THE GRAFT

The graft was placed into the right anterior maxillary cleft. The soft tissue of the palate was sewn over the graft to secure it.

The previously elevated mucoperiosteal flaps were then closed primarily over the bone

## Global mission opportunities

There are several organizations that specialize in providing free surgical repair of cleft lips and cleft palates in children and young adults worldwide. In many cases, these patients have been ostracized from their families and communities or simply abandoned, due to lack of medical resources and misunderstandings about facial deformities.

Below are a few examples of mission programs. If you'd like to know more about supporting these groups with financial assistance, in-kind donations, equipment donations or volunteering your surgical expertise, please visit the websites listed below. There are opportunities to serve both here in the United States, as well as abroad.

Remember, the Foundation for Surgical Technology, the nonprofit 501(c)3 arm of the Association of Surgical Technologists, offers financial assistance to AST members who participate in medical mission trips. Scholarship applications are available at [www.ast.org](http://www.ast.org) (Click on *Professionals*, then *Scholarships*.) There is no deadline for these scholarships. Applications are accepted and financial assistance is awarded throughout the year.

### Healing the Children— [www.healingthechildren.org](http://www.healingthechildren.org)

Healing the Children has offered both stateside programs and international mission trips since its inception in 1979. The program provides

free surgical care and/or specialized equipment to children here in the United States, as well as children from foreign countries who are brought to the US for specialized care that cannot be provided in the patient's homeland.

Teams of medical professionals also travel throughout the world to conduct surgical procedures in various specialties, including plastic and reconstructive surgery, ophthalmology, otolaryngology, urology, orthopedics and dentistry.

### Interplast—[www.interplast.org](http://www.interplast.org)

With the help of 17 volunteer teams, Interplast performs about 1,800 surgeries every year in 16 countries throughout Africa, Asia and Latin America. Volunteers provide reconstructive surgery to children with cleft lips and palates, hand injuries and disabling burns.

Interplast's mission trips typically last two weeks, and the teams perform approximately 75 to 100 surgeries during each trip. Lectures and hands-on training for local physicians, residents and nurses may also be conducted during mission trips.

### Operation Smile—[www.operationssmile.org](http://www.operationssmile.org)

Since the program's first mission trip to the Philippines in 1982, Operation Smile has provided surgical repair of cleft lips and cleft palates to more than 100,000 children and young adults in Central and South America, Africa, the Middle East, Eastern Europe and Asia.

Its volunteer network encompasses more than 5,000 medical and non-medical professionals worldwide. The organization also offers its World Care Program, which brings children and young adults to the United States for surgeries that are too complex to be performed in their home countries.

### Operation Rainbow— [www.operationrainbow.org](http://www.operationrainbow.org)

Operation Rainbow was founded in 1978 in Houston, Texas. Since then, the program has provided free plastic and orthopedic surgical care to more than 7,000 children in the US and worldwide.

In addition, the program also seeks to provide continuing education to medical professionals in underserved countries as a way of encouraging and supporting medical self-sufficiency.

### The Smile Train—[www.smiletrain.org](http://www.smiletrain.org)

This organization focuses solely on providing surgical repair of cleft lip and cleft palate. Teams of medical professionals perform approximately 60,000 surgeries every year in 71 countries throughout Africa, the Middle East, Central and South America, Eastern Europe, Russia and Asia.

In addition to performing surgery, the teams also provide training to local physicians and therapists about new surgical procedures and follow-up care.

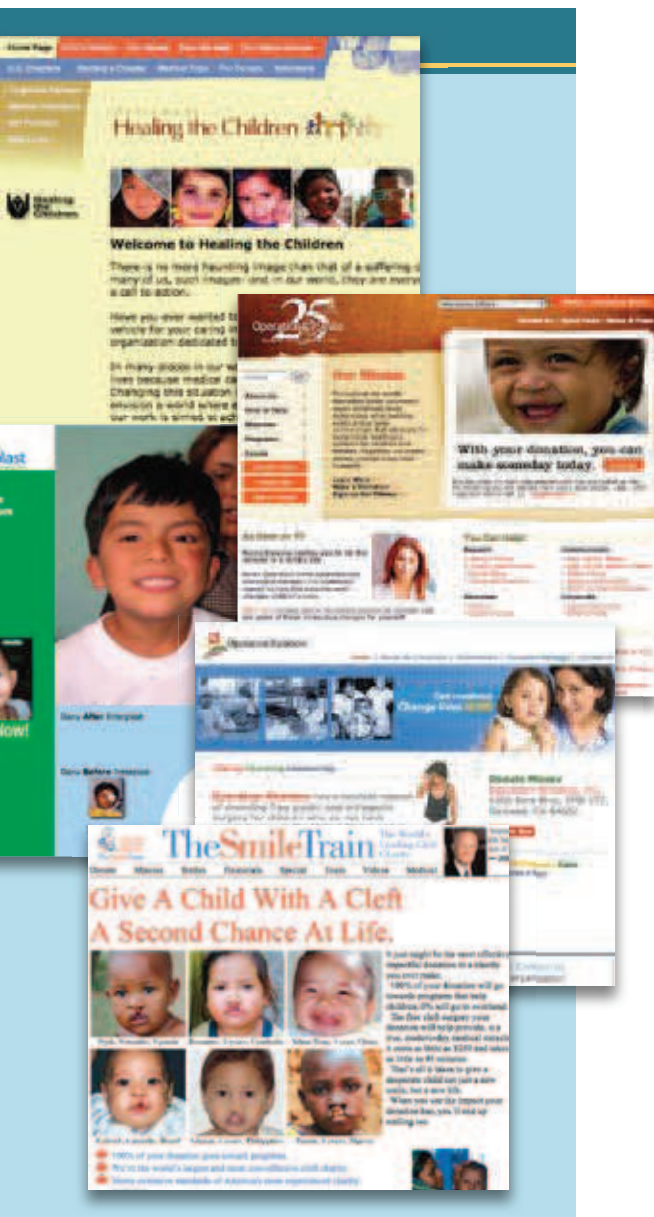
graft using 3-0 Vicryl sutures in an interrupted fashion.

Once the intra-oral wound was closed, the oral cavity was irrigated with copious amounts of normal saline, and the previously placed oropharyngeal pack was removed.

#### POSTOPERATIVE RECOVERY

At the time of discharge, the patient was given antibiotics and pain medication. The patient experienced no postoperative complications.

*Continued on page 458*



## Palatoplasty—A mother's perspective

**Pat Mancilla**

Jarrod Mancilla—the patient in this article—was born on October 6, 1992. This was also the day that we—his parents—found out that Jarrod was born with a cleft lip and palate.

During the pregnancy, there were no unusual signs or symptoms. The pregnancy was considered normal, as were all of the ultrasounds. With technology today, though, we are now able to detect many facial defects, including cleft lip and palate.

At the time of Jarrod's birth, in addition to joy, a fear of the unknown was our greatest emotion.

The doctors gave us a brief explanation of cleft lip and palate and told us what our son's immediate needs would be.

#### Diagnosis and prognosis

Following an examination by the pediatrician in the hospital and the craniofacial team from Children's Hospital of Orange County in Orange, California, we were told that his official diagnosis was right unilateral cleft lip and palate with nasal deformity.

We were told that the lip and palate would need to be repaired surgically, with the possibility of some additional minor procedures.

In reality, Jarrod has had to endure approximately eight different types of surgeries, including nasal fistula repair with revisions, rhinoplasty, lip revisions, bone grafts to the palate and nasal area, and dental extractions.

In addition to the surgeries, Jarrod has undergone six years of orthodontics so far, and he has about another year to go.

He is scheduled for a Le Fort I maxillary osteotomy and a bilateral sagittal split osteotomy (BSSO) at the completion of his orthodontic work, and he will still need a septoplasty, rhinoplasty and lip scar revision. The micrognathia repair will bring his jaw to the forward position.


#### The first days at home

We felt adequately prepared to bring Jarrod home due to the extensive education and counseling we received at the hospital. However, when we finally brought him home five days after he was born, the most challenging things we faced were feedings.

Due to the defect in the palate, nursing was not an option. For the next nine months, we tried several feeding techniques, including different nipple lengths and different hole placements on the nipples.

We finally ended up using a red rubber Robinson catheter to insert drops of breast milk into his mouth. All other forms of feeding would result in the milk coming out his nasal cavity, due to the fistula.

*Continued*



*Jarrod, now 15, is a sophomore in high school, interested in a career in music or business.*

### Surgeries during the first year

At three months of age, Jarrod underwent his first surgery—a cheilorrhaphy—to repair the lip and nasal defect.

Six months later Jarrod underwent a palatoplasty, which was described in this article.

In the years following this procedure, Jarrod would have to endure many more surgeries to revise, reshape or correct something new.

Throughout all this, he was always very happy, silly and confident in himself. He never fussed much after surgery and was always a good baby.

### Additional surgeries

One of the surgeries performed on Jarrod was a cartilage graft from the right ear to the right nasal dorsum, because of considerable droop and flattening of the lower lateral cartilage.

The right tip-defining point of the lower lateral cartilage was also retrodisplaced compared to the normal left side, and there was stenosis of the nostril.

Then when Jarrod was nine, the surgeons needed to close the oronasal fistula by implanting an autogenous iliac crest bone graft in the maxilla.

We've also been told that Jarrod has an uneven alar base. The lateral ala on the left side of his nose is intruding on the nasal passage.

In 2000, a team of surgeons—including an oral surgeon—found that his

occlusal exam showed a tendency toward an anterior cross bite, and there is a unilateral posterior cross bite. Tooth #8 is the one in the cross bite. Bone grafting to the cleft alveolar ridge will eventually take place. He already has had teeth extracted and moved, and the bone grafts are in place. The top braces are in place, and an expander was inserted to widen his narrowed arch.

It is now 2007, and Jarrod's teeth look beautiful. All he needs to do now is have the orthognathic surgery, and possibly a rhinoplasty, septoplasty, and lip revision. This will hopefully conclude his journey, unless he chooses to undergo further procedures in adulthood.

As you can see, a child born with a cleft lip and palate endures a lot—physically and emotionally—throughout his or her lifetime.

We have taught Jarrod and our other children that when they see someone who has some type of noticeable birth defect, they should not be afraid or make fun of them. They should be courteous and should approach them if they have questions.

I know that I would have appreciated someone asking me what happened to my son, rather than making fun of him in my presence.

Throughout it all, I've learned that it's important to be happy and content in life and to live life to the fullest.



Jarrod is a talented drummer and guitar player.

### ABOUT THE AUTHOR

Pat Mancilla is currently a student in the surgical technology program at Concorde Career College in San Bernardino, California. She will graduate in January 2008, and will take the national CST certification exam in February 2008.

Surgical technology is a career change for Pat. She wanted a career that allowed her to work with babies who are born with cleft lips and palates. After doing a lot of research, she chose this profession, because she felt it would give her the greatest satisfaction—as well as the ability to travel.

*Editor's note: The information contained in this article was compiled from the patient's medical records and a personal interview with the surgeon who performed this surgery.*

### References

1. Goldman DR. *Complete Home Medical Guide*. DK Publishing: New York, NY; 2003:862.
2. Jarrod Mancilla medical records. Obtained with permission from Loma Linda University Medical Center and Childrens Hospital, Loma Linda, California.
3. Peterson, Ellis, Hupp, and Tucker, eds. *Oral and Maxillofacial Surgery, 3rd ed*. Mosby: St Louis, MO; 1998.
4. Pravin, Patel K. Craniofacial, Unilateral Cleft Lip Repair. e-Medicine. Available at: <http://www.emedicine.com/plastic/topic170.html>. Accessed September 13, 2007.
5. Price P, Frey K, Junge T, eds. *Surgical Technology for the Surgical Technologist, 2nd ed*. Thomas Delmar Learning: Clifton Park, NY; 2004:696-697.
6. Personal interview with Leonard Prutsok, MD, FACS, Orange, California.
7. Rothrock JC. *Alexander's Care of the Patient in Surgery, 12th ed*. Mosby: St Louis, Mo; 2003.
8. Rynearson DR. Your Health, Cleft Lip and Cleft Palate.

Avitene is a registered trademark of CR Bard, Inc.

Betadine is a registered trademark of Purdue Pharma, Inc.

Mastisol is a registered trademark of Ferndale Laboratories, Inc.

Tegaderm and Steri-Strip are trademarks of 3M, Inc.

Vicryl is a trademark of Ethicon.