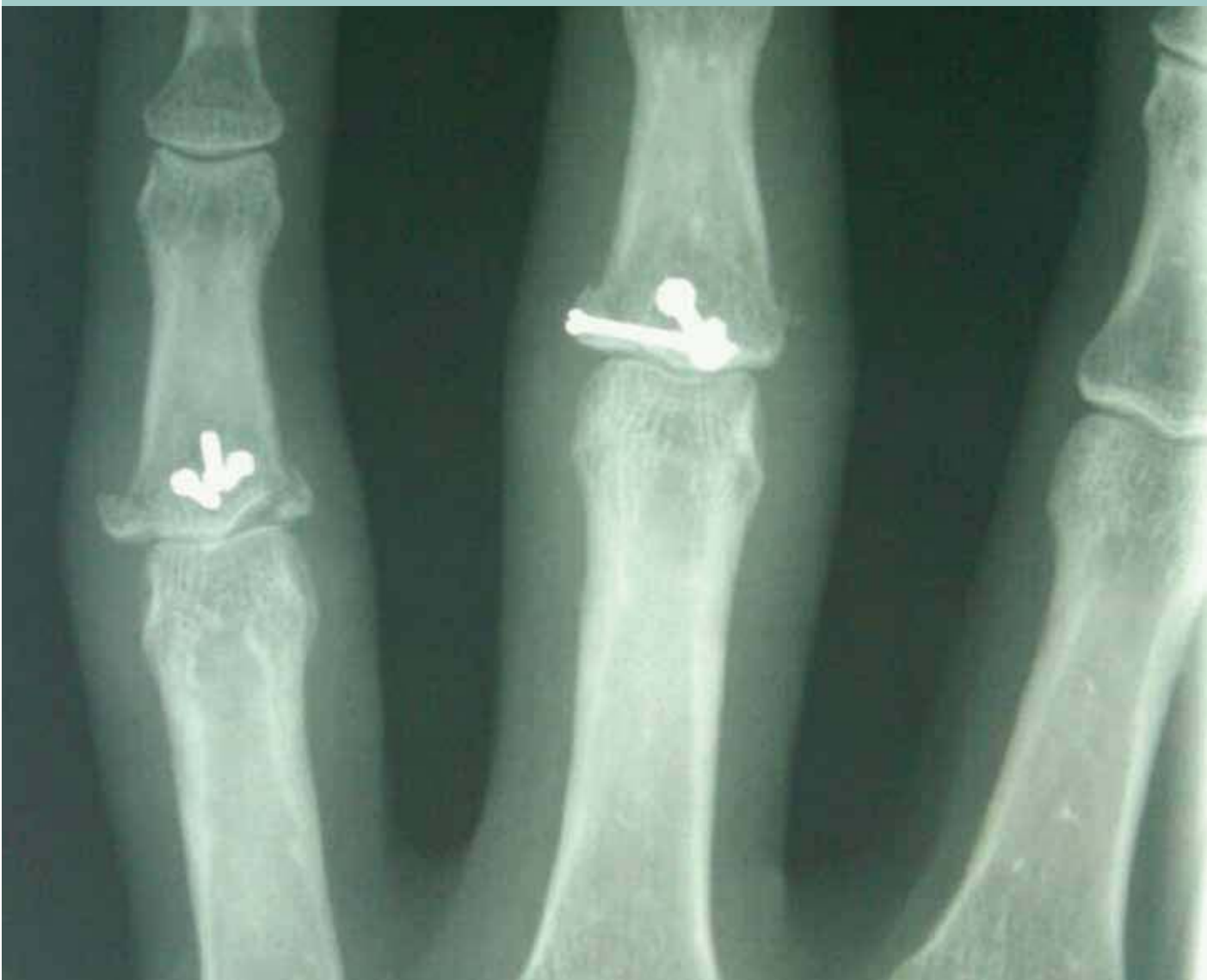



ORIF: PIP Fracture and Dislocation of the Fingers

Jeanne Rieger, CST

The Proximal Interphalangeal (PIP) joint is one of the most sensitive joints in the body. Due to its small size, as well as its proximity to structures such as the articular cartilage, volar plate and collateral ligaments, surgical reconstruction of the joint can be a very delicate procedure. Open reduction internal fixation is the preferred method of repair for this injury if it is serious enough to require surgery.

On a beautiful summer day in Indiana, a 50-year old grandmother of three was hanging out at the lake with some friends. They were taking turns on a rope swing—flying out over the water and dropping into the lake. The future patient took her turn, but when she let go to drop into the lake, her fingers became entangled in the rope. She came out of the water with the ring and middle fingers of her left hand dislocated and broken at the proximal interphalangeal (PIP) joint between the proximal phalanx and middle phalanx.

An initial X-ray at a nearby hospital revealed that the fingers were so badly broken that she would have to see an orthopedic surgeon to have them pinned and possibly plated. Normally, this type of procedure is performed by a plastic surgeon, who has completed a rotation in hand surgery. The patient chose to have her hand repaired at the Hand and Shoulder Center in Indianapolis.

After looking at the X-rays, the surgeon scheduled surgery for an open reduction internal fixation (ORIF) with screws and a possible plate. Because the fracture was through both the shaft of the bone and the articular surface of the joint, the surgeon noted

LEARNING OBJECTIVES

- Review the relevant anatomy for this procedure.
- Determine the factors that indicate if an injury should be treated surgically or nonsurgically.
- Evaluate the step-by-step process of reconstructing the PIP joint
- Examine the development of hand surgery as a specialized field
- Assess the possible risks and complications associated with this procedure

that it was one of the worst ways to have injured the fingers. According to the surgeon's nurse practitioner, who has been in the field for more than 14 years, this type of injury is especially traumatic due to the soft tissue injury combined with the small, bony joint fracture. This type of injury has increased potential for arthritis due to the interruption of the articular cartilage.

HISTORY

According to the *Journal of Hand Surgery*, Sterling Bunnell, MD, is considered the founding father of the specialty of hand surgery in the United States. Like many surgical specialties throughout history, advancements in hand surgery arose from necessity during wartime. Dr Bunnell's influence on Army medicine developed during and after WWII, when he served as a civilian consultant to the Surgeon General of the US Army, Norman T Kirk.

In 1944, Kirk was inspecting a plastic surgery center at Valley Forge General Hospital and noticed an abundance of "crippled hand" cases. He wrote a personal letter to Dr Bunnell requesting his assistance. On November 29, 1944, Bunnell was assigned "to guide, integrate and develop the special field of hand surgery" in the Army.² At the same time, he published *Surgery of the Hand*, which the Army adopted as an official text, distributing the book to all of its hospitals.²

Over the course of his visits to Army hospitals, Bunnell noted numerous cases in which improper traction, splinting and skin grafting resulted in less complete restorations of function than he believed possible. It was this realization that inspired him to improve the quality of treatment by

bringing together specialists from the fields of orthopedic, plastic and neurosurgery to work on injured hands and qualify them in all three specialties. Bunnell recognized that the three fields of specialization were very closely woven, but that having three specialists working in such a small operative area was inefficient, if not impossible.

In pursuit of his vision, Dr Bunnell visited nearly all of the general hospitals in the United States. During his tour, he conducted 23 courses of three to four days each, including presenting operative demonstrations as part of the course. At the same time, Dr Bunnell urged the formation of a hand-surgery unit in each hospital.

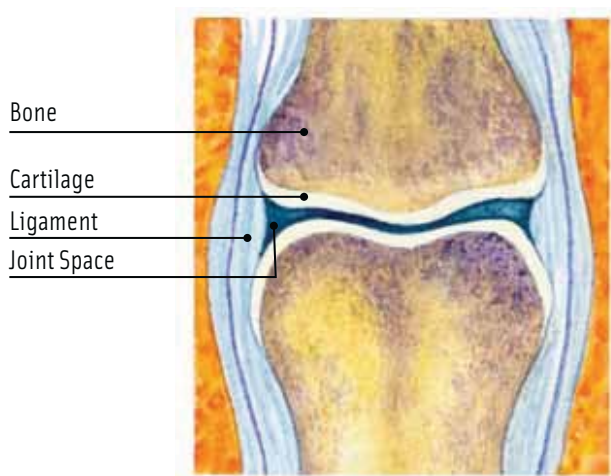
After completing his tour with the Army, Dr Bunnell was appointed as a teaching consultant in hand surgery at Letterman Army Hospital in San Francisco. In the words of Surgeon General Kirk, "[Bunnell's] tours of duty were made at heavy personal sacrifice and without regard to his own interests. The result was the achievement of functional results in surgery of the hand hitherto believed beyond attainment."²

Many of the practices taught by Dr Bunnell were carried back into civilian practice after the end of the war and have continued to evolve and develop to this day.

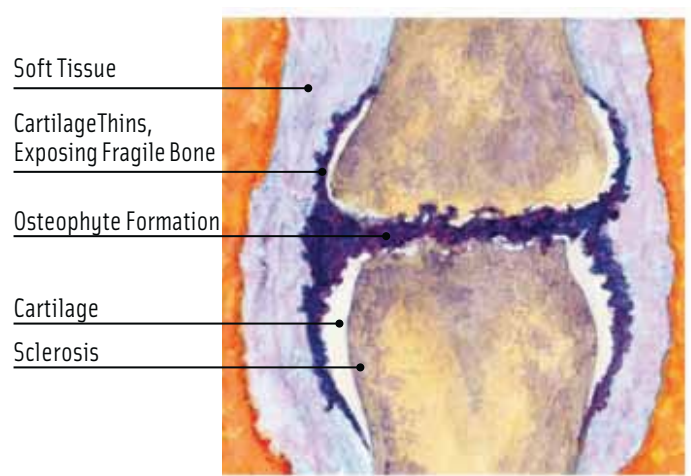
ANATOMY

The PIP joint is one of the most unforgiving joints in the body to injure. A simple sprain of the PIP joint can result in a painful and stiff finger that makes it difficult to perform simple actions such as gripping objects.¹

The joints in the fingers are hinge-like, bending and straightening with a limited range of motion. The main



NORMAL PIP JOINT



TRAUMATIC ARTHRITIS

INSTRUMENTS

Synthes Modular Hand Set, including:

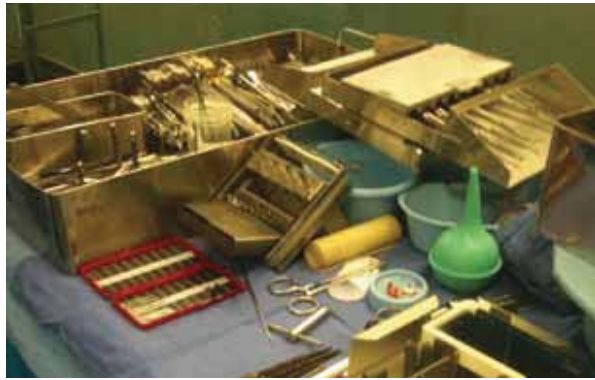- Drill bits
- Countersinks
- Screwdriver blades
- Bending/cutting pliers
- Universal pliers
- Periosteal elevators, straight and curved
- Sharp hooks
- Plate- and screw-holding forceps
- Hohmann retractors
- Coupling handles
- Cruciform screwdriver
- Depth gauges
- Reduction forceps
- Termite forceps
- Universal drill guide
- Screws and plates of various sizes
- Tenotomy scissors
- Gelpi retractors
- Bone rongeurs
- Mosquito clamps
- Skin hooks
- Knife handles
- Senn retractors
- Cricket retractors
- K-wires of various sizes
- Stryker 4200 drill

EQUIPMENT

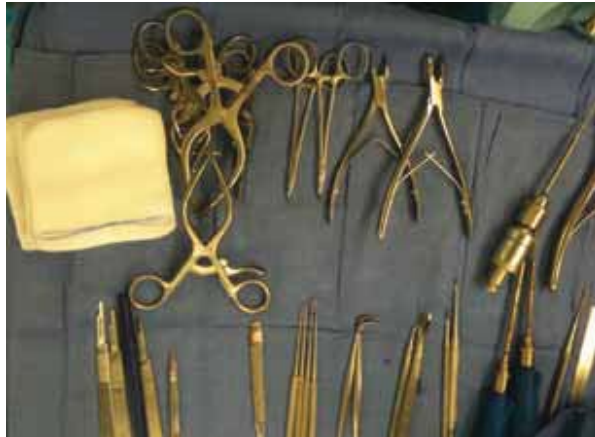- Tourniquet
- ESU
- Hand table
- Power source for instruments

SUPPLIES

- Extremity pack
- Hand towels
- Laps
- Cleaning wipes
- 4" Esmarch bandage
- #15 blade
- Prep set
- Mini C-arm drape
- Gowns and gloves
- Basin Set
- Suture



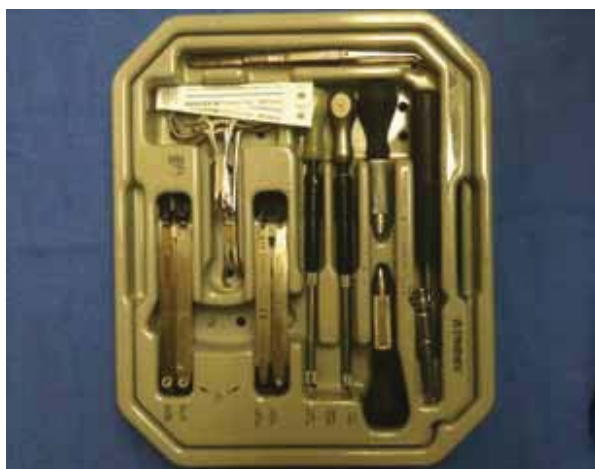Back table with K-wires.



Mayo stand for ORIF.




Plate and screw set.



Synthes Modular hand set.

knuckle, the metacarpophalangeal joint (MCP) is formed by the connection of the metacarpal bone in the palm of the hand with the phalanx. The second, third, fourth and fifth fingers are composed of three phalanges, which are separated by two interphalangeal (IP) joints. The one closest to the MCP joint is the PIP joint.

Several ligaments hold the joints together. In the PIP joint, the volar (toward the palm) plate is the primary ligament. A ligament where it originates, the volar plate is cartilaginous where it inserts. It connects the proximal phalanx to the middle phalanx on the palm side of the joint. The ligament tightens as the joint is straightened and prevents it from being hyperextended. The PIP joint is also sandwiched between two collateral ligaments, which tighten when the joint is stressed laterally, helping maintain stability.

One of the most common injuries to the PIP joint is a sprain, typically indicating that a ligament has been stretched and possibly partially torn. If a ligament is stretched too far, it can rupture. Injury to the volar plate can occur with the joint is hyperextended. If torn com-

pletely, the ligament usually ruptures or is torn away from its attachment on the middle phalanx. In some circumstances, this may result in a small bone avulsion from the middle phalanx. When the avulsion is small, it may not be a big concern, however, if it involves a significant amount of the joint surface, it may require surgery to repair the fragment and restore the joint surface.¹

The collateral ligaments can be damaged if the joint is stressed laterally, causing the ligament to rupture. These ligaments can also be injured if the PIP joint is dislocated, with the middle phalanx dislocating behind the proximal phalanx.¹

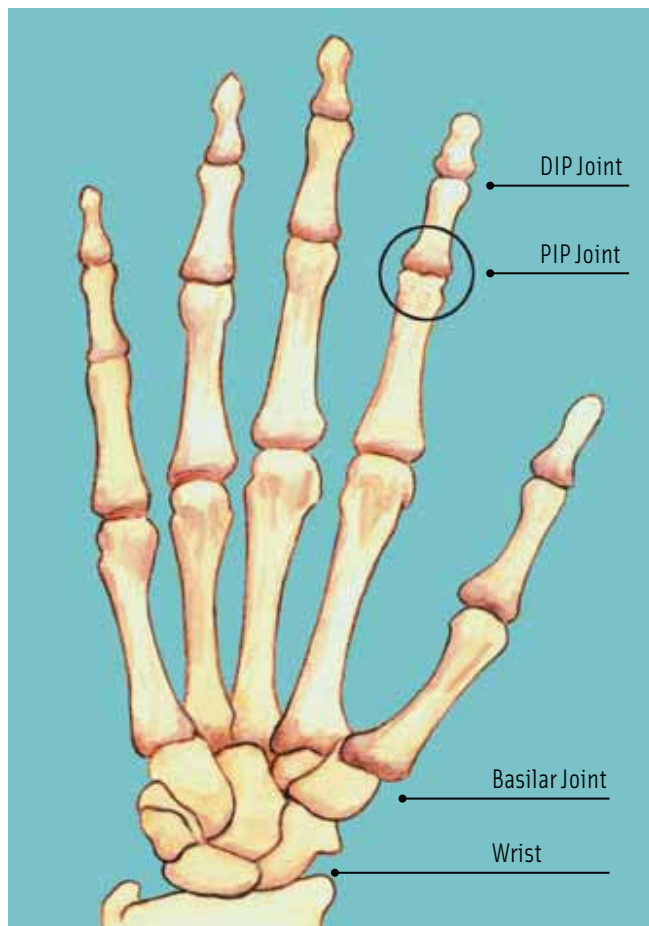
DIAGNOSIS AND TREATMENT

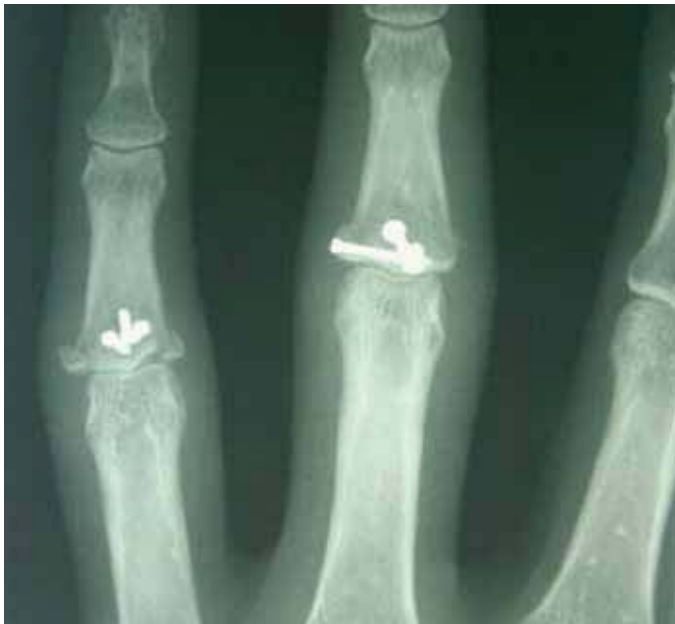In most cases, damage to the joint will be immediately evident. Pain and swelling at the suspected injury site is common, and the finger will appear physically deformed if the joint has been completely dislocated. X-rays are required to determine if there is an avulsion fracture associated with the injury, as well as to determine if the alignment of the joint after an injury or after the reduction of a dislocation. If an avulsion is present, it may alter the surgeon's recommendation for treatment.

Nonsurgical treatment is suggested for the majority of injuries to the PIP joint. It is critical to begin rehabilitation exercises shortly after injury because the PIP joint is very sensitive and can become stiff very rapidly when it is immobilized, even for short periods of time. The sooner the joint begins to move, the less likely there will be any problems with flexibility in the future.¹ A short period of splinting is advised, followed by taping the injured finger to an adjacent finger. This allows the uninjured finger to brace the injured one, while simultaneously bending and moving with the uninjured finger as the hand is used normally.

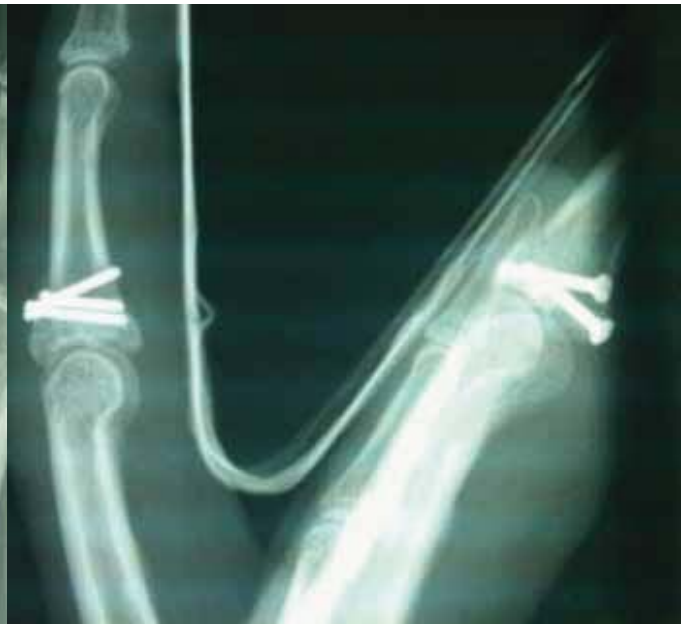Even if the joint has been totally dislocated or the volar plate has been ruptured, nonsurgical treatment is often still advised. Like a simple sprain, the goal is to keep the joint stable while beginning to move it as soon as possible. Since this injury is a result of hyperextension of the joint, a dorsal blocking splint is used to prevent full extension, while still allowing some movement. The brace is normally used for three to four weeks, allowing the ligament to heal enough to stabilize the joint.

In more severe cases, the volar plate may be caught in the joint, preventing the surgeon from reducing the joint without surgery.¹ Surgery may also be necessary to repair





Superior X-ray of two ORIF-repaired PIP joints.



Lateral X-ray of two ORIF-repaired PIP joints.

extensive damage to the collateral ligaments and volar plate, which is the case in this study.

OPEN REDUCTION INTERNAL FIXATION

Open reduction internal fixation (ORIF) is usually completed in two stages. First, the broken bone is reduced, specifically, a reduction by manipulation of the bone after surgical exposure at the site of the fracture. Second, an internal fixation device is placed on or in the bone. Internal fixation devices for this type of procedure can include screws, plates, rods and pins to hold the segments of the broken bones together.

PROCEDURE

The patient is moved into the operating room, where an axillary block and one gram of intravenous cefazolin is administered. Cefazolin is a preventative antibiotic that is regularly used when pinning or plating bone. The operative arm is prepped and draped with split drapes. The operative arm is exsanguinated with an esmarch bandage and a proximal well-padded tourniquet is inflated to 250 mmHg.

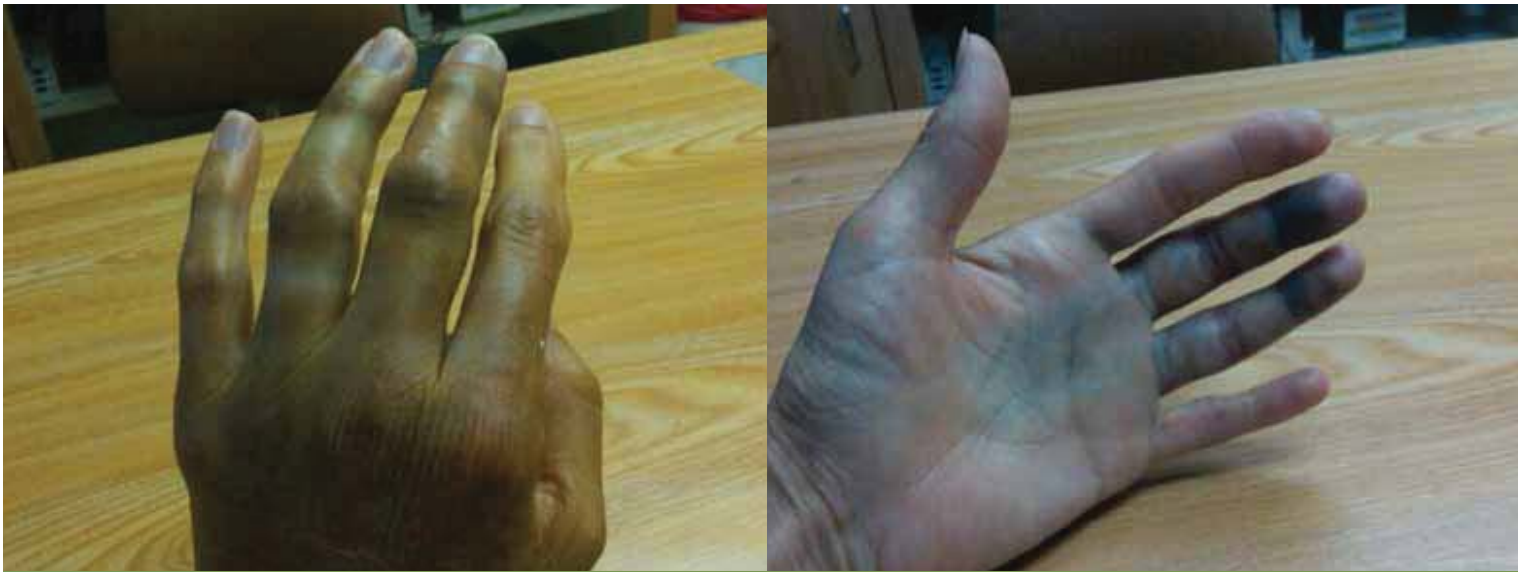A volar approach is made to the middle finger and a Bruner incision is made with sharp dissection down through the skin and subcutaneous tissue. The neurovascular bundle is identified and sharp dissection is used to elevate a full-thickness flap. Once the surgeon reaches the

tendon sheath, it is resected and the flexor digitorum superficialis (FDS) is split. The volar plate is released distally and the collateral ligaments are recessed. The joint is then able to be “shot-gunned,” exposing the articular surface. The term “shot gun” refers to the way the finger is manipulated for surgery. It has the appearance of a shot gun that is cracked at the breech to be loaded.

In this case, a hematoma is irrigated and removed with a curette. Visualization of the joint surface at the base of the middle phalanx reveals that it is broken in three pieces. The surgeon reduces the joint anatomically and provisionally holds the pieces in place with K-wires. Multiple 1.0mm and 1.3mm self-tapping titanium cortex screws are then used to perform a definitive fixation.

It should be noted that the fixation must be stable, and passive range of motion must be congruent. The surgeon must check to determine if the joint has any tendency to subluxate. There should be no crepitation or grinding. Intraoperative fluoroscopy will confirm the anatomic reduction and the position of the implants. The skin is then irrigated. The volar plate is reattached with 4-0 braided nylon suture on a P10 needle. The tendon sheath is repaired with 6-0 nylon on a P10 needle, and the skin is closed with 4-0 polypropylene suture on a P12 needle.

In this case, the ring finger, which was also injured in the fall from the rope swing, is able to be satisfactorily



Significant swelling due to two broken PIP joints.

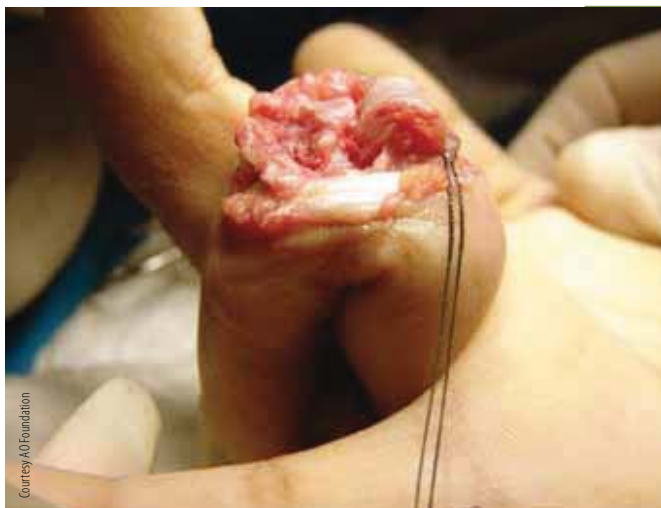aligned with closed reduction, which allows a dorsal incision to be made. The triangular ligament is split, the fracture is identified and any hematoma is removed. Provisional fixation with K-wires is performed and three 1.0 mm screws are used to perform the definitive fixation. Again, intraoperative fluoroscopy confirms that the fixation is stable and the joint motion is smooth. The triangular ligament is reapproximated with 4-0 braided nylon suture on a P10 needle, and the skin is closed with 4-0 polypropylene suture on a P12 needle.

The tourniquet is deflated and a sterile dressing is applied. The sterile dressing in this case includes a volar splint with a bulky bandage to apply pressure.

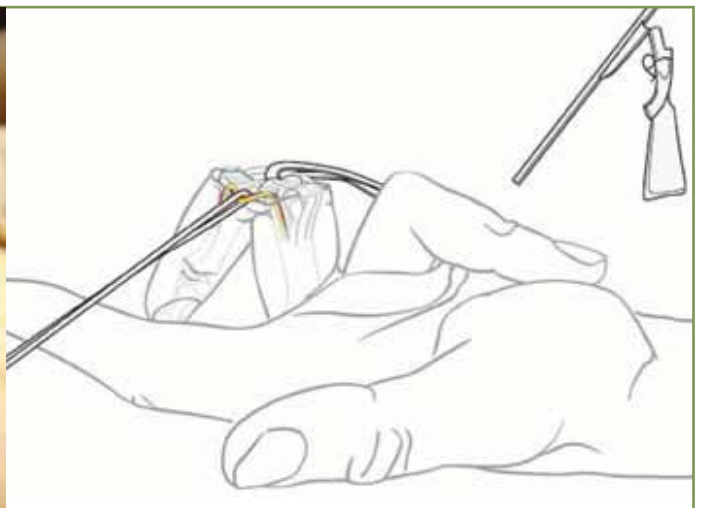POSTOPERATIVE

The patient begins a supervised occupational and physical therapy program starting six days postoperatively. The therapy sessions are consistent for two to three months. A full recovery can take up to four months. Initial visits to the therapist focus on controlling pain and swelling at the operative site. This is followed by gentle range-of-motion exercises. Initial work in achieving movement of the joint is critical because of its predisposition to becoming stiff when immobilized for prolonged amounts of time.

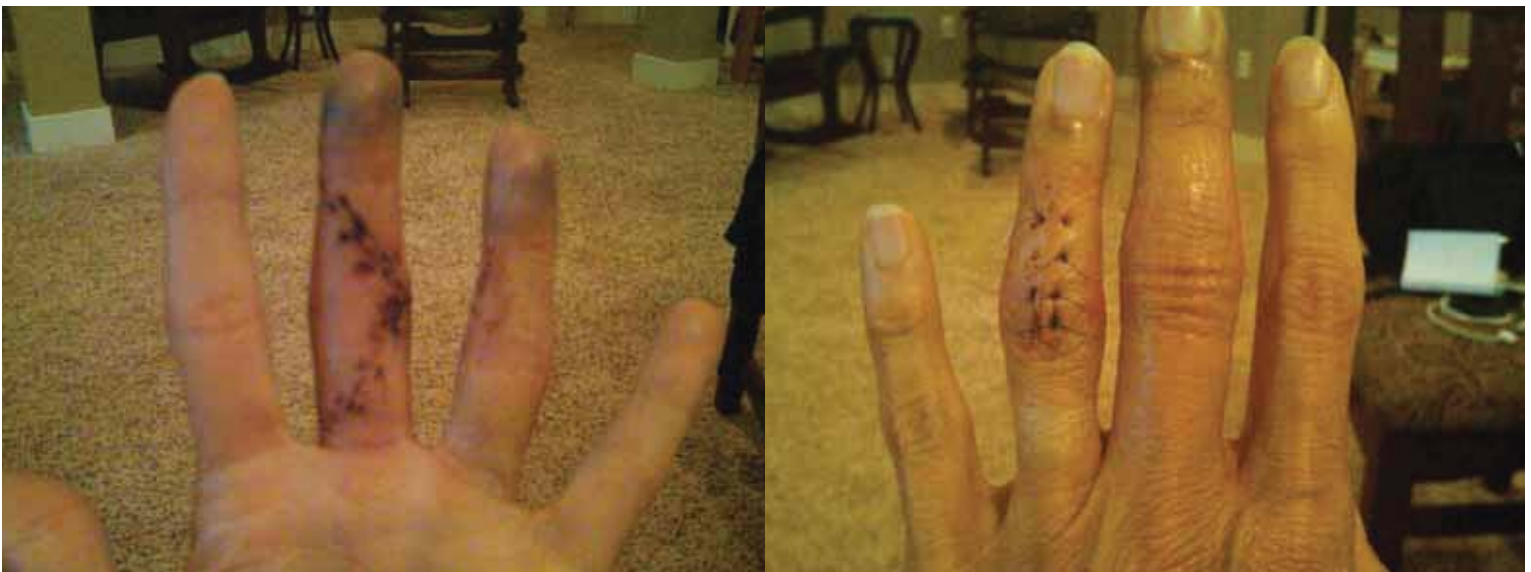Over time, strengthening exercises will be prescribed on a graduating scale as the joint heals. The exercises are



Courtesy/ AO Foundation



Shotgunning the finger allows the surgeon complete access to the joint.



A Brunner Incision is used to access the joint.

prescribed in an order that will protect the operative area from being stressed too much too soon.

The treatment of PIP fractures has very few contraindications. However, complications may arise if internal fixation is placed in either infected wounds or clean wounds that cannot be closed. If internal fixation is the chosen course of treatment in a wound that cannot be closed, any soft tissue defects should be immediately reconstituted by means of soft tissue mobilization or transposition at the time of the procedure.¹



ABOUT THE AUTHOR

Jeanne L Rieger, CST, lives in Indianapolis, Indiana. She graduated from Parkland College Surgical Technology Program in 1979, in Champaign, Illinois. She is currently the program

director of the Surgical Technology Program at Ivy Tech Community College, Indianapolis, and scrubs PRN for Meridian Plastic Surgery Center.

References

1. eOrthopod. 2009. "PIP Joint Injuries of the Finger." Accessed 11/21/2010. Available at: <http://www.eorthopod.com/content/pip-joint-injuries-finger>.
2. Kirk N. "Sterling Bunnell." *J Bone Joint Surg Am*. 1958. Vol 40, No 2:488-490.