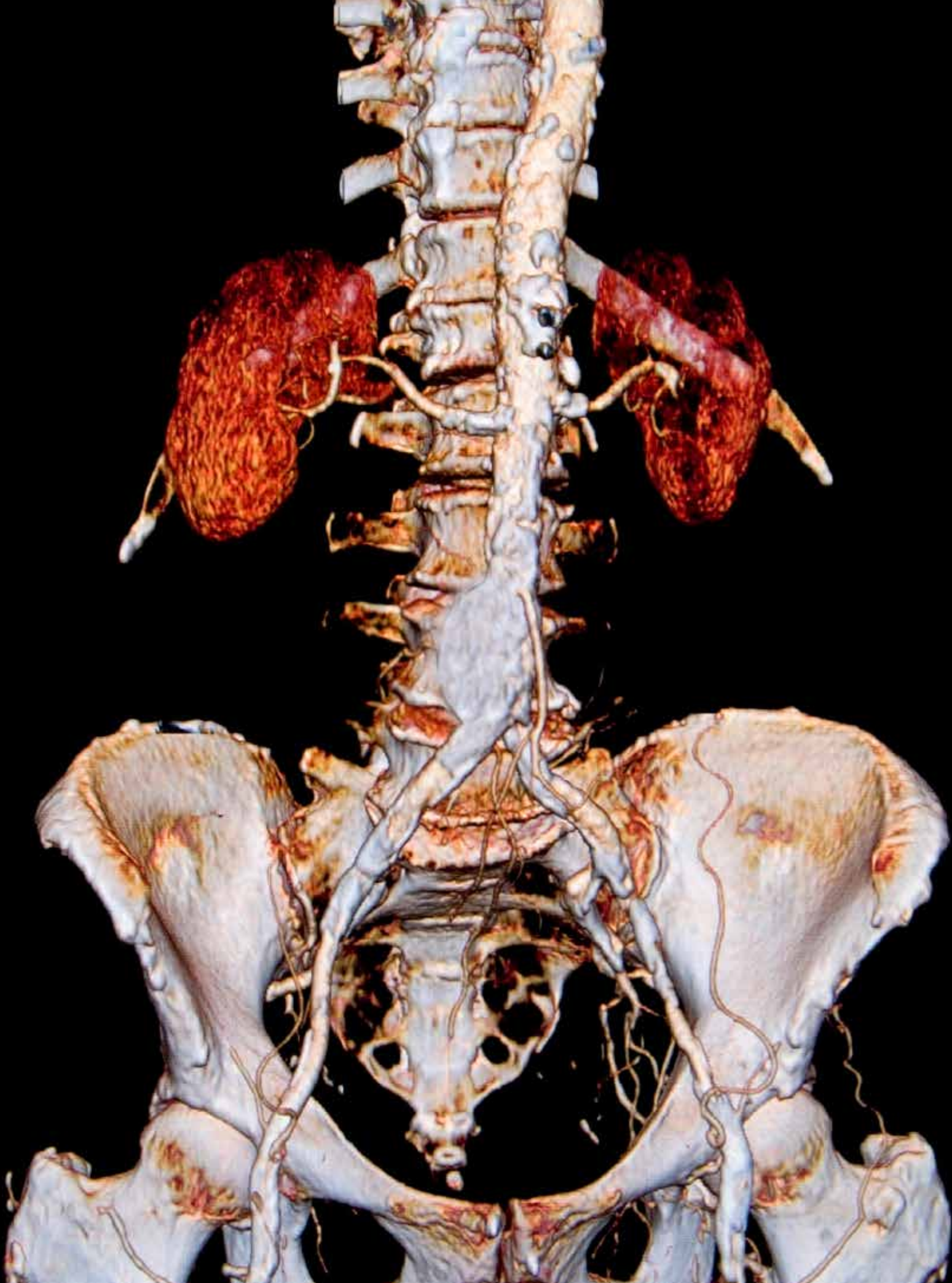

# Abdominal Aortic Aneurysm Repair

MICHAEL BAGTAS, CST

In an abdominal aortic aneurysm (AAA), the aortic wall is weakened and widening has occurred. The aneurysm can rupture with severe bleeding into the retroperitoneal areas, and may produce obstruction of aortic branches if not repaired in time through surgical intervention.

## PATHOPHYSIOLOGY

**A**n aneurysm is a restricted dilation or out pouching of a vessel wall or cardiac chamber. The dilation produces infarct development, a weak and thin layer of necrotic muscle, and fibrous tissue that bulges with each systole. Aneurysms shape in arteries where there is a disruption of the wall of the vessel associated with changes in collagen and elastin that make the vessel more susceptible to intravascular pressures. The aorta is particularly vulnerable to aneurysm formation because of constant stress on the vessel wall and the absence of penetrating vasa vasorum in the media layer. Three-fourths of all aneurysms occur in the abdominal aorta.<sup>6</sup>

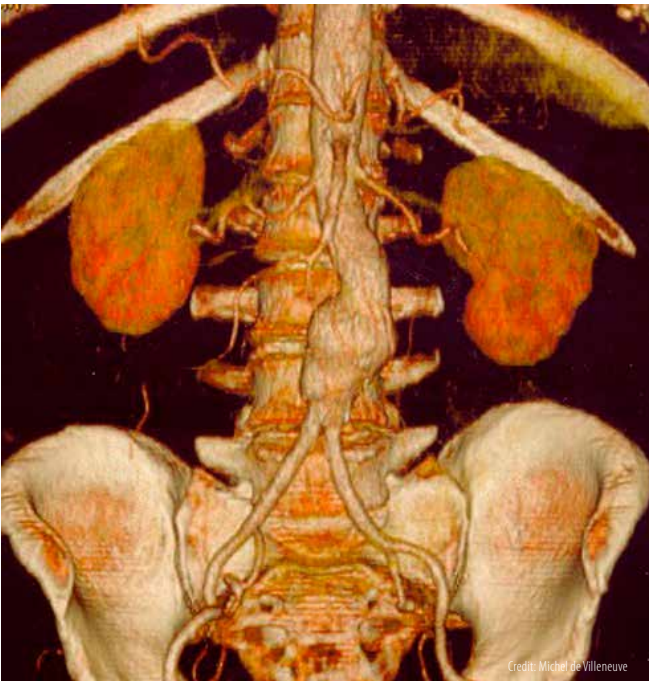
Atherosclerosis is the most common cause of arterial aneurysms because plaque formation erodes the vessel wall and contributes to inflammation and release of proteinases that can further weaken the vessel. Hypertension also contributes to aneurysm formation by increasing wall stress. Collagen-vascular disorders, syphilis and other infections that affect arterial walls also can cause aneurysms. Aortic

## LEARNING OBJECTIVES

- ▲ Examine the pathophysiology involved for an abdominal aortic aneurysm repair
- ▲ Review the steps the surgical technologist performs for this procedure
- ▲ List the complications that are related to AAA
- ▲ Identify the instruments and equipment needed for this operation
- ▲ Assess the procedure used in the surgical repair of an abdominal aortic aneurysm

aneurysms can be complicated by the acute aortic syndromes, which include aortic dissection, hemorrhage into the vessel wall or vessel rupture. Dissection of the layers of the arterial wall occurs when there is a tear in the intima and blood enters the wall of the artery.<sup>6</sup>

Dissections can involve any part of the aorta and can disrupt flow through arterial branches, thus creating a surgical emergency. Aortic aneurysms often are asymptomatic until they rupture, when they become painful. The pressure of a thoracic aneurysm on surrounding organs causes symptoms of dysphagia and dyspnea. An aneurysm that impairs flow to an extremity causes symptoms of ischemia.<sup>4</sup>



Arterial thrombi tend to develop when intravascular conditions promote activation of coagulation, or when there is stasis of blood flow. These conditions include those in which there is intimal irritation or roughening, inflammation, traumatic injury, infection, low blood pressures, or obstructions that cause blood stasis and pooling within the vessels. Inflammation of the endothelium leads to activation of the clotting cascade causing platelets to stick readily. An anatomic change in an artery can contribute to thrombus formation, particularly if the change results in a pooling of arterial blood.<sup>4</sup>

Arterial thrombi pose two potential threats to the circulation. First, the thrombus may grow large enough to occlude the artery causing ischemia in tissue supplied by

the artery. Second, the thrombus may dislodge, becoming a thromboembolus that travels through the vascular system until it occludes flow into a distal systemic vascular bed.<sup>6</sup>

## SURGICAL PROCEDURE

Skin prep begins at the midline, extending from the axilla to mid-thighs and to the table bilaterally as far as possible.<sup>7</sup> A towel folded into thirds lengthwise is placed over the pubic area, and four folded towels are placed around the operative site, followed by two sterile, plastic adhesive drapes, half drape and CV drape.<sup>4</sup>

A count is performed and time out is called. Verification of patient's information and details about the surgery are confirmed. The incision site is marked with an indelible ink-marking pen. A number 10 blade loaded onto a number 3 knife handle is used to make a vertical midline incision from the nipples to the umbilicus. The subcutaneous layer is incised using a number 15 knife blade with a number 3 knife handle and hemostasis is achieved using an electrocautery pencil. The blood vessels are clamped with hemostats, cut with Metzenbaum scissors and then ligated with 3-0 polyglactin 910 ties. US Army retractors are utilized to facilitate the operative view and the rectus abdominis and the transversalis muscles are identified and dissected with curved Mayo scissors and toothed tissue forceps. The peritoneum is then identified and dissected with a number 15 blade loaded onto a number 3 knife handle, and cut with Metzenbaum scissors. At this point, the surgical technologist prepares a large self-retaining Omni-retractor for the abdominal wall. Additional blunt dissection, with the assistance of the Omni-retractor and fellow team members, exposes the aorta and aortic aneurysm.

The red and blue vessel loops are then moistened and loaded onto hemostats before passing for easy identification of different vessels. The inferior mesenteric artery is isolated at the left border of the aneurysm with a vessel loop, and the peritoneal incision is extended to the area over the common iliac arteries. The surgical technologist prepares the offset Potts vascular clamps that are used to occlude the iliac artery. The external and internal iliac arteries are cleared for vascular clamp placement. A vascular clamp is applied to the distal portion of the common iliac artery bilaterally and the surgical technologist prepares a large right angle to mobilize the aorta. The aorta is mobilized proximal to the aneurysm up to the level of the renal arteries, and cleared for eventual placement of a vascular clamp.

Meanwhile, a 20cc plastic syringe with a 20-23 gauge hypodermic needle is used to draw venous blood for preclotting. The surgical technologist has the graft in a metal bowl ready for saturation of blood. A bifurcated knitted Dacron graft is selected after sizing, and blood is drawn from the vena cava for preclotting. The surgical technologist needs to anticipate that heparin will be administered, and the time of placement of proximal and distal vascular clamps. The patient is given intravenous heparin, and vascular clamps are applied to the external and internal iliac arteries bilaterally or to the common iliac arteries. At this point, the surgical technologist needs to verify that all anastomosis sutures are loaded and ready. An aortic vascular clamp is applied to the aorta above the aneurysm and the aneurysm is opened with a number 11 blade loaded onto a number 7 knife handle and Mayo scissors. The aneurysm is opened longitudinally along the anterolateral wall and stopped just short of the aortic bifurcation. The surgical technologist needs to prepare for thrombus material that will be saved as a specimen. Thrombus material is removed from the interior of the aorta, and lumbar vessels are sewn from within the aneurysm sac. The surgical technologist will prepare the jet action of the 20-cc syringe/heparin needle combination with heparinized saline, because it will force out small pieces of thrombus from the aortic wall.

A T-shaped extension is then cut into the proximal border of the aneurysm, and the anterior aneurysm wall is opened for copious irrigation with heparinized saline. A 3-0 polypropylene (double-armed) is loaded onto a long vascular needle holder prepared along with long Debakeys. The proximal anastomosis begins with a continuous, double-armed 3-0 polypropylene suture. Any leaks in the proximal anastomosis are patched with interrupted, pledgeted polypropylene sutures. A Fogarty clamp is placed across the graft immediately distal to the anastomosis, the aortic vascular clamp is released and the two ends of the polypropylene suture are tied together, completing the anastomosis. The surgical technologist prepares for the graft to be cut to the appropriate size and an additional vascular clamp may be placed on the distal graft. The right limb of the graft is aspirated, brought down to the common iliac bifurcation and then cut to the correct length. An arteriotomy is performed on the right common iliac vessel, and the graft limb is anastomosed in an end-to-side fashion with a double-armed 3-0 polypropylene suture. The same process is repeated for the left side.

The surgical technologist will then prepare closure suture. The anterior wall of the aneurysm sac is sutured over the proximal aortic graft with 2-0 polyglactin 910, and the surgical technologist will note the number of laps removed from the abdominal cavity. The abdominal wound is closed in layers. The peritoneum is closed with 2-0 polyglactin 910 and a first count is performed. The rectus abdominis and the transversalis muscles are sutured with 1-0 polyglactin 910. A second count is performed. The abdominal wound is closed with 1-0 polydioxanone sutures and the skin is closed with staples. A final count is performed and the wound is dressed with abdominal pads.

### **POSTOPERATIVE CARE**

The surgical technologist should wait to breakdown until after the patient has been transported out of the OR. In this case, the patient was intubated and ventilated for 12 hours and monitored cardiac, respiratory, and renal function. Medical staff will assess lower-extremity perfusion hourly and assess the patient's pain. If everything goes well, the patient is out of bed rest two days following surgery.

The patient must guard incision site from oils, lotions, and powder and avoid lifting more than 5 to 10 pounds for 6 weeks to allow abdominal restoration. The patient should walk to increase his or her strength and improve circulation. The patient should avoid sitting for more than 1 to 2 hours at a time and avoid crossing his or her legs until given permission by doctor.

### **COMPLICATIONS**

There are some serious complications that can transpire during or after this procedure is performed. Rupture of an abdominal aneurysm is a critical complication that often leads to death. It is usually preceded by agonizing pain in the lower abdomen and back, with inflammation of the aneurysm. Rupture of an abdominal aneurysm causes copious bleeding, which may lead to shock. Half of all persons with untreated abdominal aortic aneurysms die of rupture within five years. Abdominal aortic aneurysms are the 13th foremost cause of death in the US.<sup>8</sup>

Peripheral embolization of clot within the aneurysm also can occur when a piece of clot falls loose and travels further out in the arterial system. This clot fragment can lodge in a smaller artery and block the flow of blood. Infection of aneurysms can occur from raging blood flow from the rough inner surface of the affected aorta.<sup>8</sup>

In some cases, a blood clot forming in the area of the abdominal aortic aneurysm can detach and reach the arteries supplying the heart. If the clot is large enough to occlude these arteries, a heart attack occurs. Once blood is no longer able to allocate nutrients and oxygen to the muscles of the heart, the heart starts to become impaired. This damage can cause the heart to beat irregularly or lead to complete stoppage of the heart or cardiac arrest. If the heart and vessels supplying the heart cannot be repaired in time, the patient will die. Treatment includes medicines to enlarge the blocked artery, medicines to dissolve the blood clot and surgery to remove the blocked blood vessel.<sup>8</sup>

## REFERENCES

1. Bikk, A. Abdominal aortic aneurysm repair preference card (2012). Unpublished surgical preference card, Veterans Affairs Hospital.
2. Dunn, D. (2007). *Wound closure manual*. Somerville, NJ: Ethicon, Inc.
3. Gilroy, AM; MacPherson, BR; Ross, LM. (2008). *Atlas of anatomy*. Stuttgart: Thieme.
4. Goldman, MA. (2008). *Pocket guide to the operating room* (3rd ed). Philadelphia: FA Davis Co.
5. Gray, H; Pick, TP; Howden, R. (2007). *Gray's Anatomy* (Rev American, from the 15th English, ed). New York: Bounty Books.
6. Huether, SE; McCance, KL. (2004). *Understanding pathophysiology* (4th ed). St. Louis, Mo: Mosby.
7. Price, P; Frey, KB; Junge, TL. (2004). *Surgical technology for the surgical technologist: a positive care approach* (3rd ed). Clifton Park, NY: Thomson-Delmar Learning.
8. Rothrock, JC; Smith, DA; McEwen, DR. (2007). *Alexander's care of the patient in surgery* (13th ed). St. Louis, Mo: Mosby.

# Circulatory System Review

TERI JUNGE, CST, CSFA, MED, FAST

*Editor's note: This article is intended as a brief overview of the digestive system and serves as an introduction for surgical technology students, a review for practicing surgical technologists and an exam preparation tool for individuals planning to take the national certification exam. It is not a comprehensive review.*

## HEART WALL AND PERICARDIUM

The heart wall is formed by three layers of tissue. The outer layer is a thin serous membrane that is called the epicardium. The myocardium is the middle layer which is comprised of a thick layer of cardiac muscle. The inner layer is called the endocardium and is a thin, smooth layer of epithelial cells that come in contact with the blood.

The pericardium surrounds the heart and consists of three layers. From outer to inner, the layers are called parietal, fibrous and visceral. The pericardium provides a surface for cardiac movement in conjunction with the serous fluid secreted by the epicardium.

## FUNCTIONS OF THE RIGHT AND LEFT SIDES OF THE HEART

The heart can be described as having two generalized sections, the left heart and the right heart. The right heart contains blood that has a low oxygen content. Blood from the right side of the heart must pass through the pulmonary circuit to be oxygenated. The left side of the heart contains blood that is rich in oxygen and pumps the oxygenated blood through the systemic circuit to the body's various tissues.

## CHAMBERS OF THE HEART

The heart contains four chambers; two atria and two ventricles. The atria are situated superior to the ventricles. The right atrium receives deoxygenated blood from the superior vena cava, the inferior vena cava and coronary sinus. Blood from the right ventricle is pumped into the right ventricle. The right ventricle receives blood from the right atrium and pumps blood low in oxygen to the pulmonary artery. The left atrium receives oxygenated blood from the pulmonary vein and pumps blood into the left ventricle. The left ventricle receives blood from the left atrium and pumps blood high in oxygen into the aorta and to the systemic circuit. The structures dividing the chambers of the heart are called septae. The valves at the entrance of each ventricle are extensions of the septae.

## HEART VALVES

Valves are located at the entrance and exit of each ventricle and serve to prevent backflow (regurgitation) of blood when the heart contracts. The tricuspid valve, also known as the right atrioventricular valve, is located at the entrance of the right ventricle and allows blood to flow unidirectionally from the right atrium to the right ventricle. Deoxygenated blood leaving the right ventricle flows through the pulmonic valve before entering the pulmonary trunk on its way to the lungs to obtain oxygen. Oxygenated blood from the lungs moves through the bicuspid valve as it enters the left ventricle from the left atrium. The bicuspid valve is also known as the mitral valve and the left atrioventricular valve. Oxygenated blood leaving the left ventricle passes through the aortic valve, which also is called the semilunar valve, before entering the aorta and being transported to the tissues.

## CORONARY CIRCULATION

The heart receives its blood supply via several strategically mapped coronary arteries that branch off the ascending aorta. The right and left coronary arteries provide oxygenated blood to the tissue of the heart. Additional arteries of importance that branch from the coronary arteries are the circumflex, right marginal, left anterior descending and the anterior and posterior interventricular arteries. Deoxygenated blood is returned to the right atrium via the coronary veins that dump into a coronary sinus on the posterior side of the heart.

## CARDIAC CYCLE

The cardiac cycle is measured from the start of one ventricular contraction to the start of the next. The contraction phase of the cardiac cycle is called systole and the relaxation phase is called diastole. The average cardiac cycle lasts 0.8 seconds.

## CONDUCTION SYSTEM

The vital control center in the medulla oblongata influences the heart rate and provides autonomic innervation (vagus nerve - X cranial) of the heart via the vagus nerve; however, the heart beat itself is initiated within the heart. The following is a brief overview of the conduction system of the heart.

- The sinoatrial (SA) node generates the electrical impulse that begins the heartbeat.
- The electrical impulse travels throughout the muscle of the atria causing contraction.
- The atrioventricular (AV) node is stimulated.
- The impulse travels through the bundle of His, the right and left bundle branches and the Purkinje fibers causing ventricular contraction.

## TYPES OF BLOOD VESSELS

Five types of blood vessels are identified: arteries, arterioles, capillaries, venules and veins. Arteries carry blood away from the heart and as the artery travels further from the heart it becomes smaller. Small arteries are called arterioles. Arterioles carry blood toward the capillaries. Capillaries are small thin-walled vessels that allow for exchange of oxygen, nutrients and waste products to and from the cells of the various tissues. Capillaries connect arterioles and venules. Venules are small veins that carry blood away from the capillaries. As blood is carried back toward the heart in the venules, several venules merge to form veins. Veins carry blood toward the

heart. Walls of all blood vessels (except capillaries) consist of three layers which are sometimes called tunics. The outer layer is called the tunica externa and consists of connective tissue. The middle layer is known as the tunica media and is comprised of smooth muscle. The inner layer consists of endothelial cells and is called the tunica intima, which is in contact with the blood flowing through the vessel. The tunica media of an artery is much thicker than that of a vein because the artery must be able to withstand the higher pressure. Because veins have almost no pressure, they contain one-way valves to prevent blood from flowing away from the heart due to the force of gravity.

## SECTIONS OF THE AORTA

The aorta can be divided into four sections: ascending, aortic arch, descending thoracic and abdominal. The ascending aorta is the first portion of the aorta and is closest to the left ventricle. The two branches of the ascending aorta are the right and left coronary arteries. Shortly after leaving the heart, the aorta curves to the left. This curvature is called the aortic arch. The first branch off of the aortic arch is the brachiocephalic artery (formerly known as the innominate artery), which then bifurcates into the right common carotid and the right subclavian arteries. The left common carotid artery is the second branch of the aortic arch and the left subclavian artery is the final branch. Beyond the arch, the aorta descends through the chest (descending thoracic aorta), passes through the diaphragm and continues to descend through the abdomen (abdominal aorta). All arteries that serve the abdomen and lower extremities are extensions of the abdominal aorta.

## RETURN OF BLOOD TO THE HEART

The superior and inferior venae cavae are the large veins that empty into the right atrium of the heart. Blood collected from the vessels of the chest, neck and upper extremities drain into the superior vena cava and blood from the remainder of the trunk and the lower extremities drain into the inferior vena cava. The venae cavae, along with the coronary sinuses, empties into the right atrium.

## VENOUS SINUSES

A venous sinus is a dilated vein that drains a region of deoxygenated blood. Venous sinuses have thin walls and no smooth muscle. Venous sinuses are found in the heart and brain.

## HEPATIC PORTAL SYSTEM

A portal system is a venous pathway that redirects blood to another part of the body before allowing it to return to the heart. The hepatic portal system directs blood carrying ingested portions of the digestive system to the liver. The portal vein receives blood via the tributaries from the capillaries of the abdominal viscera and then drains into the hepatic sinusoids.

## FUNCTIONS OF THE BLOOD

The blood serves three main functions: transportation, regulation and protection. Blood is responsible for transportation of oxygen, nutrients, electrolytes, vitamins, minerals, waste products and hormones. Blood functions to regulate pH (maintained at 7.4, which is slightly basic); the amount of fluid in the tissues (by osmosis) and body temperature (by transporting heat from the muscles). Blood carries cells that protect the body against pathogens and antibodies functions provide immunity and blood clotting factors.

### Constituents of Blood Plasma

Blood plasma consists of 90% water. The remaining 10% is made up of dissolved or suspended substances such as:

- Plasma proteins
  - o Albumin – manufactured in the liver; important in maintaining the osmotic pressure of the blood and is the most abundant protein in the plasma
  - o Clotting factors – manufactured in the liver
  - o Antibodies – combat infection
  - o Complement of enzymes – help antibodies fight pathogens
- Nutrients
  - o Glucose – stored in the liver and released to supply energy
  - o Amino acids – products of protein digestion; absorbed into the blood through the intestinal capillaries
  - o Lipids – including fats
  - o Electrolytes – function in bone formation, transport of various hormones, acid base balance, etc
    - Chloride, carbonate and phosphate salts of sodium
      - Potassium
      - Calcium
      - Magnesium
  - o Amino acids – products of protein digestion that absorbed into the blood through the intestinal capillaries
  - o Vitamins

- o Hormones
- o Waste products
- o Drugs

## FORMED ELEMENTS (CORPUSCLES)

Three types of formed elements are found in the blood.

- Erythrocytes – Biconcave disks that are red in color; mature erythrocytes carry oxygen, which is bound to the cell by a protein containing iron called hemoglobin. There are approximately 5 million red blood cells per  $\mu\text{L}$  (microliter), making them the most abundant of the formed elements.
- Leukocytes – White blood cells (WBCs) are round colorless cells that contain nuclei. There are five different types of leukocytes in two categories:
  - o Granulocytes
    - Neutrophils
      - Also known as polymorphs because the shape of the nuclei can vary
      - Account for 54 to 62% of the WBCs
      - Perform the function of phagocytosis
      - Show lavender granules when stained
    - Eosinophils
      - Account for 1 to 3% of WBCs
      - Function during allergic reactions and defend against parasites
      - Show beadlike bright pink granules when stained
    - Basophils
      - Account for fewer than 1% of WBCs
      - Function during allergic and inflammatory reactions
      - Show large dark blue granules that often obscure the nucleus when stained
  - o Agranulocytes
    - Lymphocytes
      - Account for 25-38% of WBCs
      - Responsible for immunity (T cells and B cells)
    - Monocytes
      - Account for 3 to 7% of WBCs
      - Perform phagocytosis
      - Mature monocytes are called macrophages

- Platelets (thrombocytes)
  - o Smallest of the formed elements
  - o Fragments of megakaryocytes
  - o Do not contain a nucleus or DNA
  - o Essential for coagulation of blood

**HEMOSTASIS**

Hemostasis is the maintenance of blood volume through the control of bleeding. There are three events related to achieving hemostasis.

1. Muscle contraction (constriction) – Smooth muscles of the blood vessel wall contract reducing the blood flow from the damaged vessel wall.
2. Platelet plug formation (aggregation) – Activated platelets become sticky and adhere to the damaged vessel wall to form a temporary plug.
3. Blood clot formation

**BLOOD CLOTTING CASCADE**

When a blood vessel is injured (surgically or traumatically) a complex series of events must take place in order for blood to clot. The following is a brief summary:

- Substances released from damages vessel wall result in the formation of prothrombinase.
- Prothrombinase converts prothrombin in the blood to thrombin.
- Thrombin converts fibrinogen to fibrin that forms a network of strands to entrap plasma and blood cells to form the clot.

**REVIEW**

Write the meaning of each word element in the space provided.

	Word Element	Definition
1.	agglutin/o	
2.	aneurysm/o	
3.	angi/o	
4.	anis/o	
5.	arter/o	
6.	arteri/o	
7.	arteriol/o	
8.	ather/o	
9.	bas/o	
10.	blast/o, -blast	
11.	cardi/o	
12.	coagul/o	
13.	coron/o	
14.	cyt/o	
15.	ech/o	
16.	electr/o	
17.	-emia	
18.	eosin/o	
19.	erythr/o	
20.	-globin	
21.	hem/o	
22.	hemat/o	
23.	kary/o	
24.	morph/o	
25.	phag/o, -phage	
26.	phleb/o	
27.	poikil/o	
28.	sider/o	
29.	spher/o	
30.	thromb/o	
31.	ven/o	



**1. List and describe the three layers of the heart wall.**

1. \_\_\_\_\_  
\_\_\_\_\_
2. \_\_\_\_\_  
\_\_\_\_\_
3. \_\_\_\_\_  
\_\_\_\_\_

**2. Describe the structure of the pericardium and cite its function.** \_\_\_\_\_

\_\_\_\_\_  
\_\_\_\_\_

**3. Compare the functions of the right and left sides of the heart.** \_\_\_\_\_

\_\_\_\_\_  
\_\_\_\_\_

**4. Name the four chambers of the heart and compare their functions.**

1. \_\_\_\_\_  
\_\_\_\_\_
2. \_\_\_\_\_  
\_\_\_\_\_
3. \_\_\_\_\_  
\_\_\_\_\_
4. \_\_\_\_\_  
\_\_\_\_\_

**5. Name the valves at the entrance and exit of each ventricle and cite the function of each.**

1. \_\_\_\_\_  
\_\_\_\_\_
2. \_\_\_\_\_  
\_\_\_\_\_
3. \_\_\_\_\_  
\_\_\_\_\_
4. \_\_\_\_\_  
\_\_\_\_\_

6. Briefly describe blood circulation through the myocardium. \_\_\_\_\_

---

---

---

7. Briefly describe the cardiac cycle. \_\_\_\_\_

---

---

---

8. Name the components of the conduction system of the heart and describe the function of each. \_\_\_\_\_

---

---

---

---

9. Differentiate among the five types of blood vessels with regard to structure and function.

1. \_\_\_\_\_  
\_\_\_\_\_
2. \_\_\_\_\_  
\_\_\_\_\_
3. \_\_\_\_\_  
\_\_\_\_\_
4. \_\_\_\_\_  
\_\_\_\_\_
5. \_\_\_\_\_  
\_\_\_\_\_

10. Name the four sections of the aorta and list the main branches of each section.

1. \_\_\_\_\_  
\_\_\_\_\_
2. \_\_\_\_\_  
\_\_\_\_\_
3. \_\_\_\_\_  
\_\_\_\_\_
4. \_\_\_\_\_  
\_\_\_\_\_

11. Name the main vessels that drain into the superior and inferior venae cavae. \_\_\_\_\_  
\_\_\_\_\_  
\_\_\_\_\_

12. Define and give several examples of venous sinuses. \_\_\_\_\_  
\_\_\_\_\_  
\_\_\_\_\_

13. Describe the structure and function of the hepatic portal system. \_\_\_\_\_  
\_\_\_\_\_  
\_\_\_\_\_

14. List the functions of blood.

1. \_\_\_\_\_  
\_\_\_\_\_
2. \_\_\_\_\_  
\_\_\_\_\_
3. \_\_\_\_\_  
\_\_\_\_\_

15. List the main ingredients in plasma. \_\_\_\_\_  
\_\_\_\_\_  
\_\_\_\_\_  
\_\_\_\_\_

16. Name and describe the three types of formed elements in the blood and their functions.

1. \_\_\_\_\_  
\_\_\_\_\_
2. \_\_\_\_\_  
\_\_\_\_\_
3. \_\_\_\_\_  
\_\_\_\_\_

**17. Name and characterize the five types of leukocytes.**

1. \_\_\_\_\_  
\_\_\_\_\_
2. \_\_\_\_\_  
\_\_\_\_\_
3. \_\_\_\_\_  
\_\_\_\_\_
4. \_\_\_\_\_  
\_\_\_\_\_
5. \_\_\_\_\_  
\_\_\_\_\_

**18. Define hemostasis and cite three steps in hemostasis.**

1. \_\_\_\_\_  
\_\_\_\_\_
2. \_\_\_\_\_  
\_\_\_\_\_
3. \_\_\_\_\_  
\_\_\_\_\_

**19. Briefly describe the steps in blood clotting.**

- \_\_\_\_\_
- \_\_\_\_\_
- \_\_\_\_\_
- \_\_\_\_\_
- \_\_\_\_\_
- \_\_\_\_\_

**ANSWER KEY**

These are the answers to the definition chart on 113.

	Word Element	Definition
1.	agglutin/o	to clump
2.	aneurysm/o	aneurysm
3.	angi/o	vessel
4.	anis/o	unequal
5.	arter/o	artery
6.	arteri/o	artery
7.	arteriol/o	arteriole
8.	ather/o	fatty
9.	bas/o	base
10.	blast/o, -blast	embryonic stage of development
11.	cardi/o	heart
12.	coagul/o	clotting
13.	coron/o	heart
14.	cyt/o	cell
15.	ech/o	sound
16.	electr/o	electrical, electricity
17.	-emia	blood condition
18.	eosin/o	red
19.	erythr/o	red
20.	-globin	contains protein
21.	hem/o	blood
22.	hemat/o	blood
23.	kary/o	nucleus
24.	morph/o	form, shape
25.	phag/o, -phage	to eat or swallow
26.	phleb/o	vein
27.	poikil/o	varied, irregular
28.	sider/o	iron
29.	spher/o	round, spherical
30.	thromb/o	clot
31.	ven/o	vein

**REFERENCES**

1. Cohen, B. (2005). *Memmler's the human body in health and disease* (10th ed). Philadelphia: Lippincott Williams & Wilkins.
2. Frey, K, et al. (2008). *Surgical technology for the surgical technologist: A positive care approach* (3rd ed). United States: Delmar Cengage Learning.