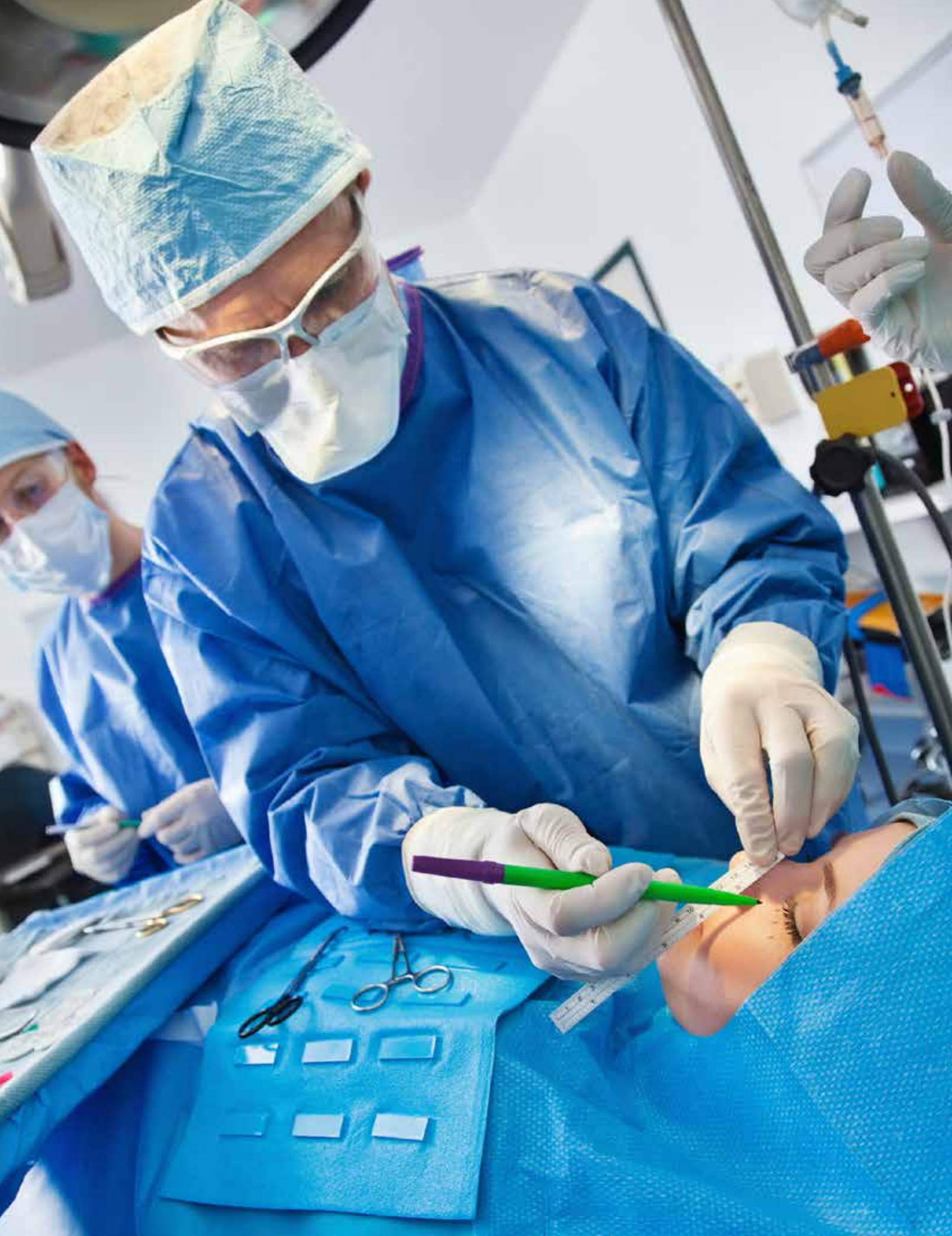



Butterfly Graft in Functional Rhinoplasty

LACIE SAUTTER, CST

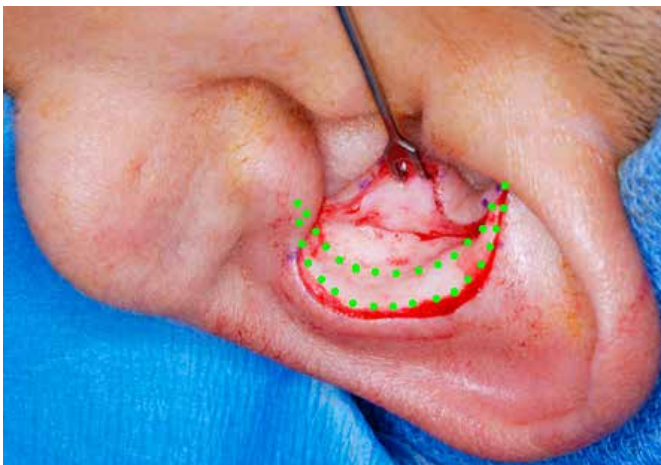
Nasal airway obstruction has numerous causes, with nasal valve disorders becoming more frequently recognized as contributors to airway obstruction.⁵ Nasal valve stenosis occurs when the nasal airway's narrowest part becomes weakened causing one or both sides of the nasal cavity to fall into the airway when breathing in. There are different ways to repair nasal valve stenosis, and different types of grafts can be used to increase airway function. For the purpose of this article, the butterfly graft will be explored as a cosmetically pleasing and successful method of correcting this condition.

ANATOMY

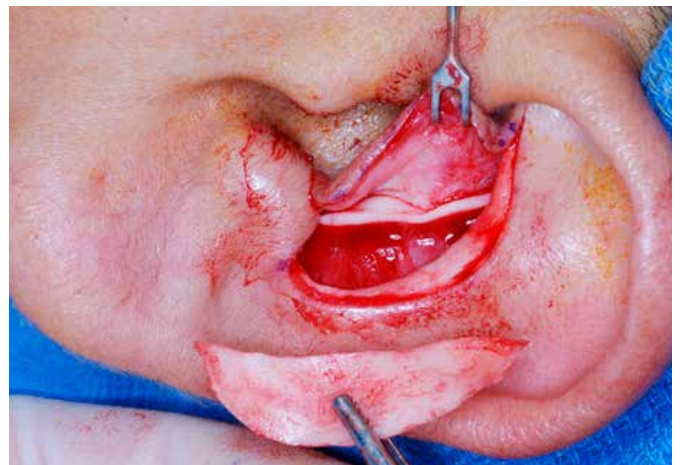
The tip of the nose is referred to as the apex.¹ The nasal septum is the cartilage that divides the nostrils, and the columella is the bridge of tissue that separates the nostrils at the nasal base. Anteriorly, the septum is cartilaginous, and posteriorly the septum has bony attachments to the ethmoid and vomer bones.² The flared external nostrils are called the ala. The internal valve is the primary regulator of nasal airflow, which is situated at the narrowest portion of the nasal airway. The area is bordered medially by the nasal dorsal septum, laterally by the caudal edge of the upper lateral cartilage, the floor of the nose inferiorly and inferolaterally by the head of the inferior middle turbinate.³ The external valve of the nose is located inside the nasal vestibule formed by the alar rim, columella and nasal floor. The dorsum is between the root and the tip, with the bridge being the upper portion of the dorsum.⁴ The superior, middle and inferior turbinates are located laterally on both sides of the nose, curving medially and directed downward.

LEARNING OBJECTIVES

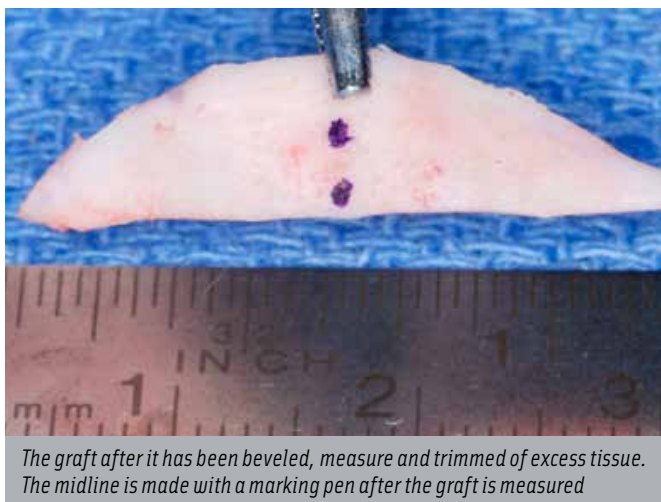
- ▲ Review the anatomy affected by a butterfly graft in functional rhinoplasty
- ▲ Examine the positioning and skin prep for the patient
- ▲ List the instrumentation and equipment used in this operation
- ▲ Recall the procedural steps involving the butterfly graft
- ▲ Identify the post-operative complications for this procedure



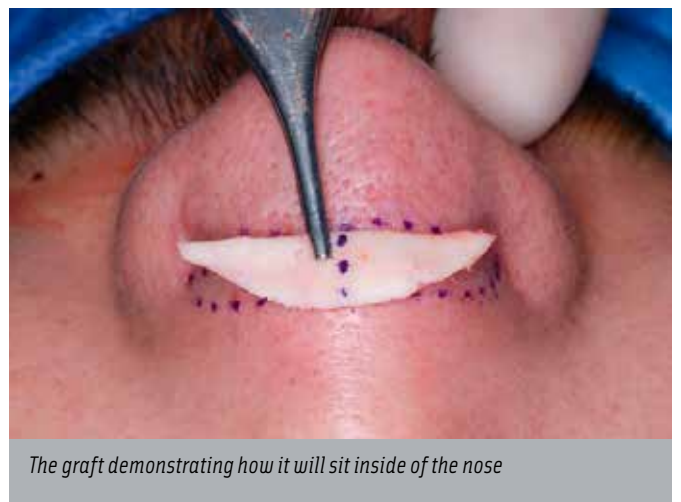
Conchal ear cartilage exposed showing the appropriate size of the graft



Conchal ear cartilage removed from the graft site



The graft after it has been beveled, measure and trimmed of excess tissue. The midline is made with a marking pen after the graft is measured



The graft demonstrating how it will sit inside of the nose

NASAL VALVE COLLAPSE AND STENOSIS

There are two classifications of nasal valve collapse: static and dynamic. Static internal nasal valve collapse is a narrowing of the middle third of the nose at rest,⁵ which is often a result from trauma or a previous rhinoplasty. Patients with static internal nasal valve collapse often have weak upper lateral cartilages, thin skin and apex ptosis, which adds to the narrowed valve angle. Dynamic nasal valve collapse is a narrowing of the upper lateral cartilage and middle third section that occurs with active nasal inspiration; it appears at normal size when at rest.⁶ This is commonly a result from nasal muscle deficiency that can result in sidewall weakness.

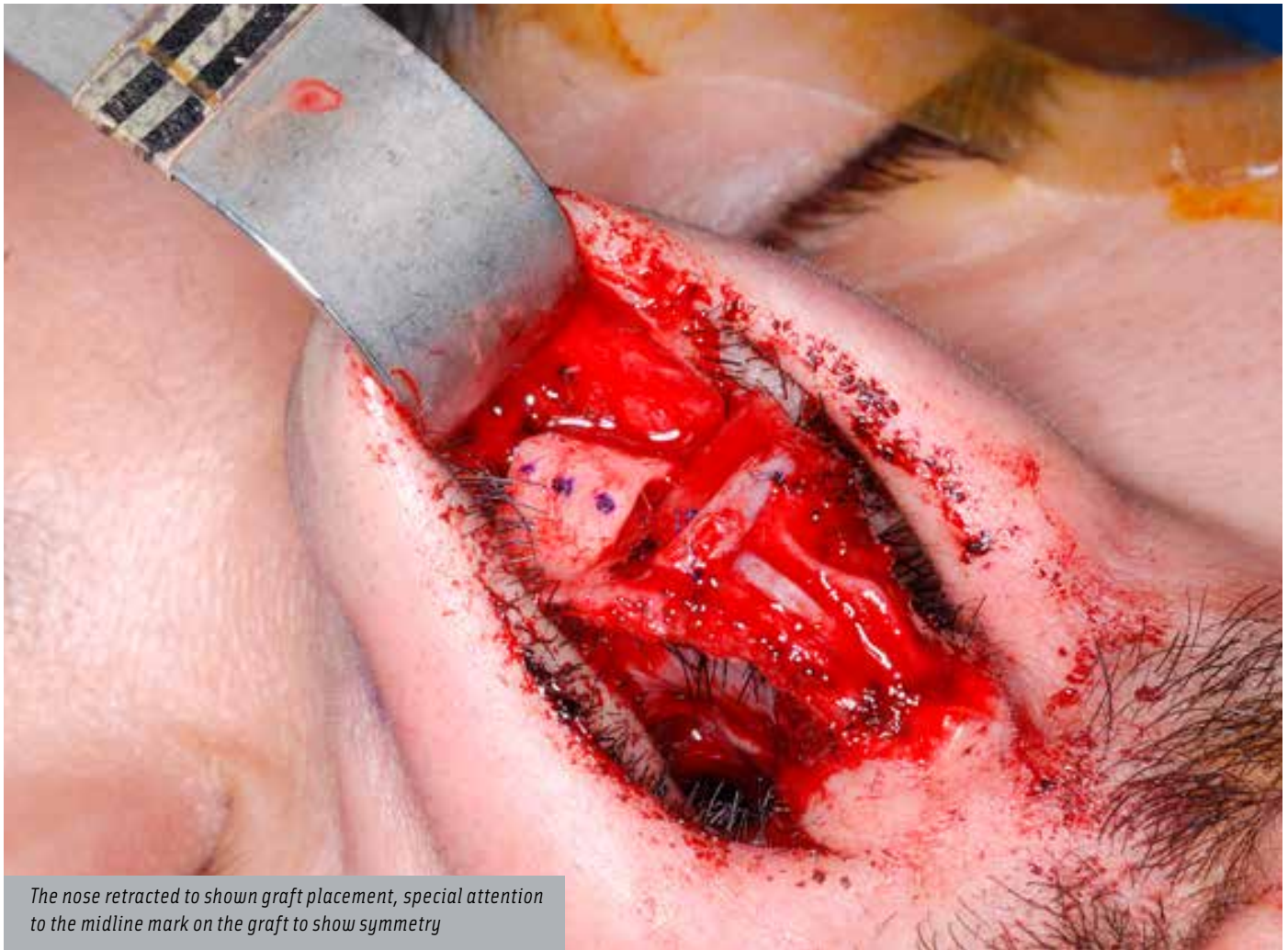EXAMINATION

The patient will need to consult with a facial plastic surgeon so the doctor may inspect the patient's nose for strength and length of the nasal bones, upper and lower

lateral cartilages and strength of tip support. Strong surgical candidates for a primary butterfly graft report nasal obstruction that is relieved with either the Cottle's maneuver or application of external nasal dilator devices.⁷ For the Cottle's maneuver, the physician applies slight lateral traction on the cheek next to the nose and assesses which movements during inspiration improve breathing as the lateral wall stiffens. To pinpoint the location of collapse, the physician may introduce a cotton tip applicator or cerumen curette intranasally to support the internal or external nasal valve to observe if nasal airflow symptoms improve.⁸ The precise location of the valve collapse is noted for surgery. The surgeon also will assess the condition of the patient's septum and inferior turbinates.

The patient will need to answer a series of questions during their initial clinic visit including:

- History of nasal trauma? If so, when?
- Is there a history of seasonal allergies? (Allergies are



The nose retracted to shown graft placement, special attention to the midline mark on the graft to show symmetry

Since the nose is an airway passage, this case is considered a clean, not sterile, procedure. The patient is positioned supine on the OR table with the arms tucked at the sides, or Fowlers position with the hands placed in the lap. The OR table may need to be turned to facilitate the surgeon's access to the operative site.

treated non-surgically.)

- Is breathing on one side of the nose better or worse?
- Have nasal steroid sprays and/or nasal salines helped alleviate symptoms?
- Is there a history of previous nasal or sinonasal surgery?
- Have the use of breathe aide strips helped to alleviate conditions?

Photos and X-rays of the patient's face will be taken at the various body planes to provide the surgeon references to symmetry, alignment and cosmetic aspects of the exterior nose and nasal cavity prior to the procedure.

EQUIPMENT, INSTRUMENTS, SUPPLIES, AND MEDICATIONS

The equipment needed for a rhinoplasty includes headlight for the surgeon, electrosurgical unit (ESU) set at 18 for coagulation, and suction. Instrumentation needed for

SPREADER GRAFTS

Another commonly performed technique to increase nasal airway function and correct nasal valve collapse, is the use of spreader grafts. Spreader grafts are 3x20-mm cartilaginous grafts used to reposition the upper lateral cartilages and maintain middle nasal vault width. The cartilage is taken from the septum and prepared into two long thin pieces to be placed along the nasal dorsum in a subsuperficial musculo-aponeurotic system plane and sutured to the upper lateral cartilages as a stent to open the nasal valves. Spreader grafts are preferred over the butterfly graft if the patient has an extremely crooked nose because the spreader graft provides better stability after bony work to straighten the nose than the butterfly graft. The spreader grafts displace the upper lateral cartilages laterally. It is placed submucosally and is secured with sutures.

1. D. Heath Stacey, MD; Ted A. Cook, MD; and Benjamin C. Marcus, MD. "Correction of Internal Nasal Valve Stenosis: A Single Surgeon Comparison of Butterfly Versus Traditional Spreader Grafts." *Annals of Plastic Surgery* 63.3 (2009): 280. Print.
2. D. Heath Stacey, MD; Ted A. Cook, MD; and Benjamin C. Marcus, MD. "Correction of Internal Nasal Valve Stenosis: A Single Surgeon Comparison of Butterfly Versus Traditional Spreader Grafts." *Annals of Plastic Surgery* 63.3 (2009): 280. Print.
3. D. Heath Stacey, MD; Ted A. Cook, MD; and Benjamin C. Marcus, MD. "Correction of Internal Nasal Valve Stenosis: A Single Surgeon Comparison of Butterfly Versus Traditional Spreader Grafts." *Annals of Plastic Surgery* 63.3 (2009): 282. Print.

When preparing the graft site, a conservative dorsal reduction is performed to create room for the graft and ensure an aesthetically pleasing nasal dorsum. The butterfly graft is placed in a pocket at the caudal end of the upper lateral cartilages and deep to the cephalic border of the lateral crura.

the procedure is a rhinoplasty or basic nasal instrument set that includes a Frazier suction tip. Needed supplies are: patient donut headrest; sterile skin marking pen; cotton-tip applicators; plastic/facial back table custom pack; 4 x 4 radiopaque sponges; #15 knife blades x 3; suction tubing; ear syringe; sterile gown and gloves; needle tip for ESU pencil; 4-0 or 5-0 plain gut suture on double-armed Keith needle; 4-0 nylon suture; 4-0 polyglactin 910 suture; 5-0 polydioxanone (PDS® II) suture; 5-0 Chromic gut suture; 6-0 plain gut suture; nasal splint; and cotton bandages. Warm saline will be needed for irrigation purposes. Additionally, the CST should confirm the patient photos and X-rays are available in the OR.

ANESTHESIA

Prior to the start of the procedure, the surgeon will inject the local anesthetic; even when general anesthesia is planned the local and topical anesthetics are administered to aid in hemostasis, reduce the size of the nasal membranes and aid in decreasing the immediate postoperative pain. The surgeon usually administers the local and topical anesthetics prior to the skin prep and draping to allow the medications to take effect; this may be performed in the preoperative holding area or the OR. The supplies and drugs needed are a Mayo stand, nasal speculum, Bayonet forceps, local anesthetic with epinephrine (usually 1% lidocaine), 10-mL Luer-Lok syringe with 25-gauge needle, crystallized cocaine or oxymetazoline (used as a decongestant), ½" x 3" cottonoid sponges, medicine cups, and cotton-tipped applicator. The surgeon injects the local anesthetic into the nose and turbinates, and inserts two cocaine or oxymetazoline soaked cottonoid sponges in each nostril.

POSITIONING, SKIN PREP AND DRAPING

Since the nose is an airway passage, this case is considered a clean, not sterile, procedure. The patient is positioned supine on the OR table with the arms tucked at the sides, or Fowler's position with the hands placed in the lap. The OR table may need to be turned to facilitate the surgeon's access to the operative site. Since a graft will be taken from the concha of the ear, general anesthesia is administered. For this case, skin prep was ordered with both the patient's face and prepped with a povidone-iodine solution. (Skin prep for this procedure may vary. Follow your facilities' protocol.) The draping will consist of a half sheet folded with a towel under the head forming a turban. It will be secured with a penetrating towel clip, and a towel will be placed over

the endotracheal tube followed by a split drape or U-drape, leaving both ears exposed. In the instance that the left ear cartilage is suboptimal for the butterfly graft, or the patient has had a previous graft taken from the left concha, the right ear may be used.

SURGICAL PROCEDURE

Using the Bayonet forceps, the surgeon removes the cottonoid sponges, and using a sterile skin pen marks an “inverted V” incision on the columella. With a #15 blade and a wide double-skin hook, the surgeon makes the initial incision as well as intercartilaginous incisions on the inside of both nostrils followed by the hemitransfixion incision. Using Iris scissors and switching to a small double-skin hook placed at the apex of the nose for exposure, the surgeon combines the incisions. Using a combination of Iris scissors and skin hooks to gain exposure, the surgeon dissects down to the upper lateral cartilages and the septum. Once the nasal cartilages have been exposed, the surgeon dissects the septum. A #15 blade will be used to score the cartilage, and a Freer elevator will be used to raise the mucoperichondral flap. A narrow Cottle nasal speculum is used to expose the septal cartilage and the septoplasty will begin by using the Freer and the Cottle to loosen the septum from the mucoperichondral flap. The Takahashi forceps is used to remove deviated portions of bone and cartilage. The surgical technologist needs to save the septal cartilage in a saline-filled medicine cup for possible graft use later. Once the surgeon assesses the available cartilage from the septum and the cosmetic adjustments that will be made to the nose, the harvesting of the conchal cartilage from the left ear will begin. If the patient has a crooked nose or has previously broken his or her nose, an osteotomy may be performed to refracture the bones in order to straighten them.

Using the sterile skin marker, an anterior helical rim incision is outlined in order to take a graft measuring 1 x 2 cm from the lateral flat portion of the concha of the ear.⁹ The incision is made with a #15 knife blade, and tenotomy scissors are used to undermine the skin and expose the conchal cartilage. Cotton-tipped applicators are utilized to push back the mucosa to expose the right plane to minimize bleeding. The conchal cartilage is incised with a #15 knife blade. The tenotomy scissors with cotton-tipped applicators are used to undermine the cartilage and completely remove it from the ear. The ESU pencil with needle tip is

used to control bleeding and a 4-0 or 5-0 fast-absorbing suture (surgeon’s preference) is used to close the incision. A dressing bolster is placed in the concha of the ear and behind the ear, and is secured with a 4-0 nylon suture to prevent a hematoma.

Once the conchal cartilage is removed, the surgeon measures the graft and draws a line directly down the center of the graft with a sterile marking pen and ruler to ensure accurate graft placement. The surgeon prepares the graft by thinning it with a #15 knife blade. Beveling the edges will ensure a smooth dorsal contour.⁹ When preparing the graft site, a conservative dorsal reduction is performed to create room for the graft and ensure an aesthetically pleasing nasal dorsum.¹⁰ The butterfly graft is placed in a pocket at the caudal end of the upper lateral cartilages and deep to the cephalic border of the lateral crura. The converse retractor is placed to hold up the pocket and the graft is inserted with

Once the surgeon assesses the available cartilage from the septum and the cosmetic adjustments that will be made to the nose, the harvesting of the conchal cartilage from the left ear will begin. If the patient has a crooked nose or has previously broken his or her nose, an osteotomy may be performed to refracture the bones in order to straighten them.

a smooth Adson-Brown forceps. The graft is secured with a 5-0 polydioxanone suture.¹¹

Frequently, especially in patients with thin skin, crushed cartilage grafts are placed on the nasal dorsum, cephalic to the upper edge of the butterfly graft, in order to camouflage the graft edges and create a smooth dorsal contour.¹² After the graft is placed, the surgeon begins closure of the nose. The anterior septum is closed with a 4-0 plain gut on a double-armed Keith needle, which is useful if a strut graft is placed for stability of the columella. A 4-0 polyglactin 910 quilting stitch is used to close the septum. The surgeon uses a 6-0 fast absorbing plain gut to close the columellar incision and a 5-0 chromic gut on a 1/2-inch reverse cutting needle for the marginal incisions inside the nose.

Two pieces of rolled up bandages are placed in both nostrils to control bleeding. The surgeon places paper tape over the nose as a soft splint. If bone work or osteotomies were performed, a cast dressing is placed on the nose.

POST-OPERATIVE CONSIDERATIONS

After the patient is awake and extubated, he or she are transported to the PACU with the head of the stretcher elevated. The CST should not break down the back table or Mayo stand until the patient is transported out of the OR. The bandage rolls are removed in the PACU, and the patient is released once he or she is awake and minimal to no bleeding is documented. Bruising, swelling and minimal bleeding are common side effects. It is not uncommon for the patient to have orbital bruising if osteotomies were performed. Patient discharge instructions include gently applying a small ice pack to the nose to aid in reducing swelling and pain, to remain in bed for the first post-operative day with his or her head elevated and to take oral analgesics. The patient is instructed to not blow the nose and avoid vigorous face-washing for one week. The main concern is significant bleeding, in which the surgeon may need to place nasal packing, or in a worse-case scenario, return the patient to surgery to cauterize or place another suture.

Photos courtesy of Tom D Wang, MD, and Adam Terella, MD. Special thanks to Dr Wang and Sachin S Pawar, MD.



AUTHOR'S BIO

Lacie Sautter, CST, lives in Portland, Oregon, with her husband and two dogs. She graduated from the surgical technology program at Concorde Career College more than four years ago and currently works at Oregon Health & Science University and The Portland Clinic where she primarily scrubs ENT.

REFERENCES

1. Oren Friedman, MD; and Ted A. Cook, MD. "Conchal Cartilage Butterfly Graft in Primary Functional Rhinoplasty." *The Laryngoscope* 119 (2009): 255-262. Print.
2. D. Heath Stacey, MD; Ted A. Cook, MD; and Benjamin C. Marcus, MD. "Correction of Internal Nasal Valve Stenosis: A Single Surgeon Comparison of Butterfly Versus Traditional Spreader Grafts." *Annals of Plastic Surgery* 63.3 (2009): 280-283. Print.

3. "Anatomy of the Nose and Sinuses." *Surgical Technology for the Surgical Technologist*. Ed. Kevin B. Frey, CST, MA and Tracy Ross, CST, M.Ed. Clifton Park, NY: Delmar Cengage Learning, 2008. 632. Print.
4. "Anatomy of the Nose and Sinuses." *Surgical Technology for the Surgical Technologist: A Positive Care Approach*. Ed. Kevin B. Frey, CST, MA and Tracy Ross, CST, M.Ed. Clifton Park, NY: Delmar Cengage Learning, 2008. 632. Print.
5. "Anatomy of the Nose and Sinuses." *Surgical Technology for the Surgical Technologist*. Ed. Kevin B. Frey, CST, MA and Tracy Ross, CST, M.Ed. Clifton Park, NY: Delmar Cengage Learning, 2008. 632. Print.
6. Oren Friedman, MD; and Ted A. Cook, MD. "Conchal Cartilage Butterfly Graft in Primary Functional Rhinoplasty." *The Laryngoscope* 119 (2009): 259. Print.
7. "Anatomy of the Nose and Sinuses." *Surgical Technology for the Surgical Technologist*. Ed. Kevin B. Frey, CST, MA and Tracy Ross, CST, M.Ed. Clifton Park, NY: Delmar Cengage Learning, 2008. 632. Print.
8. Oren Friedman, MD; and Ted A. Cook, MD. "Conchal Cartilage Butterfly Graft in Primary Functional Rhinoplasty." *The Laryngoscope* 119 (2009): 260. Print.
9. Oren Friedman, MD; and Ted A. Cook, MD. "Conchal Cartilage Butterfly Graft in Primary Functional Rhinoplasty." *The Laryngoscope* 119 (2009): 260. Print.
10. Oren Friedman, MD; and Ted A. Cook, MD. "Conchal Cartilage Butterfly Graft in Primary Functional Rhinoplasty." *The Laryngoscope* 119 (2009): 255. Print.
11. Oren Friedman, MD; and Ted A. Cook, MD. "Conchal Cartilage Butterfly Graft in Primary Functional Rhinoplasty." *The Laryngoscope* 119 (2009): 260. Print.
12. Oren Friedman, MD; and Ted A. Cook, MD. "Conchal Cartilage Butterfly Graft in Primary Functional Rhinoplasty." *The Laryngoscope* 119 (2009): 258. Print.
13. Oren Friedman, MD; and Ted A. Cook, MD. "Conchal Cartilage Butterfly Graft in Primary Functional Rhinoplasty." *The Laryngoscope* 119 (2009): 259. Print.
14. D. Heath Stacey, MD; Ted A. Cook, MD; and Benjamin C. Marcus, MD. "Correction of Internal Nasal Valve Stenosis: A Single Surgeon Comparison of Butterfly Versus Traditional Spreader Grafts." *Annals of Plastic Surgery* 63.3 (2009): 282. Print.
15. Oren Friedman, MD; and Ted A. Cook, MD. "Conchal Cartilage Butterfly Graft in Primary Functional Rhinoplasty." *The Laryngoscope* 119 (2009): 259. Print.