



CE Credit Package 12

13 Credits for \$21⁰⁰



Please submit your completed Master Answer Sheet along with payment to

AST Member Services

6 W. Dry Creek Circle, Suite 200 Littleton, CO 80120

Or fax with credit card information to (303) 694-9169.

Or scan and e-mail with credit card information to memserv@ast.org.

Table of Contents
CE Credit Package 12



Radiation Risk

Total Knee Arthroplasty

Understanding Menorrhagia Treatment with Office-Based Ablations

Surgical Correction of Acquired Adult Flatfoot Deformity

Hip Arthroscopy: Treating Femoroacetabular Impingement

**An Examination of Diagnosis and Surgical Intervention in the Open Thoracotomy Approach to
Bronchoesophageal Fistulae Repair**

Platysmaplasty a Surgical Resolution for the “Turkey Neck”

Emergency Cesarean Delivery in the Labor and Delivery Room

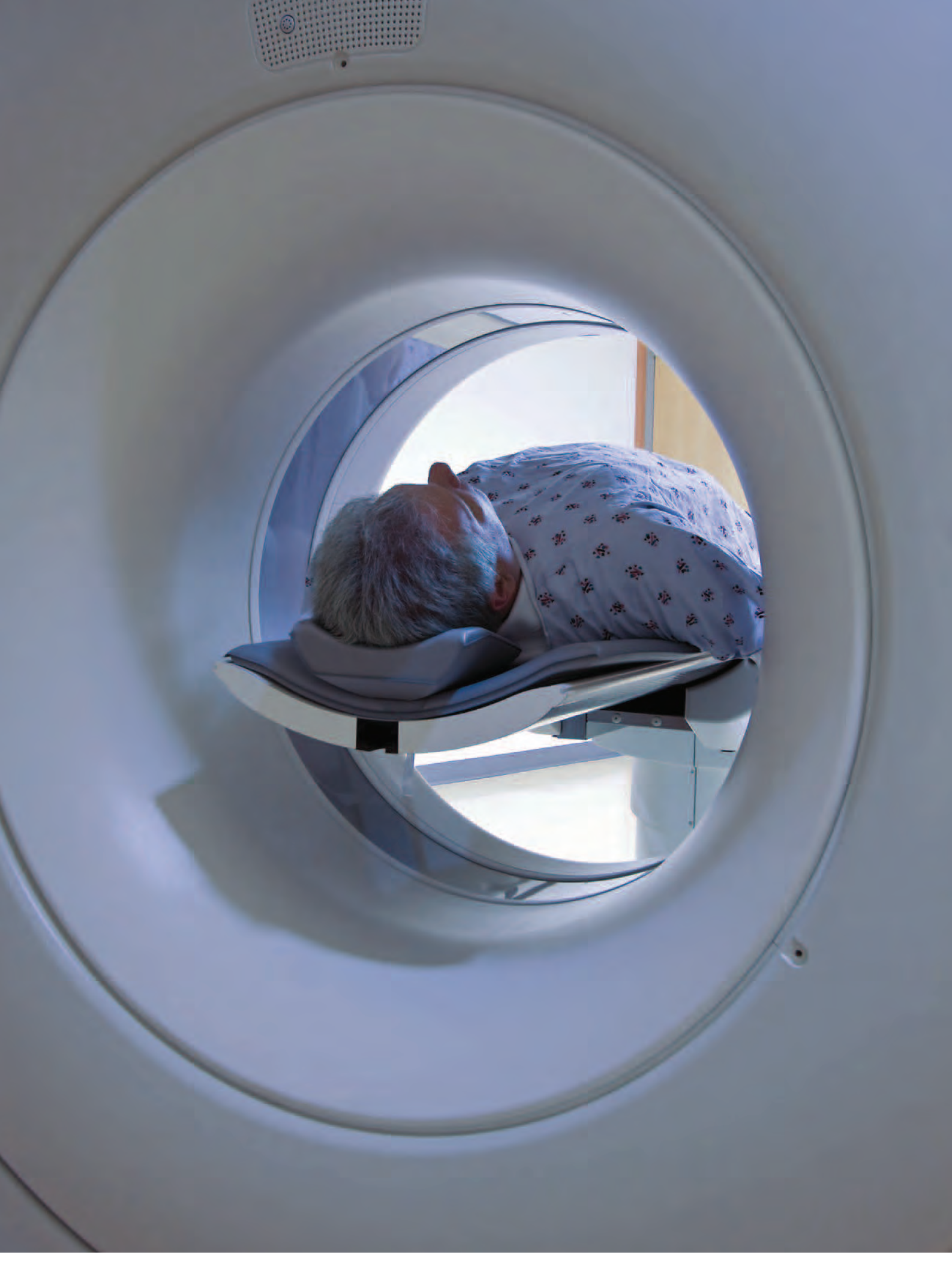Birmingham Hip Resurfacing

Radical Neck Dissection

Pectus Carinatum: Pigeon Chest

Vertical Sleeve Gastrectomy





Radiation **RISK**

by Mark Otto Baerlocher, MD

Question:

What is the estimated risk of both nonfatal and fatal malignancy associated with a CT of the abdomen at 10 milliSieverts effective dose (mSv) in a 25-year old woman?

The use of medical imaging and related exams and procedures includes everything from X-rays, intra-operative fluoroscopy, CT scans, coronary angiography/angioplasty, embolizations, and endoscopic retrograde cholangiopancreatography (ERCP), among others. The use of these exams and procedures has rapidly increased over the last two decades, and has led to enormous improvements in both the diagnosis and the treatment of diseases and pathologies. With this increase comes a concomitant increase in the cumulative exposure to ionizing radiation to patients, and by extension, an increase in estimated associated cancer risk.

As patients are largely unaware of the associated risks, it is therefore imperative that health care workers become educated on the topic. The following article briefly discusses the background of radiation risk, the model used to estimate radiation-related cancer risk, and potential education strategies.

This article is written with a primary focus on patients. However, the issues apply equally to health care workers, and certainly, to surgical technologists, for their own protection. While patients are undergoing medical imaging and related exams and

LEARNING OBJECTIVES

- ▲ Examine the effects of radiation on the human body
- ▲ Compare and contrast the difference between necessary procedures and procedures that are perceived to be necessary
- ▲ Evaluate the rate of radiation-associated cancer risk
- ▲ Analyze methods of reducing radiation exposure
- ▲ Explore methods of tracking your personal radiation exposure level

procedures for their own health, health care workers are being exposed occupationally. A lack of awareness or appreciation could therefore lead to a lack of safety and appropriate protection in an occupational setting. And because there is potential for occupational exposure on a daily basis, a lack of appropriate protection could result in very high, systematic exposure rates. It is therefore crucial that all health care workers attain a basic understanding and awareness of the related issues, not only for the sake of patients, but for personal protection as well.

RADIATION

The simplest definition of the term, “radiation,” is the transport of energy through space, which will eventually be absorbed by a material (the Earth, the human body, air particles, etc). Radiation comes in different forms—for example, a person is able to listen to his or her radio due to radio-wave radiation, and people can see their surroundings due to light-wave radiation.

The type of radiation used for medical imaging purposes is generally “ionizing,” which means that the radiation

Because there is potential for exposure on a daily basis, a lack of appropriate protection could result in very high, systematic exposure rates. It is therefore crucial that all health care workers attain a basic understanding and awareness of the issues.

carries sufficient energy to eject electrons from particles, resulting in the creation of ions.¹ Ionizing radiation is used in X-rays, CT scans, fluoroscopy, coronary angiography/angioplasty, and many other exams and procedures.

These positively-charged ions, once created, can then go on to cause damage in human tissue, by creating damage to DNA for example. Due to different protective mechanisms and growth characteristics, some cell types in the human body are more prone to radiation than others; *ie* they are more “radiosensitive.” In general, it has been found that cell radiosensitivity is directly proportional to the rate of cell division and inversely proportional to the degree of cell differentiation. In short, this means that actively-dividing cells, or those not fully mature, are most at risk from radiation.² For example, hematopoietic cells, reproductive cells, and cells within the digestive tract are particularly radiosensitive.

EFFECTS OF RADIATION

There are two categories of harm that may be caused by radiation: deterministic (nonstochastic), and stochastic.

Deterministic effects are those that occur once a given exposure is reached. Infertility and cataracts are two examples of deterministic effects. Skin erythema/redness occurs at a dose of at least five sieverts. The sievert is a unit used to derive a quantity called equivalent dose. This relates the absorbed dose in human tissue to the effective biological damage of the radiation. Not all radiation has the same biological effect, even for the same amount of absorbed dose. Equivalent dose is often expressed in terms of millionths of a sievert, or micro-sievert. To determine equivalent dose (Sv), you multiply absorbed dose (Gy) by a quality factor (Q) that is unique to the type of incident radiation.¹

Stochastic effects are those effects that are probabilistic. In other words, there is no threshold above which the effect always occurs, however, the greater the exposure, the greater the probability of occurrence. The primary stochastic effect is the development of cancer.

ESTIMATION OF RADIATION - ASSOCIATED (CANCER) RISK

Estimation of radiation-associated cancer risks is very difficult due to numerous complexities involved. Many of the estimates are based on extrapolation from atomic bomb data. Arguably, the most expert risk-estimate model estimation comes from the National Academy of Sciences (NAS)

Committee on the Biological Effects of Ionizing Radiation (BEIR) VII, which is available to read online at http://www.nap.edu/catalog.php?record_id=11340.

The BEIR VII committee uses the linear-no-threshold (LNT) model, which assumes that radiation risk is linear, and non-threshold (*ie*, there is no minimum radiation exposure which must be surpassed in order to increase the associated risk of developing cancer). As with any model, there are inherent deficiencies and inaccuracies. However, as additional data become available, the risk estimates are re-evaluated and modified.

RADIATION IN MEDICINE

As mentioned above, ionizing radiation is utilized quite extensively in medicine, both in diagnosis (X-rays, CT scans, nuclear medicine scans, fluoroscopy, coronary

angiography, ERCP, etc) and in treatment (embolizations, angioplasty/stenting, ERCP, etc). One of the largest sources of cumulative radiation exposure in medicine is from CT scans, which has increased rapidly over the last two to three decades.³ There have been estimates, for example, that if current CT usage rates continue, up to one and a half to two percent of all cancers in the United States may be caused by CT radiation in the future.³

If current CT usage rates continue, up to one and a half to two percent of all cancers in the United States may be caused by CT radiation in the future.³

While patients assume that any test or procedure requested is clinically indicated or necessary, this may not always be the case. There has been evidence, for example, that not all exams ordered may be clinically indicated, and a substantial minority may be ordered for other reasons, such as miscommunication or medico-legal reasons.³ Perhaps one contributing factor is an underestimation of the risks of radiation-associated cancer by many clinicians.⁴

Periodically, there are very high-profile papers published in high-impact medical journals such as the *New England Journal of Medicine*,^{3,5} which then lead to articles published in the mainstream media (eg *U.S. News & World Report*, CBS, *The Wall Street Journal*, *USA Today*, CNN, etc). Following such stories, there may be a tendency for misinformation to propagate and misunderstanding to ensue.

DECREASING RADIATION EXPOSURE

There are a number of approaches that are necessary in order to decrease radiation exposure, or more specifically, to ensure that *unnecessary* radiation is avoided.

EDUCATION

The primary and the crux of any approach must be education, both of health care workers, and of patients. Without at least a general awareness of radiation risk issues, there is little likelihood either group would include radiation risk into decisions regarding their own, or their patients' care.

This author is currently a final-year radiology resident in Toronto, Ontario, Canada. All radiology residents undergo mandatory, extensive radiology and radiation physics training, which includes radiation-risk education. The topic is

formally tested on the final medical boards exam (in fact, in the United States, one part of the board exams for the American Board of Radiology is specifically focused on radiology-related physics). As medical imaging and related exams and procedures are so pervasive that they are relevant for most all health care workers, this author suggests that all health care workers be given at least some basic education on radiation-risk awareness. This could be in the

form of formal lectures during training, during continuing medical education-style courses and conferences, and in formal publications such as *The Surgical Technologist*.

The best example of an international, large-scale radiation risk awareness initiative is the *Image Gently*SM

campaign by The Alliance for Radiation Safety in Pediatric Imaging, a consortium of professional societies concerned about the amount radiation exposure children receive when undergoing medical imaging procedures (www.pedrad.org).

The campaign has achieved much success in increasing awareness among both health care workers and patients, and continues to increase its reach, influence, and its partners. Although this author may hold an obvious bias as a resident in radiology, it is his opinion that the leadership on radiation risk education and awareness should come from within the field where it is most relevant—radiology. This is certainly the case, as the *Image Gently*SM campaign demonstrates.

INCREASED COMMUNICATION

Communication, or lack thereof, is one potential cause of unnecessary radiation, such as redundant exams.³ Communication includes exchanges between patients and health care workers, as well as among health care workers themselves. For example, if there is a concern that an exam may be redundant due to miscommunication, contact the relevant person and clarify prior to exposing the patient to potentially unnecessary radiation.

PROTOCOL OPTIMIZATION

Depending on the modality and type of exam or procedure, consideration should always be given to decreasing radiation exposure to the patient by optimizing the technique and protocol. This may include the use of shielding and protective garments, and adjustment of specific imaging parameters.

The proper use of protective garments for the personal safety of health care workers is crucial. Whereas patients tend to undergo solitary exams sporadically, occupation-ally-exposed health care workers may have the potential for exposure on a daily or near-daily basis, and therefore, improper protection may lead to very high, systematic, cumulative exposure.

TRACKING/LOGGING EXPOSURE, RADIATION PASSPORT FOR THE IPHONE/IPOD TOUCH

There are several excellent electronic and online resources available that have the potential to both educate patients (such as the *Image Gently*SM campaign and Web site), and now to track radiation exposure and estimate associated risks.

One such resource is an application for the iPhone and iPod Touch that this author co-developed with Tidal Pool Software and his brother, Adrian Baerlocher, called Radiation Passport. Radiation Passport is an application that is

meant to be useful for both health care workers and patients alike. The application serves two primary functions. It can be used to estimate the associated (nonfatal and fatal) cancer risk from a given medical imaging exposure, related exam or procedure for a patient of a given age and gender; and it can also track or log all of the radiation exposures from medical imaging over a patient's lifetime, and estimate the associated cancer risks from that radiation.

The average effective radiation doses associated with the relevant exams and procedures (modality and body part) were obtained by performing an OVID/Medline search of published medical literature (though if known, users can enter custom radiation doses instead for any given exam or procedure). The risk estimates are based on the LNT model used by the BEIR VII committee (linear, non-threshold, cumulative). The risks are customized to the exam or procedure modality, body part, age, and gender of the patient. (See figures 1-4). The application also includes a series of

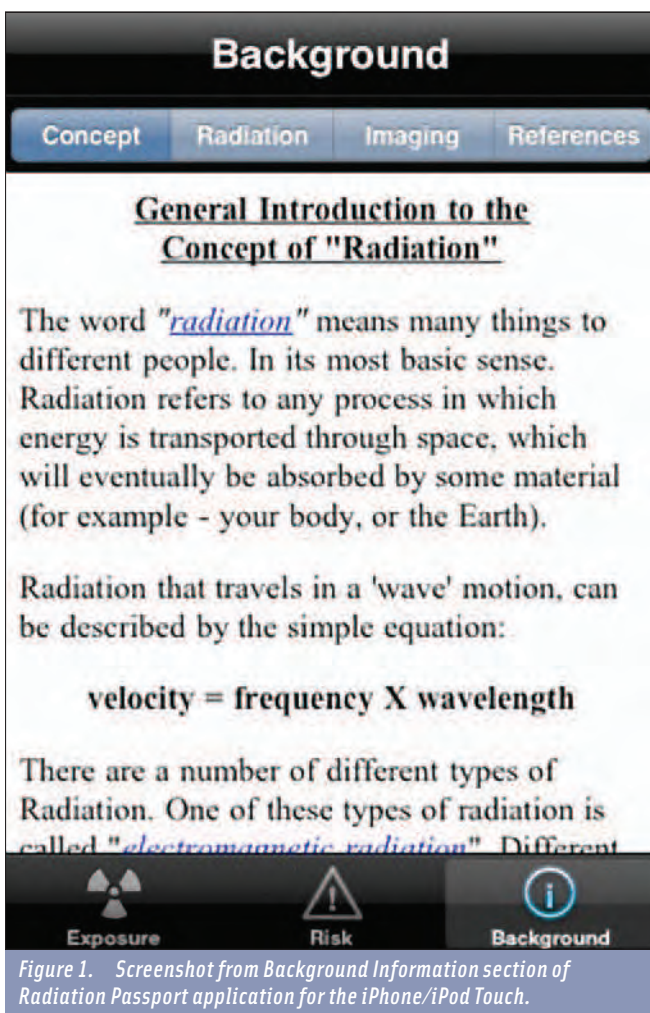


Figure 1. Screenshot from Background Information section of Radiation Passport application for the iPhone/iPod Touch.

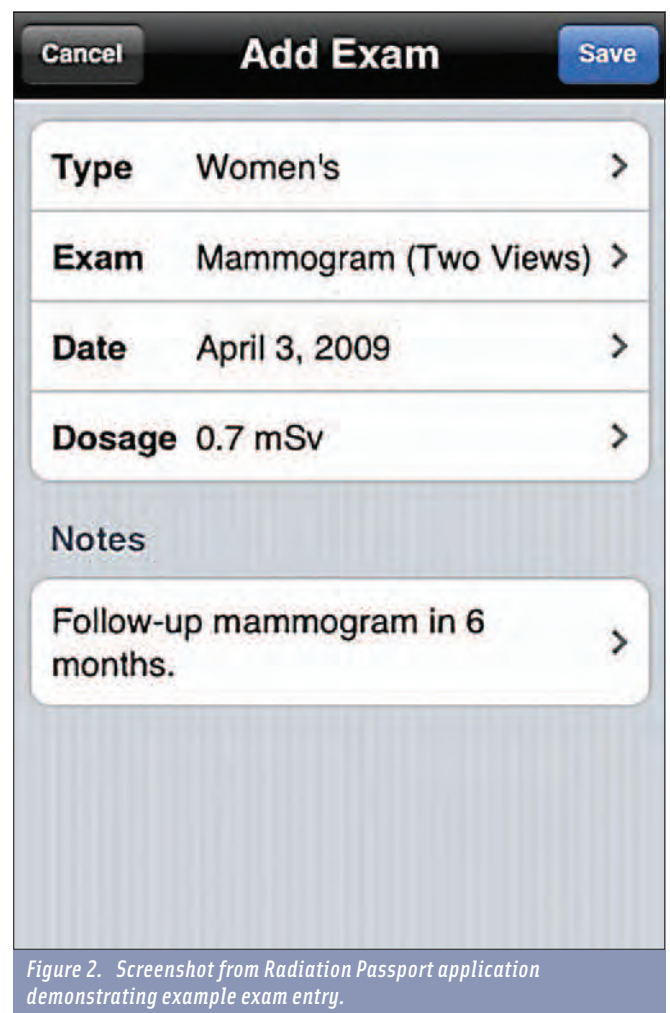


Figure 2. Screenshot from Radiation Passport application demonstrating example exam entry.

The proper use of protective garments for the safety of health care workers is crucial. Where as patients undergo solitary exams sporadically, occupationally-exposed health care workers may have the potential for exposure on a daily or near-daily basis.

SHOULD PATIENTS BE INFORMED OF THE RISKS?

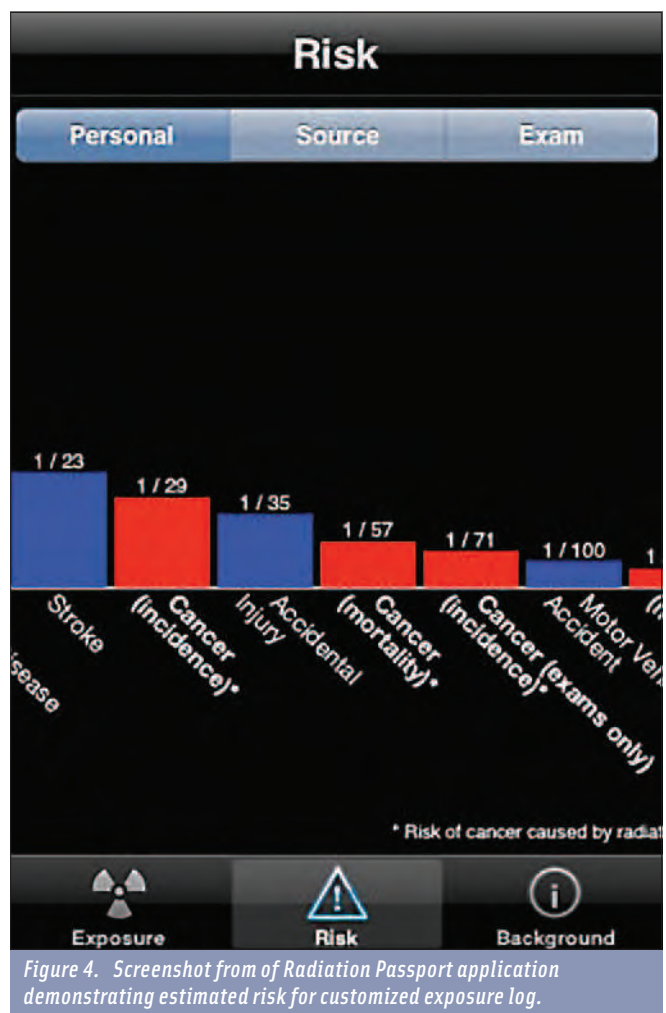
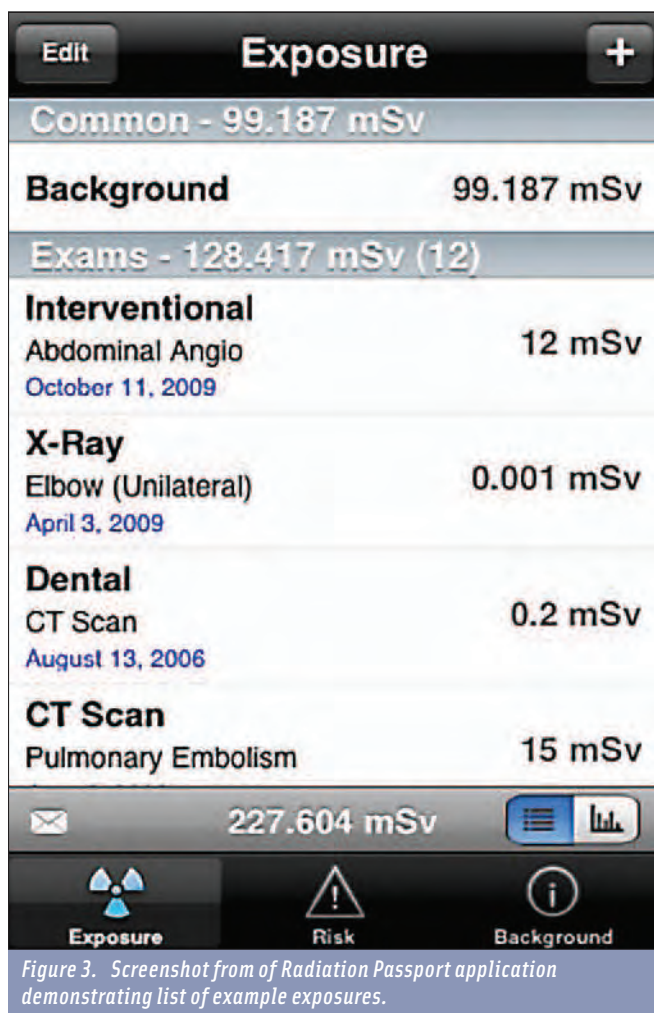
There has been some implied criticism questioning whether or not it is fair to give patients information about the radiation risks, with the worry that they may refuse an exam or procedure based on this information.⁶

This author argues that not only is it fair, but it is necessary for patients to be provided with full disclosure on potential radiation risks. When any given treatment or procedure is prescribed to a patient, it is implied that the risk-benefit equation tips favorably toward the potential benefit side, meaning that the perceived and potential benefits of the treatment or procedure outweigh the perceived and potential risks. Both sides of the equation should be explained to the patient, as well as all feasible options. The patient should be allowed to make the final treatment decision.

questions to estimate background (nonmedical) exposure, as well as an extensive background/information section.

The application is available on Apple's iTunes electronic store. Additional information can be found at <http://www.tidalpool.ca/radiationpassport/>. *

While many countries require mandatory radiation logs for those deemed "radiation workers," most do not require a similar log for patients and other health care workers. This author suggests that it is time that this is considered.



In the case of imaging and imaging-related procedures that utilize ionizing radiation, one of the potential risks is developing associated radiation-induced malignancy, and therefore, patients should be made aware of this information. This author co-authored a study that is currently under review, which demonstrates that 92 percent of patients about to undergo an imaging-related exam or procedure are unaware of any radiation risks. The more information patients are empowered with, the better (though it may be to the chagrin of many health care workers who then have to spend additional time discussing the risks). As a patient, if you are about to undergo a cholecystectomy, you would probably want to be informed of the associated major and relevant risks. This is analogous in this author's opinion, except that the primary risks are of radiation, and potentially contrast reaction, contrast-induced nephropathy (CIN), and extravasation (if relevant).

PREPARE YOURSELF WITH KNOWLEDGE

There is no question that both the diagnostic and treatment abilities of health care workers has been significantly improved with the greater use of more sophisticated imaging and related exams and procedures. However, it also comes with a price—the increasing risk of radiation-induced cancer. The precise balance between use and misuse, as well as more accurate estimates of radiation risks, will surely come under increasing examination in the coming years.

In the meantime, it is the responsibility of those involved with its use to become educated on the topic, both for their own sake, and for the sake of patients. As surgical technologists, you are often the face patients will see coming into and out of their surgery.

ABOUT THE AUTHOR

Mark Otto Baerlocher, MD, is a final-year resident in radiology at the University of Toronto, in Toronto, Ontario, Canada. Following his residency, he will attend the University of California, San Diego for a fellowship in interventional radiology. Dr Baerlocher eventually plans on entering the academic field. If you have questions or feedback, please contact him at mark.baerlocher@utoronto.ca.



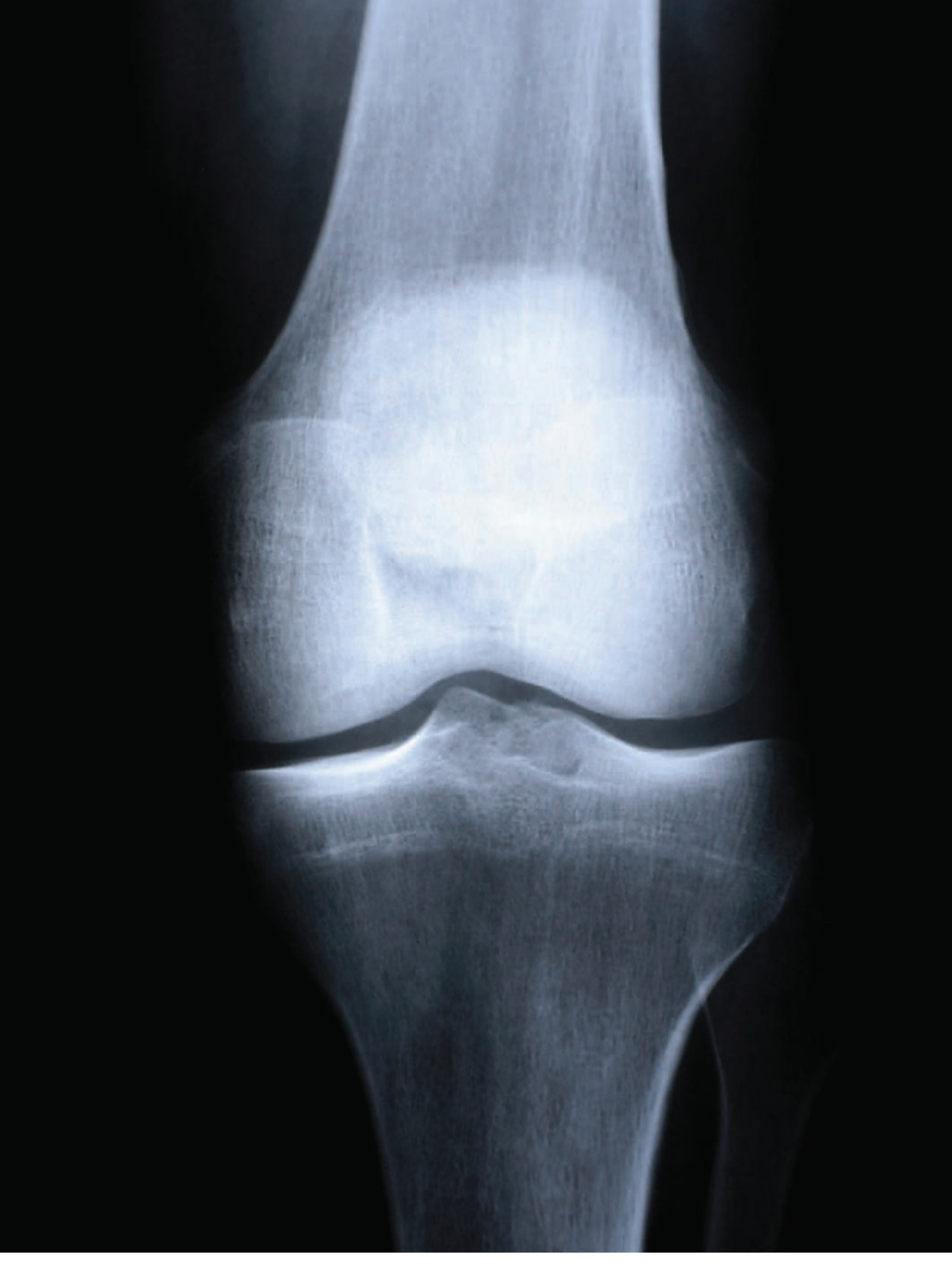
Answer to question at the start of the article:

Approximately risk of nonfatal malignancy to single CT abdomen at 10 mSv for a 25-year old woman: 1 in 1500.

Approximately risk of fatal malignancy to single CT abdomen at 10 mSv for a 25-year old woman: 1 in 750.

References

1. Idaho State University. Radiation Information Network's Radiation Related Terms. 2009. Accessed: 12/8/09. Available at: <http://www.physics.isu.edu/radinf/terms.htm>.
2. Rubin P; Casarett G W. *Clinical Radiation Pathology*. WB Saunders. Philadelphia. 1968.
3. Brenner DJ, Hall EJ. "Computed Tomography—An Increasing Source of Radiation Exposure." *New England Journal of Medicine*. 2007; 357:2277-84.
4. Lee CI; Haims AH; Monico EP; Brink JA; Forman HP. "Diagnostic CT scans: assessment of patient, physician, and radiologist awareness of radiation dose and possible risks." *Radiology*. 2004;231:393-8.
5. Fazel R; Krumholz HM; Wang Y; Ross JS; Chen J; Ting HH; Shah ND; Nasir K; Einstein AJ; Nallamothu BK. "Exposure to low-dose ionizing radiation from medical imaging procedures." *N Engl J Med*. 2009; 361(9):849-57.
6. Mason C. "Tracking radiology's risks." *CMAJ*. 2009; 181(3-4):E5.



Total Knee Arthroplasty

by Linda Bauer, CST

Total knee arthroplasty is one of the most extensive and technically difficult elective surgeries performed today. From the patient's point of view, the decision to have an important joint deliberately obliterated and replaced with manufactured components cannot be an easy one, and is further complicated by considering the potentially-devastating effects of a failed procedure.

For the surgeon, knee replacement presents formidable technical challenges, as careful planning and precise execution are critical in providing the patient with full postoperative function. Planning and precision are central in the surgical technologist's role as well, as instrumentation for this procedure is extensive and highly specialized. The introduction of navigation systems to aid in knee replacement adds another level of complexity for the surgical team, a prospect that can be quite daunting for a new or inexperienced surgical technologist. This article will discuss computer-assisted total knee arthroplasty and present information to help surgical technologists participate effectively in this surgery.

The basic principles of total knee replacement are fairly straight forward. The knee is a hinge joint, in which the distal condylar surface of the femur articulates with the proximal surface of the tibia. This articulation is maintained by a system of strong ligaments, and the joint is protected by the patella bone, which is held in place by thick tendons. Injury, age and arthritic changes can contribute to deterioration of the joint surfaces, resulting in significant pain and loss of function. The surgery

LEARNING OBJECTIVES

- ▲ Compare and Contrast the standard and navigation knee replacement systems
- ▲ Evaluate the benefits of the imageless navigation system
- ▲ Analyze the step-by-step process of the total knee procedure using an imageless navigation system
- ▲ Explore the history and development of the total knee procedure

involves the removal of the ends of the femur and tibia by means of a series of chamfered saw cuts, and the addition of artificial joint components to both bones, as well as to the inner surface of the patella.

The success of the total knee procedure depends on many factors, including patient selection, prosthesis design, the preoperative condition of the joint, surgical technique (including soft tissue balancing and limb alignment) and postoperative rehabilitation.

The success of the total knee procedure depends on many factors, including patient selection, prosthesis design, the preoperative condition of the joint, surgical technique (including soft tissue balancing and limb alignment) and postoperative rehabilitation.

HISTORY AND DEVELOPMENT

Total knee replacement has advanced considerably since the first attempts more than a century ago, when Theophilus Gluck designed and implanted a total knee made of ivory, stabilizing the implants with plaster of paris and colophony (a translucent, brittle substance produced from pine oleo resin, which is used in varnishes and inks).¹ Gluck's total knee failed for a variety of reasons, including poor bearing surface, improper fixation, and frequent infections. With many improvements, the Walldius hinge was introduced in 1951. Made of acrylic, and later upgraded to cobalt chromium (CO-CR) in 1958, this implant was used until the early 1970s. In 1968, Frank H Gunston, MD, a Canadian surgeon, designed the first polycentric knee.¹ Two basic flaws in his design limited its success: it did not replace all the condylar surfaces, and it had a small contact area. This polycentric knee was made of stainless steel and only replaced the weight-bearing part of the knee, which is not a true condylar knee. A narrow, polycentric metal replaced the weight-bearing part of the condyles, and the tibia was replaced with narrow, plastic runners. This allowed for minimal rota-

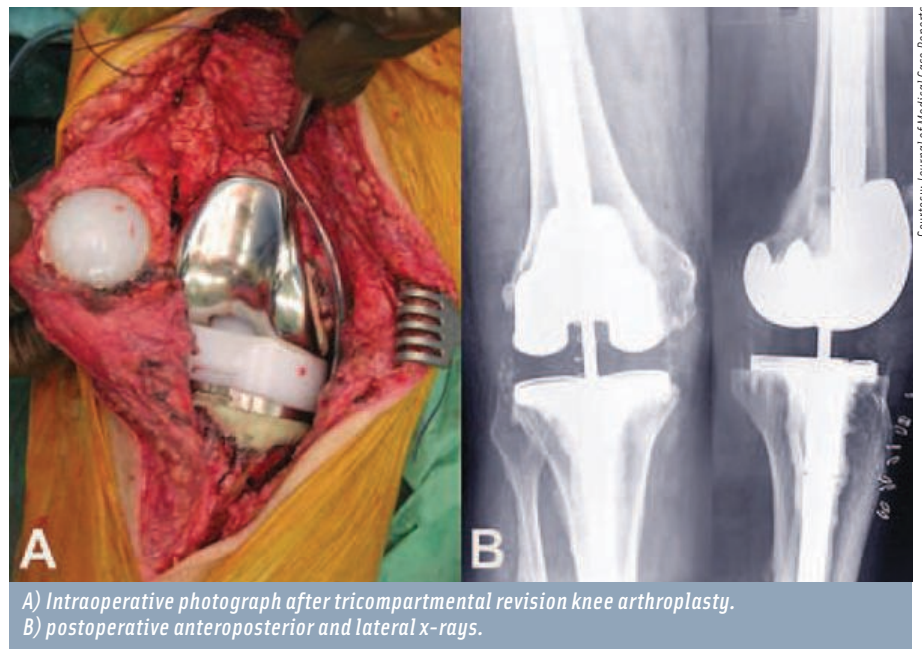
tion. Consequently, these components loosened after a while, which resulted in failure of this polycentric knee.

By the 1970s, the race was on to create the perfect condylar knee. Between 1970-73, three implants were developed independently.¹ In New York, Walker, Ranawet and Insall came up with their version. At the same time, Coventry and Turner introduced the geometric prosthesis, and Towley, from Huron, Mich, came up with the anatomic knee. There were two common threads that each of these

prostheses had. One was preserving the cruciates to ensure stability, and the other was using polymethylmethacrylate cement for fixation. The geometric knee had rotational constraint resulting in a high failure rate and was later discontinued. The anatomic knee replaced the troclear surfaces. This requires minimal removal of tibia and femur bone and allows the preserva-

tion of both cruciates. Failure occurred because of a thin tibia component and lack of fixation. As a result, the anatomic knee was also discontinued.

In 1971, Freeman and Swanson began using the Imperial College London Hospital (ICLH) knee.² It relied completely upon component geometry and soft-tissue balance to provide stability with both cruciate ligaments being sacrificed. This procedure was practiced until 1975. A study of complications and failures showed that an acceptable outcome



A) Intraoperative photograph after tricompartmental revision knee arthroplasty.
B) postoperative anteroposterior and lateral x-rays.

Courtesy: Journal of Medical Case Reports

could not be achieved reliably. The tibial components tended to sink and loosen and patella pain was persistent and sometimes resulted in a patellectomy (removal of the patella bone).² In addition, the poly surface of the tibia showed surface damage, which was attributed to the cement being left in the posterior compartment of the knee. Last but not least, alignment of the knee and the control of instability could not be achieved accurately and reliably by the eye.²

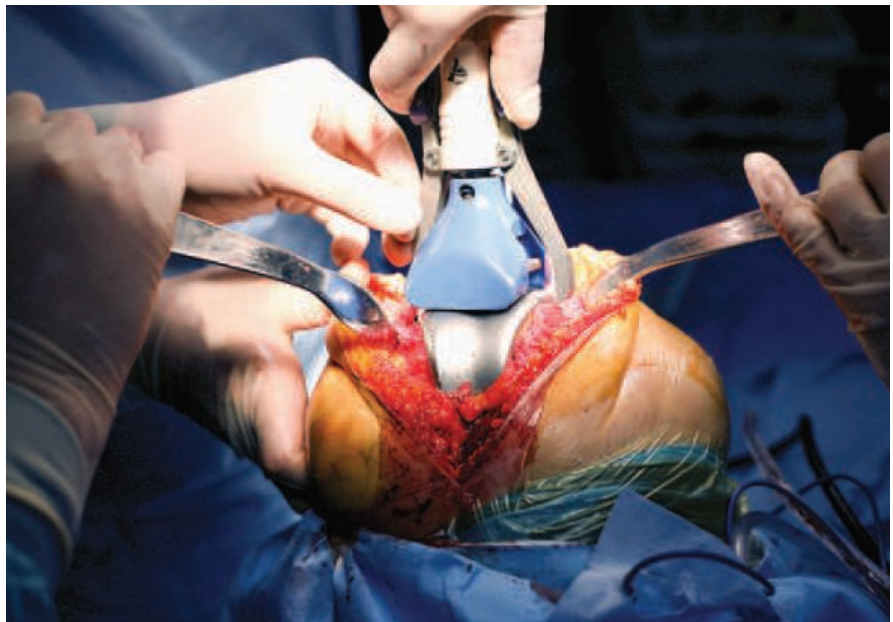
Over the next several years, many designs were attempted without success. Optimal material for the prosthesis had not been found, and stability could not be reliably maintained. In 1978, Johns Hopkins introduced the concept of universal instrumentation,¹ regardless of manufacturer. By the 1980s and 90s, most of the condylar designs incorporated universal instrumentation. Additional improvements in condylar design allowed better fixation with and without cement, reducing wear, enhanced kinematics and increased range of motion.¹

SURGICAL NAVIGATION SYSTEMS

Surgical navigation was developed to help reduce errors in component alignment during total knee arthroplasty³ and to help surgeons install implants more accurately and reproducibly. Navigation systems also record quantitative information, such as joint range-of-motion, laxity, and kinematics, intraoperatively.³

Computer-assisted surgical systems have been developed for procedures such as total hip replacement, anterior cruciate ligament reconstruction, high tibial osteotomy, revision total knee arthroplasty, and many others. The earliest and most complex were active robotic systems, in which the robot performed surgical tasks, such as drilling, without the direct intervention of the surgeon.³ This robotic system was not widely used because of the cost and complexity.

Semi-active systems do not perform surgical tasks, but may limit placement of surgical tools. With this system, the surgeon first indicates the desired position and orientation of the femoral prosthetic component on a three-dimensional digitizing template. The robot then positions the saw and drill guides so that the surgeon can make the necessary cuts and holes.³



The passive system receives information such as cut plane orientation and limb alignment that is displayed on a computer monitor in the operating room. Preoperative image systems rely on models derived from CT images, or by morphing a generic model to match the bony geometry of a particular patient.

This article focuses on the imageless navigation system by Stryker.

IMAGELESS NAVIGATION SYSTEMS

Imageless systems collect information needed for navigation through direct measurement of bony landmarks, or through kinematic algorithms to determine joint centers.³ Stryker entered the surgical navigation market in 2000, and introduced imageless navigation to orthopedics in 2001. The imageless system does not require preoperative CT or MRI scans. This navigation system is an interactive operative monitoring system designed to improve the surgical performance and clinical outcome of knee replacement surgery. As a PC-based imageless guidance system, the knee navigation system helps to facilitate improved decision-making for alignment and orientation of instruments, trials and implants as well as for balancing soft tissue.⁴ It has an open platform, which means that it has dedicated instruments that are compatible with different implant systems. With the imageless system, the medical team can use either Articular Mounted Surface (ASM) or Precision 4.0. Precision 4.0 can be used in the manual implant sizing mode or the automatic implant sizing mode, according to surgeon preferences.

To implement the Stryker navigation system, the surgical team will need: a camera, trackers, pointer, cutting jigs and fixation pins.

Navigation systems have a few basic components. An optical tracking system measures the position and orientation of the trackers that are attached to the femur and tibia with bicortical screws or drill points. The pointer digitizes

Surgical navigation was developed to help reduce errors in component alignment during total knee arthroplasty³ and to help surgeons install implants more accurately and reproducibly.

bony landmarks, monitored by a camera that is attached to the computer. The influence of navigation on the alignment is unclear. Surgical complications associated with navigation are very minimal. There is a chance of stress fractures from the tibial and femoral pin sites. Operating time increases slightly using navigation—usually by approximately 10-20 minutes. No long-term studies have proven that navigation improves postoperative functions, kinematics, allows for more rapid recovery or decreases complication rates. Debate exists on the utility of navigation,³ but it can provide valuable feed back during surgery.

Instrumentation and equipment used in navigation is not very different from setting up a regular total knee. The surgical technologist will need all of the regular total knee instruments, omitting a few of the standard jigs and replacing them with the navigation jigs. Whether the surgeon uses ASM or Precision 4.0, determines when and where he or she will put in the fixation pins. This article focuses on Precision 4.0.

The first step is to register the trackers. Lithium batteries are placed into each of the trackers and the pointer. The trackers and pointer are then registered with the computer. This is accomplished by holding the tracker up to the computer and pressing the register button. Then, two Ortholock anchoring devices are placed on the femur and tibia. On the femur, the pins are positioned close to the knee joint. To minimize muscle load, pins are placed with the knee in flexion. On the tibia, the pins can be positioned distal to the tibial tubercle to avoid the patella tendon and collisions with the tibial implant. The Ortholocks will hold the femoral and tibial trackers.

Establishing a patient's mechanical axis is critical to a successful procedure. The mechanical axis runs from the center of the femoral head through the center of the knee, then through the center of the ankle. The mechanical axis is used to determine a patient's correct standing anatomy.

The position of the camera is very important. The camera is brought into alignment with the knee joint so that

all instruments are centered in the working volume, signified by the grey circles on the monitor. The femur is registered next. By digitizing femoral landmarks, the following axes and references are defined: mechanical femur axis, femoral rotation axis, reference for resection level and reference for notching. It is very important to find the hip center, because this is the gene-

sis of all subsequent points. Hip center is the first point that is mapped after determining a patient's mechanical axis, and is accomplished by slowly and smoothly rotating the hip.

Next, the pointer's tip is placed into the sulcus of the medial epicondyle and the pointer's select button is pressed, which registers those points. The pointer is then placed on the most prominent point of the lateral epicondyle and registered. Next, the pointer is placed at the center of the troclear sulcus, anterior toward the distal end of the femoral shaft to determine the femur center. This is essentially where one would place the intramedullary rod when using conventional instrumentation. Next, the pointer is aligned with the most posterior point of the trochlea and the most anterior point of the intercondylar fossa, also referred to as Whiteside's line, and the point is registered. The medial distal condyle is then digitized, along with the lateral distal condyle and anterior cortex. This completes registration of the femur. The next step is to register the tibia.

By digitizing tibial landmarks, the following axes and references are defined: mechanical tibia axis, tibial rotation axis and reference for resection level. The leg is flexed with a retractor being placed behind the tibia, to bring it into view. First, the tibia is registered center, followed by the tibial A/P axis. The pointer is placed midpoint, at the posterior cruciate ligament and the medial third of the tibial tuberosity. Then the medial and lateral compartments are digitized. It is important to determine the most prominent aspect of the medial malleolus and the most prominent aspect of the lateral malleolus and register these points. Upon completion of femur and tibia registration, the surgeon has established

a defined reference system. The digitized reference landmarks and axes are now used to assess the kinematics and calculate the alignment of instruments and bone cuts.

When the surgical procedure is finished, all of the procedure-related information can be saved in the computer. At the surgeon's request, the information can be transferred to a CD and printed on paper. Care of the navigation trackers is very important. They can only be wiped off with an enzymatic cleaner. They cannot be immersed in water. The navigation instruments can be cleaned in the usual manner. The trackers and the navigation instruments can be autoclaved so that they can be ready for the next procedure. The monitor should be wiped down with water and a sponge, as well as a disinfectant, after every case to remove any debris.

CASE STUDY

History

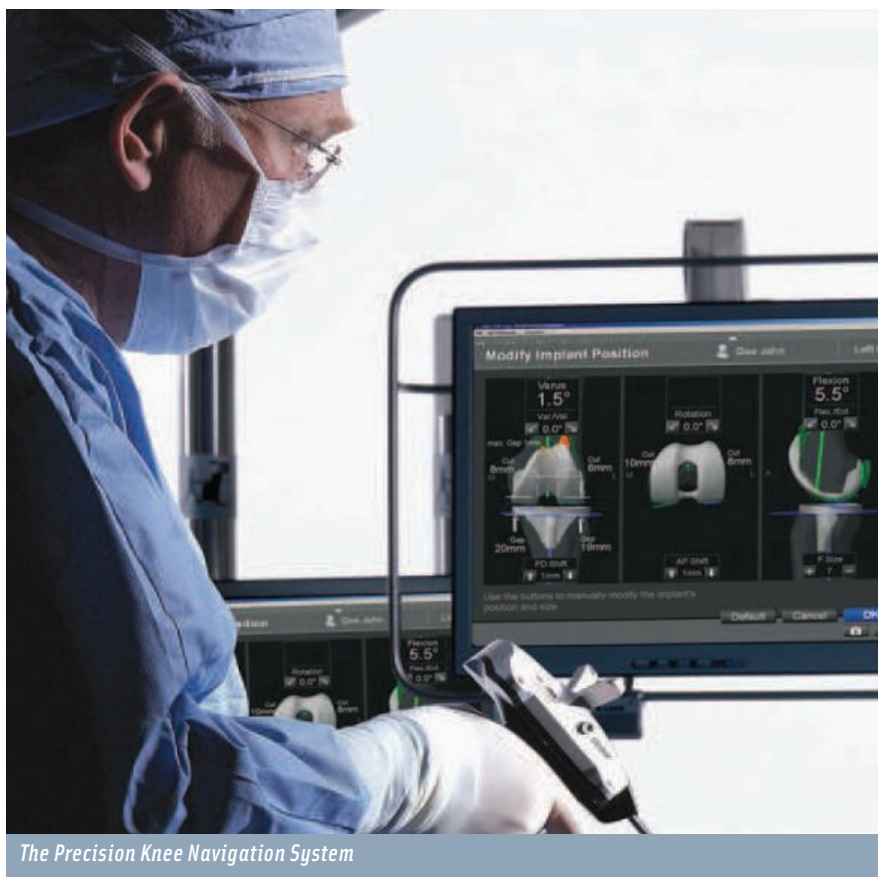The patient is a 53-year old female, who first went to her doctor in 2004, at the age of 46, due to an injury caused by a fall at her work place. She is a runner and very active. After examination, it is concluded that the patient does not have any mechanical symptoms of locking. She has a negative Lachman test and negative pivot shift. She was sent for an MRI, which showed a medial meniscal tear. X-rays show narrowing of the medial joint space, and probable chondromalacia with infusion. At the time of her initial appointment, the patient chose not to treat the tear, she was stable.

Over the next five years, she was treated with numerous steroid shots, due to pain in her knee. Then she was treated with a hyaluronate injection, which involved a series of three injections, two weeks apart. Subsequently, she experienced some relief. After six months, she repeated the hyaluronate injection protocol. In June 2009, she opted for a total knee replacement with 4.0 navigation.

Procedure

After anesthesia is administered, a well-padded tourniquet is placed about the left upper extremity. The patient is prepped with an antimicrobial, antiseptic skin cleanser,

then painted with chlorhexidine gluconate solution and draped in the usual sterile fashion. The extremity is exsanguinated and the tourniquet is inflated to 300 psi, and deflated prior to wound closure. Pins are placed from lateral to medial in the femur and the tibia for navigation. The midline incision is made. Parapatellar arthrotomy is carried out, and in this case, a large amount of clear joint fluid emerged. The joint is exposed and registered with Stryker 4.0. This patient has a very thick, plain white synovial tissue throughout the knee. It is not in fronds, and is more membranous in nature. A synovectomy will be performed at the conclusion of the case.⁵



Having registered the knee, the distal femur is resected 9mm from the high side. Rotation is centered on the average of the transverse epicondylar and A/P axis, which correlates with about three degrees external rotation relative to the posterior transcondylar axis. The patient is then shifted 1.5mm anterior so as not to notch her. Anterior and posterior beveled cuts thus created for a size four Triathlon knee. The tibia is subluxated, meniscal remnants are taken, and the posterior cruciate ligament is preserved. The tibia

is cut zero degrees mechanical axis rotation centered on the juncture of the medial middle third of the tibial tubercle with a four-degree posterior slope. The surgeon resects 1mm below the low point of the low side. Posterior osteophytes are removed. After a medial release, it is determined that the patient balances well with a 13mm insert. With full extension and flexion to 144, the knee is stable throughout a range of motion. The patella is then measured with a caliper. Osteotomy is created at the appropriate level, and resurfaced

Instrumentation and equipment used in navigation is not very different from setting up a regular total knee. The surgical technologist will need the regular total knee instruments, omitting a few of the standard jigs and replacing them with the navigation jigs.

with an asymmetric 9x29 patella. The trial components are removed and copious irrigation is carried out. Cement is packed into dried interstices of the bone and the components are placed. The Stryker Triathlon system is used: a size four femur CR (cruciate retaining), size four tibia, 13mm CR insert and an asymmetric 9x29 patella. Final kinematics are excellent—within one degree of the mechanical axis throughout the full range of motion—and the knee is stable. The tourniquet is deflated.⁵

In this case, the patella tracks well, and does not require lateral release. Copious irrigation is carried out. The wound is injected with a ropivacaine cocktail. A drain is placed in the depths of the wound. The arthrotomy is closed with #1 polyglactin 910, subcutaneous: #2-0 Polyglactin 910, skin running subcuticular poliglecaperone 25, followed by a topical skin adhesive. The patient is placed in a soft-tissue dressing and a cold-therapy unit, and returned to the recovery room in good condition.⁵

The patient spent three days in the hospital. After returning home, she underwent six-eight weeks of physical therapy, consisting of formal physical therapy two times a week, and continued the exercises on the off days. Seven weeks after surgery, the patient returned to work on light duty for two weeks, followed by two weeks of restricted light duty, meaning she could not lift more than 20 pounds. After that, she returned to full duty. After 11 weeks, the patient was doing well, continuing her exercises. The patient reported that after three months, it was the best thing she ever did.

One piece of advice that the patient strongly encourages others to follow is to take the full time off and follow the prescribed protocol exactly. The patient is a surgical technologist, working full time at a hospital in Austin, Texas.

CONCLUSION

Future research and development of navigation systems should address three major challenges in total knee arthroplasty: ensuring consistent postoperative outcomes, treating

younger and more active patients, and enabling less invasive surgery.³ Over the years, the medical field has seen the evolution of joint replacements. The procedures have improved from ivory implants being held in place with plaster of paris, to cobalt chromium (CO-CR) implants and a computer aiding the surgeon in getting just the right fit. The success of the total knee

still depends on many factors, including patient selection, preoperative conditions of the joint, and surgical technique. At the same time, it is such an exciting time for surgical technologists. There are so many exciting opportunities for learning new and more advanced procedures.

ABOUT THE AUTHOR

Linda J Bauer has been a surgical technologist for 32 years, and has been a CST since 1992. She currently works at Seton Medical Center in Austin, Texas, where she is a lead tech and specializes in orthopedics.



References

1. Ranawat C. *SOA Textbook*. "History of Total Knee Replacement." The Southern Orthopaedic Association and Data Trace Publishing Company. 2006.
2. Freeman MAR; Todd RC; Bamert P; Day WH. "ICLH Arthroplasty of the knee: 1968-1977" *The Journal of Bone and Joint Surgery*. 1978;60-B,3:339-344. Also available at: <http://www.jbjs.org.uk/cgi/reprint/60-B/3/339.pdf>.
3. Siston, Robert; Giori, Nicholas; Goodman, Stuart; Delp, Scott. "Surgical navigation for total knee arthroplasty: a perspective." *Journal of Biomechanics*. 2007;40:728-735. Also available at: http://www.mecheng.osu.edu/nmbi/files/nmbi/JoB_2007_ASB_Award_Navigation_Perspective.pdf.
4. Stryker Precision Knee Navigation. Stryker Leibinger GmbH. Available at: http://www.stryker.com/stellent/groups/public/documents/web_prod/056838.pdf
5. Carter, Shelby MD. Surgical notes. www.shelbycartermd.com



Understanding Menorrhagia

TREATMENT WITH OFFICE-BASED ABLATIONS

LaDonna Miller, CST, CFA

Menorrhagia is a condition that many women silently suffer from. Deriving from the Latin word *men + rhegnyai*, meaning to "burst forth," menorrhagia is the condition of prolonged or excessive menstruation.³ Women who lose 80 ml or more of blood during their menstrual cycle, which normally should consist of a 35–45 ml blood loss, experience menorrhagia.¹ Approximately 10 million women in the United States are affected by excessive menstrual flow. In the last few years, however, menorrhagia has become easily manageable.⁵

The first step in resolving menstrual abnormalities is recognizing the problem. Some women have suffered from menorrhagia all their life and do not recognize this as abnormal. Others have a fear of discussing this problem with anyone, including their doctor. These reasons, factored in with the hustle and bustle of everyday life, has left women living in submission to menorrhagia. Women no longer have to be embarrassed by or concede to heavy periods. It is a real condition, not just an inconvenience, with a real name, and real treatment options.

TREATMENT OPTIONS

There are a few different treatment options when it comes to helping relieve the symptoms of menorrhagia. Hormonal methods are the most conservative, and often the first step that most women will try. These include hormone replacement therapy, oral contraceptive pills, and other hormonal contraceptive devices such as the patch or ring. These, in combination with other medical therapies, such as non-steroidal anti-inflammatory drugs (NSAIDs), for some women, will greatly reduce the amount of

LEARNING OBJECTIVES

- ▲ Examine the various treatment options for menorrhagia
- ▲ Compare and contrast the different in-office procedures
- ▲ Assess the challenges that face physicians who offer in-office procedures
- ▲ Explain the process of global endometrial ablation (GEA)

menstrual flow each month. For others, these therapies are not enough to improve their daily life.¹

For women who no longer wish to preserve fertility, global endometrial ablation (GEA) is considered a conservative and effective treatment of menorrhagia. However, it should be noted that GEA is not a sterilization procedure and pregnancy following GEA is contraindicated. GEA is intended to denude the endometrial lining of the uterus and significantly reduce the amount of blood lost during a menstrual cycle. GEA is a less-invasive surgical treatment that requires minimal hospital time and recovery period for the patient. It provides an alternative for women when medical therapies have failed and the definitive treatment for menorrhagia, hysterectomy, is not conducive to the patient's life at the current time.^{2,4}

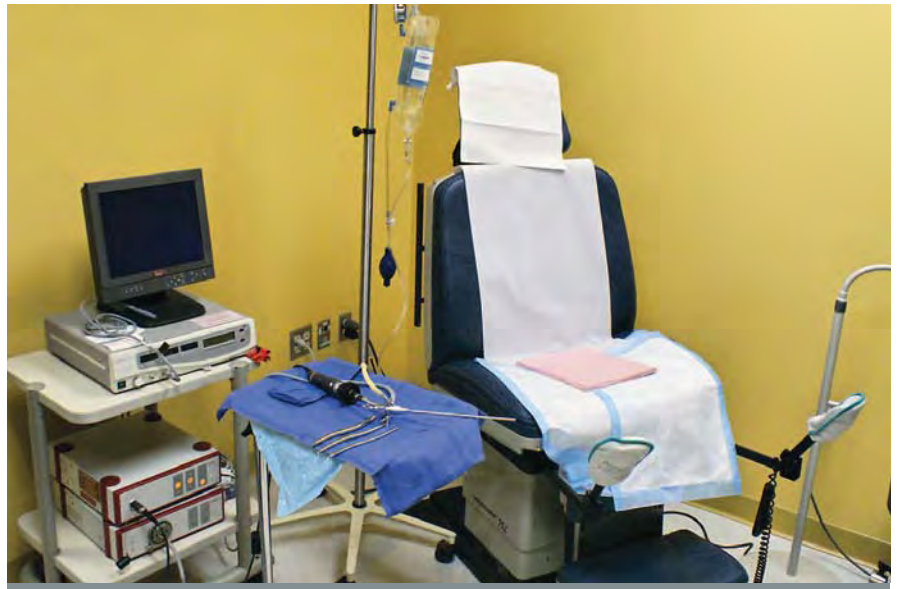Hysterectomy is the most absolute option for the treatment of menorrhagia. By removing the uterus, menorrhagia is cured. However, hysterectomy is not the answer for every woman. Hysterectomy comes with all the risks of major surgery, including higher morbidity, and requires several weeks of recovery. Hysterectomy often requires an

Global endometrial ablation (GEA) is considered a conservative and effective treatment of menorrhagia. However, it should be noted that GEA is not a sterilization procedure and pregnancy following GEA is contraindicated.

invasive abdominal incision, when the GEA can be performed transvaginally. Also, depending upon whether the ovaries need to be removed or not, a woman may need hormone replacement therapy.

GLOBAL ENDOMETRIAL ABLATION (GEA)

There are more than 600,000 hysterectomies performed annually in the United States, 90 percent of them result from benign causes.^{4,6} For that 90 percent, the standard of



This is the complete operative field and office setup. The imaging equipment, bed, IV pole and sterile field are in view.

care is changing. Once these women have completed their families and are ready to give up their fertility, they no longer need to live with menorrhagia. Hysterectomy is the right option for some women, but for most, GEA offers a less invasive approach with optimal results.

Historically, endometrial ablation was a much more complicated procedure. The older techniques, using a Nd:YAG laser and the electrosurgical rollerball, took more than three times longer to perform compared to GEA and were more

dangerous to the patient. Not only was the surgical time increased, but with that came the increase in the amount and type of fluids that were used during hysteroscopy. These factors combined together often led to hyponatremia and fluid overload. These risks, along with several others, paved the path to great advancement in endometrial ablation. The FDA's 1997 approval

of GEA gave patients and physicians a safer option for an alternative to hysterectomy.^{2,4}

ThermaChoice®, a water-filled balloon device, was the first FDA-approved global endometrial ablation device. This was first approved in 1997, and many improvements have helped the product evolve into its current state.

ThermaChoice® uses D5W in the balloon to reach an ideal pressure of 160-170 mmHg. This pressure, combined with the 87 degrees Celsius temperature that the D5W

reaches in the balloon, allows the destruction of the endometrial lining up to 5mm in depth. The procedure takes an ablation time of eight minutes. Safety mechanisms, including the machine shutting off if there is a sudden drop in pressure or if the temperature deviates out of normal range, are in place to make sure ThermaChoice® offers a safe procedure.^{2,4}

NovaSure® has been another form of GEA since its FDA approval in 2001. It is the first bipolar radiofrequency device approved for GEA. NovaSure® is made up of a fan structure layered with copper mesh. First, the bipolar electrode conforms to the contours of the uterine cavity, making sure the proper settings for the cavity length and width are noted. The system then insufflates the uterine cavity with CO₂ to perform the cavity integrity assessment to ensure that no uterine perforation has occurred. The bipolar radiofrequency procedure produces an ionized saline layer that disrupts molecular bonds without using heat. As the energy is transferred to the tissue, ionic dissociation occurs, causing removal of tissue with a thermal effect of 45-85 degrees Celsius. This procedure usually takes about two minutes or less.^{2,4}

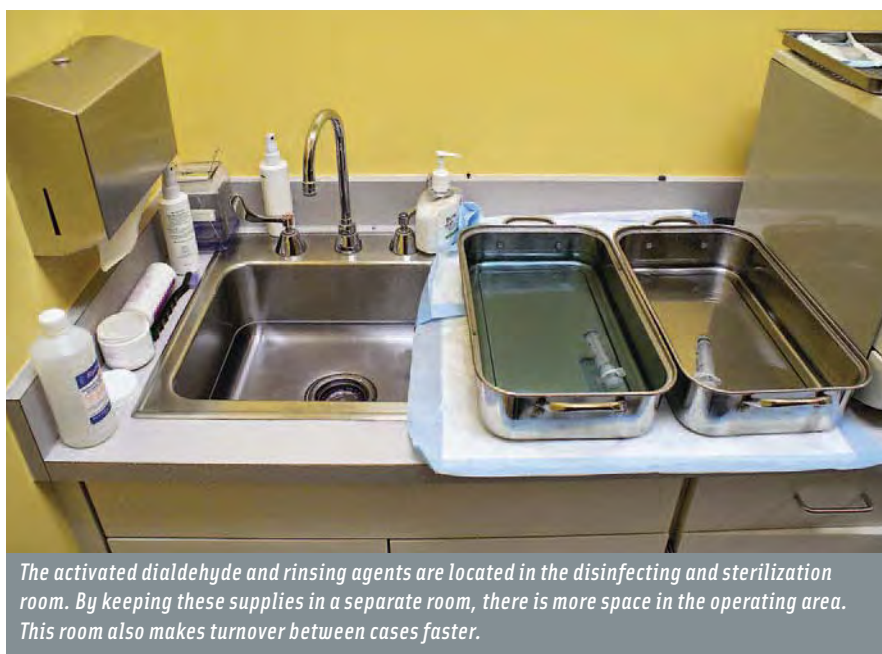
Hydrothermal ablation, or HTA, became the first balloonless hot water system to gain approval by the FDA in 2001. HTA is the only GEA method that allows hysteroscopic visualization as the procedure is performed. The saline is heated externally and reaches a temperature of 90 degrees Celsius. It then is circulated in the uterine cavity, abating the endometrium to about 3-4 mm. This procedure takes around 11 minutes, including the one-minute cool down phase. To maintain safety with this device, the pressure is kept to 55 mmHg to avoid fluid flow through the fallopian tubes. The machine is also able to detect significant fluid loss, which indicates the loss of a cavity seal.^{2,4}

A completely different method of GEA is called Her Option®, a cryosurgical endometrial ablation. Her Option® was the first GEA device that was marketed as an in-office procedure. The use of Her Option® began in 1997, and gained FDA approval in 2001.⁷ The procedure is performed with ultrasound guidance, so visualization is present during the whole procedure. A cryoprobe is cooled by pressurized gas to

-100 to -200 degrees Celsius. This allows for a tissue destruction depth of about 9-12mm. The freezing of the tissue makes the procedure less painful for the patient. This method of producing local anesthesia by localized application of cold is called cryoanesthesia, or refrigeration anesthesia. The entire procedure takes around 10-20 minutes to perform.^{2,4}

IN - OFFICE PROCEDURES

One of the greatest advantages of global endometrial ablation is the ability to perform it in an office setting. Many patients, properly selected, can alleviate their problems with menorrhagia without the complications of general anesthesia. Patients receive anxiolytics, NSAIDs and a



The activated dialdehyde and rinsing agents are located in the disinfecting and sterilization room. By keeping these supplies in a separate room, there is more space in the operating area. This room also makes turnover between cases faster.

paracervical block based on physician's preference, prior to the procedure. This, along with the less-stressful atmosphere of the office, is a perfect combination for an effective, comfortable experience.

Patient selection for office procedures includes criteria such as patient medical history and insurance coverage. The patient must be able to tolerate a mild amount of discomfort. It is also important to make sure to review the patient's history of gynecological procedures to confirm that there will not be any problems that would increase the operative time. Because office-based procedures are reimbursed by insurance companies at a different rate than hospital-based procedures, it is important to confirm that the patient's insurance carrier will reimburse for office-

based procedures. This allows for the equipment and supplies in the office to be adequately covered. Proper history screening and thorough counseling will aid in correct patient selection.

Starting Up

When a physician is contemplating starting to perform office-based ablation procedures, there are many different considerations. He or she must select which GEA device

One of the greatest advantages of global endometrial ablation is the ability to perform it in an office setting. Many patients, properly selected, can alleviate their problems with menorrhagia without the complications of general anesthesia.

will be used, hysteroscope brand and equipment, and what personnel will be helping to get the business started. Many supply companies offer incentives for choosing their product and they may aid in the equipment and device selection. (See the sidebar at the end of this article for more details.) One vital component in making the process a success is having a competent, well-trained, patient-friendly staff. It is also important for the doctor to have a surgical technologist who understands the importance of sterility and has knowledge of scope care. This will prevent the physician from having to worry about proper sterilization and any unnecessary equipment repairs.

Preoperatively

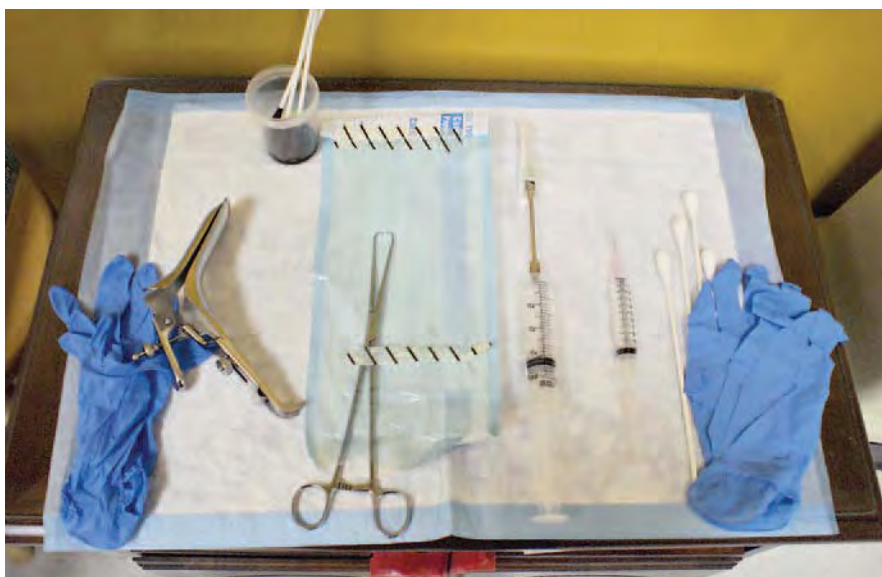For an office-based surgical technologist, the main role in in-office procedures is to ensure all the necessary equipment and supplies are available, cleaned, and sterilized correctly. Prior to the procedure, the tower containing the monitor, light and camera box needs to be turned on and pretested to make sure it is functioning without a glitch. The camera and light cord need to be disinfected and plugged into the tower. After it is determined that the

equipment is in working order, the scope and its accessories needs to be taken to the designated disinfecting station and prepared for sterilization.

The best method of sterilization for scopes in office is activated dialdehyde, which allows a quick and effective sterilization method with the least amount of damage to your scope. The hysteroscope is a big investment, and is very vulnerable to damage if handled improperly. Therefore, it is in the best interest of the physician to have it

handled by someone with knowledge of its parts and handling care. Once the scope is in the activated dialdehyde (between 12–20 minutes, depending on the type—be sure to consult the manufacturer's instructions), a nonsterile working surface containing an open-sided speculum, single-tooth tenaculum, betadine swabs, and anesthetic of choice, will

be placed in an accessible location for the surgical technologist and surgeon. Once the nonsterile field is established, a sterile area needs to be created. A Mayo stand covered with a sterile impervious drape and towels is ideal. The Mayo stand will hold the scope, white balanced and ready to go, and cervical dilators. Right before the patient comes to the room, a pre-warmed bag of normal saline needs to be hung on an IV pole in a pressure bag and hooked up to the irrigating system.



This is the nonsterile working table. This is the portion of the procedure where the physician injects the local anesthetic.

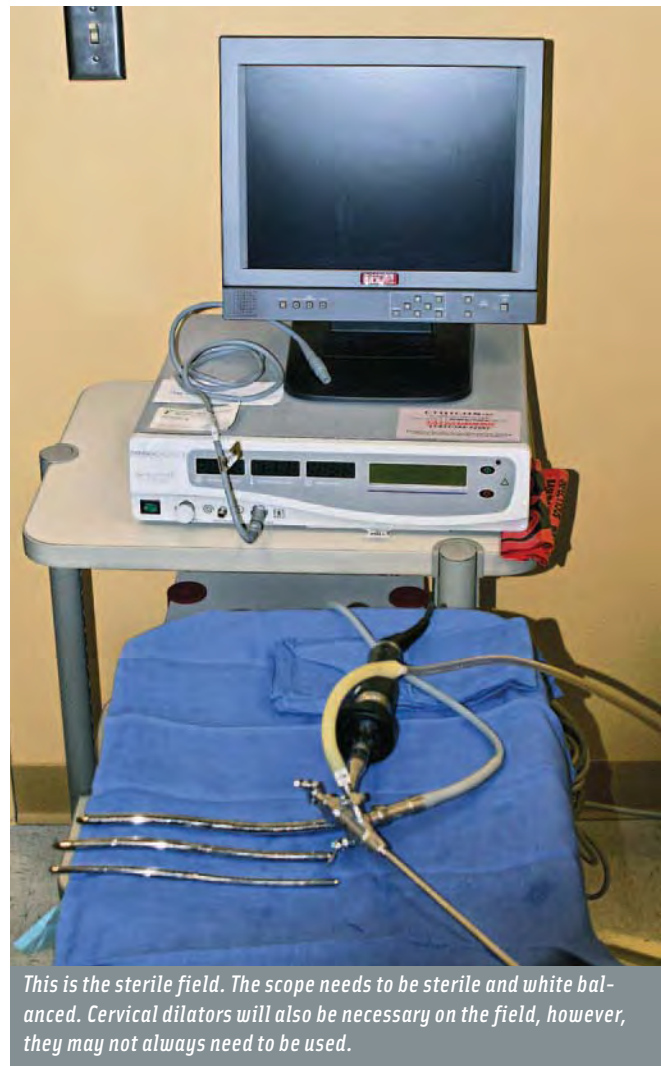Once the patient comes to the room, it is the surgical technologist's job to make sure the surgeon has exactly what he or she needs, when it is needed, but also, and more importantly, help provide a stress-free, comfortable procedure for the patient. Having everything ready and available and not having to interrupt the continuity of care is important to the patient's trust in the procedure.

First, the prepping and paracervical block will be performed. The paracervical block consists of a series of injections with a local anesthetic chosen by the physician. Once the block is given, it needs time to set up. During this time, the patient's comfort is most important. Starting conversation about family or work and answering any additional questions the patient has about the procedure is a great way to help pass time and allow the block to become effective. The block is performed as a clean procedure and does not require sterile technique.

Intraoperatively

The procedure is now ready to begin with a quick look into the uterus with a hysteroscope to make sure there are not any anatomical anomalies that would prevent the procedure from being performed. Most of the time, the cervix does not need to be dilated with instruments, but can be hydrodilated with the hysteroscope. Hydrodilation reduces the amount of discomfort for the patient if it is possible, but sometimes due to prior procedures on the cervix or lack of vaginal births, cervical dilators are necessary. Once the cavity is inspected, the GEA device can be opened onto the field and the ablation can proceed. The amount of time it takes, once again, is dependent on the device. Most patients will experience some mild cramping during the procedure, but it will subside the moment the ablation is stopped and the device removed.

When the GEA is finished, the patient will be cleaned up and allowed time to make sure they feel well enough to leave and given proper home instructions. Recovery time for each patient will vary according to how they tolerate the procedure and how the preoperative medications affect them. Most patients will go home and sleep for a couple of hours and wake up to experiencing some mild menstrual-like cramps. The physician instructions should include a medication protocol along with other methods, such as a heating pad, to help alleviate the patient's discomfort. The next day, most patients resume normal activities, excluding any vaginal activity such as tub baths or intercourse. The patient can expect a few weeks of vaginal discharge.



A patient's results can range from complete elimination of menstruation to no change at all. The size of the patient's uterine cavity, depth of the endometrial lining and accuracy in the performing of the procedure all affect the outcome. Most patients will experience a significant reduction in their menstrual cycle and this is the primary goal with global endometrial ablation.

CONCLUSION

The FDA approval of global endometrial ablation in 2001, brought a new light to women's health. Women no longer have to live with the embarrassment and hassle of menorrhagia or the fear of having major surgery. GEA is a minimally-invasive procedure with great results for most women. Not only can women alleviate or reduce their menstrual flow, but they can do it in the comfort of their doctor's office.

As GEA opened the door for better treatments in women's health, it also opened a door to more career choices for surgical technologists. The office-based procedure provides a different route of employment for surgically-trained personnel. It allows a less stressful job setting with the addition of awake-patient care. It enhances

As GEA opened the door for better treatments in women's health, it also opened a door to more career choices for surgical technologists. The office-based procedure provides a different route of employment for surgically-trained personnel.

one's ability to prioritize and effectively communicate with co-workers and patients. GEA and office-based procedures can be a great supplementary income and addition to current employment, or it can be a pathway to a part-time job opportunity. Whatever the case may be, the flow of health care changes everyday and surgical technologists must be prepared to go with it. By increasing the depth of knowledge and adding to the list of job skills, the surgical technologist becomes more marketable to the medical community.

ABOUT THE AUTHOR

LaDonna Miller, CST, CFA, is employed by OB/GYN of Paducah, in Paducah, Kentucky, as a surgical assistant. OB/GYN of Paducah specializes in da Vinci robotic hyster-



ectomies, pelvic prolapse procedures, office-based uterine ablations and office-based hysteroscopic tubal sterilization. Mrs Miller has been a surgical technologist for nearly 10 years and a certified first assistant since September 2007. She is a member of AST and ASA, and resides in Paducah, Kentucky with her husband and three children.

References

1. Jurema M; Zacur H. 2008. *Menorrhagia*. Barbieri, R (Ed). Accessed: June 2009. Available at: <http://utdol.com>.
2. Lipscomb G. 2008. Endometrial Ablation. *Global Library of Women's Medicine*, ISSN: 1756-228, DOI 10.3843/GLOWM.10024. Accessed: June 2009. Available at: <http://glowm.com/index.html>.
3. *Mosby's Medical Dictionary*. 2009. Accessed: June 2009. Available at: <http://medical-dictionary.thefreedictionary.com>.
4. Isaacson, K. 2002. Endometrial Ablation: a look at the newest global procedures. *OBG MANAGEMENT*. Vol 14, No 2. Accessed: June 2009. Available at: <http://obgmanagement.com>.
5. *Menorrhagia: Extreme periods can be treated*. 2008. Accessed: June 11, 2009. Available at: <http://www.sheknows.com>.
6. Falcone T; Cogan-Levy, S. 2009. *Overview of Hysterectomy*. Mann, W (Ed). Accessed: June 2009. Available at: <http://utdol.com>.
7. *American Medical Systems' Her Option® Office Cryoablation Effectiveness to Be Presented at Upcoming AAGL Congress*. 2007. Accessed: November 6, 2009. Available at: <http://www.redorbit.com/news>.

ThermaChoice® is a registered trademark of Johnson & Johnson.

NovaSure® is a registered trademark of Hologic, Inc.

Her® Option is a registered trademark of American Medical Systems.

A Physician's Perspective

When a physician decides to begin in office procedures, whether it is global endometrial ablation or hysteroscopic tubal sterilization, several considerations must be made. First, one must decide what type of ablation technique he or she wants to use. All have advantages and disadvantages, so it really comes down to the physician's preference. Being comfortable with the procedure avoids the cumbersome nature of learning a new technique while the patient is aware of her surroundings. Most companies have programs available where there is minimal capital investment in terms of purchase of the generator. Some generators are given to the physician after the purchase of a minimal number of disposable devices; whereas others have programs where one commits to a monthly minimal purchase for a year and the generator is provided at no extra cost.

Next, the physician must choose the hysteroscopic equipment. Most companies have similar products and competitive prices. This is usually the largest capital expense and it is important that the service of the equipment is researched prior to the purchase. In other words, one should "buy the company," not the equipment. Most major companies have representatives who are willing to come to the office and demo their equipment for a couple of days at no charge. With several companies vying for business, one can essentially do a significant number of cases, test drive several systems, and do so at no expense. Obviously, scope, light source, camera and monitor are recommended. A printer can be added for documentation purposes at the physician's discretion.

There are multiple advantages to performing in-office procedures. However, the physician must do some research prior to the implementation of this service. One must look at his/her payer mix and determine if there are enough opportunities for this to be financially feasible, as not all insurance companies will reimburse the amount needed to justify the expense of the procedure.

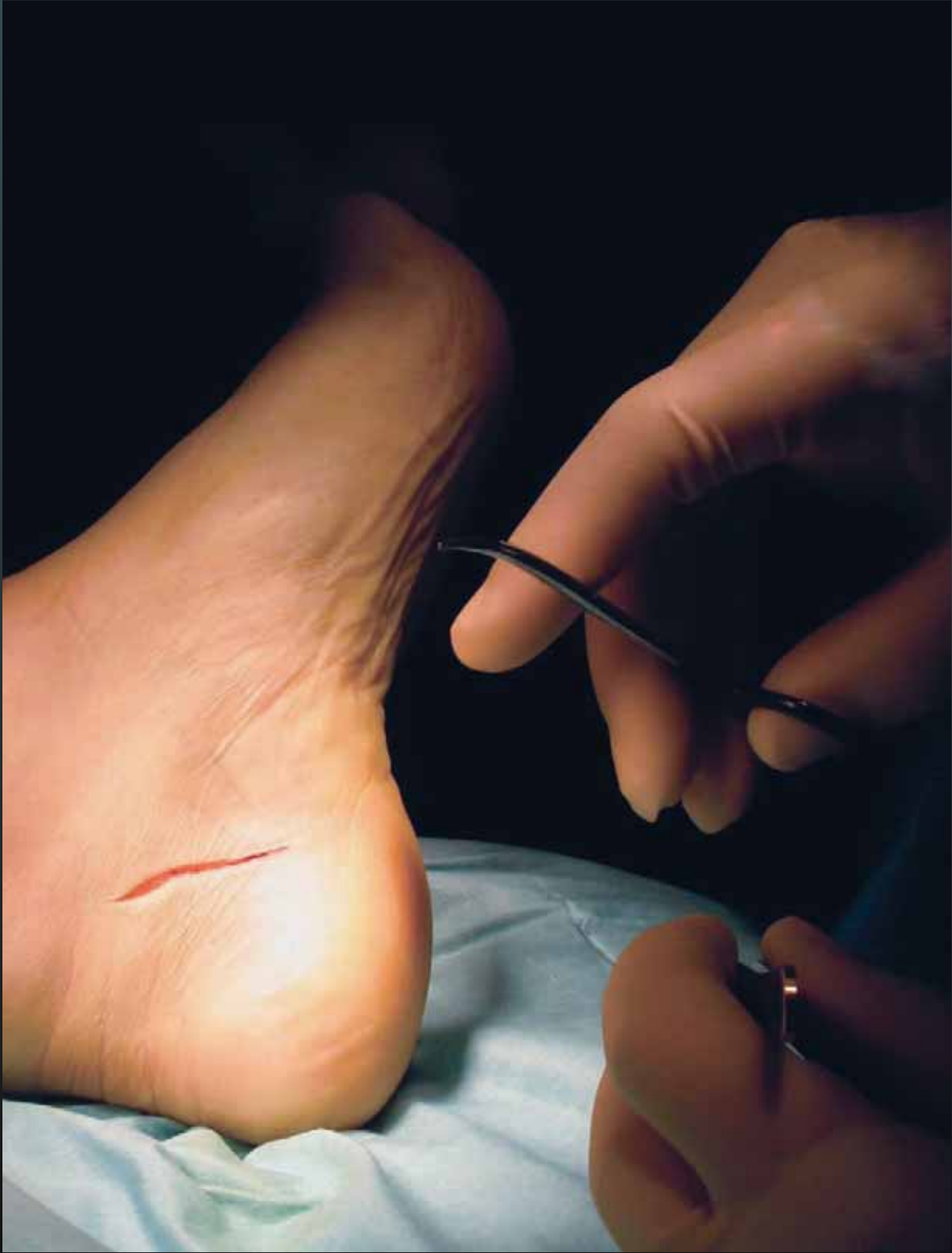There are multiple advantages to performing in-office procedures. However, the physician must do some research prior to the implementation of this service. One must look at his/her payer mix and determine if there are enough opportunities for this to be financially feasible

If the payer mix can sustain the business, this is a service that one will be surprised at how many patients prefer the in-office atmosphere for treatment of menorrhagia or for sterilization procedures.

In the office, the staff must be able to put the patient at ease. After all, that is

what the office employees provide, from answering phone calls, to giving test results, or simply a shoulder to cry on. However, oftentimes, one does not have a staff member that is efficient and qualified to care for the costly investment when it comes to handling the hysteroscope. One of the advantages of having a Certified Surgical Technologist with operating room experience on staff is that he or she provides that extra comfort. He or she can efficiently perform all the duties that may exceed the expertise provided by other office staff members. These duties include maintenance of the equipment, careful handling of the equipment, "turning over" your procedure room efficiently, respect for the sterile field, and assistance in trouble shooting the optics or the ablation equipment.

In closing, office based procedures allow the gynecologist an opportunity to increase reimbursement in an environment that is welcomed by patients. In addition, one can avoid the risks of general anesthesia by safely performing the same procedure with minimal medications.



Acquired Adult *Flatfoot Deformity*

by Angel Webb, CST

Pes Planus, or flat foot, refers to the postural appearance of the foot. This condition can be acquired or congenital. This article discusses acquired cases in which there is a change in shape and position of the back and mid portions of the foot.

Although, 10-25 percent of the population have varying degrees of flatfoot, very few are symptomatic. Those that are symptomatic may complain of painful swelling posterior to the medial malleolus that may extend into the medial arch. They may also, variably, complain of foot, ankle or lateral hindfoot pain.

ANATOMY

A review of relevant anatomy will help in understanding this topic. The subtalar joint is the articulation of the calcaneus and the talus, with the talus superior to the calcaneus. The talonavicular joint is between the talus and the navicular, and is located on the dorsal foot, just below the ankle. The calcaneocuboid joint consists of the calcaneus and the cuboid. It is located on the anterolateral midfoot (Figure 1). The medial longitudinal arch consists of the calcaneus, talus and navicular, as well as the middle, medial and lateral cuneiforms and the first through third metatarsals. The posterior tibial tendon passes behind the medial malleolus and attaches on the navicular tuberosity (bump on the inside of the instep). The flexor digitorum longus tendon is

LEARNING OBJECTIVES

- ▲ Review the relevant anatomy for this procedure.
- ▲ Examine the step-by-step process of FDL transfer.
- ▲ Compare and contrast the benefits and risks of motion-sparing procedures to arthrodesis.
- ▲ Assess the surgical alternatives and additions to FDL transfer.
- ▲ Evaluate the rehabilitation process after flatfoot surgery.

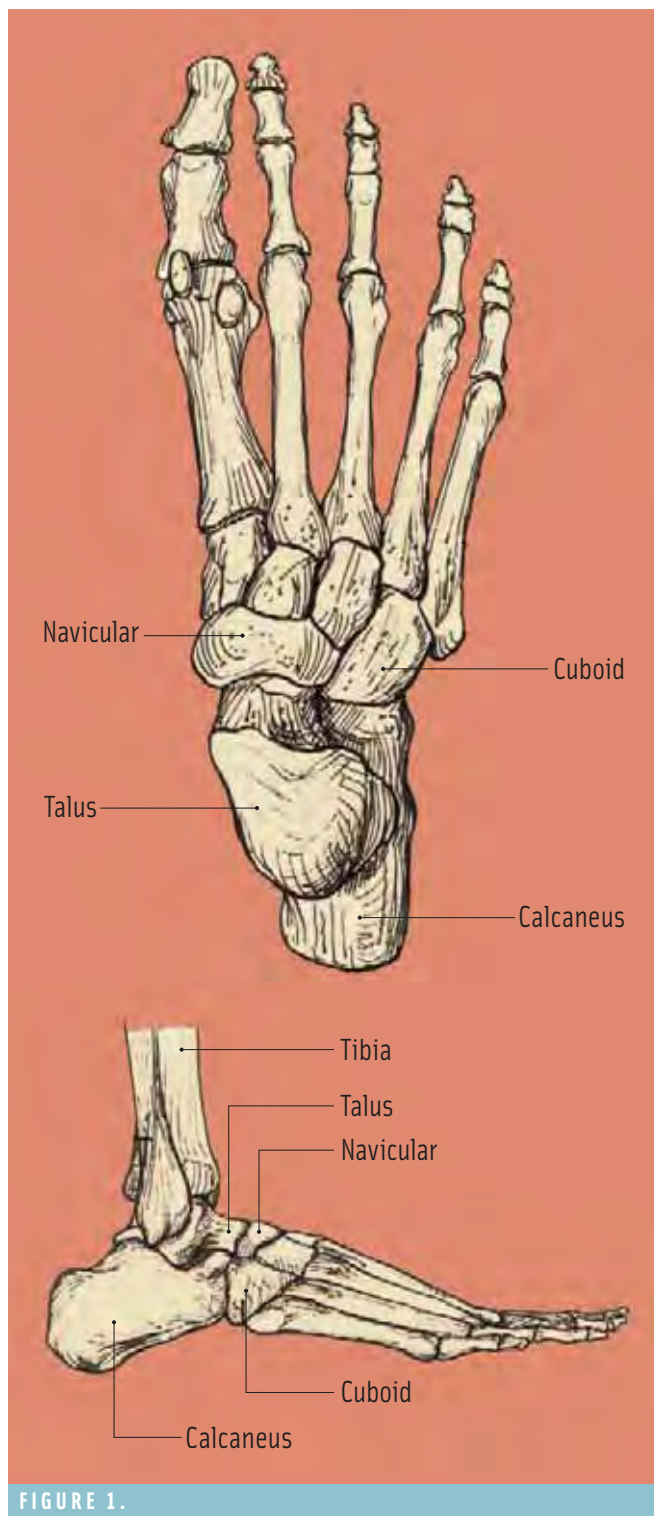


FIGURE 1.

Delmar Cengage Learning

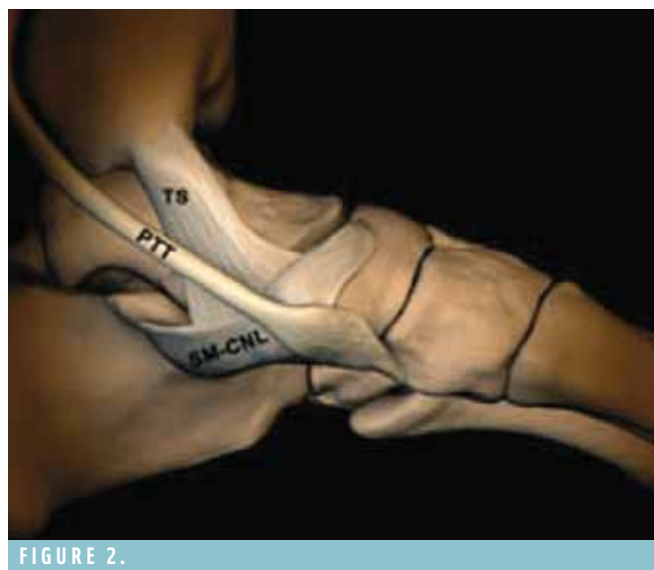

FIGURE 2.

Courtesy of Michael Stanek, MS, RadiSource

just behind and adjacent to the posterior tibial tendon. The spring ligament helps to hold up the arch by forming a supportive sling under the head of the talus (Figure 2).

The most common cause of adult-acquired flatfoot is posterior tibial tendon dysfunction (PTTD). The abnormalities of the posterior tibial tendon are divided into stages. In stage one, there is tendonitis or inflammation, but the tendon is of normal length and not torn. In stage two, the tendon is elongated, but the hindfoot remains flexible. The arch of the foot may appear normal in non-weight-bearing position. In weight-bearing positions, however, the arch appears flattened and the heel moves to the outside (valgus deformity). In stage three, the hindfoot deformity of stage two becomes rigid or “fixed.” The hindfoot is everted (valgus) and the forefoot is abducted (pointing to the outside).

SURGICAL CONSIDERATIONS

Surgical procedures for correction of the flatfoot vary, but can include: medial displacement osteotomy of the calcaneus and transfer of the flexor digitorum longus (FDL) tendon to replace the posterior tibial tendon; spring ligament reconstruction; subtalar arthrodesis; and triple arthrodesis (fusion).

Indications for medial displacement osteotomy of the calcaneus, and substitution of the posterior tibial tendon using the flexor digitorum longus (FDL), are painful PTTD stage two and a flexible flatfoot deformity. Combining the osteotomy with the transfer of the FDL is useful in improving the posture of the foot and gives some mechanical protection to the tendon transfer.

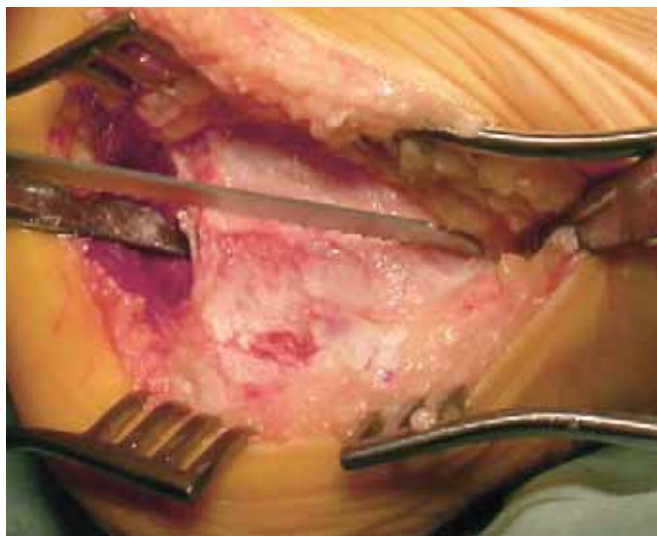


FIGURE 3.

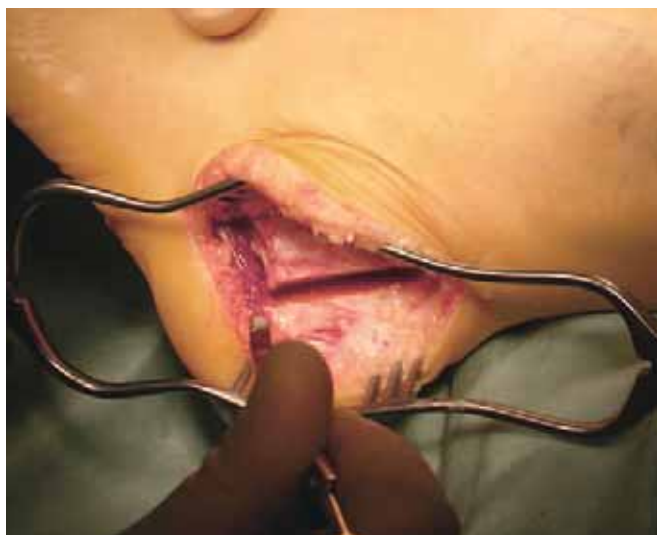

FIGURE 4.

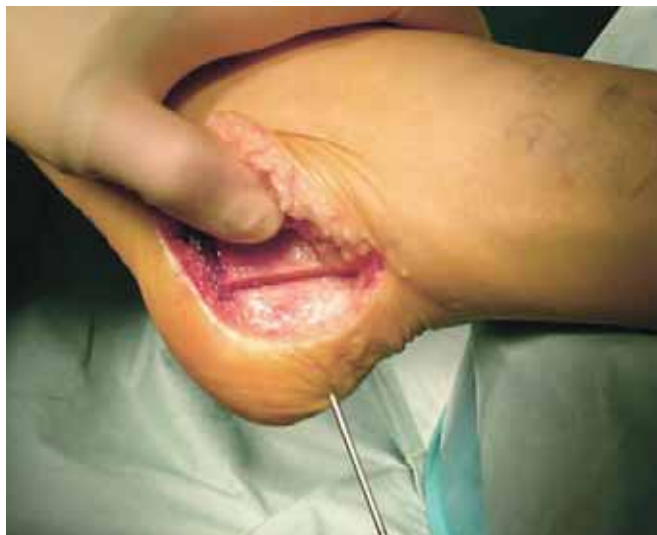

FIGURE 5.

Preoperative preparation includes weight-bearing radiographs consisting of anteroposterior, lateral, and oblique views of the foot. On the lateral view, a sagging of the talonavicular joint may be seen. On the anteroposterior view, an abduction of the foot with increased exposure of the talar head can be seen. It looks like a hat (navicular) is falling off of someone's head (talar head).

PROCEDURE

For the procedure, the patient is placed in the supine position on the operating table with two or three rolled sheets (a "bump") under the ipsilateral hip so that the affected side is internally rotated. A thigh tourniquet is applied.

The skin prep is performed and the operative leg is draped to just below the knee. The operative limb is exsanguinated and the tourniquet is inflated. The skin over the lateral heel is incised obliquely parallel and inferior to the peroneal tendons. Dissection is carried down to the bony surface of the calcaneus. The sural nerve is identified and retracted. A sagittal saw is used to create the osteotomy using care not to over-penetrate to the medial side to avoid injury to the neurovascular bundle. The calcaneal tubercle (back of heel bone) is displaced medially about one cm (Figures 3 & 4). The position can be temporarily held with a 0.062 Kirschner wire. A posterior longitudinal incision is made over the heel. A hemostat is used to enlarge the opening to accommodate the fixation screws, which may be solid or cannulated. If cannulated, the guide pin for the screw is advanced across the osteotomy site toward the lateral portion of the calcaneus (Figure 5). A cannulated screw

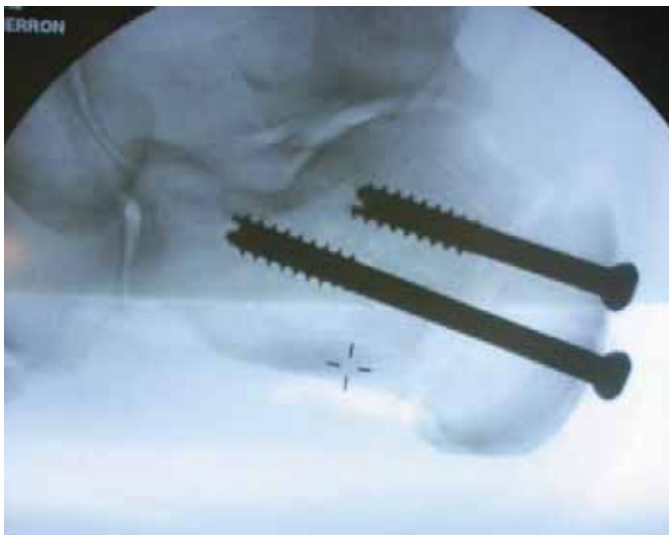


FIGURE 6.

Figures 3-6: Courtesy of Mark Herron, MD, PhD, FACS, The Foot Surgery Atlas

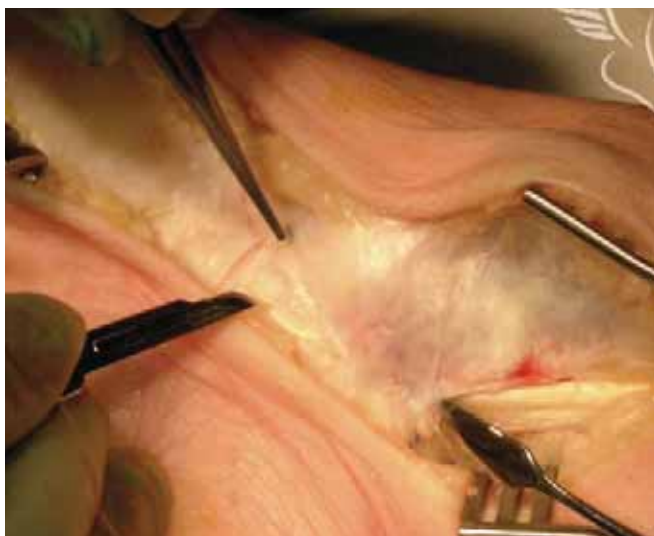


FIGURE 7.

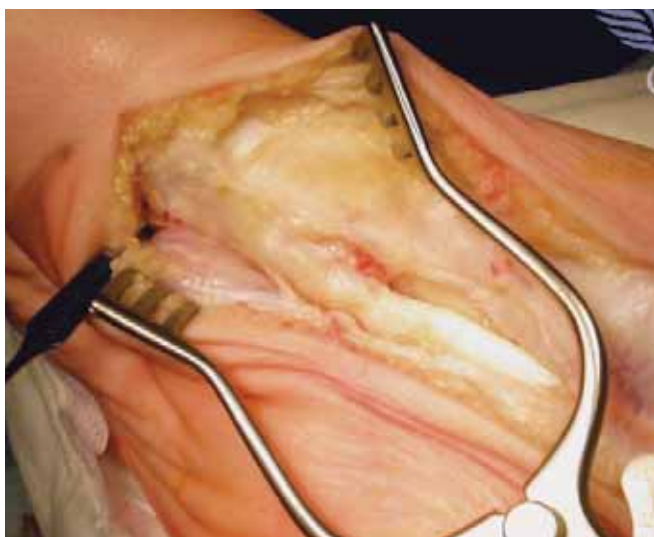

FIGURE 8.

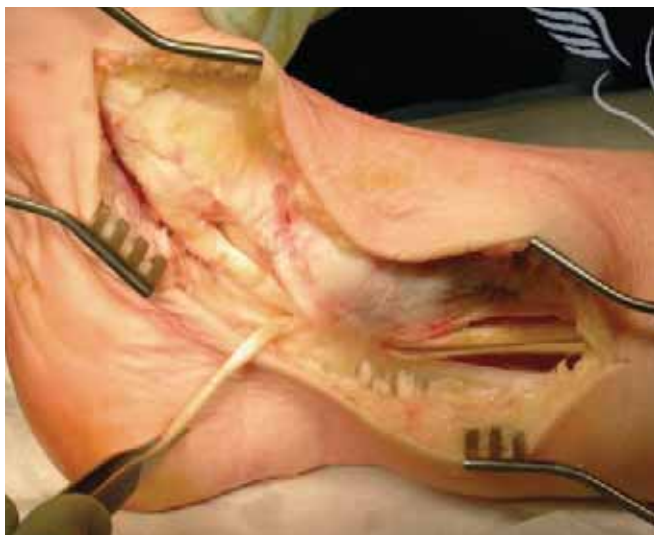

FIGURE 9.

is inserted across the osteotomy site. The screw placement and osteotomy position is radiographically checked (Figure 6). The wound is irrigated and closed in layers using either a 2-0 or 3-0 absorbable suture for the subcutaneous tissues and 3-0 nylon on the skin.

Attention is then turned to the FDL transfer and the medial side of the foot. At this point, it is helpful to have the “bump” removed from the ipsilateral hip, allowing the foot to externally rotate. An incision is made from a point superior to the tip of the medial malleolus to the navicular along the course of the posterior tibial tendon. The tendon sheath is opened and inspected (Figures 7-8). Increased fluid, fissures, change in color and texture of the tendon can be seen. The FDL tendon is identified and dissected into the midfoot (Figure 9). After the tendon is detached, it will serve to replace the damaged posterior tibial tendon. The posterior tibial tendon is usually debrided. If severe, it is largely excised, but may be saved to attach to the newly-transferred FDL to add to its power. This is called a tenodesis. The surgeon may repair the spring ligament. One method by which this is accomplished is to plicate the ligament using 2-0 fiberwire (Figure 10).

The navicular is exposed dorsally. A drill hole is made going from plantar to dorsal. A 3.2 mm drill can be used first to make a pilot hole. The hole can then be enlarged using a 4.5 mm drill to accommodate the thickness of the FDL. Figure 11 shows the hole in the navicular, which can be seen below the Senn retractor, and the FDL tendon stretched across the navicular. The FDL tendon is passed through the hole from plantar to dorsal. The foot is then

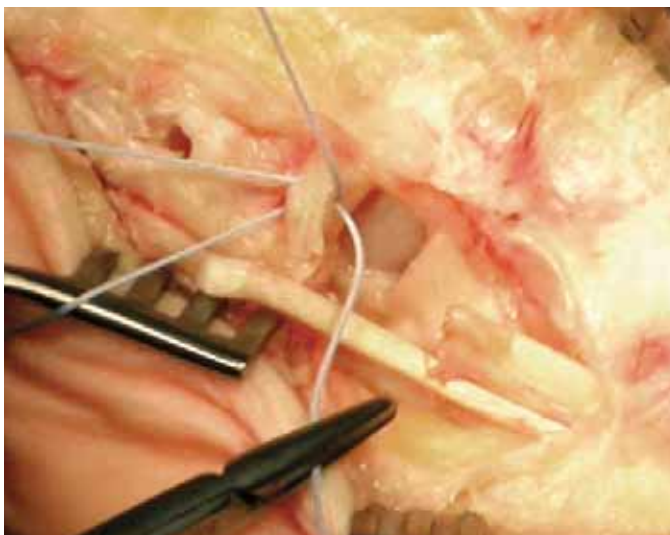


FIGURE 10.

Figures 7-13. Courtesy of Mark Heron, MD, PhD, FRCGS, The Foot Surgery Atlas

positioned into maximum inversion. The tendon is sutured into the periosteum of the navicular, the surrounding tissues, and to itself using #2 nonabsorbable suture.

Another technique of fixating the FDL tendon is the use of an absorbable biotenodesis screw. A 2-0 absorbable suture is stitched to the free end of the FDL starting about 2cm from the end of the tendon so that the ends of the suture (left long) are parallel to the length of the tendon. A long 2.0 drill bit having an eyelet on the opposite end of the flutes of the bit is passed through the navicular from

Surgical procedures for correction of the flatfoot vary, but can include: medial displacement osteotomy of the calcaneus and transfer of the flexor digitorum longus tendon to replace the posterior tibial tendon; spring ligament reconstruction; subtalar arthrodesis; and triple arthrodesis.

plantar to dorsal. A cannulated 5.0mm drill bit is passed over the first drill and removed. The long ends of the suture are threaded through the eye of the first bit. The bit is then pulled through the hole in the navicular, feeding the FDL through. A 5.0 bioabsorbable screw is placed in the hole from the plantar side while tension is applied to the sutures and the foot is held in maximum inversion (Figure 12). The suture is cut and the wound is irrigated (Figure 13). A suction drain may be placed. The wound is closed in layers, starting with a 2-0 absorbable suture for subcutaneous tissue and 3-0 nylon for skin.

After closure, the patient is held in a short-let compressive dressing consisting of a wound dressing, a bulky cotton roll, plaster or fiberglass splints, and an over wrap of an elastic bandage. This is done with the foot in inversion to protect the tendon transfer.

POSTOPERATIVE

Sutures are removed at two to four weeks and a short-leg, non-weight-bearing cast is applied with the foot still in inversion. The cast is changed intermittently every few weeks after surgery and radiographs are taken to confirm union of the osteotomy site. The patient is eventually allowed to bear weight in a walking cast and then in a

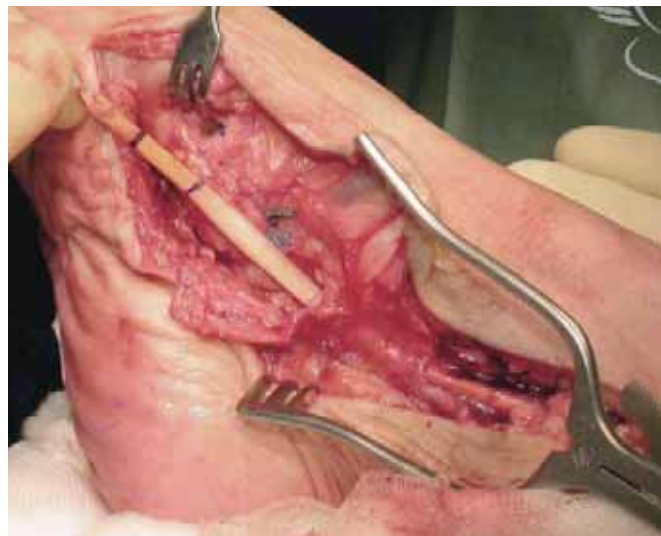

FIGURE 11.

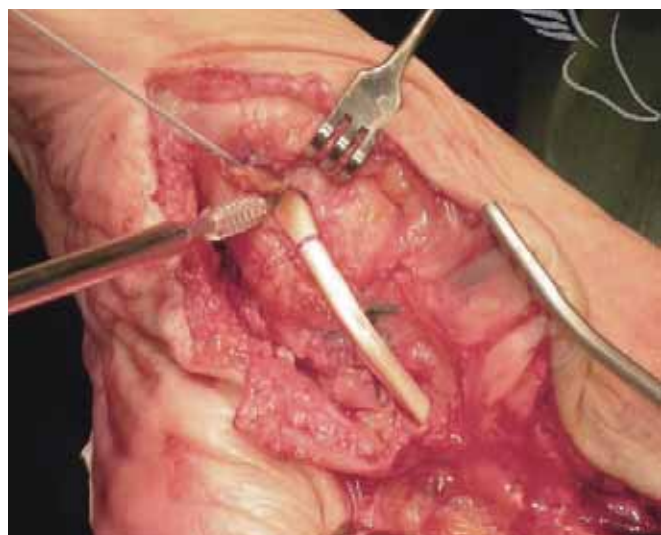

FIGURE 12.

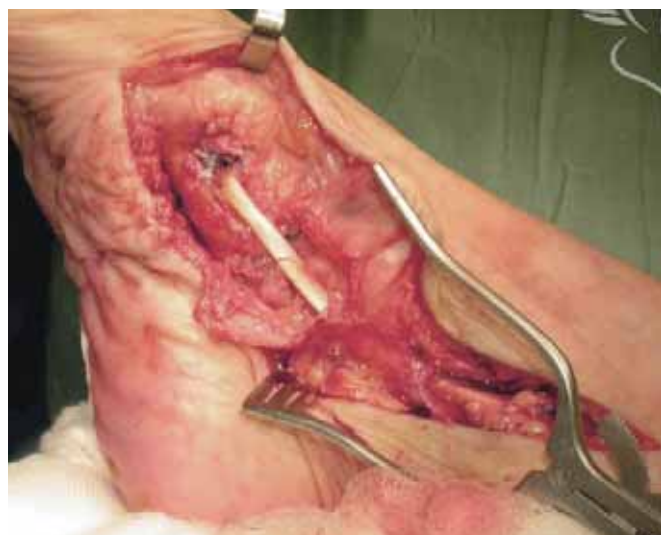

FIGURE 13.

walking boot. After three months, the patient is allowed to gradually discontinue the walking boot and begin unprotected ambulation. Patients are encouraged to begin range-of-motion exercises and are started on physical therapy for strengthening and balance.

Usually, 10-18 months are needed for maximum rehabilitation after the surgery. It is rare to have late failures of the FDL transfer and the functional results of the surgery appear to be durable.

SURGICAL ALTERNATIVES

Lateral Column Lengthening

Another option for patients presenting with stage two PTTD, peritalar subluxation, hindfoot valgus and pain at the distal fibula and lateral calcaneus, is a lateral column lengthening. This is often done through the calcaneocuboid joint with arthrodesis in conjunction with the FDL transfer and a spring ligament repair as described earlier. Iliac

Another option for patients presenting with stage two PTTD, peritalar subluxation, hindfoot valgus and pain at the distal fibula and lateral calcaneus, is a lateral column lengthening.

crest block autograft or structural allograft can be used to lengthen the lateral column.

Anteroposterior and lateral radiographs should be taken. These can show a loss of medial arch height, forefoot abduction, hindfoot valgus, and impingement of the fibula on the calcaneus.

The patient is positioned in supine with a “bump” under the ipsilateral hip to have better access to the lateral side of the foot. A thigh tourniquet is applied. A surgical prep is performed and the leg is draped up to the knee. Consideration must be taken to include concurrent draping of the ipsilateral iliac crest.

A skin incision is made over the calcaneocuboid joint. Care is taken to identify and preserve branches of the sural nerve. The extensor digitorum brevis muscle is reflected dorsally from its inferior margin. The peroneal tendons are retracted dorsally. A lamina spreader is inserted into the calcaneocuboid joint and the cartilage is removed from the joint using an osteotome, curettes, and rongeur. An osteotome may be used to shingle the subchondral bone. This is

when the subchondral bone is slightly raised up in multiple places in such a manner that it looks like shingles on a roof. This is thought to aid in the fusing of bone. Likewise, subchondral bone can also be prepared for fusion by using a 2.5-3.5 drill bit and drilling multiple holes.

A lamina spreader is placed in the joint and distraction is applied. Adduction of the forefoot and restoration of the medial longitudinal arch can be observed with this maneuver. Interoperatively, an anteroposterior image using fluoroscopy is used to assess the coverage of the talar head by the navicular. When the desired coverage is reached then a measurement of the distraction of the calcaneocuboid joint is taken. It usually ranges eight to 12mm.

From the ipsilateral hip, a tricortical graft is taken and contoured into a trapezoidal shape in order to create a wedge. This graft is impacted into place using a bone tamp. Further stabilization is achieved with the use of a small plate.

The iliac crest wound is irrigated and closed in layers with 0 polyglactin 910 , 2-0 polyglactin 910 and 3-0 nylon. The calcaneocuboid wound is irrigated and closed in layers with 2-0 polyglactin 910 and 3-0 nylon.

POSTOPERATIVE

The bump is removed. The spring ligament repair and FDL transfer are

completed in the manner previously described with the foot held in supination by the assistant.

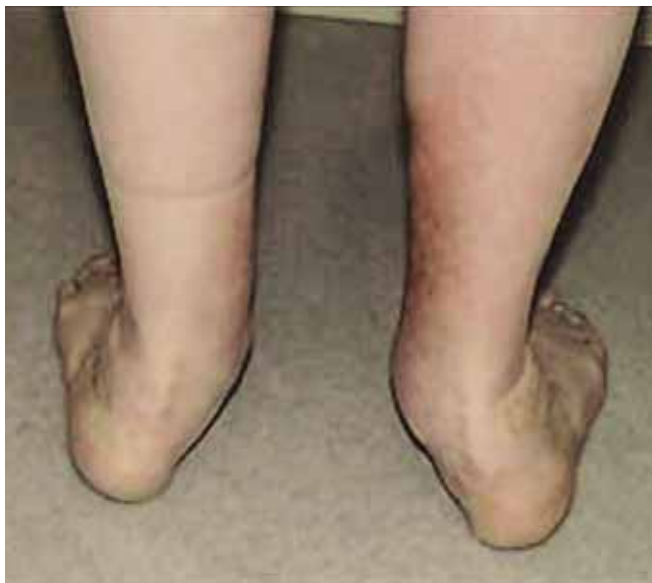After the wounds are closed, a splint is applied maintaining supination of the foot. The postoperative care is followed as described in the previous procedure.

Subtalar Arthrodesis

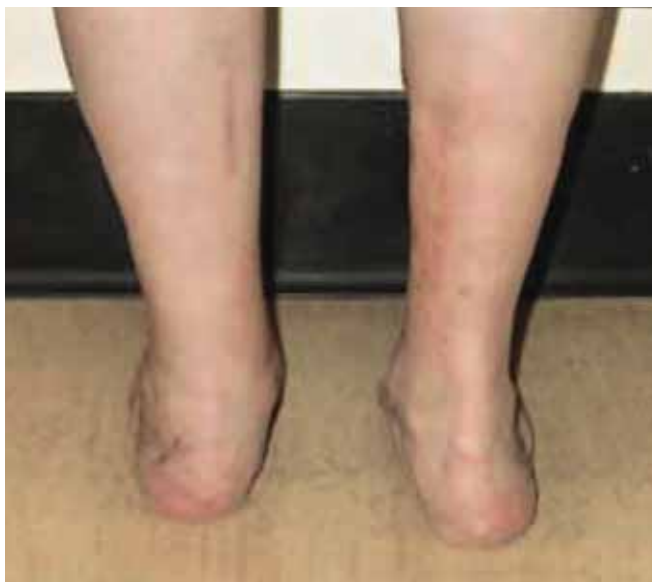There are some patients for whom the previously-described procedures are not an option due to the presence of arthritis in the subtalar joint or because the subtalar joint is fixed with the hindfoot in valgus. In such cases, a subtalar arthrodesis may be appropriate. It can be an applicable procedure when other hindfoot reconstruction operations have failed such as medial calcaneal osteotomy, posterior tibial tendon reconstruction with FDL transfer, or spring ligament repair.

Preoperative preparation includes radiographs like those outlined for the above-mentioned procedures.

For surgery, the patient is positioned supine with a “bump” under the ipsilateral hip in order to internally rotate the extremity. A thigh tourniquet is applied.



BEFORE



AFTER

After prepping and draping is complete and the tourniquet has been inflated, the incision is made starting at the tip of the lateral malleolus and continuing toward the base of the 4th metatarsal. The calcaneal attachment of the extensor digitorum brevis muscle is dissected to create a distally-based flap, allowing exposure to the calcaneocuboid joint. The peroneal tendons and sheath are retracted inferiorly. A lamina spreader is inserted into the sinus tarsi to aid exposure of the articular surfaces. Cartilage is removed using osteotomes, curettes, and rongeur until the subchondral bone is exposed. The subchondral bone is prepared for fusion using a 3.2 drill bit to drill multiple holes. A guide

wire from a 7.0 cannulated set is passed through a longitudinal incision in the heel through the posterior facet of the calcaneus into the talus, allowing for five to seven degrees of valgus. Using a depth gauge, a measurement is taken to determine the length of the screw to be placed. A cannulated drill bit is passed over the guide wire. A partially-threaded screw with a diameter of 7.0 mm having the length somewhat shorter to that shown on the depth gauge is inserted. The reason for using a shorter screw than what is shown on the depth gauge is to allow for compression of the fusion site without having the undesirable effect of the screw protruding.

When a screw is placed through the posterior facet into the talus, it is likely to have a thread length of 16mm due to the height of the talus. Conversely, a 32mm thread length can be used when the screw is placed dorsal to plantar through an incision over the talar neck due to the height of the calcaneus and the angle at which the screw is placed.

The stability is tested and fluoroscopy is used to do a final check on screw and hindfoot placement.

Bone graft may be taken from the proximal tibia using curettes and small osteotomes. If so, it is placed into the fusion site before insertion of the screws. The extensor digitorum brevis muscle is reapproximated over the bone graft and the wound is irrigated and closed in layers using 2-0 polyglactin 910 and 3-0 nylon.

POSTOPERATIVE

A splint is applied and the patient is made non-weight-bearing. After three weeks, the sutures are removed and a short-leg, non-weight-bearing cast is applied. A walking cast is applied at six to eight weeks postoperatively, and for an additional four to six weeks until evidence of arthrodesis union can be seen radiographically.

Foot and ankle rehabilitation starts after bone healing is complete and the final cast is removed. Patients can expect to have some swelling and aching for many months.

The success rate of this procedure is high for patients having PTTD and flatfoot; however, there are some patients who have more severe deformity and/or arthritis requiring a more extensive procedure such as a triple arthrodesis. Patients having a fixed hindfoot deformity, such as that resulting from posterior tibial tendon rupture with an acquired flat foot, as well as painful arthritis in the hindfoot and the tarsal joints, may need this procedure.

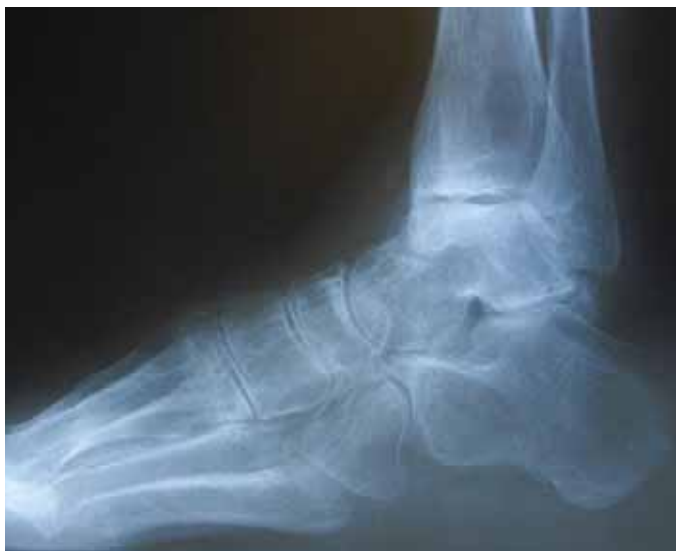

FIGURE 14.

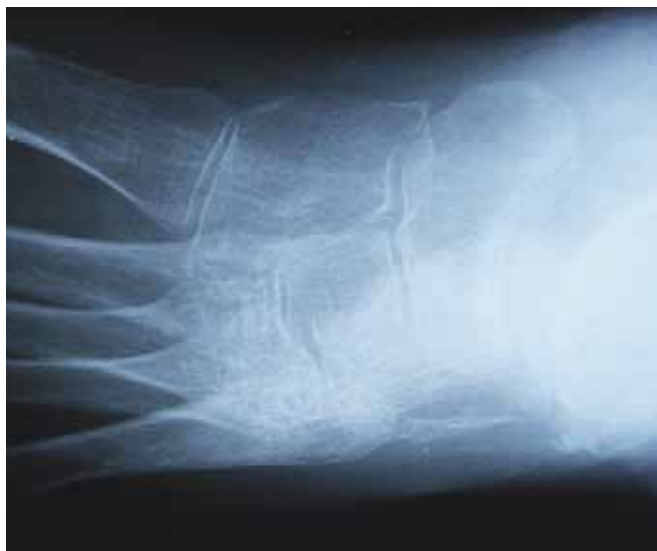

FIGURE 15.

Triple Arthrodesis

A routine foot and ankle examination and radiographs should be done. These include weight-bearing anteroposterior foot, lateral foot and anteroposterior ankle views (Figures 14 & 15). Also useful are views of oblique foot and mortise of the ankle.

As GEA opened the door for better treatments in women's health, it also opened a door to more career choices for surgical technologists. The office-based procedure provides a different route of employment for surgically-trained personnel.

For surgery, the patient is positioned, prepped and draped in the same manner as with a subtalar arthrodesis.

The incision starts from the distal fibula and runs to the base of the 4th metatarsal. The subtalar joint is prepared as described previously. The calcaneocuboid joint is prepared next using osteotomes, curettes, and ronguer while it is held open with a lamina spreader. The next to be prepared is the talonavicular joint through an anteromedial incision at the level of the talar neck. It is prepared in the same fashion as the subtalar and the calcaneocuboid joints except that a toothless lamina spreader may be used to hold the joint open. With all three joints, the subchondral bone is drilled multiple times. Bone graft is placed in all the fusion sites prior to and following insertion of hardware. Can-

nulated screws are placed across the subtalar joint in the manner previously described. The talonavicular joint can be stabilized using cannulated or solid screws. The screw is placed at a shallow angle in the medial-lateral plane in a retrograde direction. It is important to countersink the entrance hole in the navicular in order to not break the bridge of bone as the screw is tightened. It is important to be sure to hold the talonavicular joint in a reduced position so as to restore the medial longitudinal arch and obtain the correct balance of adduction-abduction and varus-valgus.

The calcaneocuboid joint is stabilized similarly. The screw is placed from the anterior process of the calcaneus into the cuboid (Figures 16 & 17).

Another approach that is used in fusing the talonavicular and calcaneocuboid joints is the use of compression plates. This technique is accomplished with plates that allow one to two screws being placed through the plate that spans the joint. Once the screws are placed, the plate is spread open causing compression of the joint (Figure 18). Even though this is not as common a technique as the one previously described, it's known to be used with a good post-operative result.



FIGURE 18.

Figures 16, ©Integra LifeSciences Corporation 2009. Reprinted with permission.

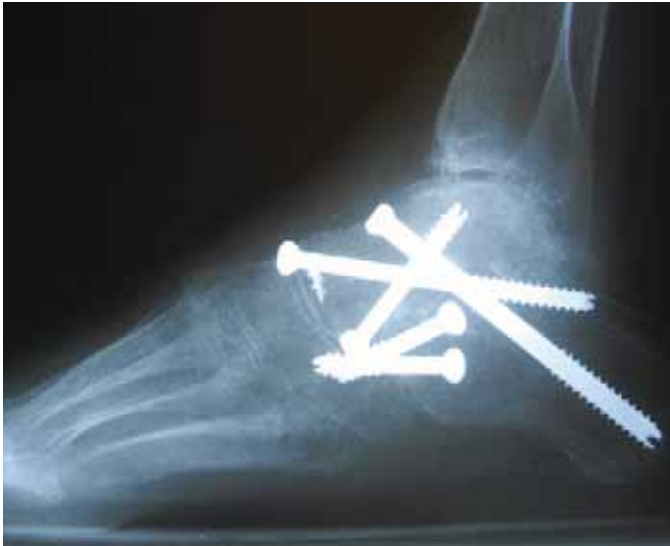

FIGURE 16.

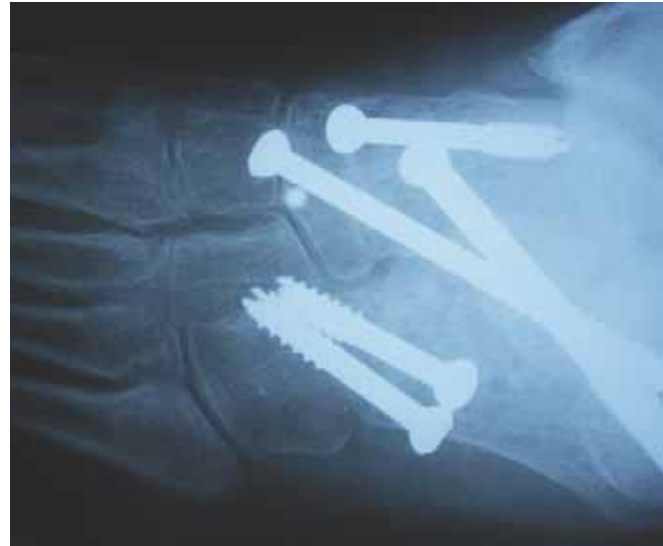

FIGURE 17.

Figures 14-17: Courtesy of James Braskly, MD

Fluoroscopy is used to check fixation placement and alignment. The extensor digitorum brevis muscle is reapproximated using 0 polyglactin 910 . The wound is irrigated and closed in layers using 2-0 polyglactin 910 and 3-0 nylon. A bulky splint is applied to allow for swelling.

POSTOPERATIVE

At the first follow-up visit, the splint and sutures are removed. A short leg cast is applied. The patient is to remain non-weight-bearing for six weeks following surgery. At six weeks, if the fusion sites have healed and there is no tenderness in those areas, the patient is allowed to wear shoes and increase activities as tolerated.

There are some possible complications of attempted arthrodesis, including nonunion of the talonavicular joint, occurring in 5-10 percent in most of the reported series in literature. This can be decreased with care in meticulous removal of cartilage and fibrotic bone. Also, the use of cancellous autograft can improve fusion rates. There is a risk for malalignment, usually occurring at the time of surgery. Careful alignment of the joints at the time of surgery helps to avoid malalignment.

CONCLUSION

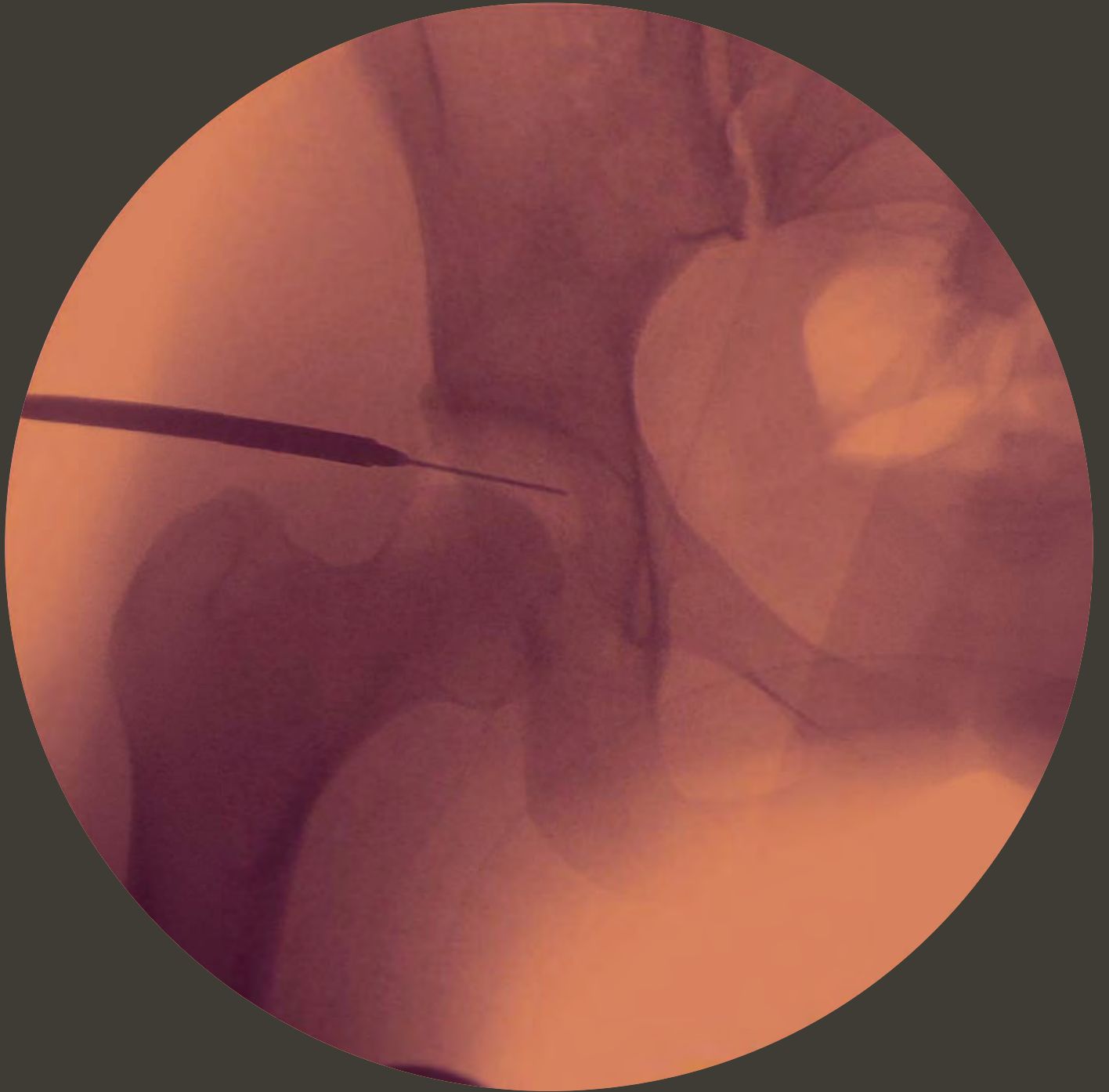Whenever possible, it is best to do motion-sparing procedures, as described earlier in this article as a first option. As long as there is no painful arthritis or lack of mobility in the hindfoot or tarsals, procedures such as medial displacement calcaneal osteotomy with FDL transfer or lateral column lengthening are motion-sparing and more

often preferred. Subtalar arthrodesis and triple arthrodesis should be reserved for patients having painful arthritis or fixed flatfoot with PTTD. It is also useful to reserve them as a secondary option for salvage procedures when the above-mentioned fail.

ABOUT THE AUTHOR

Angela Webb, CST, attended Career West Academy in California, where she majored in surgical technology. After completing her clinical training in Texas, in 1995, she worked at Baylor University Medical Center as a Certified Surgical Technologist. Ms Webb has specialized in orthopaedics for 12 years, focusing primarily on foot and ankle procedures, as well as shoulders. She currently works full-time at Mary Shiels Hospital in Dallas.





Hip Arthroscopy:

TREATING FEMOROACETABULAR IMPINGEMENT

by Margaret M Armand, CST
with contributions by
Benjamin G Domb, MD and Rima Nasser, MD

HISTORY Hip arthroscopy is a rapidly-evolving field in orthopedic surgery.¹ Similar to arthroscopic knee and shoulder surgery, hip arthroscopy involves an arthroscope inserted into the hip joint space. Its history is brief. Minimally used in the late 1980s, due to limitations in the understanding of the joint pathology and techniques, hip arthroscopy has seen a surge in technical developments since the mid 1990s and has enabled surgeons to begin treating a variety of painful hip conditions.^{2,3}

As the understanding of arthroscopic anatomy, indications, potential complications and techniques has evolved, hip arthroscopy has become a successful treatment method for a variety of hip pathologies.^{2,3}

Arthroscopic hip surgery can address a variety of painful hip conditions, including labral tears, loose bodies, ligamentum teres femoris injuries, capsular laxity, chondral deformities, coxa saltans (clicking hip), and femoroacetabular impingement.^{2,4,5,6} While it does not allow for a 360-degree view of the joint, like the more commonly-used open procedure, most pathological structures can be visualized and repaired using the arthroscopic approach. This procedure is preferable for repair because, if performed correctly, it is less invasive, less traumatic, and has a shorter recovery time than open surgery.^{7,8} Patients of all ages and activity levels tend to prefer an arthroscopic operation because of this. Hip arthroscopy is especially popular with athletes because it may allow for a quicker return to competition.

LEARNING OBJECTIVES

- ▲ Review the relevant anatomy for this procedure
- ▲ Examine the set-up and surgical positioning for this procedure
- ▲ Compare and contrast the osteoplasty-cam procedure and the acetabuloplasty-pincer procedure.
- ▲ Assess the indications for femoroacetabular impingement
- ▲ Evaluate the recovery and rehabilitation process following FAI

ANATOMY OF THE HIP

The hip is a ball and socket joint. The arrangement of bones, ligaments and muscles allow for a variety of movements and a large range of motion. The hip joint consists of the bones of the pelvis and the femur, ligaments and tendons, muscles, nerves and blood vessels. Three fused bones; the ischium, ilium, and pubis provide the frame of the pelvis. The head of the femur fits into the acetabulum formed where the three parts of the hip bone converge. The bony surfaces are lined with articular cartilage which allows for smooth movement of the bones in the joint.

Covering the rim of the acetabulum is a fibro-cartilaginous structure called the labrum. The labrum helps to create a suction seal for the joint surfaces. This labrum has several purposes, including aiding joint stability and helping to control the ingress and egress of synovial fluid. If the socket or acetabular contour is too deep, or the head/neck junction of the femoral head is irregular, this excessive bone growth can cause impingement of the labrum.⁶

Three large ligaments support the hip capsule and keep the hip in place. Anteriorly, the iliofemoral ligament is attached at the iliac spine of the hip bone to the inter-

hamstrings: biceps femoris, semitendinosus and semimembranosus, and the gluteus maximus. The piriformis, obturator internus, obturator externus, the superior and inferior gemellus muscles and the quadratus femoris muscle function as lateral rotators of the hip. The adductor muscles include the adductor longus, adductor brevis and the adductor magnus with the pectineus and gracilis muscles.⁹

Innervation is primarily provided by the femoral nerve anteriorly and the sciatic nerve posteriorly.¹⁰ The obturator nerve also passes through the hip. The femoral nerve innervates the flexor muscles of the thigh, the extensor muscles of the leg and the skin of the medial and anterior aspect of the thigh. The sciatic nerve supplies the posterior and lateral aspects of the thigh. The lateral cutaneous nerve affects the skin of the lateral, anterior and posterior aspects of the thigh.⁹

The blood supply to the hip is from the femoral arteries that run anteromedial in the thigh. The femoral artery has a deep branch called the profunda femoris, which supplies blood to the hip joint capsule.¹⁰ Within the ligamentum teres is a smaller vessel that supplies blood to the femoral head. The blood return is through the great saphenous and femoral veins.⁹

Twenty-seven muscles cross the hip that control movement and help propel the human body.⁶ The majority of these muscles originate on the pelvic girdle and insert along the femur.

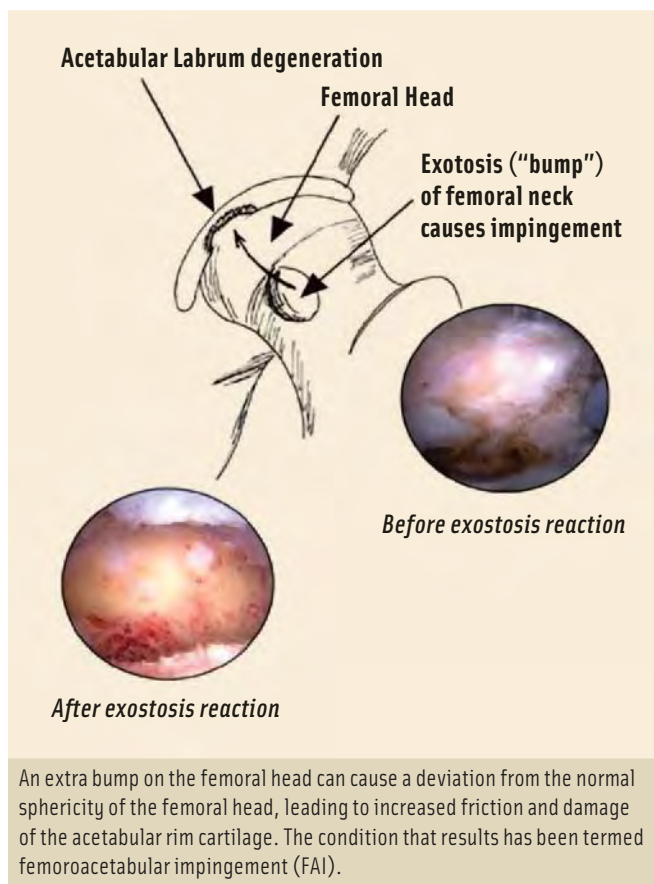
FEMOROACETABULAR IMPINGEMENT (FAI)

Many times, it is abnormal anatomy that causes impingement. In cases where there is a wide lip of bone on the socket, or over-coverage in one area, this bone pinches against the labrum and the femoral head-neck

trochanteric line of the femur, the pubofemoral ligament is attached at the pubic part of the acetabular rim to the neck of the femur, and posteriorly, the ischiofemoral ligament is attached at the ischial wall of the acetabulum to the neck of the femur. These ligaments form the hip joint capsule, which is filled with synovial fluid that lubricates the articulating bones of the joint and allows the hip to move freely. A smaller ligament, the ligamentum teres, attaches from the fossa of the acetabulum to the head of the femur.⁹

Twenty-seven muscles cross the hip that control movement and help propel the human body.⁶ The majority of these muscles originate on the pelvic girdle and insert along the femur. Major flexors include the four muscles of the quadriceps muscle: the rectus femoris, vastus lateralis, vastus medialis, and vastus intermedius along with the sartorius muscle. Extensors include the three muscles that form the

junction. An extra bony growth on the femoral neck causes a deviation from the normal sphericity of the femoral head. This also leads to increased pinching and damage to the labrum and acetabular rim cartilage.⁶ Femoroacetabular impingement (FAI) is a painful hip condition where the labrum of the acetabulum becomes impinged between an abnormally-shaped femoral head-neck junction and/or a deep or overhanging rim of the acetabulum during flexion, adduction and internal rotation.^{4,9} The pain may be caused by the repetitive tearing or crushing of the labrum, or through bone-on-bone contact of the femoral head-neck junction and the acetabulum.⁹ There are two types of FAIs: cam impingement from the femur and pincer impingement from the acetabulum.^{3,8,9,10} While these may occur independent of each other, it has been shown that combined impingement occurs in 86 percent of the cases.⁴



DIAGNOSIS

Preoperative planning is important for identifying patients who will benefit from arthroscopic hip surgery. While some patients with hip pain respond to more conservative treatments, such as therapy, rest and non-steroidal anti-inflammatory drugs (NSAIDs), some have pain that can only be treated by surgery.^{2,6} In patients with persistent symptoms, a carefully-elicited history and physical examination may suggest various anatomical and pathological processes.² A challenging goal of the physical examination is to determine if the pain is of intra-articular or extra-articular origin.^{4,2} In order to discover this, “[t]he history should include the qualitative nature of the discomfort (clicking, catching, stiffness, instability, decreased performance, and weakness), the location of the discomfort, onset of symptoms, and any history of trauma or developmental abnormality.”⁴

Extra-articular causes of hip pain, including sacroiliac joint pathology, stress fractures, trochanteric bursitis,

occult hernias and tendon injuries (iliopsoas, piriformis, rectus hamstring or adductor) occur more frequently than intra-articular causes of hip pain.^{2,11} Lateral thigh pain is typically due to trochanteric bursitis, and posterior buttock and sacroiliac pain is usually due to spinal or sacroiliac conditions.^{2,6}

Since most hip joint pathology is found within the intra-articular region, distraction is necessary to achieve arthroscopic access.¹ Determining the signs and symptoms that suggest intra-articular pathology are essential in differentiating patients who may benefit from hip arthroscopy.² The presence of groin pain and /or anterior thigh pain extending to the knee is a significant indicator, especially if the pain is activity related.^{2,8,9,10} In the case of FAI, presenting pain is commonly felt when the hip is flexed, adducted and internally rotated (the FADDIR test.)^{1,4} During these movements, the labrum becomes impinged between the bony structures. Repetitive movements cause tearing or crushing of the labrum which can be quite painful.

Radiographic imaging, three dimensional imaging from computed tomography (CT) scans, and magnetic resonance imaging (MRI) are useful in determining the pathology of the hip. Many times, bone irregularities of the acetabular rim are noted on a radiographic image. The three dimensional imaging from a CT scan can give detail on bone growths and calcified loose bodies in the joint and show abnormalities to the head neck junction of the femur.^{2,6} MRI studies are best for soft tissue problems.⁶ Therefore most tendon and labral tears can be viewed with an MRI scan or with an MR arthrogram.⁶

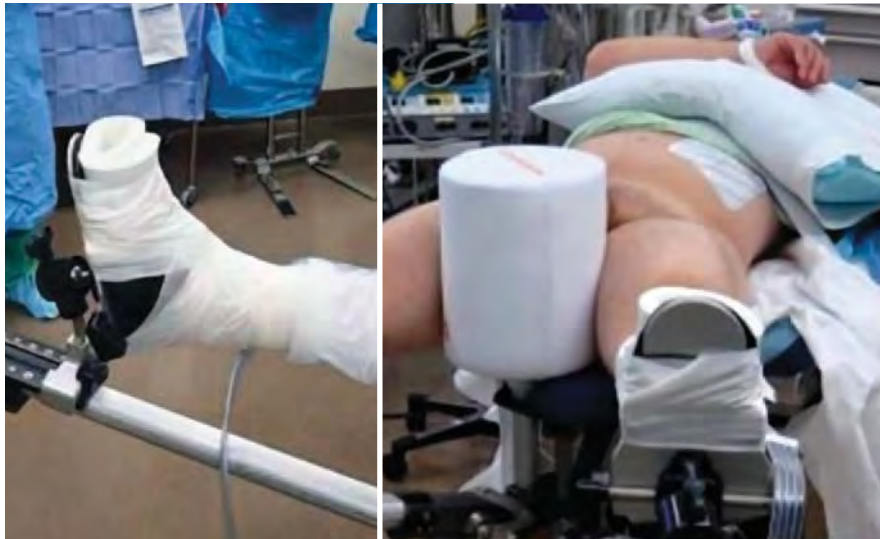Since most hip joint pathology is found within the intra-articular region, distraction is necessary to achieve arthroscopic access.¹ Determining the signs and symptoms that suggest intra-articular pathology are essential.

SURGICAL POSITIONING

Patients undergoing arthroscopic hip procedures are placed in the supine or lateral position.^{1,2,3,7} Both positions are equally effective. The choice is made by surgeon preference. For some surgeons, the supine position may be advantageous for ease of positioning, while lateral position may be preferable for obese patients.^{1,2,3} When patients are placed

in a supine position, a custom leg distraction device is attached to the operating table. The patient is positioned against a wide peroneal post with feet in distraction boots securely taped in place with three-inch silk tape. The ipsilateral arm is placed across the chest and the contralateral arm is placed on an arm board. Complete relaxation is necessary to achieve distraction and the patient is completely paralyzed to prevent any movement during the procedure so that when sharp objects are placed within the joint harm is not caused by sudden movements.⁷

The patient's operative leg is placed under traction to open up the joint, providing space to work.^{1,3,6} This is visualized under fluoroscopy.^{1,6} The lower limb is placed in slight flexion (approximately 10-20 degrees) with the foot maintained in neutral to slight internal rotation.



The patient is placed in the supine position, with the operative leg in traction.

The peroneal post is pushed against the medial portion of the thigh of the involved leg, keeping the post away from the branch of the pudendal nerve that crosses over the pubic ramus.^{1,2,3,7,8} Distraction is achieved carefully until the “vacuum phenomenon” is seen on the X-ray.^{3,8} Adequate visualization requires the femoral head to be distracted from the acetabulum with a goal of seven-10 mm between their articular surfaces.^{2,7,8}

The patient is prepped from waist to knee on the affected leg and from the midline of the abdomen to as posterior as possible using alcohol first, then with a Chloraprep® solution. Draping involves four adhesive drapes placed first at the iliac crest, mid-thigh, as anterior and as close to the peroneal post as possible and, finally, as posterior as pos-

sible followed by an isolation drape. The adhesive portion of this drape is placed over the incision site and the remainder is placed over the patient.

SCRUB NOTES

The surgical technologist stands toward the patient's head, and the first of two Mayo stands is placed over the patient's chest. This Mayo stand holds the cords necessary for the procedure: a long, 70-degree arthroscope with camera, light cord, and fluid inflow, as well as an arthroscopic shaver with suction and a radio frequency Ablator wand. The second Mayo stand abuts the first and holds the necessary instrumentation: a #11 blade for the initial incisions, a long, narrow-handled, curved beaver blade; two specially-designed, long spinal needles; a flexible guide wire; two hip trocars,

4.5 mm and 5.0 mm; two cannulated switching sticks; two slotted cannulas for exchanging instrumentation; and an arthroscopic probe.

SURGICAL PROCEDURE

The first step in the procedure includes placing portals using spinal needles and a flexible guide wire. Two portals are typically used: an anterior and an anterolateral.⁴ The anterolateral portal is placed laterally over the superior margin of the greater trochanter at its anterior border.¹ This portal is established first, as it lies most centrally within the safe zone for arthroscopic hip surgery and penetrates the gluteus medius.^{1,2} “The anterior portal is placed

at the site of intersection of a sagittal line drawn distally from the anterior superior iliac spine and a transverse line across the tip of the greater trochanter.”^{1,2} This portal penetrates the sartorius and the rectus femoris.² Other portals may be used as necessary, including posterolateral or distal lateral accessory ports. When placing the anterolateral portal, one must be extremely careful of the lateral cutaneous nerve, and when establishing the posterolateral portal, one must consider the posterior neurovascular bundle.^{3,7} The femoral artery and nerve lie well medial to the anterior portal and the sciatic nerve lies posterior to the posterolateral portal.¹

Specially-designed instruments are used to reach the depth of the hip joint, including a long spinal needle and a flexible guide wire.³ Special care must be taken to avoid

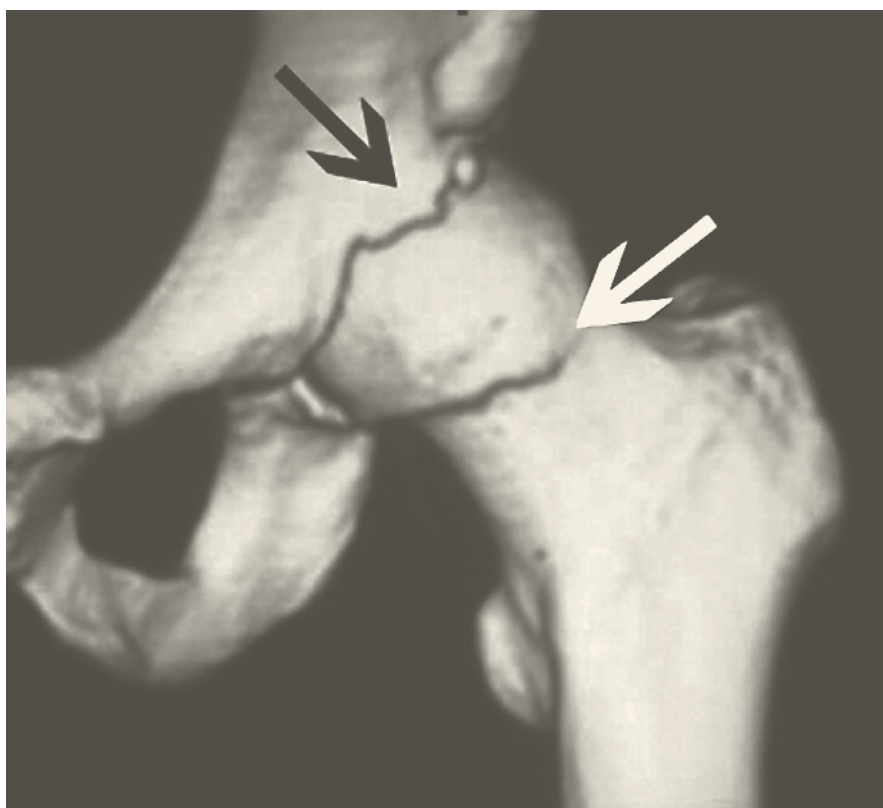


FIGURE 1. Three-dimensional computed tomography reconstruction of the hip revealing extensive anterolateral cam impingement (white arrow) and pincer impingement (black arrow).

penetration of the acetabular labrum or causing damage to the femoral head.^{1,3} As the surgeon uses the spinal needle to penetrate through the capsule into the joint space, there is a palpable decrease in resistance.³ However, if the needle is directed into the labrum the resistance felt is greater.³ Once the surgeon positions the spinal needle, air is introduced into the joint space by removing the stylet. The needle is removed and then redirected to the correct location in the joint space.

Next, the surgeon feeds a guide wire through the spinal needle, and the spinal needle is removed.¹¹ After the surgeon positions the guide wire in the joint, a cannulated trocar is used to penetrate the joint capsule.¹ Either a 30-degree or a 70-degree long arthroscope can be used.^{1,3,4,7} Use of a 70-degree scope allows for a nearly-complete visualization of the joint. Once the scope has been introduced into the joint capsule, it will aid the placement of the other portals. To improve visualization and increase access within the joint, the surgeon may perform

a capsulotomy using a curved beaver blade on a long, narrow handle.^{1,4}

During the procedure, an initial diagnostic arthroscopy is performed and the structures of the hip joint are examined.¹ The femoral head is observed for chondral deformities or damage, as well as the surface of the acetabulum, the condition of the labrum and the ligamentum teres. An arthroscopic probe is used to examine the condition of the chondral-labral junction of the acetabulum.

LABRAL PATHOLOGY

The labrum is a fibrocartilaginous structure attached to the rim of the acetabulum.^{4,10} The rim consists of a triangular shaped “tongue” of bone to which the labrum is attached.⁹ The labrum creates a type of suction seal, limiting fluid expression from the joint space, protecting the cartilage layers of the hip and acting as a joint stabilizer.⁴ Proprioceptive and noci-

ceptive nerve fibers run through the labrum, so pain is felt when it is impinged by the bony structures of the acetabular rim or the femoral neck.^{8,9} The articular surface of the labrum has decreased vascularity.^{4,7}

During the procedure, an initial diagnostic arthroscopy is performed and the structures of the hip joint are examined.¹ The femoral head is observed for chondral deformities or damage, as well as the surface of the acetabulum, the condition of the labrum and the ligamentum teres.

Two types of labral tears have been identified.¹² A primary tear, or type 1 tear, is a detachment of the labrum from the rim of the acetabulum, commonly caused by a cam impingement. A type 2 tear is an intrasubstance tear of the labrum, typically caused by a crushing of the labrum against the neck of the femur by an overhanging rim of the acetabulum, also called a pincer lesion.⁴

Debridement, or repair of the labral defect, is dependent on the causes of impingement and the severity of the tear. “The goal of surgical treatment of labral tears is to eliminate any unstable tissue by debridement or repair, while preserving as much healthy tissue as possible to allow the labrum to maintain its role as a suction seal and secondary joint stabilizer.”⁴ If the labrum is detached from the rim, a repair may be necessary and a suture anchor repair is used. If the labrum remains attached and the majority of the substance is intact, there is a possibility that a debridement with a shaver is adequate.

In order to prevent a possible fracture, a resection of less than 30 percent of the head-neck junction is recommended because this has been shown not to alter the load-bearing capacity of the femoral neck.^{4,8}

ACETABULOPLASTY-PINCER PROCEDURE

In cases where there is over-coverage of the acetabular rim, or a “deep” acetabular fossa, damage may occur to the labrum caused by its impingement between the rim and the femoral neck during flexion.^{1,3,8,9,10} Larger pincer lesions usually result in an intrasubstance tearing of the labrum, necessitating an acetabuloplasty.⁴ Depending on the size of the pincer lesion, the labrum may or may not need to be detached from the

rim.^{4,9} If detachment is necessary, the labrum is detached using a curved beaver blade on a long handle. The acetabuloplasty is performed using a motorized burr.⁸ Progress is monitored with radiographic imaging. It is not recommended to resect greater than 5 mm of acetabular rim as it may cause instability.^{4,8} A suture repair is performed if detachment is necessary.^{4,8}

OSTEOPLASTY- CAM PROCEDURE

Labral tears, which are associated with cam impingement, are more commonly type 1 tears and affect the transition zone cartilage and articular surface of the labrum.⁴ A cam-type impingement is caused by a nonspherical head-neck junction of the femur.¹ Most commonly manifested during hip flexion and internal rotation, this causes an impingement of the labrum between the anterior acetabulum and the femoral neck.^{3,8,9,10} “When the aspherical head-neck junction of the femur enters the acetabulum, it displaces the labrum toward the capsule and applies disproportionate load to the adjacent articular cartilage of the acetabulum. This leads to chondral delamination and detachment of the labrum from the acetabular rim.”⁴

Femoral osteoplasty involves recontouring the cam lesion using a motorized burr and fluoroscopy. Traction is removed and a dynamic impingement exam is performed.⁶ The hip

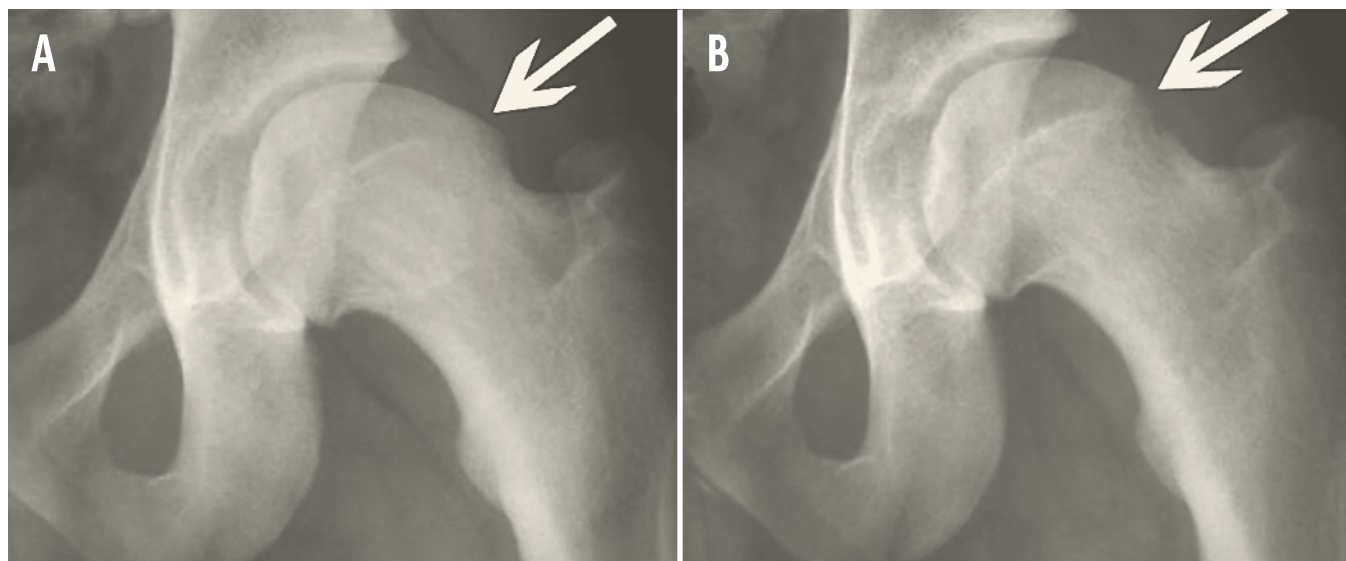


FIGURE 2. (A) An AP pelvis radiograph reveals a superior area of cam impingement (arrow) in a 21-year-old college wrestler. An aspherical head-neck junction evident on the AP radiograph in addition to the lateral radiograph indicates a more extensive cam lesion. (B) A burr was used to recontour the head-neck junction arthroscopically, and improved offset is evident on the postoperative AP radiograph (arrow).

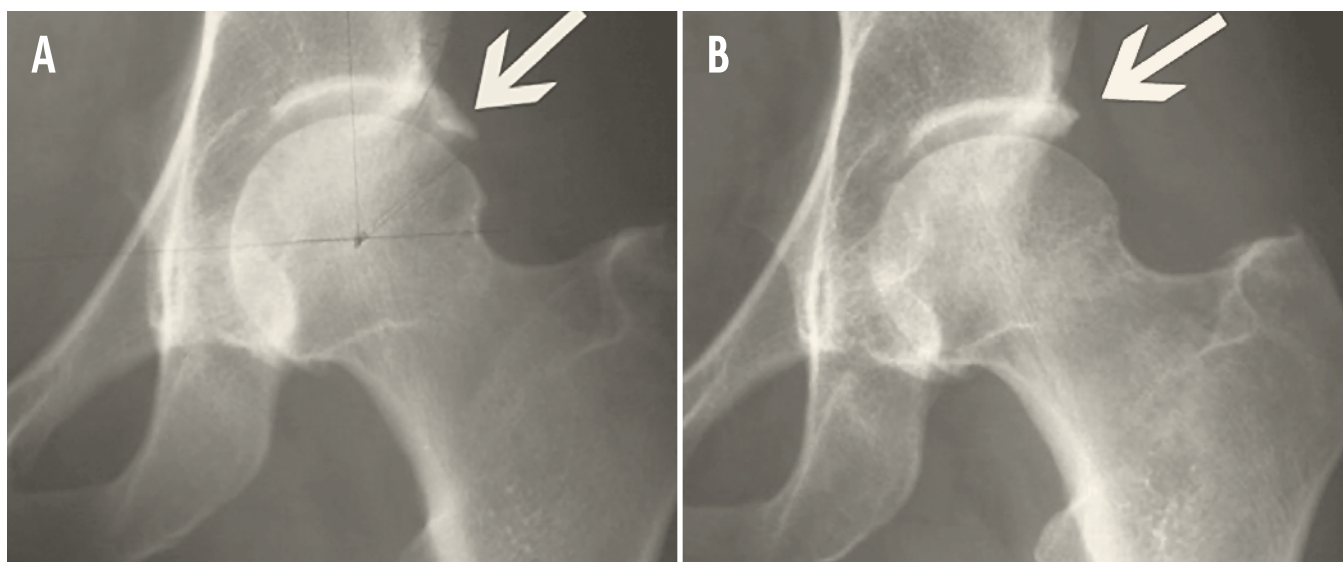


FIGURE 3. (A) An AP pelvis radiograph reveals pincer impingement with a deep acetabulum and secondary ossification of the labrum (arrow) in a 38-year-old equestrian rider with increasing pain with hip abduction. (B) Arthroscopic rim trimming was used to remove this ossified labrum and area of overcoverage (arrow), as seen on the postoperative AP radiograph. The patient's abduction range of motion normalized, and she no longer had pain during horseback riding.

will be flexed, extended, abducted, adducted, internally and externally rotated in order to determine the appropriate positioning.^{4,8} Often the area of the cam lesion can be identified by areas of damaged articular cartilage at its location. The surface cartilage is removed using a curette and a motorized shaver. Then a motorized burr is used to reduce the bony prominence. After osteoplasty, joint clearance is assessed by flexing the hip beyond 90 degrees and internally rotating under direct visualization.^{4,8} In order to prevent a possible fracture, a resection of less than 30 percent of the head-neck junction is recommended because this has been shown not to alter the load-bearing capacity of the femoral neck.^{4,8} Care must be taken not to remove too much bone and compromise the strength and integrity of the femoral neck.

DYNAMIC EXAM

A dynamic exam concludes the procedure. Traction has been removed and the hip joint is run through a complete range of motion: flexion, extension, internal and external rotation. The repair and the movement of the femoral head within the acetabulum as well as contact of the labrum are observed arthroscopically. If any signs of impingement remain, the osteoplasty can be refined at this time.

At the conclusion of the procedure, the suction is connected to the trocar and excess fluid is removed from the joint space. A local anesthetic of 20ml 0.5% bupivacaine and 2ml morphine sulfate is injected into the joint to ease postoperative pain. The portals are closed with a 3-0 nylon

suture. Bacitracin ointment is applied, followed by a non-adherent dressing, gauze pads and finally ABD pads are secured with perforated tape. A polar care hip dressing is applied and the patient's hip brace, which has been previously fitted for him or her, is secured.

RECOVERY AND REHABILITATION

Postoperative rehabilitation helps to determine and complete the success of the hip arthroscopy. In the early phase of rehabilitation, restrictions include limits on the amount of weight borne by the hip and its range of motion. In uncomplicated cases, crutches are used for approximately seven-10 days.^{2,6} In patients requiring repairs or who have extensive problems, the patient may be non-weight bearing for six-eight weeks.

Postoperative rehabilitation also includes continuous passive motion for the first four weeks for two-four hours per day.^{2,8} Starting immediately, patients are encouraged to ride a stationary bike with a high seat to avoid pinching. A slow progression to activity avoids over-activation or aggressive loading of the hip flexors, abductors and adductors, as these muscle groups are highly susceptible to fatigue and tendonitis postoperatively.⁴ Some patients will begin physical therapy as early as the next day, and some may begin two weeks postoperatively and may continue for four-eight weeks.⁶ This recovery usually covers three to four months, though patients may continue to see improvement in their symptoms for up to one year postoperatively.



FIGURE 3. (A) Arthroscopic view of left hip with arthroscope in anterior paratrochanteric portal. The femoral head is to the left, and the acetabulum is to the right. This image from a 17-year-old soccer player who had peripheral labral ecchymosis consistent with pincer impingement (white arrow) and a disruption of the labral-chondral junction with early chondral delamination consistent with cam impingement (black arrow). (B) The labrum (black arrow) was detached from the acetabular rim through the area of undersurface tearing with a beaver blade. Rim trimming was performed to the acetabular rim (white arrow) with an arthroscopic bur. (C) The labrum has been repaired/refixed to the acetabulum with 2 suture anchors (solid arrows), and traction has been released, which shows restoration of the normal sealing function of the labrum against the femoral head (dashed arrows).

CONCLUSION

Hip arthroscopy has evolved greatly in the last decade. Through improvements in equipment and techniques and a clearer understanding of indications and pathology, hip arthroscopy has become an effective means of treating a variety of intra-articular hip conditions. Though it is presently an uncommon procedure for surgical technologists, as this procedure requires highly-specialized training for the surgeons who perform hip arthroscopy, this is a procedure that will become more prevalent in the future.

ABOUT THE AUTHOR

Margaret Armand, CST, is currently working at Advocate Good Samaritan Hospital in Downers Grove, Ill. After 14 years in early childhood education she made the career change to surgical technology in 2004. She primarily works with the orthopedic surgery team.



Acknowledgements

Ms Armand wishes to recognize and thank Dr Benjamin G Domb for sharing his expertise, for his support, and encouragement with the writing of this article, Dr Rima Nasser for her editorial contributions, and most importantly her husband and family for their support.

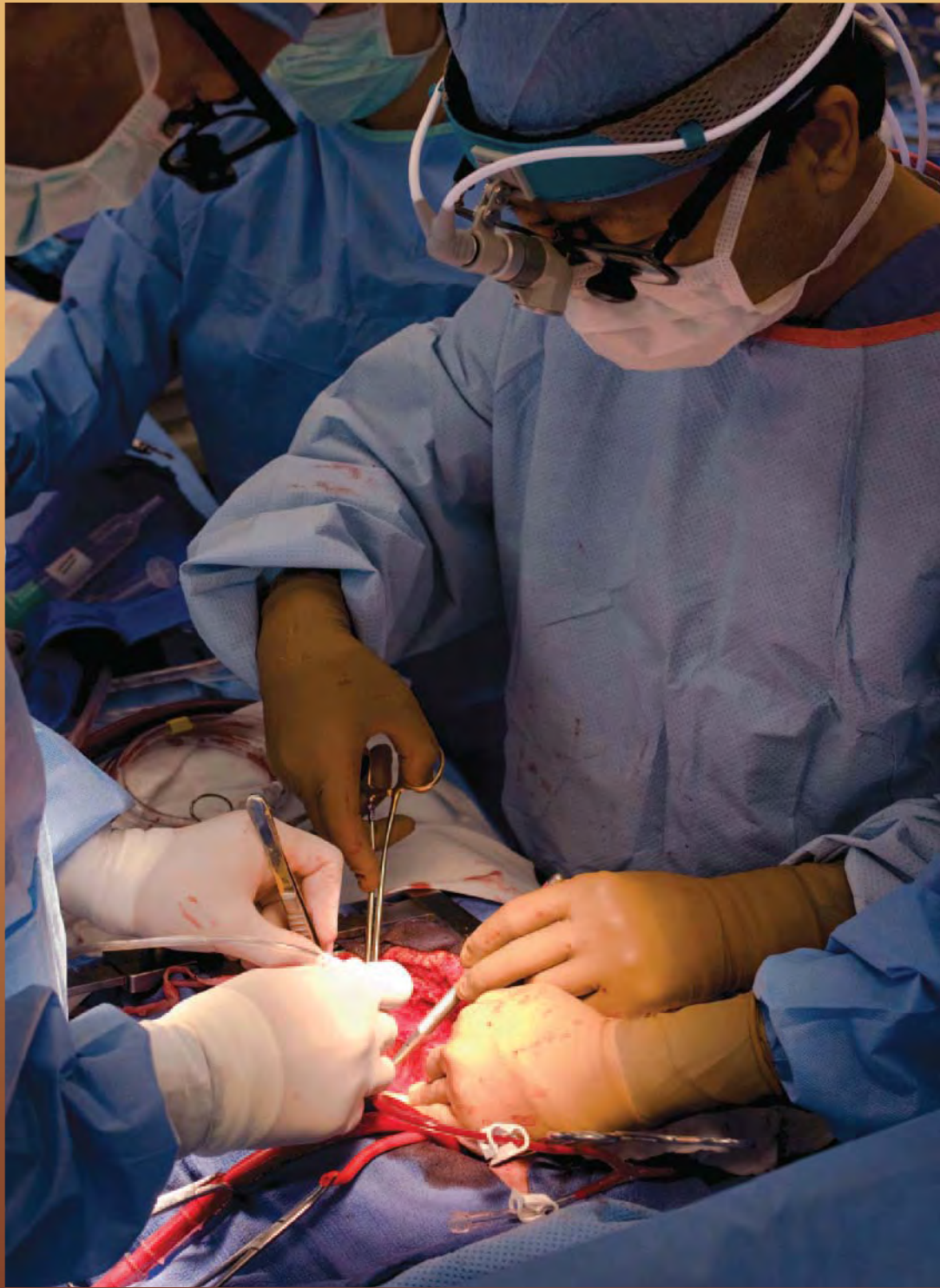References

1. Byrd, Thomas. 2006. "The Role of Hip Arthroscopy in the Athletic Hip." *Clinics in Sports Medicine*, 25. Accessed: May 9, 2009. Available at: <http://www.mdconsult.com/das/article/body/147272413-2/jorg=journal&source=&sp=16167525&sid=0/N/532245/1.html?issn=02785919>.
2. Carreira, D; Bush-Joseph, C. 2006. "Hip Arthroscopy." *Orthopedics*, 29. Accessed: April 1, 2009. Available at: <http://www.orthosupersite.com/print.asp?riD=17203>.
3. Shetty, V; Villar, R. 2007. "Hip arthroscopy: current concepts and review of literature." *British Journal of Sports Medicine*, 41. Accessed: July 1, 2009. Available at: <http://www.bjsportmed.com>.

4. Shindle, M; Domb, B; Kelly B. 2007. "Hip and pelvic problems in athletes." *Operative Techniques in Sports Medicine*, 15. 195-203.
5. Kelly B; Williams, R. 2003. "Hip arthroscopy: current indications, treatment options, and management issues." *American Journal of Sports Medicine*, 31. 1020-1037.
6. Tanner M. 2007. Central States Orthopedic Specialists. Accessed: April 1, 2009. Available at: http://www.csosortho.com/hip_arthroscopy.cfm.
7. McCarthy J; Lee, J. 2005. "Hip Arthroscopy: Indications, Outcomes, and Complications." *The Journal of Bone and Joint Surgery*, 87. Accessed: May 9, 2009. Available at: <http://www.ejbs.org/cgi/content/full/87/5/1137>.
8. Philippon, M; Schenker, M. 2006. "Arthroscopy for the Treatment of Femoroacetabular Impingement in the Athlete." *Clinics in Sports Medicine*, 25. Accessed: May 6, 2009. Available at: <http://www.mdconsult.com/das/article/body/147272413-2/jorg=journal&source=&sp=16167524&sid=0/N/532244/1.html?issn=02785919>.
9. Manaster, B; Zakel, S. 2006. "Imaging of Femoral Acetabular Impingement Syndrome." *Clinics in Sports Medicine*, 25. Accessed: June 13, 2009. Available at: <http://www.mdconsult.com/das/article/body/147272413-2/jorg=journal&source=&sp=16447420&sid=0/N/547983/1.html?issn=02785919>.
10. Newman, J; Newberg, A. 2006. "MRI of the Painful Hip in Athletes." *Clinics in Sports Medicine*, 25. Accessed: June 26, 2009. Available at: <http://www.mdconsult.com/das/article/body/147283531-2/jorg=journal&source=&sp=16447409&sid=0/N/547972/1.html?issn=02785919>.
11. Ruane, J; Rossi, T. 1998. "When Groin pain is more than just a strain." *The Physicain and Sports Medicine*, 26. 78-104.
12. Seldes, R; Tan, V; Hunt, J et al. *Anatomy, Histologic features, and Vascularity of the Adult Acetabular Labrum. Clinical Orthopaedics and Related Research*. 382:232-240, 2001.

For Further Reading

1. Byrd, J; Thomas. 2007. Arthroscopy Association of North America. Accessed: June 26, 2009. Available at: <http://www.aana.org/members/data/ElearningSystem/ReadContent.aspx?sid=536&videoname=State+of+the+Art+2007%3a+Indications+for+Hip+Arthroscopy&topicname=2007+Fall+Course&coursename=State+of+the+Art+2007%3a+Indications+for+Hip+Arthroscopy>.
2. Lubowitz, J; Poehling, G. 2009. "Who among us should perform arthroscopic surgery of the hip?" *Arthroscopy The Journal of Arthroscopic and Related Surgery*, 25. Accessed: April 1, 2009. Available at: [http://www.arthroscopyjournal.org/article/50749-8063\(09\)00106-6/fulltext](http://www.arthroscopyjournal.org/article/50749-8063(09)00106-6/fulltext).
3. Mohammed, R. 2007. "Riazuddin Mohammed: Initial Experiences of the Arthroscopy of the Hip." *Journal of Orthopaedics*, 4. Accessed: June 23, 2009. Available at: <http://www.jortho.org/2007/4/3/e9/index.html>.



The Open Thoracotomy Approach to Bronchoesophageal Fistulae Repair

by Sophanna Pech and Grant Drake

Bronchoesophageal fistulae are a relatively uncommon clinical condition that may present within a number of patient populations. Etiologies will include congenital malformation, trauma, malignancies, or secondary-to-inflammatory processes or infection.¹ Diagnosis of bronchoesophageal fistulae may be difficult due to its often-insidious nature of presentation.¹ The open thoracotomy and video-assisted thoracotomy are effective modalities of surgical intervention.²

This article will examine the common approach to clinical assessment and diagnosis of this disease state, as well as detail surgical technique with an emphasis on the specific role of surgical technologists in the open-thoracotomy-type procedure.

ETIOLOGY

Fistulae may result from congenital malformations, often presenting with esophageal atresia,³ a disordered formation of the esophagus in utero, which may cause disruption of the esophageal tissue and, in some cases, communication with the trachea and bronchi.⁴ Bronchoesophageal fistulae of a congenital nature are categorized into four typical presentations by Baimbridge and Keith.⁵

Type one fistulae occur as an esophageal diverticulum becomes subject to inflammatory processes, causing the endpoint to perforate the pleura to communicate with the bronchial lumen.

Type two fistulae are the most common,¹ and are also known as “H-type” fistulae. This configuration will feature direct tissue communication between esophageal and tracheal lumen.

LEARNING OBJECTIVES

- ▲ Review the relevant anatomy for this procedure
- ▲ Examine the set-up and surgical positioning for this procedure
- ▲ Compare and contrast the osteoplasty-cam procedure and the acetabuloplasty-pincer procedure.
- ▲ Assess the indications for femoroacetabular impingement
- ▲ Evaluate the recovery and rehabilitation process following FAI

Type three consists of fistulous tissue connection between the esophagus and a lobar cyst, which in turn communicates with the bronchus.

Type four involves fistulous tract connection with sequestered parenchyma. Parenchymal sequestration occurs as a congenital malformation in which an area of parenchymal tissue is separated from the bronchial tree and is not vascularized by the pulmonary vasculature in the typical fashion,⁶ nor does it participate in oxygenation or ventilatory activity. This parenchymal lesion is instead supplied blood by the systemic circuit, according to Boetzkes *et al*, “[it] is supplied with blood from an aberrant artery mostly originating in the thoracic aorta.”⁷

More commonly, bronchoesophageal fistula may present secondary to a variety of malignancies,⁸ including but not limited to Hodgkin’s lymphoma, esophageal carcinomas and bronchogenic carcinomas. Additionally, bronchoesophageal fistula may present secondary to occupational exposure to respiratory irritants such as asbestos and silicone, or as a complication of infectious processes where cavitating lesions may occur as in the fungal infection histoplasmosis.⁸

PATHOPHYSIOLOGY

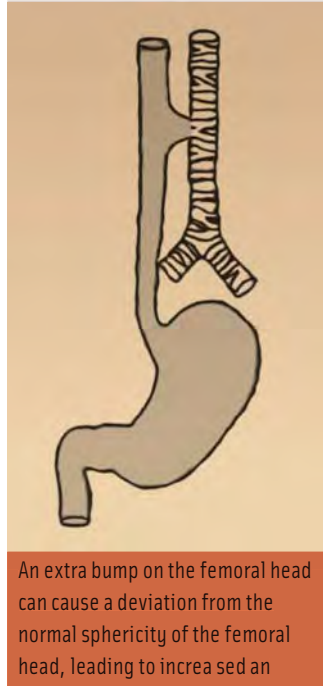Bronchoesophageal fistulae may originate in either the trachea or esophagus but will eventually involve each tissue type. This article examines the anatomical makeup of each organ and discusses pathological changes that may occur as fistulae evolve from both conducting airways and the esophagus.

The respiratory system is subdivided into two main regions. The first is the upper respiratory tract, which consists of the nose, nasopharynx, mouth, and oropharynx, where air is drawn inward upon inhalation and released during exhalation. The second is the lower respiratory tract,¹⁰ which starts at the laryngopharynx and continues through the larynx (which includes the epiglottis), trachea, carina (where the trachea bifurcates), and the bronchi. At

the carina, the bronchi separate into the right and left mainstem bronchi. As air moves distally throughout the bronchi, the conductive airways become progressively smaller in diameter, contain a decreasing amount of cartilage, and bifurcate numerous times, eventually reaching respiratory bronchioles and finally the alveoli where the actual gas exchange occurs. The alveoli make up the majority of the parenchymal surface area of the lung along with the pulmonary capillaries.

The esophagus begins at the level of the epiglottis and continues posterior to the trachea which is typically 10-11 cm long and typically will be 1.5-two cm in diameter in adults and is made up of semi-circular cartilaginous rings which are “c” shaped with no cartilage over the area where tracheal smooth muscle sits in direct contact with the esophagus.¹⁰ The one exception to the “c” shaped cartilaginous rings is the cricoid cartilage, which is a continuous cartilaginous ring and sits at the base of the larynx directly inferior to the thyroid cartilage. Patency of the alveoli is maintained by radial traction,¹² the pressure of the alveolar units themselves creating negative pressure against the parietal pleura pulling the small airways open. The trachea and both mainstem bronchi contain smooth muscle, connective tissue and a luminal surface of ciliated columnal epithelium interspersed with mucous-producing goblet cells. The trachea, mainstem bronchi, and conducting airways are lumenally coated with a sol and gel type colloid,¹³ or according to Schürch, “an aqueous substrate which covers the surface of the conducting airways consist[ing] of water, ions, sugars, proteins, proteoglycans, glycoproteins and lipids,”¹⁴ which is moved upward in airway clearance by cilia and smooth muscle function as in a cough.

In the case of bronchoesophageal or tracheoesophageal fistula, the most common type of communicating fistulae will occur as this posterior noncartilagenous area of trachea or mainstem bronchus is perforated. In neoplastic disease states, such as a squamous cell carcinoma, neoplasia within tracheal smooth muscle may result in exophytic or ulcerative lesions,⁸ causing erosion of the tracheal wall from within the epithelium moving outward, or beginning with disruption of the superficial layer of ciliated columnar epithelium, and leading to eventual erosion of connective tissues and basal cells until perforation occurs. Neoplasms may then extend extraluminally into the esophagus, eventually creating a communication between trachea and esophagus as the neoplasm expands and invades esophageal tissue.



Congenital type bronchoesophageal fistulae often occur in embryonic development. In gestational-week four, lungs begin to form as respiratory diverticuli emerge from the foregut epithelium,¹⁵ and in subsequent weeks, a tracheoesophageal ridge and the tracheoesophageal septum form to separate trachea from esophagus. In the case that this septum is not formed completely, bronchoesophageal fistula will result.

The esophagus connects the laryngopharynx with the stomach and digestive organs of the alimentary tract. It is composed of smooth muscles and is an average of 25 cm long and terminates at the lower esophageal sphincter (also called the cardiac sphincter),¹⁰ the entrance to the stomach. As the esophagus contains no cartilaginous surfaces, it is subject to constriction in areas where it meets with other anatomic surfaces. Narrowing occurs as the esophagus passes by the aortic arch, the left mainstem bronchus and the diaphragm. Histologically, the esophagus is composed of four tissue layers, the luminal mucosa layer, submucosa, muscularis and an outer layer called the serosa or adventitia.¹⁰ The mucosal layer is made up of stratified squamous epithelial cells, but also contains goblet cells, which produce mucous. The

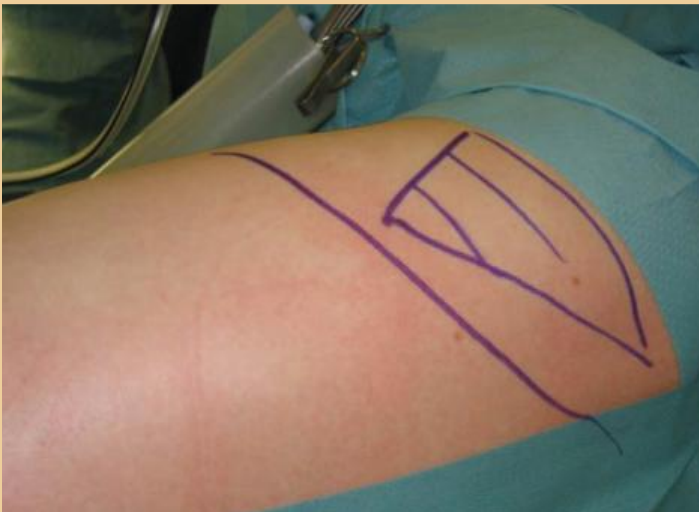submucosal layer also contains mucous-producing cells, as well as vasculature, nerve fibers and some smooth muscle

Since most hip joint pathology is found within the intra-articular region, distraction is necessary to achieve arthroscopic access.¹ Determining the signs and symptoms that suggest intra-articular pathology are essential.

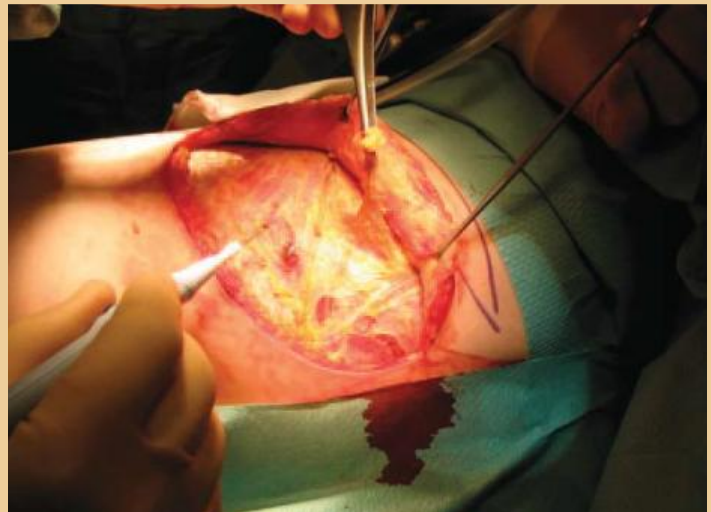
fibers. The muscle tissue contained in the third layer consists of longitudinal and circular smooth muscle tissue, which carries the major workload of peristaltic activity. The outer layer of the esophagus contains a thin, fascial layer of connective tissue housing vasculature and is considered an adventitial layer except when in contact with the trachea, when it is then considered the outer serosa.¹¹

DIAGNOSIS

Diagnosis of bronchoesophageal fistula is considerably complex in that congenital-type fistulae may go undiagnosed for a number of years if the configuration is such that both the esophagus and conducting airways maintain relatively



The patient is prepped and draped in routine fashion. The skin incision and its relation to the scapula are marked with a sterile marking pen. The patient is prepped and draped in routine fashion.



The skin is incised with a scalpel. Fat and fascia are divided with cautery as far as the muscle fascia. The triangle of fascia between the trapezius and latissimus is rasied, exposing serratus and the rhomboid muscles deeply

Images courtesy of Kieran McManus

normal patency.¹ In cases such as this, bronchoesophageal fistula may be considered when a patient has a significant history of pneumonia and respiratory infection, particularly if these are found to be associated with aspiration-type events. A patient may present with a chronic cough of moderate to paroxysmal characteristics. Paroxysmal cough is a very sudden and severe form of cough, a “coughing attack,” which involves extreme muscle stricture and spastic movement of airway musculature. Cough may present in either a productive or nonproductive nature, dysphagia and, less commonly, hemoptysis may also occur.¹

Common diagnostic procedures for any of the malignant or congenital types include bronchoscopy, esophago-gastroduodenoscopy⁹ and contrast esophogram with barium swallow or methylene blue instillation. Imaging may show chronic, inflammatory-type changes to the airway including bronchiectatic configurations of the bronchus,¹⁴ consistent with multiple aspiration events and esophageal pathologies including, but not limited to, diverticuli or esophagomalacia.

INDICATIONS FOR SURGICAL INTERVENTION

Dysphagia is of particular concern in judging surgical candidacy as this may lead to aspiration events, chronic cough, chronic infection and suppurative-type pulmonary lesion.

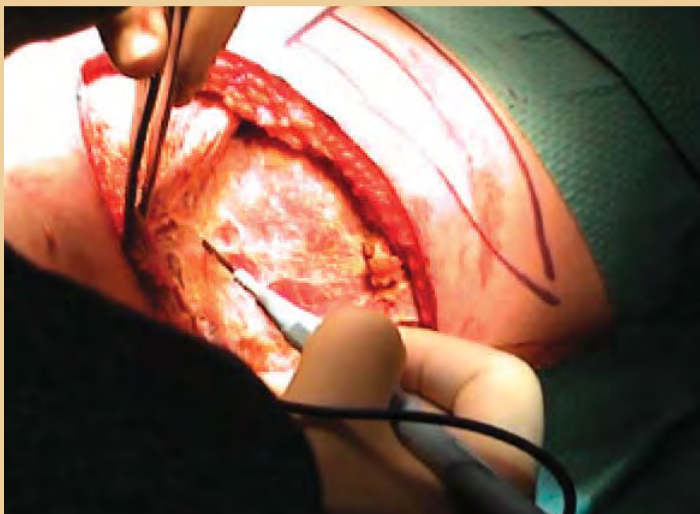
It has been recommended by Altorki and colleagues that all patients with thoracic esophageal diverticulae consider surgery as fistula may result.¹⁷ Additionally, surgical management in malignant-type cases is with precedent, and timely excision in some cases may be prophylactic to development of fistulae. In cases where recurrent infection and lack of maintainable patency in either airway or esophagus occur, surgical intervention is indicated.

SURGICAL TECHNIQUE

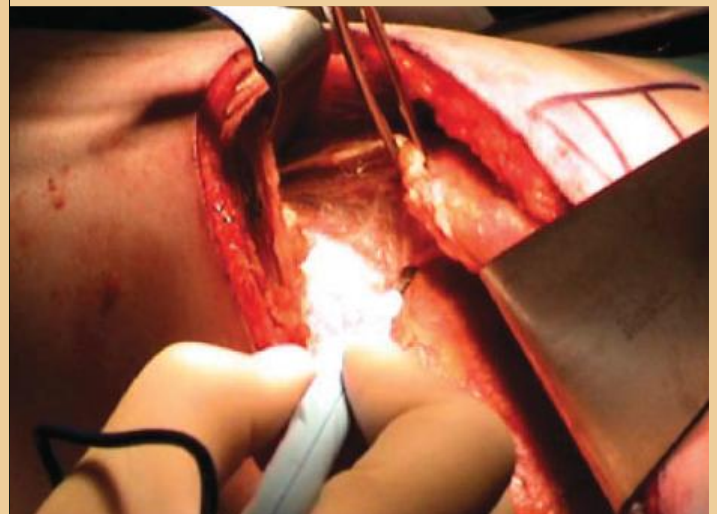
Bronchoesophageal fistulae are managed according to configuration and location of the fistula. Both open surgery and video-assisted thoracotomy are utilized and have proven to be effective in fistulae closure.

Preoperatively, the patient is positioned according to ease of access to the fistula. This will typically be lateral or supine positioning.¹⁸ The example used in this article shall assume lateral positioning and fistula between lower respiratory tract, for instance the right middle lobe segmental bronchi and esophagus.

Prior to positioning, the patient will be anaesthetized and intubated with a double lumen endotracheal tube in the supine position. If available, two compatible ventilators may be synchronized to allow for independent lung ventilation to anticipate upcoming deflation of the operative lung.



The latissimus is freed from the underlying serratus. Care must be taken not to damage the neurovascular supply to the serratus, which lies on the superficial surface of the muscle. Similarly, the trapezius is freed from the underlying rhomboids.



The serratus fascia is now incised as in a standard postero-lateral thoracotomy.

The nonsterile surgical team members then position the patient in the left lateral position. The patient will be positioned so as their nonoperative side will contact the table. Sequential compression devices are applied to the legs to prevent embolic activity, then the leg proximal to the oper-

relieve pressure placed on the brachial plexus. Rolled blankets are placed under the scapula on the nonoperative side. Finally, three-inch safety straps are placed over the thigh and shoulder to ensure stability.

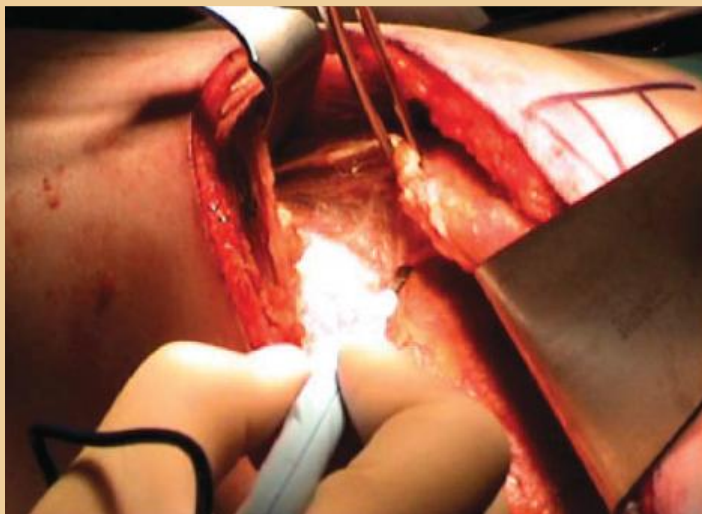
During the procedure, an initial diagnostic arthroscopy is performed and the structures of the hip joint are examined.¹ The femoral head is observed for chondral deformities or damage, as well as the surface of the acetabulum, the condition of th

ating table will be slightly flexed at the knee and abducted toward the chest. A pillow is then placed under the knee. The leg will be padded so contact with the table will not disturb the peroneal nerve. Arms are placed and secured on padded armboards with the superior arm pronated and slightly flexed, and the inferior arm positioned so the wrist is supinated and exposed so radial pulse may be palpated if necessary, and to protect the ulnar nerve. Additionally, a small roll is placed under the patient just below the last rib along the axillary line to allow for chest expansion, and to

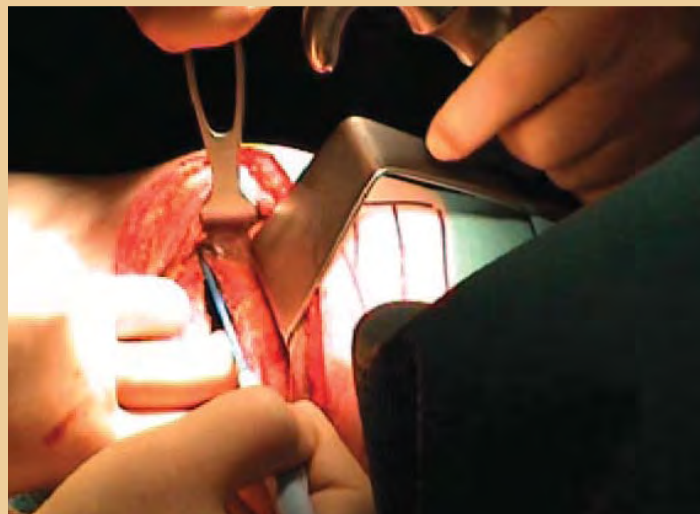
When positioning is complete, the patient is prepped for initial incision with application of topical anti-microbial preparatory agents to the area from the axilla to iliac crest, and bilaterally beyond the midline or to the table top. The incision site is then draped in a square configuration with towels, then a laparotomy drape is applied exposing only the incision site.

Various supplies are required to ensure proper patient and clinician safety in the thoracotomy procedure. The required equipment may include Bair-hugger®, cell saver, electro-surgical generator, smoke evacuator, arm boards and connected and functional suction.

Instrument sets commonly utilized are the thoracotomy tray, minor orthopedic tray and major vascular set.¹⁸ Blades required are #10, #15, and electro-surgical unit. Thoracotomy trays will typically contain large ratcheting, self-retaining retractors such as the Toufier and Reinhoff, which may be used to retract large areas of tissue, a Davidson scapula



The serratus is further dissected off the underlying ribs



The intercostal incision continues anteriorly.

Images courtesy of Kieran McManus

retractor and various smaller handheld retractors.

The thoracotomy tray may also include sternal needle holders and Duvall lung-grasping forceps, which are important for manipulation of the lung. The minor orthopedic tray is also commonly used and contains a variety of available retractors and forceps types as well as bone and soft tissue-cutting instruments, such as the Metzenbaum, which

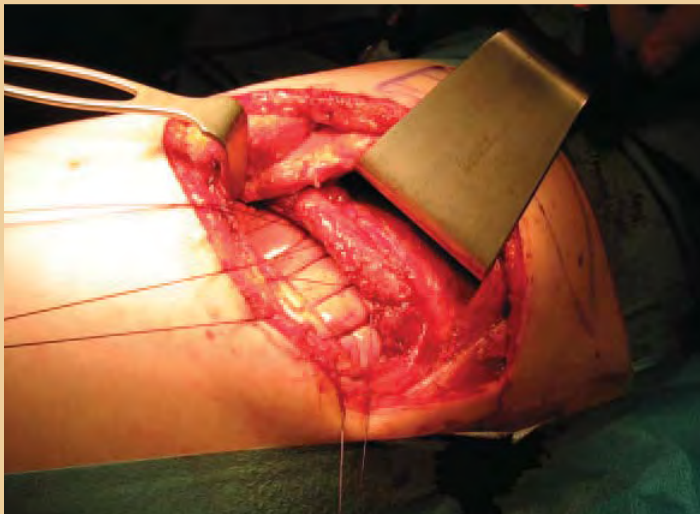
In order to prevent a possible fracture, a resection of less than 30 percent of the head-neck junction is recommended because this has been shown not to alter the load-bearing capacity of the femoral neck.^{4,8}

may be utilized at the surgeon's preference in place of the ESU or scalpel. Frasier suction tips are included for suction, and skin hooks for manipulation of distal tissues, the double prong hooks may be particularly useful in this respect.

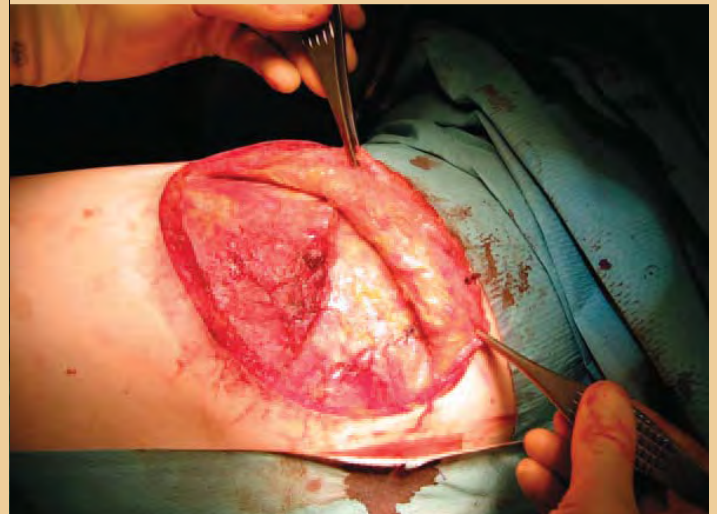The initial incision via #10 blade is made in the fourth or fifth intercostal space following the line of the rib.⁸ The incision runs laterally across the area of the fifth rib and is extended around the scapula cranially to the midline of the

scapula. Subcutaneous tissue is divided with an ESU. The latissimus dorsi is divided, and then deep to the latissimus dorsi, the serratus anterior is divided. The rhomboid muscle may be divided as well to allow retraction of the scapula.¹⁸ The surgical assistant may retract the musculature with a Richardson hand-held retractor to allow access to the intercostal muscle. When the intercostal muscle is visualized, the fascia and muscle are divided with an ESU. Care is taken to make the incision as low in the intercostal space as possible to avoid the intercostal blood supply and innervation.

Next, a rib-spreader is placed, allowing for ease of visualization and access to a fistula between lower respiratory tract and esophagus. At this time, the surgeon may elect to partially dissect the laterally-running band of intercostal muscle from the posterior aspect of the muscle to later use as a pedicle upon fistula closure in the case of large fistula.⁸ The #10 blade, or ESU, continues to incise deeper until the lungs are visualized. The lung is deflated. Upon visualization of the lung, Duval clamps are used to manipulate the lung. The surgical assistant will assist the surgeon in holding the clamps to allow for visualization of the fistula. Upon visu-



The upper blade of the retractor is inserted directly adjacent to the rib, applying no pressure to the intercostal nerve.



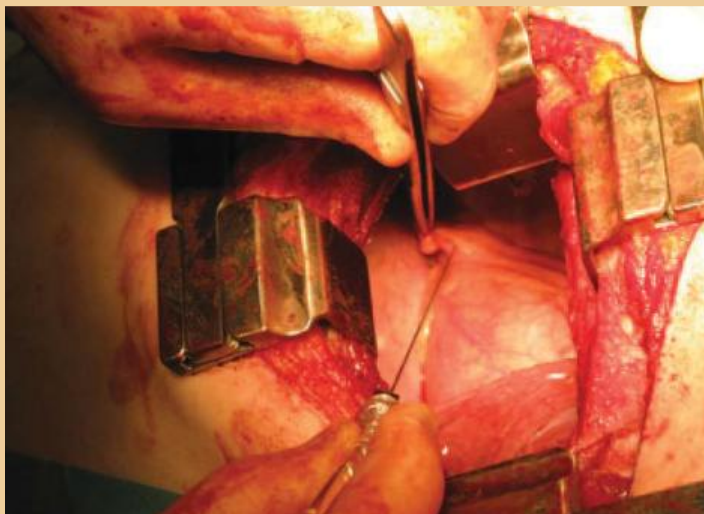
A second DeBakey rib spreader is placed at right angles to the first to retract the latissimus and serratus forward and the trapezius backwards.

alization of fistula, the esophagus is dissected immediately superior and inferior to the fistula⁸ and hand-held retractors may be placed and held with the help of the surgical assistant to separate bronchus from esophagus allowing for a clean visualization of the communicating portions of tissue. A #15 blade or ESU is then used to longitudinally incise the fistulous tissue. The surgical technologist will provide the surgeon with a series of 4-0 polyglactin 910 sutures, at which time the bronchus and esophagus are sutured in an interrupted technique.

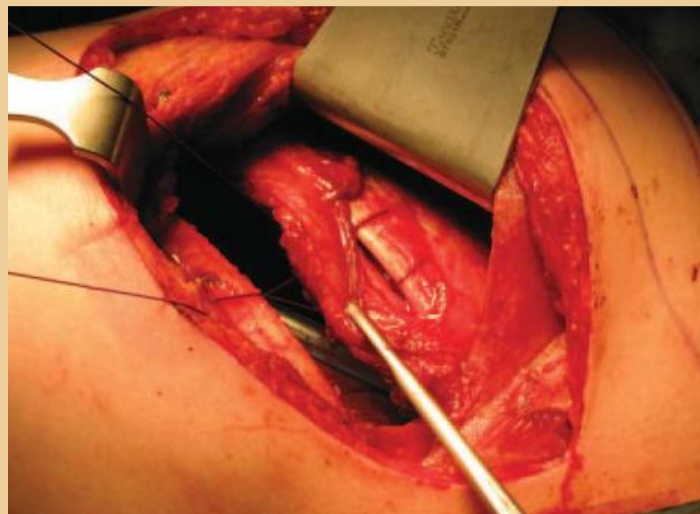
In cases involving large fistula or circumferential compromise of tissue integrity, resection and anastomosis is performed at this point if the lesion is found to be too large to be managed in a more tissue sparing fashion. The compromised tissue is excised via #15 blade or ESU in a lateral incision running the entire distance of the tissue surface slightly superior and inferior to damaged tissue. The surgical assistant will then assist with dandy nerve hooks to maintain the desired position and allow the surgeon visualization and access to the luminal space. Several traction sutures of 4-0 polyglactin 910 are placed around the circumference of the resection above the incision site. The sutures are placed in interrupted fashion and serve the purpose of relieving some of the tension placed on the anastomosis itself. Several techniques have been utilized in anastomosis and have been

found to be effective, including continuous or interrupted suturing.¹⁷

Pericardial fat is commonly used^{19,20} in bronchial closure during pneumonectomy, and Grillo has recommended utilizing pericardial pedicle placement in bronchoesophageal fistula closure using the Brewer technique²¹ in cases requiring resection of trachea and esophagus. The Brewer technique is a surgical technique that utilizes the fatty tissue that overlays the parietal pericardium anteriorly or laterally. A flap is made from the pericardial fat, which is not excised completely but remains connected on one side and has its innervation and vasculature preserved. According to Komanipalli and Sukumar, the pedicle will retain its connection to arterial flow via the superior, inferior and middle branches of the internal mammary artery and its venous return via the pericardiophrenic vessels.²² Pericardial fat pad placement involves ligation of the aforementioned vasculature and possibly the azygous vein if a large flap is necessary. Ligation is accomplished with a 0 silk suture on a needle because silk sutures are considered nonabsorbable. These ligations will need to remain in place for the pedicled tissue to retain blood flow. As this lateral strip of pericardial adipose tissue is mobilized, it is then wrapped around anastomosis sites of both the trachea and esophagus.²³ The surgical technologist then hands the surgeon a 4-0 polyglactin 910



Prior to closure, drains are placed and a long-acting anesthetic is injected into the phrenic nerve fat pad, reducing shoulder-tip pain.



Three or four pericostal sutures are placed in such a way that the neurovascular bundle is elevated. The lower intercostal nerve is protected by the groove in the rib.

Images courtesy of Kieran McManus

mounted on a needle and the fat pad is sutured in, mattress-style.⁸ In order to complete graft placement between the lower airway bronchus and esophagus, as in this example, intercostal muscle that was incised upon initial incision is sutured between the repaired fistula with mattress-style sutures, again using 4-0 polyglactin 910. Pedicle selection will ultimately depend on the location of the fistulae. After pedicle placement, all counts are performed and the thorax is closed per standard practice. A chest tube connected to a Pleurevac® is inserted to allow for drainage and to maintain inflation of the lung. Its sizing will depend on patient size, but a 30 French tube is common in adults. This will be sutured in place with a 2-0 monofilament cutting needle and dressed with a center split 4x4 sponge, which will be placed around the tube. The wound site is dressed with vaseline gauze and an adhesive, non-woven wound dressing.

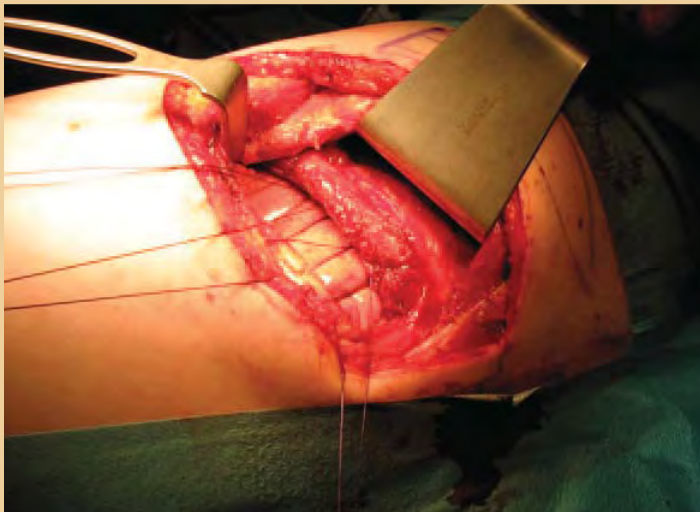
POSTOPERATIVE CONSIDERATIONS

The patient will be managed postoperatively in the surgical intensive care unit or post-anesthesia care unit as the potential for serious postoperative complications, such as hemorrhage and pneumothorax, exists and careful monitoring is essential. The patient is particularly at risk for nosocomial infection, particularly hospital-acquired pneumonia related to mechanical ventilation and sepsis secondary to opera-

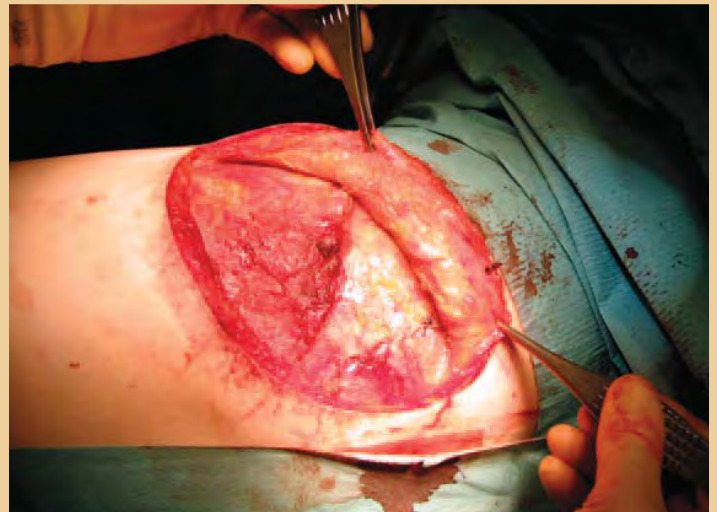tive site infection if dressings are not carefully managed and antisepsis is not meticulously maintained. The patient will initially arrive in the unit intubated, but as anesthesia and sedation levels begin to dissipate and pulmonary mechanics and arterial blood gasses return to clinically acceptable levels, the patient is quickly weaned from mechanical ventilation and extubated. Prolonged mechanical ventilation may significantly increase morbidity and mortality.¹¹

In order to prevent compromise or infection of the anastomosis or fistula closure, patients are initially placed on parenteral nutrition and, after several days, may be allowed liquids as indicated by successful swallowing evaluation. Swallowing evaluations are typically conducted by speech therapists. These evaluations may include a request for a barium swallow and contrast radiography.

The patient will swallow a liquid barium solution and X-rays will be taken to assure patency of the fistula repair and that aspirative events are not occurring. Care is taken to provide the patient with hyperinflation therapy and secretion clearance techniques as bronchial hygiene is vital to reducing the risk of incision-site infection and postoperative pneumonia. The patient will typically follow a regimen of respiratory therapy treatment including incentive spirometry or intermittent positive pressure breathing therapies to ensure adequate deep breathing and prevent



The pericostal sutures are tightened to re-approximate the ribs



The fascia of the auscultatory triangle is now re-sutured to the latissimus and the trapezius to maintain their anatomical positions.

atelectasis. During incentive spirometry, the patient inhales through the incentive spirometer device, which will measure the volume of air the patient is able to inspire. This is used to encourage deep breathing, provide the patient with a visualization of deep breathing goals and allows the respiratory therapist to measure the volume of gas inspired to assess lung expansion and respiratory effort. Therapies such as intermittent positive pressure breathing function in the same manner, but provide the patient assistance by delivering an additional degree of ventilation upon inspiratory effort.

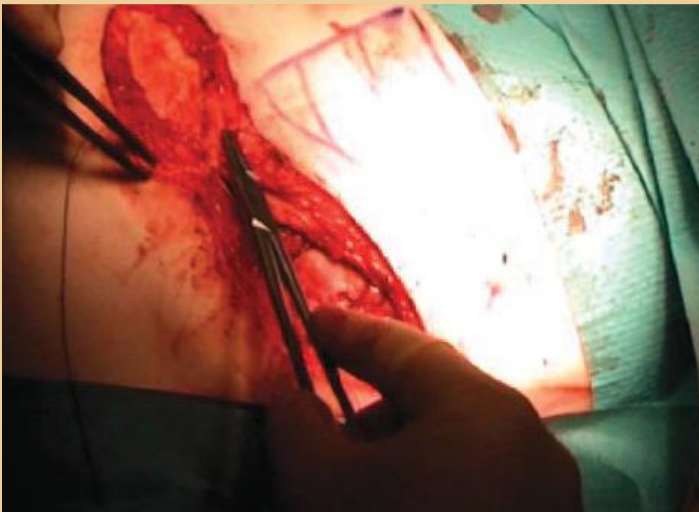
CONCLUSION

Although tracheoesophageal fistula and bronchioesophageal fistula are relatively rare, understanding the pathology of their surgical technique will aid the surgical technologist in developing critical and anticipatory thinking in regards to instrument choice as well as gaining an understanding of thoracic and pulmonary anatomy and physiology. Surgical literature includes various additional techniques that may be utilized in these cases, including bronchial or esophageal stenting, video-assisted thoroscopic approaches and various wound-sealing choices, including surgical gluing and endoscopic clipping. These techniques may be used as an adjunct or alternative to the open technique examined herein.

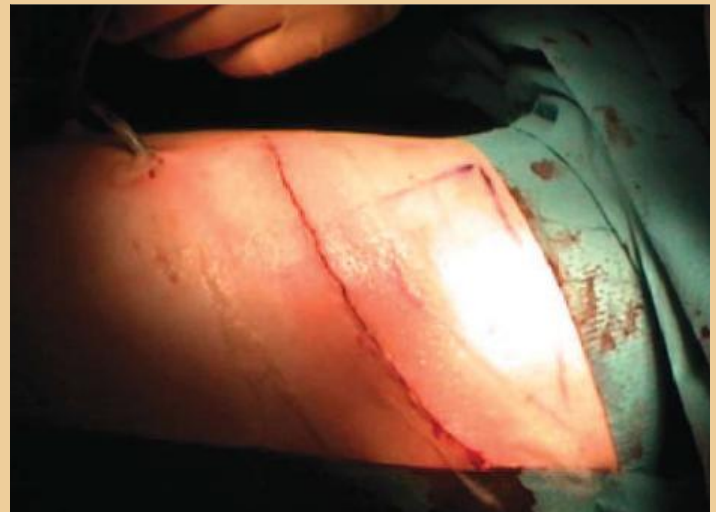
ABOUT THE AUTHORS

Sophie Pech is currently employed as a surgical technologist in the St Luke's Regional Medical Center cardiovascular surgery unit in Boise, Idaho. She is a recent graduate of The College of Western Idaho Surgical Technology Program and is currently awaiting the results of her credentialing examination.

Grant Drake is a recent graduate of the Boise State University Respiratory Therapy Program. In August 2010, he will begin the post-Baccalaureate pre-Medical program at Duquesne University and hopes to attend medical school in the future.

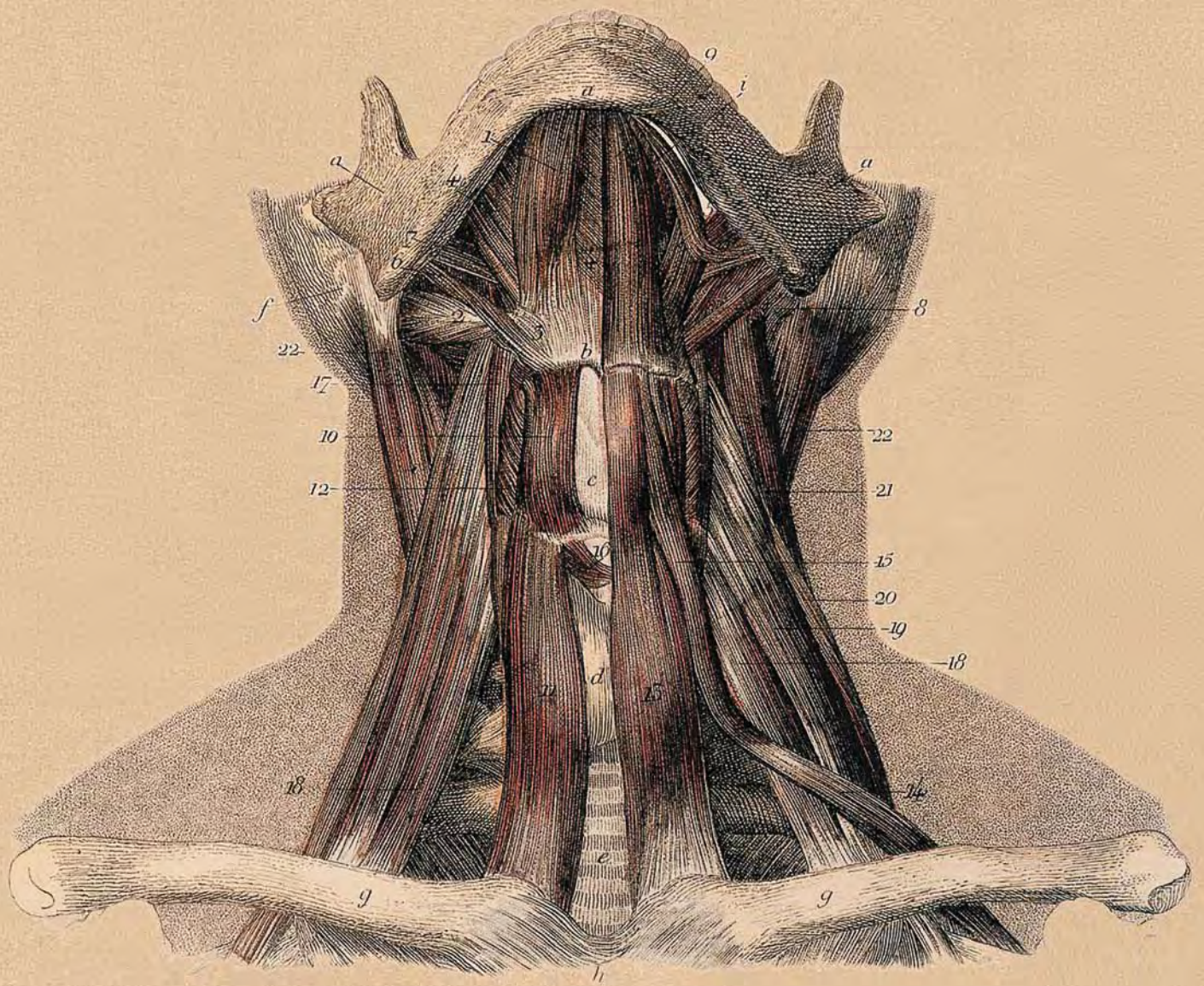

After placing a stay suture at the midpoint of the fascial layer to ensure the two sides are properly aligned, the subcutaneous fascia is closed with running polyglactin 910. A routine subcuticular polyglactin 910 suture closes the skin.



The final result.

Images courtesy of Kieran McManus



Platysmaplasty

A surgical resolution for the “turkey neck”

by Nydia I Morales, CST

The term “turkey neck” refers to the lateral ptosis of the frontal neck derma. This can occur when the platysma muscles separate, a result of natural weakening of the ligaments in the cervical region, as well as excessive lipid build-up. Other causes of this condition include genetics, bone loss and decline of skin elasticity—possibly from weight loss. It is most commonly regarded as a factor of aging, although sun exposure and smoking may also contribute.

For patients who are interested in reducing the loose look of sagging skin in the neck area under the jaw line, a platysmaplasty, or neck lift, is an option. It can be performed in conjunction with a face lift, but it is often performed as a stand-alone procedure. This article examines the surgical options for resolving turkey neck, as well as alternatives to surgery.

ETIOLOGY AND ANATOMY

The platysma muscle is one of a pair of plate-like, wide muscles at the side of the neck. It arises from the fascia covering the superior parts of the pectoralis major and the deltoideus. It crosses the clavicle and rises obliquely and medially along the side of the neck. The platysma covers the external jugular vein as the vein descends from the angle of the mandible to the clavicle. It is innervated by the cervical branch of the facial nerve and serves to draw down the lower lip and the corner of the mouth. When the platysma fully contracts, the skin over the clavicle is drawn toward the mandible, increasing the diameter of the neck.¹

The muscle has several distinct points of reference. It is attached to the mentum and the inferior madibular edge and

LEARNING OBJECTIVES

- ▲ Review the relevant anatomy for this procedure
- ▲ Examine the set-up and surgical positioning for this procedure
- ▲ Compare and contrast the differences between an in-office procedure and a typical OR procedure
- ▲ Assess the indications for platysmaplasty
- ▲ Evaluate the recovery process, as well as the potential postoperative complications for platysmaplasty

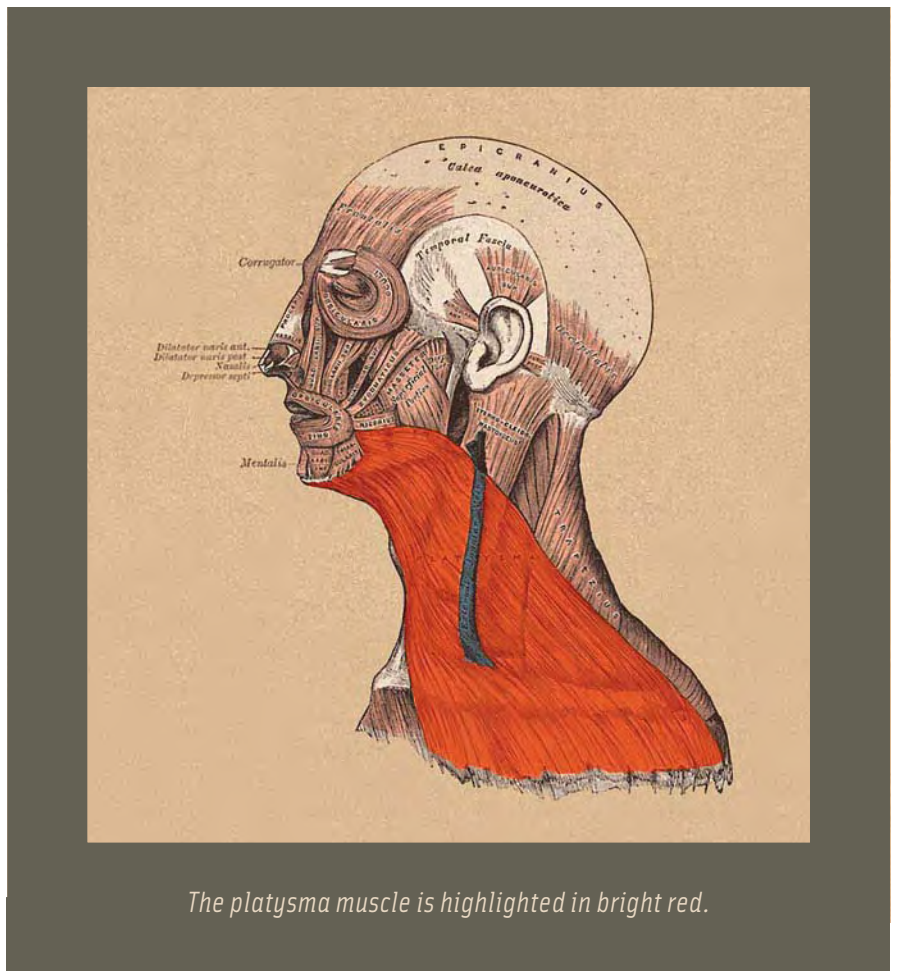
intersects the orbicularis oris laterally and the depressor anguli oris.² The skin of the cheek and the anterior neck is comprised of three interconnected layers: the superficial epidermal-dermal layer; the underlying subcutaneous fat; and a gliding membrane composed of fibro-elastic connective tissue and muscle. This gliding membrane is called the superficial musculo-aponeurotic system (SMAS).² The SMAS aids in reattaching the muscle, producing a younger, smoother facial appearance. The fat of this superficial layer consists of lobes that lie randomly on the face and intersect with the fibrous tissues of the SMAS. Thicker layers of fat are found in the neck and cheek area. The deep fat layer is thin and divided by fibrous bands. The ligaments hold the soft tissue and anchor it to the bone.³

PREOPERATIVE PREPARATION

The patient is required to cease smoking and consuming alcohol for two weeks prior to the procedure. This is to help ensure proper healing postoperatively. In addition, aspirin should not be taken preoperatively as it can cause bleeding. The patient should wear comfortable clothing during and after the procedure to facilitate nonrestrictive circulation. Baggy clothing or a sweat suit is encouraged.

Vital signs, including blood pressure and pulse oximeter readings are recorded and close attention is given to any irregularities, such as cardiac dysrhythmia.

The surgeon will review the procedure with the patient, as well as take a complete medical history. Photos of the patient are taken to provide a before-and-after comparison. The surgical technologist remains in the OR suite for the duration of the procedure to monitor the patient at all



The platysma muscle is highlighted in bright red.

times. There is no circulating nurse or anesthesiologist present. Prior to the procedure, the surgical technologist confirms that the consent form has been signed and counter signs it. He or she also reviews all medical entries at this time. Vital signs, including blood pressure and pulse oximeter readings are recorded and close attention is given to any irregularities, such as cardiac dysrhythmia.

The choice of anesthetic will vary depending on several factors, including the patient's overall health, medications the patient is currently taking and the number and length of time of the procedures being performed. Patient and surgeon preference are

also considered. A platysmaplasty alone can be performed under general anesthesia, with IV sedation or local anesthesia. Most cases are done in-office and are performed under local anesthesia.

The local anesthetic for this procedure is a tumescent solution: a combination of 400 ml normal saline, 90 ml one percent lidocaine without epinephrine, 10 ml 8.4 percent sodium bicarbonate and one ml of epinephrine 1:1000.

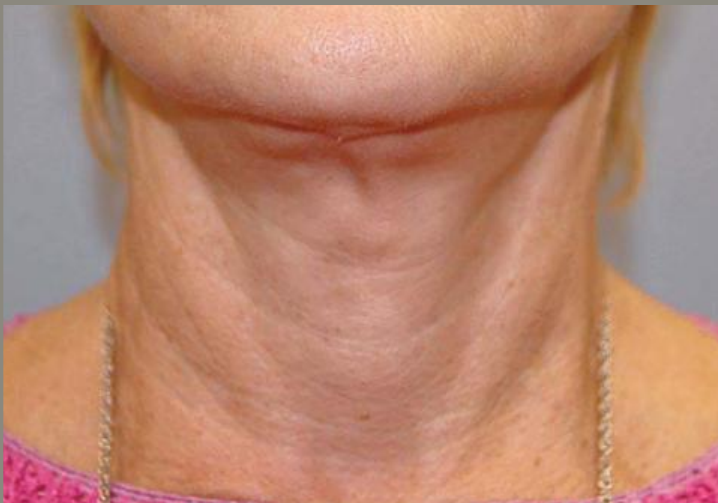
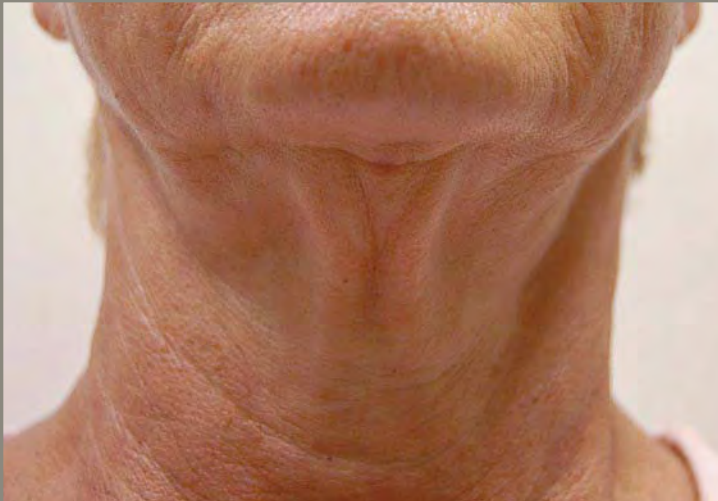Preoperative antibiotics are also administered to prevent bacterial infections. Cephalexin is the primary antibiotic of choice as it can be used in patients with certain heart problems as a means to prevent coronary infection (bacterial endocarditis). Cleocin may be used to fight bacterial infections in patients who are allergic to penicillin. Azithromycin—known as z-pack—may be used postoperatively. In most cases, a sedative is used. Five to 10 mg of diazepam is administered sublingually to treat anxiety in patients who request it. The sedative is used based on patient preference; however, the surgeon will dictate the dose to be administered.

The patient is placed in the seated position and the surgical technologist cleans the patient's neck with surgis-crub. The patient's thoracic region is draped in order to create and maintain the sterile field during the procedure. The surgeon then outlines the planned incisions with a sterile marking pen on the submental region. The local anesthetic is administered by injection into the surrounding area.

The surgical technologist sets up the Mayo stand with the following instrumentation:

- ▲ #15 knife blade and knife handle
- ▲ Army-Navy retractor
- ▲ Adson forceps with teeth
- ▲ DeBakey tissue forceps
- ▲ Needle holder
- ▲ Curved and straight Metzenbaum scissors
- ▲ Small mosquito (placed to the side in case it is needed)
- ▲ 4x4s
- ▲ 5.0 nylon suture
- ▲ 2.0 PDS

- ▲ Surgeon's magnified intense glasses
- ▲ Electrosurgical pencil with needle-tip electrode (ESU)
- ▲ 0.9 percent sodium chloride for irrigation and kidney basin
- ▲ Long tip cotton applicator
- ▲ Elastic bandage (wrap)
- ▲ Sutures and dressings of the surgeon's preference



Copyright/property of Kamran S. Jafrri, MD

In addition, the surgical technologist will lay out the sterile gloves, bouffant/cap and the head light source to be used during the procedure.

OPERATIVE PROCEDURE

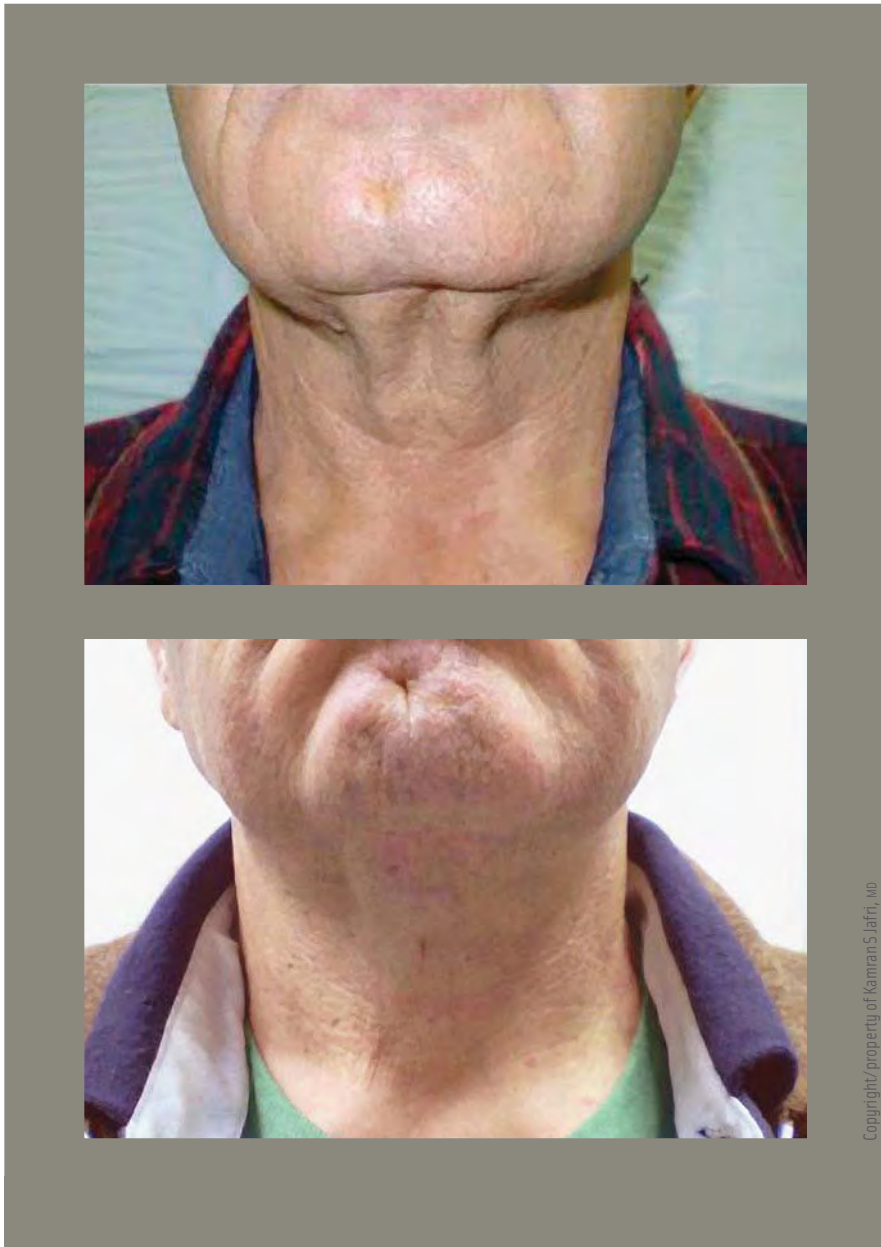
Using the #15 blade, the surgeon makes a one-inch submental incision. The ESU is then used to coagulate the blood vessels while the surgical technologist pats the area dry using the sterile 4x4s. Using a toothed Adson forceps to grasp the external derma, the dissection is continued subcutaneously, in a horizontal direction of the submental region. Using a straight Metzenbaum scissor, the surgeon separates the subcutaneous layer from the platysma muscle and exposes the fat pad.

The surgeon inserts an Army/Navy retractor approximately one inch into the incision, creating an open pocket, which is held in place by the surgical technologist. The surgeon then removes any excess adipose tissue by grasping it with a DeBakey in one hand and cutting it using a curved Metzenbaum scissor with the other. The surgical technologist removes the excised fat from the DeBakey with a 4x4. The ESU is used throughout to coagulate additional blood vessels as needed. Opened and elongated 4x4s are saturated in saline and inserted momentarily into the subcutaneous path for irrigation purposes, during which time the Army/Navy retractor is removed. When the 4x4 is extracted, the Army/Navy retractor is reinserted. The surgical technologist must keep an accurate count of the 4x4s during this process. This series of actions is repeated until the surgeon is satisfied that all necessary excess fat has been removed and the platysma muscle is sufficiently exposed.

Using the DeBakey, the surgeon collects both posterior ends of the platysma muscles that have separated and trims any uneven edges in order to suture them together with a 2.0 PDS (non-coated, monofilament polydioxanone suture), using a reverse mattress stitch, to load and release the memory. The external submental derma is then flattened out and the excess is approximated to determine the

appropriate length to trim based on the initial incision line or cervicoplasty.

Using an Adson forceps with teeth, the surgeon holds the external derma with one hand and, with the other, trims away the excess skin using curved Metzenbaum scissors.



sors. The amount of skin removed is customized for each patient. Using a 5.0 nylon suture, a subcutaneous stitch is applied with slight tension. Alternatively, a simple, uninterrupted stitch on the natural crease may be used. The method of suturing is based on the surgeon's preference and is chosen based on the amount of fat that has been removed,

thus it will vary from patient to patient. The suture ends are cut short to prevent them from causing interference. The 4x4 with antibiotic ointment should not adhere to the stitches and snag the skin when wrapped with the elastic bandage wrap.³

Another suturing technique that may be used is the “corset platysmaplasty,” so named for its similarity in appearance to the “X” pattern of an old-fashioned corset when fully laced. In this alternative, the muscle is gathered and sutured with a snug jaw line and a right-angled neck contour. This produces a successful restructuring of the platysma muscle at the midline.⁴

Once the procedure is completed, the patient’s vital signs are taken and recorded again. Prescriptions for antibiotics, which are mandatory, and any necessary pain relievers are noted. Many patients’ pain-relieving needs can be met with over-the-counter extra strength acetaminophen. A follow-up appointment is scheduled for the following week, and the patient is provided with written postoperative instructions. The surgeon will call the patient to follow up, but the patient is also instructed to call the surgeon with any concerns or to report any changes in their condition.

POSTOPERATIVE CARE

An elastic bandage should be wrapped around the head and neck for the first 24 hours postoperatively, and patients should be monitored by a friend or family member during this time. The bandage should be snug and comfortable, but not tightly wrapped. At the patient’s discretion, it may be worn for five days following the surgery for support, however, it should be removed to bathe and eat. Patients are advised to keep ice packs on the surgical area every three to four hours for the first 48-72 hours after surgery. The patient’s head must be elevated while sleeping to minimize edema, and it is suggested that patients sleep with two pillows to ensure this is maintained. No strenuous exercise is allowed, although short walks are acceptable. The patient’s diet must also be monitored as a restricted salt intake will reduce facial swelling. In addition, patients are encouraged to eat foods that are enriched with vitamin C, zinc and iron to promote healing.

Mild swelling in the surgical area may be present for up to six months postoperatively. Patients must also use a ther-

момeter to monitor increases in temperature, which may be an early sign of a possible surgical site infection. During this time, the patient should cleanse the surgical site using sterile gauze and a 50-50 mixture of hydrogen peroxide and water. Antibacterial ointment should be applied to the incision site after each cleansing.

All antibiotics must be finished as prescribed, and aspirin, ibuprofen, vitamin E and fish oil supplements are not allowed during the first week following surgery to help prevent bleeding.

The bandage should be snug and comfortable, but not tightly wrapped. At the patient’s discretion, it may be worn for five days following the surgery for support, however, it should be removed to bathe and eat.

POSTOPERATIVE RISKS AND COMPLICATIONS

Swelling, bruising and mild discomfort are common and should be expected in the week following a procedure. Infections, seroma, bleeding and hematoma, while not normally considered serious, may occur and should be monitored carefully. If a hematoma is detected—generally indicated by excessive swelling within 12 hours of the procedure’s completion—the patient must return to the surgeon’s office to have it drained with a needle in a sterile setting. Left untreated, it may become infected and possibly cause necrosis of the derma around the surgical site or enter the blood stream, leading to more complications.⁶ If the incision site acquires a green or yellow coloration, it could signify a possible infection or that blood circulation to the area is impaired.

Follow-up visits are scheduled for one week post-procedure, two weeks post-procedure and four weeks post-procedure. At the final visit, another set of photographs are taken to compare to the pre-surgical images.

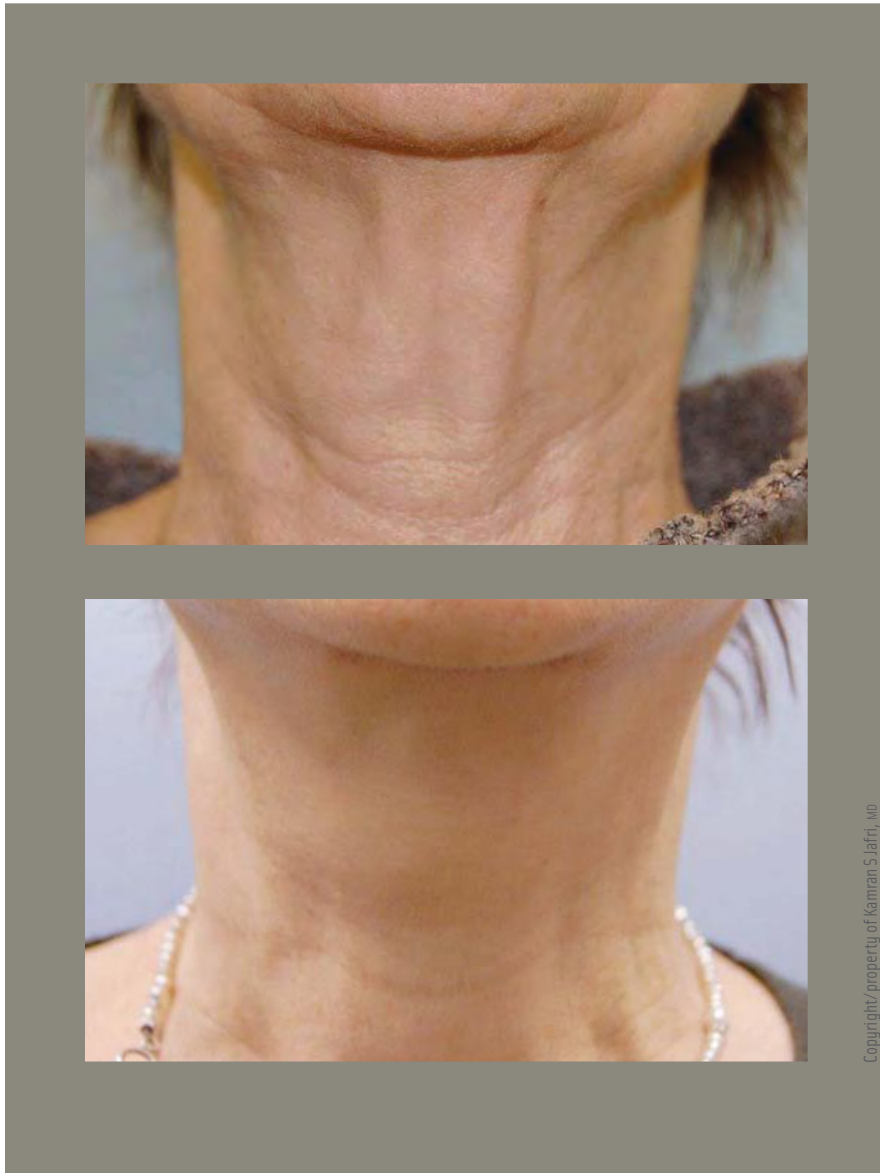
CONCLUSION

The end result of a successful platysmaplasty is a refined, smooth neck that enhances the patient’s features for a more youthful appearance. It can be combined with a face lift, filler, chemical peel and botulinum toxin injections.

Neck lifts may also be performed endoscopically, which is less invasive. This procedure lasts about an hour and a small incision is made under the chin through which the endoscope is inserted. Another alternative is a liposuction procedure, which also lasts about an hour and involves a small incision under the chin through which the fat is extracted. Finally, botulinum toxin injected directly into the platysma muscles will counteract muscle weakening and stop contractions.

ABOUT THE AUTHOR

Nydia I Morales, CST, was an elementary school teacher before entering the medical field. She graduated from New York University Langone Medical Center's surgical technology program in New York City, and became certified in September 2007. She presently assists Kamran Jafri, MD, as his surgical technologist in facial plastic surgery in New York City. She is also an adjunct lecturer (clinical site: Maimonides Medical Center) in the surgical technology program at Kingsborough Community College in Brooklyn, New York.



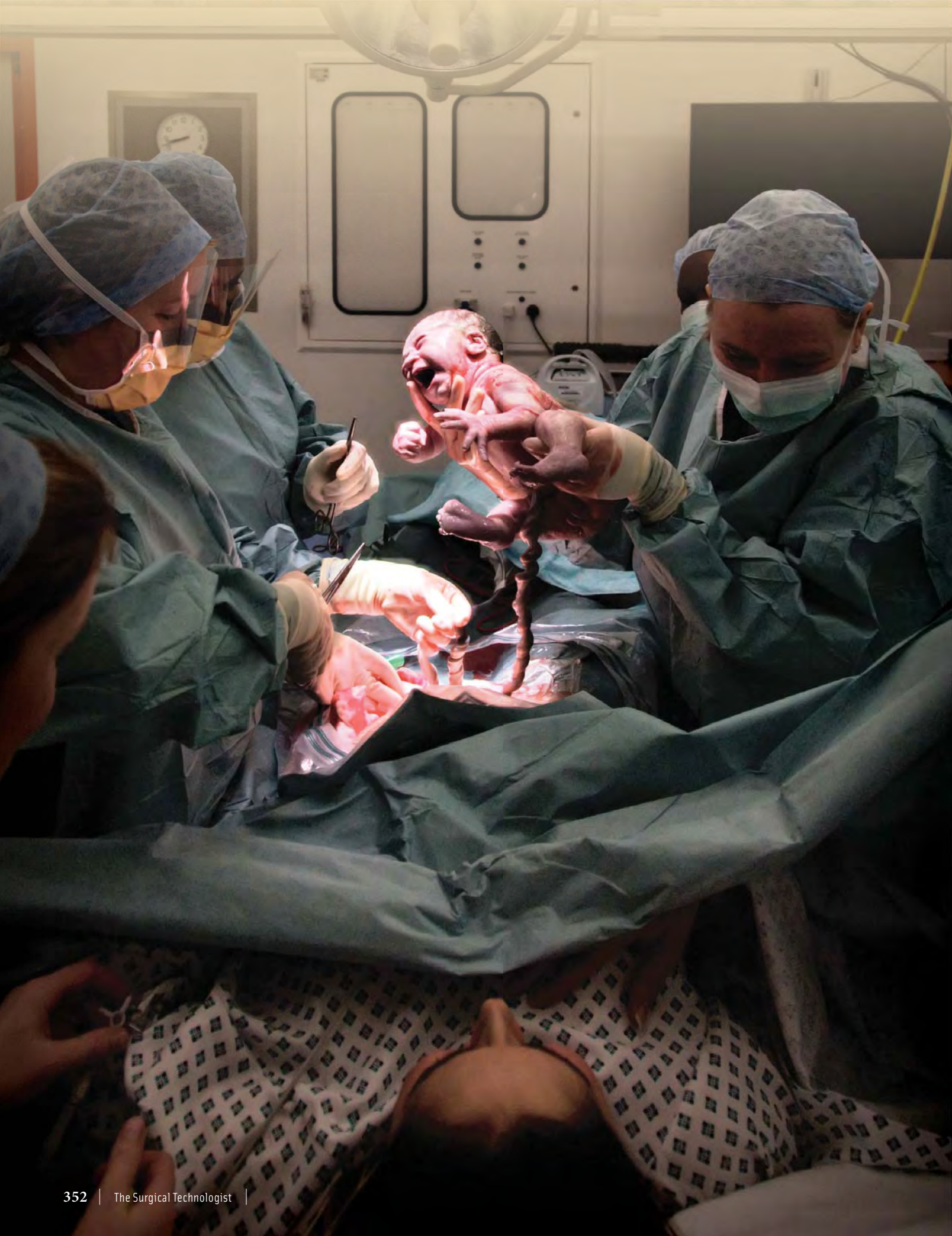References

1. Mosby's Medical Dictionary, 8th ed. 2009. Elsevier.
2. Owsley J. 2007. drjohnowsley.com. "What is the 'SMAS'?" SMAS-Platysma Face-lift. Accessed: 5/7/2010. Available at: <http://www.drjohnowsley.com/html/smas.html#smas>.
3. Fuller J. Surgical Technology: Principles and Practice, 5th ed. 2010. Elsevier. p 746.
4. Feldman, J. Neck Lift. Quality Medical Publishing Inc. p 50.
5. Jafri K. Custom-Lift. Accessed: 5/7/2010. Available at: www.custom-lift.com.
6. WebMD. 2010. "Cosmetic Surgery and the Neck Lift." Accessed: 5/7/2010. Available at: <http://www.webmd.com/skin-beauty/guide/cosmetic-procedures-neck-lift>

Copyright/property of Kamran S Jafri, MD

References

1. Matilla S; Ramo O; Salo J. "Congenital bronchoesophageal fistula in the adult." *Ann Thorac Surg*. 1995. 59(6):887-890.
2. Braghetto I; Cardemil G; Schwartz E; *et al*. "Videothoroscopic management of middle esophageal diverticulum with secondary bronchoesophageal fistula: report of a case." *Surg Today*. 2008. 38(12):1124-8.
3. Aksoy T; Ceran C; Demircan M; Kafkasli A. "Tracheal agenesis and esophageal atresia with proximal and distal bronchoesophageal fistulas." *J Ped Surg*. 2008. 43(8): e1-e3.
4. Spitz L. 2007. "Oesophageal atresia." *Orphanet J Rare Dis*. 2:24. Accessed: November 12, 2009. Available at: <http://www.ajrd.com/content/2/1/24>.
5. Baimbridge M; Keith H. "Oesophago-bronchial fistula in the adult. Thorax." 1965. 20:226-233.
6. De Boeck K; Devlieger H; Van Raemdonck D; *et al*. "Pulmonary sequestration: a comparison between pediatric and adult patients." *Eur J Cardiothorac Surg*. 2001. 19;(4):388-95.
7. de Beukelaar T; Boetzkes S; Ramet J; Wojciechowski M; Van Schil P. "Intralobar bronchopulmonary sequestration with mixed venous drainage in a 10-year-old girl." *Acta Chir Belg*. 2009. 109(4): 501-3.
8. Grillo H. *Surgery of the Trachea and Bronchi*. Hamilton, Ontario. 2004. 576-579, 592-594
9. Cooperman R; Paragi P; Shah S. "Adult congenital bronchoesophageal fistula." *Thorac Cardiovasc Surg*. 2007. 55(5):334-6.
10. Bannister L; Berry M; Collins P; Dyson M; Dussek J; Ferguson M; Williams P. "Respiratory system." *Gray's Anatomy 38th ed*. New York. Pearson. 1995. 1648-1656.
11. King D. 2010. "Histology at Southern Illinois School of Medicine." Accessed March 15, 2010. Available at: <http://www.siuedu/~dking2/erg/giguide.htm>.
12. Wilkins R; Stoller J; Kacmarek R *et al*. *Egan's Fundamentals of Respiratory Care 9th ed*. Mosby. 2008.
13. Anderson J. *Cardiopulmonary Renal Physiology Lecture*. Boise State University. September 2008.
14. Schürch S; Geiser M; Lee M; Gehr P. "Particles at the airway interfaces of the lung." *Colloids and Surfaces B: Biointerfaces*. 1999. 15(3-4):339-353.
15. Langman T; Sadler J. *Langman's medical embryology 9th ed*. Philadelphia. Lipincott&Williams. 2003. 278-285.
16. Iwazawa T; Imazato M; Ohnishi T; Kimura Y; Yano H; Monden T. "Double congenital bronchoesophageal fistulae in an adult." *Jpn J Thorac Cardiovasc Surg*. 2004. 52(8):386-9.
17. Altorki N; Sunagawa M; Skinner D. "Thoracic esophageal diverticula. Why is operation necessary?" *J Thorac Cardiovasc Surg*. 1993. 105(2):260-4.
18. Frey K; Ross T. *Surgical Technology for the Surgical Technologist: A Positive Care Approach 3rd ed*. Clifton Park, NY. Dlelmar Cengage Learning. 2008. 942-945.
19. Durrleman N; Massard G. "Posterolateral thoracotomy." *MMCTS*. 2006. (0810):1453.
20. Bardini R; Bonavina L; Asolati M; Ruol A; Castoro C; Tiso E. "Single-layered cervical esophageal anastomoses: a prospective study of two suturing techniques." *Ann Thorac Surg*. 1994. 58:1087-1089.
21. Taghavi S; Marta G; Lang G; *et al*. "Bronchial Stump Coverage with a Pedicled Pericardial Flap: An Effective Method for Prevention of Postpneumectomy Bronchopleural Fistula." *Ann Thorac Surg*. 2005. 79(1):284-288.
22. Anderson T; Miller J. "Surgical technique and application of pericardial fat pad and pericardiophrenic grafts." *Ann Thorac Surg*. 1995. 59(6):1590-1591.
23. . Komanapalli C; Sukumar M. "Pericardial Fat Pad Flap Buttress." The Cardiothoracic surgery network. Accessed March 27, 2010. Available at: http://www.ctsnet.org/sections/clinicalresources/thoracic/expert_tech-28.html.
24. Brewer L; King E; Lilly L; Bai A. "Bronchial closure in pulmonary resection: a clinical and experimental study using pedicled pericardial fat graft reinforcement." *J Thorac Surg*. 1953. 26(5):507-532.
25. Anderson T; Miller J. "Use of Pleura, Azygos Vein, Pericardium, and Muscle Flaps in Tracheobronchial Surgery." *Ann Thorac Surg*. 1995. 60:729-733.



Emergency Cesarean Delivery in the Labor and Delivery Room

by Gracelia A Scott, CST

This article addresses a new procedure for handling Cesarean deliveries performed in the Labor and Delivery Room (LDR) under extreme circumstances, eg, the mother is dying or has died.

INTRODUCTION

The origin of the term Cesarean has been thought to come from the birth of Julius Caesar. It is unlikely however, as his mother, Aurelia Cotta, lived for many years afterwards. It is more likely that the term originated from “Caesar’s Law,” which states that if a pregnant woman is clearly dead, the fetus should be cut out of her in an attempt to save it. Cesarean deliveries have been recorded in history for many centuries. Surgical removal of a baby from a dead or dying mother has been documented as far back as ancient Egyptian times. In these ancient times, if the mother-to-be was dying or had just died, Cesarean delivery was an attempt to rescue the fetus/neonate.

In the early 1900s, Cesarean delivery became more widely accepted, even though there were also other options, such as forceps and vaginal breech delivery. By the 1960s, the maternal mortality rate secondary to Cesarean delivery in severe emergencies, such as fetal bradycardia, shoulder dystocia, and cardiac arrest, was nearly zero because of major advances in anesthesiology and better methods of controlling hemorrhage.

Notwithstanding medical advances, the need for saving the

LEARNING OBJECTIVES

- ▲ Review the relevant anatomy for this procedure
- ▲ Examine the set-up and surgical positioning for this procedure
- ▲ Compare and contrast the different types of breech birth
- ▲ Assess the needs of the surgical team for this type of procedure
- ▲ Evaluate the inherent dangers of Cesarean section births

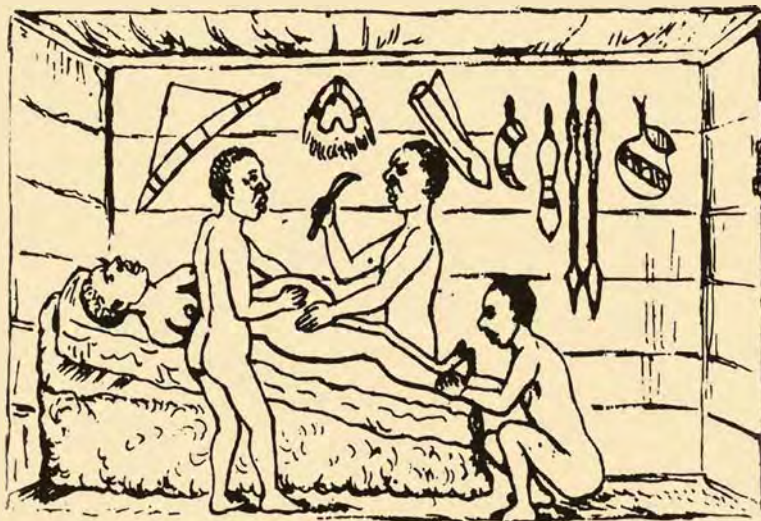

Figure 1. Successful Cesarean section performed by indigenous healers in Kahura, Uganda. As observed by RW Felkin in 1879.

neonate when a mother is dying is great, and can happen in an instant and in a labor and delivery room (LDR) setting. Sometimes, the delivery must be performed immediately after maternal death. A Cesarean delivery in the LDR is the delivery of a neonate by means of an incision into the uterus in a life-threatening emergency. Every surgical technologist who works in labor and delivery needs to be prepared for any and all emergencies.

Despite the advances in medicine and the ability to respond to LDR emergencies, mortality still remains. Since anesthesia was first used in Cesarean deliveries in 1847, the likelihood of fetal or maternal death has played an important role in deciding whether the procedure is necessary. In a true LDR emergency, the goal is to deliver the neonate as quickly as possible.

LDR CESAREAN DELIVERY REQUIREMENTS

In an LDR Cesarean Section the hospital staff may include, but is not limited to:

- The attending obstetrician
- Charge nurse or (nurse team leader)
- Anesthesiologist
- Resident on call
- Physician assistant (PA) on call
- In-house obstetric attending physician
- Patient's primary nurse
- Circulating nurse

- Scrub person (ST, RN, LPN with best skills)
- Neonatal team
- Blood bank

New York Hospital Medical Center of Queens (NYHQ), where this author works, has developed a Code Blue cart that is equipped with the following supplies, required for Cesarean deliveries in the LDR:

- Betadine solution
- Disposable scalpels (2)
- Cesarean delivery tray tally sheets
- Blades: #10 (1), and #20 (1)
- PBDS Latex-Free Labor and Delivery Module, Cesarean delivery
- Laparotomy pads (40)
- ABG kits (5)
- Placenta bucket
- Sandbag
- OR Gowns (2)
- OR bonnets, caps
- OR boots
- Masks
- Goggles
- Gloves: 7.0 latex-free (2), and 7.5 latex-free (2)
- 3/4 sheets for table (2)
- Receptacle for lap count
- Sutures: 1.0 Polyglactin 910 (2), and 1.0 Chromic (2)
- Light handle (1)
- Bovie grounding pads (2)
- Bovie pencil (2)
- 3000 cc suction set-up for surgery
- Stapler
- Foley catheter kit
- 10 cc syringe
- Suction tubing

These supplies are kept in a locked (breakaway lock), designated Code Blue cart on the labor and delivery floor, and it is brought into the LDR immediately, along with the neonatal box and anesthesia box, at the time of emergency. These boxes contain all the supplies needed to resuscitate and support the fetus and mother. The Code Blue cart is checked and signed off once each shift (7:00 am to 3:00 pm; 3:00 pm to 11:00 pm; and 11:00 pm to 7:00 am) to ensure that it is always fully stocked and ready for emergencies.

CODE BLUE PROCEDURE AT NYHQ

Once the team leader (a physician or member of the nursing staff) decides to call an emergency Cesarean delivery in the

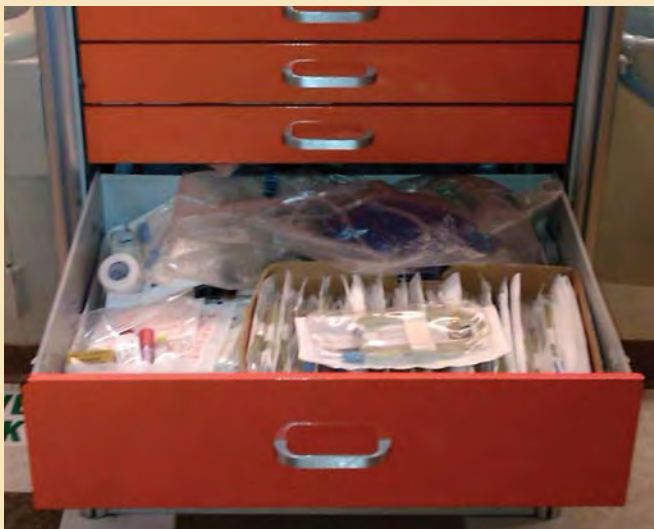
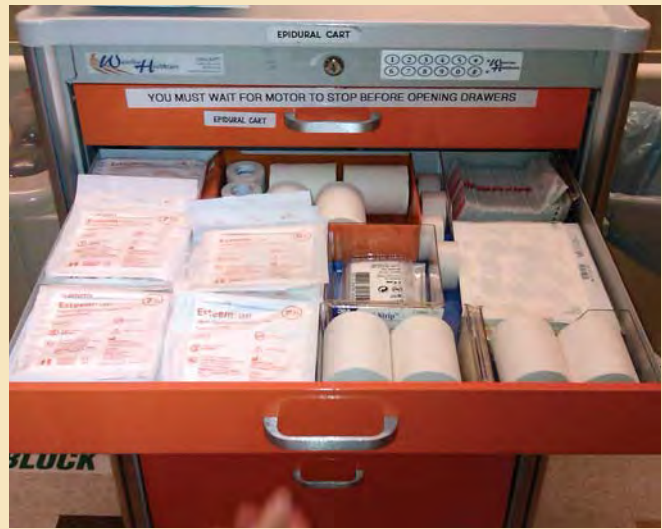
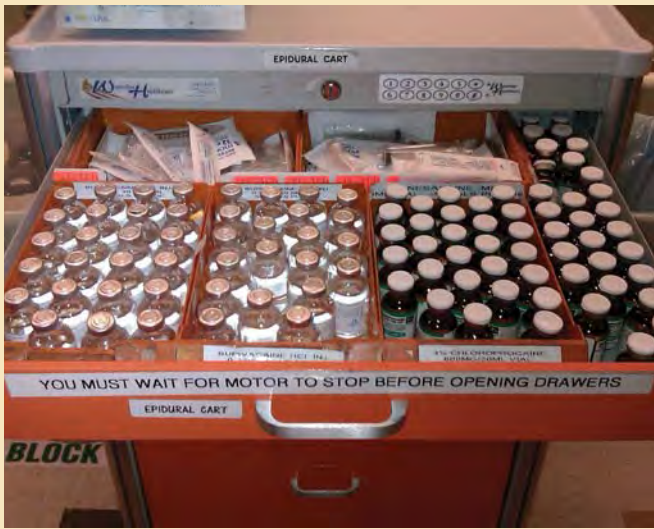Figure 2. The anesthesia cart at NYHQ.

VAGINAL BREECH BIRTH

While Cesarean section remains the most common way to deliver a breech baby in most First World countries, some infants are still delivered by a breech birth. In the breech presentation, the baby enters the birth canal with the buttocks or feet first as opposed to the normal head-first presentation.

According to the American Pregnancy Association, breech births occur in about one of 25 full-term births. When labor is premature, the incidence of breech presentation is higher. Instances of breech birth are also higher with multiple fetuses (twins, triplets, etc.); abnormal volume of amniotic fluid; fetal abnormalities; uterine abnormalities and in mothers who have undergone a prior Cesarean section.

THERE ARE FOUR CATEGORIES OF BREECH BIRTHS:

- Frank breech—the neonate's bottom comes first, and his or her legs are flexed at the hip and extended at the knees with feet near the ears. Between 65-70 percent of breech babies are in the frank breech position.
- Complete breech—the neonate's hips and knees are flexed so that it is sitting cross-legged with feet beside the bottom
- Footling breech—one or both feet come first, with the bottom at a higher position. This is rare at term, but relatively common with premature fetuses.
- Kneeling breech—the neonate is in a kneeling position, with one or both legs extended at the hips and flexed at the knees. This is extremely rare and is excluded from many classifications.

Risks to a breech birth include umbilical cord prolapse, head entrapment and injury to the brain and skull. In both umbilical cord prolapse and head entrapment, oxygen deprivation is a major concern. Brain and skull injuries are more likely in preterm births. The rapid passage of the fetus's head through the mother's pelvis causes rapid decompression of the head, which may injure the brain. In contrast, a fetus delivered in the head-down position usually experiences gradual molding of the skull over the course of a few hours.

The potential injuries that may be sustained during a breech birth may also occur during Cesarean birth, though rare. A Cesarean birth is still a breech birth; however, the soft tissues of the uterus and abdominal wall are more forgiving than the hard, bony ring of the pelvis.

LDR (Code Blue), the patient's primary nurse must communicate the decision to the nurse team leader. The nurse team leader will immediately activate the Code Blue. The alarm is heard throughout the hospital, as well as in all LDR's and operating rooms. The entire hospital knows that the labor and delivery unit needs help. The charge nurse and the hospital support team from other floors arrive at labor and delivery as quickly as possible. The nurse team leader will then assign duties to designated nursing staff. At this time, the operating room should be opened so abdominal closure can occur in a more sterile and controlled environment.

The role of the surgical technologist is critical in managing the situation. He or she arrives at the LDR as fast as possible with OR gowns and gloves in hand. Upon arrival, the surgical technologist asks for the name of the team leader who is assigned to the Code Blue. The surgical technologist identifies him/herself as such. As other members of the medical staff arrive, they will give their names and titles to the nurse recorder. The team leader will direct a staff member (nurse, surgical technologist or nurse's aide) to bring the Code Blue cart into the LDR, open the Code Blue cart, and take out the instruments for the surgical technologist. The surgical technologist finds a table or any available space to set up the instruments. At the same time, the team leader gives the surgical technologist the situation, background and assessment recommendation (SBAR) report, history and physical (H&P) and the history of events preceding the Code.

The following staff, minimally, must be present in the LDR during a Code Blue:

- Team leader
- Anesthesiologist
- Resident (most experienced)
- Nurse recorder or patient's primary nurse
- Code Blue/CAT RN (bedside nurse)
- Medication nurse
- Nurse manager
- Assistant nurse manager/charge nurse
- Runner
- Neonatal team

The runner is placed in charge of obtaining additional supplies needed for the emergency (*ie*, STAT ECG machine, etc). The runner will transport and pick up blood products from the blood bank, as well as deliver all specimens to the laboratory. Only the team leader directs the runner.

The nurse recorder documents the initial basic life support (BLS), vital signs, assessment, medications, procedures

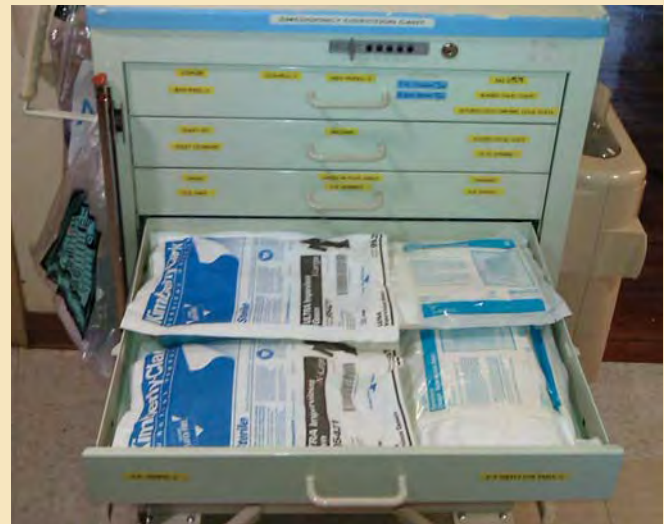
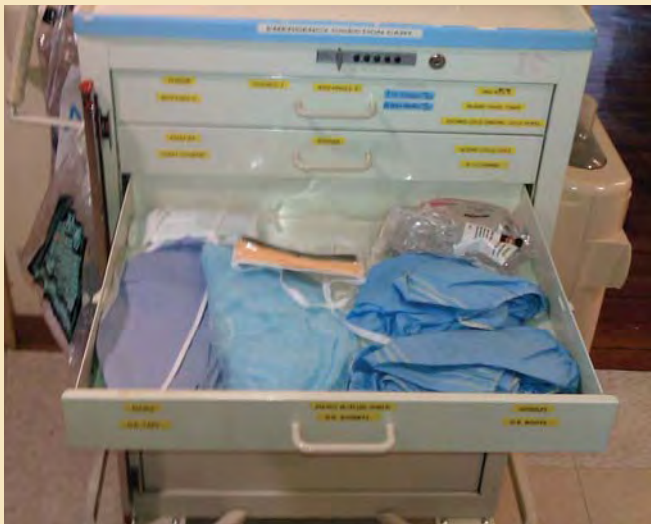
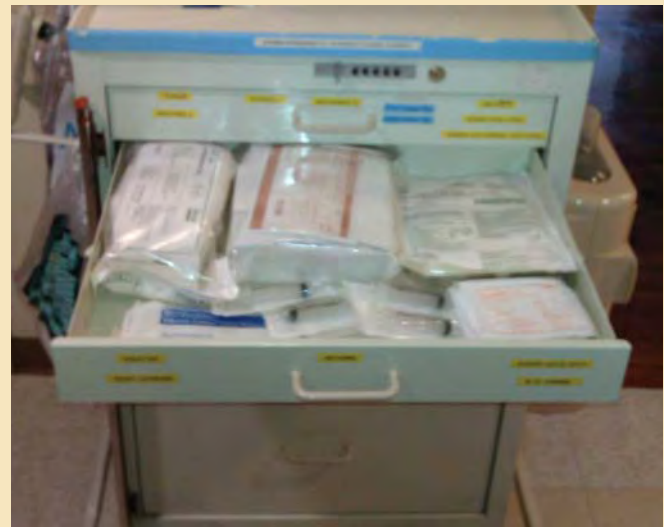Figure 3. Cesarean section “Code Blue” cart at NYHQ

and tests performed. The nurse must also record times of event and activities of Code Blue/Response Code, recording as each team member arrives. He or she will always ask names of personnel in attendance, and will fill out a debriefing form.

SURGICAL OVERVIEW

In a Code Blue, the sandbag, or bolster, is not positioned under the patient’s right hip. No safety strap is secured and, because the patient is in the LDR, the Foley catheter is already in place along with the blood pressure cuff. There is no skin preparation but, if time permits, Betadine solution is poured directly on the patient’s skin, mid-chest to pubic

area. The Cesarean delivery drape is placed. A #10 blade is used to incise the skin via a midline vertical incision down to the level of fascia. The fascia is incised at the midline and carried laterally on both sides using Mayo scissors. The posterior fascia is bluntly dissected from the rectus abdominis muscle and secured with two Kocher clamps. Sharp dissection of the aponeurosis is accomplished superiorly to near the umbilicus and inferiorly to the symphysis pubis using Mayo scissors. The peritoneal cavity is entered atraumatically. No bladder flap is created. A bladder blade is placed over the bladder. A transverse incision is made in the lower uterine segment and carried bilaterally with Lister bandage scissors. The #10 blade is the only knife used. The surgical

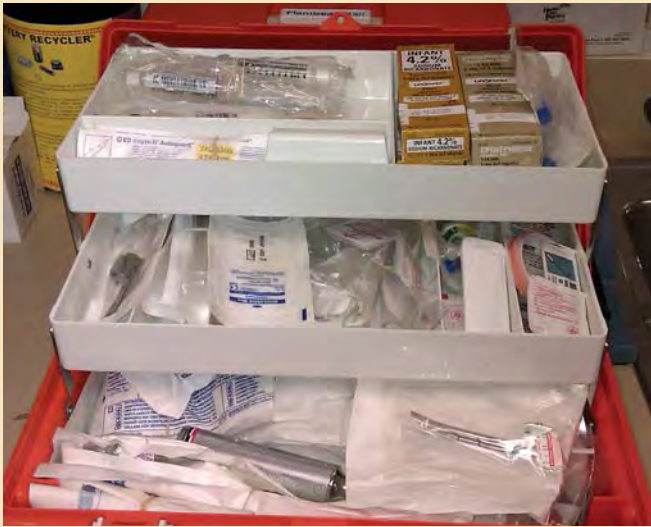

Figure 4. The neonatal box at NYHQ.

technologist should be moving as quickly as possible and must always know where the blade is. All sharp and metal objects should be removed from the field, if possible, before the delivery.

DELIVERY

The head is delivered first by flexing and elevating the fetal head. The umbilical cord is clamped with two small Kelly clamps and then cut with Lister bandage scissors. The neonate is then passed to the awaiting neonatal team. The Bovie can then be brought in for use. Warm Lactated Ringers solution and sterile water are also brought into the room at this time.

While the neonate is being taken care of, the surgical technologist prepares to move the patient. The attending physician makes the decision on when to move the patient from the LDR to the operating room (which should already be open) for the closure of the patient's abdominal wound. There should already be two #1 Polyglactin 910 CTX and two # 1 chromic sutures stocked in the Code Blue cart for use in the LDR.

CONCLUSION

Throughout the twentieth century, there have been many improvements in labor and delivery. Although the maternal mortality rate has decreased in the last several decades, women are having children at a much later age and under higher-risk circumstances. As surgical technologists, we

must be prepared for all situations and be able to react quickly. The Code Blue cart can be an invaluable tool to a surgical technologist and can save critical minutes. A Cesarean delivery that takes place in the LDR is the only hope for survival of the infant, and that can be maximized by rapid response and skilled, well-trained staff.

ABOUT THE AUTHOR

Gracelia A Scott, CST, lives in New York and graduated from the New York University Medical Center Surgical Technology Program. She has been a surgical technologist for more than 20 years at New York Hospital Medical Center of Queens. She is a member of AST and wrote this article to help fellow surgical technologists learn a new approach to an existing procedure as it is being performed in the LDR at New York Hospital Medical Center of Queens. In her spare time, Ms Scott enjoys riding her motorcycle and working with a different instrument kit—wrenches, sockets and pliers.



References

1. Code Blue/Rapid Response Drills: Roles & Responsibilities. New York Hospital Queens 2008, Department of Professional Development and Education.
2. Skupski DW; Eglington GS; Lowenwirt IP; Weinbaum FI. "Building hospital systems for managing major obstetric hemorrhage." In: B-Lynch C, et al, eds. *A Textbook of Postpartum Hemorrhage*. Sapiens Publishing. 2006.
3. Kiefer BP. "Repeat Cesarean Section" *The Surgical Technologist*. 2008; 40; 13-20.
4. Todman D. "A History of Caesarean Section: From Ancient World to the Modern Era." *Australian and New Zealand Journal of Obstetrics and Gynaecology*. 2007; 47:357-361.
5. Hillan EM. "Caesarean Section: Historical Background." *Scottish Medical Journal*. 1991;36:150-154.
6. Hayden FJ. "Maternal Mortality In History And Today." *The Medical Journal of Australia*. January 17,1970:100-109.

Birmingham Hip Resurfacing

by Jill Wehling

People who are very physically active—whether in a physical work environment or simply playing sports—are often uneasy when told by a physician that they need hip surgery to fix the severe, arthritic groin pain that can become a chronic problem. This article discusses options to return to pre-surgery activity levels without going through a total hip replacement.

Rather than replacing entire hip, as in a total hip replacement with traditional metal-on-plastic implants, (high impact activities are restricted because of increased (plastic) wear and loosening of the prosthesis), hip resurfacing simply reshapes the bone by shaving a few millimeters off the femoral head and socket and caps it with a metal component made of cobalt chrome, which allows the patient to get back to his or her active lifestyle in a matter of months.

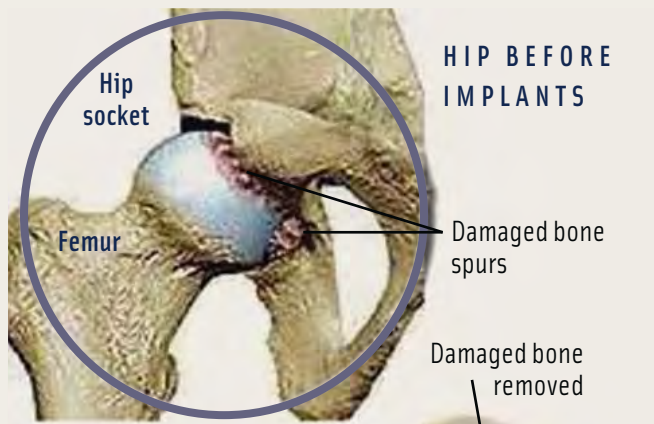
HISTORY OF HIP RESURFACING

Originally developed in the 1970s, many early hip resurfacings resulted in poor outcomes and caused many surgeons to abandon the procedure. These early attempts at the procedure failed largely because the large, metal femoral head rubbed on the then-polyethylene socket, wearing it out. This degenerative wear-and-tear caused the components to loosen, ultimately leading to femoral neck fractures. Surgeons preferred the total hip replacement.

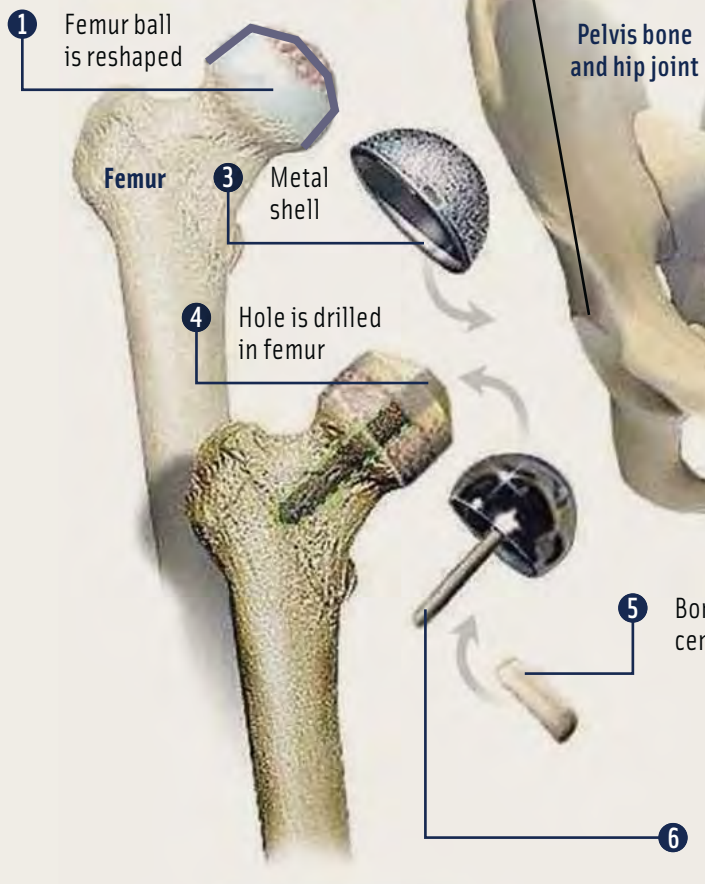
In 1997, Derek McMinn, MD, and Ronan Treacy, MD released the original concept of the Birmingham Hip Resurfacing System. Unlike the total hip replacement, in the resurfacing procedure,

LEARNING OBJECTIVES

- ▲ Review the relevant anatomy for this procedure
- ▲ Examine the set-up and surgical positioning for this procedure
- ▲ Compare and contrast the differences between hip resurfacing and hip replacement
- ▲ Assess the indications for hip resurfacing, including selecting strong candidates
- ▲ Evaluate the step-by-step process of the Birmingham Hip Resurfacing System



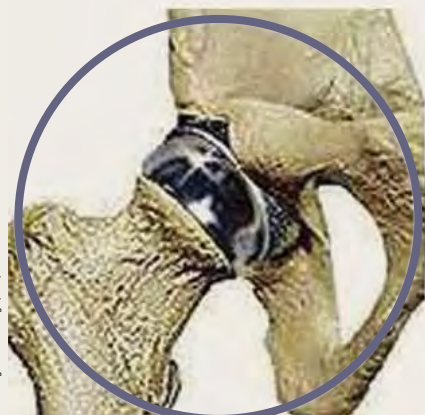HIP BEFORE IMPLANTS



Total hip resurfacing

This surgery replaces the diseased and damaged bone in the hip joint with specially-designed and manufactured “ball and socket” all-metal implants.

- STEP 1** After the thigh bone is separated from the hip socket, the damaged area is removed. The hip ball is reshaped to fit the femur and just 10 millimeters of bone is removed from the tip.
- STEP 2** Damaged cartilage and bone are removed from the hip socket (acetabulum).
- STEP 3** A specially-machined, metal shell implant is firmly pressed into the socket of the pelvis in the anatomic position.
- STEP 4** Now the surgeon focuses on the thigh bone implant. The end of the thigh is drilled to accept the stem of the implant and dried.
- STEP 5** Bone cement is placed inside the metal ball component and around the dried bone of the thigh
- STEP 6** The metal ball implant is securely inserted on top of the thigh bone.



HIP AFTER IMPLANTS

The hip socket, with its new metal shell and the femur, with its new metal part are put together to form a new resurfaced hip joint.

the femoral head and neck is not resected. McMinn's and Treacy's model eliminated the polyethylene component of the resurfacing hardware, and with it, prior concerns about it wearing out. This adaptation allows for a much greater level of activity postoperatively. Because of the larger metal-head size, the risk of dislocation is reduced by a factor of 10. Because the femoral shaft is not broached, future revision, if necessary, is much easier and longer lasting.

There are currently three FDA-approved hip-resurfacing systems: the CONSERVE® Plus Total Hip Resurfacing System, Corin Cormet™ Hip Resurfacing System, and the Birmingham Hip™ Resurfacing System, which will be discussed in this article.

IDEAL CANDIDATE FOR A BIRMINGHAM HIP RESURFACING (BHR)

The most common indication for hip resurfacing is osteoarthritis (ie, cartilage loss and bone-on-bone articulation). Other indications include hip dysplasia, avascular necrosis (impaired or disrupted blood supply) and rheumatoid arthritis. Younger, formally active patients with good bone density are the best candidates for this procedure.

SURGICAL PREPARATION

After a patient time out, the patient is anesthetized under general anesthesia on the operating table and the surgeon positions the patient in a lateral position. There are many varieties of positioning equipment, but this article addresses the Maquet positioning equipment. The patient is well-supported using a pubic padded post and lumbar post along with an axillary roll under the armpit with the upper arm in a "gutter" support. The operative leg is placed in a candy cane stirrup for prepping purposes. A compression stocking is applied to the nonoperative leg, which is slightly bent. The surgical staff is then hooded, gowned and gloved and the patient is draped. A sterile compression stocking is placed on the operative leg.

PROCEDURE

The surgeon marks his or her incision lines, and 20 cc of local mixture of one percent lidocaine with 1:1,000 epinephrine (30 ml), mixed with 0.25 percent sensorcaine plain (30 ml) for a 50/50 mixture totaling 60 ml. This mixture, used to help maintain hemostasis, is injected at the incision site. An initial incision is made and deepened through the fat while an ESU is used to cauterize bleeding vessels. The fibers of gluteus maximus and fascia lata are divided. A self-retaining

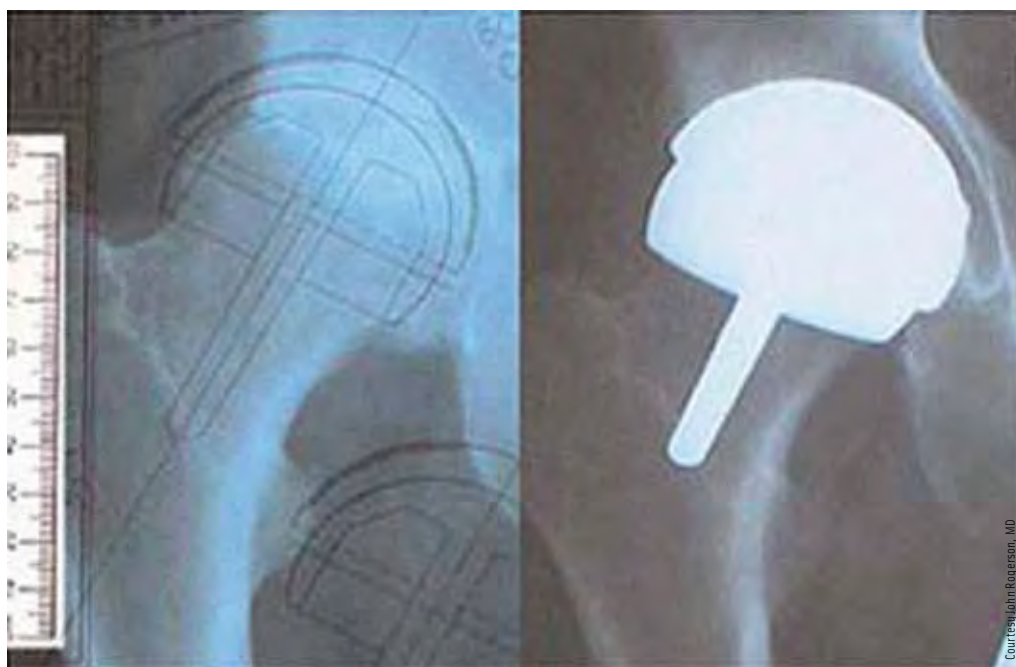


Hardware for a Birmingham Hip Resurfacing

retractor is placed to open the gluteus maximus incision. The surgeon must be careful not to injure the inferior gluteal nerve, as this can cause weakness and leave a divot in the buttock from muscle atrophy.

Dissection between the undersurface of gluteus maximus and the greater trochanteric bursa should be carried out so that the sciatic nerve can easily be palpated. A Charnley retractor is then substituted for the self-retaining retractor. At this point the surgeon injects an additional 20 cc of the local mixture to help maintain hemostasis. The greater trochanteric bursa is divided with the ESU. The next step is to identify the piriformis tendon and divide the connection between the piriformis and the gluteus medius fibers. A dull Hohmann retractor is used to retract the edge of the gluteus medius muscle. A tag suture using 1 polyglactin 910 CT-1, is placed on the piriformis, and it is released. The capsular incision is made over the femoral head to the edge of the acetabulum. A tag suture is also placed on the posterior capsule. The femoral head and posterosuperior edge of the acetabulum is exposed. The superior hip capsule is divided at the edge of the acetabulum and a third tag suture is placed. The hip is now ready to dislocate.

Capsular scissors are used in cutting the capsule further around the femoral neck. A sharp Hohmann retractor is used to retract back the minimus medius. A rongeur is used to remove any osteophytes surrounding the femoral head. The surgeon needs to find the true femoral neck in order to be able to size the head and neck for resurfacing. Once the measurement is checked the femoral head is propped under the abductor muscle with a sharp Hohmann. A second sharp Hohmann retractor is placed on the outer



**L—Pre-surgical X-ray showing surgeons measurements for the hip resurfacing components.
R—The same hip with the components in place**

edge of the acetabular wall and the Omni-Tract® system is used to secure the Hohmann retractors. A headed pin is placed below the transverse ligament and below the tear-drop and hooked to the Omni-Tract® holder. A full view of the acetabulum is achieved and the surgical technologist is ready for preparation and cup insertion.

The acetabular labrum is fully excised, and the ligamentum teres remnant also removed. If an osteophyte is present on the posterior acetabular wall, it is divided with an osteotome and removed with a rongeur. Sometimes there is soft tissue that needs to be removed. Osteophyte in the acetabular floor is excised with an osteotome and rongeur. The surgeon can now begin reaming the acetabulum. Starting with a size 44 or 46 mm reamer, the surgeon reams until he or she is confident that the acetabular floor has been reached—reaming up in 2mm increments until he or she comes close to the final acetabular reaming. At this point, the surgeon will proceed in 1mm increments. It is generally advised to ream one size under the estimated cup size and then verify the measurement by trial. When the surgeon is confident about the fit of the trial acetabular component, the true implant is opened and inserted with an impactor and heavy mallet. The surgeon can often tell by the sound that the acetabular cup is fully seated as it contacts the floor of the acetabulum. The surgeon is aiming for 40 degrees of

inclination and 20 degrees of anteversion. When the surgeon is satisfied with cup positioning, the acetabular cables are cut and the impactor cap and the cables are removed. Any protruding osteophyte is removed with a rongeur to prevent impingement. An X-ray-detectable 4x4 is placed in the acetabular cup to protect the cup during the next phase of resurfacing. All retractors are now removed and the headed pin is taken out.

Accuracy is extremely critical in the following steps. The femoral head must be fully exposed to carry out the re-shaping of

the head. In order to obtain the correct varus-valgus alignment of the femoral component, the template distance from the tip of the lesser trochanter to the desired point on the intertrochanteric crest must now be transferred from the X-ray measurement, into the operative field. A ruler and an 18g spinal needle are used to obtain this measurement, and it is marked with the ESU at its point for pin insertion. The pin is then drilled into the lesser trochanteric space, and a McMinn guide jig is placed to gain proper varus/valgus alignment. A stylus on the guide jig is used to check perimeters circumferentially on the femoral neck. Once the surgeon is satisfied with the ideal entry point, he or she will then drill a long-guide pin, via a cannulated rod, into the superior femoral head. It is important to check the guide-wire position by using the stylus tip around the femoral neck. The stylus should not touch the femoral neck in any position and should touch the periphery of the femoral head 360 degrees. These are the minimum requirements for guide-wire position.

If the surgeon is not happy with the guide-wire position, a guide-wire repositioning instrument can be used. The cannulated rod and stylus are removed, and the surgeon will drill through the lesser trochanter into the canal of the femur to place a drain cannula for suction. A urology drape is then placed around the femoral head to protect

the soft tissues from being contaminated by bony reaming during the femoral preparation. The guide wire is now over-drilled with two different-sized drilling instruments then replaced with a guide rod. A continuous flow of irrigation is recommended during the next three stages. A head-neck template is used as a protector while reaming the femoral head with the cylindrical reamer. An osteotome is used to remove the peripheral ring of femoral head bone. A rongeur is used to remove any osteophyte left behind on the femoral head-neck junction. The cylindrical reamer is then used by hand to remove any fragments left behind. A marking pen will mark the head and neck joint and summit of the head. A plain cutter is used to carefully resect down to the marked point. This is checked with the head-neck template. The chamfer cutter is used until the instrument is fully seated. There is an internal stop in this instrument. This is the final stage of re-shaping the femoral head. Keyholes are drilled with a Wroblewski drill for cement. The guide rod is removed with a slap hammer and the central hole in the femoral head and neck is enlarged with a taper drill. Any cysts seen are removed with a curette. The femoral head is now prepped by pulse lavage and patted dry with lap sponges and suctioned dry. The surgeon checks the correct size of the femoral head, and the box is opened to surgical staff.

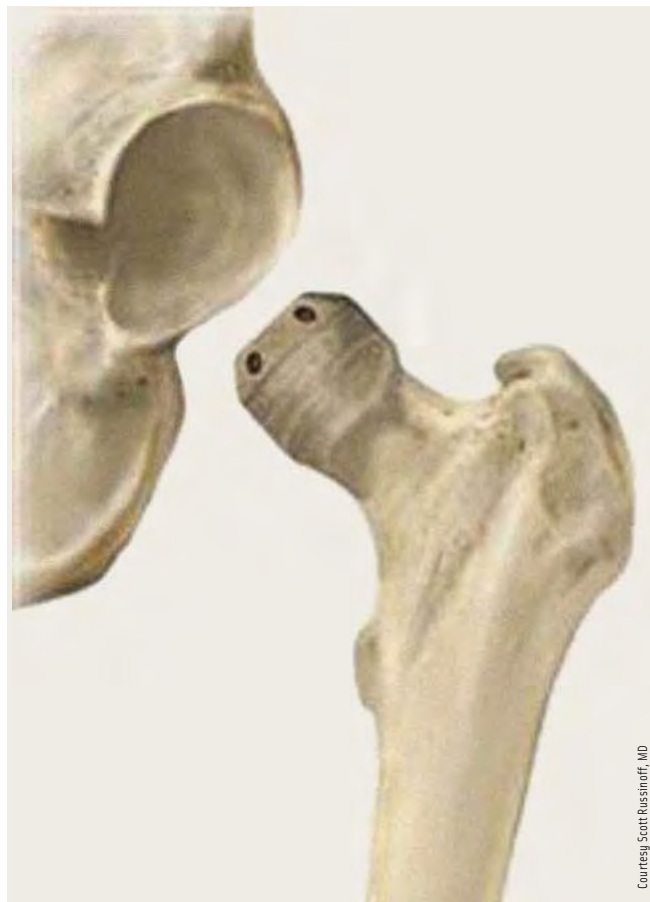Preparation of cement consists of a mixing bowl, spatula, 60 cc catheter tip syringe, cement powder, liquid and stop watch with head impactor with heavy mallet available. The femoral head is draped with three clean lap sponges in alternating directions. At the surgeon's request, he or she will tell the surgical technologist when to start mixing as he or she has only one minute from the time the liquid contacts the powder to implantation. As a surgical technologist, the mixing has to be done quickly, but thoroughly. Ideally, at about 25 seconds, the surgeon should be able to draw up the liquid in the syringe and start filling the femoral head to one-third full. At the one minute mark, the surgeon places the femoral head with the impactor. Any excess cement is wiped away, and a rongeur is used to remove any small osteophyte at the head—neck junction. A pulse lavage is used to irrigate and clean the femoral head and surrounding tissue. The drain cannula is removed, and a clotting agent is injected into the canal. Forceps are used to retrieve the raytec from the acetabular cup, saline is used to fill the acetabular cup and a bone hook is used to lift femoral head component along with traction on the leg to reduce into the acetabulum. The surgeon now double checks the leg length and range of motion for any impingement.

CLOSURE

For closure, the surgeon chooses to use a 3/32 drill to place an anchor into the greater trochanter. Then a 1-Vicryl®CT-1 is used to close the external rotators and capsule along with the tagged piriformis and posterior capsule. 2-0 Vicryl CT-1 is used to close the subcutaneous layer, followed by staples for skin. The incision area is cleaned with a wet and dry. Skin glue is applied along with two, sterile 4x4s and an island dressing. An anti-embolism stocking is placed on patient's leg with one pillow between the legs for the first few hours of recovery. An X-ray is taken in recovery when the patient is awake to ensure that dislocation has not occurred in moving from the operating table.

RECOVERY

Rehabilitation usually starts on the first day after surgery. Patients are on crutches the next day and weight bearing is allowed as tolerated. Physical therapy will start one or two days after surgery, beginning with simple bed exercises that



Courtesy Scott Russinoff, MD

The femoral head and hip socket after being trimmed to fit the new prosthesis.

will strengthen the muscles in the hip and lower extremity. It is the physical therapist's job to teach the patient proper technique to perform such simple tasks as moving from lying to sitting, sitting to standing and standing to sitting. The patient must learn to perform these movements safely, so that he or she doesn't dislocate the hip or suffer other injury. Patients will start the use of the pool three days after the operation. The patient should have hip flexion of about 90 degrees four to five weeks postoperatively.

Most patients can return to whatever level of physical activity they previously enjoyed approximately one year postoperatively. In the first three months, patients will be able to golf, and at six months, high-impact activities should be possible. However, during the first year, more conservative, low-impact activities, such as walking, swimming and bicycling are recommended for strengthening the femoral neck and muscles around the resurfaced joint. The bone is strengthened as new bone grows. According to Wolff's Law, bone in a healthy person will adapt to the loads it is placed under. If loading on a particular bone increases, the bone will remodel itself over time to become stronger and resist that sort of loading.

Because the femoral neck is maintained in a resurfacing procedure, the weight-bearing forces through the calcar and proximal femur remain normal and calcium deposition is normalized gradually.

CONCLUSION

Hip resurfacing is a technically demanding procedure, but it can be successful, and the results can be satisfying for the patient. Hip resurfacing requires good bone quality. Some acetabular deformities cannot be addressed. However, it is an attractive option for a young patient fearing a potentially difficult future revision.

ABOUT THE AUTHOR

Jill D Wehling lives in Verona, Wisconsin, and graduated from Mt Hood Community College Surgical Technology Program in Portland, Oregon, in 2003. She currently works at Meriter Hospital in Madison, Wisconsin, where she is the lead orthopedic surgical technologist.



References

- McMinn D, ed. *Modern Hip Resurfacing*. Birmingham, UK: Springer-Verlag; 2009.
- Rogerson JS. *Birmingham hip resurfacing*. Available at: <http://orthorogerson.com>. Accessed August 9, 2010.
- *Wolff's law*. Encyclopædia Britannica. 2010. Encyclopædia Britannica Online. Available at: <http://www.britannica.com/EBchecked/topic/646611/Wolffs-law>. Accessed July 19, 2010.

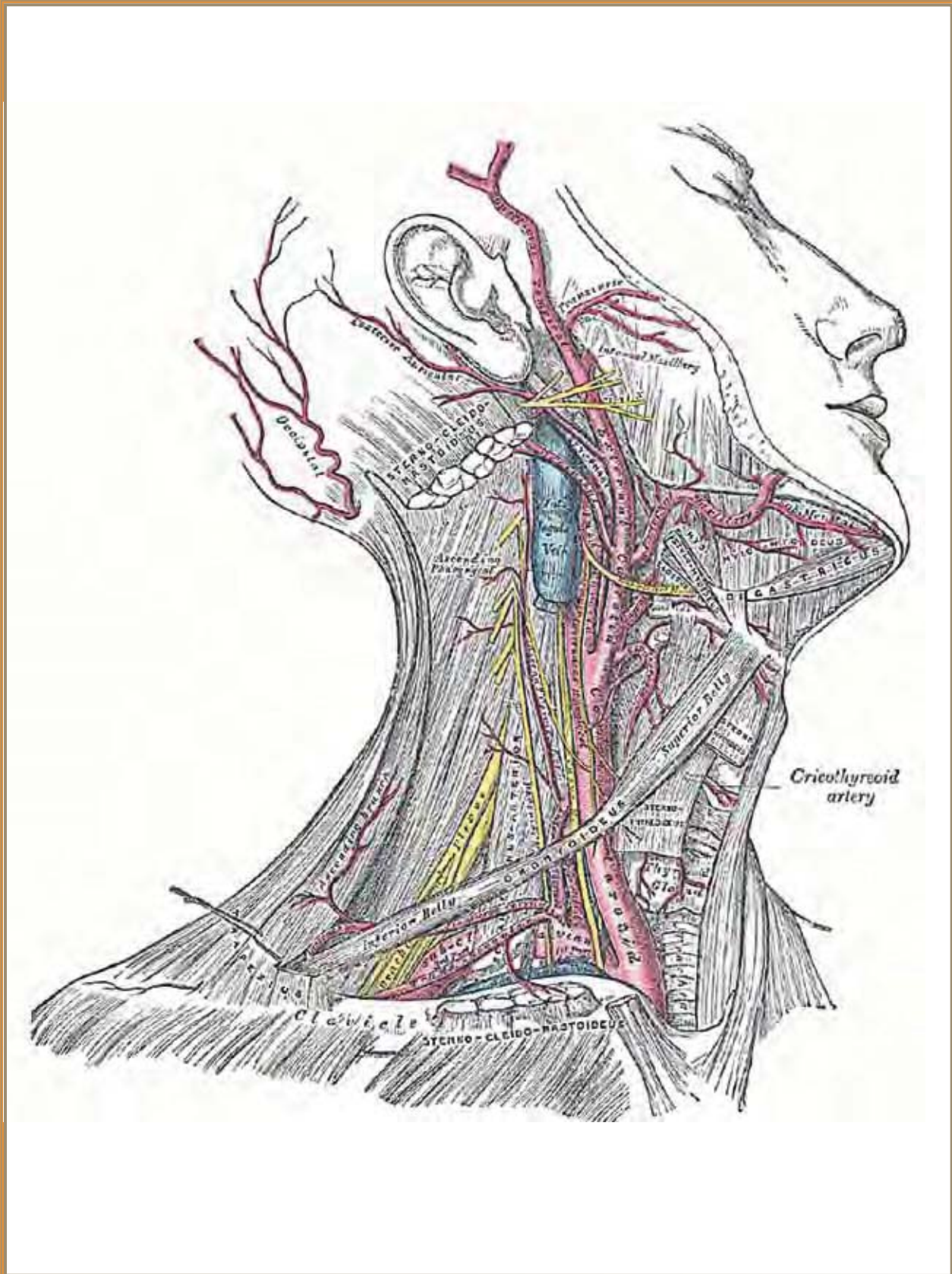
CONSERVE is a registered trademark of Wright Medical Technology.

Corin Cormet is a trademark of the Corin Group PLC.

Birmingham HIP Resurfacing System is a trademark of Smith and Nephew.

Omni-Tract is a registered trademark of Omni-Tract Surgical.

Vicryl is a registered trademark of Ethicon, a division of Johnson & Johnson.



Radical Neck Dissection

Deborah D. Lamb, CST

A radical neck dissection is performed when malignant lesions are found in a patient's head and/or neck, as well as in his or her cervical nodes. This metastasis happens through the lymphatic channels via the bloodstream. The disease can affect the oral cavity, lips and the thyroid gland, which in turn can cause the cancer to spread slowly to the neck.

HISTORY

The first radical neck dissection was described and performed by George Washington Crile at the Cleveland Clinic in 1906.¹ The revolutionary procedure marked a great step forward in the treatment of metastatic neck diseases. At the time, Crile, a founding member of both the Cleveland Clinic and the American College of Surgeons, was already well known for his work in thyroidectomies, of which he performed more than 25,000 in his career.¹

As performed by Dr Crile, the radical neck dissection called for the removal of all the lymph nodes on one side of the neck, as well as the spinal accessory nerve, internal jugular vein and sternocleidomastoid muscle. The main drawback to this procedure was shoulder dysfunction, which occurred due to the sacrificing of the accessory nerve.² Future practitioners eventually established more conservative measures.

It wasn't until the 1940s that surgery began to take over as the treatment of choice for the majority of cancers of the head and neck. It was in this time frame that advances in the field of anesthesiology allowed for more elaborate surgeries. Additionally, the introduction of antibiotics during the second World War allowed

LEARNING OBJECTIVES

- ▲ Review the relevant anatomy for this procedure
- ▲ Examine the set-up and surgical positioning for this procedure
- ▲ Compare and contrast the modifications of the radical neck dissection
- ▲ Assess the risks and benefits of skin and nerve grafts
- ▲ Evaluate the step-by-step procedure for a radical neck dissection

surgery to emerge as the primary choice for management of cancers of the head and neck.³

In the 1940s and 50s, Hayes Martin, MD, performed radical neck dissections on a routine basis in order to manage neck metastasis. The main objective, as he saw it, was to remove and block the entire ipsilateral lymphatic structures from the mandible to the clavicle and from the infrahyoid muscles to the anterior border of the trapezius. His method also resected the spinal accessory nerve, the internal jugular vein, the sternocleidomastoid muscle and the submandibular gland. The remaining structures, including the carotid arteries, vagus nerve, hypoglossal nerve, brachial plexus and phrenic nerve were left intact.⁴

In the early 1960s, an Argentinean surgeon, Oswaldo Suarez, described the facial compartments in the neck and facial envelope covering a selective group of lymph nodes. He proposed a modification of Crile and Martin's radical neck dissection, which he termed as a functional neck dissection. Suarez's method was to remove a selected group of lymph nodes and preserve the vital structures, including the accessory nerve, jugular vein and sternomastoid muscle that Crile's procedure had originally designated for extraction.² This method was further popularized in Europe by Ettore Bocca and Caesar Gavilan, and in the United States by Richard Jesse, Alando Ballantyne and Robert Byers.²

The last four decades have made way for progressive advances to occur, giving an understanding of cervical fascial planes, lymphatic drainage patterns, preoperative staging and extracapsular spread. In 1991, a report was published by the American Academy of Otolaryngology-Head and Neck Surgery that standardized the terminology for the different types of neck dissections. In 2001, the report was updated with very few changes. These changes dealt with the application of various types of selective neck dissection procedures for oral cavity, pharyngeal and laryngeal, thyroid and cutaneous malignancies.

The modifications to the radical neck dissection are as follows:

Type I: The spinal accessory nerve is preserved.

Type II: The spinal accessory nerve and the internal jugular vein are preserved.

Type III: The spinal accessory nerve, internal jugular vein and the sternocleidomastoid muscle are preserved.

Extended Radical Neck Dissection: The lymph node groups and/or additional structures not included in the classic neck dissection are resected.

PRE-SURGICAL PREPARATION

The patient is placed on the OR table in the supine position. The anesthesiologist administers general endotracheal anesthesia, after which the patient is positioned for surgery. The patient's head is extended moderately with the affected side of the face and neck facing upward. The shoulder on the operative side is slightly rotated so that the surgical field from the posterior midline of the neck to the anterior midline of the neck is accessible. The face and neck skin prep is extensive and starts at the hairline and goes down to the nipples, as well as down to the table both anterior and posterior. If a skin graft is to be harvested, the thigh is also prepped and draped using sterile towels that are placed over the sterile area for later use as the dermal skin graft before the neck wound is closed. This graft is used to protect the carotid artery due to the possibility that the patient has undergone extensive previous or preoperative radiation therapy.

The patient is draped with a head drape, which consists of a drape sheet and two towels under the head with the upper towel wrapped around the head and clamped. The neck is draped with folded towels and secured with sterile plastic adhesive. Some surgeons' preference is to suture or staple the sterile towels to the skin. Once the sterile towels are in place, the fenestrated sheet, (diagram A), is then placed over the patient.

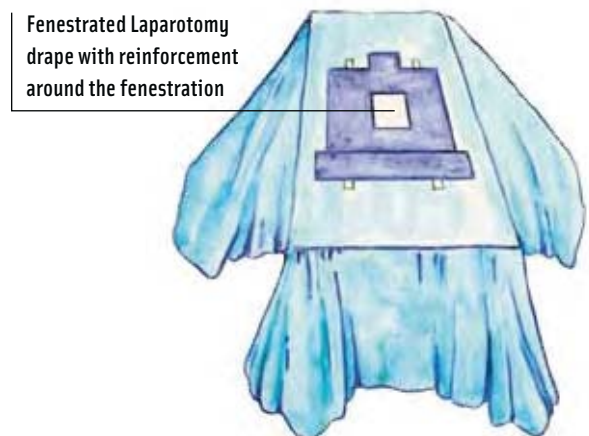

Diagram A

Instrumentation setup for this surgical procedure varies, depending on the surgeon's preference. The surgical technologist should familiarize him or herself with the surgeon's preference card, however, each setup does include the following:

- 50 Mosquito hemostats, curved
- 8 Allis forceps
- 8 Kelly hemostats
- 8 Pean forceps
- 4 Thyroid tenacula
- 4 Babcock forceps
- 2 Right angle clamps
- Assorted needle holders
- 12 Towel clamps
- 2 Tonsil suction tubes
- 1 Trousseau tracheal dilator
- 2 Rake retractors
- 2 Army-Navy retractors
- 2 Richardson retractors
- 2 Vein retractors
- 4 Skin hooks, 2 single and 2 double
- 1 Gelpi retractor
- 4 knife handles, no. 3, with no. 10 and no. 15 blades
- 1 Tracheal hook
- 2 Mayo scissors, straight and curved
- 2 Metzenbaum scissors
- 2 scissors, small, curved, sharp and blunt
- 4 Tissue forceps, 2 with and 2 without teeth
- 2 Adson tissue forceps
- 2 Brown-Adson tissue forceps
- 1 Periosteal elevators
- 2 Freer elevators
- 1 Bayonet forceps
- Brown or Stryker dermatome (if a skin graft is anticipated)

EQUIPMENT:

- Suction
- Electrosurgical unit (ESU)
- Scales (to weigh sponges)

SUPPLIES:

- Foley catheter and urimeter
- Basin set
- Marking pen
- Suction tubing
- Electrosurgical pencil

- Needle magnet or counter
- Graduate
- Bulb syringes (2)
- Dissectors (peanut)
- Umbilical tapes, vessel loops
- Nerve stimulator (locator)
- Suction drainage unit (Hemovac)
- Lap sponges
- 4x4 Raytech sponges

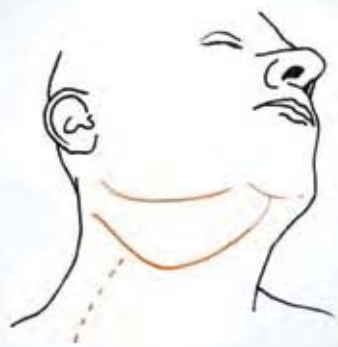As with instruments, equipment and supplies vary depending on surgeon preference, so it is always a good idea to familiarize oneself with the surgeon's preference card.

The last four decades have made way for progressive advances to occur, giving an understanding of cervical fascial planes, lymphatic drainage patterns, preoperative staging and extracapsular spread.

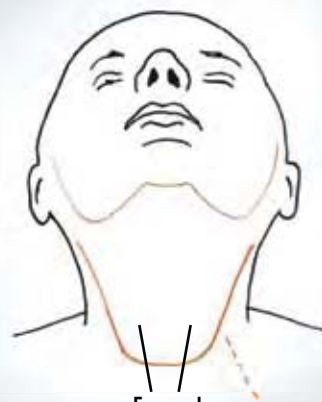
THE SURGICAL PROCEDURE

The surgical incision is made starting at the lateral neck from beneath the jaw to the supraclavicular area (diagram B). Skin flaps are mobilized while hemostasis is achieved using fine hemostats as well as ligatures on bleeding vessels. Once the skin flaps are freed, the surgeon places a traction suture in different areas of the skin flap and then places a hemostat on the end. This is done to retract the skin flap for better exposure. Using curved scissors, the anterior trapezius muscle is exposed, as well as the external jugular vein. The trapezius muscle and the external jugular vein are clamped, ligated and divided. The internal jugular vein is then found, isolated and divided. The omohyoid muscle is identified and transected. The fatty tissue in the neck houses lymph nodes. These lymph nodes are dissected away from other structures and the common carotid artery and vagus nerve are identified (diagram C).

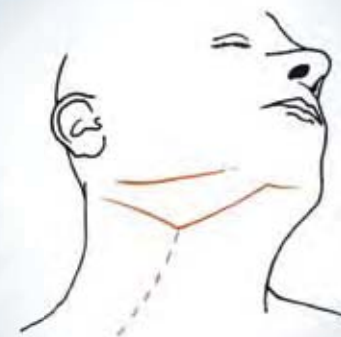The thyrocervical artery is then clamped, divided, and ligated. The posterior triangle are dissected starting at the anterior of the trapezius muscle and continuing to the bra-



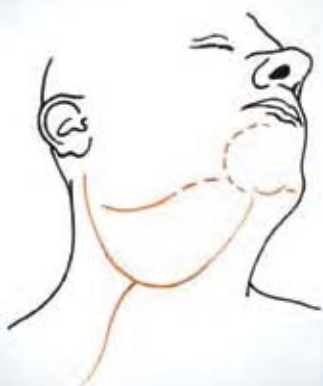Latyshevsky and Freund



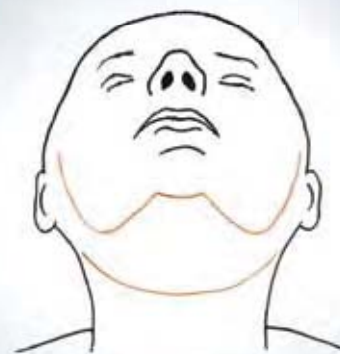Freund



Crile



Incision used for unilateral supra-omohyoid neck dissection



Incision used for bilateral supra-omohyoid neck dissection

Diagram B

chial plexus, the levator scapulae and the scalene muscles. Branches of the cervical and suprascapular arteries are identified then clamped, ligated, and divided. Once the anterior portion dissection is complete, the omohyoid muscle is severed where it attaches to the hyoid bone. Once hemostasis is controlled, all hemostats are removed. The surgical field is then covered with warm, moist, sterile laparotomy packs. Next, the sternocleidomastoid muscle is cut and retracted out of the way. At this point the submental space is dissected from fatty tissue that houses lymph nodes, starting upward and working down. The fascia that is deep on the lower portion of the mandible is then incised and the facial vessels are then divided and ligated.

Entering the submandibular triangle, the submandibular duct is divided and ligated. The submandibular glands that have fatty tissue and lymph nodes surrounding them

are dissected going toward the digastrics muscle. The facial branch of the external carotid artery is identified and divided. Parts of the digastrics, as well as the stylohyoid muscles, are then cut where they attach to the hyoid bone and mastoid. The top end of the internal jugular vein is elevated and divided, and the mass is removed.

The entire surgical site is checked for any bleeding and irrigated with warm saline solution. If a skin graft is needed, it is placed over the bifurcation of the carotid artery downward about four inches, then sutured using 4-0 absorbable suture on a small cutting needle. Tubing for the Hemovac drain, if that is the surgeon's preference, is placed in the wound. The skin flaps are then approximated and closed with interrupted, fine non-absorbable sutures or skin staples. A pressure dressing is applied to the neck, which also depends on the surgeon's preference.

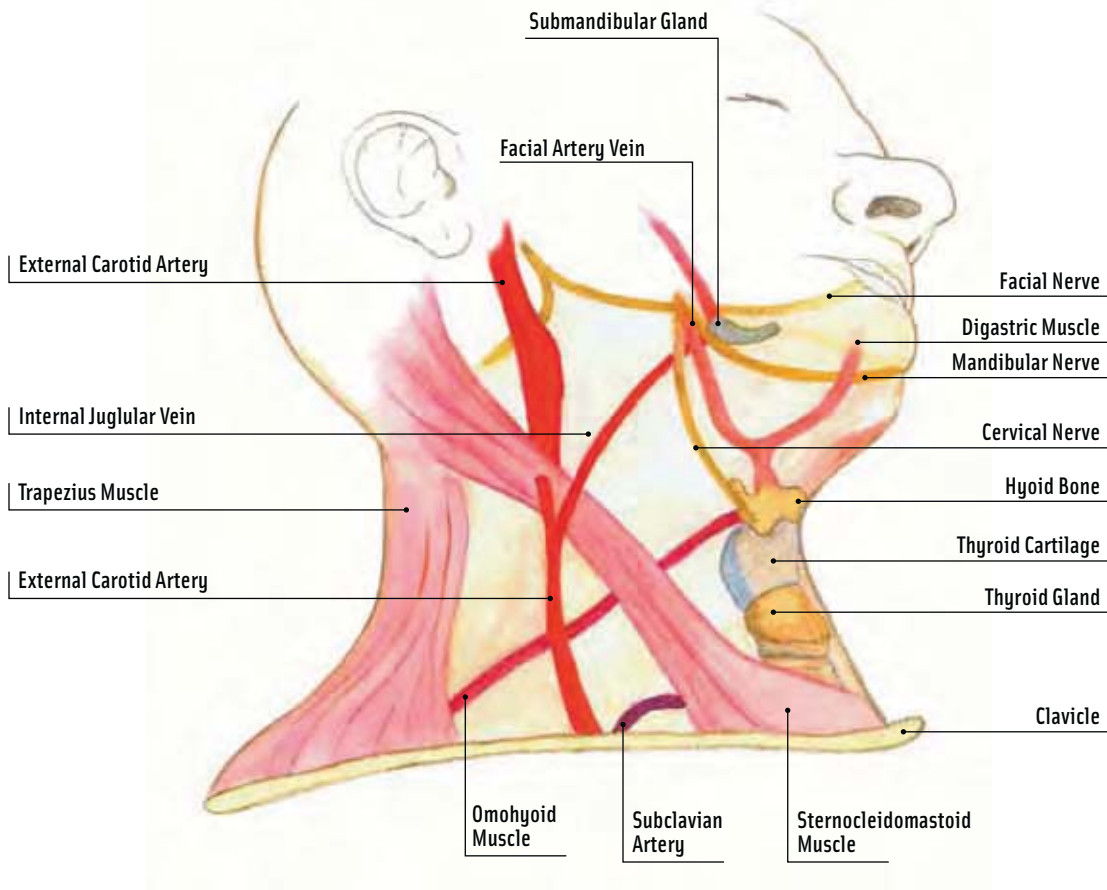
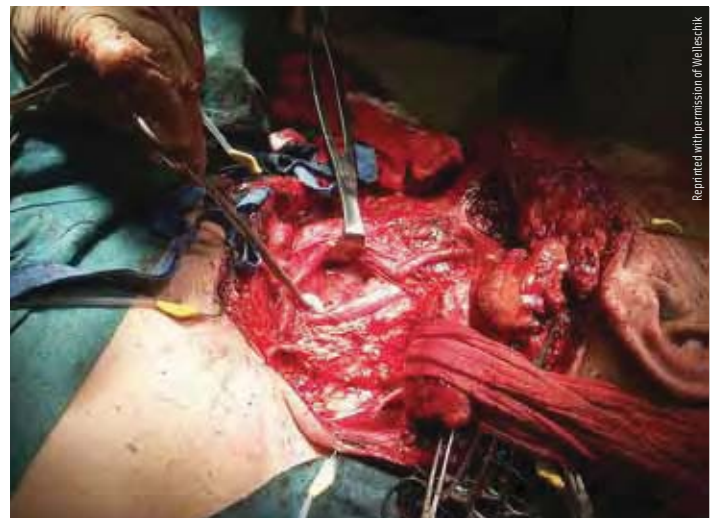

Diagram C

RECONSTRUCTIVE PROCEDURES

When reconstructive procedures are performed, the method used depends on the surgical defect. The surgical wound may be closed primarily or with split-thickness skin grafts. Local flaps may be used. These skin grafts are used for facial or intraoral defects. For nasal and facial defects, full-thickness skin grafts are used. The pectoralis major musculocutaneous flap is an example of a regional flap. The radial forearm flap, free jejunal flap and rectus abdominis flap are used for microvascular tissue transfer. The iliac crest flap is used for microvascular osteocutaneous flaps. All of these flaps are used to restore function and cover defects. The grafts and flaps listed above are performed when it is deemed necessary due to large defects that are created. When microvascular flaps are used, surgical and anesthesia time increase significantly. This is because veins and arteries are connected



Radical Neck Dissection

microscopically. Nerve grafts and bone grafts may also be used, and must be connected by using plates and screws.

In a 2000 study, published in *The Laryngoscope*, it was determined that allograft, or cadaveric tissue, may be useful in this type of procedure. Benefits of allograft include a reduction in the the surgical time, as well as the amount of time that a patient is under general anesthesia. AlloDerm® is a dermal graft that is derived from banked human tissue. Because it has been decellularized, AlloDerm® does not induce an immune response in the body, reducing the probability that the graft will be rejected.⁵ The study concludes that a previously-irradiated field does not adversely affect the integration of AlloDerm®, making it a potentially viable alternative to an autograft option—or the harvesting of the patient’s own tissue for reconstructive purposes. Originally developed for use in burn patients, it has recently made strides toward wider acceptance and utilization in different surgical settings.

Doppler units are used intraoperatively as well as postoperatively. It is paramount to have thorough nursing assessment skills so that occlusions and/or spasms of the vessels can be spotted in order for the transplanted flap to survive. The patient’s average hospital stay is 13-15 days.

SPECIAL NOTE:

- * Make sure the blood bank has blood available and ready for the patient as ordered.
- * The surgical sponges must be weighed and the irrigation fluids measured accurately.

ABOUT THE AUTHOR



Deborah D Lamb, CST, graduated from Hinds Community College in Jackson, Mississippi as a President’s Scholar in 1997. She worked at a Level I trauma center in Jackson until 1998, when she transferred to a small hospital in Athens, Alabama, where she worked until 2000. After spending six years as a vet tech, Ms Lamb decided to retire, but she continues to maintain her certification.

AlloDerm® is a registered trademark of LifeCell Corp.

References

1. Kazi, RA. “The Life and Times of George Washington Crile: An Outstanding Surgeon.” *The Internet Journal of Otorhinolaryngology*. 2003. Vol 2, No 2.
2. Shaha, A. 2007. “Editorial: Complications of Neck Dissection for Thyroid Cancer.” *Annals of Surgical Oncology*. Accessed: August 19, 2010. Available at: <http://www.ncbi.nlm.nih.gov/pmc/articles/PMC2244697/>.
3. American Head & Neck Society. 2005. “Hayes Martin Biography.” Accessed: August 19, 2010, Available at: <http://www.ahns.info/foundation/hayesmartin.php>.
4. Martin, H. “The Treatment of Cervical Metastatic Cancer.” *Annals of Surgery*. 1941. Vol 114, No 6. Available online at: <http://www.ncbi.nlm.nih.gov/pmc/articles/PMC1385835/pdf/annsurg00378-0016.pdf>.
5. Dubin, M; Feldman, M, et al. “Allograft Dermal Implant (AlloDerm) in a Previously Irradiated Field.” *The Laryngoscope*. Lippincott Williams & Wilkins, Inc. Philadelphia. 2000.



Earn CE Credits at Home

You will be awarded continuing education (CE) credits toward your recertification after reading the designated article and completing the test with a score of 70% or better. If you do not pass the test, it will be returned along with your payment.

Send the original answer sheet from the journal and make a copy for your records. If possible use a credit card (debit or credit) for payment. It is a faster option for processing of credits and offers more flexibility for correct payment. When submitting multiple tests, you do not need to submit a separate check for each journal test. You may submit multiple journal tests with one check or money order.

Members this test is also available online at www.ast.org. No stamps or checks and post to your record automatically!

Members: \$6 per credit
(per credit not per test)

Nonmembers: \$10 per credit
(per credit not per test plus the \$400 nonmember fee per submission)

After your credits are processed, AST will send you a letter acknowledging the number of credits that were accepted. Members can also check your CE credit status online with your login information at www.ast.org.

3 WAYS TO SUBMIT YOUR CE CREDITS

Mail to: AST, Member Services, 6 West Dry Creek Circle Ste 200 Littleton, CO 80120-8031

Fax CE credits to: 303--694-9169

E-mail scanned CE credits in PDF format to: memserv@ast.org

For questions please contact Member Services - memserv@ast.org or 800-637-7433, option 3. Business hours: Mon-Fri, 8:00a.m. - 4:30 p.m., mountain time

Pectus Carinatum:

Pigeon Chest

Tracy Cheek

Pectus carinatum is a deformity of the chest wall distinguished by a protuberant sternum and rib cage. It is caused by congenital and genetic abnormalities found in pediatric patients. This unusual deformity can have both physiological consequences and significant psychological impacts on the untreated patient.

PATIENT CASE STUDY

The patient is a 13-year old Caucasian male who presented with a protuberant sternum and characteristic *pectus carinatum*. The chest wall deformity has slowly been increasing in prominence and distortion over time as the patient has grown, causing discomfort and pain on occasion. The patient was experiencing bouts of fatigue and dyspnea (shortness of breath) during physical activity, which became more frequent in the last year. The young man recently expressed concerns to his parents that he felt his chest deformity was hindering him from normal physical activities at school, and that he felt self-conscious of his appearance, particularly around his peers. The patient's parents noted that he was beginning to isolate himself from both friends and family and showing signs of depression. They articulated that, at this point, the primary concern with their son was his emotional state of mind, and that it was directly related to the cosmetic appearance of his chest wall deformity. The patient has a past history of psychological issues and problems with socialization. The parents felt that the next logical step would be surgical intervention to repair the *pectus carinatum*.

LEARNING OBJECTIVES

- ▲ Review the relevant anatomy for this procedure
- ▲ Examine the set-up and surgical positioning for this procedure
- ▲ Compare and contrast the various genetic disorders that may cause *pectus carinatum*
- ▲ Evaluate the step-by-step procedure for surgical correction of *pectus carinatum*
- ▲ Assess the postoperative precautions and recovery time for this procedure

THE DISEASE

Pectus carinatum is an uncommon deformity of the anterior chest wall that is typically characterized by a protruding breast bone (sternum) and ribs caused by an overgrowth of the costal cartilages. It is a pediatric disease that can present solely as a congenital abnormality or in conjunction with other genetic disorders. It frequently goes unrecognized until adolescence, where it is predominantly seen in males, and typically increases in severity with age, particularly during growth spurts. It is sometimes referred to as “pigeon chest,” as it causes the patient’s chest to have the appearance of a bowed bird’s chest.¹

Treatment for *pectus carinatum* includes both surgical and nonsurgical options. Children with mild forms of *pectus carinatum* will often only require nonsurgical treatments, which can include being fitted with an external pressure brace or no treatment at all. Similar in theory to how orthodontic braces work on the teeth, a pressure brace applies a constant, gentle pressure against the bone (in this case the sternum), which over time pushes the bone back into normal anatomical position. The number of days, as well as the amount of time per day that a child wears the brace until desired results are accomplished will be dependent on the amount of severity in disproportion of the child’s chest. Although this treatment option has been shown to provide positive results over time, some parents have found that it is difficult to keep their child from taking off the brace due to it being uncomfortable to wear, which reduces the overall therapeutic process.¹

Patients with moderate to severe *pectus carinatum* will require surgical intervention. Surgical treatment involves removing the cartilages that project the sternum forward

and suturing them into normal, anatomical position. As the patient heals, the cartilage regenerates and forms in the new position. Surgical treatment can take anywhere from two to six hours, depending on the amount of cartilage to be removed, and a postoperative hospital stay can be anywhere from three to seven days, depending on complications and pain management.¹


The most common method of surgical treatment for *pectus carinatum* is the Ravitch procedure. It involves cutting the costal cartilage away from each side of the sternum and making the sternum lie flat. In this procedure, the surgeon may choose to utilize stabilization bars that can be inserted into the sternum to help maintain its new shape. These bars remain in place permanently. Drains are placed on each side of the chest to evacuate fluids from the wound and are sutured in place. The Ravitch procedure has a 97 percent satisfaction rate among patients.²

Pectus carinatum is mainly an asymptomatic disease with little or no interference with the patient’s cardiopulmonary function. However, as studies have suggested, there can be decreased lung capacity and mitral valve prolapse associated with the disorder. The outward projecting and rigidity of the sternum can impair the gas exchange process of the cardiopulmonary system, which in turn can decrease a patient’s physical stamina. Additionally, connective tissue disorders affecting major blood vessels and heart valves are being seen along with emphysema, respiratory tract infections and dyspnea. Many patients experience pain and tenderness in the chest area. Yet among all of these symptoms, it appears the primary concern for patients suffering from *pectus carinatum* and their families revolves around the significant cosmetic concerns this disorder can present.³

EPIDEMIOLOGY

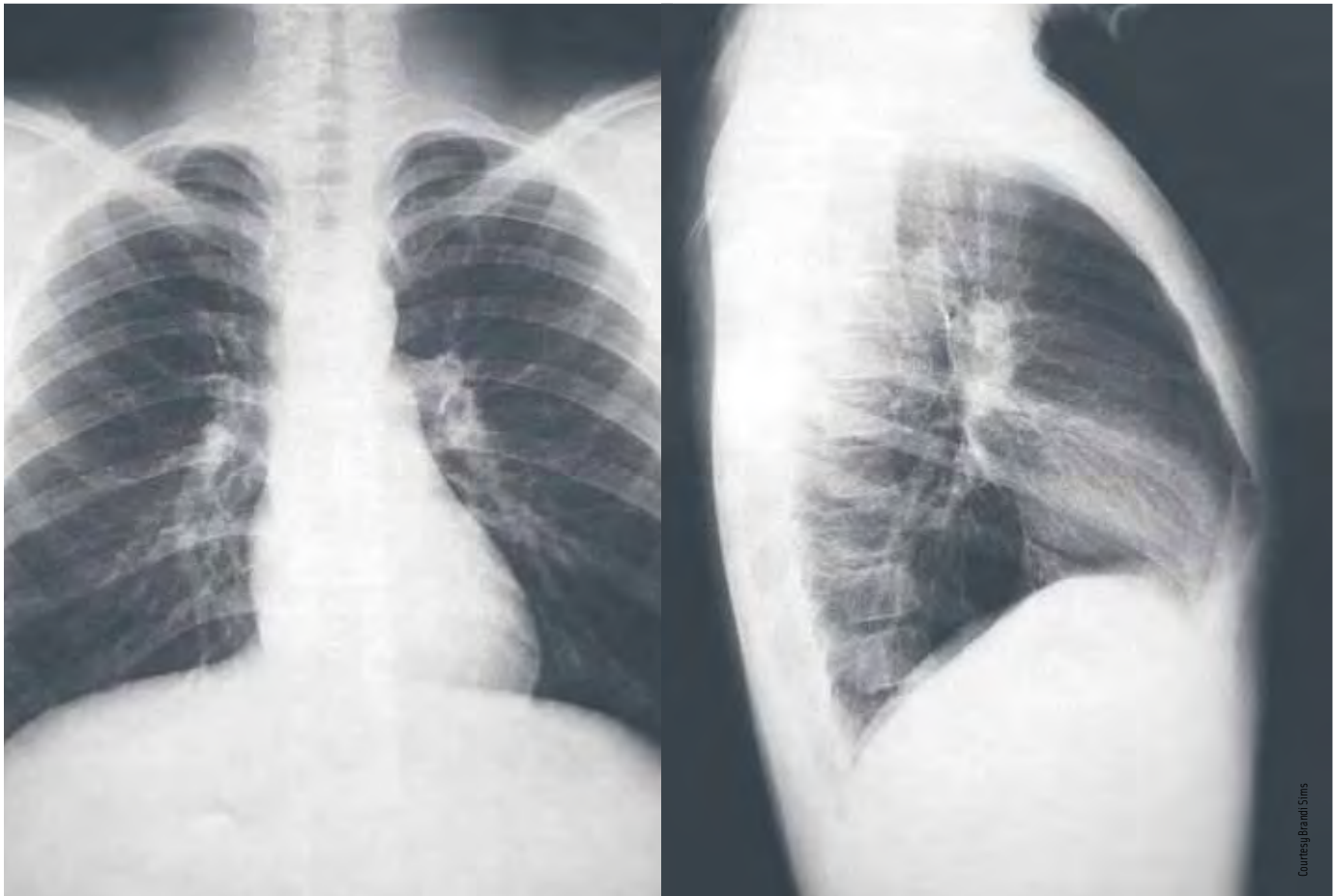
According to the Seattle Children’s Research Foundation, *pectus carinatum* occurs in approximately one out of every 1,500 children. It is five times more likely to occur in males than in females.¹

Pectus excavatum is another chest deformity that is similar to *pectus carinatum*, but has the reverse effect on the patient’s sternum. This disorder presents as an inverted, or “funnel chest,” as opposed to *pectus carinatum*’s protruding chest. *Pectus excavatum* generally affects the lower half of the sternum and is much more common than *pectus carinatum*, affecting one in every 500-1,000 children. Like *pectus carinatum*, *pectus excavatum* is also believed to be caused from genetic factors passed down familial lines.⁴



An external pressure brace.

Courtesy Westcoast Brace & Limb*



Front and lateral X-rays of an adolescent male with *pectus carinatum*.

ANATOMY AND PHYSIOLOGY

The thorax (chest) is a conical-shaped, airtight, protective compartment made up of an osseo-cartilaginous cage. The primary purpose of the thorax is to protect the principal organs of respiration and circulation (the lungs and heart).⁵

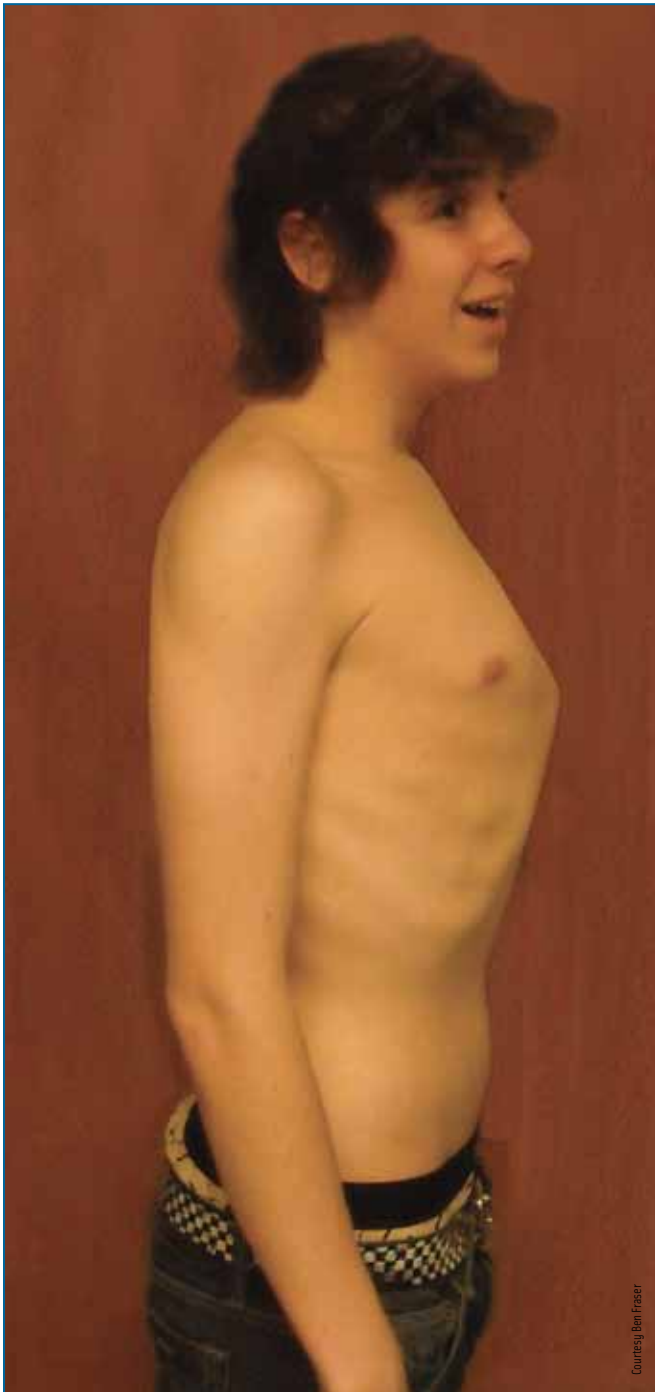The thorax is narrow at the superior end and wide at the inferior end. Its anatomical boundaries include the 12 thoracic vertebrae (T-1 through T-12), which form the posterior boundary; the sternum and costal cartilages, which form the anterior boundary; and the ribs, which are at each of the lateral margins.⁵

The human body contains 24 ribs, the first seven superior ribs are considered the “true ribs,” and they are attached to the sternum by the costal cartilages. The purpose of the costal cartilages is to allow the ribs to stretch forward and back during respirations. The eighth, ninth, and tenth ribs are considered the “false ribs.” These ribs adjoin with the costal cartilages of the superior ribs. The eleventh and twelfth ribs are also known as false ribs. These ribs are not

joined with the sternum by the costal cartilages. The false ribs are also known as the “floating ribs.”⁵

The superior opening of the thorax is wide from side to side. It is formed by the first thoracic vertebrae (T-1) posteriorly, the superior portion of the sternum anteriorly, and the first rib laterally. The inferior opening of the thorax is formed by the twelfth thoracic vertebrae (T-12) posteriorly, the eleventh and twelfth ribs laterally, and the seventh, eighth, ninth, and tenth rib cartilages (costal cartilages) anteriorly. The costal cartilages form the subcostal angle at the xiphoid process. The diaphragm, a large sheet of muscle, extends across the bottom of the thoracic compartment and separates the thoracic cavity from the abdominal cavity.⁵

The spaces between the ribs, known as the intercostal spaces, are occupied by muscles known as the intercostal muscles, which assist in the mechanics of respiration. There are 11 external intercostal muscles that aid in inhalation and 11 internal intercostal muscles that aid in exhalation. Each of these muscles has its own blood supply and inner-



Courtesy Ben Fraser

Adolescent male presenting with severe *pectus carinatum*.

vation. The intercostal arteries supply blood to the muscles and branch from the internal thoracic artery and the aorta. The intercostal veins connect with the mammary veins and the azygos and hemiazygos veins. The intercostal nerves, branch from the thoracic spinal nerves and the ventral rami nerves, innervate the intercostal muscles.⁵

The pectoralis major is a large muscle group that is located on the sides of the chest, superiorly and contralaterally. This group of muscles branch from the sternum, the superior ribs, and the clavicle area. They are innervated by the lateral and medial pectoral nerves.⁶

The male thorax is different from the female thorax. In the male, the thorax has a larger capacity than that of the female. The level of the upper sternum is at the second thoracic vertebrae (T-2), whereas in the female the level of the upper sternum is at the third thoracic vertebrae (T-3). Additionally, the upper ribs in the male thorax are less mobile than the female thorax.⁵

DISEASE PRESENTATION

There are several possible causes for *pectus carinatum*, all of which can present in three separate situations: at birth, during growth spurts and post-surgically. Generally, post-surgical presentations of the disease are due to the sternum's malunion during healing. This is seen in cases where a patient has undergone cardiac surgery, but it is fairly uncommon. Patients who develop *pectus carinatum* from surgery will require additional future surgical intervention to correct the sternal protrusion.⁷

Congenital presentations are the second most likely presentation of *pectus carinatum*. The newborn will have a circular chest, which develops into a protrusion at around three years of age. Often in these cases, surgical intervention to correct the deformity will take place once the child reaches puberty.

The most frequent presentation of *pectus carinatum* is in adolescent males undergoing growth spurts. This kind of presentation can come on rapidly and can be the cause of much emotional turmoil for the child and the parents. Surgical intervention in these cases is generally more for the cosmetic effects than symptomatic reasons.⁷

PATHOPHYSIOLOGY

Pectus carinatum can be caused by either sole congenital abnormalities or from genetic abnormalities. One type of genetic disorder associated with the development of *pectus carinatum* is Edward's syndrome, or Trisomy 18. Trisomy 18 is a genetic disorder that involves a person having extra genetic material from chromosome 18. This genetic syndrome is fairly common and occurs in females more often than males. Symptoms of Trisomy 18 include low birth weight, mental deficiency, micrognathia, microcephaly, low-set ears, clenched hands, crossed legs, round-bottomed

feet, undescended testicles, underdeveloped fingernails, and *pectus carinatum*.⁸

Trisomy 21 is another genetic abnormality that is commonly associated with Down syndrome and another possible contributor to the development of *pectus carinatum*.⁹

Marfan syndrome is another genetic disorder that has been associated with *pectus carinatum*. Marfan syndrome is a connective tissue disorder that affects the eyes, skin, heart, blood vessels, lymphatic vessels and bones. In this disorder, a genetic defect involving the gene fibrillin-1 interferes with the body's tissue-building properties and, in turn, causes an excessive growth in the long bones of the body. Symptoms of Marfan syndrome include arachnodactyly, flat feet, loose joints, learning disabilities, nearsightedness, eye problems, scoliosis, and *pectus excavatum* or *pectus carinatum*.¹⁰ Although Marfan syndrome is considered an inherited genetic disease, approximately 30 percent of the children presenting with this defect have no known family history of the disorder.¹⁰

It appears the primary concern for patients suffering from *pectus carinatum* and their families revolves around the significant cosmetic concerns this disorder can present.

Homocystinuria is another genetic disorder associated with the development of *pectus carinatum*. This genetic disorder involves the inability of the body to correctly metabolize methionine, an amino acid. Similar to Marfan syndrome, homocystinuria affects the tissue building properties of the body, particularly the joints. Marfan syndrome causes the body joints to become loose, whereas homocystinuria affects the joints by causing them to be stiff and tight. Common symptoms of homocystinuria include flushed cheeks, knocked knees, long limbs, mental retardation, psychiatric disorders, highly-arched feet and chest deformities such as *pectus excavatum* and *pectus carinatum*.¹¹

Morquio syndrome is a genetically inherited disease that affects the metabolism. The body lacks the proper enzymes to breakdown glycosaminoglycan, a specific type of sugar molecule. Morquio is associated with a group of diseases known as mucopolysaccharidoses, or MPS. The common symptoms

of Morquio syndrome include knock knees, widely-spaced teeth, macrocephaly, loose joints and an abnormal development of bones including those of the thorax.¹²

Multiple lentiginos syndrome is a genetic disorder that is tied to *pectus excavatum* and *pectus carinatum*. Symptoms of this syndrome include dark skin spots on the neck and chest area, delayed puberty, pulmonic stenosis, cryptorchidism, hypogonadism, *pectus excavatum* or *pectus carinatum*.¹³ Generally, patients diagnosed with multiple lentiginos have a strong family history of the disorder.

A congenital disorder called *osteogenesis imperfecta* (brittle bone disease) is another potential cause for the development of *pectus carinatum*. This disorder is caused by a defective gene that is responsible for the production of collagen. Type I collagen is an important component of bone building. Common symptoms of *osteogenesis imperfecta* include multiple bone fractures, deafness, eye discolorations, loose joints, flat feet, bowed limbs, scoliosis, kyphosis and *pectus carinatum*.¹⁴

DIAGNOSTIC TESTING

The patient in the case study has been given several preoperative diagnostic tests to confirm the diagnosis of *pectus carinatum*. The physician treating the patient performed a thorough physical examination and review of his complete medical history. The patient's medical history reveals that the 13-year old has a history of emotional disorder, specifically attention deficit hyperactivity disorder (ADHD), for which he is being treated with the drug methylphenidate. Additionally, it is found that when the patient was seven-years old, he underwent a right-side inguinal hernia repair with no noted postoperative complications. No other medical interventions or diagnoses are found in the patient's history and physical exam.¹⁵

Diagnostic testing continues with an X-ray exam to view the patient's chest abnormalities and verify any signs of scoliosis. Results of the X-ray are conclusive, revealing that the patient has a moderate protrusion of the thoracic wall with an over growth of five of the costal cartilages, contralaterally. No scoliosis is noted. A computed tomography (CT) scan is performed to review the patient's chest anatomy. His lungs and heart appear normal in size for the patient's age and build.¹⁵

A pulmonary function test (spirometry) is performed to identify any lung abnormalities and to verify lung function. The physician also performs an electrocardiogram (ECG) to observe the electrical conductivity of the patient's heart

and an echocardiogram to confirm the patient's heart structure is sufficient and functioning properly. The spirometry, electrocardiogram and echocardiogram show normal heart and lung function.¹⁵

Several blood tests are performed, including a complete CBC, metabolic, enzyme and chromosomal study panels. These blood tests are performed to confirm and rule out genetic disorders associated with pectus carinatum. No genetic disorder is identified.

Finally, the patient has a urine analysis conducted to verify kidney function and rule out diabetes.¹⁵

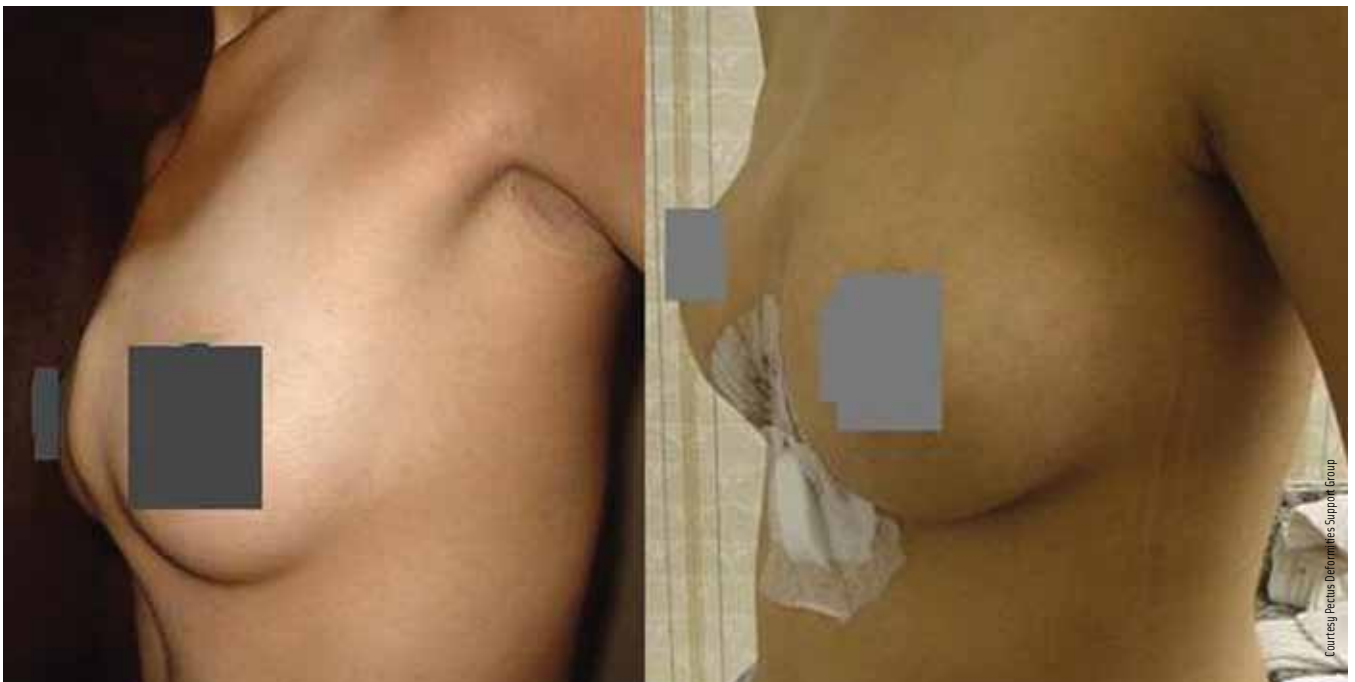PREOPERATIVE PREPARATION

The patient is scheduled for surgery at 13:30 hours. The surgical technologist (ST) and the circulator begin preparing the operating room for the procedure at approximately 12:50 hours. Per the surgeon's preference card, the pediatric instrumentation trays pulled for the case consist of a plastics set, a minor orthopedic set, and several specialty items that are requested by the surgeon for this procedure, including Lane bone holding forceps, a Shaw scalpel, additional Freer elevators (Freer elevators are included in the minor orthopedic set, however, the surgeon uses several during this particular procedure as they become dull, and requested to have extra on hand), and two Davol drain systems.

A major laparotomy module is pulled, which includes the basic items needed for setting up the sterile field, including:

- A back-table cover
- 77 x 108 pediatric drape
- Mayo stand cover
- 32-oz plastic basin
- Lap sponges
- X-ray-detectable sponges
- Bulb syringe
- Large basin
- Specimen cups
- Rigid light handle covers
- Towels
- Emesis basin
- Sterile marking pen
- #15 blades
- Electrosurgical-tip-cleaner pad
- Electrosurgical pencil with needle tip and holster
- Suture garbage bag
- Magnetic needle holder/counter
- Three sterile surgical gowns

Additional sterile items pulled for the procedure include bone wax, adhesive skin closure strips, suction tubing, cord



A lateral view of a 20-year old female before and after having her pectus carinatum surgically repaired.

and blade for Shaw scalpel, and several sutures including 2-0, 3-0, and 4-0 polyglactin 910 RB-1 and 4-0 polyglicaprone 25 CT-1.

At approximately 13:10 the ST began establishing the sterile field, starting by arranging the operating room furniture into place for the procedure and ensuring all items had been pulled for the case prior to opening. The ST opens the major laparotomy pack on the back table and places the instrumentation sets on a prep stand. Once the items are placed, the ST and the circulator don sterile face masks and begin opening the items to establish the sterile field. During this time, the circulator adjusts the room temperature and confirms with the ST what local anesthetic will be used for the procedure, (one percent lidocaine with epinephrine, 1:200,000). Once the back table (laparotomy pack) and the instrumentation sets are opened, the ST proceeds to the scrub sink to perform a surgical scrub, according to facility policy. After the scrub, the ST returns to the operating room and dons his or her gown and gloves. The circulator assists the ST as needed.

Once the ST is gowned and gloved he or she organizes the back table and performs an initial sponges, sharps, and instrument count, according to facility policy, with the circulator. At the conclusion of the initial count, the circulator pours sterile water and normal saline solutions in labeled bowls on the back table and prepares the local anesthetic. At this time, the circulator exits the operating room to get the patient. The ST continues setting up the Mayo stand and back table for the procedure. The anesthesia provider is now present in the room and advises that the patient had been given an epidural of morphine sulfate at 13:00 hours.

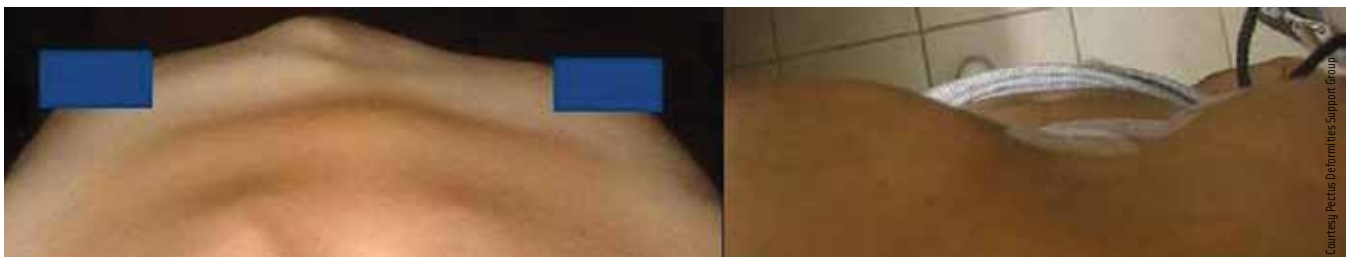At approximately 13:15 the circulator returns to the operating room with the 13-year old male patient, who is conscious and alert. He has been given a preoperative sedative of midazolam (1 mg) to reduce anxiety. Shortly afterward, the surgeon and a resident surgeon enter the oper-

For some patients, additional surgical intervention will be required in the future due to inadequate contracture of the chest wall that resulted in an undesirable cosmetic look. It is for this reason that it is desirable to wait for a child's skeletal system to reach maturity prior to surgical intervention.

ating room and talk briefly with the patient. The surgeon confirms with the ST his or her suture preference and that two Davol drains are available for the procedure.

At 13:25 the patient is moved to the operating table, anesthetized, and intubated by the anesthesia provider. The circulator and the anesthesia provider assist in positioning the patient in supine position with his chest slightly hyperextended with a rolled towel. The patient's head is placed on a foam donut pad with his arms tucked at the sides with a sheet. A small pillow is placed under his knees, and a safety strap is applied. The circulator applies a dispersive electrode pad to the patient's posterior near the sacrum. The anesthesia provider adjusts the operating table height to an optimal level and at a slight reverse Trendelenburg position, as requested by the surgeon.

Once the patient is positioned, the circulator performs a skin prep on the patient's chest, beginning at the incision site and extending out to each side contralaterally, from chin to umbilicus, down to the table sides. Povidone-iodine solution is used as the skin prep agent. During this time, the surgeon and resident proceed out of the operating room to perform a surgical scrub, after which the ST assists them



Superior view of a 20-year old female before and after having her pectus carinatum surgically repaired.

with drying, gowning and gloving.

With the skin prep completed, the ST assists the surgeon with draping the patient. Draping consists of four folded towel drapes secured with Backhaus towel clips and a fenestrated, pediatric chest drape.

At approximately 13:30 hours, the surgeon performs a “time out” according to facility policy. The “time out” procedure verifies the patient’s name, identification number, operative procedure and site (correct surgical site is marked on the patient’s chest with a sterile surgical marking pen). Additionally, it is confirmed that the patient has no known allergies,¹⁵ preoperative medications have been given, and consent has been signed. The ST, circulator, anesthesia provider, and resident acknowledge this information.

The ST moves the Mayo stand and back table into position and begins laying out the electrosurgical pencil, suction, Shaw scalpel and accessory light handles on the operative field and prepares for the intraoperative portion of the procedure.

INTRAOPERATIVE PROCEDURE

The ST places two X-ray-detectable sponges at the operative sight and hands the surgeon the Shaw scalpel. The surgeon begins by making a transverse inframammary incision on the left side of the patient’s chest with the scalpel. The incision is carried down through the dermis, epidermis, and subcutaneous tissues. Hemostasis is achieved with periodic use of the electrosurgical pencil; however, minimal hemorrhaging is seen due to the surgeon’s use of the Shaw scalpel and its cutting and coagulating properties.

As the surgeon continues incising downward through the layers of tissue, the ST prepares the Cobb elevator. Utilizing the Cobb elevator, the surgeon makes a skin flap and elevates it from the pectoral muscles superiorly and inferiorly. The pectoral muscles are then lifted off the costal cartilage on both sides. The surgeon observes that there appear to be five abnormal cartilages on each side of the patient’s rib cage.

The ST retrieves the Cobb elevator and hands the surgeon the Freer elevator and the Lane bone holding forceps. Using the Freer elevator and the Lane bone forceps intermittently, the surgeon proceeds to remove each cartilage by incising the perichondrium, stripping it off of the cartilage, and then removing the cartilage, leaving behind the perichondrial bed.¹⁵ The ST provides the surgeon with the electrosurgical pencil and suction as needed. As pieces of cartilage are removed, they are placed in a sterile specimen

cup. All pieces of cartilage are placed in one sterile specimen cup per the surgeon’s request.

The surgeon removes all 10 of the abnormal costal cartilages and then proceeds to pull the sternum down into a more anatomical position. The ST hands the surgeon a prepared 2-0 polyglactin 910 RB-1 suture on an 8” Crile-Wood needle holder. The surgeon takes the suture and begins to imbricate the costal beds. This method of overlapping the cartilages and retracting the pectoral muscles pulls the sternum downward and contracts the thoracic wall. The ST provides the electrosurgical pencil, irrigation, suction and suture scissors as requested throughout this process. Care is taken to change out soiled X-ray-detectable sponges as necessary.

Once the surgeon completes pulling the sternum downward with the suturing technique, the ST prepares two Davol evacuating drainage systems, one 1/4 inch and one 3/16 inch, for use, along with additional 2-0 polyglactin 910 suture to secure the drains. The surgeon takes the 1/4-inch Davol drain and places it under the pectoral muscle. It is then re-approximated and affixed to the periosteum of the sternum using the 2-0 polyglactin 910. The surgeon then takes the 3/16-inch Davol drain and places it in the subcutaneous space. Once the drains are in place, the surgeon closes the skin using 3-0 and 4-0 polyglactin 910 in the subcutaneous tissue, and 4-0 polyglactin 25 in the skin (dermis and epidermis). He or she administers local anesthetic (one percent lidocaine with epinephrine, 1:200,000) at the operative site to provide additional postoperative pain management and hemostasis.

The ST initiates a final count of sharps and sponges with the circulator during the skin closure and prepares the postoperative dressings. A wet and dry sponge is also readied in anticipation of cleaning the operative site once the skin closure is complete.

While the surgeon finishes up the skin closure, the ST ensures all pieces of the cartilage are in the specimen cup securely. The cup is labeled appropriately, according to facility policy, with the patient’s name, identification number, and the name of the specimen contents. This information is verified with the patient’s chart. The cup is then handed off to the circulator, who transports it to pathology in a dry state.

POSTOPERATIVE PROCEDURE

At the completion of the skin closure the surgeon requests a wet and dry X-ray-detectable sponge to clean off the patient’s

operative wound site and to remove any remaining skin prep solution. The ST assists the surgeon with this task. Once the wound has been cleaned, the ST hands the surgeon bacitracin antibiotic ointment (placed on the back of a tissue forceps handle), which the surgeon applies liberally onto the closed suture line. Using smooth Adson tissue forceps, pre-cut adhesive skin closure strips (the strips are cut into thirds per the surgeon's request) are then applied to the site followed by folded, sterile 4x4 dressings and padded tape.

Once the dressings are in place the ST carefully pulls back the Mayo stand and, in keeping with proper sterile technique, pushes the back table several feet away from the operative table as to allow for adequate room to remove drapes, disposable suction tubing and electrical cords from the field and provide space to move the patient to the gurney. After removing the disposable items, the ST removes his or her outer gloves and provides assistance in moving the patient off the operating table to the gurney. Once the patient is securely on the gurney and out of the operating room, the ST begins the postoperative clean up procedure.

All sharps (blades, hypodermic needles, suture needles and electrosurgical pencil tips) are verified with the count board and disposed of properly, according to facility policy, in the sharps container. Dirty instrumentation is separated from clean instrumentation. Dirty, sharp instrumentation is placed in a separated basin with sterile water while non-sharp, dirty instrumentation is placed in another basin with sterile water. Each of the basins is marked, according to facility policy, with the operating room number, the ST's initials, the time of the surgical procedure and the date. Clean instrumentation is returned to its set container with the lid on. All instrumentation is then placed in the dirty case cart. All sponges, disposable towels and items are rolled up in the back table cover and discarded. The facility's postoperative surgical team member (PST) removes the used suction canisters, takes out the waste containers and cleans and mops the operating room to prepare it for the next case. The ST doffs his or her gown and gloves, washes his or her hands and dons new nonsterile gloves. After ensuring all instrumentation is in placed in the case cart, the ST proceeds to the dirty dumb waiter and transfers the items to the facility's sterile processing and distribution center (SPD) for decontamination and sterilization. Upon return, the ST removes the gloves and washes his or her hands again. All unused core supplies are acquired from the operating room and returned to their specified locations in the sterile core.

PATIENT POSTOPERATIVE

At 15:37 hours, the patient arrives at PACU for recovery and stays for approximately one hour. He is in a semi-conscious state upon his arrival, where he is given 10 milligrams of hydrocodone for postoperative pain management. At approximately 16:40, the patient is transferred to his hospital room.¹⁵

The first night post-operatively, the patient reports several episodes of moderate to severe postoperative pain in the chest area. On a scale of one to 10, the patient advises that he is experiencing an eight. Consequently, the patient is given additional hydrocodone the following night to ease his symptoms and help him sleep. On the second postoperative day, the patient's pain has lessened and he is more comfortable than he had been the night before. On day three, the patient has his Davol drains removed and is discharged from the hospital. A two-week postoperative appointment is made for the patient.¹⁵

The patient and his parents are instructed on postsurgical at-home care. They are advised to keep the incision site clean and dry, and dressings are to be changed daily. Any signs of redness, swelling or puckering around the incision site are indications of infection and the parents are directed to contact the doctor immediately if this is the case. The patient is given a breathing treatment machine (spirometer) to improve lung function while healing.

The patient is directed to limit his physical activity level, particularly any twisting movements or rapid elevation of arms over his head for the next four months. The patient is given a list of lower extremity exercises that he is to perform for the next two weeks prior to his next postoperative checkup. He is told that light weights are beneficial for his upper extremities, but was to avoid lifting or carrying anything weighing more than 25 pounds. The patient will not be able to participate in any athletic activities for the next five months. Pain will be managed with ibuprofen and acetaminophen.

SPECIAL CONSIDERATIONS AND COMPLICATIONS

Postoperative complications for a repair of a *pectus carinatum* include hemorrhage, infection, pleural effusion, pneumothorax, keloid scarring and pain. Generally, a patient's hospital stay will be based on postoperative complications and pain management. An average hospital stay for this procedure is anywhere from three to seven days.¹

Although pain was a significant complication in the first night post-op, the patient in this case study showed marked

improvement in tolerance within 24 hours, and therefore his postoperative hospital stay was only three days. At the time of this report, the patient is healing as expected and no complications have been reported as of his last postoperative check up.¹⁵

For some patients, additional surgical intervention will be required in the future due to inadequate contracture of the chest wall that resulted in an undesirable cosmetic look. It is for this reason that it is desirable to wait for a child's skeletal system to reach maturity prior to surgical intervention.⁹

CONCLUSION

Aside from the apparent physiological problems resulting from a pectus abnormality, pediatric patients can have considerable emotional issues that affect their daily lives. As with the patient in the case study, although he did suffer occasional pain and discomfort related to the pectus carinatum, and consequently physical activities were cut short due to dyspnea, there was clearly a negative social impact that the deformity was having on his life. His self image and confidence were causing him to isolate from his peers and family members, and he was beginning to show progressive signs of clinical depression. Already having a past medical history of psychiatric behavioral issues, it was apparent that this physical abnormality was causing additional emotional stress on the child that could possibly have devastating consequences in the future if surgical intervention was not taken.

ABOUT THE AUTHOR



Tracy Cheek is a surgical technology student at San Joaquin Valley College in Fresno, California. Prior to going back to school to pursue this career, she spent 21 years in the fire service, working for the California Department of Forestry and Fire Protection. She is currently in her clinical externship at Children's Hospital of Central California and Community Regional Medical Center in Fresno, California.

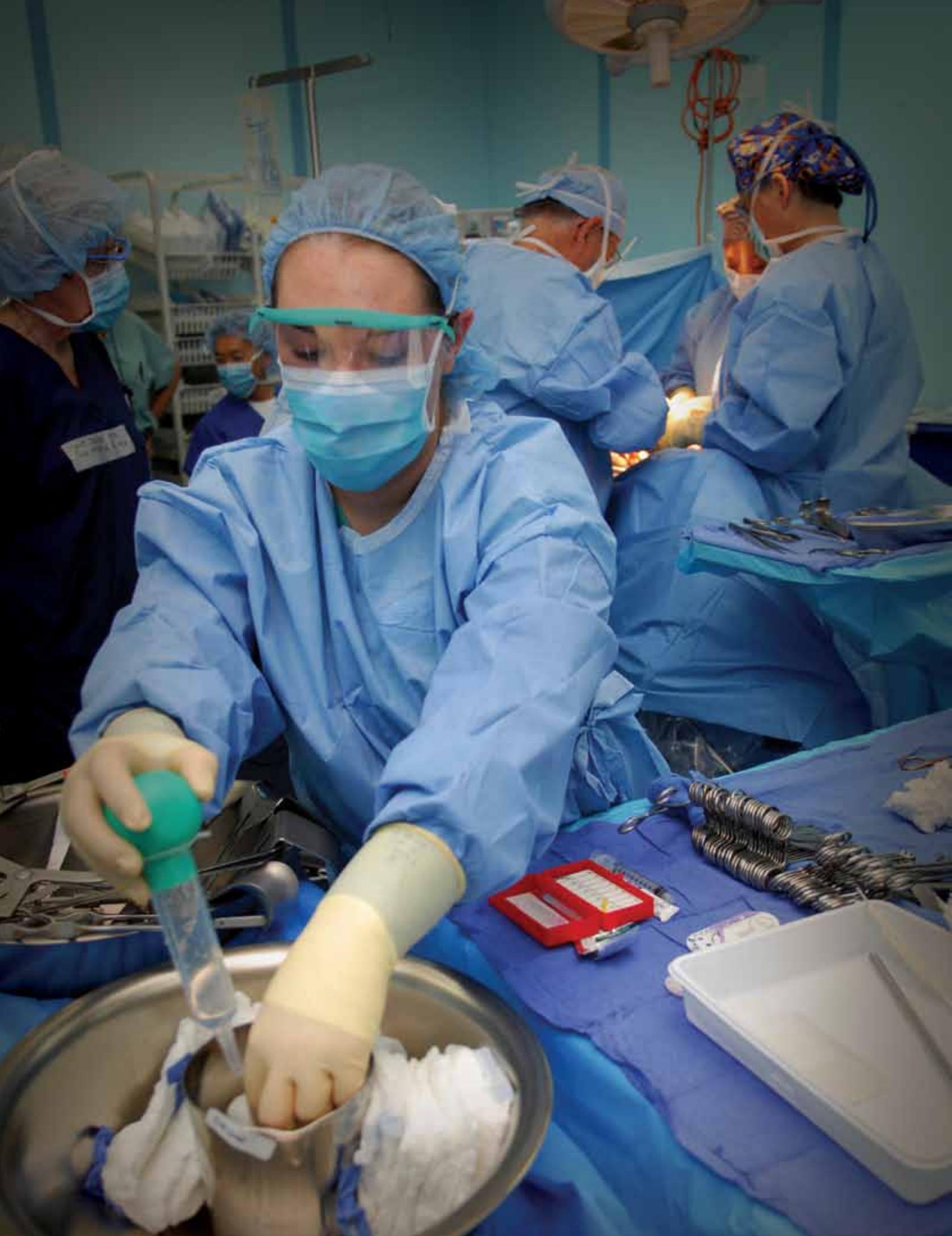References

1. Seattle Children's Hospital Research and Foundation (July 2010), *Pectus carinatum*. Retrieved on July 30, 2010 from <http://www.seattlechildrens.org/medical-conditions/bone-joint-muscle-conditions/pectus-carinatum/>.
2. UK Pectus Excavatum and Pectus Carinatum Information (2010), *Surgical treatment*. Retrieved on July 30, 2010 from <http://www.pectus.org/surgical.htm>.
3. Cataletto, M. (August 25, 2008). Pectus carinatum. Retrieved June 30, 2010 from <http://emedicine.medscape.com/article>.
4. Family Practice Notebook (2010), *Pectus carinatum*. Retrieved July 30, 2010 from <http://www.fpnotebook.com/lung/Exam/>.
5. Rothrock, J. (2007). *Alexander's care of the patient in surgery*, 13 ed, St. Louis, MI: Mosbey, Elsevier.
6. Cohen, B. (2009). *Memmler's the human body in health and disease*, 11th ed, USA: Lippincott, Williams, and Wilkins.
7. Wisegeek, (2010), What is pectus carinatum. Retrieved July 30, 2010 from <http://www.wisegeek.com/what-is-pectus-carinatum.htm>.
8. US National Library of Medicine. 2010. "Trisomy 18." Medline Plus. Accessed: August 18, 2010. Available at: <http://www.nlm.nih.gov/medlineplus/ency/article/001661.htm>.
9. Medline Plus (June 25, 2010), Pectus carinatum. Retrieved on July 2, 2010 from <http://www.nlm.nih.gov/medlineplus/ency/article/003321.htm>.
10. US National Library of Medicine. 2010. "Marfan syndrome." Medline Plus. Accessed: August 18, 2010. Available at: <http://www.nlm.nih.gov/medlineplus/ency/article/000418.htm>.
11. US National Library of Medicine. 2010. "Homocystinuria." Medline Plus. Accessed: August 18, 2010. Available at: <http://www.nlm.nih.gov/medlineplus/ency/article/001199.htm>.
12. US National Library of Medicine. 2010. "Morquio syndrome." Medline Plus. Accessed: August 18, 2010. Available at: <http://www.nlm.nih.gov/medlineplus/ency/article/001206.htm>.
13. US National Library of Medicine. 2010. "Multiple lentiginos syndrome." Medline Plus. Accessed: August 18, 2010. Available at: <http://www.nlm.nih.gov/medlineplus/ency/article/001473.htm>.
14. US National Library of Medicine. 2010. "Osteogenesis Imperfecta." Medline Plus. Accessed: August 18, 2010. Available at: <http://www.nlm.nih.gov/medlineplus/osteogenesisimperfecta.html>.
15. Children's Hospital of Central California. Patient Chart. 2010. Unpublished patient chart. Cincinnati Children's (2010), Chest/lungs diagnoses and conditions. Retrieved July 30, 2010. Available at: <http://www.cincinnatichildrens.org/health/info/chest/diagnose/pectus-carinatum.htm>.

Additional Resources

- Frey, K. (2008). *Surgical technology for the surgical technologist: a positive care approach*, 3rd ed, USA: Delmar Cengage Learning.
- Goldman, M. (2000). *Pocket guide to the operating room*, 3rd ed, Philadelphia, PA: F.A. Davis Company.

*Westcoast Brace & Limb, 5311 E Fletcher Ave, Tampa, FL 33617, 813-985-5000



Vertical Sleeve Gastrectomy

By Margaret Rodriguez, CST, CFA, FAST

Aeger primo is the guiding principle under which surgical technologists and first assistants practice. Nothing exemplifies that very principle more than when the practitioner becomes the patient. There is an interesting dichotomy of feeling fully knowledgeable about a procedure, all its components and how well cases typically go, but simultaneously being completely unnerved by the awareness of all that can go wrong. On December 29, 2009 this author took that leap of faith that each and every one of her patients takes when undergoing a surgical procedure. In this article, the author documents the issues faced by bariatric patients in general and the technical components of her procedure in particular.

HISTORY

The May 2009, issue of *The Surgical Technologist* highlights an article by Karen L Chambers, CST, entitled “Obesity: An American Epidemic.”¹ Identified by the Centers for Disease Control and Prevention (CDC) as the number-one health threat in the United States, obesity has come out of the proverbial closet and is now an issue that many people face, either for themselves or someone they know, and as a society that is at risk of reversing and reducing life-expectancy statistics.²

Chambers’ article mentions vertical banded gastroplasty, also known as “stomach stapling,” as a technique that has fallen out of favor since its development in the 1970s. There is a newer version of this procedure that is currently in use and is increasing in popularity called vertical sleeve gastrectomy (VSG). This surgical technique, though still considered somewhat investigational, was originally developed as a type of staging procedure for morbidly obese patients considered too ill or physiologically unstable to

LEARNING OBJECTIVES

- ▲ Review the selection criteria for this procedure
- ▲ Evaluate the procedural risks and complications of VSG
- ▲ Compare and contrast the different options for bariatric surgery
- ▲ Examine the step-by-step procedure of VSG
- ▲ Assess the risks and possible complications of the VSG procedure

undergo the Roux-en-Y gastric bypass. The vertical sleeve gastrectomy allowed for conversion to the gastric bypass at a later date when the patient had reduced their body mass index (BMI) and, by extension, their surgical risk.³ Unlike banding procedures, VSG is permanent and irreversible.

SELECTION CRITERIA

The vertical sleeve gastrectomy, in concept, is quite simple. It is a restrictive mechanical alteration in the digestive tract that actually removes up to 85-90 percent of the stomach, depending on the patient's needs and surgeon's discretion. No rerouting of the intestines takes place, as in gastric bypass, and no foreign bodies are implanted, as in banding procedures. The stomach is converted into a small, banana-shaped tube (sleeve) that changes neither the upper nor lower sphincters. The segment of the lesser curvature of the stomach that remains, between the esophageal sphincter and the pyloric sphincter, is more resistant to the stretching that the gastric body and fundus allow following ingestion of potentially-large amounts of food. For these and other reasons, vertical sleeve gastrectomy is gaining popularity and becoming an option of choice for patients who have a BMI less than 40.⁴

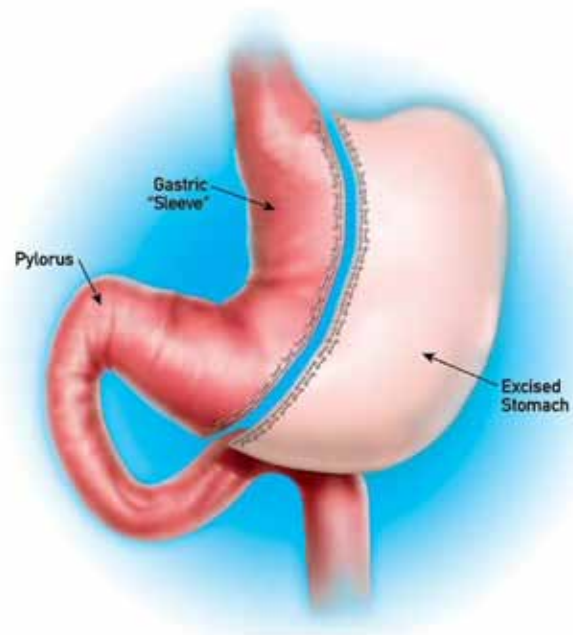
Comorbid conditions may become the factor that will allow a patient with a lower BMI to qualify for a bariatric procedure. Examples of comorbid conditions are pre-diabetes, diabetes, hypertension, dyslipidemia, sleep apnea, venous stasis disease, gastroesophageal reflux, and chronic joint pain or osteoarthritis. The severity of comorbid conditions is balanced against the individual patient's age and BMI to determine the appropriateness of bariatric surgical intervention.⁵

The presence of diseases considered comorbid to obesity are common and, in many cases, expected. Surgeons treating bariatric patients require extensive medical history information from patients and their primary care physicians (PCPs). A pattern of failed attempts at weight loss is considered one of the determining criteria for patients considering weight loss surgery. Some PCPs will begin a dialogue with their patients about the surgical options available to them, but a large number of patients initiate the process of information gathering on their own. Family practice or internal medicine physicians prescribe the tried and true "exercise, watch your diet and lose weight." The comorbid diseases that arise require medical treatment, so a regimen of prescriptions starts. Prescriptions carry risks of their own, and the rollercoaster ride starts for patients who suffer

from medical problems that arise from the body's inability to manage extreme amounts of excess weight. The dosage of the drugs to treat comorbid conditions may have to be adjusted to higher levels because of the physiologic mechanisms of absorption and bioavailability in the obese patient.

Patients with conditions such as inflammatory bowel disease, or who have had previous intestinal procedures, as well as smokers and those on anticoagulation medications may be better candidates for VSG than for bypass. Sleeve gastrectomy is contraindicated in patients with a history of gastric cancer. Patients with a large hiatal hernia with severe gastroesophageal reflux disease (GERD) require either simultaneous or prior repair due to the alteration of the stomach anatomy.

A barrier to selection of VSG as an option is its relatively new status as an in-between option in bariatric surgery. Surgeons and insurance carriers in the United States favor the better-known gastric bypass and band procedures. There are longer-term outcomes data in the literature and years of surgeons' experiential histories and skill base. According to www.laparoscopy.com, there is no surgical procedure code (CPT) at this time for the vertical sleeve gastrectomy. Patients who have the ability to self-pay may opt for the VSG, but must be aware that they will be responsible for all costs incurred if there are postoperative complications requiring additional surgery. Insurance-covered gastric bypass and banding procedures have higher incidence of



A basic illustration of the VSG procedure.

re-operation. The current cost of the VSG at the Cleveland Clinic is approximately \$19,000, making it slightly more expensive than laparoscopic banding, but with less likelihood of requiring any further surgical intervention.⁶

A barrier to selection of VSG as an option is its relatively new status as an in-between option in bariatric surgery. Surgeons and insurance carriers in the United States favor the better-known gastric bypass and band procedures.

PROCEDURAL RISKS AND COMPLICATIONS

Laparoscopic VSG shares all of the same risks of any other laparoscopic procedure. Among surgeons who perform bariatric procedures, there is debate and cautionary tales regarding sleeve gastrectomy. Jeffery L Lord, MD, director of MIS and bariatrics at the Sacred Heart Institute of Surgical Weight Loss in Pensacola, Florida, and chairman of the professional liability committee of the American Society for Metabolic and Bariatric Surgery has expressed concerns over the rise in popularity of VSG and its use in lower-BMI patients.⁶

His particular concerns involve the possible complications of a leak at the esophageal-gastric junction during sleeve gastrectomy, the learning curve of surgeons, and their capacity to deal with treating those leaks. He has seen postoperative complications requiring secondary operations to treat leaks resulting in pleural effusion, sepsis, wound infections and fistulas. Dr Lord fears the rise in the percentage of leakage complications corresponds with the rapid increase of VSGs performed. He states, “To have someone with minimal comorbidities get a sleeve because it’s a new, ‘gee-whiz’ option? I think that’s a bad choice. We don’t even know what five or 10-year data shows on it.” Surgeons do agree that regardless of the choice of surgical option for bariatric patients, there should be a multidisciplinary approach taken, surgeons should be proctored and monitored, and procedures should be performed in specialized centers of excellence.⁶

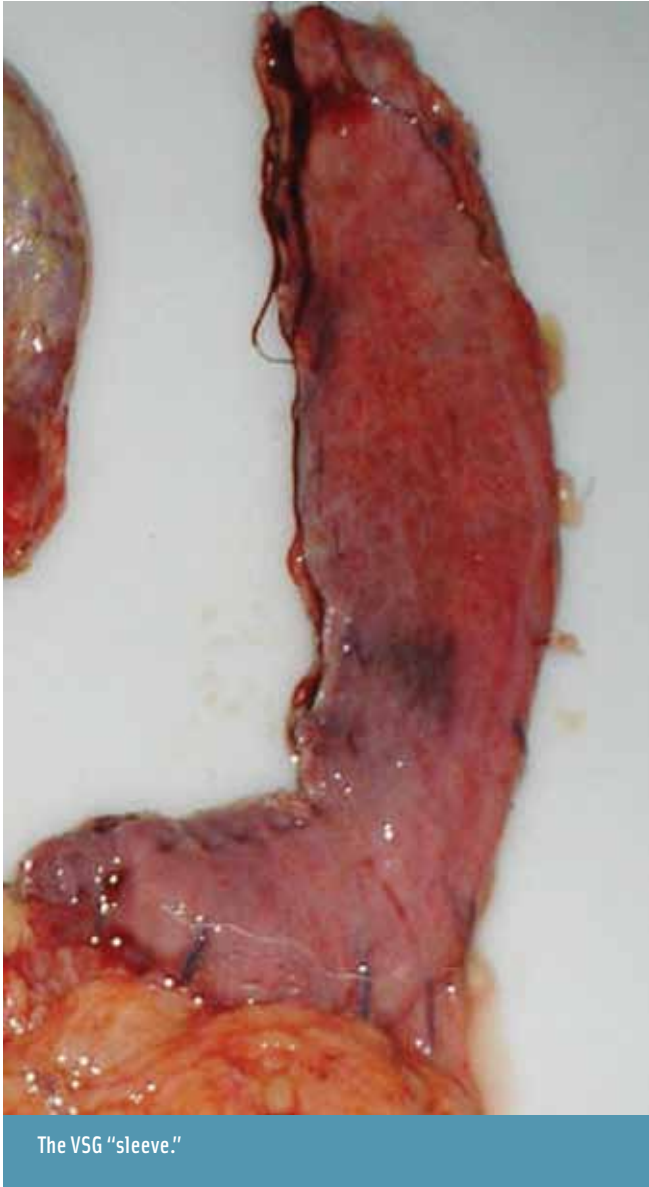
PREOPERATIVE PATIENT PREPARATION

Bariatric patients are required to complete several screening processes to assess their physical and physiological status as well as their psychological stability. The routine blood

chemistries: H&H (hemoglobin and hematocrit); bleeding times (PT, PTT); comprehensive metabolic panel including: blood urea nitrogen (BUN), creatinine, eGFR, sodium, potassium, chloride, carbon dioxide, calcium, total protein, albumin, globulin, albumin/globulin ratio, total bilirubin, alkaline phosphatase, AST and ALT are performed to assess liver and kidney function and potential risks of hemorrhage from long-term use of anti-inflammatory drugs for chronic joint pain. A serum pregnancy test is performed on any pre-menopausal female patients. Routine urinalysis is also done to rule

out potential urinary tract infection. A barium swallow radiology study is ordered to determine if there are any problems with the esophagus and sphincter or swallowing reflexes. It is not uncommon for morbidly obese patients to suffer from gastroesophageal reflux disease (GERD) and less-common problems with erosion or distention of the esophagus or gastric ulcers. Surgeons must decide, based on the individual patient, what the size of the sleeve should ultimately be, but they must first discover from the barium swallow if there will be potential problems with compatibility of the two structures’ lumen size. In addition to the upper GI X-ray, a pre-operative chest X-ray may also be taken to rule out abnormalities in patients with a history of cardiac or pulmonary disease.⁷ In patients without such history, pre-operative chest X-rays are seldom performed. In many cases, an electrocardiogram is done preoperatively. Hypertension is one of the most common comorbid conditions and the stress of excess weight, increased cholesterol and triglycerides, all contribute to potential cardiac instability during laparoscopic bariatric procedures.

Preoperative education with a nutritionist is required for patients who will be permanently changing their relationship with food. Every form of bariatric surgery, permanent or not, can fail if patients are unable, unwilling or ill-prepared to comply with dietary guidelines. The patient is taught to take the time to read product labels and focus on carbohydrates, fat and protein contained in food items. The goal is for patients to take in 64 ounces of water to maintain hydration and help with the feeling of satiety. Muscle tone and collagen in tissues require protein, and the need for protein is enhanced due to the greatly-reduced dietary intake. Patients are given tips on how to increase the amount of protein in their diets, both in foods long-term



The VSG "sleeve."

and in the more immediate postoperative recovery period in the form of protein drinks and shakes. It is recommended that patients begin the protein drinks preoperatively as part of a preoperative liquid diet designed to detoxify and reduce the size of the liver. In the sleeve gastrectomy, intraoperative complications of liver or spleen laceration are possible, especially if the liver is particularly large from a fatty food diet and/or excessive alcohol intake. Sipping of very small amounts (one ounce increments or less) of liquids is stressed in order to prepare the patient for the postoperative change in intake capacity. Sipping also reduces the problem of swallowed air that will cause gastric distention and discomfort. Carbonated drinks will become a thing of the past due to the same problems with gas/air bubbles. Typically, sodas

are high in calories and are of little or no nutritional value, so they are placed on the list of restricted items. Caffeine and alcohol are restricted both preoperatively and postoperatively. Caffeine has a diuretic effect and patients must avoid potential dehydration. In VSG, there is no change in the absorption of food or nutrients, but alcohol has a high calorie count and may be more readily metabolized due to the decreased size of the stomach and time spent there. Foods that are highly processed or fried are also put on the restricted list. Overall, the "common sense" dietary guidelines are stressed and reinforced.

Bariatric surgery is only as successful as the patient's commitment to changing his or her lifestyle—forever. Additionally, a psychiatrist screens patients to determine their understanding of the process, the expected outcomes and, most importantly, the responsibility for compliance. If a potential candidate has the misguided view that the surgical procedure itself is the deciding factor in his or her overall success and that he or she has no real requirement to alter daily habits, then that patient may not be cleared for surgery. A personality profile is also administered to identify potential psychological pitfalls and misunderstandings. If a patient places undue emphasis on the superficial benefits of weight loss or expresses unrealistic goals or results from the procedure, red flags of caution are raised.

Support from family and friends is extremely important for bariatric patients who may have bouts of uncertainty beforehand and need for reaffirmation of their efforts afterwards. It is not just the patient who has to change his or her relationship with food; family members and friends need to take care not to undermine success by pushing someone to eat more, just because they perceive the dietary change to be too drastic, compared to before surgery.

PROCEDURAL STEPS

Editor's Note: There may be variations in sequencing due to surgeons' preferences and training, individual patients' anatomy and physiology, and potentially unanticipated events. The following procedural steps are based on one patient's operative note, as dictated, as well as the author's personal research, including accessing the website OR Live.⁸

The patient is given an intravenous antibiotic for infection prophylaxis. A preoperative enoxaparin sodium injection and bilateral calf-compression devices are used for deep vein thrombosis (DVT) prophylaxis. General anesthesia is administered via endotracheal intubation with the patient in the supine position. The abdomen is prepped with

betadine soap and paint (depending on surgeon's preference and patient's allergy status) from nipple line to upper thighs, laterally bedside to bedside and draped with towels for squaring off the operative area and a large fenestrated laparoscopy sheet with armboard covers and instrument pouches attached.

A 12 mm supraumbilical, off-midline incision is made through the epidermis, dermis and subcutaneous tissues. A 12 mm trocar is placed into the peritoneal cavity under direct visualization and intraabdominal pressure of 15 mmHg is created using carbon dioxide pneumoperitoneum. A 10 mm, 30-degree laparoscope is then placed through the trocar cannula.

Omental adhesions around the umbilicus, secondary to a previous laparoscopic cholecystectomy are lysed. The liver and stomach are visualized and appear normal. Two additional 12 mm trocars are placed at the right and left midabdominal, and two 5 mm trocars are placed at the upper right quadrant epigastric and the left subcostal.

A retractor is inserted through the epigastric port to elevate the left lobe of the liver, securing the diaphragmatic hiatus and exposing the angle of His, which is opened with electrocautery. A measurement is taken from the pylorus about five cm along the greater curve. The greater curve is marked with the electrocautery instrument and the greater omentum is opened. The surgeon enters the lesser sac with an ultrasonic scalpel. The greater omentum is divided off of the greater curve of the stomach and the short gastric vessels are divided, moving cranially toward the left crus. The left crus is then fully mobilized with the ultrasonic scalpel. The anterior and posterior leaflets of the gastrosplenic ligament is divided and the gastrocolic ligament is divided towards the pylorus. This allows complete mobilization of the greater curve of the stomach.

A 60 mm surgical stapler with the green staple cartridge and the buttress seam guard material is fired, partially stapling across the stomach approximately five cm from the pylorus towards the angle of the incisura. A 34-Fr Bougie dilator is passed into the esophagus and stomach, along the lesser curve of the stomach towards the pylorus. A partial gastrectomy is performed with the 34-Fr calibration tube in place with multiple firings of the stapler with the green staple cartridge, using the buttress seam guard material along the Bougie, creating the sleeve gastrectomy. The last two staple firings are done using the blue staple cartridge at the fundus.

After a complete resection of the lateral aspect of the

stomach, the staple line is examined for leaks. In this case, it appears intact with no staple line disruption. A small bowel clamp is placed just distal to the ligament of Treitz. An intraoperative upper GI endoscopy is performed, demonstrating an appropriate-sized sleeve gastrectomy without intraluminal hemorrhage. No evidence of air leakage is seen with the sleeve submerged in saline and hemostasis is also achieved and demonstrated. At this point, the endoscope is withdrawn from the stomach sleeve, the small bowel clamp is removed and the GI endoscope is withdrawn from the stomach and esophagus. The surgeon noted a small hiatal hernia.

Following the removal of the endoscope, irrigation is clear and evacuated and hemostasis is once again achieved. A fibrin tissue sealant is placed along the staple line, which again appears intact. The left midabdominal 15 mm trocar is then removed and the trocar site is expanded and dilated to 24-Fr diameter. The resected portion of the stomach is extracted through the dilated trocar site from the abdominal cavity and sent to pathology for permanent section.

The fascial defect of the dilated left midabdominal incision is closed with 0 polyglactin 910, using the Carter-Thompson device. The wound is thoroughly irrigated with triple-antibiotic solution consisting of neomycin, polymyxin and bacitracin,⁹ and a 19 Fr drain is placed along the gastric sleeve staple line and brought out through the upper right quadrant trocar site and secured with a 2-0 silk suture on a 3/8 circle cutting needle.

All other trocars are removed under direct visualization and no evidence of hemorrhage from the trocar sites

Bariatric surgery is only as successful as the patient's commitment to changing his or her lifestyle—forever. Additionally, a psychiatrist screens patients to determine their understanding of the process, the expected outcomes and, most importantly, the responsibility for compliance.

is noted. The remaining carbon dioxide insufflations gas is released. Fascial sutures are secured and all wounds are irrigated with triple-antibiotic solution. All skin incisions are closed with 4-0 polyglactin 910 in subcuticular fashion. A skin adhesive is applied as skin closure and dressing. The counts are performed and determined to be correct. The patient is then awakened, extubated, transferred to a transport stretcher and taken to the PACU in stable condition.

Some patients are given patient-controlled analgesia (PCA) and usually remain overnight in the hospital. Prior to discharge on the first postoperative day, a Gastrografin swallow radiographic study is performed to assess sleeve status and rule out leaks or obstruction.




ABOUT THE AUTHOR

Margaret Rodriguez, CST, CFA, FAST, currently sits on AST's Board of Directors as vice president. She is also vice-chair of the Council on Surgical & Perioperative Safety. Ms Rodriguez lives in El Paso, Texas, and has been an AST member since 1992.

References

1. Chambers K. "Obesity: An American Epidemic." *The Surgical Technologist*. 2009. Vol 41, No 5.
2. Olshansky J; Passaro D; et al. "A Potential Decline in Life Expectancy in the United States in the 21st Century." *N Engl J Med*. 2005; 352: 1138-1145.
3. ClinicalTrials.gov. March 31, 2009. "Banded Sleeve Gastrectomy Versus Banded Ring Gastric Bypass in Morbidly Obese Patients." ClinicalTrials.gov Identifier: NCT00873405. Available at: <http://clinicaltrials.gov/ct2/show/NCT00873405>.
4. Vertical Sleeve Gastrectomy (VSG) Surgery Forum. 2010. Accessed: March 24, 2010. Available at: <http://www.obesityhelp.com/forums/vsg/mode,pcontent/cmsID,8874/>.
5. Yermilov I; McGory ML; Shekelle PW; Ko CY; Maggard MA. "Appropriateness criteria for bariatric surgery: beyond the NIH guidelines." US National Library of Medicine. 2009. Accessed: Oct 15, 2010. Available at: <http://www.ncbi.nlm.nih.gov/pubmed/19343019>.
6. Pleatman M. "VSG Frequently Asked Questions (FAQ)." *Advanced Laparoscopic Surgery*. 2010. Accessed: Sept 19, 2010. Available at: <http://www.laparoscopy.com/pleatman/vsgfaq.htm>.
7. McMahon H. "Routine Admission and Preoperative Chest Radiography." *The American College of Radiology*. 2008. Accessed: Oct 15, 2010. Available at: http://www.acr.org/SecondaryMainMenuCategories/quality_safety/app_criteria/pdf/ExpertPanelonThoracicImaging/RoutineAdmissionandPreoperativeChestRadiographyDoc6.aspx.
8. ORLive Inc. 2010. "Broadcast: Weight Loss Surgery: Gastric Sleeve." Accessed: Oct 22, 2009. Available at: <http://www.orldive.com/shawneemission/videos/weight-loss-surgery-gastric-sleeve>.
9. Dirschl DR; Wilson FC. "Topical antibiotic irrigation in the prophylaxis of operative wound infections in orthopedic surgery." US National Library of Medicine. 1991. Accessed: Oct 22, 2009. Available at: <http://www.ncbi.nlm.nih.gov/pubmed/1852419>.



Earn CE Credits at Home

You will be awarded continuing education (CE) credits toward your recertification after reading the designated article and completing the test with a score of 70% or better. If you do not pass the test, it will be returned along with your payment.

Send the original answer sheet from the journal and make a copy for your records. If possible use a credit card (debit or credit) for payment. It is a faster option for processing of credits and offers more flexibility for correct payment. When submitting multiple tests, you do not need to submit a separate check for each journal test. You may submit multiple journal tests with one check or money order.

Members this test is also available online at www.ast.org. No stamps or checks and post to your record automatically!

Members: \$6 per credit
(per credit not per test)

Nonmembers: \$10 per credit
(per credit not per test plus the \$400 nonmember fee per submission)

After your credits are processed, AST will send you a letter acknowledging the number of credits that were accepted. Members can also check your CE credit status online with your login information at www.ast.org.

3 WAYS TO SUBMIT YOUR CE CREDITS

Mail to: AST, Member Services, 6 West Dry Creek Circle Ste 200 Littleton, CO 80120-8031

Fax CE credits to: 303-694-9169

E-mail scanned CE credits in PDF format to: memserv@ast.org

For questions please contact Member Services - memserv@ast.org or 800-637-7433, option 3. Business hours: Mon-Fri, 8:00a.m. - 4:30 p.m., mountain time

CE Exams

Radiation Risk

1. **The use of medical imaging ____.**
 - a. Has rapidly increased in the last 20 years
 - b. Has improved diagnosis and treatment
 - c. Increases estimated cancer risks
 - d. All of the above
2. **Radiation that carries enough energy to eject electrons from particles is described as ____.**
 - a. Ionizing
 - b. X-Ray
 - c. Radiosensitive
 - d. All of the above
3. **Radiation effects that are measured by probabilities are considered ____.**
 - a. Deterministic
 - b. Radiosensitive
 - c. Stochastic
 - d. Sieverts
4. **Many estimates of radiation-associated cancer risks are based on ____.**
 - a. Stochastic data
 - b. Radiation absorption rate
 - c. Atomic bomb data
 - d. Size of absorbed dose
5. **Cell radiosensitivity is directly proportional to ____.**
 - a. The degree of cell differentiation
 - b. The rate of cell division
 - c. The cell maturity level
 - d. None of the above
6. **If current rates continue, 1.5-2 percent of future US cancers will be caused by ____.**
 - a. CT scans
 - b. Nuclear medicine scans
 - c. Embolizations
 - d. Coronary angiography
7. **Radiographic procedures can be ordered due to ____.**
 - a. Diagnostic reasons
 - b. Miscommunications
 - c. Medico-legal reasons
 - d. All of the above
8. **Deterministic effects do not include ____.**
 - a. Infertility
 - b. Cancer development
 - c. Skin erythema
 - d. Cataracts
9. **By optimizing technique and protocol, radiation exposure may be ____.**
 - a. Eliminated
 - b. Decreased
 - c. Accurately measured
 - d. Improved
10. **Unnecessary radiation and redundant exams can be eliminated through ____.**
 - a. Technological advances
 - b. Patient cooperation
 - c. Communication
 - d. Proper safety attire

Total Knee Arthroplasty

- 1. The first known total knee implant was made of ____.**
 - a. Ivory
 - b. Plaster of paris
 - c. Wood
 - d. Acrylic
- 2. From 1951 through the early 70s, the ____ was the primary replacement system.**
 - a. Polycentric knee
 - b. Condylar knee
 - c. Walldius hinge
 - d. Geometric prosthesis
- 3. Universal instrumentation was introduced in ____.**
 - a. 1975
 - b. 1987
 - c. 1978
 - d. 1971
- 4. Surgical navigation systems can record ____ intraoperatively.**
 - a. Joint range-of-motion
 - b. Laxity
 - c. Kinematics
 - d. All of the above
- 5. The greatest detriment to early robotics system was ____.**
 - a. Inaccuracy
 - b. Cost and complexity
 - c. Training personnel
 - d. None of the above
- 6. A system with dedicated instruments that are compatible with different implant systems is considered ____.**
 - a. Open platform
 - b. Interchangeable
 - c. Imageless navigation
 - d. Precision 4.0
- 7. The ____ digitizes bony landmarks, monitored by a camera attached to a computer.**
 - a. Optical tracking system
 - b. Fixation pin
 - c. Camera
 - d. None of the above
- 8. The ____ is used to determine a patient's correct standing anatomy.**
 - a. Femoral tracker
 - b. Femoral rotation axis
 - c. Mechanical axis
 - d. Reference for resection level
- 9. Pins are placed with the knee in flexion to reduce ____.**
 - a. Incidence of fracture
 - b. Muscle load
 - c. Collisions with the tibial implant
 - d. All of the above
- 10. When setting up for a total knee using navigation, the ST will need ____.**
 - a. Navigation jigs
 - b. Standard jigs
 - c. All regular total knee instruments
 - d. A & C only

Office-Based Ablations

- ___ is not a conservative method of treating menorrhagia.**
 - Hysterectomy
 - Hormone replacement therapy
 - Oral contraceptives
 - All are conservative methods
- Of the 600,000 hysterectomies performed in the United States, ___ percent are from benign causes.**
 - 75
 - 80
 - 85
 - 90
- ___ is an FDA-approved alternative to hysterectomy.**
 - ThermaChoice®
 - NovaSure®
 - Global Endometrial Ablation
 - All of the above
- ___ is made up of a fan structure layered with copper mesh.**
 - NovaSure®
 - ThermaChoice®
 - Her Option®
 - All of the above
- The only GEA method that allows hysteroscopic visualization during the procedure is ___.**
 - ThermaChoice®
 - Her Option®
 - Hydrothermal ablation
 - B & C
- Producing local anesthesia by localized application of cold is known as ___.**
 - Her Option®
 - Cryoanesthesia
 - Refrigeration anesthesia
 - B & C
- By keeping pressure to 55 mmHg, HTA avoids ___.**
 - Ionic dissociation
 - Fluid flow through the fallopian tubes
 - FDA sanctions
 - All of the above
- The best method for sterilizing scopes in the office is ___.**
 - Steam sterilization
 - Sterile wipes
 - Activated dialdehyde
 - Antimicrobial solution
- A/an ___ consists of a series of injections with a local anesthetic.**
 - Paracervical block
 - Ionic dissociation
 - Refrigeration anesthetic
 - None of the above
- Postoperatively, most patients can expect ___.**
 - Mild, menstrual-like cramps
 - A few weeks of vaginal discharge
 - Significant reduction in menstrual cycle
 - All of the above

Acquired Adult Flatfoot Deformity

- 1. The talonavicular joint is located ____.**
 - a. between the talus and navicular
 - b. on the anterolateral midfoot
 - c. on the dorsal foot, below the ankle
 - d. a & c
- 2. Attaching the posterior tibial tendon to the transferred FDL is called ____.**
 - a. Midfoot dissection
 - b. Tenodesis
 - c. Spring ligament repair
 - d. Ligament fixation
- 3. Surgical procedures to correct flatfoot include ____.**
 - a. Spring ligament reconstruction
 - b. Triple arthrodesis
 - c. Subtalar arthrodesis
 - d. All of the above
- 4. Weight-bearing radiographs should be taken ____.**
 - a. Preoperatively
 - b. Postoperatively
 - c. At the surgeon's discretion
 - d. Only when screws are used
- 5. The most common cause of adult-acquired flatfoot is ____.**
 - a. Lateral hindfoot pain
 - b. Navicular tuberosity
 - c. Posterior tibial tendon dysfunction
 - d. Achilles tendonitis
- 6. The ____ can be used to replace the posterior tibial tendon.**
 - a. Achilles tendon
 - b. FDL tendon
 - c. Peroneal tendon
 - d. None of the above
- 7. ____ can be used to lengthen the lateral column in this surgical alternative.**
 - a. Iliac crest block autograft
 - b. Structural allograft
 - c. FDL transfer
 - d. A & B
- 8. Varying degrees of flatfoot are present in ____ percent of the population**
 - a. 10-25
 - b. 15-30
 - c. More than 50
 - d. Unknown
- 9. In the lateral column lengthening procedure, the "bump" under the ipsilateral hip provides ____.**
 - a. Support for the hip
 - b. Relief of a bony pressure point
 - c. Better access to the lateral side of the foot
 - d. Stability for the thigh
- 10. Patients with painful arthritis or fixed flatfoot with PTTD are usually best served with ____.**
 - a. Motion-sparing procedures
 - b. Subtalar arthrodesis
 - c. Triple arthrodesis
 - d. B & C

Hip Arthroscopy : Femoroacetabular Impingement

- The ___ should include the qualitative nature of discomfort, location, onset and history of trauma/developmental abnormality.**
 - Diagnosis
 - Patient history
 - Treatment
 - Rehabilitation
- Primary portals are placed ___.**
 - Anterior and anterolateral
 - Anterior and posterior
 - Anterolateral and posterolateral
 - Superior and inferior
- A pincer lesion is located on the ___.**
 - Femoral head
 - Femoral head neck junction
 - Acetabular fossa
 - Acetabular rim
- The labrum is made up of ___.**
 - Fibrocartilage
 - Osseous abnormalities
 - Bone
 - Hyaline cartilage
- The ___ is/are located on the femoral head-neck junction.**
 - Cam lesion
 - Pincer lesion
 - Labrum
 - Nerve fibers
- The anterolateral portal penetrates the ___.**
 - Sartorius
 - Rectus femoris
 - Gluteus medius
 - Greater trochanter
- The femoral artery and nerve lie ___ to the anterior portal.**
 - Posterior
 - Medial
 - Lateral
 - Superior
- A type 2 tear is ___.**
 - Detachment or pincer impingement
 - Detachment or cam impingement
 - Intrasubstance tear or pincer impingement
 - Intrasubstance tear or cam impingement
- The anterior portal penetrates the ___.**
 - Sartorius
 - Rectus femoris
 - Gluteus medius
 - Both a & b
- Postoperative rehabilitation includes ___.**
 - Walking or light jogging
 - Rest
 - Crutches
 - Continuous passive motion and physical therapy

Open Thoractomy Approach to Bronchoesophageal Fistula Repair

- Bronchoesophageal fistulae are categorized into ____ typical presentations.**
 - 1
 - 2
 - 3
 - 4
- During embryonic development, the lungs begin to form during gestational week ____.**
 - 2
 - 3
 - 4
 - 5
- Bronchoesophageal fistulae may present secondary to ____.**
 - Hodgkin's lymphoma
 - Certain respiratory irritants
 - Cavitating lesions
 - All of the above
- The ____ is made up of stratified squamous epithelial cells.**
 - Mucosal layer
 - Submucosa
 - Mainstem bronchus
 - Muscularis
- The most common type of fistula is ____.**
 - Type 1
 - H-type
 - Sequestered parenchyma
 - None of the above
- ____ has been proven as an effective surgical method in fistula closure.**
 - Endotracheostomy
 - Open thoracotomy
 - Video-assisted thoracotomy
 - B & C
- According to ease of access to the fistula, the typical patient is preoperatively positioned in either __ or __ position.**
 - Lateral/Trendelenburg
 - Supine/Fowler's
 - Supine/Lateral
 - No proper combination
- An "H-type fistula" refers to a direct connection between the esophagus and the ____.**
 - Tracheal lumen
 - Bronchus
 - Parenchymal tissue
 - None of the above
- Postoperative swallowing evaluations may include ____.**
 - Speech therapy
 - Barium swallow
 - Contrast radiography
 - B & C
- Postoperative complications may include ____.**
 - Hemorrhage
 - Pneumothorax
 - Nosocomial infection
 - All of the above

Platysmaplasty: A Surgical Resolution for the Turkey Neck

1. The ___ covers the external jugular vein in the neck
 - a. Platysma
 - b. Deltoideus
 - c. Superior part of the pectoralis major
 - d. None of the above
2. A ___ is used to separate the subcutaneous layer from the platysma muscle.
 - a. Army/Navy retractor
 - b. Adson forceps
 - c. #15 blade
 - d. Straight Metzenbaum scissor
3. Patients must cease drinking and smoking ___ prior to the procedure.
 - a. 24 hours
 - b. One week
 - c. Two weeks
 - d. One month
4. Patients should wear an elastic bandage around the head and neck for ___.
 - a. 24 hours postoperatively
 - b. 48-72 hours postoperatively
 - c. Up to five days postoperatively
 - d. All of the above
5. Platysmaplasty can be performed using ___ anesthesia.
 - a. General
 - b. IV sedation
 - c. Local
 - d. All of the above
6. The method of suturing for this procedure is based on ___.
 - a. Surgeon's preference
 - b. The amount of fat removed
 - c. The type of suture
 - d. A & B
7. ___ is administered preoperatively to help prevent infection.
 - a. Cleocin
 - b. Cephalexin
 - c. Azithromycin
 - d. Penicillin
8. To prevent bleeding, ___ are not allowed during the first week following surgery.
 - a. Vitamin D
 - b. Aspirin
 - c. Acetaminophen
 - d. A & B
9. Which item is not laid out on the Mayo stand?
 - a. DeBakey tissue forceps
 - b. Elastic bandage
 - c. Head light source
 - d. Surgeon's magnified intense glasses
10. Possible complications from platysmaplasty include ___.
 - a. Hematoma
 - b. Infection
 - c. Seroma
 - d. All of the above

Emergency Cesarean Delivery

- 1. Early practice of Cesarean section often resulted in ____.**
 - a. Fetal bradycardia
 - b. Shoulder dystocia
 - c. Cardiac arrest
 - d. All of the above
- 2. What important innovation helped make the Cesarean delivery safer in the mid-1800s?**
 - a. Anesthesia
 - b. Blood bank
 - c. ESU
 - d. Oxytocin
- 3. The ____ must be present in the LDR during a Code Blue.**
 - a. Patient's next of kin
 - b. Anesthesiologist
 - c. Blood bank
 - d. In-house obstetric attending physician
- 4. The rarest presentation of a breech birth ____.**
 - a. Kneeling breech
 - b. Complete breech
 - c. Frank breech
 - d. Footling breech
- 5. The ____ is placed in charge of obtaining additional supplies in emergency situations.**
 - a. Nurse manager
 - b. Assistant nurse manager
 - c. Patient's primary nurse
 - d. Runner
- 6. During the delivery, the ____ is delivered first.**
 - a. Bottom
 - b. Head
 - c. Feet
 - d. Umbilical cord
- 7. Breech birth risks include ____.**
 - a. Umbilical cord prolapse
 - b. Head entrapment
 - c. Oxygen deprivation
 - d. All of the above
- 8. What size blade does the surgical technologist need to incise the patient's skin?**
 - a. #20
 - b. #11
 - c. #15
 - d. #10
- 9. Which of the following factors is not influential in the occurrence of a breech birth?**
 - a. The sex of the baby
 - b. Multiple fetuses
 - c. Premature labor
 - d. Uterine abnormalities
- 10. Who determines if the patient should be moved to the OR for further patient management and/or closure?**
 - a. Team leader
 - b. Physician
 - c. Medication nurse
 - d. None of the above

Birmingham Hip Resurfacing

- 1. A polyethylene component is used in the ___ system.**
 - a. Total hip replacement
 - b. Birmingham Hip Resurfacing
 - c. Corin Cormet Hip Resurfacing
 - d. CONSERVE® Plus Total Hip Resurfacing
- 2. The acetabular cup should be seated at ___ degrees of inclination and ___ degrees of anteversion.**
 - a. 40/20
 - b. 20/40
 - c. 44/46
 - d. 46/44
- 3. A ___ is placed around the femoral head to protect soft tissues from being contaminated by bony reaming during the femoral preparation.**
 - a. Continuous flow of irrigation
 - b. Sterile 4x4 pad
 - c. Urology drape
 - d. Drain cannula
- 4. Indications for hip resurfacing include ___.**
 - a. Impaired or disrupted blood supply
 - b. Rheumatoid arthritis
 - c. Bone-on-bone articulation
 - d. All of the above
- 5. Why is an X-ray-detectable 4x4 placed in the acetabular cup after it is set?**
 - a. To prevent impingement
 - b. To protect the cup during the next process
 - c. To take X-ray measurements
 - d. All of the above
- 6. There are currently ___ FDA-approved hip resurfacing systems**
 - a. 1
 - b. 2
 - c. 3
 - d. 4
- 7. A/an ___ is used to remove the peripheral ring of femoral head bone.**
 - a. Osteotome
 - b. Cannulated rod
 - c. Rongeur
 - d. Cylindrical reamer
- 8. The best candidates for hip resurfacing are ___.**
 - a. Elderly, inactive patients
 - b. Younger, active patients
 - c. Elderly, moderately-active patients
 - d. Young, relatively inactive patients
- 9. Rehabilitation can begin ___ after surgery.**
 - a. One day
 - b. Three to five days
 - c. One week
 - d. 10-15 days
- 10. "If loading on a particular bone increases, the bone will remodel itself over time to become stronger and resist that sort of loading," is a principle of ___.**
 - a. Science
 - b. Medical theory
 - c. Wolff's Law
 - d. Birmingham Hip Resurfacing

Radical Neck Dissection

- How many modifications to the radical neck dissection are there?**
 - 1
 - 2
 - 3
 - 4
- The ___ is isolated and divided immediately after the external jugular vein.**
 - Anterior trapezius muscle
 - Omohyoid muscle
 - Internal jugular vein
 - Thyrocervical artery
- The first radical neck dissection was performed by ___.**
 - George Crile
 - Hayes Martin
 - Oswaldo Suarez
 - Ettore Bocca
- A ___ is used to protect the carotid artery in the event the patient has undergone previous radiation therapy.**
 - Sterile towel
 - Dermal skin graft
 - Sterile plastic adhesive
 - Fenestrated sheet
- The lymph node groups and additional structures not included in the classic neck dissection are resected in the ___.**
 - Type I modification
 - Type II modification
 - Type III modification
 - Extended radical neck dissection
- Surgical and anesthesia times increase significantly when ___ are used.**
 - Radial forearm flaps
 - Rectus abdominis flaps
 - Microvascular flaps
 - Nerve grafts
- Which medical advancement allowed surgery to become the primary treatment for cancers of the head and neck?**
 - Radical neck dissection
 - Preservation of the spinal accessory nerve
 - Antibiotics
 - All of the above
- Cadaveric tissue grafts may be successful in radical neck dissections because ___.**
 - It can reduce surgical time
 - It can reduce time under anesthetic
 - A previously-irradiated field does not affect its integration
 - All of the above
- After the thyrocervical artery is clamped, divided and ligated, the ___ is/are dissected.**
 - Posterior triangle
 - Cervical and suprascapular arteries
 - Omohyoid muscle
 - None of the above
- A radical neck dissection will generally keep a patient in the hospital for ___.**
 - 3-5 days
 - 5-7 days
 - 7-12 days
 - 13-15 days

Pectus Carinatum : Pigeon Chest

- 1. Pectus Carinatum is characterized by a/an ___ of the sternum.**
 - a. Protrusion
 - b. Indentation
 - c. Fracture
 - d. A & C
- 2. Effects of pigeon chest include ____.**
 - a. Fatigue
 - b. Dyspnea
 - c. Psychological issues
 - d. All of the above
- 3. The surgical procedure can take anywhere from ____.**
 - a. 2-4 hours
 - b. 2-6 hours
 - c. 4-6 hours
 - d. None of the above
- 4. The Ravitch procedure has a ___ percent of satisfaction rate among patients.**
 - a. 97
 - b. 87
 - c. 79
 - d. 92
- 5. Patient's cardiopulmonary function can be affected by ____.**
 - a. Mitral valve prolapsed
 - b. Decreased lung capacity
 - c. Impaired gas exchange in cardiopulmonary system
 - d. All of the above
- 6. The Ravitch procedure does not involve ____.**
 - a. Cutting the costal cartilage
 - b. Using a stabilization bar
 - c. External pressure brace
 - d. Removal of some costal cartilage
- 7. The ratio of males to females that develop pectus carinatum is ____.**
 - a. 3:1
 - b. 7:2
 - c. 6:2
 - d. 5:1
- 8. The principal organs of respiration and circulation are protected by the ____.**
 - a. Thorax
 - b. Pectoral muscles
 - c. Sternum
 - d. Thoracic vertebrae
- 9. The human body has ___ false ribs.**
 - a. Ten
 - b. Six
 - c. Three
 - d. Two
- 10. A chest deformity characterized by an inverted sternum is ____.**
 - a. Pectus carinatum
 - b. Pigeon chest
 - c. Pectus excavatum
 - d. All of the above

Pectus Carinatum: Pigeon Chest – questions cont.

11. The intercostal spaces are located between the ____.
- Lungs
 - Ribs
 - Vertebral bodies
 - Costal cartilages
12. Pectus carinatum can present at which phase of a patient's life?
- At birth
 - Post surgically
 - During growth spurts
 - All of the above
13. Which genetic disorder is not considered a possible cause of pectus carinatum?
- Trisomy 21
 - Morquio syndrome
 - Brittle bone disease
 - Scoliosis
14. One percent lidocaine with epinephrine, 1:200, 000 describes ____.
- Sterile solution
 - General anesthetic
 - Local anesthetic
 - Anxiety medication
15. In the case presented, the patient is in the ____ position for surgery.
- Reverse Trendelenburg
 - Supine
 - Trendelenburg
 - None of the above
16. ____ is/are performed preoperatively to rule out genetic disorders.
- Blood tests
 - Urine analysis
 - X-ray
 - ECG
17. The average hospital stay for this procedure is ____.
- 1-5 days
 - 3-5 days
 - 3-7 days
 - 5-9 days
18. Preoperative diagnostic tests include ____.
- Pulmonary function
 - CT scan
 - Urine analysis
 - All of the above
19. ____ is a genetic disorder in which the body cannot metabolize methionine.
- Homocystinuria
 - Morquio syndrome
 - Trisomy 18
 - Marfan syndrome
20. Twisting movement or rapid elevation of the arms is restricted for ____.
- Two months
 - Four months
 - Six weeks
 - Until postoperative checkup

Vertical Sleeve Gastrectomy

- 1. What separates the VSG from a banding procedure?**
 - a. VSG is permanent
 - b. VSG does not implant a foreign body
 - c. VSG removes most of the stomach
 - d. All of the above
- 2. ___ is a comorbid condition that can qualify a patient for a bariatric procedure.**
 - a. Diabetes
 - b. Obesity
 - c. Elevated BMI
 - d. All of the above
- 3. Sleeve gastrectomy is contraindicated for patients with a history of ___.**
 - a. Diabetes
 - b. GERD
 - c. Gastric cancer
 - d. Sleep apnea
- 4. VSG has a/an ___ risk of re-operation as compared to alternative bariatric procedures.**
 - a. Higher
 - b. Lower
 - c. Equal
 - d. Insufficient data to determine
- 5. One possible complication of VSG is a leak at the esophageal- gastric junction, which can cause ___.**
 - a. Fistulae
 - b. Pleural effusion
 - c. Infections
 - d. All of the above
- 6. Which of these screening processes is not required for all bariatric patients?**
 - a. Blood chemistries
 - b. Comprehensive metabolic panel
 - c. Serum pregnancy test
 - d. All processes are required
- 7. Preoperative education with a ___ is required for VSG patients.**
 - a. Nutritionist
 - b. Physical therapist
 - c. Psychologist
 - d. Personal Trainer
- 8. A total of ___ 12 mm trocars are placed during this procedure.**
 - a. 1
 - b. 2
 - c. 3
 - d. 4
- 9. The sleeve is checked for air leakage by ___.**
 - a. Submersion in saline solution
 - b. Carbon dioxide pneumoperitoneum
 - c. Surgeon's visual examination
 - d. None of the above
- 10. Wounds are irrigated with triple-antibiotic solution, which does not include ___.**
 - a. Bacitracin
 - b. Neomycin
 - c. Polymyxin
 - d. Saline

Answers CE CREDIT PKG 12: 13 CONTINUING EDUCATION CREDITS

Certified Member

AST Member No: _____

Name: _____

Certification No: _____

Address: _____ City: _____ State: _____ Zip: _____

Telephone: _____ Email: _____

CE Credit PKG 12: 13 CONTINUING EDUCATION CREDITS

The fee is \$21. This package is only available to AST & ASA members.

Check Enclosed Yes, I want to pay by Credit Card: Visa MasterCard AmEx

Card# _____ Expiration Date _____ Signature _____

Radiation Risk

a	b	c	d	a	b	c	d			
1.	<input type="checkbox"/>	<input type="checkbox"/>	<input type="checkbox"/>	<input type="checkbox"/>	7.	<input type="checkbox"/>	<input type="checkbox"/>	<input type="checkbox"/>	<input type="checkbox"/>	Mark one box next to each number. Only one correct or best answer will be selected for each question.
2.	<input type="checkbox"/>	<input type="checkbox"/>	<input type="checkbox"/>	<input type="checkbox"/>	8.	<input type="checkbox"/>	<input type="checkbox"/>	<input type="checkbox"/>	<input type="checkbox"/>	
3.	<input type="checkbox"/>	<input type="checkbox"/>	<input type="checkbox"/>	<input type="checkbox"/>	9.	<input type="checkbox"/>	<input type="checkbox"/>	<input type="checkbox"/>	<input type="checkbox"/>	
4.	<input type="checkbox"/>	<input type="checkbox"/>	<input type="checkbox"/>	<input type="checkbox"/>	10.	<input type="checkbox"/>	<input type="checkbox"/>	<input type="checkbox"/>	<input type="checkbox"/>	
5.	<input type="checkbox"/>	<input type="checkbox"/>	<input type="checkbox"/>	<input type="checkbox"/>						
6.	<input type="checkbox"/>	<input type="checkbox"/>	<input type="checkbox"/>	<input type="checkbox"/>						

Total Knee Arthroplasty

a	b	c	d	a	b	c	d			
1.	<input type="checkbox"/>	<input type="checkbox"/>	<input type="checkbox"/>	<input type="checkbox"/>	7.	<input type="checkbox"/>	<input type="checkbox"/>	<input type="checkbox"/>	<input type="checkbox"/>	Mark one box next to each number. Only one correct or best answer will be selected for each question.
2.	<input type="checkbox"/>	<input type="checkbox"/>	<input type="checkbox"/>	<input type="checkbox"/>	8.	<input type="checkbox"/>	<input type="checkbox"/>	<input type="checkbox"/>	<input type="checkbox"/>	
3.	<input type="checkbox"/>	<input type="checkbox"/>	<input type="checkbox"/>	<input type="checkbox"/>	9.	<input type="checkbox"/>	<input type="checkbox"/>	<input type="checkbox"/>	<input type="checkbox"/>	
4.	<input type="checkbox"/>	<input type="checkbox"/>	<input type="checkbox"/>	<input type="checkbox"/>	10.	<input type="checkbox"/>	<input type="checkbox"/>	<input type="checkbox"/>	<input type="checkbox"/>	
5.	<input type="checkbox"/>	<input type="checkbox"/>	<input type="checkbox"/>	<input type="checkbox"/>						
6.	<input type="checkbox"/>	<input type="checkbox"/>	<input type="checkbox"/>	<input type="checkbox"/>						

Office-Based Ablations

a	b	c	d	a	b	c	d			
1.	<input type="checkbox"/>	<input type="checkbox"/>	<input type="checkbox"/>	<input type="checkbox"/>	7.	<input type="checkbox"/>	<input type="checkbox"/>	<input type="checkbox"/>	<input type="checkbox"/>	Mark one box next to each number. Only one correct or best answer will be selected for each question.
2.	<input type="checkbox"/>	<input type="checkbox"/>	<input type="checkbox"/>	<input type="checkbox"/>	8.	<input type="checkbox"/>	<input type="checkbox"/>	<input type="checkbox"/>	<input type="checkbox"/>	
3.	<input type="checkbox"/>	<input type="checkbox"/>	<input type="checkbox"/>	<input type="checkbox"/>	9.	<input type="checkbox"/>	<input type="checkbox"/>	<input type="checkbox"/>	<input type="checkbox"/>	
4.	<input type="checkbox"/>	<input type="checkbox"/>	<input type="checkbox"/>	<input type="checkbox"/>	10.	<input type="checkbox"/>	<input type="checkbox"/>	<input type="checkbox"/>	<input type="checkbox"/>	
5.	<input type="checkbox"/>	<input type="checkbox"/>	<input type="checkbox"/>	<input type="checkbox"/>						
6.	<input type="checkbox"/>	<input type="checkbox"/>	<input type="checkbox"/>	<input type="checkbox"/>						

Acquired Adult Flatfoot Deformity

a	b	c	d	a	b	c	d			Mark one box next to each number. Only one correct or best answer will be selected for each question.
1.	<input type="checkbox"/>	<input type="checkbox"/>	<input type="checkbox"/>	<input type="checkbox"/>	7.	<input type="checkbox"/>	<input type="checkbox"/>	<input type="checkbox"/>	<input type="checkbox"/>	
2.	<input type="checkbox"/>	<input type="checkbox"/>	<input type="checkbox"/>	<input type="checkbox"/>	8.	<input type="checkbox"/>	<input type="checkbox"/>	<input type="checkbox"/>	<input type="checkbox"/>	
3.	<input type="checkbox"/>	<input type="checkbox"/>	<input type="checkbox"/>	<input type="checkbox"/>	9.	<input type="checkbox"/>	<input type="checkbox"/>	<input type="checkbox"/>	<input type="checkbox"/>	
4.	<input type="checkbox"/>	<input type="checkbox"/>	<input type="checkbox"/>	<input type="checkbox"/>	10.	<input type="checkbox"/>	<input type="checkbox"/>	<input type="checkbox"/>	<input type="checkbox"/>	
5.	<input type="checkbox"/>	<input type="checkbox"/>	<input type="checkbox"/>	<input type="checkbox"/>						
6.	<input type="checkbox"/>	<input type="checkbox"/>	<input type="checkbox"/>	<input type="checkbox"/>						

Hip Arthroscopy : Femoroacetabular Impingement

a	b	c	d	a	b	c	d			Mark one box next to each number. Only one correct or best answer will be selected for each question.
1.	<input type="checkbox"/>	<input type="checkbox"/>	<input type="checkbox"/>	<input type="checkbox"/>	7.	<input type="checkbox"/>	<input type="checkbox"/>	<input type="checkbox"/>	<input type="checkbox"/>	
2.	<input type="checkbox"/>	<input type="checkbox"/>	<input type="checkbox"/>	<input type="checkbox"/>	8.	<input type="checkbox"/>	<input type="checkbox"/>	<input type="checkbox"/>	<input type="checkbox"/>	
3.	<input type="checkbox"/>	<input type="checkbox"/>	<input type="checkbox"/>	<input type="checkbox"/>	9.	<input type="checkbox"/>	<input type="checkbox"/>	<input type="checkbox"/>	<input type="checkbox"/>	
4.	<input type="checkbox"/>	<input type="checkbox"/>	<input type="checkbox"/>	<input type="checkbox"/>	10.	<input type="checkbox"/>	<input type="checkbox"/>	<input type="checkbox"/>	<input type="checkbox"/>	
5.	<input type="checkbox"/>	<input type="checkbox"/>	<input type="checkbox"/>	<input type="checkbox"/>						
6.	<input type="checkbox"/>	<input type="checkbox"/>	<input type="checkbox"/>	<input type="checkbox"/>						

Open Thoractomy Approach Brochoesophageal Fistula Repair

a	b	c	d	a	b	c	d			Mark one box next to each number. Only one correct or best answer will be selected for each question.
1.	<input type="checkbox"/>	<input type="checkbox"/>	<input type="checkbox"/>	<input type="checkbox"/>	7.	<input type="checkbox"/>	<input type="checkbox"/>	<input type="checkbox"/>	<input type="checkbox"/>	
2.	<input type="checkbox"/>	<input type="checkbox"/>	<input type="checkbox"/>	<input type="checkbox"/>	8.	<input type="checkbox"/>	<input type="checkbox"/>	<input type="checkbox"/>	<input type="checkbox"/>	
3.	<input type="checkbox"/>	<input type="checkbox"/>	<input type="checkbox"/>	<input type="checkbox"/>	9.	<input type="checkbox"/>	<input type="checkbox"/>	<input type="checkbox"/>	<input type="checkbox"/>	
4.	<input type="checkbox"/>	<input type="checkbox"/>	<input type="checkbox"/>	<input type="checkbox"/>	10.	<input type="checkbox"/>	<input type="checkbox"/>	<input type="checkbox"/>	<input type="checkbox"/>	
5.	<input type="checkbox"/>	<input type="checkbox"/>	<input type="checkbox"/>	<input type="checkbox"/>						
6.	<input type="checkbox"/>	<input type="checkbox"/>	<input type="checkbox"/>	<input type="checkbox"/>						

Platysmaplasty: A Surgical Resolution for the Turkey Neck

a	b	c	d	a	b	c	d			Mark one box next to each number. Only one correct or best answer will be selected for each question.
1.	<input type="checkbox"/>	<input type="checkbox"/>	<input type="checkbox"/>	<input type="checkbox"/>	7.	<input type="checkbox"/>	<input type="checkbox"/>	<input type="checkbox"/>	<input type="checkbox"/>	
2.	<input type="checkbox"/>	<input type="checkbox"/>	<input type="checkbox"/>	<input type="checkbox"/>	8.	<input type="checkbox"/>	<input type="checkbox"/>	<input type="checkbox"/>	<input type="checkbox"/>	
3.	<input type="checkbox"/>	<input type="checkbox"/>	<input type="checkbox"/>	<input type="checkbox"/>	9.	<input type="checkbox"/>	<input type="checkbox"/>	<input type="checkbox"/>	<input type="checkbox"/>	
4.	<input type="checkbox"/>	<input type="checkbox"/>	<input type="checkbox"/>	<input type="checkbox"/>	10.	<input type="checkbox"/>	<input type="checkbox"/>	<input type="checkbox"/>	<input type="checkbox"/>	
5.	<input type="checkbox"/>	<input type="checkbox"/>	<input type="checkbox"/>	<input type="checkbox"/>						
6.	<input type="checkbox"/>	<input type="checkbox"/>	<input type="checkbox"/>	<input type="checkbox"/>						

Emergency Cesarean Delivery

a	b	c	d	a	b	c	d			Mark one box next to each number. Only one correct or best answer will be selected for each question.
1.	<input type="checkbox"/>	<input type="checkbox"/>	<input type="checkbox"/>	<input type="checkbox"/>	7.	<input type="checkbox"/>	<input type="checkbox"/>	<input type="checkbox"/>	<input type="checkbox"/>	
2.	<input type="checkbox"/>	<input type="checkbox"/>	<input type="checkbox"/>	<input type="checkbox"/>	8.	<input type="checkbox"/>	<input type="checkbox"/>	<input type="checkbox"/>	<input type="checkbox"/>	
3.	<input type="checkbox"/>	<input type="checkbox"/>	<input type="checkbox"/>	<input type="checkbox"/>	9.	<input type="checkbox"/>	<input type="checkbox"/>	<input type="checkbox"/>	<input type="checkbox"/>	
4.	<input type="checkbox"/>	<input type="checkbox"/>	<input type="checkbox"/>	<input type="checkbox"/>	10.	<input type="checkbox"/>	<input type="checkbox"/>	<input type="checkbox"/>	<input type="checkbox"/>	
5.	<input type="checkbox"/>	<input type="checkbox"/>	<input type="checkbox"/>	<input type="checkbox"/>						
6.	<input type="checkbox"/>	<input type="checkbox"/>	<input type="checkbox"/>	<input type="checkbox"/>						

Birmingham Hip Resurfacing

a	b	c	d	a	b	c	d			
1.	<input type="checkbox"/>	<input type="checkbox"/>	<input type="checkbox"/>	<input type="checkbox"/>	7.	<input type="checkbox"/>	<input type="checkbox"/>	<input type="checkbox"/>	<input type="checkbox"/>	Mark one box next to each number. Only one correct or best answer will be selected for each question.
2.	<input type="checkbox"/>	<input type="checkbox"/>	<input type="checkbox"/>	<input type="checkbox"/>	8.	<input type="checkbox"/>	<input type="checkbox"/>	<input type="checkbox"/>	<input type="checkbox"/>	
3.	<input type="checkbox"/>	<input type="checkbox"/>	<input type="checkbox"/>	<input type="checkbox"/>	9.	<input type="checkbox"/>	<input type="checkbox"/>	<input type="checkbox"/>	<input type="checkbox"/>	
4.	<input type="checkbox"/>	<input type="checkbox"/>	<input type="checkbox"/>	<input type="checkbox"/>	10.	<input type="checkbox"/>	<input type="checkbox"/>	<input type="checkbox"/>	<input type="checkbox"/>	
5.	<input type="checkbox"/>	<input type="checkbox"/>	<input type="checkbox"/>	<input type="checkbox"/>						
6.	<input type="checkbox"/>	<input type="checkbox"/>	<input type="checkbox"/>	<input type="checkbox"/>						

Radical Neck Dissection

a	b	c	d	a	b	c	d			
1.	<input type="checkbox"/>	<input type="checkbox"/>	<input type="checkbox"/>	<input type="checkbox"/>	7.	<input type="checkbox"/>	<input type="checkbox"/>	<input type="checkbox"/>	<input type="checkbox"/>	Mark one box next to each number. Only one correct or best answer will be selected for each question.
2.	<input type="checkbox"/>	<input type="checkbox"/>	<input type="checkbox"/>	<input type="checkbox"/>	8.	<input type="checkbox"/>	<input type="checkbox"/>	<input type="checkbox"/>	<input type="checkbox"/>	
3.	<input type="checkbox"/>	<input type="checkbox"/>	<input type="checkbox"/>	<input type="checkbox"/>	9.	<input type="checkbox"/>	<input type="checkbox"/>	<input type="checkbox"/>	<input type="checkbox"/>	
4.	<input type="checkbox"/>	<input type="checkbox"/>	<input type="checkbox"/>	<input type="checkbox"/>	10.	<input type="checkbox"/>	<input type="checkbox"/>	<input type="checkbox"/>	<input type="checkbox"/>	
5.	<input type="checkbox"/>	<input type="checkbox"/>	<input type="checkbox"/>	<input type="checkbox"/>						
6.	<input type="checkbox"/>	<input type="checkbox"/>	<input type="checkbox"/>	<input type="checkbox"/>						

Pectus Carinatum: Pigeon Chest

a	b	c	d	a	b	c	d	a	b	c	d	a	b	c	d					
1.	<input type="checkbox"/>	<input type="checkbox"/>	<input type="checkbox"/>	<input type="checkbox"/>	7.	<input type="checkbox"/>	<input type="checkbox"/>	<input type="checkbox"/>	<input type="checkbox"/>	13.	<input type="checkbox"/>	<input type="checkbox"/>	<input type="checkbox"/>	<input type="checkbox"/>	19.	<input type="checkbox"/>	<input type="checkbox"/>	<input type="checkbox"/>	<input type="checkbox"/>	Mark one box next to each number. Only one correct or best answer will be selected for each question.
2.	<input type="checkbox"/>	<input type="checkbox"/>	<input type="checkbox"/>	<input type="checkbox"/>	8.	<input type="checkbox"/>	<input type="checkbox"/>	<input type="checkbox"/>	<input type="checkbox"/>	14.	<input type="checkbox"/>	<input type="checkbox"/>	<input type="checkbox"/>	<input type="checkbox"/>	20.	<input type="checkbox"/>	<input type="checkbox"/>	<input type="checkbox"/>	<input type="checkbox"/>	
3.	<input type="checkbox"/>	<input type="checkbox"/>	<input type="checkbox"/>	<input type="checkbox"/>	9.	<input type="checkbox"/>	<input type="checkbox"/>	<input type="checkbox"/>	<input type="checkbox"/>	15.	<input type="checkbox"/>	<input type="checkbox"/>	<input type="checkbox"/>	<input type="checkbox"/>						
4.	<input type="checkbox"/>	<input type="checkbox"/>	<input type="checkbox"/>	<input type="checkbox"/>	10.	<input type="checkbox"/>	<input type="checkbox"/>	<input type="checkbox"/>	<input type="checkbox"/>	16.	<input type="checkbox"/>	<input type="checkbox"/>	<input type="checkbox"/>	<input type="checkbox"/>						
5.	<input type="checkbox"/>	<input type="checkbox"/>	<input type="checkbox"/>	<input type="checkbox"/>	11.	<input type="checkbox"/>	<input type="checkbox"/>	<input type="checkbox"/>	<input type="checkbox"/>	17.	<input type="checkbox"/>	<input type="checkbox"/>	<input type="checkbox"/>	<input type="checkbox"/>						
6.	<input type="checkbox"/>	<input type="checkbox"/>	<input type="checkbox"/>	<input type="checkbox"/>	12.	<input type="checkbox"/>	<input type="checkbox"/>	<input type="checkbox"/>	<input type="checkbox"/>	18.	<input type="checkbox"/>	<input type="checkbox"/>	<input type="checkbox"/>	<input type="checkbox"/>						

Vertical Sleeve Gastrectomy

a	b	c	d	a	b	c	d			
1.	<input type="checkbox"/>	<input type="checkbox"/>	<input type="checkbox"/>	<input type="checkbox"/>	7.	<input type="checkbox"/>	<input type="checkbox"/>	<input type="checkbox"/>	<input type="checkbox"/>	Mark one box next to each number. Only one correct or best answer will be selected for each question.
2.	<input type="checkbox"/>	<input type="checkbox"/>	<input type="checkbox"/>	<input type="checkbox"/>	8.	<input type="checkbox"/>	<input type="checkbox"/>	<input type="checkbox"/>	<input type="checkbox"/>	
3.	<input type="checkbox"/>	<input type="checkbox"/>	<input type="checkbox"/>	<input type="checkbox"/>	9.	<input type="checkbox"/>	<input type="checkbox"/>	<input type="checkbox"/>	<input type="checkbox"/>	
4.	<input type="checkbox"/>	<input type="checkbox"/>	<input type="checkbox"/>	<input type="checkbox"/>	10.	<input type="checkbox"/>	<input type="checkbox"/>	<input type="checkbox"/>	<input type="checkbox"/>	
5.	<input type="checkbox"/>	<input type="checkbox"/>	<input type="checkbox"/>	<input type="checkbox"/>						
6.	<input type="checkbox"/>	<input type="checkbox"/>	<input type="checkbox"/>	<input type="checkbox"/>						